



HAL
open science

Pythium insidiosum: An overview

Wim Gaastra, Len J.A. Lipman, Arthur W.A.M. de Cock, Tim K. Exel,
Raymond B.G. Pegge, Josje Scheurwater, Raquel Vilela, Leonel Mendoza

► **To cite this version:**

Wim Gaastra, Len J.A. Lipman, Arthur W.A.M. de Cock, Tim K. Exel, Raymond B.G. Pegge, et al.. Pythium insidiosum: An overview. *Veterinary Microbiology*, 2010, 146 (1-2), pp.1-10.1016/j.vetmic.2010.07.019 . hal-00636632

HAL Id: hal-00636632

<https://hal.science/hal-00636632>

Submitted on 28 Oct 2011

HAL is a multi-disciplinary open access archive for the deposit and dissemination of scientific research documents, whether they are published or not. The documents may come from teaching and research institutions in France or abroad, or from public or private research centers.

L'archive ouverte pluridisciplinaire **HAL**, est destinée au dépôt et à la diffusion de documents scientifiques de niveau recherche, publiés ou non, émanant des établissements d'enseignement et de recherche français ou étrangers, des laboratoires publics ou privés.

Accepted Manuscript

Title: *Pythium insidiosum*: An overview

Authors: Wim Gaastra, Len J.A. Lipman, Arthur W.A.M. De Cock, Tim K. Exel, Raymond B.G. Pegge, Josje Scheurwater, Raquel Vilela, Leonel Mendoza



PII: S0378-1135(10)00354-8
DOI: doi:10.1016/j.vetmic.2010.07.019
Reference: VETMIC 4975

To appear in: *VETMIC*

Received date: 20-4-2010
Revised date: 19-7-2010
Accepted date: 19-7-2010

Please cite this article as: Gaastra, W., Lipman, L.J.A., De Cock, A.W.A.M., Exel, T.K., Pegge, R.B.G., Scheurwater, J., Vilela, R., Mendoza, L., *Pythium insidiosum*: An overview, *Veterinary Microbiology* (2010), doi:10.1016/j.vetmic.2010.07.019

This is a PDF file of an unedited manuscript that has been accepted for publication. As a service to our customers we are providing this early version of the manuscript. The manuscript will undergo copyediting, typesetting, and review of the resulting proof before it is published in its final form. Please note that during the production process errors may be discovered which could affect the content, and all legal disclaimers that apply to the journal pertain.

1 **Title: *Pythium insidiosum*: An overview**

2

3 Type of article: **Review**

4 Authors: Wim Gaastra¹, Len J. A. Lipman^{2*}, Arthur W.A.M. De Cock³, Tim K. Exel²,
5 Raymond B.G. Pegge², Josje Scheurwater², Raquel Vilela⁴, Leonel Mendoza^{4,5}.

6

7 ¹ Department of Infectious Diseases and Immunology, Faculty of Veterinary Medicine,
8 Utrecht University, The Netherlands.

9

10 ² Division of Public Health and Food Safety, Institute for Risk Assessment Sciences, Utrecht
11 University, The Netherlands.

12

13 ³ CBS-KNAW, Fungal Biodiversity Centre, Utrecht, The Netherlands

14

15 ⁴ Biomedical Laboratory Diagnostics, Michigan State University, East Lansing, USA.

16

17 ⁵ Microbiology and Molecular Genetics, Michigan State University, East Lansing, USA.

18

19 *Corresponding Author: Division of Public Health and Food Safety, Institute for Risk
20 Assessment Sciences, Utrecht University, Yalelaan 2, 3508 TD Utrecht, The Netherlands, Tel.
21 31-302535342; E-mail: L.J.A.Lipman@iras.uu.nl

22

23

24

25

26 Keywords: *Pythium insidiosum*, pythiosis, oomycete, immunotherapy.

27

28

29

30

31

32

33

34

35

36

37

38

39 Abstract

40

41 *Pythium insidiosum* is an oomycete pathogenic in mammals. The infection occurs
42 mainly in tropical and subtropical areas, particularly in horses, dogs and humans. Infection is
43 acquired through small wounds via contact with water that contains motile zoospores or other
44 propagules (zoospores or hyphae). The disease, though described as emerging has in fact
45 already been described since 1884. Depending on the site of entry, infection can lead to
46 different forms of pythiosis i.e. a cutaneous, vascular, ocular, gastrointestinal and a systemic
47 form, which is rarely seen. The infection is not contagious; no animal-animal or animal-
48 human transmission has been reported so far. Therapy includes radical surgery, antifungal
49 drugs, immunotherapy or a combination of these therapies. The prevention to contract the
50 disease in endemic areas is difficult. Avoiding stagnant waters could be of help, although the
51 presence of *P. insidiosum* on grass and soil in enzootic areas renders this practice useless.

52

53

54 Introduction

55 *Pythium insidiosum* is the only etiologic agent of pythiosis in mammals. Most cases of
56 pythiosis have been reported in dogs, horses and humans. Only sporadic cases in other
57 animals, such as calves (Pérez et al., 2005), cats (Miller et al., 1985, Thomas and Lewis, 1998,
58 Rakich et al., 2005), sheep (Miller et al., 1985, Tabosa et al., 2004, Santurio et al., 2008), a
59 bird (Pesavento et al., 2008) and tropical animals held in captivity (Camus et al., 2004,
60 Wellahan et al., 2004, Buergelt et al., 2006) are known. Pythiosis is a rarely occurring, non-
61 transmissible disease traditionally found in tropical, subtropical and temperate regions (de
62 Cock et al. 1987, Mendoza et al., 1993, Mendoza, 2005). Recently however, pythiosis was
63 also observed in California and Arizona, where the climate does not fit this description. These
64 observations might indicate that the environmental niche for *P. insidiosum* is expanding,
65 probably as a consequence of environmental changes like deliberate flooding of rice fields or
66 irrigated landscape development (Berryessa et al., 2008, White et al., 2008). In Thailand
67 pythiosis is considered to be endemic. Pythiosis in humans is life-threatening with high rates
68 of morbidity and mortality, especially in regions with a lack of tools for early diagnosis and
69 effective treatment. While pythiosis is often described as an emerging disease (Laohapensang,
70 et al., 2009), the disease was already described in 1884 by British veterinarians working with
71 horses in India (Smith, 1884).

72 The agent causing the disease (at that time named *Hyphomycosis destruens equi*) was
73 isolated for the first time in 1901 by Dutch scientists working with horses in Indonesia and

74 again in 1924 by another Dutch (de Haan and Hoogkamer, 1901, Witkamp 1924). The disease
75 has been known under various other names: bursattee or bursatte (derived from the Indian
76 word Burus, Bursator or Bausette which means rainy season), espundia (Latin America),
77 equine phycomycosis (Australia, USA), granular dermatitidis (Japan), hyphomycosis
78 *destruens equi* (Indonesia), leeches (USA), swamp cancer (Australia, USA) and summer sores
79 (Australia, Latin America, USA) (Kerr, 1829, Fish, 1895, Witkamp, 1924, Gonzalez and
80 Ruiz, 1975, Ichitani and Amemiya, 1980).

81 The fungus-like nature of the causal agent of the disease was probably first reported by Smith
82 (1884) and Drouin (1896). By lack of sporulation the agent could not be identified and it did
83 not get a name until 1961 when Bridges and Emmons (1961) named the organism
84 *Hyphomyces destruens*. This name was derived from the name of the disease Hyphomycosis
85 *destruens* which was introduced by de Haan and Hoogkamer (1901) and later extended to
86 Hyphomycosis *destruens equi* by De Haan (1902). However, the name *H. destruens* was not
87 validly published and lacked a Latin description and the designation of a type. Bridges and
88 Emmons called the disease phycomycosis because they thought the organism was a
89 zygomycete, probably *Mortierella*. Austwick and Copland (1974) observed zoospore
90 development when cultures grown on Sabouraud dextrose agar were transferred to an aqueous
91 medium. They concluded that the *H. destruens* actually belonged to the Oomycete genus
92 *Pythium*. Based on this discovery, Chandler et al (1980) proposed the term pythiosis for the
93 disease. In 1980, Ichitani and Amemiya (1980) isolated a *Pythium* sp. from a diseased horse
94 and found it to be morphologically similar to *Pythium gracile* Schenk (Amemiya, 1982).
95 However, *P. gracile* is a poorly described species of which the identity cannot be verified.
96 Moreover, it was isolated from algae in Germany, where pythiosis does not occur. The
97 oomycete was formally described as *Pythium insidiosum* when sexual sporulation was
98 observed by De Cock et al (1987). Almost simultaneously Shipton (1987) proposed the
99 binomial *Pythium destruens* for a strain isolated from an Australian horse with pythiosis.
100 Based on priority *P. destruens* is now considered a synonym of *P. insidiosum* (Mendoza and
101 Marin, 1989).

102 *Pythium insidiosum* mainly occurs in surface water amongst others in standing inland
103 waters and occasionally in soil (Mendoza et al., 1993, Mendoza et al., 1996). Not much is
104 known about the ecological preference of *P. insidiosum*, but the presence of water which
105 induces the formation of zoospores seems to be a prerequisite (Supabandhu et al., 2008).
106 Since *P. insidiosum* usually occurs under wetland conditions, more cases are seen after heavy
107 rain or floods (Miller, 1983, Miller and Campbell, 1983, Mendoza et al., 1993). Other risk

108 factors for developing pythiosis have not yet been identified. Floods after heavy rain have
109 been incriminated as one of the natural resources used by *P. insidiosum* to expand its
110 ecological niche to new areas (Mendoza et al., 1993, Supabandhu et al., 2008).
111 Phylogenetic analysis has shown that *Pythium* spp. are closer related to diatomeae and algae
112 than to true fungi (Kwon-Chung, 1994, Hudspeth et al., 2000, Martin; 2000). *Pythium* spp.
113 belong to the kingdom Stramenopila, the Phylum Oomycota, the order Peronosporales and the
114 family Pythiaceae (Alexopoulos et al., 1996). *Pythium* spp have also been classified by others
115 in the kingdom Chromista, the Phylum Pseudofungi, the class Oomycetes, the order Pythiales
116 and the family Pythiaceae (Mendoza et al., 1996). In the most recent classification (Dick,
117 2001), *P. insidiosum* as a member of the genus *Pythium* is classified in the kingdom
118 Straminipila, class Peronosporomycetes (= Oomycetes), order Pythiales and family
119 Pythiaceae. This classification, however, was not yet based on DNA sequence data and may
120 change in the near future.

121

122 **The Agent**

123 Microscopically *P. insidiosum* develops mycelium like fungi, but it is not a true
124 fungus, since its cell walls do not contain chitin but are composed of cellulose and β -glucans,
125 its cytoplasmic membrane lacks ergosterol, the thallus is diploid and coenocytic, the sexual
126 process is oogamy and the organism develops biflagellate zoospores in wet environments
127 (Alexopoulos et al, 1996). Zoospores are single nucleated cells without a cell wall that can
128 swim with the help of two flagella; a tinsel (anterior) flagellum and a whiplash (posterior)
129 flagellum. The posterior flagellum is thought to be responsible for the movement of the
130 zoospore through water, the anterior flagellum functions as a rudder. Zoospores swim in a
131 helical or spiral pattern interrupted by random changes of direction. Zoospores cannot divide
132 or multiply (Walker and van West, 2007). The zoospores are considered to be the infective
133 propagules, they show chemotaxis and become encysted once they come in contact with
134 either decaying or injured plant tissue (there is no evidence that healthy plant tissue has a
135 similar effect). Injured tissue of a mammalian host that enters the ecosystem of *P. insidiosum*
136 exerts the same effect. A glycoprotein secreted on the surface of the encysted zoospores
137 allows adhesion to the injured tissue (Estrada-Garcia et al., 1990, Mendoza et al., 1993,
138 Mendoza et al., 1996).

139 *Pythium insidiosum* infections occur mostly in apparently healthy humans and animals
140 (Thianprasit, 1990, Mendoza et al., 1996, Thomas and Lewis, 1998, Grooters, 2003,
141 Mendoza, 2005). Pythiosis occurs in regions of Southeast Asia (India, Indonesia, Japan,

142 Korea, New Guinea, and Thailand) (Ichitani and Amemiya, 1982, Thianprasit, 1986, 1990,
143 Sohn et al., 1996), eastern coastal Australia and New Zealand (Miller, 1983, Triscott et al.,
144 1993, Murdoch and Parr, 1997), South America (Argentina, Brazil, Colombia, Venezuela)
145 (Gonzalez and Ruiz, 1975, Mendoza, 2005), Costa Rica (Mendoza and Alfaro, 1986, Alfaro
146 and Mendoza, 1990), Guatemala (Mendoza et al., 1996), Haiti (Virgile et al., 1993), Panama
147 and Nicaragua (Mendoza and Alfaro, 1986) and North America, Mexico and the United States
148 (Miller, 1983, Grooters, 2003, Mendoza, 2005). In the USA it occurs most often in the Gulf
149 coast states but has also been identified in other states (Mendoza, 2005, Grooters, 2007). The
150 first case of pythiosis from Africa (Mali) was reported in a dog (Rivierre et al., 2005). This
151 case was confirmed by molecular sequencing, placing the African strain in a separate taxon
152 from the American and Asian clusters reported by Schurko et al., (2003a).

153 *Pythium insidiosum* is well adapted to the body temperature of its mammalian hosts. It
154 has an optimum and maximum temperature for growth of 34-36° and 40-45° respectively (De
155 Cock et al., 1987). It grows well on various artificial media when incubated at 25° or 37°C.
156 Sabouraud agar (Witkamp, 1924, 1925, De Cock et al., 1987), vegetable extract agar, peptone
157 yeast glucose agar and potato flakes agar all can be used (de Cock et al., 1987, Shipton, 1987,
158 Grooters et al., 2002b). On Sabouraud agar *P. insidiosum* grows in submerged, white to
159 colourless colonies, which have an irregular radiate pattern (de Cock et al., 1987, Mendoza et
160 al., 1993, 1996) (Fig. 1A). Zoospores are only developed in water cultures; they are
161 stimulated by the presence of ions such as K⁺, Ca²⁺, Mg²⁺ and chemically attracted by plant
162 material, animal hairs or pieces of animal tissue (Austwick and Copland, 1974, Shipton, 1987,
163 Mendoza and Prendas, 1988, Chaiprasert et al., 1990, Mendoza et al., 1993). While in some
164 oomycetes, zoospore formation can occur within minutes and is considered one of the fastest
165 developmental processes in any biological system (Walker and van West, 2007), in
166 *P. insidiosum* zoospore formation can take one hour or more (Mendoza and Prendas, 1988). *P.*
167 *insidiosum* does not need a susceptible mammalian host for its survival or propagation since it
168 is able to survive and multiply in its natural environment on decaying plants (Mendoza et al.
169 1993).

170

171 **Molecular Phylogeny of *Pythium insidiosum*.**

172 The first reports showing that *P. insidiosum* is a unique oomycetous pathogen of
173 mammals came from molecular phylogenetic studies of several *Pythium* species (Martin,
174 2000; Lévesque and de Cock, 2004). Lévesque and de Cock (2004) divided *Pythium* species
175 in at least 10 different phylogenetic groups (designated A to K). *P. insidiosum* is found in

176 group C together with *P. grandiosporangium*. Grouping of *P. insidiosum* together with this
177 marine saprotrophic microbe is intriguing since *P. insidiosum* is a fresh water organism.
178 Moreover, the two species are significantly different with regard to morphology and
179 growth/temperature relationships. The clustering of the two in one clade is more likely to be
180 the consequence of long range attraction than of a genuine close relationship.

181 Schurko et al (2003a, b) observed heterogeneity in ribosomal DNA sequences (IGS
182 and ITS) among isolates of *P. insidiosum* which were correlated to geographic origin but not
183 to host. They distinguished three different groups: clade I is comprised of isolates from North,
184 Central and South America, clade II consists of isolates from Asia and Australia, whereas
185 clade III contains isolates from Thailand and the USA. Clade I and II are closely related but
186 Clade III is significantly different from the other two. Moreover, one isolate in clade III from
187 *Tremarctos ornatus* is deviating from the other strains in this clade. Therefore it was
188 hypothesized that the members of the third group might represent a new species, but they
189 were not treated as such.

190 The ability of *P. insidiosum* to develop appressoria and the chemotaxis of its
191 zoospores to plant tissue suggests that this pathogen took advantage of these ancestral features
192 and adapted them to a lifestyle as a mammalian parasite. When *P. insidiosum* acquired the
193 pathogenic attributes to invade mammals, hopefully can be answered after completion of its
194 complete genome sequence. Several genome sequencing projects of plant pathogenic
195 oomycetes are already finished and some others are underway. To our knowledge this is not
196 yet the case for *P. insidiosum*.

197

198 **Epidemiology and pathogenesis**

199 Zoospores show a marked chemotaxis towards animal hair, wounds, other damaged
200 skin parts or intestinal mucosa (De Cock et al 1987, Mendoza et al 1993). Upon microscopy,
201 adhesion of zoospores to the cut edges of skin but hardly to undamaged tissue was observed
202 (Mendoza et al., 1993, Grooters, 2003). The location of the lesions is therefore directly related
203 to the parts of the body that were in direct contact with water containing zoospores of *P.*
204 *insidiosum*. For example, in horses lesions are seen especially on the legs and ventral parts of
205 the abdomen. Lesions caused by punctures and insect bites can also be a “port d'entree” for
206 *Pythium insidiosum* (Mendoza et al., 1993, Mendoza et al., 1996, Rees, C.A., 2004). Insect
207 bites are of interest from an epidemiological point of view since Schurko et al., (2003a)
208 identified an isolate from an infected larva of *Culex quinquefasciatus* (a widespread tropical
209 mosquito) in India as *P. insidiosum*. This suggests that *P. insidiosum* has the ability to invade

210 insects and thus the possibility of transmission through infected mosquitoes is of concern,
211 especially in the tropical regions where mosquitoes are prevalent.

212 Once the zoospores are in contact with mammalian or plant tissue (in wet
213 environments) they encyst on the surface of the injured tissue(s). The encysted zoospores
214 secrete a sticky amorphous glycoprotein that mediates the adhesion of zoospores to tissue
215 before they enter the tissue (Mendoza, et al., 1993, Mendoza et al., 1996). The encysted
216 zoospores stimulated by the host's body temperature develop a germ tube (hypha) that
217 extends from the zoospores into the infected tissue and later can also infiltrate blood vessels
218 (humans), which makes spreading within the body tissues easier. The disease can also be
219 acquired through traumatic lesions and contact with hyphae of *P. insidiosum* (Mendoza et al.,
220 1990). The invasion of blood vessels can lead to thrombosis and invasion of large arteries
221 (Imwidthaya, 1994, Thitithanyanont, 1998, Krajaejun et al., 2006, Pupaibool, et al., 2006,
222 Laohapensang et al., 2009). In addition to *P. insidiosum* host colonization by invasive growth,
223 the secretion of proteases and the exertion of mechanical force by the tips of the elongating
224 hyphae have been implicated as putative virulence factors (Shipton, 1987, Ravishankar et al.,
225 2001). For *P. insidiosum* this force has been measured and compared with the resistance of
226 human and equine skin to needle insertion. The data show that a significant reduction in tissue
227 strength has to be obtained by the action of proteases, before penetration of the tissue by
228 hyphae can take place (Ravishankar et al., 2001, MacDonald et al., 2002, Davis et al., 2006).
229 All three tested strains of *P. insidiosum* secrete three or more proteases of different molecular
230 weight. Two of them were present in the three strains. The specificity of the proteases is not
231 known, but inhibition experiments identified them as serine proteases (Davis et al., 2006).
232 Secretion of proteases seems to be a general feature of pathogenic oomycetes (Bangyeekhun
233 et al., 2001, Torto-Alalibo et al., 2005). Pythiosis progresses rapidly and if not treated in the
234 early stages can become life threatening in both humans and animals. So far zoonotic
235 properties have not been demonstrated for *P. insidiosum*.

236

237 **Clinical signs in animals**

238 Pythiosis has been reported in several species, but most cases occur in otherwise
239 immunocompetent horses and dogs. In animals the infection develops in the form of a
240 cutaneous or intestinal disease, although cases of localized lung and bone infection, as well as
241 systemic dissemination through lymph nodes have been also described (Witkamp, 1925,
242 Goad, 1984, Mendoza et al., 1988, Alfaro and Mendoza, 1990, Reis et al., 2003).

243 *Horses*

244 In horses there seems to be no predisposition for breed, age or sex of the animals (Miller,
245 1983, Mendoza and Alfaro, 1986, Mendoza, 2005, White et al, 2008). In this species the
246 cutaneous form is more prevalent whereas the intestinal form is rarely recorded (Brown and
247 Roberts 1988, Morton et al., 1991, Purcel et al., 1994). The Dutch authors (Bubberman, 1914,
248 Witkamp, 1924) describe for all their equine patients that they were apparently suffering from
249 itching, since they were rubbing the infected area of the body against the wall of the stable or
250 biting the wound when allowed. In some cases this lead to auto-mutilation (Mendoza et al.,
251 1986). These authors also describe the awful smell associated with horses infected with this
252 pathogen. Lesions in the cutaneous form often consist of large, rounded, granulomatous
253 nodular ulcerative tissue. The lesions are tumour-like and consist of necrotic tissue,
254 containing eosinophils and hyphae of *P. insidiosum* (Headley et al., 2002, Miller, 1983, Miller
255 and Campbell, 1984, Mendoza and Alfaro, 1986, Chaffin, et al., 1995). The tissue and the
256 draining fistulas contain cores of necrotic yellow-gray material referred to as “kunkers”.
257 Kunkers can vary in size, from a grain of rice, to various centimetres and can sometimes be
258 found in bandage material (Fig. 2). Kunkers are specific for equine pythiosis and absent in
259 other affected species (Leal et al., 2001, Mendoza et al., 1996, Mendoza, 2005). Kunkers in
260 horses are formed by degranulation of eosinophils over the invading hyphae of *P. insidiosum*.
261 New eosinophils degranulate over the old ones and the structural mass grows in size. In
262 horses with chronic pythiosis the only place where the hyphae of *P. insidiosum* can be found
263 is within kunkers. The clinical signs of a horse with pythiosis may include in addition to skin
264 and bone lesions, lameness and enlargement of regional lymph nodes, anemia and
265 hypoproteinemia. Both hypoproteinemia and anemia occur as a result of blood loss and loss of
266 exudates consisting of serum and cations through large ulcerated skin lesions (Miller,1983,
267 Mendoza and Alfaro, 1986) (Fig. 3). Intestinal pythiosis in horses is characterized by stenotic
268 fibrous and disseminated gastrointestinal lesions (Brown and Roberts,1988, Allison and
269 Gillis, 1990, Purcell et al., 1994).

270 *Dogs*

271 In dogs, in contrast to horses, the gastrointestinal form of pythiosis occurs more often than the
272 subcutaneous form (Fig. 4). The clinical symptoms include vomiting, weight loss, intermittent
273 diarrhoea and palpable masses in the abdomen (Fischer at al., 1994). Extension of the
274 infection to the pancreas, mesenteric lymph nodes and bile ducts can occur (Thomas and
275 Lewis, 1998, Grooters, 2003, Berryessa et al., 2008). Lesions may involve legs and face or
276 tail (Thomas and Lewis, 1998). Infection by *P. insidiosum* in dogs is more frequent in young
277 immunocompetent adults (Grooters, 2003, Grooters et al., 2003).

278 *Cats*

279 Pythiosis in cats is rare and usually the lesions are confined to the skin and subcutaneous
280 tissues (Fig. 5) (Thomas and Lewis, 1998, Grooters, 2003,). Gastrointestinal infections in cats
281 were reported only recently (Rakich et al., 2005). There is no predisposition for breed, age or
282 sex (Grooters, 2003).

283 *Cattle*

284 Pythiosis in cattle usually occurs during the rainy season in subtropical areas. It is considered
285 a sporadic disease in this species. However, an epizootic event involving more than 60 calves
286 was reported in Venezuela (Pérez et al., 2005). The disease occurs more frequently on the
287 limbs with pruritus and claudication. Tumor-like masses with fistules and ulcerated tissue of
288 the limbs is common. The hyphae are usually localized at the centre of eosinophilic
289 granulomas. The affected areas are extremely painful and most animals cannot stand up which
290 usually leads to dehydration and death. Secondary bacterial contamination with anaerobes and
291 other bacteria is common (Fig. 6) (Miller et al., 1985, Santurio et al 1998, Perez et al. 2005).
292 It has been suggested that in tropical countries the disease in cattle termed “infectious
293 pododermatitis” usually attributed to anaerobic bacteria, maybe caused by *P. insidiosum*,
294 which could open the door for anaerobic bacteria causing pododermatitis as a secondary
295 infection (Perez et al., 2005).

296 *Sheep*

297 Pythiosis in sheep has been reported to cause cutaneous lesions in different anatomical areas
298 and as a rhinopharyngeal disease (Tabosa et al. 2004; Riet-Correa et al., 2008). Eosinophilic
299 granulomatous lesions are usually reported on the limbs and rhinopharyngeal areas. Clinical
300 signs involving the rhinopharynx include bilateral serosanguineous nasal discharge, swelling
301 of nostrils, and the skin of the face (Fig. 7) (Riet-Correa et al., 2008). Involvement of the
302 lungs has also been reported (Tabosa et al., 2004).

303 *Birds*

304 Only a single report on *P. insidiosum* affecting birds has been recorded (Pesavento et al.,
305 2008). The infected animal was a Californian nestling white-faced ibis (*Plegadis chihi*) with
306 multiple ulceration of its wings, neck, head and limbs. *P. insidiosum* hyphae were found at the
307 centre of necrotizing eosinophilic granulomas. This report shows that *P. insidiosum* can also
308 affect birds and thus veterinarians dealing with birds should investigate similar skin lesions
309 for the presence of this oomycete.

310 *Captive animals*

311 In the last 10 years various reports on pythiosis in captive zoo animals have appeared. The
312 animals involved include animals such as bears, camels and members of the Pantherae such as
313 a tiger and a jaguar. Reports on the following species are available.

314 *Spectacled Bears*

315 How often the disease occurred in this species or the number of cases has yet to be officially
316 reported. So far all cases have come from a zoo in Columbia, South Carolina. Several adult
317 spectacled bears (*Tremarctos oronatus*) were seen with lesions involving the preputial glands,
318 other cutaneous areas and the gastrointestinal tract (A.A. Padhye, personal communication).
319 The disease has been reported at least twice in this species from the same zoo. The presence
320 of *P. insidiosum* in the affected tissue was confirmed by microscopy and culture.

321 *Camels*

322 Only a single case of pythiosis involving a 4.5 years-old male captive dromedary camel
323 (*Camelus dromedarius*) in a Florida zoo has been recorded (Wellehan et al., 2004). The
324 animal developed a granulomatous mass on the right side of the face and the diagnosis
325 pythiosis was confirmed by culture. Despite immunotherapy and iodine treatment the camel
326 died six months after the initial diagnosis. At necropsy hyphae of *P. insidiosum* were also
327 found in the third compartment of the stomach. Two unpublished cases of pythiosis in camels
328 from a zoo in Tennessee were recently confirmed (Videla, R. and Mendoza, L. unpublished).

329 *Big cats*

330 *P. insidiosum* has been reported causing an unusual primary pulmonary infection in a seven
331 months old Central American jaguar (*Panthera onca*) that later died of the infection (Camus
332 et al., 2004). In addition, an adult captive Bengal tiger (*Panthera tigris tigris*) was diagnosed
333 with abdominal pythiosis in Florida (Buergelt et al. 2006). The tiger later died of the
334 infection. At necropsy several intestinal tumor-like masses were found. The diagnosis was
335 confirmed by serology.

336

337 **Pythiosis in Humans**

338 Although it has long been observed in animals, the disease in humans was only
339 recently described in Thai patients (Thianprasit, 1986, 1990). In humans too, pythiosis affects
340 apparently healthy individuals. Susceptible hosts become infected after contact with
341 zoospores through contact of a skin wound with contaminated water. Agricultural related
342 activities or water associated leisure activities are considered to be predisposing factors for
343 human pythiosis (Sathapatayayongs et al., 1989, De Moraes Gimenes Bosco et al., 2005,
344 Supabandhu J., 2008). Thalassemia is also considered to be a predisposing factor in Thailand

345 (Sathapatayayongs et al., 1989), but in a population with a high incidence of Thalassemic
346 patients this claim has been questioned (Mendoza et al., 2003b). The majority of human cases
347 (80%) of pythiosis have been reported in Thailand (Sathapatayayongs et al., 1989,
348 Thianprasit, 1990, Imwidthaya, 1994, Vanittakanakom et al., 2004). Other countries where
349 human pythiosis cases have been reported include: Australia, Brazil, Haiti, Malaysia, New
350 Zealand, and the USA, (Rinaldi, et al., 1989, Triscot et al., 1993, Virgile et al., 1993,
351 Badenoch, et al., 2001, de Moraes Gimenes Bosco et al., 2005). In a report on more than 100
352 cases of pythiosis in Thailand, four different forms of pythiosis were described: a) the (sub)
353 cutaneous form (infecting the face or limbs as a granulomatous and ulcerating lesion), found
354 in 5% of the cases, b) the vascular type (affecting arteries and resulting in arterial occlusion
355 and aneurysm), found in 59% of the cases, c) the ocular and orbital form in which corneal
356 ulcers are formed, is found in 33% of the cases and d) pythiosis at unusual places (i.e.
357 disseminated pythiosis and infection of internal organs, observed in 3% of the cases
358 (Krajaejun et al., 2006). From a Brazilian study, in which the morphological and molecular
359 characteristics of a new equine isolate were compared with a human isolate, it was clear that
360 both isolates are 99% similar (De Moraes Gimenes Bosco et al., 2008). The isolates were
361 obtained from the same region. This indicates that both humans and animals are sensitive for
362 the same agent and host specificity of different genotypes seems not very likely. Since all
363 American *P. insidiosum* isolates are included in a single phylogenetic taxon indicating their
364 similarity (Schurko et. al., 2003b), this observation was not unexpected. In the USA human
365 cases of pythiosis are seldom reported and only a small number of cases have been officially
366 published (Rinaldi et al., 1989, Shenep at al., 1998). However, it is likely that pythiosis in the
367 past has been misdiagnosed as a fungal infection (Mendoza et al., 2003). In Australia and the
368 USA children seem more susceptible to the orbicular form (Rinaldi et al., 1989, Triscott et al.,
369 1993, Shenep et al., 1998, Mendoza et al., 2003b), whereas adults develop the subcutaneous
370 form.

371

372 **Experimental pythiosis**

373 *Rabbits*

374 The susceptibility of rabbits to experimental infection with *P. insidiosum* was
375 demonstrated almost 100 year ago by Witkamp (1924, 1925) and has been used ever since as
376 an experimental model to test the effectiveness of immunotherapy and antimycotic agents
377 (Amemiya, 1969, Ichitani and Amemiya, 1980, Miller and Campbell, 1983, Patino-Meza,
378 1988, Santurio et al., 2003a, Pereira et al., 2007, 2008). It is believed that 17,500 zoospores

379 are needed to generate the disease in rabbits (Santurio et al., 2003a). However, Patino-Meza
380 (1988) induced the infection using only 500 or less zoospores. The inoculation with *P.*
381 *insidiosum* in any other species has been consistently unsuccessful. Patino-Meza (1988)
382 reported no results on the experimental inoculation of *P. insidiosum* in species such as cattle,
383 dogs, and horses. The author used a container with water containing hundreds of *P.*
384 *insidiosum* zoospores and submerged a horse limb with small skin wounds, without success.
385 Witkamp (1924) mentions that in guinea pigs a similar syndrome as in rabbits develops after
386 experimental infection, but the guinea pigs apparently were suffering much less and their
387 general health was much better. Oddly, natural infection of rabbits with *P. insidiosum* has yet
388 to be documented (Mendoza 2005). In a bizarre report, inoculation of native people and
389 equines with kunkers (from horses with pythiosis) without developing the disease was
390 mentioned (Smith 1884). In summary, experimental pythiosis is only possible in rabbits.

391

392 **Immunology of *Pythium insidiosum* infections**

393 In an early report by veterinarians on equine pythiosis in Indonesia (the former
394 Netherlands India) it was mentioned that infected animals develop anti-*P. insidiosum*
395 antibodies easily detected using antigens extracted from the pathogen in an immunodiffusion
396 test (Witkamp, 1924). This was confirmed by serological studies in humans and animals
397 suffering from pythiosis, showing that *P. insidiosum* antigens trigger a humoral immune
398 response upon contact with the host (Miller and Campbell, 1982, Mendoza et al., 1986,
399 Imwidthaya and Srimuang, 1989, Mendoza et al., 1992a, Grooters et al., 2002a, Mendoza and
400 Newton, 2005). It seems, however, that the presence of this type of immunity does, not clear
401 infections in humans or animals (Miller and Campbell, 1982, Mendoza and Alfaro, 1986,
402 Triscott et al., 1993, Thitithanyanont et al., 1998). The cellular immunity, provided by
403 activated macrophages, mast cells, eosinophils and other inflammatory cells, seems directly
404 involved in the extensive tissue damage observed in infected hosts (Miller and Campbell,
405 1982, Mendoza and Alfaro, 1986). Degranulation of eosinophils and mast cells at the infected
406 sites causes the intensive pruritus reported in horses and other species; and is also responsible
407 for the bacterial contamination occurring after development of necrosis and ulcerating tissue
408 with the classical strong odour reported in equine pythiosis of the skin (Bubberman, 1914).

409 Based on these data it was postulated that the humoral immunity observed in infected
410 hosts with pythiosis only triggers precipitating and agglutinating anti-*P. insidiosum* antibodies
411 related to a T helper 2 (Th2) immune response (Mendoza et al., 2003a, Mendoza and Newton,
412 2005). These antibodies are not protective, but can be used for the diagnosis of the disease. It

413 was further postulated that the cellular immunity triggered by *P. insidiosum* locks the immune
414 system in a Th2 mode which contributes to a worsening of the condition and eventually leads
415 to death. It was suggested that treatment of the disease, using antigenic proteins extracted
416 from *P. insidiosum* (see *Immunotherapy* below), might nevertheless work if these
417 immunogens were presented to the immune system in a different fashion. The observation
418 that high levels of interferon gamma (IFN- γ) and Interleukin 2 (IL2) (indicators of a Th1
419 mediated immunity) and a decrease of Th2 mediated interleukins are present in cured patients
420 supports this idea (Thitanyakanont et al., 1998, Mendoza and Newton, 2005).

421 Of interest with respect to the immunology of pythiosis is a report that anti-*P.*
422 *insidiosum* antibodies developed by different host species seem to detect different *P.*
423 *insidiosum* antigens. Antibodies present in cattle, horses and humans with pythiosis were seen
424 to bind to different hyphal cell compartments upon immuno-electron microscopy and protein-
425 A colloidal gold –labeling (Garcia et al. (2007). This suggested that different hosts recognize
426 different *P. insidiosum* antigens, which can have implications for the variable response to
427 immunotherapy in some species (see *Immunotherapy* below). Western blot analysis with sera
428 from bovine, feline, canine, equine and human patients, also showed the detection of different
429 antigens depending on the serum of the species tested (Chindamporn et al., 2009).
430 Recognition of different dominant *P. insidiosum* antigens by antibodies present in cattle sera,
431 but not by horse and rabbit antibodies has likewise been reported (Leal et al., 2005).

432

433 **Diagnostics**

434 Equine pythiosis should not be mistaken for habronemiasis (also named swamp
435 cancer, a disease of horses caused by the nematodes *Habronema muscae*, *H. majus* (*H.*
436 *microstoma* and *Draschia megastoma*), skin fungal infections caused by *Conidiobolus* and
437 *Basidiobolus* spp., extreme granulation tissue, bacterial granulation tissue or an invasive
438 squamous cell carcinoma (Miller, 1983). Early diagnosis of pythiosis is very important for a
439 successful therapy. Clinical expertise of a veterinarian or physician with the various clinical
440 forms of the disease in different species is crucial for an early diagnosis.

441 *Sample Collection*

442 For equine pythiosis the collection of several kunkers and their transportation to the
443 laboratory in water or a saline solution with antibiotics (streptomycin and ampicillin) is
444 recommended. Biopsies and scrapings should be transported to a laboratory as soon as possible.
445 The samples have to be washed with distilled water and transported at room temperature in
446 water or saline solution. For long trips (two days or more) the clinical samples (including

447 kunkers) should be transported in saline solution with a few drops of broad spectrum
448 antibiotics such as chloramphenicol or tetracycline. However, it was shown that specimens
449 can also be refrigerated and *P. insidiosum* can be recovered from specimens that have been
450 refrigerated for up to 5 days (Grooters et al., 2002b). In our experience however, cooling at
451 4°C (shipping on ice) inhibits growth of *P. insidiosum* from about 20% of the clinical
452 samples.

453 A positive diagnosis for *P. insidiosum* infection can be obtained in three ways: a)
454 determination of the presence of the agent by wet mount examination in 10% KOH followed
455 by culturing, b) detection of anti-*P. insidiosum* antibodies using serological assays, and c)
456 detection of DNA of the infectious agent in the infected tissue by PCR and sequencing.
457 Cytology and histology, may help in the diagnosis of pythiosis, but do not allow
458 differentiation between pythiosis and infections caused by the zygomycetes *Conidiobolus*
459 and *Basidiobolus* (Miller, 1983, Mendoza, 2005, Grooters, 2007).

460 a) *Culturing and Wet Mount Examination*

461 Wet mount examination in 10% KOH can be performed directly on samples taken
462 from the infected individual. Wet mount preparations are a rapid way to microscopically
463 detect the presence of sparsely septate hyphae, which may suggest the presence of *P.*
464 *insidiosum* and pythiosis (Fig. 8). Next, a positive diagnosis can be made by culturing
465 followed by sporulation of the pathogen in liquid cultures (Mendoza and Prendas, 1986,
466 Chaiprasert et al., 1990). The production of zoospores alone is not sufficient for a positive
467 diagnosis as other oomycetes produce similar zoospores. Kunkers collected from horses are
468 more likely than biopsied tissues to yield a positive culture. Care should be taken to avoid
469 bacterial contamination upon culturing by the addition of antibiotics and careful processing of
470 samples (Grooters, 2007). Usually, the collected biopsy samples, kunkers (horses) or tissue,
471 are washed three times with sterile saline solution before culture. The tissue is then cut into 5
472 to 10 mm in diameter blocks, implanted into 2% dextrose Sabouraud agar plates and
473 incubated at 37°C. A beaker with distilled water to increase the humidity inside the incubator
474 is recommended. Positive samples are detected after 24 to 48 hours of incubation as small
475 radiate growing colonies coming from the inoculated blocks (L. Mendoza, unpublished data)
476 (Fig. 1A).

477 For an accurate diagnosis, a tissue biopsy or tissue deep scrapings can be taken from
478 cutaneous and subcutaneous pythiosis cases; clinical samples can be cultured and
479 microscopically examined for the presence of sparsely septate hyaline hyphae (Fig. 1B). Due
480 to the fact that *P. insidiosum* in culture does not develop sporangia on the commonly used

481 agar media, the induction of a sporangium producing motile biflagellate zoospores should
482 usually be performed in order to identify the pathogen as *P. insidiosum* (Mendoza and
483 Prendas, 1988, Grooters et al., 2002b) (Fig. 9). All *Pythium* species develop zoospores in wet
484 cultures in the presence of calcium and magnesium ions. Since *P. insidiosum* was recognized
485 as the only oomycete pathogenic for mammals for a long time, induction of zoosporogenesis
486 was considered enough for a presumptive diagnosis of pythiosis. With the description of an
487 emerging oomycosis in 2003, that still awaits confirmation this might no longer be the case
488 (Grooters et al., 2003). However, further identification of the culture as *P. insidiosum* by
489 serology or using molecular tools, including sequencing is recommended in any case
490 (Schurko et al., 2004, Mendoza, 2005).

491 *Histopathology*

492 In contrast to zygomycetes in the order of the mucorales (*Absidia*, *Mucor*, *Rhizopus*,
493 *Saksenaea*, and others) and in the order of the entomophthorales (*Basidiobolus* and
494 *Conidiobolus*) *Pythium insidiosum* hyphae do not stain well in Hematoxylin and Eosin (H&E)
495 (Ribes et al., 2000, Mendoza, 2005). Histopathologically a pyrogranulomatous inflammatory
496 infiltration with large quantities of eosinophilic granulocytes is often seen (Rees, 2004,
497 Mendoza, 2005, Grooters, 2007). Although the visualization of hyphae is difficult in H&E
498 staining, the presence of necrotic eosinophilic granulomas should lead to consideration of the
499 presence of entomophthoromycetous fungi (*Conidiobolus* and *Basidiobolus* species), *P.*
500 *insidiosum*, and/or putative parasitic infections such as habronemiasis in horses (Fig. 10). To
501 visualize *P. insidiosum* hyphae in tissue, samples can be stained with PAS (periodic acid-
502 Schiff) or Gomori methenamine silver staining of which the latter is to be preferred
503 (Mendoza, 2005). *P. insidiosum* hyphae are present as 2.6 to 6.4 μm wide (sometimes as large
504 as $>10.0 \mu\text{m}$), irregular sparsely septate hyaline filaments with a thick cell wall. Occasionally
505 branches are formed at angles of 90° degrees (Miller, 1983, Miller and Campbell, 1984,
506 Mendoza and Alfaro, 1986, Mendoza, 2005) (Fig.10).

507 *b) Serodiagnosis.*

508 Serodiagnosis of pythiosis can be performed by immunodiffusion. The test is very specific but
509 unfortunately has a low sensitivity (Mendoza et al., 1986, Prachartam et al., 1991). Other tests
510 based on detection of antibodies, like an Enzyme Linked Immuno-Sorbent Assay (ELISA), an
511 immunochromatographic assay or a Western blot were developed later to increase sensitivity
512 and specificity (Mendoza et al., 1992a, Mendoza et al., 1997, Grooters et al., 2002a,
513 ,Krajaejun et al., 2002, Chindamporn et al., 2009, Krajaejun et al., 2009). Because these tests
514 are difficult to perform in rural areas, Jindayok et al., (2009) developed a haemagglutination

515 test in which agglutination of sheep red blood cells coated with a *P. insidiosum* extract is
516 tested against serum samples of patients suspected of pythiosis. The test was found to be
517 simple, rapid and reliable for serodiagnosis of vascular and cutaneous pythiosis. *P. insidiosum*
518 can also be identified in fixed tissues by immunofluorescence (Mendoza et al., 1987) or by the
519 immunoperoxidase staining technique (Brown and Roberts, 1988).

520 *c) Molecular diagnosis, PCR.*

521 Molecular techniques have been developed to identify *P. insidiosum* in the clinical laboratory
522 in the absence of culture. A specific diagnostic PCR using the internal transcribed spacer
523 (ITS) of the rRNA locus of *P. insidiosum* has been used by several laboratories (Grooters and
524 Gee, 2002, Reis et al., 2003, Vanittanakom, et al., 2004, de Moraes Gimenes Bosco et al.,
525 2008). Since most skin and intestinal lesions are contaminated with environmental microbes
526 of which DNA sequences are not yet available from the data base, diagnostics based solely on
527 the specific molecular weight of amplicons has to be interpreted with caution. A species
528 specific DNA probe, based on a 530 bp fragment of the ribosomal intergenic spacer (IGS),
529 was developed by Schurko et al. (2004). Although these methodologies are not yet available
530 on a large scale, they can be of help in cases of where fixed tissue is submitted for
531 histopathology (see also serodiagnosis).

532

533 **Management of pythiosis**

534 The infections caused by *P. insidiosum* poorly respond to therapy. In addition to wide
535 surgical excision, antimicrobial agents and immunotherapy have been used with some success
536 in the treatment of pythiosis. Independent of the chosen therapy, it is of utmost importance
537 that treatment starts as early as possible.

538 Radical surgery, including amputation, still is the most **used and effective treatment**
539 for this infection in humans and animals (McMullan et al., 1977, Mendoza and Alfaro, 1986,
540 Thomas and Lewis, 1998, Krajaejun et al., 2006). Surgical debridement of skin lesions in
541 dogs and horses with the disease is very popular as well but a high rate of reoccurrence is seen
542 (45%). Some investigators have recommended immunotherapy as an important alternative for
543 the treatment of equine pythiosis. It has to be taken into account that the reported cure rates of
544 different therapies most often are calculated from a small number of patients and that therapy
545 is often a combination of actions like surgical therapy, immunotherapy or administration of
546 antimycotic agents.

547 *Antimycotic agents*

548 Since *P. insidiosum* was believed to be a fungus several antimycotic agents were used
549 to treat the infection (McMullan et al., 1977). However, Stramenopilan microbes such as *P.*
550 *insidiosum* lack ergosterol in their cytoplasmic membrane and thus should not be susceptible
551 to antimycotic agents (Sekhon et al., 1992, Mendoza, 2005, Mendoza and Newton, 2005).
552 Agents interfering with ergosterol biosynthesis like the azoles (itraconazole, ketoconazole,
553 miconazole, fluconazole etc.) and terbinafine and amphotericin B change the permeability of
554 the cell membrane, causing fungal cell lysis and thus can be expected to have little effect on
555 *P. insidiosum*. Despite this drawback there are reports of clinical success using these drugs
556 (Bissonnette et al., 1991, Triscott et al., 1993, Shenep et al., 1998, Grooters, 2003). Several
557 reports on the sensitivity of *P. insidiosum* for combinations of ergosterol biosynthesis
558 inhibitors and caspofungin (an inhibitor of β -glucan synthesis, (Deresinski and Stevens, 2003)
559 have appeared recently (Grooters, 2003, Pereira et al., 2007, 2008, Argenta et al., 2008,
560 Brown et al., 2008, Cavalheiro et al., 2009a, 2009b, Argenta et al., 2010). The oomycete cell
561 wall mainly contains cellulose and β -glucan, which is an essential component of the cell wall
562 (Hendrix, J.W., 1964). Consequently, in these reports inhibitors of β -glucan synthesis (like
563 caspofungin) have been tested.

564 Caspofungin when tested *in vivo* in a model such as the rabbit, generates a reduction in
565 the growth of the lesions in treated animals. Growth of the lesions resumes when therapy is
566 stopped (Pereira et al., 2007). Combinations of terbinafine and itraconazole or voriconazole
567 performed better against a number of isolates of *P. insidiosum* than each agent apart (Argenta
568 et al., 2008). An observation also made for combinations of terbinafine and amphotericin B,
569 metronidazole, rifampicin, ibuprofen and fluvastatin (Carvalho et al., 2009a, 2009b). It is
570 of concern that a high variability in susceptibility of the different *P. insidiosum* strains used in
571 these studies was observed (Cavalheiro et al., 2009a). An antimycotic agent that awaits
572 further study of its usefulness against *P. insidiosum* infection is the phenylamide compound
573 mefenoxam, an inhibitor of RNA polymerase that has been used against plant pathogenic
574 oomycetes (Brown et al., 2008). Unfortunately, the extensive testing of new antimycotic
575 drugs in animals is often hampered by the costs involved.

576 *Immunotherapy*

577 Immunotherapy for the treatment of pythiosis in horses has been used for more than 20
578 years and more than 600 animals have been treated today (Miller, 1981, Mendoza and Alfaro,
579 1986, Mendoza and Newton, 2005). The first vaccine, developed in 1981 and derived from
580 killed ultrasonicated mycelium, was effective in half of the equine patients and clinical
581 improvement was observed in another 33% (Miller, 1981). A second vaccine containing

582 antigens secreted by *P.insidiosum* and obtained from a broth culture after precipitation was
583 tested in a number of horses from Costa Rica (Mendoza and Alfaro, 1986). The efficacy of
584 this vaccine was not much different from the efficacy of the vaccine developed by Miller, but
585 it is more stable and easier to prepare (Mendoza et al., 2003). In a clinical study involving 18
586 infected horses and 6 infected dogs which were treated with *P. insidiosum*-vaccine 72% of the
587 horses and 2 dogs were cured. **It is important to note that the cure rates in this study were**
588 **obtained by combination therapies using either surgery or antimycotical agents.** Most animals
589 that were treated developed a mild reaction at the injection site (Mendoza and Newton, 2005).
590 After a week of immunotherapy it became evident that the hyphae of *P. insidiosum* in the
591 infected tissue were damaged. In dogs this therapy was also applied with some success
592 (Hensel et al., 2003). Immunotherapy in dogs has a lower cure rate than in horses and in cats
593 it has only has been tested three times with no response whatsoever (Thomas and Lewis,
594 1998). In cattle immunotherapy worked in the majority of the treated cases, about 65 animals
595 have been treated with success. This variation in success rate between species is intriguing
596 and deserves further study (see also *Immunology of Pythium insidiosum infections*). Vaccines
597 prepared from extracts of *P. insidiosum* cultures in liquid medium with ultrasound or by
598 vortexing have also been used for immunotherapy. The vaccine prepared by ultrasound
599 treatment showed no effect on the lesions while the vortexed vaccine reduced the lesions in
600 experimental rabbits by 71% (Santurio et al., 2003a).

601 In humans, immunotherapy was first successfully used in 1998 in a Thai boy who had
602 a *P. insidiosum* vascular infection where surgery and antimycotic therapy did not work
603 adequately. The boy was given a dose of *P. insidiosum* vaccine twice, with an interval of 2
604 weeks and within a year healing occurred (Thitithanyanont et al., 1998). In a clinical study in
605 people suffering from the vascular form of pythiosis, immunotherapy was used as a last resort
606 (Wanachiwanawin et al., 2004). After two administrations of the vaccine with a two week
607 interval, four patients reacted positively to the vaccine, two patients moderately and two
608 patients showed no response. The last two deceased within a short time. It is assumed that the
609 success of this therapy is better if it is applied as soon as the disease is diagnosed. The
610 mortality increases especially when people suffer from chronic lesions older than two months
611 (Wanachiwanawin et al., 2004). Until now ~60 Thai patients have been treated with
612 immunotherapy against *P. insidiosum* infection with about 55% cure rate.

613 A likely explanation for the mechanism by which immunotherapy against
614 *P.insidiosum* infection works is that a switch in the host's immune response occurs from a
615 Th2 (during infection) to a Th1 immune response (after immunotherapy) (Mendoza et al.,

616 2003, Mendoza and Newton, 2005). This is supported by the detection of an increase in
617 interleukins related to Th1 or Th2 immune responses (Thitithanyanont et al., 1998). For
618 instance, the immune response to *P. insidiosum* infection in humans appears in all cases to be
619 characterized by an elevated response in interleukin 4 and 5 production, with high IgE titers,
620 and inflammatory cells such as mast cells and eosinophils present in large amounts. This
621 response is consistent with a Th2 response and suggests that the pathogen has developed an
622 evolutionary strategy to present antigens to the immune system that may trigger such a
623 response. In contrast, in vaccinated cured patients a response with high titres of interleukin 2
624 and INF- γ which induce a mononuclear immune response, typical of a Th1 response is
625 triggered (Thitithanyanont et al., 1998, Mendoza et al., 2003a). Details of the immune
626 response triggered during infection and after immunotherapy are shown in (Fig. 11). It has
627 been argued that an effective treatment of *P. insidiosum* in the future should include
628 immunotherapy and a combination of both immunotherapy and surgery or immunotherapy
629 and antifungal drugs (Mendoza and Newton, 2005). A rapid diagnosis and an early start of the
630 treatment are essential in the management of this infection (Mendoza and Newton, 2005).

631

632 **Prevention**

633 *P. insidiosum* infection occurs after exposure of hosts with an open skin to
634 environments containing propagules (zoospores or hyphae) of the pathogen. Tropical wetland
635 environments have been implicated as important infection sites including ponds of water, soil
636 and grass in the endemic areas. People and animals in contact with zoospores (incriminated as
637 the infecting units) from the environment are at risk of contracting the infection. Besides
638 zoospores, hyphae and resting oospores are also seen as a possible source of infection.
639 Acquiring the infection from infected animals has not yet been reported (Mendoza, 2005,
640 Mendoza and Newton, 2005). In fact, Arvis (1916) mentions explicitly that a foal touching an
641 infected area beside the udder with its nose and lips for weeks stayed completely healthy.
642 Nevertheless, physicians and medical personnel should handle cases of the disease carefully
643 wearing protective gloves during treatment of wounds in humans and animals suffering from
644 pythiosis.

645

646 **Conclusions**

647 *Pythium insidiosum* is the cause of pythiosis, a rare non-transmissible disease that
648 currently occurs in the tropics, subtropics and some temperate regions. However, in view of
649 the global warming it can be expected that this disease could spread to more temperate areas

650 in the world (Mendoza, 2009). Relatively few cases of pythiosis are reported yearly,
651 irrespective of the species infected, but this is very likely an underestimation as the disease
652 mainly occurs in rural areas in developing countries. *Pythium insidiosum* has the appearance
653 of a fungus, but is closely related to algae and diatomaea. Infection occurs mainly in horses,
654 dogs and humans. Infections are caused by motile zoospores that are present in surface water
655 and infect an apparently healthy individual through small skin lesions. The zoospores are
656 attracted to these wounds or lesions by a chemo-attractant. No individual-individual
657 transmission occurs. Extensive surgery is in many cases the only way to treat patients. This is
658 not always successful and death of patients occurs regularly. Immunotherapy is also relatively
659 successful but a marked difference in response to immunotherapy from one species to another
660 is observed. The meaning of the immunogenic preferences within different hosts is not
661 known, but ongoing investigations in this area hopefully will soon shed some light on this
662 peculiar finding.

663 Since *P. insidiosum* is not a true fungus it does not react well to treatment with
664 antifungal agents. The search for a chemical therapy for this disease therefore has to continue
665 unabated. Little is known about potential virulence factors of the agent. Hopefully knowledge
666 of this aspect of *P. insidiosum* pathogenesis will increase once the complete nucleotide
667 sequence of its genome becomes available. In general the molecular biology of *P. insidiosum*
668 pathogenesis is not yet well developed in comparison to other infectious agents. Until then, *P.*
669 *insidiosum* will remain a fascinating microbe for those who study it and a devastating one for
670 those who suffer from it.

671
672 Acknowledgements.

673 We would like to thank Dr. Y. Perazzo, Dr. R.C. Thomas,, Dr. R. C. Perez , Dr. J.J. Luis-
674 Leon, Dr. F. Riet-Correa and Dr. S.M.S. Silva for allowing us to use the pictures shown in
675 Figs. 4, 5, 6 and 7.

676
677 **Conflict of interest.**

678 **A conflict of interest of one of the authors (LM) concerning immunotherapy should be**
679 **reported. The author has a commercial interest in the immunotherapy product.**

680
681 **References**

682 Alexopoulos, C.J., Mims, C.W., Blackwell, M., 1996. Introductory Mycology, 4th ed. John Wiley &
683 Sons, Inc., New York, N.Y., pp. 61-85, 683-737.

- 684 Alfaro, A.A., Mendoza, L., 1990. Four cases of equine bone lesions caused by *Pythium insidiosum*.
685 Equine Vet. J. 22, 295–297.
- 686 Allison, N., Gillis, J.P., 1990. Enteric pythiosis in a horse. J. Am. Vet. Med. Assoc. 196, 462-464.
- 687 Amemiya, J., 1969. Isolation of a fungus of the Mortierellaceae from an equine granular dermatitis III.
688 Bull. Fac. Agric. Kagoshima Univ. 19, 31–50.
- 689 Amemiya, J., 1982. Granular dermatitis in the horse, caused by *Pythium gracile*. Bull Fac Agric
690 Kagoshima Univ., 32, 141–147.
- 691 Argenta, J.S., Santurio, J.M., Alves, S.H., Pereira, D.I., Cavalheiro, A.S., Spanemberg, A., Ferreira, L.,
692 2008. In vitro activities of voriconazole, itraconazole, terbinafine, alone or in combination against *Pythium*
693 *insidiosum* isolates from Brazil. Antimicrob. Agents Chemother. 52, 767-769.
- 694 Argenta, J.S., Alves, S.H., Silveira, F., Maboni, G., Pereira, D.I.B., Spanemberg, A., Santurio, J.M.,
695 Ferreira, L., 2010. In vitro paradoxical growth of *Pythium insidiosum* in the presence of caspofungin. Vet.
696 Microbiol., doi:10.1016/j.vetmic.2010.04.001.
- 697 Austwick, P.K.C., Copland, J.W., 1974. Swamp cancer. Nature 250, 84.
- 698 Avis, J.A.R., 1916. Hyphomycosis destruens equi. Veeartsenijkundige Bld. voor Ned. Indië 28, 34-38.
- 699 Badenoch, P.R., Coster, D.J., Wetherall, B.L., Brettig, H.T., Rozenbils, M.A., Drenth, A., Wagels G.,
700 2001. *Pythium insidiosum* keratitis confirmed by DNA sequence analysis. Br. J. Ophthalmol. 85, 502-503.
- 701 Bangyeekhun, E., Cerenius, L., Söderhäll, K., 2001. Molecular cloning and characterization of two
702 serine proteinase genes from the crayfish plague fungus, *Aphanomyces astaci*. J. Invertebr. Pathol. 77, 206-216.
- 703 Berryessa, N.A., Marks, S.L., Pesavento, P.A., Krasnansky, T., Yoshimoto, S.K., Johnston, E.G.,
704 Grooters, A.M., 2008. Gastrointestinal Pythiosis in 10 Dogs from California. J. Vet. Intern. Med. 22, 1065-1069.
- 705 Bissonnette, K.W., Sharp, N.J., Dykstra, M.H., Robertson, I.R., Davis, B., Padhye, A.A. Kaufman, L.,
706 1991. Nasal and retrobulbar mass in a cat caused by *Pythium insidiosum*. J. VMed. Vet. Mycol. 29, 39-44.
- 707 Bridges, C. H., Emmons, C.W., 1961. A phycomycosis of horses caused by *Hyphomyces destruens*. J.
708 Am. Vet. Med. Assoc. 138, 579-589.
- 709 Brown, C.C., Roberts, E.D., 1988. Intestinal pythiosis in a horse. Aust. Vet. J. 65, 88-89.
- 710 Brown, T.A., Grooters, A.M., Hosgood, G.L., 2008. In vitro susceptibility of *Pythium insidiosum* and a
711 *Lagenidium* sp to itraconazole, posaconazole, voriconazole, terbinafine, caspofungin, and mefenoxam. Am. J.
712 Vet. Res. 69, 1463-1468.
- 713 Bubberman, C., 1914. Twee uitgebreide gevallen van *Hyphomycosis destruens equi*.
714 Veeartsenijkundige Mededeeling 12, 2-17.
- 715 Buergelt, C., Powe, J., White, T., 2006. Abdominal pythiosis in a Bengal tiger (*Panthera tigris tigris*).
716 J. Zoo Wildl. Med. 37, 186-189.
- 717 Camus, A.C., Grooters, A.M., Aquilar, R.F., 2004. Granulomatous pneumonia caused by *Pythium*
718 *insidiosum* in a central American jaguar, *Panthera onca*. J. Vet. Diagn. Invest. 16, 567-571.
- 719 Cavalheiro, A.S., Mabon, G., de Azevedo, M.I., Argenta, J.S., Pereira, D.I.B., Spader, T.B., Alves,
720 S.H., Santurio, J.M., 2009a. In vitro activity of terbinafine combined with caspofungin and azoles against
721 *Pythium insidiosum*. Antimicrob. Agents Chemother. 53, 2136-2138.
- 722 Cavalheiro, A.S., Zanette, R.A., Spader, T.B., Lovato, L., Azevedo, M.I., Botton, S., Alves, S.H.,
723 Santurio, J.M., 2009b. In vitro activity of terbinafine associated to amphotericin B, fluvastatin, rifampicin,
724 metronidazole and ibuprofen against *Pythium insidiosum*. Vet. Microbiol. 137, 408-411.
- 725 Chaffin, M.K., Schumacher, J., McMullan, W.J., 1995. Cutaneous pythiosis in the horse. Vet Clin
726 North Am: Equine Pract. 11, 91–103.
- 727 Chairprasert, A., Samerpitak, S., Wanachiwanawin, W., Thasnakorn, P., 1990. Induction of zoospore
728 formation in Thai isolates of *Pythium insidiosum*. Mycoses 33, 317-323.
- 729 Chandler, F. W., W. Kaplan, W., Ajello, L., 1980. A color atlas and textbook of the histopathology of
730 mycotic diseases., Year Book Medical Publishers, Inc., Chicago pp. 104-105.
- 731 Chindamporn, A., Vilela, R., Hoag, K.A., Mendoza, L., 2009. Antibodies in the sera of host species
732 with Pythiosis recognize a variety of unique immunogens in geographically divergent *Pythium insidiosum*
733 strains. Clin. Vac. Immunol. 16, 330-336.
- 734 Davis, D.J., Lanter, K., Makselan, S., Bonati, C., Asbrock, P., Ravishankar, J.P., Money, N.P., 2006.
735 Relationship between temperature optima and secreted protease activities of three *Pythium* species and
736 pathogenicity toward plant and animal hosts. Mycol. Res. 110, 96-103.
- 737 De Cock, A.W., Mendoza, L., Padhye, A., Ajello, L., Kaufman, L., 1987. *Pythium insidiosum* sp. Nov.,
738 the etiologic agent of pythiosis. J. Clin. Microbiol. 25, 344-349.
- 739 De Haan, J., Hoogkamer, L.J., 1901. Hypho-mycosis destruens. Veeartsenijkundige. Bld. voor Ned.
740 Indië 13, 350-374.
- 741 De Haan, J., 1902. Bosartige Schimmelkrankheit des Pferdes (Hyphomycosis destruens equi). Zentralbl.
742 Bakt. Parasitenkd. Infektionskr. Hyg. Abt. 1 Orig. 31, 758-763.

- 743 De Moraes Gimenes Bosco, S., Bagagli, E., Araújo, J.P. Jr., Candeias, J.M., de Franco, M.F., Alencar
 744 Marques, M.E., Mendoza, L., de Camargo, R.P., Alencar Marques, S., 2005. Human pythiosis, Brazil. *Emerg*
 745 *Infect Dis.* 11, 715-718.
- 746 De Moraes Gimenes Bosco, S., Martins Reis, G., Cordeira Theodora, R., Assis da Graça Macoris, S.,
 747 Alencar Marques, S., Da Graça Macoris, D., Bagagli, E., 2008. Morphological and molecular characterization of
 748 an equine isolate of *Pythium insidiosum* and comparison with the first human isolate from the same geographic
 749 region. *Med. Mycol.* 46, 557-565.
- 750 Deresinski, S.C., Stevens, D.A., 2003. Caspofungin. *Clin. Infect. Dis.*, 36, 1445-1457.
- 751 Dick, M.W., 2001. Straminipilous fungi: systematics of the peronosporomycetes including accounts of
 752 the marine straminipilous protist, the plasmodiophorids and similar organisms. Kluwer Academic publishers,
 753 London, England. pp.67.
- 754 Drouin, V. 1896. Sur une nouvelle mycose du cheval. *Recl. Med. Vet.* 3, 337-344.
- 755 Estrada-Garcia, M.T., Callow, J.A., Green, J.R., 1990. Monoclonal antibodies to the adhesive cell coat
 756 secreted by *Pythium aphanidermatum* zoospores recognize 200x300Mr glycoproteins stored within large
 757 peripheral vesicles. *J. Cell. Sci.* 95, 199-206.
- 758 Fish, P.A., 1895–96. Leeches: a histological investigation of two cases of equine mycosis with a
 759 historical account of a supposed similar disease, called bursatte, occurring in India. 12th and 13th Annual Report
 760 of the Bureau of Animal Industry 229–259.
- 761 Fischer, J.R., Pace, L.W., Turk, J.R., Kreeger, J.M., Miller, M.A., Gosser, H.S., 1994. Gastrointestinal
 762 pythiosis in Missouri dogs: eleven cases. *J. Vet. Diagn. Invest.* 6, 380–382.
- 763 Garcia, R.B., Pastor, A., Mendoza L., 2007. Mapping of *Pythium insidiosum* hyphal antigens and
 764 ultrastructural features using TEM. *Mycol. Res.* 111, 1352-60.
- 765 Goad, M.E., 1984. Pulmonary pythiosis in a horse. *Vet. Pathol.* 21, 261-262.
- 766 Gonzalez, H.E., Ruiz, A., 1975. Espundia equina: Etiologia y patogenesis de una ficomicosis. *Revista*
 767 *ICA Bogota (Colombia)* 10, 175.
- 768 Grooters, A.M., 2003. Pythiosis, lagenidiosis and zygomycosis in small animals. *Vet. Clin. North. Am.*
 769 *Small. Anim. Pract.* 33, 695-720.
- 770 Grooters, A.M., 2007. Pythiosis and Zygomycosis. In: Sellon, D., Long, M. (Eds), *Equine Infectious*
 771 *Diseases.* Saunders Elsevier, St. Louis, Missouri, USA, pp. 412-419.
- 772 Grooters, A.M., Gee, M.K., 2002. Development of a nested polymerase chain reaction assay for the
 773 detection and identification of *Pythium insidiosum*. *J. Vet. Intern. Med.* 16, 147-152.
- 774 Grooters A.M., Hodgins, E.C., Bauer, R.W., DeTrisac, C.J., Znajda, N.R., Thomas, R.C., 2003.
 775 Clinicopathologic findings associated with *Lagenidium* sp. infection in 6 dogs: initial description of an emerging
 776 oomycosis. *J Vet Intern Med.* 17, 637-46.
- 777 Grooters, A.M., Leise, B.S., Lopez, M.K., O'Reilly, K.L., 2002a. Development and evaluation of an
 778 Enzyme-Linked Immunosorbent Assay for the serodiagnosis of pythiosis in dogs. *J. Vet. Intern. Med.* 16, 142-
 779 146.
- 780 Grooters, A.M., Whittington, A., Lopez, M.K., Boroughs, M.N., Roy, A.F., 2002b. Evaluation of
 781 microbial culture techniques for the isolation of *Pythium insidiosum* from equine tissues. *J. Vet. Diagn. Invest.*
 782 14, 288-294.
- 783 Headley, S.A., Arruda, H.N., Leggi, T.C.S.S., Bett, V., 2002. Cutaneous pythiosis in a slaughtered
 784 horse: a case report. *Arq. Inst. Biol.* 69, 109-112.
- 785 Hendrix, J.W., 1964. Sterol induction of reproduction and stimulation of growth of *Pythium* and
 786 *Phytophthora*. *Science* 144, 1028-1029.
- 787 Hensel, P., Greene, C.E., Medleau, L., Latimer, K.S., Mendoza, L., 2003. Immunotherapy for treatment
 788 of multicentric cutaneous pythiosis in a dog. *J. Am. Vet. Med. Assoc.* 223, 215-218.
- 789 Hudspeth, D.S.S., Nadler, S.A., Hudspeth, M.E.S., 2000. A COX2 molecular phylogeny of the
 790 peronosporomycetes. *Mycologia* 92, 674-684.
- 791 Ichitani, T., Amemiya, J., 1980. *Pythium gracile* isolated from the foci of granular dermatitis in the
 792 horse (*Equus caballus*). *Trans Mycol Soc Jpn.* 21, 263–265.
- 793 Imwidthaya, P., 1994. Human pythiosis in Thailand. *Postgraduate Medicine J.* 70, 558-560.
- 794 Imwidthaya, P., Srimuang, S., 1989. Immunodiffusion test for diagnosing human pythiosis.
 795 *Mycopathologia*, 106, 109-112.
- 796 Jindayok, T., Piromsontikorn, S., Srimuang, S., Khupulsup, K., Krajaejun, T., 2009. Hemagglutination
 797 test for rapid serodiagnosis of human pythiosis. *Clin. Vac. Immunol.* 16, 1047-1051.
- 798 Kaufman, L., 1998. *Penicilliosis marneffei* and pythiosis: emerging tropical diseases. *Mycopathologia*
 799 143, 3-7.
- 800 Kerr, J., 1829. On the disease to which horses are subject to the East Indies, termed baursette.
 801 *Veterinarian* 2, 419-421.

- 802 Krajaejun, T., Imkhieo, S., Intaramat, A., Ratanabanangkoon, K., 2009 Development of an
 803 immunochromatographic test for rapid serodiagnosis of human pythiosis. *Clin. Vac. Immunol.* 16, 506-509.
- 804 Krajaejun, T., Sathapatayavongs, B., Prachartam, R., Nitiyanant, P., Leelachaikul, P.,
 805 Wanachiwanawin, W., Chairprasert, A., Assanasen, P., Saipeth, M., Moosikapun, P., Chetchotisakd, P.,
 806 Lekhakula, A., Mitarnun, W., Kalnauwakul, S., Supparatpinyo, K., Chaiwarith, R., Chiewchanvit, S., Tananuvat,
 807 N., Srisri, S., Suankratay, C., Kulwichit, W., Wongsaisuwana, M., Somkaew, S., 2006. Clinical and
 808 Epidemiological Analysis of Human Pythiosis in Thailand. *Clin. Infect. Dis.* 43, 569-576.
- 809 Krajaejun, T., Kunakorn, M., Niemhom, S., Chongtrakool, P., Prachartam, R., 2002. Development
 810 and evaluation of an in-house enzyme-linked immunosorbent assay for early diagnosis and monitoring of human
 811 pythiosis. *Clin. Diagn. Lab. Immunol.* 9, 378-82.
- 812 Kwon-Chung, K.J., 1994. Phylogenetic spectrum of fungi that are pathogenic to humans. *Clin. Infect.*
 813 *Dis.* 19, S1-7.
- 814 Laohapensang, K., Rutherford, R.B., Supabandhu, J., Vanittanakom, N., 2009. Vascular pythiosis in a
 815 thalassemic patient. *Vascular* 17, 234-238.
- 816 Leal, A.B., Leal, A.T., Santurio, J.M., Kommers, G.D., Catto, J.B. 2001. Pitiosis equina no Pantanal
 817 brasileiro: aspectos clínico-patológicos de casos típicos e atípicos. *Pesq.Vet. Bras.* 21, 151-56.
- 818 Lévesque, C.A., de Cock, A.W., 2004. Molecular phylogeny and taxonomy of the genus *Pythium*.
 819 *Mycol. Res.* 108, 1363-1383.
- 820 MacDonald, E., Millward, L., Ravishankar, J.P., Money, N.P., 2002. Biomechanical interaction
 821 between hyphae of two *Pythium* species (*Oomycota*) and host tissues. *Fungal Gen. Biol.* 37, 245-249.
- 822 Martin, F.N., 2000. Phylogenetic relationships among some *Pythium* species inferred from sequence
 823 analysis of the mitochondrially encoded cytochrome oxidase II gene. *Mycologia* 92, 711-727.
- 824 McMullan, W.C., Joyce, J.R., Hanselka, D.V., Heitmann, J.M., 1977. Amphothericin B for the
 825 treatment of localized subcutaneous phycomycosis in the horse. *J. Am. Vet. Med. Assoc.* 170:1293-8.
- 826 Mendoza, L., 2005. *Pythium insidiosum*. In: Merz, W.G., Hay, R.J. (eds). *Topley and Wilson's*
 827 *Microbiology and Microbial Infections. Medical Mycology* 10th edition. pp. 617-30.
- 828 Mendoza, L., 2009. *Pythium insidiosum* and mammalian hosts. In: K. Lamour and S. Kamoun (eds).
 829 *Oomycete Genetics and Genomics. Diversity, interaction, and research tools.* Wiley-Blackwell pp. 387-405.
- 830 Mendoza, L., Ajello, L., McGinnis, M.R., 1996. Infections caused by the oomycetous pathogen *Pythium*
 831 *insidiosum*. *J. Mycol. Med.* 6, 151-164.
- 832 Mendoza, L., Alfaro, A.A., 1986. Equine pythiosis in Costa Rica: Report of 39 cases. *Mycopathologia*,
 833 94, 123-129.
- 834 Mendoza, L., Alfaro, A.A., and Villalobos, J. 1988. Bone lesions caused by *Pythium insidiosum* in a
 835 horse. *J. Med. Vet. Mycol.* 26, 5-12
- 836 Mendoza, L., Hernandez, F., Ajello, L., 1993. Life Cycle of the human and animal oomycete pathogen
 837 *Pythium insidiosum*. *J. Clin. Microbiol.* 31, 2967-2973.
- 838 Mendoza, L., Kaufman, L., Mandy, W., Glass, R., 1997. Serodiagnosis of human and animal pythiosis
 839 using an enzyme-linked immunosorbent assay. *Clin. Diagn. Lab. Immunol.* 4, 715-718.
- 840 Mendoza, L., Kaufman, L., Standard, P.G., 1986. Immunodiffusion test for diagnosing and monitoring
 841 pythiosis in horses. *J. Clin. Microbiol.* 23, 813-816.
- 842 Mendoza, L., Kaufman, L., Standard, P., 1987. Antigenic relationship between the animal and human
 843 pathogen *Pythium insidiosum* and nonpathogenic *Pythium* spp. *J. Clin. Microbiol.* 25, 2159-2162.
- 844 Mendoza, L., Mandy, W., Glass, R., 2003. An improved *Pythium insidiosum*-vaccine formulation with
 845 enhanced therapeutic properties in immune horses and dogs with pythiosis. *Vaccine* 21, 2797-2804.
- 846 Mendoza, L., Marin, G., 1989. Antigenic relationship between *Pythium insidiosum* de Cock et al. 1987
 847 and its synonym *Pythium destruens* Sipton 1987. *Mycoses* 32, 73-77.
- 848 Mendoza, L., Newton, J. C., 2005. Immunology and immunotherapy of the infections caused by
 849 *Pythium insidiosum*. *Med. Mycol.* 43, 477-486.
- 850 Mendoza, L., Nicholson, V., Prescott, J.F., 1992a. Immunoblot analysis of the humoral immune
 851 response to *Pythium insidiosum* in horses with pythiosis. *J. Clin. Microbiol.* 30, 2980-2983.
- 852 Mendoza, L., Prasla, S.H., and Ajello. 2003. Orbital pythiosis: a non-fungal disease mimicking orbital
 853 mycotic infection, with retrospective review of the literature *Mycoses* 47, 14-23
- 854 Mendoza, L., Prendas, J., 1988. A method to obtain rapid zoosporegenesis of *Pythium insidiosum*.
 855 *Mycopathologia* 104, 59-62.
- 856 Mendoza, L., Villalobos, J., Calleja, C.E., Solis, A., 1992b. Evaluation of two vaccines for the
 857 treatment of pythiosis insidiosi in horses. *Mycopathologia*, 119, 89-95.
- 858 Miller, R.I., 1981. Treatment of equine phycomycosis by immunotherapy and surgery. *Aust. Vet. J.* 57,
 859 377-382.
- 860 Miller, R.I., 1983. Granulomatous and neoplastic disease of equine skin. *Veterinary Reviews and*
 861 *Monographs* No 6. James Cook University of North Queensland, Townsville, Australia. pp 1-92.

- 862 Miller, R.I., Campbell, R.S., 1983. Experimental pythiosis in rabbits. *Sabouraudia* 21, 331-341.
- 863 Miller, R.I., Campbell, R.S., 1984. The comparative pathology of equine cutaneous phycomycosis. *Vet.*
864 *Pathol.* 21, 325-332.
- 865 Miller, R.I., Olcott, B.M., Archer, M., 1985. Cutaneous pythiosis in beef calves. *J. Am. Vet. Med.*
866 *Assoc.* 186, 984-986.
- 867 Morton, L.D., Morton, D.G., Baker, G.J., Gelberg, H.B., 1991. Chronic eosinophilic enteritis attributed
868 to *Pythium* sp. in a horse. *Vet. Pathol.* 288, 542-544.
- 869 Murdoch, D., Parr, D., 1997. *Pythium insidiosum* keratitis. *Australian New Zealand J. of*
870 *Ophthalmology* 25, 177-179.
- 871 Patino-Meza, F., 1988. Role of the zoospores of *Pythium insidiosum* in the experimental reproduction
872 of pythiosis in susceptible species. DVM thesis, National University, Heredia, Costa Rica 1-31.
- 873 Pereira, D.I.B., Santurio, J.M., Alves, S.H., Argenta, J.S., Potter, L., Spanamberg, A., Ferreira, L., 2007
874 Caspofungin *in vitro* and *in vivo* activity against Brazilian *Pythium insidiosum* strains isolated from animals. *J.*
875 *Antimicrob. Chemother.* 60, 1168-1171.
- 876 Pereira, D.I.B., Santurio, J.M., Alves, S.H., de Azevedo, M.I., Silveira, F., da Costa, F.F., Sallis,
877 E.S.V., Pötter, L., Ferreira, L., 2008. Comparison between immunotherapy and caspofungin as agents to treat
878 experimental pythiosis in rabbits. *J. Mycol. Med.* 18, 129-133.
- 879 Pérez, R., Luis-León, J.J., Vivas, J.L., Mendoza, L., 2005. Epizootic cutaneous pythiosis in beef calves.
880 *Vet. Microbiol.* 109, 121-128.
- 881 Pesavento, P.A., Barr, B., Riggs, S.M., Eigenheer, A.L., Pamma, R., Walker, R.L., 2008. Cutaneous
882 pythiosis in a nestling white faced ibis. *Vet. Pathol.* 45, 538-541.
- 883 Prachartam, R., Changtrakool, P., Sathapatayavongs, B., Jayanetra, P., Ajello, L., 1991.
884 Immunodiffusion test for diagnosis and monitoring of human pythiosis insidiosum. *J. Clin. Microbiol.*, 29, 138-
885 141.
- 886 Pupaibool, J., Chindamporn, A., Patarakul, K., Suankratay, C., Sinduphak, W., Kulwichit, W., 2006.
887 Human Pythiosis. *Emerg. Infect. Dis.* 12, 517-518.
- 888 Purcell, K.L., Johnson, P.J., Kreeger, J.M., Wilson, D.A., 1994. Jejunal obstruction caused by a
889 *Pythium insidiosum* granuloma in a mare. *J. Am. Vet. Med. Assoc.* 205, 337-339.
- 890 Rakich, P.M., Grooters, A.M., Tang, K-N., 2005. Gastrointestinal pythiosis in two cats. *J Vet. Diagn.*
891 *Invest.* 17,262-269.
- 892 Ravishankar, J.P., Davis, C.M., Dacis, D.J., MacDonald, E., Makselan, S.D., Millward, L., Money,
893 N.P., 2001, Mechanics of solid tissue invasion by the mammalian pathogen *Pythium insidiosum*. *Fung. Genet.*
894 *Biol.* 34, 167-175.
- 895 Rees, C.A., 2004. Disorders of the skin. In: Reed, S.M., Bayly, W.M., Sellon, D.C., *Equine Internal*
896 *Medicine*. Saunders, 2nd edition: 695-696.
- 897 Reis, J.L., Quirez de Carvalho, E.C., Girão Nogueira, R.H., Lemos, L.S., Mendoza, L., 2003.
898 Disseminated pythiosis in three horses. *Vet. Microbiol.* 96, 289-295.
- 899 Ribes, J.A., Vanover-Sams, C.L., Baker, D.J., 2000. Zygomycetes in human disease. *Clin. Microbiol.*
900 *Rev.* 13, 236-301.
- 901 Riet-Correa, F., Dantas, A.F.M., Azevedo E.O., Simoes, S.D.V., Silva, S.M.S., Vilela, R., Mendoza, L.,
902 2008. Outbreak of rhinopharyngeal zygomycosis in sheep in Paraiba, Northeastern Brazil. *Pesq. Vet. Bras.* 28,
903 29-35.
- 904 Rinaldi, M.G., Seidenfeld, S.M., Fotherbill, A.M., McGough, D.A., 1989. *Pythium insidiosum* causes a
905 severe disease in a healthy boy. *Mycol. Observer* 9, 7.
- 906 Rivierre, C., Laprie, C., Guiard-Marigny, O., Bergeaud, P., Berthelemy, M., Guillott, J., 2005.
907 Pythiosis in Africa. *Emerg. Infect. Dis.* 11, 479-481.
- 908 Santurio, J.M., Argenta, J.A., Schwendler, S.E., Cavalheiro, A.S., Pereira, D.I.B., Zanette, R.A., Alves,
909 S.H., Dutra, V., Silva, M.C., Arruda, L.P., Nakazata, L., Colodel, E.M., 2008. Granulomatous rhinitis associated
910 with *Pythium insidiosum* infection in sheep. *Vet. Rec.* 163, 276-277.
- 911 Santurio, J.M., Leal, A.T., Leal, A.B.M., Festugatto, R., Lubeck, I., Sallis, E.S.V., Copetti, M.V.,
912 Alves, S.H., Ferreira, L., 2003a. Three types of immune therapy against pythiosis insidiosum developed and
913 evaluated. *Vaccine* 21, 2535-2540.
- 914 Santurio, J.M., Leal, A.T., Monteiro, A.B., 2003b. Pythiose. In: Lefèvre, P.C., Blancou, J., Chermette,
915 R., (eds). *Principales maladies infectieuses et parasitaires de bétail*. Lavoisier, Paris. pp. 1231-1241.
- 916 Santurio, J.M., Monteiro, A.B., Leal, A.T., Kommers, G.D., de Sousa, R.S., Catto, J.B., 1998.
917 Cutaneous Pythiosis insidiosum in calves from the Pantanal region of Brazil. *Mycopathologia* 141, 123-125.
- 918 Sathapatayavongs, B., Leelachaikul, P., Prachartam, R., Atichartakarn, V., Sciphojanart, S.,
919 Trairatvorakul, P., Jirasiritham, S., Nontasut, S., Eurvilaichit, C., Flegel, T., 1989. Human pythiosis associated
920 with thalassemia hemoglobinopathy syndrome. *J. Infect. Dis.* 159, 274-280.

- 921 Schurko, A.M., Mendoza, L., de Cock, A.W., Klassen, G.R., 2003a. Evidence for geographic clusters:
 922 molecular genetic differences among strains of *Pythium insidiosum* from Asia, Australia and the Americas are
 923 explored. *Mycologia* 95, 200-208.
- 924 Schurko, A.M., Mendoza, L., Lévesque, C.A., Désaulniers, N.L., de Cock, A.W., Klassen, G.R.,
 925 2003b. A molecular phylogeny of *Pythium insidiosum*. *Mycol. Res.* 107, 537-544.
- 926 Schurko, A.M., Mendoza, L., de Cock, A.W.A.M., Bedard, J.E.J., Klassen, G.R., 2004. Development
 927 of a species specific probe for *Pythium insidiosum* and the diagnosis of Pythiosis. *J. Clin. Microbiol.* 42, 2411-
 928 2418.
- 929 Sekhon, A.S., Padhye, A.A., Garg, A.K., 1992. In vitro sensitivity of *Penicillium marneffeii* and *Pythium*
 930 *insidiosum* to various antifungal agents. *Eur. J. Epidemiol.* 8, 427-432.
- 931 Shenep, J.L., English, B.H., Kaufman, L., Pearson, T.A., Thompson, J.W., Kaufman, R.A., Frisch, G.,
 932 Rinaldi, M.G., 1998. Successful medial therapy for deeply invasive facial infection due to *Pythium insidiosum* in
 933 a child. *Clin. Infect. Dis.* 27, 1388-1393.
- 934 Shipton, W.A., 1987. *Pythium destruens* sp.nov., an agent of equine pythiosis. *J. Med. Vet. Mycol.* 25,
 935 137-151.
- 936 Smith, F., 1884. The pathology of bursattee. *Vet. J.*, 19, 16-17.
- 937 Sohn, Y., Kim, D., Kweon, O., Seo, I., 1996. Enteric pythiosis in a Jindo dog. *Korean J. Vet. Res.* 36,
 938 447-51.
- 939 Supabandhu, J., Mathew C.F., Mendoza, L., Vanittanakom, N. 2008. Isolation and identification of the
 940 human pathogen *Pythium insidiosum* from environmental samples collected in Thai agricultural areas. *Med.*
 941 *Mycol.* 46, 41-52.
- 942 Tabosa, I.M., Riet-Correa, A.F., Nobre, V.M.T., Azevedo, E.O., Reis-Júnior, J.L., Medeiros, R.M.T.,
 943 2004. Outbreaks of pythiosis in two flocks of sheep in northeastern Brazil. *Vet. Pathol.* 41, 412-415.
- 944 Thianprasit, M. 1986. Fungal infection in Thailand. *Jpn J Dermatol.* 96, 1343-1345.
- 945 Thianprasit, M. 1990. Human pythiosis. *Trop Dermatol.* 4, 1-4.
- 946 Thitithanyanont, A., Mendoza, L., Chuansumrit, A., Prachartam, R., Laothamatas, J.,
 947 Sathapatayayongs, B., Lolekha, S., Ajello, L., 1998. Use of an immunogenic therapeutic vaccine to treat a life-
 948 threatening human arteritic infection caused by *Pythium insidiosum*. *Clin. Infect. Dis.*, 27, 1394-1400.
- 949 Thomas, R.C., Lewis, D.T., 1998. Pythiosis in dogs and cats. *Compend. Contin. Educ. Pract. Vet.* 20,
 950 63-74.
- 951 Torto-Alalibo, T., Tian, M., Gajendran, K., Waugh, M.E., van West, P., Kamoun, S., 2005. Expressed
 952 sequence tags from the oomycete fish pathogen *Saprolegnia parasitica* reveal putative virulence factors. *BMC.*
 953 *Microbiol.* 5, 46.
- 954 Triscott, J.A., Weedon, D., Cabana, E., 1993. Human subcutaneous pythiosis. *J. Cutaneous Pathol.* 20,
 955 267-271.
- 956 Virgile, R., Perry, H.D., Pardanani, B., Szabo, K., Rahn, E.K., Stone, J., Salkin, I., Dixon, D.M., 1993.
 957 Human corneal ulcer caused by *Pythium insidiosum*. *Cornea* 12, 81-3.
- 958 Vanittanakom, N., Supabandhu, J., Khamwan, C., Praparattanapan, J., Thirach, S., Prasertwikayakij, N.,
 959 Louthrenoo, W., Chiewchanvit, S., Tananuvat, N., 2004. Identification of Emerging Human-Pathogenic *Pythium*
 960 *insidiosum* by serological and molecular assay based methods. *J. Clin. Microbiol.* 42, 3970-3974.
- 961 Walker, C.A., van West, P., 2007. Zoospore development in the oomycetes. *Fungal Biol. Rev.*, 21, 10-
 962 18.
- 963 Wanachiwanawin, W., Mendoza, L., Visuthisakchai, S., Mutsikapan, P., Sathapatayayongs, B.,
 964 Suwanagool, P., Manuskiatti, W., Ruangsetakit, C., Ajello, L., 2004. Efficacy of immunotherapy using antigens
 965 of *Pythium insidiosum* in the treatment of vascular pythiosis in humans. *Vaccine*, 22, 3613-3621.
- 966 Wellahan, J.F., Farina, L.L., Keoughan, C.G., Lafortune, M., Grooters, A.M., Mendoza, L., Brown, M.,
 967 Terrel, S.P., Jacobson, E.R., Heard, D.J., 2004. Pythiosis in a dromedary camel (*Camelus dromedaries*). *J. Zoo*
 968 *Wildl. Med.* 35, 564-568.
- 969 White, S.D., Ghoddsi, M., Grooters, A.M., Jones, K., 2008. Cutaneous pythiosis in a California
 970 nontravelled horse. *Vet. Dermatol.* 19, 391-394.
- 971 Witkamp, J., 1924. Bijdrage tot de kennis van de *Hyphomycosis destruens*. *Ned. Ind. Blad voor*
 972 *Diergeneeskd. en Dierenteelt*, 36, 229-245.
- 973 Witkamp, J. 1925. Het voorkomen van metastasen in de regionale lymphlieren by *Hyphomycosis*
 974 *destruens*. *Ned Ind Blad voor Diergeneeskd en Dierenteelt* 37, 79-102.

978 Legends to Figures

979

980 Figure 1 A five days old culture of *Pythium insidiosum* at 37°C grown on 2% Sabouraud
 981 dextrose agar (Panel A). *P. insidiosum* from plate cultures showing sparsely septate hyphae in
 982 lactophenol blue (20 X) (Panel B).

983
 984 Figure 2 Fresh kunkers collected from a horse with cutaneous pythiosis. Kunkers are
 985 stony masses found only in horses with pythiosis. Note the different shapes developed in
 986 horses with pythiosis. Similar masses have been reported in equine habronemiasis. A
 987 differential diagnosis of habronemiasis and pythiosis can be made by demonstration of
 988 sparsely septate hyaline hyphae within kunkers in the case of pythiosis.

989
 990 Figure 3 Equine pythiosis can affect different areas of the skin (Panel A and B) and in
 991 chronic cases bones can also be invaded (Panel C).

992
 993 Figure 4. In Panel A and B the clinical manifestation of cutaneous pythiosis in dogs is
 994 shown. In dogs this type of infection is very insidious and life threatening. Ulcerate
 995 granulomatous tissues, usually contaminated with bacteria are the main characteristic of dog
 996 pythiosis. Intestinal pythiosis is the most common type of infection in this species. In Panel C
 997 a duodenal tumoral-like mass from a dog with chronic gastro-intestinal tract pythiosis is
 998 shown (Courtesy of Dr. Y. Perazzo).

999
 1000 Figure 5. Pythiosis in cats occurs less frequent than in dogs and horses. The infection
 1001 affects the subcutaneous tissue but rarely becomes ulcerate. The cat in the figure has a typical
 1002 mass near the toraxic area caused by *Pythium insidiosum* (Courtesy of Dr. R.C. Thomas)

1003
 1004 Figure 6. In Panels A and B two beef cattle with ulcerate tissue caused by *Pythium*
 1005 *insidiosum* are shown. Note the swelling of the affected limb and the presence of some
 1006 fistulae (Panel A) (Courtesy of Drs. R.C. Perez and J.J. Luis-Leon).

1007
 1008 Figure 7. In Panel A a sheep with a strong inflammation of the face and bloody
 1009 rhinorrhea caused by *Pythium insidiosum* is shown. In Panel B the location of the
 1010 granulomatous tissue is inside the nostril passages (Courtesy of Drs. F. Riet-Correa and
 1011 S.M.S. Silva).

1012
 1013 Figure 8. A 10% KOH wet mount preparation of a kunker from a horse. Panel A and B
 1014 are the continuous microscopic field of the clinical sample. Note the long sparsely septate
 1015 hyaline hyphae of *Pythium insidiosum*. The presence of numerous vesicles within the hyphae
 1016 is usually observed.

1017
 1018 Figure 9. Water cultures containing positive ions and grass leaves inoculated with
 1019 *Pythium insidiosum* trigger the formation of sporangia containing zoospores. Sporangia are
 1020 not differentiated from vegetative hyphae and are present inside the grass blades. Only a
 1021 hypha-like discharge tube grows out through which the protoplasm is released in a thin-
 1022 walled vesicle at the tip. Inside the vesicle the zoospores are differentiated. Zoospores are
 1023 released after rupture of the vesicle membrane. Panel A: the vesicles with zoospores that
 1024 developed after three hours incubation. Panel B: a close-up of a vesicle before zoospore
 1025 release. Below the vesicle the empty discharge tube is visible.

1026
 1027 Figure 10. Panels A and B are H&E histological preparations showing a granulomatous
 1028 reaction with numerous eosinophils, giant cells, mast cells and other cells from an intestinal
 1029 case of dog pythiosis. Panel B: unstained hyphae of *Pythium insidiosum* (arrow, 40X). Panels

1030 C (20X) and D (50X) are a Silver stain preparation of the same tissue. Note the presence of
1031 numerous none septate hyphae, some forming rounded shape structures.

1032

1033 Figure 11. The right section of the figure shows the inflammatory response of a host
1034 naturally exposed to *Pythium insidiosum*. In this scenario, zoospores (or other propagules) of
1035 *P. insidiosum* attach to the injured skin of a host; the encysted zoospore stimulated by the
1036 host's temperature develops a germ tube that actively penetrates the host tissue causing the
1037 infection. As the hypha develops it releases exoantigens that are presented to the host immune
1038 system. The antigen presenting cells (APC) will process the immunogens and by releasing
1039 IL4 the Th0 naïve cells become Th2. The stimulated Th2 subset will then release IL4, IL5,
1040 and IL10, which in turn stimulates B cells to produce precipitating IgG, IgM and IgE
1041 molecules. IgE along with IL5 triggers the migration of mast cells and eosinophils to the site
1042 of infection that later degranulate over the *P. insidiosum* hyphae causing tissue damage in the
1043 infected host. The left side of the figure depicts the putative response to *P. insidiosum*
1044 immunogens after immunotherapy. Upon injection the immunogens are presented to APC in a
1045 different fashion than during natural infection. The Th0 naïve cells turn into Th1 releasing
1046 IFN γ and IL2 stimulating the cell mediate immunity (CMI) and cytotoxic lymphocytes (CTL)
1047 that eventually could eliminate the pathogen from the infected tissues. Experimental evidence
1048 suggests that this strategy could protect the host for short periods of time (one year) by
1049 stimulating B cells to produce protective IgG classes.

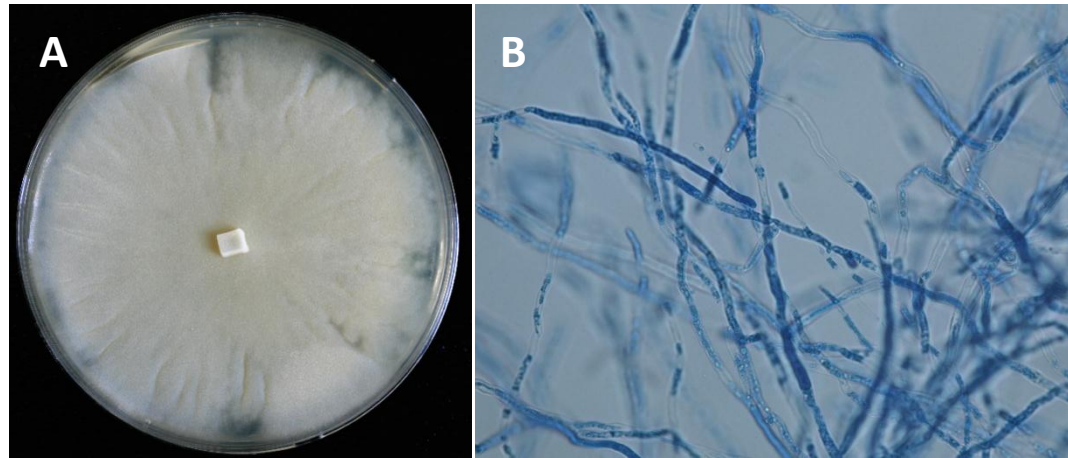


Figure 1

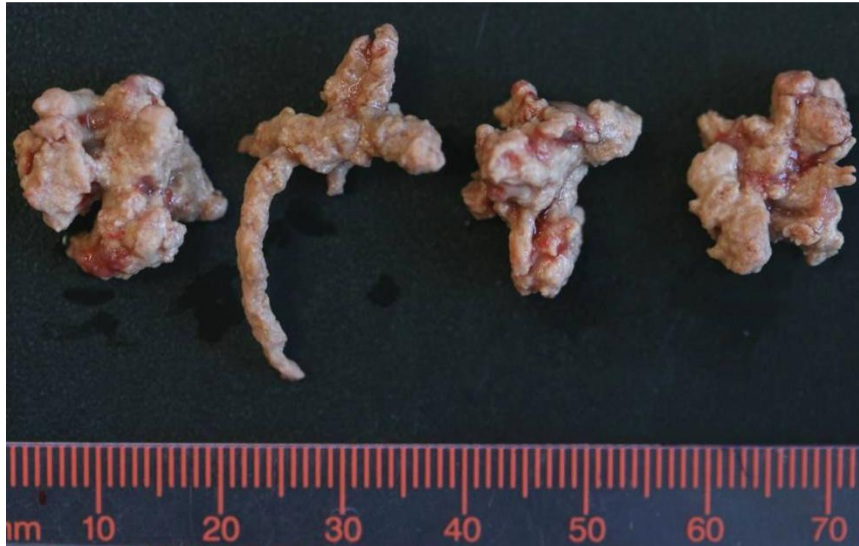


Figure 2

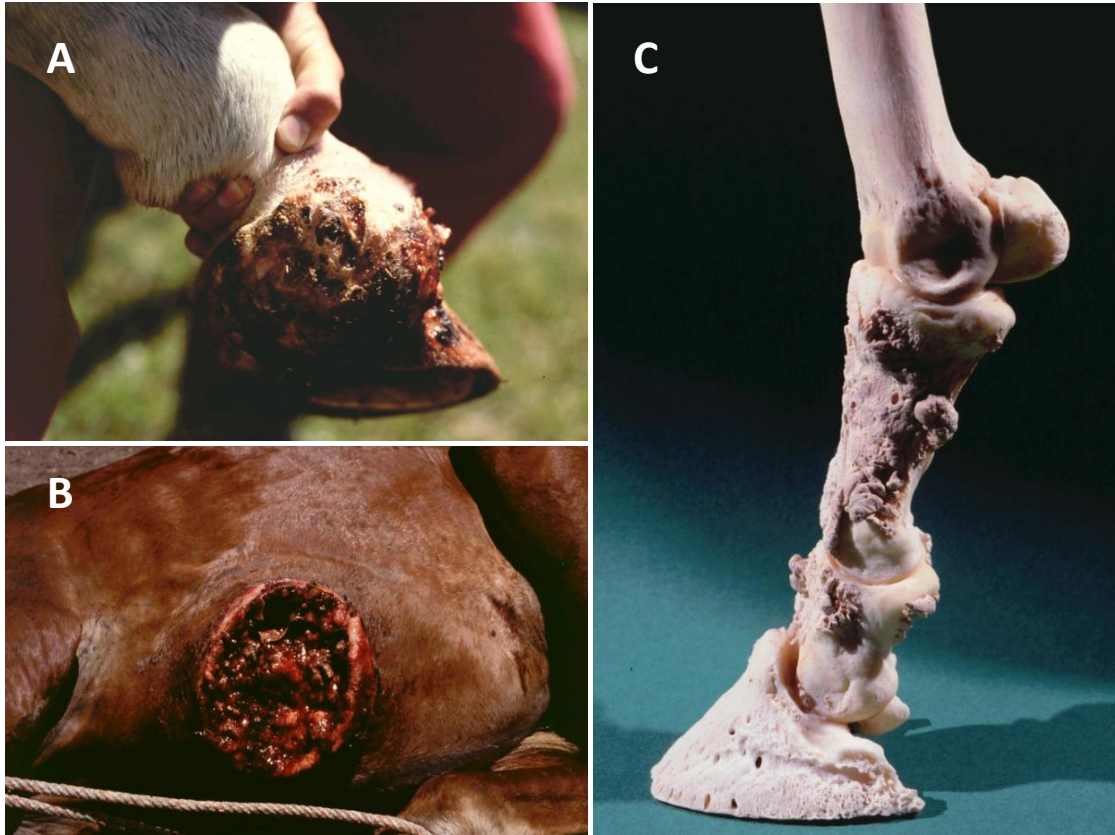

Figure 3

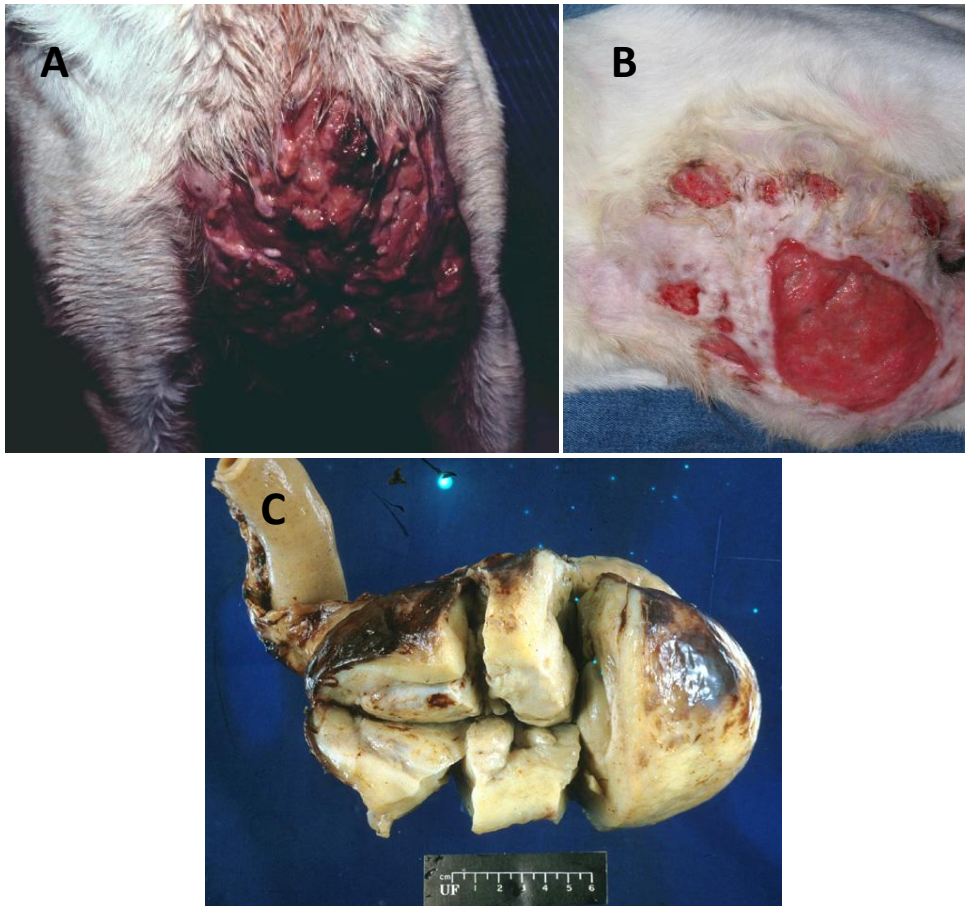


Figure 4

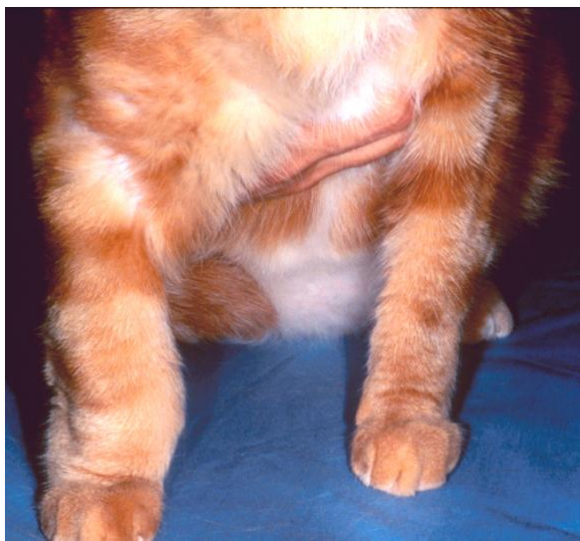


Figure 5

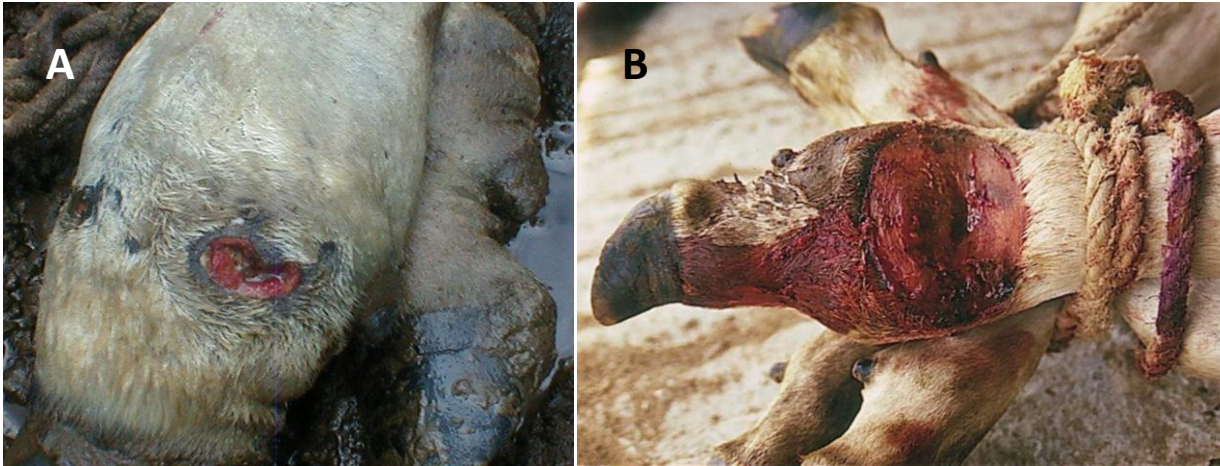


Figure 6

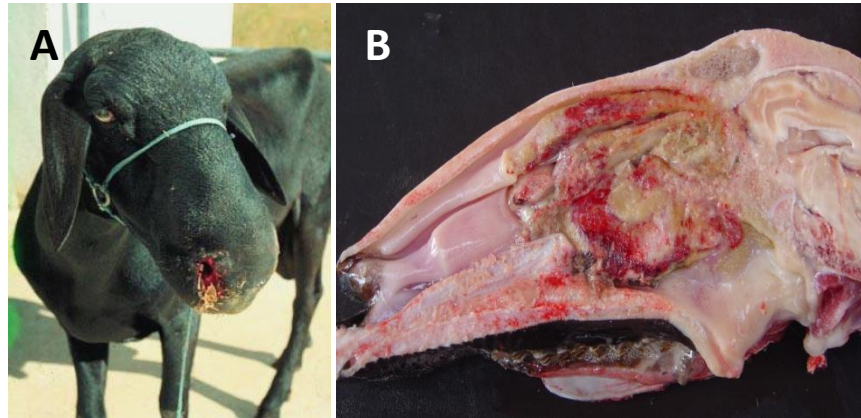


Figure 7

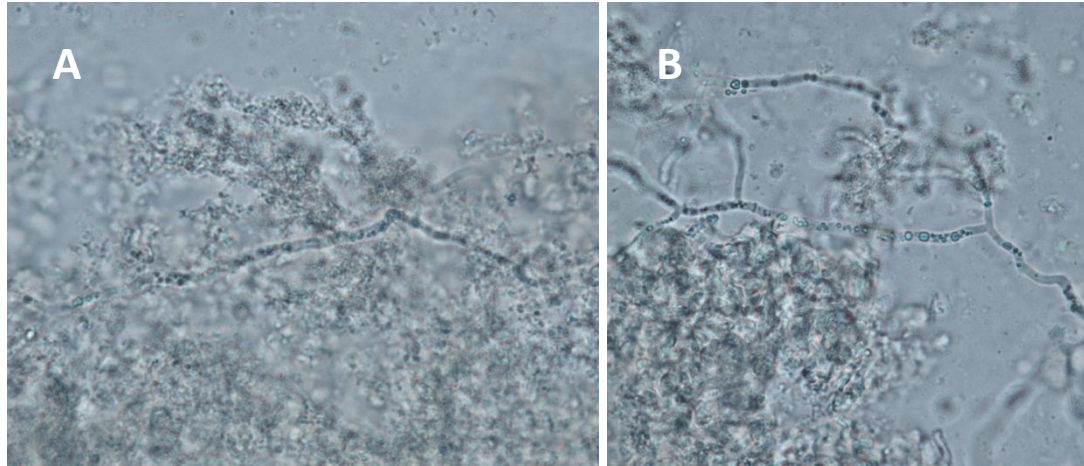


Figure 8

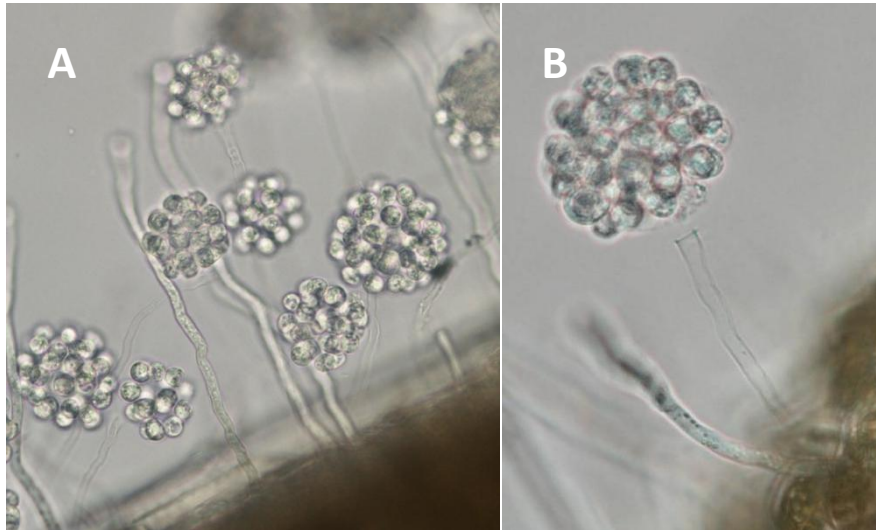


Figure 9

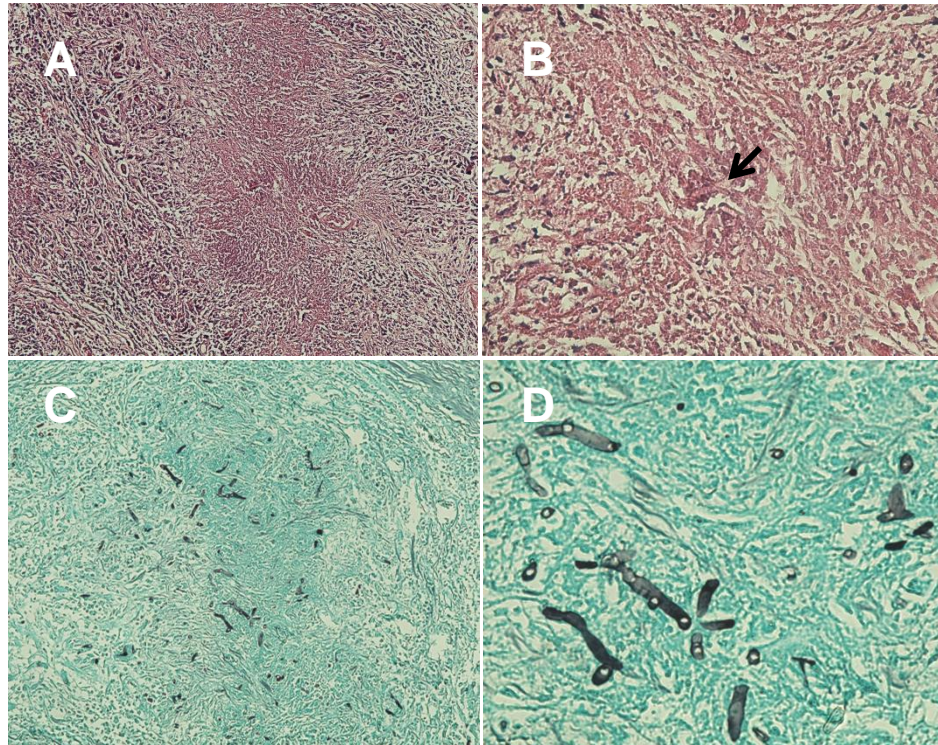


Figure 10

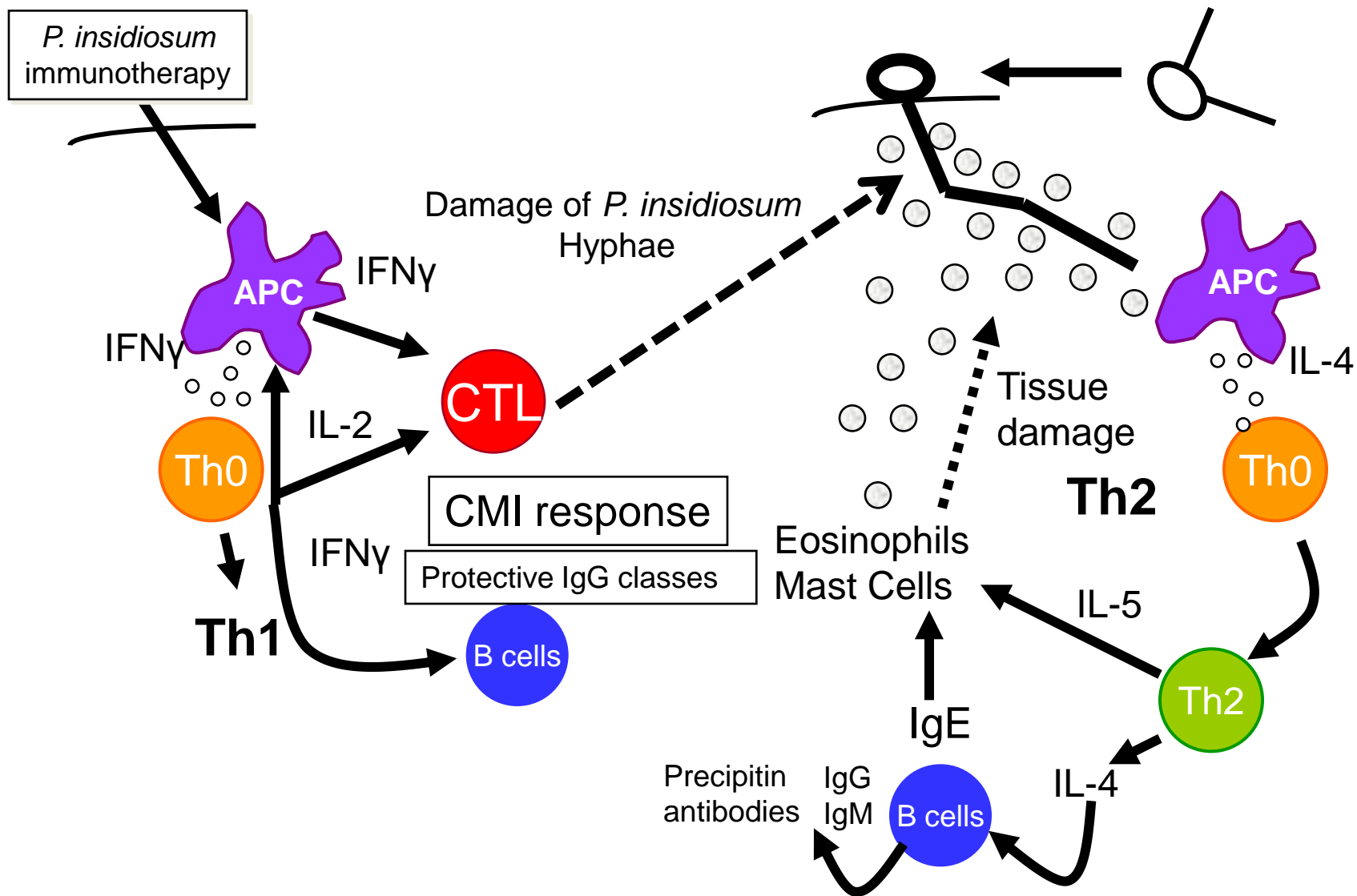


Figure 11 Redrawn after Mendoza and Newton, 2005