



**HAL**  
open science

## **Genomic and clinical characteristics of six patients with partially overlapping interstitial deletions at 10p12p11**

Christian Wentzel, Evica Rajcan-Separovic, Claudia Ruivenkamp, Sandra Chantot-Bastaraud, Corinne Metay, Joris Andrieux, Göran Annerén, Antoinet Gijbbers, Luc Druart, Capucine Hyon, et al.

### ► To cite this version:

Christian Wentzel, Evica Rajcan-Separovic, Claudia Ruivenkamp, Sandra Chantot-Bastaraud, Corinne Metay, et al.. Genomic and clinical characteristics of six patients with partially overlapping interstitial deletions at 10p12p11. *European Journal of Human Genetics*, 2011, <10.1038/ejhg.2011.71>. <hal-00636187>

**HAL Id: hal-00636187**

**<https://hal.science/hal-00636187v1>**

Submitted on 27 Oct 2011

**HAL** is a multi-disciplinary open access archive for the deposit and dissemination of scientific research documents, whether they are published or not. The documents may come from teaching and research institutions in France or abroad, or from public or private research centers.

L'archive ouverte pluridisciplinaire **HAL**, est destinée au dépôt et à la diffusion de documents scientifiques de niveau recherche, publiés ou non, émanant des établissements d'enseignement et de recherche français ou étrangers, des laboratoires publics ou privés.



HAL Authorization

1 **Genomic and clinical characteristics of six patients with partially**  
2 **overlapping interstitial deletions at 10p12p11**

3 Christian Wentzel<sup>a</sup>, Evica Rajcan-Separovic<sup>b</sup>, Claudia A L Ruivenkamp<sup>c</sup>, Sandra Chantot-  
4 Bastaraud<sup>d</sup>, Corinne Metay<sup>e</sup>, Joris Andrieux<sup>f</sup>, Göran Annerén<sup>a</sup>, Antoinet C J Gijsbers<sup>c</sup>, Luc  
5 Druart<sup>d</sup>, Capucine Hyon<sup>g</sup>, Marie-France Portnoi<sup>d</sup>, Eva-Lena Stattin<sup>h</sup>, Catherine Vincent-  
6 Delorme<sup>f</sup>, Sarina G Kant<sup>e</sup>, Michelle Steinraths<sup>i</sup>, Sandrine Marlin<sup>d</sup>, Irina Giurgea<sup>e</sup>, Ann-Charlotte  
7 Thuresson<sup>a,\*</sup>

8 <sup>a</sup> Department of Immunology, Genetics and Pathology, Uppsala University, Uppsala, Sweden

9 <sup>b</sup> The Child and Family Research Institute and University of British Columbia, Vancouver, BC  
10 Canada

11 <sup>c</sup> Department of Clinical Genetics, Center for Human and Clinical Genetics, Leiden University  
12 Medical Center (LUMC), Leiden, The Netherlands

13 <sup>d</sup> Service de Génétique, Hôpital Armand Trousseau, Paris, France

14 <sup>e</sup> Service de Biochimie-Génétique, Plateforme de Génomique Constitutionnelle, Hôpital Henri  
15 Mondor, Créteil, France

16 <sup>f</sup> Laboratoire de Génétique Médicale, Hopital Jeanne de Flandre, CHRU de Lille, France

17 <sup>g</sup> Université Paris decarte, Service de génétique hôpital necker Paris, France

18 <sup>h</sup> Department of Medical Biosciences, Medical and Clinical Genetics, Umeå University, Sweden

19 <sup>i</sup> Department of Laboratory Medicine, Pathology and Medical Genetics, Victoria General  
20 Hospital, Victoria, BC Canada

21  
22 **\*Corresponding author:** Ann-Charlotte Thuresson, PhD. Department of Immunology, Genetics  
23 and Pathology, Uppsala University, 751 85 Uppsala, SWEDEN

24 Phone: +46-18-611 2441

25 **Fax:** +46-18-554025

26 **E-Mail:** ann-charlotte.thuresson@igp.uu.se

27

28

## 29 **Abstract**

30 With the clinical implementation of genomic microarrays, the detection of cryptic unbalanced  
31 rearrangements in patients with syndromic developmental delay has considerably improved.  
32 Here we report the molecular karyotyping and phenotypic description of six new unrelated  
33 patients with partially overlapping microdeletions at 10p12.31p11.21 ranging from 1.0 Mb to  
34 10.6 Mb. The smallest region of overlap is 306 kb, which includes *WAC* gene, known to be  
35 associated with microtubule function and to play a role in cell division. Another patient has  
36 previously been described with a 10 Mb deletion, partially overlapping with our six patients. All  
37 seven patients have developmental delay and a majority of the patients have abnormal behaviour  
38 and dysmorphic features including bulbous nasal tip, deep set eyes, synophrys/thick eyebrows,  
39 and full cheeks, while other features varied. All patients also displayed various visual  
40 impairments and 6 out of 7 patients had cardiac malformations. Together with the previously  
41 reported patient, our study suggests that the detected deletions may represent a new contiguous  
42 gene syndrome caused by dosage sensitive genes that predispose to developmental delay.

43

## 44 **Keywords:**

45 10p deletion, Developmental delay, Dysmorphic features, Learning disability, Mental  
46 retardation, WAC

## 47 **Introduction**

48 Today, genome-wide microarray based screening for detection of copy number variations (CNV)  
49 is routinely offered to patients with developmental delay (DD) and dysmorphic features. The  
50 outcome of this is an increasing number of reported newly detected syndromes, and databases

51 like DECIPHER (<http://decipher.sanger.ac.uk/>) and Ecaruca  
52 (<http://agserver01.azn.nl:8080/ecaruca/ecaruca.jsp>) have become important tools in collecting  
53 clinical information for detected chromosomal imbalances.

54

55 The recurrent CNVs associated with new syndromes are in some cases fairly consistent in size  
56 with reproducible breakpoints that map to areas of low copy repeats, as for example in Smith  
57 Magenis and Williams-Beuren syndrome<sup>1</sup>. On the other hand, other genomic abnormalities,  
58 although mapping to the same chromosomal region, may show a range of sizes and variable  
59 breakpoints with small areas of overlap like the 2q33.1<sup>2</sup> and 12q14 microdeletion syndromes<sup>3-4</sup>.

60

61 Recurrent chromosomal abnormalities involving the short arm of chromosome 10 have been  
62 rarely reported, and involve for example the DiGeorge syndrome region 2 (MIM 601362) with  
63 breakpoints mapping at 10p14-p13. Here we report six patients presenting with partially  
64 overlapping microdeletions of a more proximal region of the short arm of chromosome 10  
65 (10p12.31p11.21), ranging from 1 to 10 Mb, with a common overlap of 306 kb. There is one  
66 previous report of a patient with DD and dysmorphic features presenting with a microdeletion  
67 within this region detected with arrayCGH<sup>5</sup>. The seven patients share some phenotypic traits and  
68 dysmorphic features. We describe the phenotypic traits that are shared between all individuals  
69 and suggest that microdeletions of 10p12.31p11.21 might be associated with a new clinically  
70 recognisable microdeletion syndrome.

71

## 72 **Materials and methods**

### 73 *Patients*

74 DNA studies were performed after informed consent was obtained for all patients. Genomic  
75 DNA was extracted from peripheral blood leukocytes from patients using standard procedures.  
76 All patients showed a normal chromosomal karyotype by G-banding, except patients 4 and 5  
77 who had a visible interstitial 10p deletion.

78

### 79 *Microarray analysis*

80 The deletion in patient 1 was detected by an Affymetrix Genome-Wide SNP Array 6.0  
81 (Affymetrix Inc, Santa Clara, California, USA). Data analysis was carried out with Genotyping  
82 Console 4.0.

83 Agilent array was used to detect deletions in patients 2, 4, 5 and 6. In patient 2 and 5, the deletion  
84 was detected by Agilent Human 105A array and in patient 6 with Agilent Human 244K array  
85 (Agilent, Santa Clara, California, USA). Data analysis was carried out with DNA Analytics  
86 4.0.76. In patient 4, the deletion was mapped using the Agilent Human 44K array. An Agilent  
87 Human 105A array was later used to refine the breakpoints of the detected deletion.  
88 Confirmation of the deletion and parental analysis of patient 5 was carried out by using Cytochip  
89 v2.0 microarray (Bluegenome, Cambridge, UK) and data analysis with BlueFuse for Microarrays  
90 v3.5 (Bluegenome, Cambridge, UK).

91 In patient 3, Illumina's HumanHap300 Genotyping BeadChip was used to detect CNVs. Data  
92 analysis was carried out with BeadStudio version 3.0. Parental analysis of patient 3 was  
93 performed with the same method.

94 All microarray and data-analysis were performed in accordance with the manufacturer's  
95 instructions.

96

### 97 *MLPA*

98 Confirmation of detected CNVs of patient 1 and 3, and parental analysis of patient 1, was carried  
99 out by using synthetic MLPA-probes specifically designed to cover the region of interest, as  
100 previously described<sup>6-7</sup>. Data analysis was performed with GeneMarker software 1.85  
101 (Softgenetics, USA).

102

### 103 *FISH*

104 Confirmation of microarray data and parental analysis of patient 2, 4 and 6 was performed by  
105 FISH analysis using BAC probes within the deleted region following standard techniques<sup>8</sup>.

106

## 107 **Case Report**

108 Clinical features of all six patients are described in detail below and summarised in Table 1.

109 **Patient 1**

110 This 6-year-old female patient (Figure 1A) was the first child born to non-consanguineous,  
111 healthy parents, both of 31 years of age at time of birth. The family history was not contributory.

#3

112 The patient was delivered by scheduled caesarean section at 38+6 weeks after an uneventful  
113 pregnancy. Apgar scores were 8-7-8. Birth weight was 2940 g (-1.5 SD; 20<sup>th</sup> percentile), length  
114 49 cm (-0.5 SD; 45<sup>th</sup> percentile) and head circumference (HC) 35 cm (+1.4 SD; 75<sup>th</sup> percentile).  
115 She was immediately transferred to the neonatology ward after birth due to hypothermia,  
116 hypoglycemia and respiratory problems. The rest of the neonatal period was without  
117 complications.

118 At the age of nine months, concerns regarding DD and hypotonia were noted. She started  
119 walking at the age of 1.5 years. She spoke her first words when she was 2.5-3 years old. Her  
120 speech has improved, but is still somewhat limited compared to other children of her age. At 6  
121 years of age, she was no longer hypotonic but had problems with spasticity in her calves,  
122 especially on her left calf. Review of systems shows hyperopia, strabismus, episodic constipation  
123 and celiac disease. Hearing is normal. In terms of behavioural phenotype, she is hyperactive, gets  
124 easily frustrated and has aggressive outbursts. She does not show any stereotypic or self-  
125 mutilating behaviour. Investigations include an echocardiogram showing a ductus arteriosus that  
126 did not require treatment. MRI of the brain done at 4 months of age and 2.5 years were normal.  
127 Because of her short stature, a screening for TSH, GH and IGF1 hormone levels was performed,  
128 which were all normal. Clinical examination at 4 and 6 years of age showed the following  
129 dysmorphic features: frontal bossing, short palpebral fissures, deep set eyes, low set eyebrows,  
130 synophrys, flat nose with a bulbous nasal tip, low posterior hairline, low set nipples, and  
131 hirsutism, especially on the legs.

132 **Patient 2**

133 This 5-year-old female patient (Figure 1B) was the second child born to non-consanguineous,  
134 healthy parents. The patient was delivered by caesarean section at full term, Apgar 8-9-9. Birth  
135 weight was 3645 g (+0.6 SD; 60<sup>th</sup> percentile), length 52 cm (+1.3 SD; 80<sup>th</sup> percentile) and HC  
136 37cm (+3SD; 99<sup>th</sup> percentile). The mother was 36 and the father was 45 years old at the time of  
137 birth. During the neonatal period, she had feeding problems and problems with constipation.

138 From an early age, she has had pronounced sleep disturbance with very little sleep apparently  
139 required. She is currently on melatonin and Clonidine, and without medication, she is reported to  
140 not sleep at all for several nights. She has moderate DD including walking and first words at age  
141 2 years, as well as only starting smiling and being socially engaging around the same time. She is  
142 extremely hyperactive but quite clumsy, with a wide based gait and dragging her left leg behind  
143 when walking. She has some autistic traits including a history of repetitive behaviours such as  
144 rocking and narrow interests. She interacts with her parents but does not play well with other  
145 children. She has problems with pronunciation of most words and an unusual voice. She has  
146 astigmatism with decreased vision in her left eye. Hearing was normal when tested at age 2. MRI  
147 of the brain showed a small left frontal intraventricular lesion felt likely to be a cyst and normal  
148 ventricular size. Echocardiogram was normal.

149 Clinical examination at 2.5 and 4 years of age showed the following dysmorphic features: a low  
150 anterior hairline with a prominent supraorbital ridge, downslanting palpebral fissures, synophrys,  
151 short nose with a bulbous nasal tip, prominent premaxilla, short neck, inverted nipples, wide  
152 chest, hirsutism with prominent dark hair over her back, tapered digits with mildly hypoplastic  
153 nails on the fifth finger, and puffy dorsum of hands and feet. On examination at age 4 years, her

154 height was 109 cm (+1.9 SD; 90<sup>th</sup> percentile), weight 20 kg (+1.8 SD; 85<sup>th</sup> percentile) and HC  
155 52cm (+1.7 SD; 80<sup>th</sup> percentile).

### 156 **Patient 3**

157 This female patient (Figure 1C) was the second child born to non-consanguineous, healthy  
158 parents. The mother and father were 24 and 26 years old, respectively, at the time of birth. The  
159 pregnancy was uneventful. Birth was at 38 weeks by a cesarean section because of transverse  
160 position. Birth weight was 2845 g (-1.5 SD; 15<sup>th</sup> percentile). Moderate DD was noted in the first  
161 year. She walked independently at 21 months. She also had speech delay and was diagnosed with  
162 autism spectrum disorder. Hearing is normal. Her vision is impaired because of amblyopia,  
163 astigmatism and moderate myopia. She had surgery for strabismus and an open ductus arteriosus.  
164 CT and MRI of the brain both showed no abnormalities.

#3

165 At the age of 11 years, her height was 142 cm (-1.3 SD; 35<sup>th</sup> percentile), weight was 41.3 kg  
166 (+0.8 SD; 65<sup>th</sup> percentile) and HC was 52.8 cm (-0.4 SD; 40<sup>th</sup> percentile). She was  
167 brachycephalic. She had small ears with a narrow ear canal and a slightly dysplastic helix, a  
168 broad nose with a bulbous nasal tip, abnormal palmar creases, a short fifth metacarpal on both  
169 sides and scoliosis. Her gait was stiff and she had normal tone.

### 170 **Patient 4**

171 This 3-year-old male patient (Figure 1D) was the first child born to non-consanguineous, healthy  
172 parents. At time of birth the mother was 25 years old and the father 27. The patient was delivered  
173 by spontaneous delivery at 40 weeks. Birth weight was 2840 g (-1.5 SD; 15<sup>th</sup> percentile), length  
174 47 cm (-1.5 SD; 15<sup>th</sup> percentile) and HC 34 cm (+0.5 SD; 60<sup>th</sup> percentile). He had aortic stenosis  
175 for which he had a surgery at 4 days of age.

#3

176 He has gross motor delays including walking at 20 months. There is no known speech delay.. He  
177 has hyperactivity requiring medical treatment. Review of systems shows lacrimal duct stenosis,  
178 hyperopia, bilateral inguinal hernia and unilateral cryptorchidism. X-rays showed a  
179 supernumerary rib. Moderate ventriculomegaly was noted on head ultrasound. His physical  
180 findings were noteworthy for a depressed nasal bridge, thick eyebrows, macrocephaly, and small,  
181 thick fingers.

## 182 ***Patient 5***

183 This 4-year-old male patient (Figure 1E) was the second child born to non-consanguineous,  
184 healthy parents. The age of the mother and father at time of birth was 34 and 38 years old, #3  
185 respectively. At 35 weeks of gestation, cerebral ventriculomegaly and ventricular septal defect  
186 (VSD) were detected by fetal ultrasonography. Antenatal karyotype was undertaken and an  
187 interstitial 10p deletion was diagnosed, with normal FISH for DGCR2 locus. The patient was  
188 born at 39 weeks of gestation with normal growth parameters: weight was 3360 g (+0.5 SD; 55<sup>th</sup>  
189 percentile), length 48 (-1 SD; 25<sup>th</sup> percentile) cm and HC 34.5 cm (+0.8 SD; 65<sup>th</sup> percentile).  
190 During the neonatal period, he required one month of oxygen therapy for pulmonary arterial  
191 hypertension. He had multiple VSDs (a perimembranous defect partially obstructed by aneurysm  
192 of the membranous septum and two small trabecular defects), which closed spontaneously within  
193 the first year. He had delayed psychomotor development, including not sitting until 3 years. At  
194 age 4, he was not walking without support and only had two or three single words. He had  
195 episodes of aggressive behaviour. Ophthalmic examination revealed chorioretinal coloboma of  
196 the right eye. Severe bilateral sensorineural and conductive hearing loss was diagnosed at 1 year  
197 of age. Transtympanic drains in the treatment of serous otitis improved the hearing loss. CT scan  
198 of the temporal bone was normal. He also had bilateral cryptorchidism requiring surgery at 20

199 months of age. Brain MRI showed ventriculomegaly, cerebellar hypoplasia and bilateral anterior  
200 optic nerve hypoplasia.

201 On physical examination, he had a normal weight for his age but developed a postnatal growth  
202 retardation (-3 SD) and microcephaly (-4 SD). He had axial hypotonia and peripheral hypertonia.  
203 Facial dysmorphia included bilateral ptosis and epicanthal folds, anteverted nares, short neck,  
204 dysplastic ears, a large mouth with Cupid's bow upper lip, downturned corners and bifid tongue.  
205 Camptodactyly and syndactyly of the toes were noted.

### 206 ***Patient 6***

207 This girl (Figure 1F) is the only child of parents with no medical concerns. She was born at 38.5  
208 weeks of gestation with growth retardation: weight 1920 g (-3 SD; <3<sup>rd</sup> percentile), length 46 cm  
209 (-2 SD; 3<sup>rd</sup> percentile) and HC 32 cm (-1,5 SD; 15<sup>th</sup> percentile). The age of the mother and father  
210 at time of birth was 36 and 39 years old, respectively. Congenital anomalies include right  
211 choanal atresia, stenosis of the left piriform sinus, and pulmonary valve stenosis. She showed  
212 significant difficulty in swallowing. Because of speech delay, a hearing test was performed at 3  
213 years of age and bilateral sensorineural hearing loss was diagnosed. The hearing loss was  
214 progressive and at 14 years of age, she has a profound deafness. She has moderate DD including  
215 walking at age 3. She has attention-deficit hyperactivity disorder treated with Methylphenidate  
216 and occasionally has self-aggressive behavior. A cerebral MRI done at age 7 years due to  
217 seizures showed hypoplasia of the corpus callosum and cerebellar abnormalities. Her menstrual  
218 periods started at the age of 8 years and remain irregular.

219 At the time of clinical examination at the age of 14 years, her weight, height and HC are normal.  
220 She has facial asymmetry, dysplastic ears, enophthalmos, synophrys, arched eyebrows and slight  
221 inferior prognathism. The rest of her clinical examination is unremarkable.

222

## 223 **Results**

224 Molecular results of the six patients are summarised in Figure 2. All deletions were *de novo*. The  
225 position of the array targets are according to NCBI36 (hg18).

226 In patient 1, analysis by SNP array revealed two tandem deletions of 0.51 and 4.0 Mb,  
227 respectively, located at 10p12.1 and 10p12.1p11.23 (26.207.895-26.709.981 and 26.852.317-  
228 30.875.579). The deletion could not be detected by MLPA in her parents.

229 In patient 2, a 2.5 Mb interstitial deletion was detected by an oligonucleotide microarray at  
230 10p12.1p11.23 (26.714.221-29.234.923). Parental investigations by FISH analysis proved the  
231 deletion to be *de novo*.

232 In patient 3, a 1Mb deletion was detected at 10p11.23 (28.833.195-29.823.698) with a SNP  
233 array. The deletion could not be detected by the same method in her parents. FISH analysis of  
234 the mother revealed no structural abnormalities of chromosome 10.

235 In patient 4, microarray analysis revealed a 6.6 Mb deletion (25.266.223-31.857.811) located at  
236 10p12.1p11.22. The deletion could not be detected in the parents by FISH analysis.

237 In patient 5, microarray analysis revealed a 10.7 Mb deletion at 10p12.1p11.21 (27.375.620-  
238 38.031.389). No deletion could be detected in his parents by BAC arrayCGH.

239 In patient 6, a 6.8 Mb interstitial deletion was detected at 10p12.31p11.23 (22.338.042-  
240 29.138.742) by an oligonucleotide microarray. Parental investigations by FISH proved the  
241 deletion to be *de novo*.

## 242 **Discussion**

243 Here we present six new patients with deletions of different sizes encompassing 10p12.31p11.21.  
244 None of the patients share common breakpoints. Non-homologous end joining (NHEJ) or  
245 FoSTeS (fork stalling and template switching) might be likely mechanisms for recurrence of  
246 deletions in this region of chromosome 10 as the breakpoints do not contain any segmental  
247 duplications required for NAHR<sup>1,10</sup>.

248 Comparison of clinical features of our six patients showed that they share some similarities such  
249 as DD (6/6), motor (6/6) and speech delay (5/6), hyperactivity (4/6) and hypotonia (3/6). They  
250 also display dysmorphic features such as: synophrys/thick eyebrows (5/6), short neck (3/6), deep  
251 set eyes (4/6), low set eyebrows (3/6), bulbous nose (4/6) and full cheeks (5/6). All patients also  
252 had different kinds of visual impairments. Our 6 patients share some features with the previously  
253 described patient with a 10p12-p11 deletion<sup>5</sup>. Clinical data for this patient are summarized in  
254 Table 1 (genomic data kindly provided by dr. Nicole de Leeuw chr10: 26.901.972-36.934.901  
255 (hg18)). The similarities between our six patients and the patient reported in the literature  
256 included developmental delay and a majority of the patients have abnormal behaviour and  
257 dysmorphic features including bulbous nasal tip, deep set eyes, synophrys/thick eyebrows, and  
258 full cheeks, while other features varied. In contrast, the previously described patient had unique  
259 changes detected on X-ray. Plain radiography showed pseudoarthrosis of the right clavicle and a

260 significant beaten copper appearance of the cranium without any evidence of sutural synostosis.  
261 None of our patients have had X-rays to assess for these abnormalities.

262 Cardiac abnormalities, mostly conotruncal heart defects, were present in patients 1 and 3-6, as  
263 well as in the previously published patient. All the patients except patient 6 shared a 589 kb  
264 deletion (chr10: 29.823.698-29.234.923 (hg18)). Two protein-coding genes are present in the  
265 region: *LYZL1* and *SVIL*. *SVIL* is suggested to play a role as a high-affinity link between the actin  
266 cytoskeleton and the membrane and appears to be involved in myosin II assembly. In addition,  
267 two noncoding RNAs, mir-604 and mir-938, are located within this commonly deleted region.  
268 Several reports have indicated a role for noncoding RNAs in the molecular pathogenesis of  
269 different developmental disorders<sup>9</sup>. However, the role they might play in the development of the  
270 heart is still unknown.

271 The smallest region of overlap in all seven patients is 306 kb in size and contains only two genes,  
272 *BAMBI* and *WAC* (Figure 2). *BAMBI* encodes a transmembrane glycoprotein related to the type I  
273 receptors of the TGF-beta family, whose members play important roles in signal transduction in  
274 many developmental and pathological processes. The encoded protein, however, is a  
275 pseudoreceptor, lacking an intracellular serine/threonine kinase domain required for signaling,  
276 and was recently shown to be dispensable for mouse embryonic development and postnatal  
277 survival<sup>11</sup>, but may play a role in pain modulation<sup>12</sup>. The protein encoded by *WAC* represents a  
278 subunit of the Augumin complex, which is required for centrosome-independent microtubule  
279 generation within the spindle. *Wac* depletion in cultured *Drosophila* S2 cells has been shown to  
280 cause severe defects in spindle assembly<sup>13-14</sup>. In developing *Drosophila*, *WAC* is required for cell  
281 proliferation, but its homozygous or heterozygous deletions were not found to be lethal. Instead,  
282 in somatic cells, the deletion of *WAC* resulted in delayed mitotic progression with a proper

283 chromosomes segregation in general. The defects of genes coding for proteins responsible for  
284 microtubule function has previously been associated with neurodevelopmental disorders with  
285 dysmorphic features <sup>15</sup>, with *MAPT* representing one recent example. This gene is considered to  
286 be the candidate for the features of the recurrent 17q21 deletion syndrome <sup>16</sup>, which interestingly  
287 shows DD, facial dysmorphisms including a long face, a tubular or pear-shaped nose and a  
288 bulbous nasal tip as well as eye abnormalities among the recurrent features. It is therefore  
289 possible that *WAC* is one of the candidates for the DD, which is the only feature common in all  
290 seven patients. However, functional studies are required to draw any conclusions if *WAC* could  
291 be a candidate gene responsible for the DD.

292 In conclusion, we report six new unrelated patients with a deletion at 10p12p11 that together  
293 with a previously published case share a similar clinical phenotype characterized by DD,  
294 abnormal behavior, visual impairment, cardiac abnormalities and dysmorphic features like deep  
295 set eyes, synophrys/thick eyebrows, full cheeks and a bulbous nasal tip.

296

297 The possible role of *WAC* gene as a candidate gene for DD was raised but further molecular  
298 characterisation of additional patients is needed to further delineate its role in abnormal human  
299 development.

300

## 301 **Acknowledgements**

302 We would like to thank all of the families for agreeing to participate in this study. This work was  
303 supported by grants from the Sävstaholm Society, the Borgström Foundation, Foundation Jerome  
304 Lejeune and the Canadian Institutes of Health Research (ERS). ERS acknowledges the Michael

305 Smith Foundation of Health Research Scholar Award. We are grateful for technical assistance  
306 and scientific discussion to Laure Lecerf, Audrey Briand and Sandra Whalen.

307 **Competing Interests**

308 The authors declare that they have no competing interests

309

## 310 References

- 311 1. Stankiewicz P, Lupski JR: Structural variation in the human genome and its role in disease. *Annu*  
312 *Rev Med* 2010; **61**: 437-455.
- 313 2. Van Buggenhout G, Van Ravenswaaij-Arts C, Mc Maas N *et al*: The del(2)(q32.2q33) deletion  
314 syndrome defined by clinical and molecular characterization of four patients. *Eur J Med Genet*  
315 2005; **48**: 276-289.
- 316 3. Lynch SA, Foulds N, Thuresson AC *et al*: The 12q14 microdeletion syndrome: six new cases  
317 confirming the role of HMGA2 in growth. *Eur J Hum Genet* 2011.
- 318 4. Menten B, Buysse K, Zahir F *et al*: Osteopoikilosis, short stature and mental retardation as key  
319 features of a new microdeletion syndrome on 12q14. *J Med Genet* 2007; **44**: 264-268.
- 320 5. Shahdadpuri R, de Vries B, Pfundt R, de Leeuw N, Reardon W: Pseudoarthrosis of the clavicle  
321 and copper beaten skull associated with chromosome 10p11.21p12.1 microdeletion. *Am J Med*  
322 *Genet A* 2008; **146A**: 233-237.
- 323 6. Stern RF, Roberts RG, Mann K, Yau SC, Berg J, Ogilvie CM: Multiplex ligation-dependent probe  
324 amplification using a completely synthetic probe set. *Biotechniques* 2004; **37**: 399-405.
- 325 7. Thuresson AC, Bondeson ML, Edeby C *et al*: Whole-genome array-CGH for detection of  
326 submicroscopic chromosomal imbalances in children with mental retardation. *Cytogenet*  
327 *Genome Res* 2007; **118**: 1-7.
- 328 8. Dauwerse JG, Jumelet EA, Wessels JW *et al*: Extensive cross-homology between the long and the  
329 short arm of chromosome 16 may explain leukemic inversions and translocations. *Blood* 1992;  
330 **79**: 1299-1304.
- 331 9. Szulwach KE, Jin P, Alisch RS: Noncoding RNAs in mental retardation. *Clin Genet* 2009; **75**: 209-  
332 219.
- 333 10. Zhang F, Gu W, Hurler ME, Lupski JR: Copy number variation in human health, disease, and  
334 evolution. *Annu Rev Genomics Hum Genet* 2009; **10**: 451-481.

- 335 11. Chen J, Bush JO, Ovitt CE, Lan Y, Jiang R: The TGF-beta pseudoreceptor gene Bambi is  
336 dispensable for mouse embryonic development and postnatal survival. *Genesis* 2007; **45**: 482-  
337 486.
- 338 12. Tramullas M, Lantero A, Diaz A *et al*: BAMBI (bone morphogenetic protein and activin  
339 membrane-bound inhibitor) reveals the involvement of the transforming growth factor-beta  
340 family in pain modulation. *J Neurosci* 2010; **30**: 1502-1511.
- 341 13. Goshima G, Mayer M, Zhang N, Stuurman N, Vale RD: Augmin: a protein complex required for  
342 centrosome-independent microtubule generation within the spindle. *J Cell Biol* 2008; **181**: 421-  
343 429.
- 344 14. Meireles AM, Fisher KH, Colombie N, Wakefield JG, Ohkura H: Wac: a new Augmin subunit  
345 required for chromosome alignment but not for acentrosomal microtubule assembly in female  
346 meiosis. *J Cell Biol* 2009; **184**: 777-784.
- 347 15. Jaglin XH, Chelly J: Tubulin-related cortical dysgeneses: microtubule dysfunction underlying  
348 neuronal migration defects. *Trends Genet* 2009; **25**: 555-566.
- 349 16. Koolen DA, Vissers LE, Pfundt R *et al*: A new chromosome 17q21.31 microdeletion syndrome  
350 associated with a common inversion polymorphism. *Nat Genet* 2006; **38**: 999-1001.

351

352

353 **Titles and legends to figures**

354 **Figure 1.** (A) Patient 1 at age 4 (B) Patient 2 at age 2 years, 5 months. (C) Patient 3 at 11 years  
355 of age. (D) Patient 4 at 3 years, 9 months. (E) Patient 5 at 3 years, 9 months. (F) Patient 6 at 14  
356 years of age.

357 **Figure 2.** Schematic illustration of chromosome 10 displaying the deletions at 10p12p11 in  
358 patients 1-6 and patient by Shadadpuri et. al. <sup>5</sup> detected by microarray using the Ensembl  
359 browser. Deleted regions for the respective cases are shown as black bars. Smallest region of  
360 overlap (SRO) is indicated by vertical dotted lines. Positions are according to NCBI36 (hg18).

361

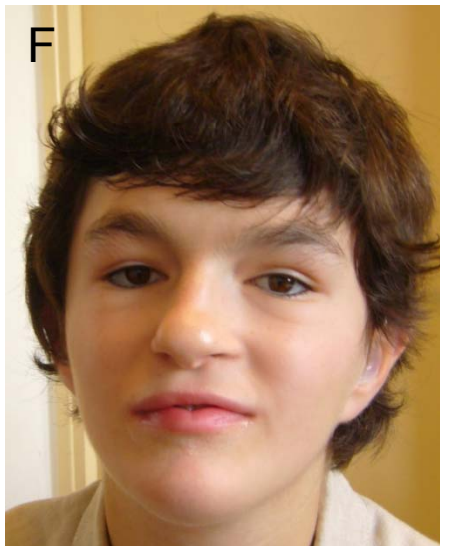
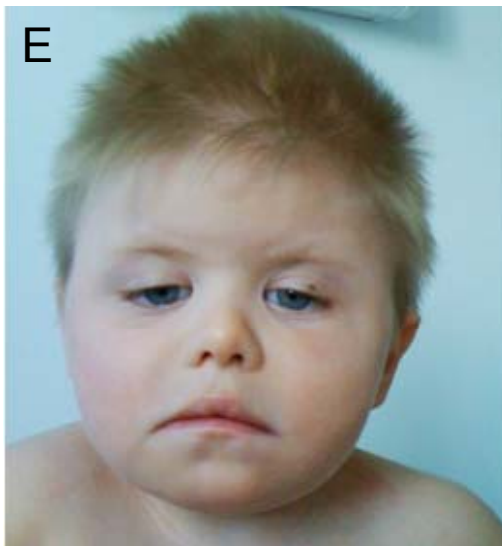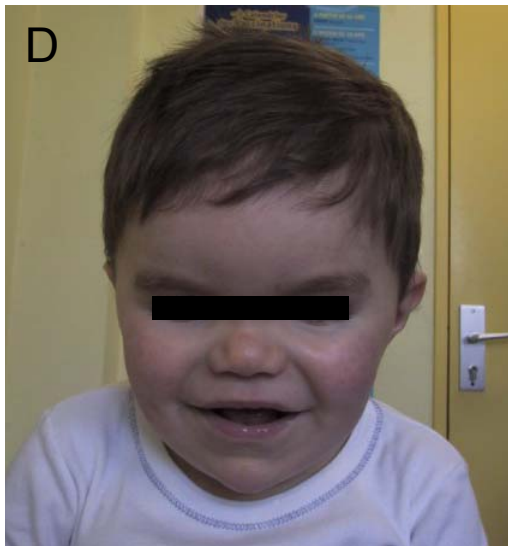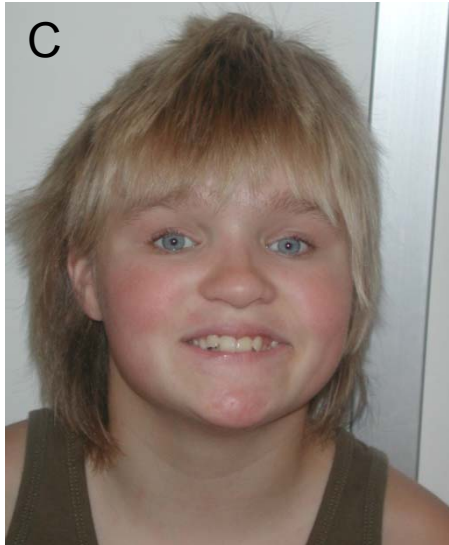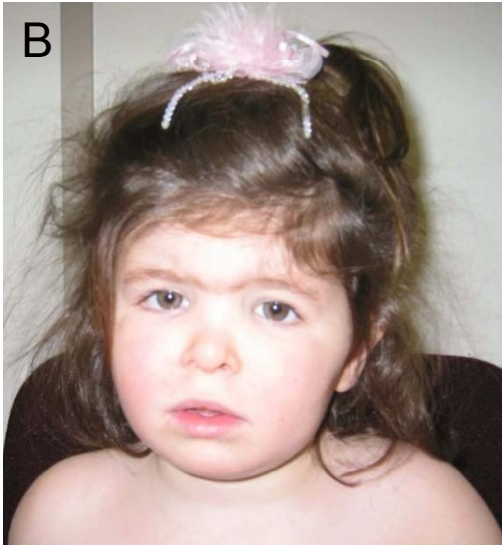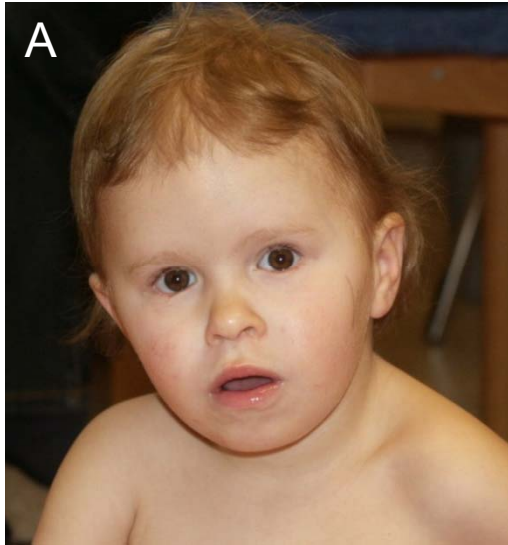


Figure 1

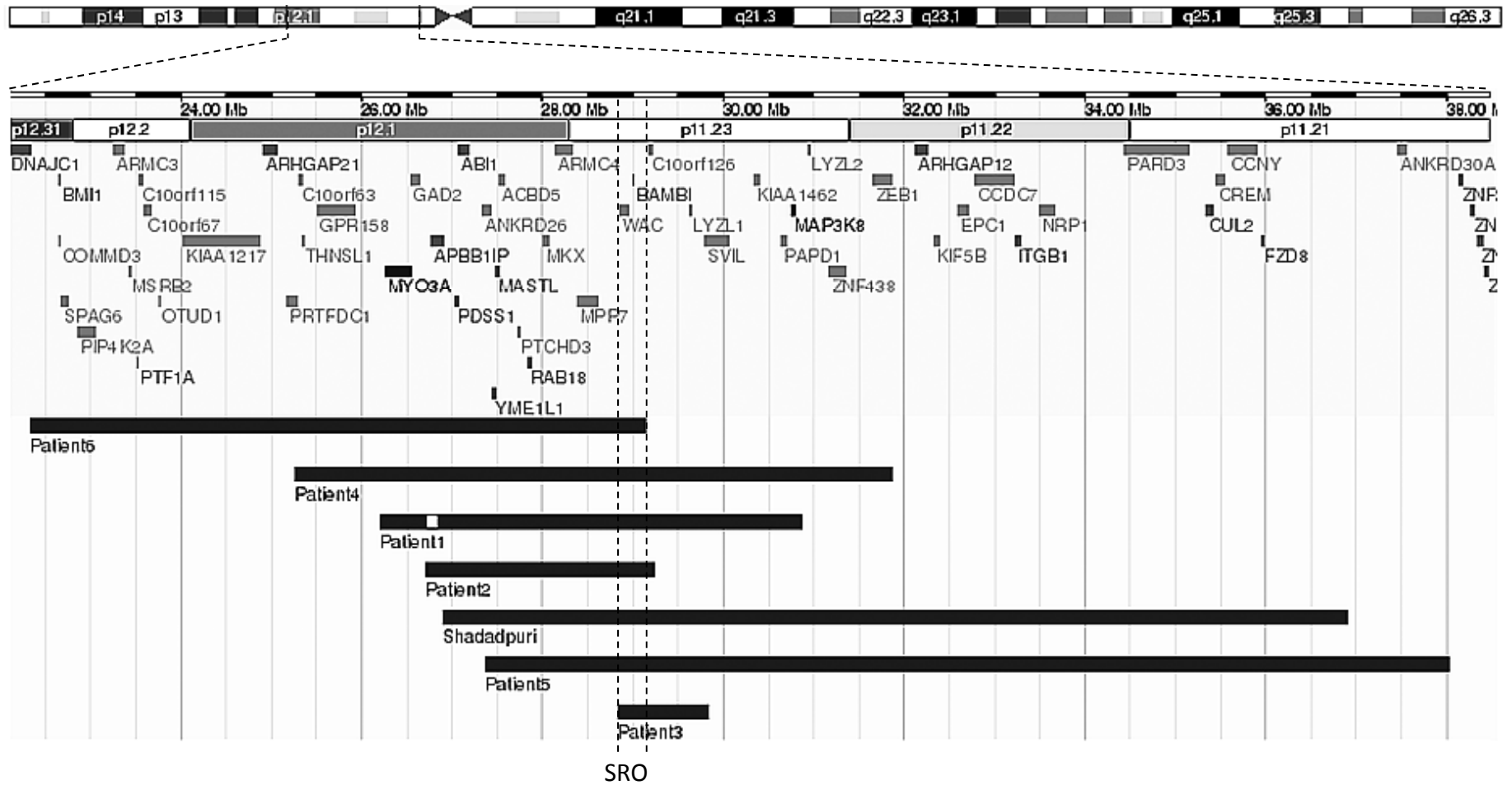


Figure 2

<b>Table 1</b> Summary of clinical features of present and previously reported cases with a deletion at 10p12.1p11.23			
	<b>Patient 1</b>	<b>Patient 2</b>	<b>Patient 3</b>
Gender	F	F	F
Molecular karyotype	arr 10p12.1p11.23 (26.207.895-26.709.981)x1 dn ; 10p12.1 (26.852.317-30.875.579)x1 dn	arr 10p12.1p11.23 (26.714.221-29.234.923)x1 dn	arr 10p12.1p11.23 (28.833.195-29.823.698)x1 dn
Size of deletion (Mb)	0.5 and 4.0	2.5	1
Gestation (weeks)	38+6	40	38
Weight (g)	2940	3645	2845
Length (cm)	44	52	NI
Head circumference (cm)	35	37.5	33
Growth Parameters/age	4 years	4 years	11 years
Length	-2 SD	+1.9 SD	-1.3 SD
Weight	-1.5 SD	+1.8 SD	+1.3 SD
Head circumference	-1.5 SD	+1.7 SD	-0.4 SD
Developmental delay	+	+	+
Feeding problems	celiaki	neonatal period	-
Abnormal behaviour	hyperactive	hyperactive + autistic traits	autistic
Motor delay	+	+	+
Speech delay	+	+	+
Hypotonia	+	+	-
Seizures	+	-	-
Brain anomalies	-	small intraventricular lesion	-
Cardiac abnormalities	ductus arteriosus	-	patent ductus arteriosus
Hearing impairment	-	-	-

Visual impairment	hyperopia, strabism	astigmatism, visual impairment of left eye	myopia, astigmatism, amblyopia, strabismus
Constipation	+	+	-
Sleep disturbance	nocturnal screaminess	+	-
Deep -set eyes	+	+	-
Palpebral fissures	short	downslanting	-
Synophrys	+	+	thick eyebrows
Low set eyebrows	+	+	-
Nose	bulbous nasal tip, flat nose	bulbous nasal tip, short nose	bulbous nasal tip
Upper lip without a cupid bow	+	+	-
Full cheeks	+	+	+
Ears	-	-	small and slightly dysplastic hel
Short neck	+	+	-
Anomalies of hands/feet	-	tapered digits, mildly hypoplastic nails 5th finger,	abnormal palmar creases (not simean)
Hirsutism	+	+	-
Pseudoarthrosis of the clavicle	X-ray never taken	X-ray never taken	X-rays never taken
Copper beaten skull	X-ray never taken	X-ray never taken	X-rays never taken
Other			
+=feature present, -=feature absent, F=female, M=male, NI=no information, VSD=ventricular septal defects			

<b>Patient 4</b>	<b>Patient 5</b>	<b>Patient 6</b>	<b>Shahdadpuri et al <sup>5</sup></b>	<b>Total</b>
M	M	F	M	4F/3M
arr 10p12.1p11.22 (25.266.223-31.857.811)x1 dn	arr 10p12.1p11.21 (27.375.620-38.031.389)x1 dn	arr 10p12.31p11.23 (22.338.042-29.138.742)x1 dn	arr 10p12.1p11.21 (26.901.972-36.934.901)x1 dn	
6.6	10.7	6.8	10.0	
40	39	38.5		
2840	3360	1920		
47	48	46		
34	34.5	32		
6 years	3.5 years	15 years		
-2 SD	-3 SD	- 2 SD	25th-50th centile	
-1 SD	0 SD	-1 SD (15 years)		
+2 SD	-3 SD	-1.5 SD		
+	+	+	+	7/7
-	-	neonatal period		
hyperactive	agressive	hyperactive, aggressive		6/6
+	+	+		6/6
-	+	+		5/6
-	+	-		3/6
-	-	+		2/6
ventriculomegaly; plexus choroideus cysts	hypoplasia of corpus callosum, cerebellar hypoplasia, mild dilatation of the ventricles	hypoplasia of corpus callosum, cerebellum anomaly	thin corpus callosum, mild dilatation of the lateral ventricles, mild white matter signal abnormality	5/7
coarctation aorta, VSD	interventricular communications	pulmonary valve stenosis	VSD, ventricular hypertrophy, bicuspid aortic valve	6/7
-	mixed deafness	senorineural hearing loss	sensorineural hearing loss	3/7

hyperopia	hypoplasia of bilateral anterior segment optical, chorioretinal coloboma	strabismus	myopia, astigmatism	7/7
-	-	-		2/6
+	-	-		3/6
+	-	+	+	5/7
-	downslanting	short		
thick eyebrows	-	+		5/6
-	+	-		3/6
bulbous nasal tip, depressed nasal bridge. small, broad	small, pinched nostril	choanal and pyriform sinus atresia	bulbous nasal tip	5/7
+	-	-		3/6
+	+	-		5/6
-	slightly dysplastic helix	dysplastic ears	overfolded crupled ear helix	4/7
-	+	-		3/6
small and thick fingers	camptodactyly of toes, bilateral syndactyly of 2-3 toes	-	abnormal palmar creases	5/7
-	-	-		2/6
X-rays never taken	X-rays never taken	X-rays never taken	+	
X-rays never taken	X-rays never taken	X-rays never taken	+	
lacrimial duct stenosis, bilateral inguinal hernia, unilateral cryptorchidism	cryptorchidy, down-turned angles of the mouth, bifid tongue	early puberty, hormonal dysregulation, facial assymetry		