



HAL
open science

The development of the oviducal gland in the Rajid thornback ray,

Bárbara Serra-Pereira, Fernando Afonso, Inês Farias, Pedro Joyce, Megan Ellis (nee Storrie), Ivone Figueiredo, Leonel Serrano Gordo

► **To cite this version:**

Bárbara Serra-Pereira, Fernando Afonso, Inês Farias, Pedro Joyce, Megan Ellis (nee Storrie), et al.. The development of the oviducal gland in the Rajid thornback ray,. *Helgoland Marine Research*, 2010, 65 (3), pp.399-411. 10.1007/s10152-010-0232-1 . hal-00634810

HAL Id: hal-00634810

<https://hal.science/hal-00634810>

Submitted on 24 Oct 2011

HAL is a multi-disciplinary open access archive for the deposit and dissemination of scientific research documents, whether they are published or not. The documents may come from teaching and research institutions in France or abroad, or from public or private research centers.

L'archive ouverte pluridisciplinaire **HAL**, est destinée au dépôt et à la diffusion de documents scientifiques de niveau recherche, publiés ou non, émanant des établissements d'enseignement et de recherche français ou étrangers, des laboratoires publics ou privés.

1 **The development of the oviducal gland in the Rajid thornback ray, *Raja clavata***

2 Bárbara Serra-Pereira*^{1,2}, Fernando Afonso³, Inês Farias¹, Pedro Joyce^{1,2}, Megan Ellis (nee Storrie)⁴,

3 Ivone Figueiredo¹ and Leonel Serrano Gordo²

4

5 ¹Unidade de Recursos Marinhos e Sustentabilidade, Instituto de Investigação das Pescas e do Mar
6 (IPIMAR - INRB), Av. Brasília, 1449-006 Lisboa, Portugal

7 ² Faculdade de Ciências de Lisboa, Centro de Oceanografia & Departamento de Biologia Animal, Bloco
8 C2, Campo Grande, 1749-016 Lisboa, Portugal.

9 ³ Faculdade de Medicina Veterinária da Universidade Técnica de Lisboa, Departamento de Sanidade
10 Animal, Av. da Universidade Técnica, Polo Universitário do Alto da Ajuda, 1300-477 Lisboa, Portugal.

11 ⁴ Industry and Investment NSW, Port Stephens Fisheries Institute, Taylors Beach, 2316, Australia

12

13 *corresponding author: tel: +351 213027108, fax: +351 213015948, e-mail: bpereira@ipimar.pt

14

1 **Abstract**

2 The reproductive processes of chondrichthyans are complex. Knowledge of the development and
3 maturation of the oviducal gland is vital for understanding the reproductive biology of a species. This
4 study represents the first contribution of this subject for skates. In the oviparous thornback ray, *Raja*
5 *clavata*, oviducal gland development begins early in the developing stage with the formation of gland
6 tubules and the distinct lamellae of each zone: club, papillary, baffle and terminal. Oviducal development
7 is complete by the end of the developing stage when the storage and secretion of products is evident
8 within the gland tubules of each zone. Periodic acid-Schiff and alcian blue histological staining showed
9 that the secretory mucous cells of the club and papillary zones produce neutral and sulfated acid mucins.
10 The last row of gland tubules of the papillary zone stains intensely for sulfated acid mucins. The baffle
11 zone, which is responsible for the production of the egg capsule, represented 60 to 80% of the glandular
12 zone of the oviducal gland. Sperm bundles were observed in the deeper recesses of the baffle zone during
13 the maturation process, and during capsule extrusion, sperm were detected near the lumen. The terminal
14 zone was composed of two types of gland tubules: serous (producing protein fibres) and mucous glands
15 (producing sulfated acid mucins).

16

17 **Keywords:** maturation; oviparous; Portugal; Rajidae; reproduction.

18

1 **Introduction**

2 The class of chondrichthyan fish includes two subclasses, the elasmobranchs (sharks, skates and rays) and
3 the holocephalans (chimaeras). In this class, there is a great diversity of reproductive strategies including,
4 oviparity and several types of viviparity, but all share internal fertilization (Musick and Ellis 2005).
5 Skates are oviparous and release to the sea fertilized eggs enclosed in a hard egg covering, a capsule
6 (Musick and Ellis 2005). Embryonic development takes place inside the capsule, which has been released
7 to the sea, with expense of yolk reserves. Depending on the species, the estimated incubation time lasts
8 from 4.5 to 14 months, and for thornback ray, *Raja clavata*, it is approximately 5 months (Clark 1922).

9 Capsule formation is a process that involves an important organ of the female reproductive tract, the
10 oviducal gland (OG), which skates share with most chondrichthyans. The OG is derived from the oviduct
11 and anterior to the uterus. The important physiological functions that the OG is responsible for are: 1) the
12 production of egg investments; 2) the formation of the tertiary egg coverings, including the hard egg
13 capsule of oviparous species; 3) the transport of fertilized eggs; and 4) sperm storage in some species
14 (Hamlett et al. 1998). Each of these functions is, in general, attributed to one of the four zones of the OG.

15 The OG of most chondrichthyans shares the same internal organization. The oviparous small-spotted
16 catshark, *Scyliorhinus canicula*, was the first to be studied (e.g. Threadgold 1957; Rusaouën 1976; Knight
17 et al. 1993) and most of the knowledge on the morphology and functionality of the OG was recorded from
18 this species. In general, the OG is made from numerous simple gland tubules. In the tubules, secretory
19 cells produce and secrete the materials of each zone and these are transported through the tubules and are
20 extruded into the lumen via secretory ducts between epithelial projections, lamellae, lining the gland
21 lumen. The terminology for the zonation of the OG adopted in this work follows the one proposed by
22 Hamlett et al. (1998). According to these authors, there are four distinct zones, named according to the
23 shape of lamellae or position in the OG, and from anterior to posterior are the club, papillary, baffle and
24 terminal zone. The club zone is characterized by club-shaped lamellae, whereas the papillary zone has
25 elongate digit-shaped lamellae. The baffle zone refers to the baffle plates of the spinneret region that are
26 confluent with the secretory ducts. These plates assist with the extrusion of the capsule material into the
27 transverse grooves that alternate with flattened plateau projections, the lamellae. The terminal zone is the
28 most posterior zone of the gland. Terminal refers to its end position and it is characterized by not having

1 transverse grooves. The gland tubules are short and simple and are composed of mucous, serous or a
2 mixture of the two types of cells (Hamlett et al. 1998, 2005).

3 The first step in the formation of the egg covering is the enclosure of the fertilized egg inside an egg jelly
4 layer secreted by the club and papillary zones (Hamlett et al. 1998; Rusaouën 1976). In skates, the egg
5 jelly leaves the capsule after approximately one third of its development through the slits laterally located
6 at each horn or tendril of the egg capsule, opening the capsule to embryo-assisted flow of sea water (Long
7 and Koob 1997). The egg jelly serves as a structural device to hydrodynamically support the egg and the
8 developing embryo, and not as a substantial source of carbohydrate nutrition for early development (Koob
9 and Straus 1998). In addition, it is believed that the egg jelly produced by the papillary zone functions as
10 a bonding layer and as a lubricant during encapsulation, reducing the friction between the jelly and the
11 forthcoming capsule (Hamlett et al. 1998, 2005).

12 The baffle zone produces and secretes a complex material, a network of fibres that forms the tertiary egg
13 covering. First, the proteins and enzymes enclosed in the tertiary egg covering formation are continuously
14 produced and stored in a prepolymerized condition as storage granules which are involved by a
15 membrane. These granules are located within the secretory cells of the gland tubules. At the final stage of
16 the granules development, the membranes of the storage granules coalesce with the membrane of the
17 secretory cell (at the apical surface). The granule contents are then released to the lumen of gland tubules,
18 through a merocrine secretion process. Inside the lumen, the polymerization process, triggered by an ionic
19 change of the environment, transforms the secreted material into coalescent strands (fibrillogenesis). The
20 material is transported to the spinneret, by ciliary action and secreted around the egg jelly surface as
21 parallel oriented fibrils closely packed together. During the stabilization process fibrils experience a
22 progressive decrease in thickness with water loss, and consequent increase in resistance, improving
23 embryo's protection (Knight et al. 1993; Hamlett et al. 1998). The secreted material consists of a sulphur-
24 containing protein called prokeratine, which is chemically close to keratin (Rusaouën 1976). In some
25 species of sharks the egg covering also contains collagen (Krishnan 1959). While in the uterus, the egg
26 covering undergoes a sclerotization by quinone tanning, due to the presence of a phenolic protein
27 (catechol) in the uterus, and an oxidation of the catechol to quinone by the enzymes, tyrosine hydroxylase
28 and catechol oxidase (Koob and Cox 1990, 1993; Threadgold 1957). Egg capsule morphology of
29 oviparous chondrichthyans is species specific and offers an effective protection to the fertilized

1 egg/embryo due to extreme toughness and strength, flexibility, moderate extensibility and high
2 permeability to low molecular weight substances and ions (Knight et al. 1994a, b, 1996).

3
4 The terminal zone, the last zone of the OG, is responsible for the formation of surface hairs coated with
5 mucous secretions that cover the exterior of the capsule in some oviparous species, like the holocephalan,
6 *Callorhynchus milli* (Smith et al. 2004) and the little skate, *Raja erinacea* (Hamlett et al. 1998). When the
7 oviparous egg capsule is extruded to the environment, it becomes covered with materials such as sand and
8 other sea debris, due to the presence of the sticky hairs that serve as anchors and assist to camouflage the
9 egg capsule (Hamlett et al. 2005). The terminal zone is also the site of sperm storage in some
10 chondrichthyans (e.g. Fishelson and Baranes 1998; Hamlett et al. 1998; Smith et al. 2004; Hamlett et al.
11 2005; Storrie et al. 2008).

12
13 No previous studies have described the structural development of the skate OG and only two researchers
14 have investigated the development and maturation of the chondrichthyan OG (Storrie 2004, Nalini 1940).
15 The main aim of the current study was to describe the processes underlying OG development in an
16 oviparous Rajid, from the beginning of differentiation to the extrusion of the egg capsules. The nature of
17 the secretions produced by the different gland zones at the different maturity stages was identified
18 through histological staining techniques. The *R. clavata* is the most abundant Rajid species in the NE
19 Atlantic (Walker and Hislop 1998), however limited information is available about the reproductive
20 biology of this species (e.g. Holden 1975; Walker 1999). Consequently, *R. clavata* was selected as a study
21 species to better understand the process of OG development in Rajids.

22 23 **Material and Methods**

24 **Sampling**

25 The thornback ray, *Raja clavata*, has been routinely sampled since 2004 by the Portuguese Fisheries
26 Institute (IPIMAR), under the scope of the National Data Collection Program (PNAB, DCR). From
27 February 2004 to June 2008 female *R. clavata* were collected from: (1) IPIMAR bottom-trawl research
28 surveys carried out along the Portuguese continental shelf, and (2) landings of commercial artisanal fleets

1 operating with trammel nets, gillnets and longline, along northern (Matosinhos) and central (Peniche)
2 Portugal.

3 For each specimen the total length (TL) and disc width (DW) were measured (mm). The total weight
4 (TW) (g) was recorded. The specimen was sexed and a maturity stage was assigned by applying the
5 maturity scale proposed by Stehmann (2002) for oviparous elasmobranchs, and adapting the universal
6 reproductive terminology proposed by Brown-Peterson et al. (2007) (Table 1). The oviducal glands (OG)
7 of each specimen were removed, measured in mm (width, height and thickness; Fig. 1a), weighed (0.01 g)
8 and preserved in 10% buffered formaldehyde. The relationship of maturity and morphometric
9 characteristics of the OG was analysed using ANOVA and Tukey's HSD (Honestly Significant
10 Difference) tests.

11

12 Histological procedures

13 The modifications in the histological structure of the OG and the presence and nature of the secretions
14 produced during the development process were analysed using a selection of one OG per specimen,
15 covering all the maturity stages. Sagittal sections of about 3 mm thick were removed from the middle of
16 the OGs (Fig. 1b). The samples were processed using an automated tissue processing machine (Leica
17 TP1020, Germany). The protocol consisted of: 1) dehydration through a series of alcohols from 70% to
18 absolute ethanol; 2) clearing with xylene; and 3) impregnation and embedding in paraffin wax.
19 Embedding of the samples in paraffin wax blocks was made using the heated paraffin embedding system
20 (Leica EG 1140H, Germany). The paraffin blocks were then sliced, in sagittal sections, at 3-5 μm of
21 thickness, using a sliding microtome (Leica SM 2000 R, Germany) and a rotary microtome (Leica
22 RM2125RT, Germany). Different staining techniques were tested to analyse the histological structure of
23 the OG: 1) Hematoxylin and Eosin (H&E), staining the nucleus black and the cytoplasm pink; and 2)
24 Toluidine blue (TB) a metachromatic dye with a blue nuclear counterstain. Additional staining procedures
25 were used to investigate the chemical nature of the secretions produced by the different glandular zones:
26 1) periodic acid-Schiff (PAS), with and without diastase, used to detect neutral mucins (PAS+ structures
27 stained pink); 2) combined alcian blue and PAS to detect sulfated acid and neutral mucins (PAS/AB)
28 (PAS+ structures stained pink, AB+ stained blue and PAS+AB+ stained in different intensities of purple);
29 3) Van Gieson stain (VG) to detect collagen, stained in red. Histological staining protocols used by

1 Bancroft and Gamble (2002) were followed, with some adaptations to improve the results. These
2 included: a) in PAS and PAS/AB staining techniques, sections were covered with Schiff's solution, for
3 about 8-10 minutes, instead of 15 minutes, since longer times caused background staining; b) in PAS/AB
4 staining, after staining with AB, sections were covered with 1% Periodic acid, for 3 minutes, instead of 5
5 minutes, with the same results; and c) in VG staining, sections were covered in Van Gieson solution for 5
6 minutes instead of 3 minutes, for more intense staining .

7

8 The histological slides were observed using a stereo microscope (Olympus SZX9, USA) and an optic
9 microscope (Carl Zeiss Axioplan 2 imaging, Germany). The former was used to observe the whole
10 sagittal section of the gland and the latter was used to analyse the *in-situ* gland structure in more detail.
11 Images were obtained using a Sony DFW-SX910 camera and the imaging software TNPC 4.1 used with
12 the stereo microscope and a Zeiss AxioCam MRC camera and the imaging software AxioVision 4.1
13 used with the optic microscope.

14 AxioVision 4.1 was used to collect detailed measurements of the OGs in different maturity stages in order
15 to evaluate the gland structures growth with maturity. The thickness of the smooth muscular tissue layer
16 surrounding the OG was measured. The gland tubules growth was evaluated using gland tubules diameter
17 and wall thickness (from the lumen to the periphery) measurements. TNPC 4.1 was also used to measure
18 several aspects of the OG, in order to evaluate the growth and the final area occupied by each zone of the
19 OG. For that purpose, the surface length or distance along the surface of the OG lumen lined with
20 lamellae, and the area occupied by the gland tubules, in each zone, were measured.

21

22 **Results**

23 A total of 142 female *Raja clavata* were used for studying the development of the OG. The reduced
24 number of females with developed oviducal gland (OG) specimens was due to an overrepresentation of
25 immature females in landings. The female reproductive tract in the spawning stage of maturity is
26 represented in Figure 1a. At this stage, it was possible to observe the two ovaries filled with large yolked
27 follicles. The OGs, located between the oviduct and the uterus, were completely formed (40 mm width) at
28 this stage (Fig.1b). They were composed of two identical bean-shaped halves surrounding a flattened
29 lumen. The succession of the different zones from the oviduct to the anterior uterus was observed both in

1 sagittal section (Fig. 1c) and in the frontal view, with the two halves of the OG separated (Fig. 1d). Inside
2 the uterus, two egg capsules were in development, still flexible and without surface fibres. A fully formed
3 capsule of *R. clavata* is shown in Figure 1e. The capsule was rectangular in shape, dark brown in
4 coloration with two short horns on each distal extremity and the dorsal and ventral surfaces were covered
5 by a high density of fibres. In most examples these features made the egg capsule opaque.

6

7 Macroscopic development

8 The size of the OG increased with maturity (Fig. 2a-c). In the immature stage the OG was not
9 differentiated, so no measurements were collected. All the morphometric characteristics (width, height
10 and thickness) were demonstrated to be statistically different between maturity stages (Table 2). No
11 statistical differences were observed within the spawning stage, if the three stages from Stehmann's
12 (2002) maturity scale were considered (Table 2). During the developing stage the gland was visible and
13 the values of the three measurements were the lowest of all maturity stages. Macroscopic development of
14 the OG was completed during the spawning stage, when the median values for width, height and wall
15 thickness were the greatest. Some overlap of OG measurement across stages occurred because females of
16 the same TL showed great variation in OG size (Fig. 2d).

17

18 Microscopic structure

19 A total of 70 OGs from females at different stages of maturity were selected for histological examination.
20 Figure 3 presents the general appearance of OG during development: a) immature (Fig. 3a); b) early
21 developing (Fig. 3b); c) mid developing (Fig. 3c); and d) spawning capable (Fig. 3d).

22

23

24 In an *immature stage*, there was no visible differentiation of the OG from the rest of the reproductive tract
25 (Fig. 3a). The region of the reproductive tract representing the OG contained some lamellae and the
26 lumen was lined by simple columnar epithelium cells.

27 During the early part of the developing stage, *early developing stage*, the OG was visible as an expansion
28 of the reproductive tract between the oviduct and uterus. Uniform lamellae were observed along the entire
29 section of the OG (Fig. 3b). At this stage, the simple and unbranched gland tubules have started to

1 differentiate and this differentiation began from the lumen and extended to the periphery of the gland
2 (Fig. 3c). The gland tubules were supported by loose connective tissue which was reduced as the gland
3 tubules proliferated throughout the OG. In the developing stage, it was possible to distinguish serous and
4 mucous glands prior to the differentiation of the distinct lamellae of each zone. In cross section, the gland
5 tubules had an average diameter of $57.27 \pm 11.55 \mu\text{m}$ and an average wall thickness of $20.54 \pm 4.89 \mu\text{m}$
6 ($n=48$). Near the gland tubules in the centre of the OG, where the baffle zone will be originated, some
7 homogeneous brown material accumulations were sometimes visible (Figs. 4a and 4b). None of the
8 staining techniques used in this study produced a positive result to identify the brown material. At this
9 stage, the smooth muscular tissue layer surrounding the OG was thin and with a small number of
10 muscular fibres ($496.42 \pm 39.61 \mu\text{m}$). Staining with VG produced negative results, indicating that the OG
11 did not contain collagen.

12 In the *late developing stage*, the OG was fully differentiated into four zones (Fig. 3d): club, papillary,
13 baffle, and terminal. The zones were identified according to the shape of the lamellae lining the lumen
14 (first column in Fig. 5) and by the distinct secretory tubules (general appearance in the second column in
15 Fig. 5 with cellular detail in the third column in Fig. 5). The gland tubules have become large (average
16 diameter $74.89 \pm 7.11 \mu\text{m}$, $n=50$) and their walls thick (average wall thickness $23.39 \pm 4.58 \mu\text{m}$, $n=50$). The
17 club zone had club shaped lamellae (Fig. 5a). The surface epithelium of the lamellae, similar in the four
18 zones, was composed of ciliated cells and secretory cells. Similarly, the gland tubules (Fig. 5b) also
19 contained two types of cells: a) sustentacular ciliated cells with elongated apical nuclei; and b) secretory
20 cells with, large, globular, basal nuclei (Fig. 5c). The papillary zone had digit shaped lamellae (Fig. 5d).
21 Most of the gland tubules were very similar to the ones in the club zone, with the exception of the caudal-
22 most papillary tubules, adjacent to the baffle zone, that were more vacuolated (Fig. 5e). As in the club
23 zone, the epithelium of the tubules contained ciliated cells and secretory cells (Fig. 5f). The baffle zone
24 had two types of epithelial projections: a pair of small folds in the spinneret region, the baffle plates,
25 surrounded by a pair of large folds, the plateau projections (Fig. 5g). A blood vessel was observed within
26 each plateau projection. For the baffle zone, the number of transverse grooves ranged from 25 to 30, in
27 each half of the lumen ($n=17$). The epithelium of the gland tubules was composed of secretory cells and
28 ciliated cells (Figs. 5h and 5i). The cytoplasm of the secretory cells was packed with numerous secretory
29 granules (Fig. 5i). The terminal zone (Fig. 5j) consisted of elongated gland tubules and a regular surface

1 epithelium with unequal spacing of the secretory duct openings, without lamellae. Two types of gland
2 tubules were identified, those composed of serous secretory cells (similar to those in the baffle zone) and
3 those composed of mucous secretory cells (frothy, vacuolated cells) (Fig. 5k). Both types of gland tubules
4 had an epithelium lining the lumen, composed of ciliated cells and secretory cells (Fig. 5l).

5 In the *spawning capable stage*, the secretory tubules had thicker walls (average wall thickness
6 $24.31 \pm 14.02 \mu\text{m}$, $n=60$) as a consequent of more secretions stored inside their cells. The granules of the
7 secretory cells of the club zone stained PAS+ and AB+ (Figs. 6a and 6b). The secretory tubules of the
8 papillary zone produced three distinct types of mucins as identified by their differential staining (Fig. 6c):
9 a) the majority of the tubules were PAS+ and AB+ (Fig. 6d); b) the region near the lumen was intensely
10 PAS+ (Fig. 6e), or PAS+ and AB+; and c) the most-caudal row of secretory tubules near the baffle zone
11 were AB+ (Fig. 6f). The cells of the baffle zone did not react to any of the special staining techniques
12 tested in the present work (Fig. 6g). In some spawning capable females, the secretory tubules deep in the
13 baffle zone (near the muscle tissue) contained almost no secretory materials. In the terminal zone, mucous
14 glands were AB+ and serous glands were PAS- and AB- (Figs. 6h and 6i). Secretions were also detected
15 in the lumen of the gland tubules in: a) the papillary zone (Fig. 7a); b) the baffle zone, both in the gland
16 tubules (Fig. 7b) and secretory ducts (Fig. 7c); and c) the terminal zone (Fig. 7d).

17 At *spawning stage*, the gland tubules attained the largest average sizes in diameter $94.03 \pm 14.02 \mu\text{m}$ and
18 wall thickness $43.43 \pm 8.85 \mu\text{m}$ ($n=30$). The secretory tubule lumens, closest to the lumen of the whole
19 OG, were filled with secretions in all four zones. In spawning females, brown material accumulations
20 were also observed, in the baffle and terminal zones (Figs. 4c and 4d).

21

22 Presence of sperm

23 Sperm were observed inside the OG of 13 females, from the developing to the spawning stage. Sperm
24 were observed as laterally aligned bundles in the deep recesses of the baffle zone tubules, adjacent to the
25 muscle layer, mainly located in the anterior portion of the baffle zone (Figs. 8a and 8b). These tubules
26 containing sperm were composed of both secretory and sustentacular ciliated cells. In the spawning stage,
27 non-aggregated individual sperm were also observed inside the gland tubules near the spinneret in the
28 baffle zone (Figs. 8c and 8d).

29

1 Histological measurements

2 The surface length and glandular area of each zone of the OG increased in size with maturity (Fig.9). The
3 maximum surface length occurred earlier than the associated glandular area, which was attained only in
4 the spawning stage. The surface length of the club and papillary zones each represented about 12% of the
5 total surface length of all lamellae (Fig. 9a). The maximum surface length of the baffle zone was found in
6 the developing stage, and represented about 35% of the total surface length. Similarly, the terminal zone
7 average 37% of the total surface length. When analysing the glandular growth of the different maturity
8 stages (Fig. 9b), the baffle zone was most often the largest, occupying 60 to 80% of the total glandular
9 area. The club and papillary zones together represented 10 to 20%. They were analysed together, because
10 of the difficulty in distinguishing the limits between them. The terminal zone was the only glandular zone
11 that decreased in relative size with maturation, from 12-17% in the developing stage to 5-7% in the
12 extruding stage.

13

14

15 Discussion

16 The main morphology and functionality features of the oviducal gland (OG) are virtually identical
17 between all chondrichthyans. Only numbfishes, a family (Narcinidae) of electric rays from the order
18 Torpediniformes, are reported to lack this organ (Prasad 1945). Oviparous species have the largest OGs in
19 chondrichthyans (Hamlett et al. 2005). The OG of *Raja clavata* is one of the biggest and is similar in size
20 (at the spawning stage) to the OG from the grey bambooshark, *Chiloscyllium griseum* (50 mm height and
21 38 mm width; Nalini 1940), and the catshark, *Scyliorhinus canicula* (35 mm height and 20 mm width;
22 Knight et al. 1996). Within the Rajidae family, the OG is virtually similar, although small histological
23 differences could be observed (Hamlett et al. 1998). Oviparous species have species specific egg capsules
24 (i.e. different shape and size). In the species that have egg capsules with surface hairs (e.g. *R. clavata*,
25 *Raja erinacea* and *Raja eglanteria*), the terminal zone possesses both mucous and serous glands, while
26 the latter are absent from those species with smooth egg capsules, like *S. canicula* (Knight et al. 1996;
27 Hamlett et al. 2005).

28 This study is the first to describe the OG development throughout the reproductive maturation of skates.

29 In developing *R. clavata* females, mucins were first visualized in the club, papillary and terminal zones.

1 Therefore, it could be concluded that this stage is when the secretory cells of the gland tubules start to
2 produce secretion materials, since prior to this stage (immature stage) to oviducal gland development was
3 even observed. In the spawning capable stage, the secretory tubules enlarge as a result of the increase in
4 size and number of the secretory granules stored inside the secretory cells. Later, the secretory material is
5 released into the lumen of the gland tubules, and is transported through the tubules by ciliary action of the
6 ciliated cells in the tubule epithelium. The secretory material is transformed from secretory granules into
7 a coalescent strand within the tubular lumen, and is visible in every zone of the *R. clavata* OG. When the
8 coalescent strands pass through the spinneret regions of the baffle zone, they become ribbon like in form,
9 and are integrated in the network of packed fibrils that will compose the future egg capsule (Knight et al.
10 1993).

11 The chemical nature of the secretions produced by the different gland zones was investigated using
12 special histological staining techniques. The secretions of the club, papillary and terminal zones all
13 contained mucins. In spawning capable females, the gland tubules from the club and papillary zones were
14 filled with neutral and sulfated acid mucins, which stained positively with PAS and AB. In the papillary
15 zone, three distinct areas were identified: a) one area showed similar staining as the club zone, PAS+ and
16 AB+, and included the majority of the papillary gland tubules; b) another area close to the lamellae
17 contained many neutral mucins that stained intensely with PAS+, and c) the third area was located close
18 to the junction with the baffle zone and produced sulfated acid mucins that markedly stained with AB+.
19 Most of the jelly produced by the papillary zone seemed to have a final major input of neutral mucins by
20 the second type of gland tubules, which could influence the final viscosity of the secreted product. In fact,
21 according to Koob and Straus (1998) the jellies produced by the club and papillary zones showed
22 different viscosities, the latter being more viscous than the layer of jelly closest to the egg. The
23 differential viscosity resulted from a different chemical composition, with higher concentrations of
24 galactosamine, glucosamine, galactose and fucose, and consequent higher viscosity inside the horns (egg
25 jelly produced by the papillary zone), and lower concentration and lower viscosity near the egg (egg jelly
26 produced by the club zone). Future studies need to focus on where and in what quantities each of these
27 four carbohydrates are produced in the club and papillary zones, to fully understand the dynamic of the
28 oviducal gland. In the papillary zone, the secretory material produced in the last row of tubules showed a
29 different chemical composition (only sulphated acid mucins) from the material produced in the remaining

1 tubules. This feature was already described to occur in oviparous species, like *C. griseum* (Nalini 1940)
2 and *Callorhynchus milli* (Smith et al. 2004), and in viviparous species, like *Mustelus antarcticus* (Storrie
3 2004). It is believed that the thin layer of egg jelly, produced by the caudal-most papillary tubules,
4 functions as a bonding layer and lubricant between the egg investments secreted by the club and papillary
5 zones, and the egg envelop secreted by the baffle zone (Nalini 1940).

6 The larger number of transverse grooves in the baffle zone provides for a thicker egg covering (Knight et
7 al. 1993; Hamlett et al. 1998). In general, oviparous species, like *R. clavata* (25 to 30 transverse grooves;
8 present study), *C. griseum* (74 transverse grooves; Nalini 1940) and *S. canicula* (20 transverse grooves;
9 Hamlett et al. 2005) have more transverse grooves than viviparous species. In the aplacental viviparous
10 spiny dogfish, *Squalus acanthias*, the baffle zone has considerably fewer transverse grooves (number not
11 provided by the authors), and consequently the egg covering is reduced to a flexible egg candle that
12 surrounds the embryos and disappears prior to parturition. The baffle zone is completely absent in the
13 aplacental viviparous yellow spotted stingray, *Urolophus jamaicensis*, and no egg covering is produced
14 (Hamlett et al. 1998). Besides the differences in structure, the secretory cells of chondrichthyan baffle
15 zone may also produce secretory material with different chemical compositions. In the present study, the
16 secretory material produced by the baffle zone was not identified as one of the mucins tested in *R. clavata*
17 OG. Yet, the observation of secretory cells with the cytoplasm packed with numerous spherical granules
18 about 1.22 μm in diameter, which is characteristic of cells specializing in protein secretion (Knight et al.
19 1993; Junqueira and Carneiro 1995), suggests that the secretions produced in the baffle zone were
20 proteins, as described for other species (Knight et al. 1993; Koob and Cox 1993). Studies on the OG of *R.*
21 *erinacea* showed that the six major proteins, present in the granules, all contain high levels of glycine,
22 serine, proline and tyrosine (Koob and Cox 1993). The application of Van Gieson stain showed further
23 that the granules were not composed of collagen. This constituent was also absent in *R. erinacea* but
24 present in the egg covering of oviparous sharks, such as *S. canicula* (Knight et al. 1993) and *C. griseum*
25 (Krishnan 1959).

26 The chemical nature of the homogeneous brown material observed in the baffle and terminal zones could
27 not be identified. No positive results were obtained for each of tested staining techniques. Despite being
28 observed in a very early stage of the gland development, the texture and colour of these accumulations are

1 similar to the tanned egg covering (Koob and Cox 1990, 1993; Threadgold 1957). Egg envelope material
2 was observed emerging into the lumen from the baffle zone tubules in *M. antarcticus* (Storrie 2004)..
3 Sperm storage in female chondrichthyans, particularly sharks and holocephalans, has been largely
4 confirmed by histological analysis (e.g. in the Oman shark, *Iago omanensis* - Fishelson and Baranes
5 1998; in *C. milli* - Smith et al. 2004; in *M. antarcticus* - Storrie et al. 2008). Sperm storage occurs inside
6 specialized tubules (sperm storage tubules) located in the terminal zone. The secretory cells present in the
7 sperm storage tubules produced secretions that contributed to the support, nourishment, and maintenance
8 of the sperm during the storage period (Hamlett et al. 2002b; Storrie 2004; Storrie et al. 2008). The
9 tubules also contained ciliated cells, which are responsible for the transport of sperm into and out of the
10 tubules.

11 In the case of Rajids, sperm has been histologically detected as nonnagregated, individual sperm in the
12 baffle zone near the gland lumen, and rarely in the deeper regions of the gland of *R. erinacea* (Hamlett et
13 al. 1998). Sperm storage has been experimentally inferred through female specimens of the blonde ray,
14 *Raja brachyura* (Clark 1922) and of *R. clavata* (Ellis and Shackley 1995) kept in captivity. In the two
15 experiments, females were isolated from males and were able to lay fertilized eggs after 5 (*R. brachyura*)
16 and 13 (*R. clavata*) weeks of isolation.

17 In the present study on the OG of *R. clavata*, small groups of sperm were occasionally found in the
18 tubules of the baffle and terminal zones near the lamellae, and more frequently, sperm bundles were
19 observed in the tubules at the deep recesses of the baffle zone. The presence of sperm in the baffle zone of
20 developing females indicates that mating occurs before maturity is reached, which was also reported in
21 other chondrichthyans (e.g. *M. antarcticus*, Storrie 2004; Storrie et al. 2008). The baffle tubules containing
22 sperm bundles, which is a sperm aggregation characteristic of sperm storage tubules (Hamlett et al. 1998,
23 2002b, 2005; Storrie 2004; Storrie et al. 2008), have both secretory and ciliated cells. In *R. clavata*, the
24 secretory function may only be related to egg capsule secretion rather than to sperm maintenance because
25 the tubules and secretory cells resemble those in the entire baffle zone, and were not surrounded by highly
26 vascularised connective tissue, a main sperm storage tubule characteristics presented in previous studies
27 (e.g. Hamlett et al. 2005; Storrie et al. 2008). Thus, the sperm observed could be the result of a recent
28 mating episode and not from sperm that was stored for an extended period of time. Hence, further studies
29 should be conducted to widen the observations made in the present study on *R. clavata* and to other Rajid

1 species, in order to investigate the explanation for the sperm storage facts reported in previous studies that
2 were based on pregnant captive females (Clark 1922; Ellis and Shackley 1995).

3 In *R. clavata*, the terminal zone seems only to be responsible for the formation of hair filaments on the
4 surface of the capsule, and is not involved with sperm storage. As observed, this zone is composed of
5 mixed gland tubules (two different types of gland tubules) that contain both mucous and serous glands.
6 First the mucous section of the tubules produce secretions, then as the emerging hair filaments, produced
7 by the serous glands, pass through the mucoid region they gain a coat of sticky material that will serve the
8 purpose of attaching debris for camouflage (Hamlett et al. 2005). In aplacental species, the terminal zone
9 is only composed of mucous glands and SSTs (Hamlett et al. 1998). As described for other
10 chondrichthyans (e.g. Smith et al. 2004; Hamlett et al. 2005), the terminal zone is generally not organized
11 into lamellae. Instead it consists of isolated, scattered tubules, which, in the case of species that have egg
12 capsules with surface hairs it determines the positioning of those hairs. In the case of the *R. clavata* that
13 produces an egg capsule full of surface hairs, the terminal zone is much extended in terms of its surface.

14

15 In conclusion, the formation of the egg capsule in *R. clavata* is a continuous process involving the
16 oviducal gland. Capsule formation starts at the developing stage, when the OG becomes completely
17 formed and all four zones begin to produce and secrete the relevant materials. There are no great
18 variations in the size of the gland tubules within the spawning stage, if the three stages included in the
19 maturity stage from Stehmann (2002) are considered. In fact, all three stages are related to the production
20 of the capsule which is a very fast process (not more than one day for *R. clavata*) (Ellis and Shackley
21 1995). The sperm, observed inside tubules of the baffle zone from developing to extruding females, was
22 not sperm storage. Some questions remain to be answered about the chemical nature of the secretions
23 produced by the OG, and need future investigation. Given the complexity and variability of the
24 reproductive strategies among chondrichthyans, it would be important to expand this histological
25 investigation to other species in order to better understand their life cycles.

26

27

28 **Acknowledgments**

1 We thank Dr. Beverly J. Macewicz for their valued suggestions for improvement, by revising the English
2 and the scientific content of the manuscript. We would like to acknowledge the histology technician
3 Rosário Jorge from the Faculty of Veterinary Medicine for teaching and helping with the histological
4 procedures, especially the staining techniques. Additionally, we would also like to thank Ana Neves from
5 FCUL/DBA and João Oliveira and Carmo Silva from IPIMAR for preparing some of the histological
6 slides. This study was partially supported by project EU Data Collection/, DCR (PNAB). B. Pereira was
7 funded by grant from the Fundação para a Ciência e a Tecnologia, SFRH/ BD/23777/ 2005.

8

9 **References**

10 Bancroft J, Gamble M (2002) Theory and Practice of Histological Techniques. 5th Edn. Churchill
11 Livingstone, Elsevier, London.

12

13 Brown-Peterson NJ, Lowerre-Barbieri SK, Macewicz BJ, Saborido-Rey F, Tomkiewicz J, Wyanski DM
14 (2007) An improved and simplified terminology for reproductive classification in fishes. Pre-print doc.
15 doi: <http://hdl.handle.net/10261/11844>

16

17 Clark RS (1922) Rays and skates (Raiaae). No. I – Egg capsules and young. J Mar Biol Assoc UK 12: 577-
18 643.

19

20 Ellis J, Shackley SE (1995) Observations on egg-laying in the thornback ray. J Fish Biol 46: 903-904.
21 doi: [10.1111/j.1095-8649.1995.tb01613.x](https://doi.org/10.1111/j.1095-8649.1995.tb01613.x)

22

23 Fishelson L, Baranes A (1998) Observations on the Oman shark, *Iago omanensis* (Triakidae), with
24 emphasis on the morphological and cytological changes of the oviduct and yolk sac during gestation. J
25 Morphol 236: 151-165. doi: [10.1002/\(SICI\)1097-4687\(199806\)236:3<151::AID-JMOR1>3.0.CO;2-6](https://doi.org/10.1002/(SICI)1097-4687(199806)236:3<151::AID-JMOR1>3.0.CO;2-6)

26

27 Hamlett WC, Knight DP, Koob TJ, Jezior M, Luong T, Rozycki T, Brunette N, Hysell MK (1998) Survey
28 of oviducal gland structure and function in elasmobranchs. J Exp Zool 282: 399-420. doi:
29 [10.1002/\(SICI\)1097-010X\(199811/12\)282:4/5<399::AID-JEZ2>3.0.CO;2-6](https://doi.org/10.1002/(SICI)1097-010X(199811/12)282:4/5<399::AID-JEZ2>3.0.CO;2-6)

1
2
3
4
5
6
7
8
9
10
11
12
13
14
15
16
17
18
19
20
21
22
23
24
25
26
27
28

Hamlett WC, Reardon M, Clark J, Walker TI (2002a) Ultrastructure of sperm storage and male genital ducts in a male holocephalan, the elephant fish, *Callorhynchus milii*. *J Exp Zool* 292: 111-128. doi: 10.1002/jez.1148

Hamlett WC, Musick JA, Hysell CK, Sever DM (2002b) Uterine epithelial-sperm interaction, endometrial cycle and sperm storage in the terminal zone of the oviducal gland in the placental smoothhound, *Mustelus canis*. *J Exp Zool* 292: 129–144. doi: 10.1002/jez.1149

Hamlett WC, Knight DP, Pereira FTV, Steele J, Sever DM (2005) Oviducal gland in Chondrichthyans. In: Hamlett WC (ed) *Reproductive Biology and Phylogeny of Chondrichthyans: Sharks, Batoids and Chimaeras*, vol. 3. Science Publishers, Inc, New Hampshire, pp. 301-335.

Junqueira LC, Carneiro J (1995) *Histologia Básica*, 8ª ed. GuanabaraKoogan, Rio de Janeiro.

Knight DP, Feng D, Stewart M, King E (1993) Changes in macromolecular organization in collagen assemblies during secretion in the nidamental gland and formation of the egg capsule wall in the dogfish *Scyliorhinus canicula*. *Philos Trans R Soc Lond B Biol Sci* 341: 419–436.

Knight DP, Feng D (1994a) Interaction of collagen with hydrophobic protein granules in the egg capsule of the dogfish, *Scyliorhinus canicula*. *Tissue Cell* 26: 155-167.

Knight DP, Feng D (1994b) Some observations on the collagen fibrils of the egg capsule of the dogfish, *Scyliorhinus canicula*. *Tissue Cell* 26: 384-401.

Knight DP, Feng D, Stewart M (1996) Structure and function of the selachian egg case. *Biol Rev* 76: 81-111. doi: 10.1111/j.1469-185X.1996.tb00742.x

1 Krishnan G (1959) Histochemical studies on the nature and formation of egg capsules of the shark
2 *Chiloscyllium griseum*. Biol Bull 117: 298-307.
3
4 Koob TJ, Cox DL (1990) Introduction and oxidation of catechols during the formation of the skate (*Raja*
5 *erinacea*) egg capsule. J Mar Biol Assoc UK 70: 395-411.
6
7 Koob TJ, Cox DL (1993) Stabilization and sclerotization of *Raja erinacea* egg capsule proteins. Environ
8 Biol Fishes 38: 151-157. doi: 10.1007/BF00842911
9
10 Koob TJ, Straus JW (1998) On the role of egg jelly in *Raja erinacea* egg capsule. Bull Mt Desert Is Biol
11 Lab 37: 117-119.
12
13 Long JH, Koob T J (1997) Ventilating the skates egg capsule: the transitory tail pump of embryonic little
14 skates (*Raja erinacea*). Bull Mt Desert Is Biol Lab 36: 117-119.
15
16 Musick, JA, Ellis, JK (2005) Reproductive evolution of Chondrichthyans. In: Hamlett WC (ed)
17 Reproductive Biology and Phylogeny of Chondrichthyans: Sharks, Batoids and Chimaeras, vol. 3.
18 Science Publishers, Inc, New Hampshire, pp. 45-79.
19
20 Nalini MKP (1940) Structure and function of the nidamental gland of *Chiloscyllium griseum* (Mull. and
21 Henle). Proc Indian Acad Sci 12: 189-214. doi:10.1007/BF03049107
22
23 Prasad RR (1945) The structure, phylogenetic significance and function of the nidamental glands of some
24 elasmobranchs of the Madras Coast. Proc Nat Instit Sci India 11: 282-303.
25
26 Pratt HL (1993) The storage of spermatozoa in the oviducal glands of western North Atlantic sharks.
27 Environ Biol Fishes 38: 139-149. doi: 10.1007/BF00842910
28
29 Rusaouën M (1976) The dogfish shell gland, a histochemical study. J Exp Mar Biol Ecol 23: 267-283.

1
2
3
4
5
6
7
8
9
10
11
12
13
14
15
16
17
18
19
20
21

Smith RM, Walker TI, Hamlett WC (2004) Microscopic organization of the oviducal gland of the holocephalan elephant fish, *Callorhynchus milii*. *Mar Freshwater Res* 55: 155-164. doi:10.1071/MF01078

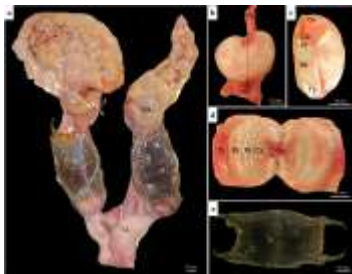Stehmann M (2002) Proposal of a maturity stages scale for oviparous and viviparous cartilaginous fishes (Pisces, Chondrichthyes). *Arch Fish Mar Res* 50: 23–48.

Storrie MT (2004) Microscopic modifications of the female reproductive tissues of *Mustelus antarcticus*. PhD thesis. School of Ecology and Environment, Deakin University.


Storrie MT, Walker TI, Laurenson LJ, Hamlett WC (2008) Microscopic organization of the sperm storage tubules in the oviducal gland of the female gummy shark (*Mustelus antarcticus*), with observations on sperm distribution and storage. *J Morphol* 269: 1308-1324. doi: 10.1002/jmor.10646

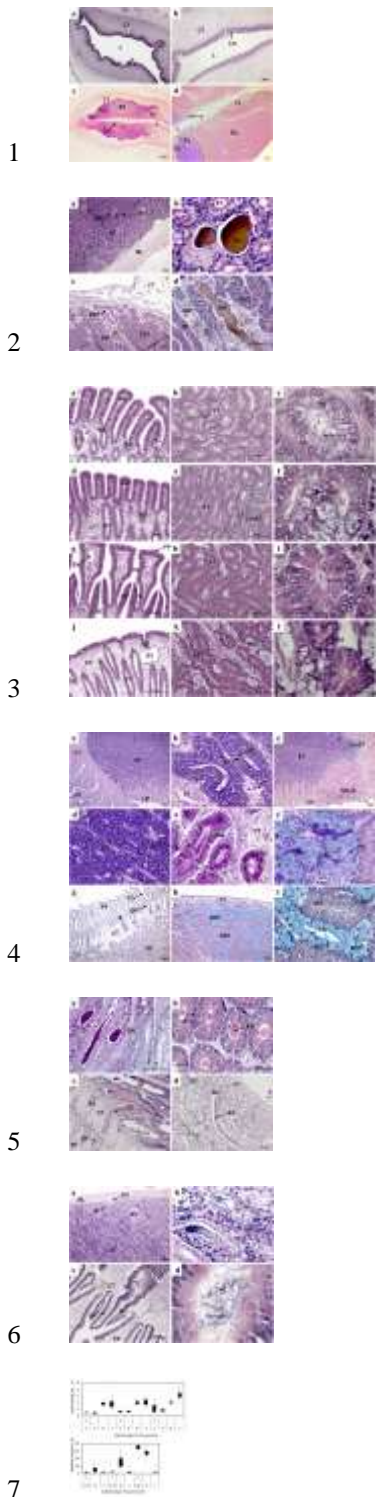
Threadgold LT (1957) A histochemical study of the shell gland of *Scyliorhinus caniculus*. *J Histochem Cytochem* 5: 159-166.

Walker P, Hislop J (1998) Sensitive skates or resilient rays? Spatial and temporal shifts in ray species composition in the central and north-western North Sea between 1930 and the present day. *ICES J Mar Sci* 55: 392–402. doi: 10.1006/jmsc.1997.0325



22
23





8 **Figure captions**

9 **Fig. 1** a) Reproductive tract of a female *Raja clavata* at the actively spawning stage. The measurements
 10 made on the OGs are represented: w: width; h: height; t: thickness. b) External anatomy of the OG at the
 11 actively spawning stage. Anteriorly, the OG communicates with the oviduct, while posteriorly it

1 communicates with the uterus. The dotted line in the center indicates the position of sagittal sectioning. c)
2 Sagittal section of the OG at the actively spawning stage, showing the different zones from anterior to
3 posterior: club zone; papillary zone; baffle zone; terminal zone. d) Internal view of the two halves of the
4 OG at the actively spawning stage, displaying the different gland zones, from the oviduct to the uterus:
5 club zone; papillary zone; baffle zone; terminal zone. e) Dorsal view of an egg capsule, the surface of
6 which is covered with hairs. O: ovary; F: follicles; OG: oviducal gland; C: capsule; U: uterus; Ov:
7 oviduct; Cz: club zone; Pz: papillary zone; Bz: baffle zone; Tz: terminal zone.

8

9 **Fig. 2** Oviducal gland (OG) measurements by maturity stage (2: developing; 3: spawning capable; 4:
10 actively spawning): a) width; b) height; c) thickness. d) Relationship between OG width and the specimen
11 total length.

12

13 **Fig. 3** Sagittal sections of the oviducal gland (OG) of *Raja clavata*, at the different stages of development.

14 a) Undifferentiated OG in an immature female. H&E. b) Beginning of the development of the OG in an
15 early developing female. H&E. c) Formation of lamellae, gland tubules and differentiation of the four
16 distinct zones in a developing female. H&E. d) Fully developed OG with full differentiation of the four
17 secretory zones in a spawning capable female. PAS/AB. CT: connective tissue; L: lumen; Lm: lamellae;
18 Cz: club zone; Pz: papillary zone; Bz: baffle zone; Tz: terminal zone.

19

20 **Fig. 4** Brown material accumulations. a) Deep recesses of the baffle zone in a developing female. H&E.

21 b) Detail of the brown material observed in the baffle zone in a developing female. H&E. c) Terminal
22 zone in an actively spawning female. H&E. d) Detail of the brown material observed in the terminal zone
23 in an actively spawning female. BM: brown material; ST: secretory tubules; BV: blood vessel; ML:
24 muscle layer; CT: connective tissue; MST: mucous secretory tubule; SST: serous secretory tubule.

25

26 **Fig. 5** Differentiated zones of the oviducal gland in the late developing stage. H&E. a) Club zone

27 lamellae. b) Club zone secretory tubules. c) Detail of a secretory tubule, in the club zone, with ciliated and
28 secretory cells. d) Papillary zone lamellae. e) Papillary zone secretory tubules. The caudal-most papillary
29 tubules adjacent to the baffle zone are distinct from the remaining tubules. f) Detail of a secretory tubule,

1 in the papillary zone, with ciliated cells, and secretory cells. Secretory granules stored inside secretory
2 cells. g) Baffle zone lamellae. The secretory ducts open into the lumen through the spinneret region,
3 composed of two baffle plates. The baffle plates are surrounded by another pair of large folds, the plateau
4 projections, lining the transverse groove. h) Baffle serous secretory tubules. i) Detail of a secretory tubule,
5 in the baffle zone, with ciliated cells and secretory cells. Secretory cells contain secretory granules. j)
6 Structural organization of the terminal zone displaying the regular surface epithelium and the elongated
7 tubular glands opening into the lumen. k) Terminal zone secretory tubules, with both mucous and serous
8 secretory cells. l) Detail of the two types of secretory tubules, in the terminal zone, mucous and serous.
9 Both tubules present ciliated cells and secretory cells. Secretory cells of serous tubules present secretory
10 granules. Lm: lamellae; BV: blood vessel; ST: secretory tubule; SD: secretory duct; CT: connective
11 tissue; SC: secretory cell; CC: ciliated cell; L: Lumen; C: cilia; CmST: caudal-most secretory tubules on
12 papillary zone; SM: secretory material; PP: plateau projection; TG: transverse groove; BP: basal plate; S:
13 spinneret; SG: secretory granules; SST: serous secretory tubules; MST: mucous secretory tubule.

14

15 **Fig. 6** Secretory material produced by the secretory tubules from the four zones of the oviducal gland of a
16 spawning capable/actively spawning female. PAS/AB. a) Club zone with PAS+ and AB+ secretory
17 material stored inside the tubules. b) Secretory tubules of the club zone with PAS+ and AB+ secretory
18 material stored inside the secretory cells. c) Structural organization of the different regions of the
19 papillary zone. d) Secretory tubules of the papillary zone, containing PAS+ and AB+ secretory material.
20 e) Papillary secretory tubules near the lumen containing PAS+ secretory granules. f) Caudal-most
21 papillary tubules containing AB+ secretory material. g) Baffle zone secretory tubules PAS- and AB-. h)
22 Terminal zone mucous secretory tubules containing AB+ secretory material and serous secretory tubules
23 PAS- and AB-. i) Mucous secretory tubules containing AB+ secretory material stored inside secretory
24 cells. CT: connective tissue; ST: secretory tubules; Lm: lamellae; Ov: oviduct; SC: secretory cell; CC:
25 ciliated cell; L: Lumen; STLm: secretory tubules near the lamellae on papillary zone; CmST: caudal-most
26 secretory tubules on papillary zone; SM: secretory material; PP: plateau projection; TG: transverse
27 groove; BP: basal plate; S: spinneret; SST: serous secretory tubules; MST: mucous secretory tubule.

28

1 **Fig. 7** Secretory material accumulated in the tubules lumen of spawning capable females. a) Papillary
 2 zone containing PAS+ secretory material. PAS/AB. b) Baffle zone tubular glands containing egg capsule
 3 material. H&E. c) Baffle zone secretory ducts secreting the egg capsule material to the gland lumen.
 4 H&E. d) Terminal zone secretory ducts secreting the surface hairs to the gland lumen. H&E. ST:
 5 secretory tubule; SM: secretory material; L: Lumen; SD: secretory duct; CT: connective tissue; EC: egg
 6 capsule; PP: plateau projection; BP: basal plate. SH: surface hair.

7
 8 **Fig. 8** Sperm observed inside the oviducal gland. H&E. a) Sperm bundles inside the tubules of the baffle
 9 zone deep in the oviducal gland, in the late developing stage. b) Detail of the tubules containing sperm in
 10 the deep recesses of the baffle zone in the late developing stage. c) Non-aggregated individual sperm
 11 inside the secretory ducts of the baffle zone in spawning capable females. d) Detail of the secretory duct
 12 containing sperm, in the spawning capable stage. ML: muscle layer; BV: blood vessel; S: sperm; ST:
 13 secretory tubules; L: lumen; CT: connective tissue; SD: secretory duct; BP: basal plate; PP: plateau
 14 projection.

15
 16 **Fig. 9** Measurements of the different zones (C: club; P: papillary; C+P: club and papillary; B: baffle; T:
 17 terminal) of the oviducal gland by maturity stage (2: developing; 3: spawning capable; 4: actively
 18 spawning). a) Surface fold length (μm). b) Glandular area (μm^2). Boxes limit the percentiles 25 and 75.
 19 Bars stands for the upper and lower value observed.

20
 21

22 **Table 1** Maturity scale for oviparous elasmobranch females adapted from Serra-Pereira
 23 (in press). Both macroscopic and histological descriptions are presented.

Stages	Macroscopic	Histological
Immature	Ovaries small, whitish and homogeneous; undistinguishable ovarian follicles. Absent oviducal gland and thread-like narrow uterus.	Ovary with primordial (smaller than 0.3 mm) and primary follicles (0.3 to 1 mm) connected to the germinal epithelium and tunica albuginea. Uterus composed mainly by connective tissue, covered by simple columnar epithelium with some invaginations; some blood vessels present.
Developing	Ovaries enlarged with small follicles in	Ovary with primordial, primary, pre-

	<p>different stages of development, sometimes restricted to the anterior part of the ovary. Developing oviducal gland. Enlarged uterus.</p> <p>Three sub-phases can be considered: <i>Early developing:</i> ovary with only white follicles with less than 2 mm, oviducal absent or beginning to form (whitish);</p> <p><i>Mid developing,</i> ovary with yellow follicles below 8 mm (commonly below 30 follicles), developing oviducal gland;</p> <p><i>Late developing:</i> ovary with a great quantity of yellow follicles (commonly above 30) with diameter less than 15 mm, oviducal gland completely formed.</p> <p>Large ovaries with large yolked follicles that can reach around 40 mm in diameter. Oviducal gland and uterus fully developed.</p>	<p>vitellogenic and vitellogenic follicles (smaller than 15 mm). Oviducal gland can show only the beginning of gland tubules formation or be completely formed, with differentiation of the four secreting zones, depending on the advance in maturation. Beginning of secretions production in the oviducal gland and uterus. Uterus more invaginated and vascularized.</p>
Spawning capable	<p>Ovaries and oviducal gland similar to the spawning capable phase. Large yolked-egg may be present in the oviducal gland. Egg capsule present in the uterus and attached or not to the oviducal gland. Capsules may be starting to be produced or be fully formed, hardened and dark; present in one or both uterus.</p>	<p>Follicles in all stages can be observed in the ovary. Secretions present in the gland tubules of the oviducal gland. Uterus highly invaginated, showing longitudinal folds producing secretions to the lumen.</p>
Actively spawning		<p>Follicles in all stages can be observed in the ovary. Post-ovulatory follicles can be present in the ovary. Oviducal gland tubules full of secretion materials. Secretions also present in the gland lumen. Uterus producing secretions to the lumen.</p>

-
- 1
 - 2
 - 3

1 **Table 2** Statistical results on the effect of maturity on the morphological characteristics
 2 of the oviducal gland (width, height and thickness). Maturity stages: 2: developing; 3:
 3 spawning capable; 4: actively spawning.

	ANOVA		Tukey's HSD test					
			(a)					
	All		2 vs. 3		2 vs. 4		3 vs. 4	
	n	p-value	n	p-value	n	p-value	p-value	n
Width	138	<0.01	104	<0.01	97	<0.01	75	0.01
Height	138	<0.01	104	<0.01	97	<0.01	75	<0.01
Thickness	102	<0.01	104	<0.01	97	<0.01	75	<0.01

4

5

6