



Long-term stability of surgical bone regenerative procedures of peri-implantitis lesions in a prospective case-control study over three years

Ann-Marie Roos-Jansåker, Christel Lindahl, Rutger G. Persson, Stefan Renvert

► To cite this version:

Ann-Marie Roos-Jansåker, Christel Lindahl, Rutger G. Persson, Stefan Renvert. Long-term stability of surgical bone regenerative procedures of peri-implantitis lesions in a prospective case-control study over three years. *Journal of Clinical Periodontology*, 2011, 38 (6), pp.590. 10.1111/j.1600-051X.2011.01729.x . hal-00631684

HAL Id: hal-00631684

<https://hal.science/hal-00631684>

Submitted on 13 Oct 2011

HAL is a multi-disciplinary open access archive for the deposit and dissemination of scientific research documents, whether they are published or not. The documents may come from teaching and research institutions in France or abroad, or from public or private research centers.

L'archive ouverte pluridisciplinaire **HAL**, est destinée au dépôt et à la diffusion de documents scientifiques de niveau recherche, publiés ou non, émanant des établissements d'enseignement et de recherche français ou étrangers, des laboratoires publics ou privés.



**Long-term stability of surgical bone regenerative
procedures
of peri-implantitis lesions in a prospective case-control
study over three years**

Journal:	<i>Journal of Clinical Periodontology</i>
Manuscript ID:	CPE-10-10-2899.R2
Manuscript Type:	Original Article Implant Dentistry
Date Submitted by the Author:	15-Feb-2011
Complete List of Authors:	Roos-Jansåker, Ann-Marie; Public dental health Services, Periodontology Lindahl, Christel; University of Kristianstad, Oral Sciences PERSSON, Rutger; University of Berne, Periodontology, Div Oral Micorbiology; University of Washington, Periodontics and Department of Oral Medicine Renvert, Stefan
Topic:	Implantology
Keywords:	Peri-implantitis, Surgery, Bone graft, Membrane, Defect fill
Main Methodology:	Other

SCHOLARONE™
Manuscripts

1
2
3
4
5
6
7
8
9
10
11
12
13
14
15
16
17
18
19
20
21
22
23
24
25
26
27
28
29
30
31
32
33
34
35
36
37
38
39
40
41
42
43
44
45
46
47
48
49
50
51
52
53
54
55
56
57
58
59
60

**Long-term stability of surgical bone regenerative procedures
of peri-implantitis lesions in a prospective case-control study over
three years**

**Ann-Marie Roos-Jansåker¹, Christel Lindahl², G. Rutger Persson^{2,3, 4}, Stefan
Renvert^{2, 5, 6}**

¹Department of Periodontology, Public Dental Health Service, Kristianstad, Sweden

²Department of Oral Sciences, Kristianstad University Kristianstad, Sweden

³Departments of Periodontics and Oral Medicine, University of Washington, Seattle
WA. USA.

⁴Department of Periodontology University of Bern, Bern, Switzerland

⁵School of Dental Sciences, Trinity Collage, Dublin, Ireland

⁶Blekinge Institute of Technology, Karlskrona, Sweden

Key words: Peri-implantitis, surgery, bone graft, membrane, defect fill, plaque index

Running title: Surgical treatment of peri-implantitis

Number of words in abstract: 199

Number of words in manuscript: 3264

Number of tables: 5

Number of figures: 8

Corresponding author:

Stefan Renvert
Kristianstad University, 291 88 Kristianstad, Sweden
Tel. +46+44-204090
E mail: stefan.renvert@hkr.se

Abstract

Objectives: To evaluate the extent of bone fill over three years following surgical treatment of peri-implantitis with bone grafting with or without a membrane.

Material & Methods: In a non-submerged wound healing mode, 15 subjects with 27 implants were treated with a bone substitute (Algipore®) alone, and 17 subjects with 29 implants were treated with the bone substitute and a resorbable membrane (Osseoquest®). Implants with radiographic bone loss ≥ 1.8 mm following the first year in function, and with bleeding and/or pus on probing were included. Following surgery subjects were given systemic antibiotics (10 days) and rinsed with chlorhexidine. After initial healing the subjects were enrolled in a strict maintenance program.

Results:

Statistical analysis failed to demonstrate changes in bone fill between one and three years both between, and within procedure groups. Mean defect fill at three years was $1.3 \pm (\text{S.D.})1.3$ mm if treated with bone substitute alone and $1.6 \pm (\text{S.D.})1.2$ mm if treated with an adjunct resorbable membrane, ($p=0.40$). Plaque index decreased from approximately 40% to 10% remaining stable during the following two years.

Conclusion: Defect fill using a bone substitute with or without a membrane technique in treatment of peri-implantitis can be maintained over three years.

1
2
3
4
5
6
7
8
9
10
11
12
13
14
15
16
17
18
19
20
21
22
23
24
25
26
27
28
29
30
31
32
33
34
35
36
37
38
39
40
41
42
43
44
45
46
47
48
49
50
51
52
53
54
55
56
57
58
59
60

Clinical Relevance

Scientific rationale: Limited information is available regarding the long term prognosis of regenerative treatment of intraosseous defects following surgical treatment of peri-implantitis lesions in humans.

Principal findings: Over a follow-up period of three years, a similar extent of radiographic evidence of bone fill following placement of a bone graft material with or without a concomitant use of a resorbable membrane in osseous defects adjacent to implants was identified. No changes were observed between year one and year three and both procedures appear to provide stable results in regards to radiographic evidence of bone fill.

Practical implications: Bone fill obtained following surgical treatment of peri-implantitis lesions can be obtained, and remain stable if subjects comply with supportive therapy visits and maintain good oral hygiene.

Conflict of interest and sources of funding statement:

None of the authors declare a conflict of interest. The present study was supported by research foundations from the Public Dental Health Service, County of Skåne, Sweden and Kristianstad University

For Peer Review

Introduction

It is well established that peri-implantitis has an infectious etiology. A complex biofilm around implants with peri-implantitis has been identified (Renvert et al. 2007, 2008, Shibli et al. 2008). The infection results in a pathology that includes soft tissue inflammation, and loss of implant surrounding alveolar bone. In the progression of peri-implantitis, severe bone lesions with crater formed defect characteristics can be found (Schwarz et al. 2007). Data suggest that the prevalence of peri-implantitis is high (Roos-Jansåker et al. 2006a, Fransson et al. 2009, Koldslund et al. 2010). Data also suggest that within the same subject with peri-implantitis the characteristics of the bony lesions are similar and that the rate of untreated lesions appear to increase over time (Fransson et al. 2010). There is no evidence that the implant surface characteristics can have an influence on the initiation of peri-implantitis (Renvert et al. 2011). Surgical treatment of peri-implantitis lesions with an intra bony component has a favorable treatment outcome (Schwarz et al. 2010).

Non-surgical therapy of peri-implantitis does not seem to be efficacious (Schwarz et al. 2006b, Renvert et al. 2009, Persson et al. 2010). Surgical intervention and cleaning of implants with hydrogen peroxide and adjunct systemic antibiotics have demonstrated limited success over a five year period (Leonhardt et al. 2003).

Resective surgery and implantoplasty of cases with peri-implantitis seems to be effective over a three year period (Romeo et al. 2005).

Different bone regenerative therapies have been used attempting to accomplish healing of peri-implantitis defects in humans. A useful surgical treatment modality

1
2
3 including bone grafts covered by ePTFE membranes in animal with experimentally
4 induced peri-implantitis is effective in the management of peri-implantitis (Schou et al.
5 2003, Fiorellini et al. 2007). Surgical treatment of circumferential defects around
6 implants in humans using bone grafting and collagen membranes have been shown
7 to be useful (Schwarz et al. 2009, 2010). Available data also suggest that surgical
8 treatment of non-submerged implants with bony dehiscence can successfully be
9 treated with a stiff non-resorbable membrane combined with a xenograft (De Boever
10 & De Boever 2005).

11
12
13
14
15
16
17
18
19
20
21
22
23
24
25
26
27
28
29
30
31
32
33
34
35
36
37
38
39
40
41
42
43
44
45
46
47
48
49
50
51
52
53
54
55
56
57
58
59
60

Other studies in humans have shown that surgical treatment of implants with bone lesions that were ≥ 4 mm, and with circumferential crater defects can effectively be treated with a mixture of autogenous and xenogenous bone (Wiltfang et al. 2010).

Almost complete bone fill in subjects with peri-implantitis treated with surgical intervention using laser debridement and application of bone grafts with collagen membrane coverage has been demonstrated (Romanos & Nentwig 2008). These findings are supported by other studies demonstrating that surgical treatment of peri-implant defects with bone graft substitutes combined with resorbable membrane methods and submerged healing or regenerative treatment with a bone substitute alone or in combination with a resorbable membrane in a non-submerged model results in defect fill (Roos-Jansåker et al. 2007a, b). The aim of the present study was to evaluate three-year stability of defect fill after surgical regenerative therapy of peri-implantitis including the use of a bone graft material with, or with a resorbable membrane in an non-submerged mode of wound healing.

Material and Methods

Study design

The study design was a human prospective case-control, single blinded, longitudinal study comparing the radiographic outcome after three years.

Study population

The Institutional Review Board at the University of Lund, Sweden approved the study. All participating individuals signed an informed consent. The CONSORT guidelines for clinical trials were followed (Figure 1). Study subjects were recruited from (I) individuals examined in a survey evaluating the prevalence of peri-implantitis 9-14 years following placements of Brånemark implants (Brånemark system®, Nobel Pharma, Göteborg, Sweden) and (II) subjects who had been referred for the treatment of peri-implantitis to the Clinic of Periodontology, Public Dental health Services and University of Kristianstad, Sweden. The present paper is a follow-up report based on the publication by Roos-Jansåker et al. 2007.

Thirty-eight consecutive consenting subjects scheduled by the surgeon for surgical treatment of peri-implantitis were enrolled. In order to be included the subject had a minimum of one osseo-integrated implant with peri-implantitis. In order to be included the subject must have an implant demonstrating a progressive bone loss of ≥ 3 threads (≥ 1.8 mm) following the first year of healing (Renvert et al. 2007). In addition, bleeding on probing with or without suppuration must be present at enrollment. This is in agreement with the consensus report of the 7th European Workshop on Periodontology (Lang & Berglundh 2011). Furthermore, efforts must first have been to treat the condition using a non-surgical protocol, and that such

1
2
3 treatments had failed. Subjects with radiographic evidence of horizontal bone loss
4
5 only and without evidence of a vertical crater-like defect were not included.
6
7
8
9

10 All subjects had surgical regenerative treatment using a bone graft substitute
11 (Algapore[®], Friadent, Malmö, Sweden). The first 19 subjects were treated with the
12 graft substitute that was covered with a resorbable membrane (Osseoquest[®], W.L.
13 Gore & Associates, Inc, Flagstaff, AZ). The next 19 subjects were treated with the
14 bone graft substitute alone.
15
16
17
18
19
20
21
22
23
24

25 *Clinical and Radiographic examination*

26
27 At baseline and year-three, the same examiner (A-M.R.J) performed the
28 radiographic examinations. At the time of assessment of the radiographs, the
29 examiner had only access to coded radiographs. Radiographs were obtained of
30 implants using individually made bite-blocks on an Eggen holder (Renvert et al.
31 1981). The bite-blocks were made of Provil[®] Novo, Putty Soft (Heraeus Kulzer,
32 GmbH I, Hanau, Germany). The X-ray films (Kodak Insight, EKC, Rochester, NY)
33 were supported by the bite-block to avoid displacement and curving of the films.
34 Attempts were made to place the film parallel to the long axis of the implant
35 examined. During the exposure the extension arm of the film holder was inserted into
36 an acrylic track mounted on the long cone of the X-ray apparatus. Threads not
37 supported by bone at the mesial and distal site of the implants were assessed.
38
39 Plaque index was defined as visible or not visible at the implant. Probing pocket
40 depth measurements were deferred at year three as the super-structures remained in
41 place. Hence the values would not be comparable to pre-surgical baseline.
42
43
44
45
46
47
48
49
50
51
52
53
54
55
56
57
58
59
60

Surgical treatment

The study population and the surgical techniques have been described in detail previously (Roos-Jansåker et al. 2007a). All subjects received antibiotic coverage (amoxicillin 375 mg x 3 per day, and metronidazole 400 mg x 2 per day) during the first 10 days following surgery. Briefly, following removal of the supra-structure granulosomatous tissue was removed. The exposed implant threads were carefully debrided, treated with hydrogen peroxide (3%), and rinsed with copious amounts of a saline solution. The osseous defects were filled with a bone graft substitute (Algipore[®], Friadent, Malmö, Sweden). Before insertion of the Algipore[®] bone fill material, the bone graft material was mixed with blood from the subject. The first 19 consecutive subjects had a resorbable membrane (Osseoquest[®], W.L. Gore & Associates, INC, Flagstaff, AZ), placed over the filled defect. The following 19 consecutive subjects were treated with the bone graft substitute without a resorbable membrane. The abutments were then reconnected and the flaps were sutured with non-resorbable sutures (Gore 5-0, W.L. Gore & Associates, INC, Flagstaff, AZ) and the supra-structures were remounted. The wound healing was performed in a non-submerged mode.

During the first 5 weeks all subjects rinsed with 0.1 % chlorhexidine. During the first 3 days all subjects also received an anti-inflammatory and analgesic drug (Ibuprofen 400 mg x 3 days). Six weeks after surgery the first supportive therapy was given, and the subjects were enrolled in a maintenance program with visits every third month. At the visits, full mouth plaque scores were obtained. Plaque was disclosed using an erythrosine dye (Top Dent Lifco Dental AB, Enköping, Sweden). Re-instruction in oral hygiene procedures was performed as necessary. Teeth and implants were cleaned

using a rubber cup and a low-abrasive paste. During the follow-up period, none of the subjects was prescribed antibiotics.

Statistical methods

Parametric tests (independent t-tests, equal variance not assumed), and non – parametric tests (Mann-Whitney U test, Wilcoxon test, and Pearson χ^2 were performed to assess differences over time and between groups. Statistical significance was declared at $p < 0.05$. The Kolmogorov-Smirnov test was used to define if the data presented with normal distribution or not. The SPSS PASW 18.0 statistical software (SPSS Inc. Chicago IL) for PC was used in the analysis.

Results

Subject characteristics at study baseline are presented (Table 1). At baseline, a total of 38 subjects were enrolled. Two subjects died before the 1-year control, leaving 17 subjects, with 29 treated implants in the group receiving bone graft and membrane treatment and 19 subjects with 36 treated implants in the group treated with bone graft alone. Four subjects in the group treated with bone graft alone were lost to follow-up during the 3-year period, leaving 15 subjects with 27 implants in this group after three years. In the present analysis only the 32 subjects who returned to the follow-up examination and had radiographs taken could be assessed. During the present study period, no clinical complications as a result of the interventions were found in any of the subjects.

One subject in each group had received Astra implants (Astra Tech system[®], Astra Tech, Mölndal, Sweden). These implant had the same thread distance between

1
2
3
4
5
6
7
8
9
10
11
12
13
14
15
16
17
18
19
20
21
22
23
24
25
26
27
28
29
30
31
32
33
34
35
36
37
38
39
40
41
42
43
44
45
46
47
48
49
50
51
52
53
54
55
56
57
58
59
60

threads as for the Brånemark implants (0.6 mm) other subjects had received machined surfaced implants (Brånemark system[®], Nobelpharma, Göteborg, Sweden).. Subject characteristics are presented (Table 1). Analysis by Mann-Whitney U test confirmed the lack of difference by study method.

The radiographic evidence of defect mean improvement with defect fill between baseline and year three at implants treated with bone graft and membrane was a mean gain of 1.6 mm (S.D. \pm 1.2 mm, range: -1 to +7). The corresponding improvement with defect fill at implants treated with bone graft alone was a mean gain of 1.3 mm (S.D. \pm 1.3, range -2 to + 6 threads) (NS). Statistical analysis failed to demonstrate differences in the extent of defect fill (mean difference: 0.3 mm, S.E. diff: 0.3 mm, 95% CI: -1.0 to + 0.4 mm, P = 0.34). In the group treated with bone graft material and membrane, a total of 15 implants (51.7 %) had a defect fill \geq 1.8 mm. In the group treated with bone graft alone, a total of 12 implants (44.4 %) gained more than 1.8 mm in defect fill.

When the data were dichotomized in regards to change in the number of exposed threads as a gain if bone or bone fill could be identified at one or more previously exposed threads, or if no change had occurred or if one or more additional threads had been exposed three years after intervention statistical analysis (Pearson's χ^2) failed to demonstrate differences in gain /loss of thread exposure by surgical treatment modality (p = 0.89). The distribution of bone level changes in the two study groups between baseline and year three after surgery are presented (Table 2). Statistical analysis failed to demonstrate differences in the extent of defect fill both in regards to number of threads filled and defect fill in mm by study group assignment.

The distribution of bone level changes in the two study groups between baseline and year three after surgery are presented (Table 3).

Analysis by Mann-Whitney U test failed to demonstrate a difference in bone fill between year one and year three between the two study groups ($P = 0.36$). Within each study group related samples Wilcoxon signed rank test failed to demonstrate a difference in bone fill between year one and year three in the group receiving bone graft alone ($P = 0.18$), or in the group treated with bone fill and membrane ($P = 0.42$). Bone fill mean values, SD, and range of fill are presented (Table 4).

Non-parametric Wilcoxon test identified that plaque index continued to improve between year one and year three after surgery ($p = 0.02$). Statistical analysis (Mann-Whitney U test) failed to demonstrate differences in this change of plaque scores by intervention ($p = 0.43$). The distributions of changes in the mean % plaque scores at various time points up to year three are presented (Figure 4).

Examples of treatment outcome at year three

Background clinical information and radiographs from before treatment of peri-implantitis and at year three are presented for one selected case defined as a non-responding case, and from one case defined as successfully treated (Table 5). Intra-oral radiographs taken immediately before and at three years after surgical treatment of peri-implantitis representing a non responding treatment outcome (Figure 5A and 5B) and a successfully treated case (Figure 6A and 6B) are shown. In these cases, the immediate postoperative wound healing was uneventful. The maintenance

protocol was highly effective as illustrated by the low plaque scores during the study period.

Discussion

In a previous report, one-year data following surgical treatment of peri-implantitis using a bone graft substitute demonstrated that the clinical conditions and radiographic conditions had improved (Roos-Jansåker et al.2007a). These results had occurred in spite of the fact that a majority of the subjects included were smokers, and with a past history of periodontitis (Roos-Jansåker et al. 2007a). It has previously been discussed that a smoking history and having a history of periodontitis can negatively influence the outcome of surgical treatment and reconstruction of defects around dental implants (Roos-Jansåker et al. 2006b, Karoussis et al. 2004, Máximo et al. 2008). Smoking has also been considered as a risk factor during wound healing following implant placement (Sadig & Almas 2004). The fact that smoking may have a negative influence on regenerative procedures in the management of periodontitis is well established (Mayfield et al. 1998, Trombelli et al. 1997, Rosén et al. 1996, Tonetti et al.1995, Kornman & Roberson 2000). It is therefore of interest that also in smokers, the use of a bone graft material placed in bone defects around implants can remain stable also at three years after intervention. Our findings are consistent with results reported elsewhere using bone substitutes in a non smoking study population (Schwarz et al.2008).

Subjects with a history of periodontitis and specifically in men with dental implants appear to be at risk for peri-implantitis. A history of smoking may be of less significance as a risk factor for peri-implantitis (Koldslund et al. in press). In spite of the accrued risk factors in the present study population it should be emphasized that both surgical study modalities resulted in a successful three year outcome of surgical

1
2
3 treatment reestablishing bone fill around implants with a previous history of peri-
4
5 implantitis (2006).
6
7
8
9

10 The importance of plaque control after periodontal therapy and supportive therapy
11 has been described extensively (i.e. Nyman et al. 1975, 1977, Rosling 1983, Rosling
12 et al. 2001). In the present study the post-surgical management was focused on a
13 strict oral hygiene program that continued during the study. Thus, the overall average
14 plaque score at year three was very low. This may explain the good results reported.
15
16 In a previous study using non-surgical management of peri-implantitis it was not
17 possible to reach a similar oral hygiene level which in part may explain the less
18 favorable clinical outcome (Renvert et al 2009, Persson et al. 2010). It is possible that
19 the surgical intervention in this study resulted in an improved soft tissue architecture
20 after wound healing facilitating oral hygiene measures. This may, in part, explain the
21 differences in plaque control efficacy in the present surgical intervention study
22 compared to the non-surgical intervention reported in previous papers. Nevertheless,
23 other studies employing surgical intervention in non-smokers with peri-implantitis
24 reported higher plaque scores. However, they also reported a gradual deterioration of
25 results primary obtained (Schwarz et al. 2006a). Higher plaque scores than reported
26 in the present study have also been reported in a long term retrospective study
27 (Matarasso et al. 2010). Thus, the surgical procedure and the wound healing may not
28 be effective without good plaque control during the follow up period.
29
30
31
32
33
34
35
36
37
38
39
40
41
42
43
44
45
46
47
48
49
50
51

52 The present follow-up, three years after surgical intervention comparing a bone
53 substitute with or without the adjunct treatment with a resorbable membrane
54 demonstrated that the additional effort to obtain stability did no seem to result in
55 enhanced three year results as assessed by radiographs. Our results are consistent
56
57
58
59
60

1
2
3
4
5
6
7
8
9
10
11
12
13
14
15
16
17
18
19
20
21
22
23
24
25
26
27
28
29
30
31
32
33
34
35
36
37
38
39
40
41
42
43
44
45
46
47
48
49
50
51
52
53
54
55
56
57
58
59
60

with those reported from studies of experimental healing in dogs (Nociti et al. 2000), or in a non-human primate model (Schou et al. 2003). It is possible that the use of a bone graft with the additional placement of a membrane may be more efficient in specific bone lesions around implants (Schwarz et al. 2010). Although somewhat better results have been presented in a 10-year follow clinical trial using bone grafts with the adjunct use of resorbable membranes in comparison to not using such membranes, the clinical relevance appeared to be negligible (Nygaard-Østby et al. 2010). The study by Nygaard-Østby et al. (2010) also identified that the resolution of deep intra-bony periodontal defects requires a structured maintenance program emphasizing high oral hygiene standards.

In the present study, the extent of bone fill obtained at one year after surgical treatment using either a bone graft alone or bone graft and a resorbable membrane could be maintained up to three years after treatment. Thus, provided oral hygiene is excellent both procedures resulted in a clinically relevant defect fill. A pre-requisite for a successful treatment outcome might also be the anatomy of bone defect. A well defined crater-like defect might be the most reliable factor for stable conditions.

The limitation of using the radiographic assessment method used in the present study is obvious. The radiographic evaluation does not allow distinguishing between osseo-integration of the graft in direct contact to the implant, or if the bone graft simply remains as a defect fill. However in comparison to the one year results (Roos-Jansåker et al. 2007a) the present findings at three years demonstrated stable results without progression of bone loss. Our results are consistent with histological results obtained from animal studies demonstrating that hard tissue fill and osseo-

1
2
3 integration can occur in experimentally created defects around implants (Abushahba
4
5 et al. 2008). This would also be the result at implants previously exposed to an
6
7 infectious biofilm, and animal studies it has also been demonstrated that it is possible
8
9 to obtain re-osseointegration on previously infected implant surfaces (Alhag et al.
10
11 2008).
12
13
14
15
16

17 The two cases identified with the similar age and clinical conditions, albeit with
18
19 opposite gender represent examples of a successful and a non-successful treatment
20
21 outcome of circumferential advanced lesions at implants placed in the maxilla. Both
22
23 subjects had had a previous history of peri-implantitis at the same or other implants,
24
25 and both of them were former smokers. At the time of surgical intervention in the
26
27 study the clinical conditions were similar in both cases. The presences of
28
29 circumferential defects with a significant vertical component were in both cases
30
31 suitable for the assigned therapy. The study treatment was the same in both cases
32
33 using a bone graft material without membrane coverage. Both subjects complied with
34
35 the post-surgical instructions and maintained excellent oral hygiene. The differences
36
37 identified between the two cases were that the subject with a non-successful
38
39 outcome had a medical diagnosis of diabetes mellitus and clinical lack of keratinized
40
41 and attached mucosa at the buccal aspect of the implant in treatment. Furthermore,
42
43 the infection at the implant appeared to harbor pathogens that are commonly therapy
44
45 resistant. The present observations from these two cases and the observations made
46
47 should only be used to suggest further studies on the role of keratinized attached
48
49 tissues, systemic health, and local infection in relation to therapy in cases with peri-
50
51 implantitis.
52
53
54
55
56
57
58
59
60

1
2
3
4
5
6
7
8
9
10
11
12
13
14
15
16
17
18
19
20
21
22
23
24
25
26
27
28
29
30
31
32
33
34
35
36
37
38
39
40
41
42
43
44
45
46
47
48
49
50
51
52
53
54
55
56
57
58
59
60

In conclusion, defect fill obtained at one year after surgical treatment with a bone graft and membrane or with bone graft alone remain stable between one and three years in cases on maintenance care.

Acknowledgements

This project was supported by research foundations from the Public Dental Health Service, County of Skåne, Sweden and Kristianstad University, Sweden. We thank Mr. Nuray Güner, (MA, Medical Statistics, MSc, Engineering Physics), for the help with the statistics.

References

Abushahba, F., Renvert, S., Polyzois, I., & Claffey, N. (2008) Effect of grafting materials on osseointegration of dental implants surrounded by circumferential bone defects. An experimental study in the dog. *Clinical Oral Implants Research* **19**, 329-334.

Alhag M, Renvert S, Polyzois I, & Claffey N. (2008) Re-osseointegration on rough implant surfaces previously coated with bacterial biofilm: an experimental study in the dog. *Clinical Oral Implants Research* **19**, 182-187.

De Boever AL, De Boever JA. (2005) Guided bone regeneration around non-submerged implants in narrow alveolar ridges: a prospective long-term clinical study. *Clinical Oral Implants Research* **16**, 549-556.

Fiorellini, J.P., Kim, D.M., Nakajima, Y., & Weber, H.P. (2007) Osseointegration of titanium implants following guided bone regeneration using expanded polytetrafluoroethylene membrane and various bone fillers. *International Journal of Periodontics Restorative Dentistry* **27**, 287-294.

Fransson C, Wennström J, Tomasi C. & Berglundh T. (2009) Extent of peri-implantitis-associated bone loss. *Journal of Clinical Periodontology* **36**, 357-363.

Fransson, C., Tomasi, C., Pikner, S.S., Gröndahl, K., Wennström, J.L., Leyland, A.H & Berglundh, T. (2010) Severity and pattern of peri-implantitis-associated bone loss. *Journal of Clinical Periodontology* **37**, 442-448.

1
2
3
4
5
6
7
8
9
10
11
12
13
14
15
16
17
18
19
20
21
22
23
24
25
26
27
28
29
30
31
32
33
34
35
36
37
38
39
40
41
42
43
44
45
46
47
48
49
50
51
52
53
54
55
56
57
58
59
60

Karoussis, I.K, Müller, S, Salvi, G.E., Heitz-Mayfield, L.J.A., Brägger, U. & Lang, N.P. (2004) Association between periodontal and peri-implant conditions: a 10-year prospective study. *Clinical Oral Implants Research* **15**, 1-7.

Koldslund, O.C, Scheie, A.A & Aass, A.M. (2010) Prevalence of Peri-implantitis related to severity of disease with different degrees of bone loss. *Journal of Periodontology* **81**, 231-238.

Koldslund OC, Scheie AA, Aass AM. The association between selected risk indicators and severity of peri-implantitis using mixed model analyses. *Journal of Clinical Periodontology* 2010 Dec 15 (preprint)

Kornman, K. & Robertson, P. (2000) Fundamental principles affecting the outcomes of therapy for osseous lesions. *Periodontology 2000* **22**, 22-43.

Lang N.P, & Berglundh T (2011), Peri-implant diseases. Consensus report 7th European Workshop on Periodontology. *Journal of Clinical Periodontology*, (pre-online access)

Leonhardt, Å., Dahlen, G. & Renvert, S. (2003) Five-year clinical, microbiological, and radiographical outcome following treatment of peri-implantitis in man. *Journal of Periodontology* **74**, 1415-1422.

Máximo, M.B., de Mendonça, A.C., Alves, J.F., Cortelli, S.C., Peruzzo, D.C., & Duarte, P.M. (2008) Peri-implant diseases may be associated with increased time loading and generalized periodontal bone loss: preliminary results. *Journal of Oral Implantology* **34**, 268-273.

1
2
3 Matarasso, S., Rasperini, G., Iorio Siciliano, V., Salvi, G.E., Lang, N.P. & Aglietta, M.
4
5 A (2010) 10-year retrospective analysis of radiographic bone-level changes of
6
7 implants supporting single-unit crowns in periodontally compromised vs. periodontally
8
9 healthy patients. *Clinical Oral Implants Research* **21**, 898-903.

10
11
12
13 Mayfield, L., Söderholm, G., Hallström, H., Kullendorff, B., Edwardsson, S., Bratthall,
14
15 G., Brägger, U. & Attström, R. (1998) Guided tissue regeneration for treatment of
16
17 intraosseous defects using a bioabsorbable membrane. A controlled clinical study.
18
19 *Journal of Clinical Periodontology* **25**, 585-595.

20
21
22
23
24
25 Nociti, F.H. Jr., Caffesse, R.G., Sallum, E.A., Machado, M.A., Stefani, C.M., & Sallum,
26
27 A.W. (2000). Evaluation of guided bone regeneration and/or bone grafts in the
28
29 treatment of ligature-induced peri-implantitis defects: a morphometric study in dogs.
30
31 *Journal of Oral Implantology* **26**, 244-249.

32
33
34
35
36
37 Nygaard-Østby, P., Bakke, V., Nesdal, O., Susin, C., & Wikesjö, U.M. (2010)
38
39 Periodontal healing following reconstructive surgery: effect of guided tissue
40
41 regeneration using a bioresorbable barrier device when combined with autogenous
42
43 bone grafting. A randomized-controlled trial 10-year follow-up. *Journal of Clinical*
44
45 *Periodontology* **37**, 366-373.

46
47
48
49
50
51 Nyman, S., Rosling, B. & Lindhe, J. (1975) Effect of professional tooth cleaning on
52
53 healing after periodontal surgery. *Journal of Clinical Periodontology* **2**, 80-86.

54
55
56
57
58
59 Nyman, S., Lindhe, J. & Rosling, B. (1977) Periodontal surgery in plaque-infected
60
dentitions. *Journal of Clinical Periodontology* **4**, 240-249.

1
2
3
4
5
6
7
8
9
10
11
12
13
14
15
16
17
18
19
20
21
22
23
24
25
26
27
28
29
30
31
32
33
34
35
36
37
38
39
40
41
42
43
44
45
46
47
48
49
50
51
52
53
54
55
56
57
58
59
60

Persson, G.R., Samuelsson, E., Lindahl, C., & Renvert, S.(2010) Mechanical non-surgical treatment of peri-implantitis: a single-blinded randomized longitudinal clinical study. II. Microbiological results. *Journal of Clinical Periodontology* **37**, 563-573

Renvert, S., Roos-Jansåker, A.M., Lindahl, C., Renvert, H., & Persson, G.R (2007) Infection at titanium implants with or without a clinical diagnosis of inflammation. *Clinical Oral Implants Research* **18**, 509-516.

Renvert, S., Roos-Jansåker, A-M. & Claffey, N. (2008) Non surgical treatment of peri implant mucositis and peri-implantitis: a literature review. *Journal of Clinical Periodontology* **35** (Suppl. 8), 305-315.

Renvert, S., Samuelsson, E., Lindahl, C. & Persson, G.R. (2009) Mechanical non-surgical treatment of peri-implantitis: a double-blind randomized longitudinal clinical study. I: clinical results. *Journal of Clinical Periodontology* **36**, 604-609.

Renvert S., Polyzois J., Claffey N. (2011) How do implant characteristics influence peri-implant disease. *Journal of Clinical Periodontology* (pre-online access).

Romanos, G.E., & Nentwig, G.H.(2008) Regenerative therapy of deep peri-implant infrabony defects after CO2 laser implant surface decontamination. *International Journal of Periodontics Restorative Dentistry*. **28**, 245-255.

Romeo, E., Ghisolfi, M., Murgolo, N., Chiapasco, M., Lops, D., & Vogel, G. (2005) Therapy of peri-implantitis with resective surgery. A 3-year clinical trial on rough

1
2
3 screw-shaped oral implants. Part I: clinical outcome. *Clinical Oral Implants Research*
4
5 **16**, 9-18.
6
7

8
9 Rosling, B. (1983) Periodontally treated dentitions: their maintenance and prognosis.
10
11 *International Dental Journal* **33**, 147-151.
12
13

14
15
16 Rosling, B., Serino, G., Hellström, M.K., Socransky, S.S. & Lindhe, J. (2001)
17
18 Longitudinal periodontal tissue alterations during supportive therapy. Findings from
19
20 subjects with normal and high susceptibility to periodontal disease. *Journal of Clinical*
21
22 *Periodontology* **28**, 241- 249.
23
24

25
26
27
28 Roos-Jansåker, A-M., Lindahl, C., Renvert, H. & Renvert, S. (2006a) Nine - to
29
30 fourteen- year follow-up of implant treatment. Part II. presence of peri-implant lesions.
31
32 *Journal of Clinical Periodontology* **33**, 290-295.
33
34

35
36
37 Roos-Jansåker, A-M., Lindahl, C., Renvert, H. & Renvert, S. (2006b) Nine - to
38
39 fourteen- year follow-up of implant treatment. Part III. factors associated with peri-
40
41 implant lesions. *Journal of Clinical Periodontology* **33**, 296-301.
42
43

44
45
46 Roos-Jansåker, A-M., Renvert, H., Lindahl, H. & Renvert, S. (2007a) Surgical
47
48 treatment of peri-implantitis using a bone substitute with or without a resorbable
49
50 membrane: a prospective cohort study. *Journal of Clinical Periodontology* **34**, 625-
51
52 632.
53
54
55
56
57
58
59
60

1
2
3
4
5
6
7
8
9
10
11
12
13
14
15
16
17
18
19
20
21
22
23
24
25
26
27
28
29
30
31
32
33
34
35
36
37
38
39
40
41
42
43
44
45
46
47
48
49
50
51
52
53
54
55
56
57
58
59
60

Roos-Jansåker, A-M., Renvert, H., Lindahl, H. & Renvert, S. (2007b) Submerged healing following surgical treatment of peri-implantitis: a case series. *Journal of Clinical Periodontology* **34**, 723-727.

Rosen, P.S., Marks, M.H., & Reynolds, M.A. (1996) Influence of smoking on long-term clinical results of intrabony defects treated with regenerative therapy, *Journal of Periodontology* **67**, 1159-1163.

Sadig, W. & Almas, K. (2004) Risk factors and management of dehiscant wounds in implant dentistry. *Implant Dentistry* **13**, 140-147.

Schwarz, F., Bieling, K., Latz, T., Nuesry, E. & Becker, J. (2006a) Healing of intrabony peri-implantitis defects following application of a noncrystalline hydroxyapatite (Ostim™) or a bovine-derived xenograft (Bio-Oss™) in combination with a collagen membrane (Bio-Gide™). A case series. *Journal of Clinical Periodontology* **33**, 491-499.

Schwarz, F., Bieling, K., Nuesry, E., Sculean, A., Becker, J. (2006b) Clinical and histological healing pattern of peri-implantitis lesions following non-surgical treatment with an Er:YAG laser. *Lasers Surgery in Medicine* **38**, 663-671.

Schwarz, F., Herten, M., Sager, M., Bieling, K., Sculean, A., Becker, J (2007). Comparison of naturally occurring and ligature-induced peri-implantitis bone defects in humans and dogs. *Clinical Oral Implants Research* **18**, 161-170.

Schwarz, F., Sculean, A, Bieling, K., Ferrari, D., Rothamel, D. & Becker, J. (2008) Two-year clinical results following treatment of peri-implantitis lesions using nanocrystalline hydroxyapatite or natural bone mineral in combination with a collagen membrane. *Journal of Clinical Periodontology* **35**, 80-87.

Schwarz, F., Sahm, N., Bieling, K. & Becker, J. (2009) Surgical regenerative treatment of peri-implantitis lesions using a nanocrystalline hydroxyapatite or a natural bone mineral in combination with a collagen membrane: a four-year clinical follow-up report. *Journal of Clinical Periodontology* **36**, 807-814.

Schwarz, F., Sahm, N., Schwarz, K., & Becker, J. (2010) Impact of defect configuration on the clinical outcome following surgical regenerative therapy of peri-implantitis. *Journal of Clinical Periodontology* **37**, 449-455.

Schou, S., Holmstrup, P., Skovgaard, L.T., Stoltze, K., Hjørting-Hansen, E., & Gundersen, HJ.(2003) Autogenous bone graft and ePTFE membrane in the treatment of peri-implantitis. II. Stereologic and histologic observations in cynomolgus monkeys. *Clinical Oral Implants Research* **14**, 404-411.

Shibli, J.A., Melo, L., Ferrari, D.S., Figueiredo, L.C., Faveri, M. & Feres, M. (2008) Composition of supra- and subgingival biofilm of subjects with healthy and diseased implants. *Clinical Oral Implants Reserach*.**19**, 975-982.

Tonetti, M.S., Pini-Prato, G., & Cortellini, P. (1995) Effect of cigarette smoking on periodontal healing following GTR in infrabony defects. A preliminary retrospective study. *Journal of Clinical Periodontology* **22**, 229-234.

1
2
3
4
5
6
7
8
9
10
11
12
13
14
15
16
17
18
19
20
21
22
23
24
25
26
27
28
29
30
31
32
33
34
35
36
37
38
39
40
41
42
43
44
45
46
47
48
49
50
51
52
53
54
55
56
57
58
59
60

Trombelli, L., Kim, C.K., Zimmerman, G.J., & Wikesjö, U.M.E. (1998) Retrospective analysis of factors related to clinical outcome of guided tissue regeneration procedures in intrabony defects. *Journal of Clinical Periodontology* **24**, 366-371.

Wiltfang, J., Zernial, O., Behrens, E., Schlegel, A., Warnke, P.H., & Becker, .S.T (2010). Regenerative Treatment of Peri-Implantitis Bone Defects with a Combination of Autologous Bone and a Demineralized Xenogenic Bone Graft: A Series of 36 Defects. *Clinical Implant Dentistry Related Research*.**21**, (in press).

Zitzmann, N.U., & Berglundh, T.(2008). Definition and prevalence of peri-implant diseases.*Journal of Clinical Periodontology* **35** (8 Suppl), 286-291.

Table 1

Subject characteristics at study baseline (IDDM: diabetes mellitus)

	Bone graft only including 15 subjects	Bone graft and membrane including 17 subjects
Age	Mean: 65.6 S.D.: 7.4 Range: 54-76	Mean: 66.3 S.D.: 6.7 Range: 55-79
Gender	Female: 57.9 %	Female: 58.8 %
Years of education	Mean: 9.3 S.D.: 3.6 Range: 6-17	Mean: 9.1 S.D.: 2.7 Range: 6-15
Systemic conditions	Health: 64.7 % IDDM: 5.9 % Heart disease: 17.6 % Other: 11.8 %	Health: 52.6 % IDDM: 10.5 % Heart Disease: 15.8 % Other: 21.1 %
Current smokers	68.4 %	70.6 %
Never smoked	10.5 %	5.9 %
Number of smoke years	Mean: 40.5 S.D.: 12.0 Range: 0 - 57	Mean: 38.6 S.D.: 15.9 Range: 0 - 62
Tooth loss	Unknown: 43.8 % Periodontitis: 56.3 %	Unknown: 50.0 % Periodontitis: 50.0 %
Teeth	Edentulous maxilla: 94.1 % Edentulous mandible: 41.4 % Total edentulous: 52.9 %	Edentulous maxilla: 78.9 % Edentulous mandible: 26.3 % Total edentulous: 36.8 %
% bone loss at teeth if present	Mean: 69.5 % S.D.: 27.8 % Range: 33-88 %	Mean: 69.3 % S.D.: 35.5 % Range: 21- 88 %

Table 2.
Defect changes between baseline and year three after surgery (implant level).

Bone level change (mm)	Bone graft and membrane including 29 implants		Bone graft alone including 27 implants	
	Number	%	Number	%
-1.2	0	0	1	4
-0.6	2	7	2	7
0.0	3	10	4	15
0.6	2	7	3	11
1.2	4	14	5	18
1.8	6	21	4	15
2.4	5	17	2	7
3.0	5	17	4	15
3.6	0	0	2	7
4.2	2	7	0	0

Table 3.
Defect changes between year one and year three of follow -up after surgery (implant level).

Bone level change (mm)	Bone graft and membrane including 29 implants		Bone graft alone including 27 implants	
	Number	%	Number	%
-1.8	1	3	0	0
-1.2	0	0	0	0
-0.6	1	3	1	4
0.0	21	73	24	89
0.6	3	10	0	0
1.2	2	7	1	4
1.8	1	3	0	0
2.4	0	0	1	4

1
2
3
4
5
6
7
8
9
10
11
12
13
14
15
16
17
18
19
20
21
22
23
24
25
26
27
28
29
30
31
32
33
34
35
36
37
38
39
40
41
42
43
44
45
46
47
48
49
50
51
52
53
54
55
56
57
58
59
60

Table 4

Results of treatment at the implant level observed after three years compared to one year for implants treated with bone graft and membrane, or bone graft alone.

Variable	Bone graft and membrane			Bone graft alone		
	Mean	S.D.	Range	Mean	S.D.	Range
Defect fill (number of threads)	0.2	± 0.9	2.5:-3.0	0.2	± 0.8	3.5:-1.0
Defect fill (mm)	0.1	± 0.5	1.5:-1.8	0.1	± 0.5	2.1:-0.6

Table 5.

Characteristic findings for two cases illustrating either a non-responding or a responding outcome of surgical treatment of peri-implantitis, and with an observation period of three years.

Variables	Non responding case	Responding case
Gender and age	Male, 68 years	Female, 69 years
Medical /smoking	Diabetes mellitus (type II), former smoker	No systemic diseases reported former smoker
Periodontal therapy	No case history	Periodontal therapy in the past
Peri-implantitis	Previous treatment at other implants	Previous treatment for peri-implantitis at this location
Implant(location and years in function	14, 10 years	24; 5 years
Probing pocket depth	mes: 4 mm, buc: 4mm dist:4 mm, pal:4 mm	mes: 6 mm, buc: 5mm dist:5 mm, pal:6 mm
Bone sounding	mes: 7 mm, buc: 8 mm dist: 8 mm, pal: 6 mm	mes: 10 mm, buc: 12 mm dist: 10 mm, pal: 11 mm
Surgical procedure	Open flap debridement with Algipore ® treatment without membrane technique, antibiotic coverage	Open flap debridement with Algipore ® treatment without membrane technique, antibiotic coverage
Baseline thread exposure (xray)	mes: 6 threads and dist: 6 threads	mes: 4 threads and dist: 5 threads
Threads exposed at surgery	mes:6, buc:7 dist:7, pal:7	mes: 3, buc:6, dist:6, pal:7
Horizontal destruction at surgery	mes 3 mm, buc: 5 mm dist:2 mm, pal:5 mm	mes:0 mm, buc:5 mm, dist: 0 mm, pal: 3mm
Vertical destruction assessed at surgery (depth)	mes:2 mm, buc: 0 mm dist:3 mm, pal: 0 mm circumferential	mes: 3 mm buc:0 mm, dist: 1 mm, pal: 2 mm circumferential
Year 3 mesial thread exposure (xray)	6	0
Year 3 distal thread exposure (xray)	6	0
Buccal mucosa baseline	non keratinized, no change to year 3	keratinized 3 mm, no change to year 3
Mucosal recession baseline	Buccal: 4 mm, Pal:2 mm	
Bacterial findings at the time of surgery	Enterococci positive Antibiotic resistance consistent with Pseudomonas infection	<i>S.epidermis</i> , <i>F.nucleatum</i> , <i>S.sanguinis</i>
Bacterial findings at year 3	negative	negative
Oral hygiene	Excellent, plaque scores on average < 10%	Excellent plaque scores on average < 10 %

1
2
3
4
5
6
7
8
9
10
11
12
13
14
15
16
17
18
19
20
21
22
23
24
25
26
27
28
29
30
31
32
33
34
35
36
37
38
39
40
41
42
43
44
45
46
47
48
49
50
51
52
53
54
55
56
57
58
59
60

Legends

Figure 1.

CONSORT flowchart

Figure 2

Examples of radiographs taken from one subject at baseline, year one, and year 3 after follow-up.

Figure 3

Example of radiographs taken from another subject at baseline, year one, and year 3 after follow-up.

Figure 4

Mean plaque index from baseline to 3 years in Group 1 (bone graft substitute + membrane) and Group 2 (bone graft substitute).

Figure 5A

Baseline radiograph illustrating the alveolar bone conditions at the implant (replacing tooth 24) at a non-responding defect. Notice the number of implant threads not supported by bone and the crater defect. Clinical details are presented in table 5.

Figure 5B

Radiograph from year three after surgical intervention and placement of bone graft material illustrating the alveolar conditions at the implant (replacing tooth 24) at a non-responding defect, and similar extent of bone defect and implant threads exposed as at baseline. Notice the number of implant threads not supported by bone and the crater defect. Clinical details are presented in table 5.

Figure 6 A

Intra-oral radiograph from baseline illustrating the alveolar bone conditions at the implant (replacing tooth 14). Notice the number of implant threads not supported by bone and the crater defect. Clinical details are presented in table 4. The opaque area visible on the radiograph is part of the stent used to standardize the positioning before image exposure.

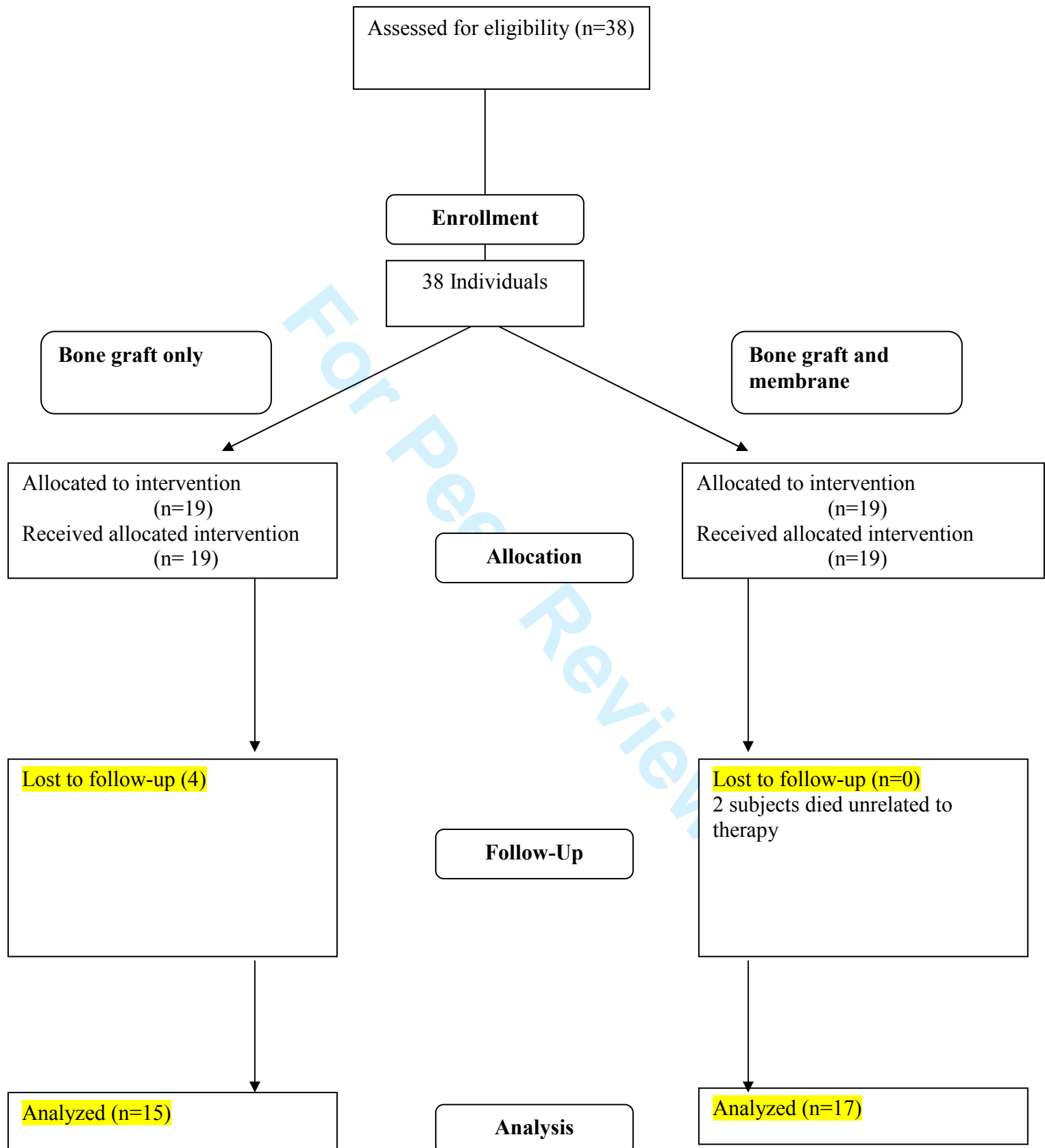
Figure 6B

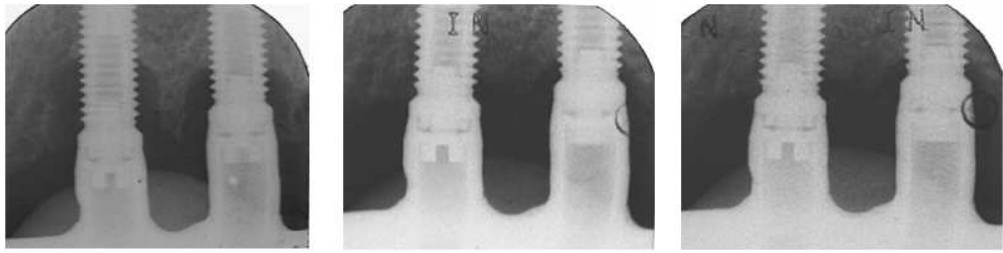
Radiograph from year three after surgical intervention and placement of bone graft material illustrating the alveolar conditions at the implant (replacing tooth 14), and in principle complete fill of crater defect with bone fill material used. Notice that no threads are exposed. Clinical details are presented in table 5. The image suggests

1
2
3
4
5
6
7
8
9
10
11
12
13
14
15
16
17
18
19
20
21
22
23
24
25
26
27
28
29
30
31
32
33
34
35
36
37
38
39
40
41
42
43
44
45
46
47
48
49
50
51
52
53
54
55
56
57
58
59
60

that the lesion has been filled with radiopaque material and this should not be interpreted as bone regeneration or “osseo-integration”.

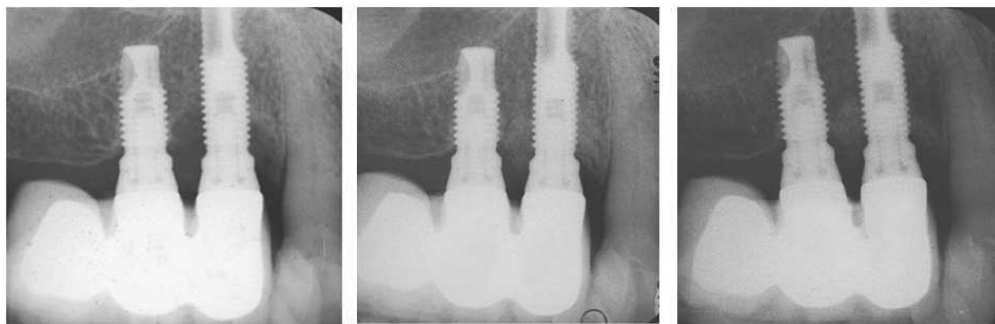
For Peer Review





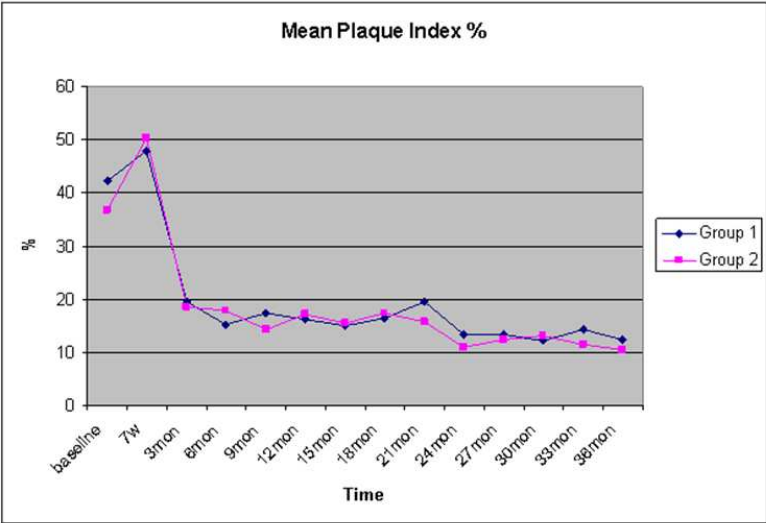
Examples of radiographs taken from one subject at baseline, year one, and year 3 after follow-up.

For Peer Review

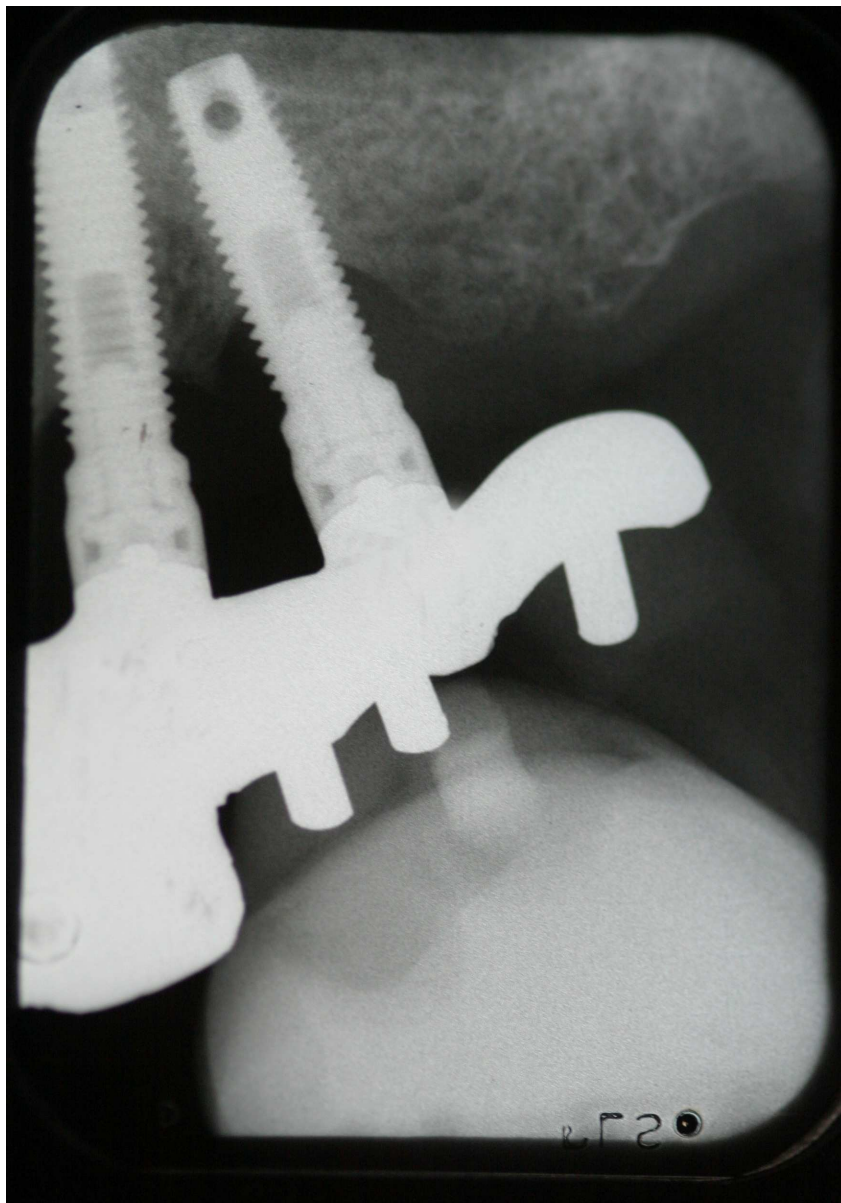


Example of radiographs taken from another subject at baseline, year one, and year 3 after follow-up.

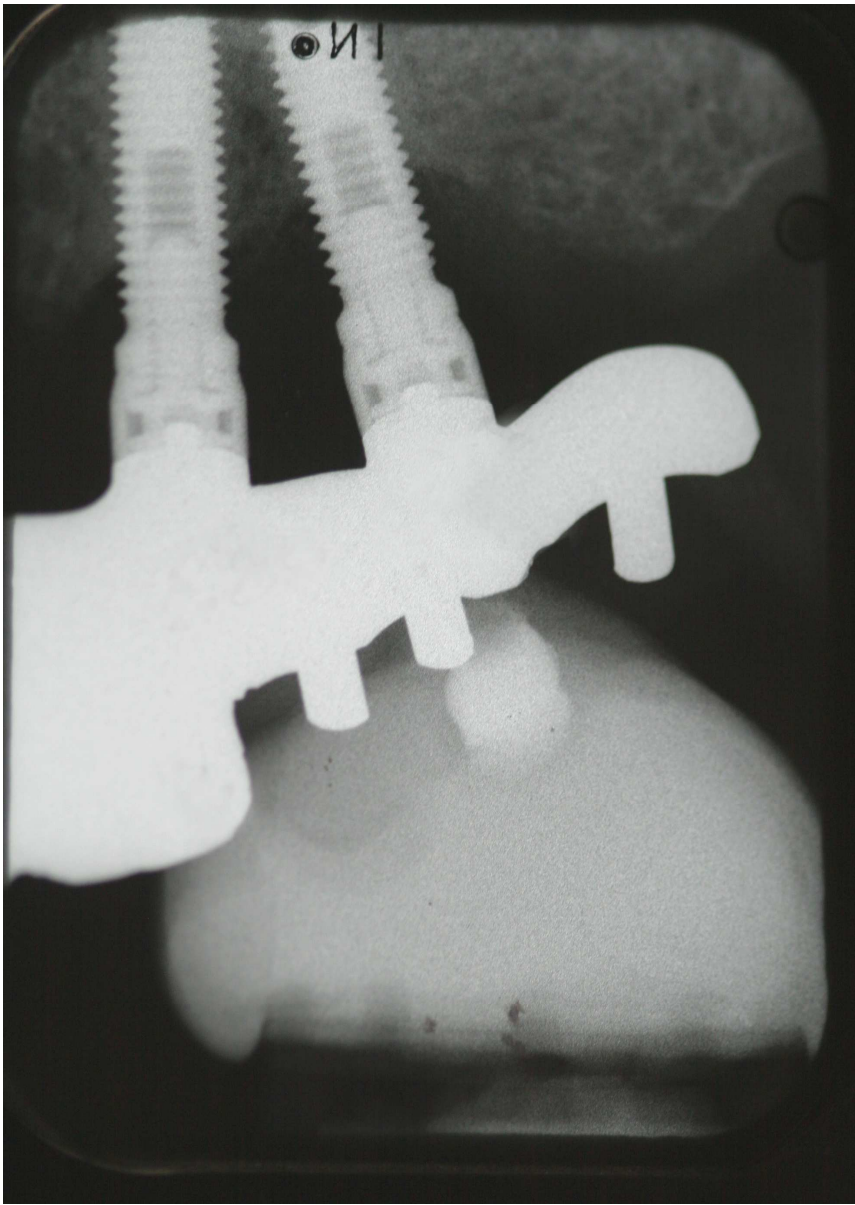
Or Peer Review



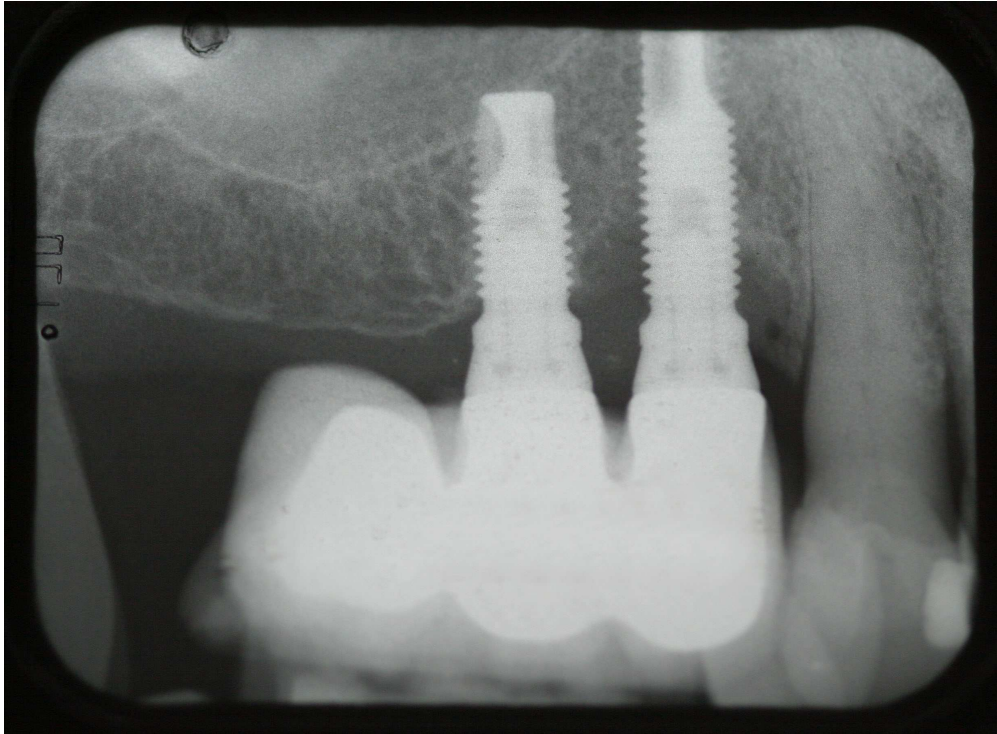
Mean plaque index from baseline to 3 years in Group 1 (bone graft substitute + membrane) and Group 2 (bone graft substitute).



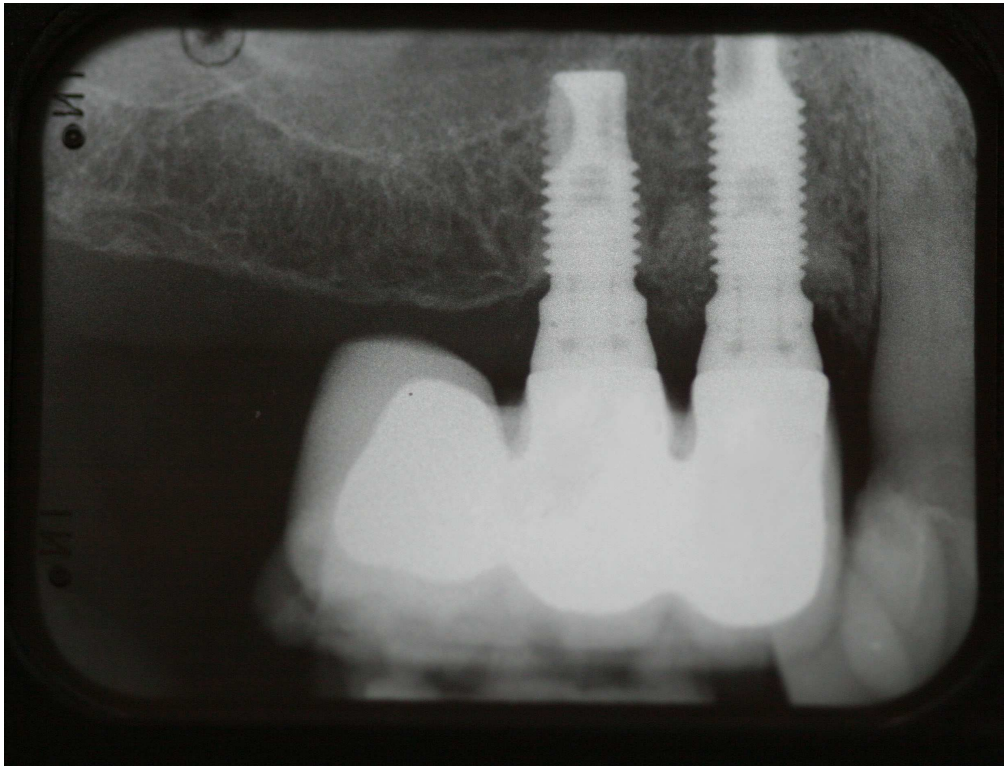
Baseline radiograph illustrating the alveolar bone conditions at the implant (replacing tooth 24) at a non-responding defect. Notice the number of implant threads not supported by bone and the crater defect. Clinical details are presented in table 5.



Radiograph from year three after surgical intervention and placement of bone graft material illustrating the alveolar conditions at the implant (replacing tooth 24) at a non-responding defect, and similar extent of bone defect and implant threads exposed as at baseline. Notice the number of implant threads not supported by bone and the crater defect. Clinical details are presented in table 5.



Intra-oral radiograph from baseline illustrating the alveolar bone conditions at the implant (replacing tooth 14). Notice the number of implant threads not supported by bone and the crater defect. Clinical details are presented in table 4. The opaque area visible on the radiograph is part of the stent used to standardize the positioning before image exposure.



Radiograph from year three after surgical intervention and placement of bone graft material illustrating the alveolar conditions at the implant (replacing tooth 14), and in principle complete fill of crater defect with bone fill material used. Notice that no threads are exposed. Clinical details are presented in table 5. The image suggests that the lesion has been filled with radiopaque material and this should not be interpreted as bone regeneration or “osseo-integration”.