



**HAL**  
open science

## **Preparing pathology for personalized medicine: possibilities for improvement of the pre-analytical phase.**

Patricia Jta Groenen, Willeke A Blokx, Coos Diepenbroek, Lambert Burgers,  
Franco Visinoni, Pieter Wesseling, Han van Krieken

### ► **To cite this version:**

Patricia Jta Groenen, Willeke A Blokx, Coos Diepenbroek, Lambert Burgers, Franco Visinoni, et al.. Preparing pathology for personalized medicine: possibilities for improvement of the pre-analytical phase.. *Histopathology*, 2011, 59 (1), pp.1. 10.1111/j.1365-2559.2010.03711.x . hal-00630795

**HAL Id: hal-00630795**

**<https://hal.science/hal-00630795>**

Submitted on 11 Oct 2011

**HAL** is a multi-disciplinary open access archive for the deposit and dissemination of scientific research documents, whether they are published or not. The documents may come from teaching and research institutions in France or abroad, or from public or private research centers.

L'archive ouverte pluridisciplinaire **HAL**, est destinée au dépôt et à la diffusion de documents scientifiques de niveau recherche, publiés ou non, émanant des établissements d'enseignement et de recherche français ou étrangers, des laboratoires publics ou privés.



**Preparing pathology for personalized medicine: possibilities for improvement of the pre-analytical phase.**

Journal:	<i>Histopathology</i>
Manuscript ID:	HISTOP-08-10-0429
Wiley - Manuscript type:	Review
Date Submitted by the Author:	06-Aug-2010
Complete List of Authors:	Groenen, Patricia; Radboud University Nijmegen Medical Centre, Pathology Blokx, Willeke; Radboud University Nijmegen Medical Centre, Pathology Diepenbroek, Coos; Radboud University Nijmegen Medical Centre, Pathology Burgers, Lambert; Radboud University Nijmegen Medical Centre, Pathology Visinoni, Franco; Milestone s.r.l. Wesseling, Pieter; Radboud University Nijmegen Medical Centre, Pathology van Krieken, Han; Radboud University Nijmegen Medical Centre, Pathology
Keywords:	tissue , molecular pathology , fixation, pre-analytical tissue processing, immunohistochemistry

SCHOLARONE™  
Manuscripts

Title and Author's names:

**Preparing pathology for personalized medicine: possibilities for improvement of the pre-analytical phase.**

Patricia J.T.A. Groenen, Willeke A.M. Blokk, Coos Diepenbroek, Lambert Burgers, Franco Visinoni<sup>1</sup>, Pieter Wesseling, J. Han J.M. van Krieken.

Dept. of Pathology, Radboud University Nijmegen Medical Centre, the Netherlands

<sup>1</sup>Milestone s.r.l., Italy

**Address for correspondence:**

Patricia J.T.A. Groenen, PhD

824 Dept. of Pathology

Radboud University Nijmegen Medical Centre

P.O. Box 9101

6500 HB Nijmegen

The Netherlands

E-mail: P.Groenen@pathol.umcn.nl

Fax: + 31 (0) 24 366 8750

**Running title:** The pre-analytical phase in Pathology

**Keywords:** tissue, fixation, molecular pathology, pre-analytical tissue processing, immunohistochemistry

**Abstract**

With the introduction of new biological agents for cancer treatment enabling “personalized medicine”, treatment decisions based on the molecular features of the tumor are increasingly common. Consequently, tissue evaluation in tumour pathology is becoming more and more based on a combination of classical morphological and molecular analysis. Results of diagnostic tests rely not only on the quality of the method used but to a large extent also on the quality of specimens which is dependent on the pre-analytical procedures and storage. With the introduction of predictive immunohistochemical and molecular tests in clinical pathology, improvement and standardization of pre-analytical procedures has become crucial. The aim of this review is to increase awareness for tissue handling, for standardization of the pre-analytical phase of a diagnostic process and to address several processing steps in tissue handling that need to be improved in order to obtain the quality needed for modern molecular medicine. Optimal, standardized procedures are crucial to reach a high standard of test results, which is what each patient deserves.

**Keywords:** tissue, fixation, molecular pathology, pre-analytical tissue processing, immunohistochemistry

## Introduction

Tissue evaluation by pathologists is a critical issue for establishing a final diagnosis and prognosis for a patient suspected of having cancer. Before the year 2000, the pathological diagnosis of tumours was mainly based on morphological analysis (including immunohistochemistry and electron microscopy). In the last decade, the knowledge about the pathogenesis and molecular background of many types of cancer has drastically increased. As a result, cancer diagnostics is nowadays more complex and requires molecular tests, such as assessment of microsatellite instability for identifying cases that have increased risk for Lynch syndrome (1-3), the detection of clonality in the diagnosis of lymphoma (4-7), of chromosomal translocations and aberrations in sarcomas and glioblastoma, respectively (8-12). The main driver of change in this diagnostic process has been the arrival of drug therapies targeting specific molecular aspects of tumors ('targeted therapy'), such as Trastuzimab, targeting the *HER2/neu* oncogene in patients with breast cancer (13,14) and a plethora of other receptor tyrosine kinase inhibitors. These specific targeted therapies require implementation of additional and more complex molecular genotyping tests, such as analysis of the genes *EGFR* and *KRAS*, *KIT* and *PDGFRA*, *BRAF* and *NRAS*, in patients with respectively colorectal and lung cancer (15-18), gastrointestinal stromal tumors (19-21), and melanoma (22,23), thereby allowing truly 'personalized' therapeutic decision-making.

Obviously, an optimal tissue diagnosis requires optimal material. Many methods used in pathology are more than 100 years old and are well suited for diagnosis based on morphology, however when performed under non-controlled conditions these methods can be detrimental for molecular pathology. Results of diagnostic tests, particularly molecular tests, are not only determined by the quality of the diagnostic

methods but to a large extent by the many tissue handling steps in the pre-analytical phase as well. A controlled and standardized handling in the pre-analytical phase, will lead to a more accurate and thus more optimal pathology diagnostics, which should become available for each patient.

### **The pre-analytical phase in clinical pathology**

The handling and pre-treatment of tissue specimens during transport to the laboratory as well as within the pathology laboratory clearly affects the quality of the tissue, and the proteins (including nucleic acids) therein, as depicted in Figure 1.

*Transport* of tissues from the operating room to the pathology lab is an important step. In many hospitals, the excised tissues are delivered fresh and 'dry', or in case of small specimens immersed in saline (0.9%) in "dry containers", and stored at room temperature. Often however, biopsies and even organs are immersed in formalin, in operation theatres that are not suited for this toxic agent (see below). Delays in transport may explain why DNA or RNA may be degraded (24). Antigen stability detected by immunohistochemistry may also decrease after warm ischemia (25,26). Grossing and dissection is performed within the pathology lab by highly qualified personnel, trained in selection and cutting the tissue into representative parts for microscopic and molecular analysis (23,26).

*Fixation* is the most critical step in the pre-analytical phase. Formalin is commonly used in pathology laboratories. Formalin is however toxic and potentially carcinogenic (28). By chemical crosslinking of proteins and nucleic acids, formalin results in fragmentation of nucleic acids (29-31), thereby hampering molecular analysis. The usual practice in traditional histopathology, is fixation in neutral-buffered formalin for 12-24 hr, which gives a good sample preservation for morphologic evaluation. Small-

sized tissue specimens and short fixation times (8 hrs in formalin, ref: 32) are the best conditions to preserve DNA and RNA, while maintaining good morphology. Too short fixation times may render the tissue insufficiently protected against the continuous enzymatic degradation and leads to suboptimal morphology, while prolonged fixation may lead to severe degradation of nucleic acids. Too short or too long fixation time will also compromise the result of immunohistochemical stainings (33-37). Note that neutral-buffered formalin fixation is preferred over un-buffered formalin, which results more severe degradation of DNA/RNA (38-40).



Fig.1

*Tissue processing*, which involves dehydration, clearing and paraffin-embedding is the last critical step in the pre-analytical phase. Traditionally, tissue processing occurs in a vacuum infiltrating tissue processor, which occurs normally during the night. Xylene is commonly used as clearing agent, to remove the dehydrant (usually a series of alcohol concentrations) from the tissue, however xylene is hazardous. Isopropanol (41), a solvent based on long chain aliphatic hydrocarbons or limonene can be used as an alternative, although these are less effective (41). In addition, limonene-based solvent is capable of inducing dermatitis and allergic reactions (42,43). Progress in automation of systems, and the introduction of microwave-based technology using strictly defined protocols resulted in fast, standardized tissue processing (44-48, Burgers *et al.*, manuscript in prep.). Currently, however, multiple protocols for transport, fixation and histo-processing are still being used in different pathology labs. This lack of standardization substantially affects the accuracy of specific test results, which is exemplified by a study by American pathologists. In this study, the presence of human epidermal growth factor receptor 2 (HER2), under different conditions by different techniques was evaluated (49) and resulted in (ASCO and CAP joint) guidelines to improve hormone receptor testing.

## Possibilities for improvement of modern pathology

### *Tissue preservation*

The increased need for well-preserved tissues has stimulated interest in alternative preservative liquids. In some hospitals, outside the laboratory environment, the fresh excised unfixed tissues are immersed in mild isotonic media (like RPMI) or solutions with specific salts (HANKS) with bovine or calf serum added to it, saline (0,9%), kept at 4-8°C and transported to the pathology laboratories. Although a cell culture medium has a good preservation quality in terms of morphology and molecular analysis, the media are very expensive especially in case of large diagnostic specimens (e.g. resection specimens from breast, colon), not standardised (because of the variability of the serum), and therefore not recommended. *Bens Michel's liquid* is currently used in nephropathology and dermatopathology allowing adequate preservation of the sample to stay in this liquid at room temperature up till 24 to 48 hours before performing immunofluorescence on frozen tissue with good reproducibility (50). However, the use of Michel's fixative and PBS results in low quantities and purity of extracted DNA (51). Normal saline has been described for preservation of nucleic acids (52), however the histomorphology is not well preserved.

Tissue transfer to pathology laboratories in under-vacuum conditions is a safe alternative compared to tissue transfer in formalin (44). Preservation under vacuum is particularly suitable for large surgical specimens. Immediately after removal, the specimens are put in specialized plastic bags. After creating vacuum and sealing of the bag that only takes approximately 15 seconds, the specimen can be stored in a refrigerator for up to 48 hours and subsequently transferred to the pathology lab. The morphology of the tissue is well preserved. Also the quality of RNA-preservation,



even in tissues kept in the fridge under vacuum for long time, is of acceptable quality (53). Importantly, since there is no immersion of the whole specimen in formalin, this is a first step into an environmentally-safe step towards a formalin-free hospital (54). Vacuum-based preservation of surgical specimens also allows collection of “fresh” material, which is recommended for optimal molecular analysis. Currently, molecular tests for detection of oncogenic mutations, such as mutations in the *KRAS* gene for colon carcinoma, *KRAS-EGFR* for lung carcinoma, *KIT- PDGFRA* for gastro-intestinal stromal tumor and *BRAF-NRAS-HRAS* gene mutations for melanoma, routinely occur on DNA-extracted from FFPE tissue. The reason is that the use of FFPE tissues relatively easy allows enrichment of the tumor cells, by dissection of a section part that contains predominantly tumor cells. However, one of the reasons why expression arrays have not (yet) entered our diagnostic armory is the problem of obtaining RNA of sufficient quality from FFPE tissues.

### *Fixation*

Formalin, which is in fact a solution of formaldehyde, is a world-wide used fixative, but has its disadvantages as describe above and results in the need for efficient ventilation and fume concentration monitoring. The development and use of alternative formalin-free “molecular” fixatives together with the elimination of xylene and formalin from the tissue processor was therefore undertaken by many. New types of fixatives are zinc (55,56), HOPE fixative (57) or alcohol-based (48,58,59) [such as Do-Path from Dentec (the Netherlands), RCL2 from Alphelys (France) and Fine-Fix from Milestone (Italy)] are being developed and have improved opportunities of nucleic acid analysis. However, the problem is that the morphology from tissues fixed in an alcohol-based fixative is different from that after formalin-tissue fixation. In

addition, in our hands, immuno-histochemical stains performed on alternatively fixed tissue lead to insufficient immuno-histochemical staining results (even after repeating the stainings without antigen retrieval, unpublished data: HvK, WB). Non-formalin based fixatives (such as GFT and Prefer) also compromised the FISH analysis of Her-2/neu oncogene amplification (60). Therefore, one needs to realise that changing the fixative will require adjustments of protocols for immuno-histochemistry and in situ hybridization (ISH), which are currently developed and optimised for formalin fixed tissue. Yet, changing from formalin to an alcohol-based fixative may be necessary in the next future since the International Agency of Research Cancer (IARC) has recognized formaldehyde as a (type 1) carcinogen in 2004. Indeed, there is evidence for a statistically significantly increased risk for mortality from myeloid leukemia (28). In the next years, we need to get prepared for a worldwide prohibition on the use of formalin in pathology and we have to invest in alternatives and optimize the methods for working with a new 'non-formalin' fixative.

Ultrasound-accelerated formalin fixation of tissues is a fast fixation method that may be applicable in short term. While in this procedure formalin is still used, this approach resulted in superior nucleic acid integrity and preservation of antigens compared to conventional methods (61). The highest RNA yield and quality were obtained by short fixation in buffered formalin (15 minutes) whilst being irradiated with high-frequency, high-intensity ultrasound. No differences with regards to the quality of histology and immunohistochemical staining were observed (62).

### *Tissue processing*

The trend to use molecular, non-formalin based fixatives with improved possibilities for molecular analysis coincides with the need of rapid fixation and processing of

tissues. The newest generation of fully-automated microwave based tissue processors is designed to speed up and standardize the fixation process (53,54). Moreover, instead of the toxic xylene, isopropanol is used as an intermediate solvent. There are only a few laboratories that have reported on the use of these microwave-based tissue processors in routine pathology. Indeed, the incorporation of microwave-based tissue processing clearly affects laboratory work patterns and reduces turnaround times. Importantly, the morphology is maintained or even is modestly improved (31,45-48,63,64, Burgers *et al.*, manuscript in prep.). The immunohistochemical stainings obtained after automated microwave-assisted rapid tissue processing method in general gave good results (46,48) although minor adjustments of the working concentrations of the antibodies may be beneficial to improve signal intensities (45). Also, in situ hybridization using probes for HPV, EBV and Her-2-neu gave good gene visualization using the microwave-processing (45). The application of microwave-stimulated tissue processing in the routine pathology setting also improves the possibilities for molecular testing (31, 59, 65).

## Outlook

The quality of the tissue specimen has to be optimal, to ensure optimal diagnostics. Why is it that not many pathology laboratories introduce standardized protocols or new technologies in tissue transfer, tissue-fixation or –processing? Clearly, changing working patterns in general is difficult. Introduction of new procedures requires changes in logistics and process automation, which may indeed be difficult at first glance. However, introduction of new pathology techniques will ameliorate the quality of the tissue specimens for further analysis. Not only for the current molecular analysis, but also for the future spectrum of technologies that will be needed for

analysis on tissue specimens that may become essential for diagnosis (such as assessment of the proteome, or the metabolome). Although several laboratories have reported the results on new 'non-formalin' fixatives or on microwave-assisted tissue processing, these studies are from only a few, specific tissues.

*What is the next step?*

Obviously, for development, testing and standardization of transport, fixation and histo-processing different readouts are essential. Our strategy to improve the pre-analytical pathology phase is to focus on transport conditions (under-vacuum versus transport in "dry containers, and testing different "storage" or transport times), subsequent fixation in pH-controlled formalin and an alcohol-based fixative, using different fixation times. Microwave-assisted histo-processing will be used, as this processing method has proven to be successful in multiple studies (31,45-48,63,64). In the first phase, it is important to test and evaluate large numbers of different tissue samples (e.g.: colon, lung, skin, brain, kidney, liver, heart, muscle, mammary carcinoma, sarcoma, lymphoma) and focus on evaluation of the histology of the specimens which should be done by several experienced pathologists.

The conditions that give good (acceptable) results, will be further investigated in the second phase of the study, where the focus is on immuno histochemistry (IHC), for a range of different proteins, both cytosolic as well as nuclear proteins. Adjustments in staining protocols will be necessary to optimize the staining results. Also antigen-retrieval protocols should be evaluated as this can confound IHC results.

The tissue specimens that guarantee optimal performance in histology and IHC under the different test conditions, will be evaluated for molecular techniques in the final testing phase. After testing and evaluation protocols for nucleic acid extraction, different molecular readouts should be analysed, e.g; mutation detection using PCR

and sequencing analysis of *KRAS* and *EGFR* genes in lung and colon carcinoma, Ig/TCR clonality assessment for lymphoma diagnostics, RT-PCR on extracted RNAs from sarcoma specimens. Also FISH should be evaluated, using probes for detection of oncogene amplification (Her2-neu), break-apart probes (for detection of chromosomal breaks) and RNA-ISH probe (EBER). A multicenter study using large numbers of different tissue specimens and readouts enabling statistical evaluation to show that the outcome is not laboratory dependent, will ultimately result in controlled and standardized protocols for tissue transport and fixation, enabling modern pathology evaluation.

Particular attention should be given to the diffusion of results and technology dissemination of standardized and validated protocols. Obviously, the new approaches need to be taught to pathology residents. In fact, pathologists, molecular biologist and residents engaged in modern pathology should have a leading role in the dissemination of the new standardized approaches, and thereby contribute to the improvement of modern (including 'molecular') medicine in order to maximize the benefit for patients suffering from oncologic disorders.

## Legend

Figure 1: The diagnostic process. Tissues obtained from patients undergo transport and tissue processing steps, including the handling steps during the pre-analytical phase in pathology laboratories, that affect the quality of the diagnostic tissue.

Analytical tests in oncology nowadays are often based on a combination of morphological and molecular analysis. Molecular tests are primarily PCR-based tests using different technological readouts, however, also array-technology and Next Generation Sequencing (NGS) technology (are) will be used. Both morphological and molecular analysis are needed to reach to a proper diagnosis that ideally not only carries prognostic but also predictive information.

## References

1. Mueller J, Gazzoli I, Bandipalliam P, Garber JE, Syngal S, Kolodner RD. Comprehensive molecular analysis of mismatch repair gene defects in suspected Lynch syndrome (hereditary nonpolyposis colorectal cancer) cases. *Cancer Res.* 2009; 69: 7053-61.
2. Overbeek LI, Ligtenberg MJ, Willems RW, *et al.* Interpretation of immunohistochemistry for mismatch repair proteins is only reliable in a specialized setting. *Am. J. Surg. Pathol.* 2008; 32: 1246-51.
3. Kievit W, de Bruin JH, Adang EM, *et al.* Cost effectiveness of a new strategy to identify HNPCC patients. *Gut.* 2005; 54: 97-102.
4. Van Dongen JJM, Langerak AW, Bruggemann M, *et al.* Design and standardization of PCR primers and protocols for detection of clonal immunoglobulin and T-cell receptor gene rearrangements in suspect lymphoproliferations. Report of the BIOMED-2 Concerted Action BMH4-CT98-3936. *Leukemia.* 2003; 17: 2257-317.
5. Evans PAS, Pott CH, Groenen PJTA *et al.* Significantly improved PCR-based clonality testing in B-cell malignancies by use of multiple immunoglobulin gene targets: Report of the BIOMED-2 Concerted Action BHM4-CT98-3936. *Leukemia.* 2007; 21: 207-14.
6. Bruggemann M, White H, Gaulard P *et al.* Powerful strategy for PCR-based clonality assessment in T-cell malignancies. Report of the BIOMED-2 Concerted Action BHM4-CT98-3936. *Leukemia.* 2007; 21: 215-21.
7. Groenen PJTA, Langerak AW, van Dongen JJM, van Krieken JHJM. Pitfalls in TCR gene clonality testing: Teaching cases. *J. Hematopathol.* 2008; 1: 97-109.

8. Yip S, Iafrate AJ, Louis DN. Molecular diagnostic testing in malignant gliomas: a practical update on predictive markers. *J. Neuropathol. Exp. Neurol.* 2008; 67: 1-15.
9. Jeuken JW, van der Maazen RW, Wesseling P. Molecular diagnostics as a tool to personalize treatment in adult glioma patients. *Technol. Cancer Res. Treat.* 2006; 5: 215-29.
10. Jeuken JW, Cornelissen SJ, Vriezen M, *et al.* MS-MLPA: an attractive alternative laboratory assay for robust, reliable, and semiquantitative detection of MGMT promoter hypermethylation in gliomas. *Lab. Invest.* 2007; 87: 1055-65.
11. Oliveira AM, Fletcher CD. Molecular prognostication for soft tissue sarcomas: are we ready yet? *J. Clin. Oncol.* 2004;22:4031-4.
12. Bovée JV, Hogendoorn PC. Molecular pathology of sarcomas: concepts and clinical implications. *Virchows Arch.* 2010; 456: 193-9.
13. Dawood S, Broglio K, Buzdar AU, Hortobagyi GN, Giordano SH. Prognosis of women with metastatic breast cancer by HER2 status and trastuzumab treatment: an institutional-based review. *J. Clin. Oncol.* 2010; 28: 92-8.
14. Lin A, Rugo HS. The role of trastuzumab in early stage breast cancer: current data and treatment recommendations. *Curr. Treat. Options Oncol.* 2007; 8: 47-60.
15. Roth AD, Tejpar S, Delorenzi M, *et al.* Prognostic role of *KRAS* and *BRAF* in stage II and III resected colon cancer: results of the translational study on the PETACC-3, EORTC 40993, SAKK 60-00 trial. *J. Clin. Oncol.* 2010; 28: 466-74.



16. Ogino S, Meyerhardt JA, Irahara N, *et al.* Cancer and Leukemia Group B; North Central Cancer Treatment Group; Canadian Cancer Society Research Institute; Southwest Oncology Group. *KRAS* mutation in stage III colon cancer and clinical outcome following intergroup trial CALGB 89803. *Clin. Cancer Res.* 2009; 15: 7322-9.
17. Rosell R, Moran T, Queralt C, *et al.* Spanish Lung Cancer Group. Screening for epidermal growth factor receptor mutations in lung cancer. *N. Engl. J. Med.* 2009; 361: 958-67.
18. Kobayashi S, Boggon TJ, Dayaram T, *et al.* *EGFR* mutation and resistance of non-small-cell lung cancer to gefitinib. *N. Engl. J. Med.* 2005; 352: 786-92.
19. Lasota J, Miettinen M. Clinical significance of oncogenic *KIT* and *PDGFRA* mutations in gastrointestinal stromal tumours. *Histopathology.* 2008; 53: 245-66.
20. Heinrich MC, Owzar K, Corless CL, *et al.* Correlation of kinase genotype and clinical outcome in the North American Intergroup Phase III Trial of imatinib mesylate for treatment of advanced gastrointestinal stromal tumor: CALGB 150105 Study by Cancer and Leukemia Group B and Southwest Oncology Group. *J. Clin. Oncol.* 2008; 26: 5360-67.
21. Antonescu CR, Besmer P, Guo T, *et al.* Acquired resistance to imatinib in gastrointestinal stromal tumor occurs through secondary gene mutation. *Clin. Cancer Res.* 2005; 11: 4182-90.
22. Halaban R, Zhang W, Bacchiocchi A, *et al.* PLX4032, a selective BRAF(V600E) kinase inhibitor, activates the ERK pathway and enhances cell migration and proliferation of BRAF melanoma cells. *Pigment. Cell Melanoma Res.* 2010; 23:190-200.

23. Smalley KS, Nathanson KL, Flaherty KT. Genetic subgrouping of melanoma reveals new opportunities for targeted therapy. *Cancer Res.* 2009; 69:3241-4.
24. Medeiros F, Rigl CT, Anderson GG, Becker SH, Halling KC. Tissue handling for genome-wide expression analysis: a review of the issues, evidence, and opportunities. *Arch. Pathol. Lab. Med.* 2007; 131: 1805-16.
25. Kumar V: Cellular injury and cellular death, in Cotran RS, Kumar V, Robbins SL (Eds). *Pathologic Basis of Disease*. Elsevier Inc., Philadelphia, 2006, pp23-25.
26. Ruijter E, van de Kaa C, Aalders T, *et al.*, Heterogeneous expression of E-cadherin and p53 in prostate cancer: clinical implications. BIOMED-II Markers for Prostate Cancer Study Group. *Mod. Pathol.* 1998;11:276-81
27. Bova GS, Eltoum IA, Kiernan JA, *et al.* Optimal molecular profiling of tissue and tissue components: defining the best processing and microdissection methods for biomedical applications. *Methods Mol. Med.* 2005; 103: 15-66.
28. Hauptmann M, Stewart PA, Lubin JH, *et al.*, Mortality from lymphohematopoietic malignancies and brain cancer among embalmers exposed to formaldehyde. *J. Natl. Cancer Inst.* 2009;101:1696-708.
29. Masuda N, Ohnishi T, Kawamoto S, Monden M, Okubo K. Analysis of chemical modification of RNA from formalin-fixed samples and optimization of molecular biology applications for such samples. *Nucleic Acids Res.* 1999; 27: 4436-43.
30. Srinivasan M, Sedmak D, Jewell S. Effect of fixatives and tissue processing on the content and integrity of nucleic acids. *Am. J. Pathol.* 2002; 161: 1961-71.

31. Cox ML, Schray CL, Luster CN, *et al.* Assessment of fixatives, fixation, and tissue processing on morphology and RNA integrity. *Exp. Mol. Pathol.* 2006; 80: 183-91.
32. van Maldegem F, de Wit M, Morsink F, Musler A, Weegenaar J, van Noesel CJ. Effects of processing delay, formalin fixation, and immunohistochemistry on RNA Recovery From Formalin-fixed Paraffin-embedded Tissue Sections. *Diagn. Mol. Pathol.* 2008; 17: 51-8.
33. van der Loos CM. A focus on fixation. *Biotech. Histochem.* 2007; 82: 141-54.
34. Goldstein NS, Ferkowicz M, Odish E, Mani A, Hastah F. Minimum formalin fixation time for consistent estrogen receptor immunohistochemical staining of invasive breast carcinoma. *Am. J. Clin. Pathol.* 2003; 120: 86-92.
35. Oyama T, Ishikawa Y, Hayashi M, Arihiro K, Horiguchi J. The effects of fixation, processing and evaluation criteria on immunohistochemical detection of hormone receptors in breast cancer. *Breast Cancer.* 2007; 14: 182-8.
36. De Marzo AM, Fedor HH, Gage WR, Rubin MA. Inadequate formalin fixation decreases reliability of p27 immunohistochemical staining: probing optimal fixation time using high-density tissue microarrays. *Hum. Pathol.* 2002; 33: 756-60.
37. Takai H, Kato A, Ishiguro T, *et al.* Optimization of tissue processing for immunohistochemistry for the detection of human glypican-3. *Acta Histochem.* 2010; 112: 240-50.
38. Greer CE, Peterson SL, Kiviat NB, Manos MM. PCR amplification from paraffin-embedded tissues. Effects of fixative and fixation time. *Am. J. Clin. Pathol.* 1991; 95: 117-24.

39. Nuovo GJ, Silverstein SJ. Comparison of formalin, buffered formalin, and Bouin's fixation on the detection of human papillomavirus deoxyribonucleic acid from genital lesions. *Lab. Invest.* 1988; 59: 720-4.
40. Zsikla V, Baumann M, Cathomas G. Effect of buffered formalin on amplification of DNA from paraffin wax embedded small biopsies using real-time PCR. *J. Clin. Pathol.* 2004; 57: 654-6.
41. Buesa RJ, Peshkov MV. Histology without xylene. *Ann. Diagn. Pathol.* 2009;13:246-56.
42. Matura M, Sköld M, Börje A, et al., Selected oxidized fragrance terpenes are common contact allergens. *Contact Dermatitis.* 2005; 52: 320-8.
43. Foti C, Zambonin CG, Conserva A, Casulli C, D'Accoliti L, Angelini G. Occupational contact dermatitis to a limonene-based solvent in a histopathology technician. *Contact Dermatitis.* 2007; 56: 109-12.
44. Visinoni F, Milios J, Leong AS-Y, Boon ME, Kok LP, Malcangi F. Ultra-rapid microwave / variable pressure-induced histoprocessing: description of a new tissue processor. *J. Histotechnol.* 1998; 21: 219-24.
45. Morales AR, Nassiri M, Kanhoush R, Vincek V, Nadji M. Experience with an microwave-assisted rapid tissue processing method. Validation of histologic quality and impact on the timeliness of diagnostic surgical pathology. *Am. J. Clin. Pathol.* 2004; 121: 528-36.
46. Hafajee ZA, Leong AS. Ultra-rapid microwave-stimulated tissue processing with a modified protocol incorporating microwave fixation. *Pathology.* 2004; 36: 325-9.

47. Leong AS, Leong FJ. Strategies for laboratory cost containment and for pathologist shortage: centralised pathology laboratories with microwave-stimulated histoprocessing and telepathology. *Pathology*. 2005; 37: 5-9.
48. Boon ME, Kok LP. Theory and practice of combining coagulant fixation and microwave histoprocessing. *Biotech. Histochem*. 2008; 83: 261-77.
49. Wolff AC, Hammond ME, Schwartz JN, *et al*. American Society of Clinical Oncology/College of American Pathologists. American Society of Clinical Oncology/College of American Pathologists guideline recommendations for human epidermal growth factor receptor 2 testing in breast cancer. *Arch. Pathol. Lab. Med*. 2007; 131: 18-43.
50. Michel B, Milner Y, David K. Preservation of tissue-fixed immunoglobulins in skin biopsies of patients with lupus erythematosus and bullous diseases-preliminary report. *J. of Invest. Dermatol*. 1973; 59: 449-52.
51. Bramwell NH, Burns BF. The effects of fixative type and fixation time on the quantity and quality of extractable DNA for hybridization studies on lymphoid tissue. *Exp. Hematol*. 1988; 16: 730-2.
52. Vincek V, Nassiri M, Nadji M, Morales AR. A tissue fixative that protects macromolecules (DNA, RNA, and protein) and histomorphology in clinical samples. *Lab. Invest*. 2003; 83: 1427-35.
53. Bussolati G, Vhiosa L, Cimino A, D'Armento G *et al*. Tissue transfer to pathology labs: under vacuum is the safe alternative to formalin. *Virchows Arch*. 2008; 452: 229-31.
54. Di Novi C, Minniti D, Barbaro S *et al*. Vacuum-based preservation of surgical specimens: an environmentally-safe step towards a formalin-free hospital. *Sci. Total Environ*. 2010;408:3092-5.

55. Wester K, Asplund A, Bäckvall H, *et al.* Zinc-based fixative improves preservation of genomic DNA and proteins in histoprocessing of human tissues. *Lab. Invest.* 2003; 83: 889-99.
56. Lykidis D, Van Noorden S, Armstrong A, *et al.* Novel zinc-based fixative for high quality DNA, RNA and protein analysis. *Nucleic Acids Res.* 2007; 35: e85.
57. Sen Gupta R, Hillemann D, Kubica T, *et al.* HOPE-fixation enables improved PCR-based detection and differentiation of Mycobacterium tuberculosis complex in paraffin-embedded tissues. *Pathol. Res. Pract.* 2003; 199: 619-23.
58. Boon ME, Schmidt U, Cramer-Knijnenburg GI, van Krieken JH. Using Kryofix as alternative for formalin results in more optimal and standardized immunostaining of paraffin sections. *Pathol. Res. Pract.* 1992; 188: 832-5.
59. Stanta G, Mucelli SP, Petrera F, Bonin S, Bussolati G. A novel fixative improves opportunities of nucleic acids and proteomic analysis in human archive's tissues. *Diagn. Mol. Pathol.* 2006; 15: 115-23.
60. Willmore-Payne C, Metzger K, Layfield LJ. Effects of fixative and fixation protocols on assessment of Her-2/neu oncogene amplification status by fluorescence in situ hybridization. *Appl. Immunohistochem. Mol. Morphol.* 2007; 15: 84-7.
61. Chu W-S, Furusato B, Wong K, *et al.* Ultrasound-accelerated formalin fixation of tissue improves morphology, antigen and mRNA preservation. *Mod. Pathology.* 2005; 18: 850–63.
62. Fracasso T, Heinrich M, Hohoff C, Brinkmann B, Pfeiffer H. Ultrasound-accelerated formalin fixation improves the preservation of nucleic acids extraction in histological sections. *Int. J. Legal Med.* 2009; 123; 521-5.

63. Iesurum A, Balbi T, Vasapollo D, Cicognani A, Ghimenton C. Microwave processing and ethanol-based fixation in forensic pathology. *Am. J. Forensic Med. Pathol.* 2006; 27: 178-82.
64. Mathai AM, Naik R, Pai MR, Rai S, Baliga P. Microwave histoprocessing versus conventional histoprocessing. *Indian J. Pathol. Microbiol.* 2008; 51: 12-6.
65. Bödör C, Schmidt O, Csernus B, Rajnai H, Szende B. DNA and RNA isolated from tissues processed by microwave-accelerated apparatus MFX-800-3 are suitable for subsequent PCR and Q-RT-PCR amplification. *Pathol. Oncol. Res.* 2007; 13: 149-52.

Peer Review

# The Diagnostic Process

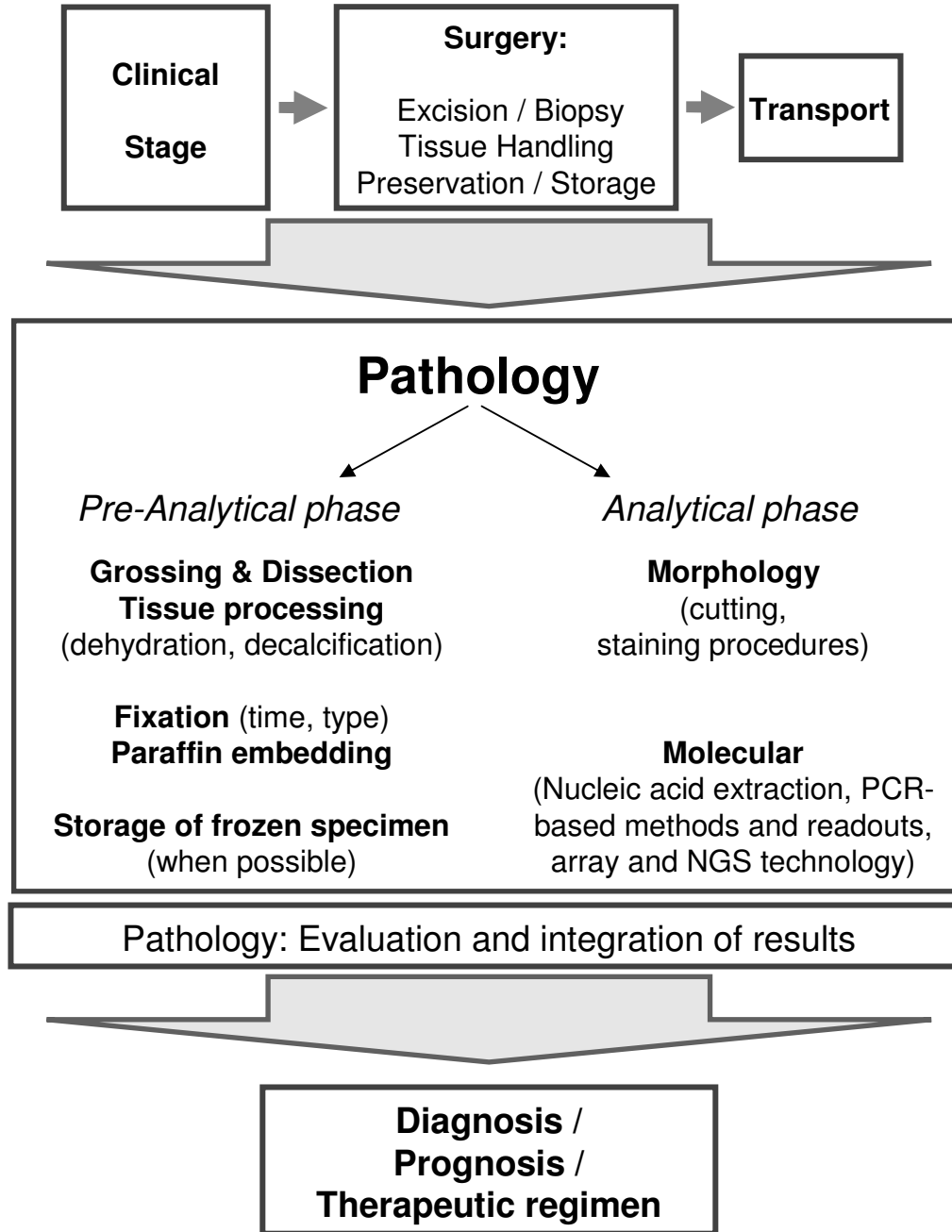


Figure 1