



HAL
open science

Co-expression of hypoxia-inducible factor 1 alpha (HIF1 α) & glucose transporter 1 (GLUT-1) is associated with poor prognosis in oral squamous cell carcinoma patients

Alexander Eckert, Matthias Mhw Lautner, Andreas Schütze, Helge Taubert, Johannes Schubert, Udo Bilkenroth

► To cite this version:

Alexander Eckert, Matthias Mhw Lautner, Andreas Schütze, Helge Taubert, Johannes Schubert, et al.. Co-expression of hypoxia-inducible factor 1 alpha (HIF1 α) & glucose transporter 1 (GLUT-1) is associated with poor prognosis in oral squamous cell carcinoma patients. *Histopathology*, 2011, 58 (7), pp.1136. 10.1111/j.1365-2559.2011.03806.x . hal-00626295

HAL Id: hal-00626295

<https://hal.science/hal-00626295>

Submitted on 25 Sep 2011

HAL is a multi-disciplinary open access archive for the deposit and dissemination of scientific research documents, whether they are published or not. The documents may come from teaching and research institutions in France or abroad, or from public or private research centers.

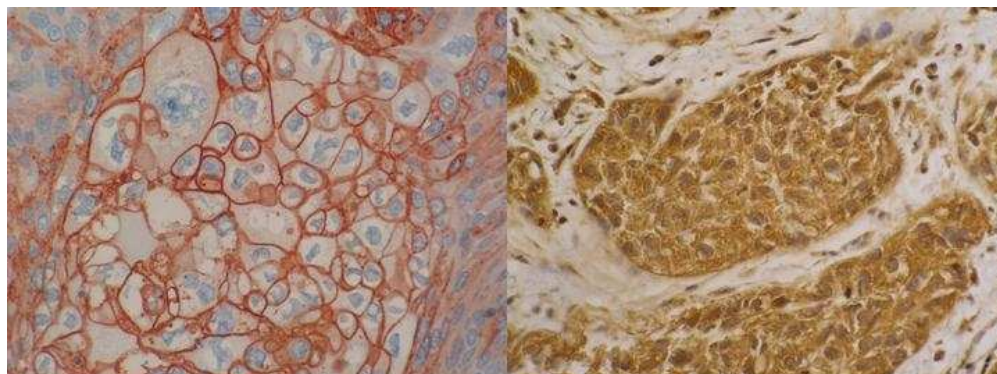
L'archive ouverte pluridisciplinaire **HAL**, est destinée au dépôt et à la diffusion de documents scientifiques de niveau recherche, publiés ou non, émanant des établissements d'enseignement et de recherche français ou étrangers, des laboratoires publics ou privés.



Co-expression of hypoxia-inducible factor 1 alpha (HIF1 α) & glucose transporter 1 (GLUT-1) is associated with poor prognosis in oral squamous cell carcinoma patients

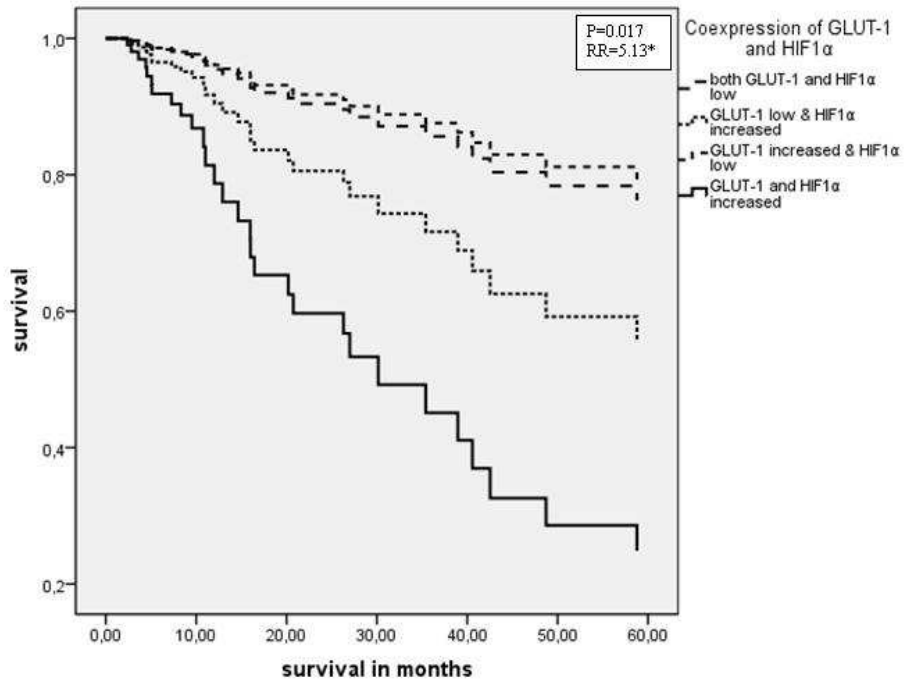
| | |
|-------------------------------|---|
| Journal: | <i>Histopathology</i> |
| Manuscript ID: | HISTOP-11-09-0650.R2 |
| Wiley - Manuscript type: | Original Article |
| Date Submitted by the Author: | 13-Jul-2010 |
| Complete List of Authors: | Eckert, Alexander; University of Halle, Department of Oral and Maxillofacial Plastic Surgery Lautner, Matthias; University of Halle, Department of Oral and Maxillofacial Plastic Surgery Schütze, Andreas; University of Magdeburg, Department of Oral and Maxillofacial Plastic Surgery Taubert, Helge; University of Halle, Department of Oral and Maxillofacial Plastic Surgery Schubert, Johannes; University of Halle, Department of Oral and Maxillofacial Plastic Surgery Bilkenroth, Udo; Hospital Eisleben, Institute of Pathology |
| Keywords: | hypoxia-inducible factor 1 alpha, head and neck , glucose transporter 1 |
| | |





Association between HIF1 α /GLUT-1 expression and prognosis in OSCC patients
254x190mm (72 x 72 DPI)

Review



Association between HIF1 α /GLUT-1 expression and prognosis in OSCC patients
254x190mm (72 x 72 DPI)

**Co-expression of hypoxia-inducible factor 1 alpha (HIF1 α) &
glucose transporter 1 (GLUT-1) is associated with poor prognosis in
oral squamous cell carcinoma patients**

A.W.Eckert^{1*}, M.H.W. Lautner¹⁺, A. Schütze¹, H. Taubert¹, J. Schubert¹ and U.Bilkenroth²

¹ Department of Oral and Maxillofacial Plastic Surgery, Martin Luther University Halle-
Wittenberg, Ernst-Grube-Str. 40, 06120 Halle

² Institute of Pathology, Hohethorstr. 25, 06295 Eisleben

+ The first and second authors contributed equally to the manuscript

* **Corresponding author**

Alexander W. Eckert MD

Department of Oral and Maxillofacial Plastic Surgery

Martin Luther University Halle-Wittenberg

E.-Grube-Str. 40

D - 06120 Halle

Germany

Phone: +49 345 557 5246

Fax: +49 345 557 5291

e-mail: helge.taubert@medizin.uni-halle.de

Keywords: hypoxia-inducible factor 1 alpha; glucose transporter 1; head and neck
cancer; oral squamous cell carcinoma

Abbreviations: HIF1 α : hypoxia-inducible factor 1 alpha; GLUT-1: glucose transporter 1;
OSCC: oral squamous cell carcinoma(s)

Summary

Aims: To study if co-expression of the two hypoxia-related proteins HIF1 α and GLUT-1 has prognostic relevance in oral squamous cell carcinomas [OSCC].

Methods and results: Eighty-two OSCC tumor samples were analyzed for expression levels of HIF1 α and GLUT-1 by immunohistochemistry. Protein expression was assessed using an immunoreactive score system and the correlation between gene expression and both clinical and pathohistological parameters were examined. Overexpression of either GLUT-1 or HIF1 α was associated with poor disease specific survival in OSCC patients. Multivariate Cox's proportional-hazards regression analysis revealed that an increased expression of HIF1 α was significantly associated with disease specific survival (RR=3.24, p=0.024) as compared to the group with low level of expression. Co-expression of both HIF1 α and GLUT-1 were additively and significantly associated with adverse prognoses in patients with OSCC. Patients whose tumors had increased levels of expression of both HIF1 α and GLUT-1 were found to have a 5.13-fold increased risk of tumor-related death (p=0.017).

Conclusions: Co-expression of high levels of HIF1 α and GLUT-1 is significantly correlated with prognosis in OSCC patients, suggesting that the co-expression of these proteins can be used as both an early diagnostic and independent prognostic marker.

Deleted: GLUT-1 or

Deleted: but only significantly for HIF1 α

Deleted: RR=1.76, p=0.171; and

Deleted: , respectively

Deleted: s

Deleted: s

Introduction

Despite possessing some advantages over other tumors in terms of diagnosis and therapeutic strategies, oral squamous cell carcinoma (OSCC) is one of the ten most common malignant human tumors, with a 5-year overall survival rate of approximately 50%.¹ The Tumor-Nodes-Metastases system (TNM) and the extent of histopathological differentiation that the tumor exhibits alone are not sufficient to allow prediction of prognosis in OSCC. There is a need for the identification of further independent prognostic markers to improve diagnosis and therapeutic regimens. The impacts that various molecular markers have had on the calculation of individuals' prognosis has been described by Lothaire.² Hypoxia is one of the most important features of locally advanced tumors that have hypoxic areas with pO₂ values ≤ 2.5 mm Hg.³ A rapidly growing tumor quickly outstrips its vasculature and thus lacks nutrients and oxygen.⁴ Under these conditions, a hypoxia signaling pathway is turned on. This pathway is largely based on the transcriptional activation of more than 70 genes by the hypoxia-inducible factor 1 (HIF1).^{5,6} Since its discovery in 1995, the HIF1 transcriptional complex has emerged as a key regulator of the adaptive response to reductions in intratumoral oxygen tension.⁷⁻¹⁰ The heterodimeric hypoxia-inducible transcription factor HIF1 consists of two subunits. The first is the oxygen sensitive subunit alpha [HIF1 α], what dimerizes with the constitutive β -subunit [HIF1 β].⁸ Previous studies have shown that the expression of HIF1 α is associated with poor prognosis in head and neck squamous cell carcinoma both on univariate¹¹⁻¹⁶ and multivariate analysis.^{11, 14} However, Kyzas and coworkers (2005) found no correlation between HIF1 α expression and prognosis, and two other groups found that elevated expression of HIF1 α was associated with improved prognosis.¹⁷⁻¹⁹

In general, malignant tumor cells have an increased rate of glucose consumption and the glucose is generally metabolized through glycolysis.²⁰ As a consequence, several glucose transporters (GLUTs) can be upregulated in malignant tumors. The GLUT-superfamily consists of 13 members.^{21,22} The erythrocyte-type (or HepG2/brain-type) glucose transporter (GLUT 1) was the first of the family of facilitative glucose transporter proteins to be cloned.²³ GLUT-1 expression is

found in very low levels in most tissues, but it is expressed at higher levels in erythrocytes, brain, cartilage, retina, and placenta and it is overexpressed in many tumors and tumor-derived cell lines.²⁴ It is thought to be responsible for "housekeeping" levels of glucose transport, i.e., the uptake of glucose required for oxidative phosphorylation. The rate of glucose transport via GLUT-1 can be altered under conditions in which the metabolic rate must be adjusted, such as during cell division (mitosis and meiosis), differentiation, transformation, and nutrient starvation.²⁵ Increased GLUT-1 expression was found to be correlated with poor survival and therapeutic outcome in oral squamous cell carcinomas on univariate analysis in two previous studies,^{26,27} but this correlation was not observed in a third study.²⁸ Two studies showed a correlation between elevated GLUT-1 expression and overall survival on multivariate analysis.^{27,29} However, the co-expression of HIF1 α and GLUT-1 and its association with a prognosis has yet to be investigated in OSCC patients. Therefore, we analyzed the expression of both proteins by immunohistochemistry and examined the correlation between HIF1 α and GLUT-1 co-expression and survival using a multivariate Cox's proportional-hazards regression analysis.

Materials and Methods

Patients and tumor tissues

Tissue specimens of 82 patients with OSCC who underwent surgery in the Department of Oral and Maxillofacial Plastic Surgery of Martin Luther University were included in this analysis. Clinical data (gender, age, location of the primary tumor, type of tumor resection, multimorbidity, tumor recurrence, alcohol consumption, and tobacco smoking history, therapy) and pathohistological data (TNM stage and grade of histopathological differentiation) were collected in a data bank using PASW 18 (SPSS Inc. Chicago, IL). The 82 patients were treated as follows: 45 patients only by surgery, 25 patients by surgery and radiotherapy, seven by surgery and radio and chemotherapy, four only by radiation and one patient by radio and chemotherapy. The resection margins were in 65 cases R0, in 12 cases R1 or R2 and in five cases only a sample excision was performed.

Immunohistochemistry

All paraffin-embedded specimens were cut into 4 μm sections, deparaffinized and dehydrated. Afterwards, slides were warmed to 60°C for 30 min for dewaxing, then boiled in 10 mM citrate buffer (pH=6.0) in a microwave oven by microwave treatment for 20 min to demask the antigens. To block endogenous peroxidase activity, 0.3% hydrogen superoxide was applied.

Immunohistochemical staining for HIF1 α was carried out using a standard immunoperoxidase technique (the ABC-method) according to the manufacturer's protocol as previously described.³⁰ Briefly, the specimens were incubated with the primary antibody (NB-100-131 Novus, Germany) at a dilution of 1: 500 for 24 h at 5°C. The slides were then washed three times with PBS and were incubated with the secondary antibody for 12 min at room temperature. A peroxidase/DAB, rabbit/mouse detection kit (Dako, Germany) was then applied. HIF1 α staining was then visualized using chromogen diaminobenzidine. Cells incubated without the primary antibody was used as the negative control. As a positive control, glioblastoma cells were stained as described by Dellas et al.

30

Immunohistochemical detection of GLUT-1 was performed as described previously.²⁹ Briefly, the primary antibody (dilution 1:200, Acris antibodies, Germany) was incubated at room temperature for 30 min. After washing with PBS, the secondary antibody was applied and incubated at room temperature for 12 min. Staining for GLUT-1 expression was then performed using the chromogen kit (Zymed) and counterstaining was carried out with hemalum (Midas E).

The expression of both HIF1 α and GLUT-1 was determined by semi-quantitatively assessing the percentage of positively marked tumor cells and the staining intensity in an immunoreactive score.³¹ The percentage of positive cells was rated as follows: 1 – 10% cells positive (1); 11 – 50% cells positive (2); 51 – 80% cells positive (3); and, > 80% cells positive (4). Staining intensity was scored as negative (1), moderate (2), and intense (3). Scores for the percentage of positive cells and cellular expression intensity were multiplied to calculate an immunoreactive score (IRS) using the method previously described by Remmele: 0 – 2 = no staining, 3 – 4 = weak staining, 6 – 8 = moderate staining, 9 – 12 = strong staining.³¹ The stained tumor specimens were viewed at magnifications of 100 x and 200 x by three independent investigators (U.B., A.S. and A.W.E.) and the average of their evaluations was calculated for statistical analyses.

Statistical analysis

Statistical analyses were performed with the PASW 18 software (SPSS Inc. Chicago, IL). The correlation between immunohistochemical staining results and clinical data was examined using the χ^2 -test, Kaplan-Meier-analysis, the log-rank-test, and multivariate Cox's proportional-hazards regression analysis. The multivariate Cox's regression hazard analysis was performed backward stepwise to exclude non significant factors. P-values of less than 0.05 were considered statistically significant.

Results

Patients

The study group consisted of 82 OSCC-patients. There were 60 men and 22 women included in the study and the average age at tumor diagnosis was 59 years (range: 23 to 83 years). The 5-year-disease specific survival rate of included patients was 62.4%. Clinical, histopathological and immunohistochemical data are summarized in Tab.1.

Clinical/pathohistological factors and prognosis

We analyzed several clinical and pathohistological factors for their association with disease specific survival as location of primary tumor, tumor size, lymph node stage, tumor stage, histological grade, type of tumor resection, multimorbidity, tumor recurrence and therapy. In a backward stepwise multivariate Cox's regression analysis only lymph node stage, multimorbidity, tumor recurrence and therapy remained significantly correlated with disease specific survival (Tab. 2)

HIF1 α expression and its correlation with clinical factors and prognosis

We have considered only cytoplasmic HIF1 α staining since nuclear staining was only in a few cases detected and could not be used for statistical analysis. This finding was in accordance with results of Koukourakis et al.. They suggest that analysis based on pure nuclear expression provides marginal statistical association with other molecular factors or prognosis, and that strong cytoplasmic HIF expression, which is a tumor-specific finding, better reflects the HIF-upregulated pathway in paraffin-embedded material.^{12,32}

Of the 82 included specimens, 11 (13.4%) had negative staining for HIF1 α , 24 tumors (29.3%) had weak staining, 40 tumors (48.8%) had moderate staining, and 7 (8.5%) had strong levels of staining for HIF1 α . We summarized negative and weak staining tumors to the group of low staining tumors and the moderate and strong staining tumors to the group of increased staining tumors (Tab. 1 and 2). Typical immunohistochemical staining results are shown in Fig. 1. There were no significant

correlations observed between HIF1 α expression and clinical or pathohistological parameters. There was a trend towards an association between HIF1 α expression and tumor size ($p=0.08$; χ^2 -test), but HIF1 α expression was not correlated with clinical factors as location of primary tumor, lymph node stage, tumor stage, tumor grade, tumor recurrence, type of tumor resection, multimorbidity or therapy (data not shown). However, HIF1 α expression was significantly correlated with disease specific survival. Patients whose tumors expressed HIF1 α low had a median survival time of 53.6 months, whereas patients whose tumors expressed HIF1 α increased only had a 36.6-month median survival time. The average 5-year survival time of OSCC patients decreased from > 80% in patients with low HIF1 α expression in their tumors to 42% in patients with increased HIF1 α expression in their tumors. (data not shown).. The multivariate Cox's proportional-hazards regression analysis (adjusted for lymph node stage, multimorbidity, recurrence and therapy) revealed a 3.24-fold increase in the risk of tumor-related death in OSCC patients whose tumors overexpressed HIF1 α ($p=0.024$).

GLUT-1 expression and its correlation with clinical factors and prognosis

Tumors from 79 out of 82 patients were stained for GLUT-1. There were 47 tumors (59%) that stained positive for GLUT-1. Out of these 47, GLUT-1 was expressed weakly in 13 tumors, it was moderately expressed in 22 cases and it was strongly expressed in 12 cases. The remaining 32 tumors (41%) did not express GLUT-1. We summarized negative and weak staining tumors to the group of low staining tumors and the moderate and strong staining tumors to the group of increased staining tumors (Tab. 1 and 2). There was a correlation between expression of GLUT-1 and recurrence, but GLUT-1 expression was not associated with other clinical factors such as location of primary tumor, lymph node stage, tumor size, tumor stage, tumor grade, type of tumor resection, multimorbidity or therapy (data not shown). Patients whose tumors had a low expression of GLUT-1 had a 13.3% risk of recurrence, whereas patients whose tumors increased expressed GLUT-1 had a recurrence rate of 68.4% ($p = 0.010$; χ^2 -test). The expression of GLUT-1 was significantly

correlated with disease specific survival. Patients whose tumors showed a low expression of GLUT-1 had a median survival time of 51.0 months, whereas patients whose tumors increased expressed GLUT-1 had a median survival of 34.3 months ($p=0.004$; Kaplan-Meier analysis, log-rank test). The multivariate Cox's proportional-hazards regression analysis (adjusted for lymph node stage, multimorbidity, recurrence and therapy) revealed that patients whose tumors showed an increased expression GLUT-1 had an 1.76-fold increased risk of tumor-related death but this was not significant (Tab. 2).

Co-expression of HIF1 α /GLUT-1 and its correlation with clinical factors and prognosis

There were 32 patients whose tumors expressed both genes at low levels and 21 patients whose tumors expressed increased levels of both HIF1 α and GLUT-1. In addition, 13 patients' tumors expressed low levels of HIF1 α but increased levels of GLUT-1 and 21 patients' tumors expressed increased levels of HIF1 α but low levels of GLUT-1. The co-expression of HIF1 α and GLUT-1 was significantly correlated with the tumor size ($p=0.025$; χ^2 -test) and recurrence ($p=0.045$; χ^2 -test). There was no correlation observed between HIF1 α and GLUT-1 co-expression and other clinical factors, such as location of primary tumor, lymph node stage, tumor stage, tumor grade, type of tumor resection, multimorbidity or therapy (data not shown). The co-expression of both factors was also significantly associated with survival time: patients in the group with low HIF1 α and GLUT-1 expression in their tumors had a median survival time of 53.6 months as compared to patients in the group with increased levels of expression of both HIF1 α and GLUT-1, who had a 24.3 months median survival time ($p=0.00002$; log-rank test). Multivariate Cox's proportional-hazards regression analysis (adjusted for tumor size and tumor grade) revealed a significant 5.13-fold increased risk of tumor-related death for patients whose tumors had increased levels of expression of both HIF1 α and GLUT-1 ($p=0.017$; Fig. 2). The co-expression of HIF1 α and GLUT-1 can therefore be considered an independent prognostic factor for patients with OSCC.

Discussion

Hypoxia is a characteristic feature of locally advanced solid tumors, and it can promote tumor progression and resistance to therapy. It has been suggested that hypoxia should be considered an independent adverse prognostic factor in patients with head and neck cancers.^{3,33} The main transcription factor activated by hypoxia is HIF1 α , which regulates cellular metabolism as part of the cell's response to hypoxia. The largest functional group of genes that is consistently regulated by HIF1 α is the group of genes associated with glucose metabolism.³⁴ This is likely because there is a major cellular shift from mitochondrial respiration to glycolysis in hypoxic cancer cells and therefore an increase in glucose uptake is essential. HIF1 α can increase a cell's rate of glucose uptake through the transcriptional activation of the facultative glucose transporters GLUT-1 and GLUT-3 (reviewed in ³⁴). Elevated expression of either HIF1 α or GLUT-1, but not the co-expression of HIF1 α and GLUT-1, has been previously detected in many different cancers, including head and neck cancer.³ Several studies have found a significant correlation between the increased expression of HIF1 α or GLUT-1 in head and neck cancers and overall prognosis has on multivariate analysis.^{11,14,27} However, to the best of our knowledge, there has been no study investigating the correlation between co-expression of high levels of HIF1 α and GLUT-1 and clinical factors or prognosis in other studies. We were able to show that increased expression of HIF1 α and GLUT-1 was correlated with a 5.13-fold increased risk of tumor-related death in OSCC patients (P=0.017; multivariate Cox's proportional-hazards regression analysis, adjusted for lymph node stage, multimorbidity, recurrence and therapy). On Kaplan-Meier analysis, the elevated expression of both HIF1 α and GLUT-1 was associated with a mean average disease specific survival of 24 months. In comparison, patients (reference group) whose tumors did not co-express these genes or weakly expressed HIF1 α and GLUT-1 survived, on average, 54 months (P=0.00002). Although GLUT-1 is transcriptionally regulated by HIF1 α , we see an additive 5.13-fold increased risk of mortality in patients whose tumors express increased levels of both factors, whereas there is only an 1.76-fold or a 3.24-fold increased risk of tumor-related death in patients whose tumors

overexpress GLUT-1 or HIF1 α alone, respectively. This finding suggests that GLUT-1 may affect prognosis in both a HIF1 α -dependent and HIF1 α -independent manner. [Furthermore, the finding of HIF1 \$\alpha\$ and GLUT-1 coexpression as independent prognostic marker may support their application as biomarker for treatment escalation, e.g. for the use of postoperative radiotherapy or chemoradiotherapy.](#)

Why does overexpression of both HIF1 α and GLUT-1 have such a strong effect on prognosis and how prognostically reliable is the detection of elevated levels of protein expression of HIF1 α and GLUT-1? The major metabolic changes that occur within tumors as compared to normal tissues were described by Otto Warburg almost 80 years ago. A tumor cell obtains most of its energy by glycolysis, whereas a normal cell obtains only about 10% of its energy from glycolysis, with the rest derived from the respiratory activity of mitochondria. Because glycolysis delivers only 2 ATP molecules as compared to the 38 ATP molecules delivered by respiration, an increased glucose supply is essential for the cancer cell to obtain sufficient energy. In order to obtain more glucose, the GLUT-1 protein, one of the major cellular glucose transporters, is ubiquitously expressed on tumor cells. In addition to their increased need for glucose, tumor cells suffer from cellular stress induced by acidosis, increased interstitial fluid pressure, and hypoxia. The major mechanism by which tumor cells respond to the stress of acidosis and hypoxia is through the activation of HIF1 α . In addition, HIF1 α can be activated by the loss of tumor suppressor gene activity (p53, PTEN, VHL) and/or gain of oncogene activity (Ras, SRC, PI3K) in tumor cells (reviewed in ³⁴). Therefore, both HIF1 α and GLUT-1 play a major role in tumor metabolism, especially under conditions of hypoxia. [More than half of patients in this study were treated only by surgery but showed a comparable expression of HIF1 \$\alpha\$ and GLUT-1 as the patients treated alone or in addition by radio or chemotherapy suggesting that hypoxia is not just an issue of radio responsiveness but a general biomarker of disease aggressiveness.](#)

Furthermore, several reports have shown that hypoxia can result in the dedifferentiation of tumor cells. For example, hypoxic neuroblastoma and breast cancer cells lose the gene expression pattern

Deleted: s

that is characteristic of differentiated cells of their cell type and develop a stem cell-like phenotype (reviewed in ³⁵). Normal stem cells have higher rates of survival, proliferation, and expression of stem cell-associated genes under hypoxic conditions than differentiated cells.³⁶⁻³⁸ Furthermore, under conditions of hypoxia, HIF1 α or GLUT-1 expression can be elevated in different stem cells.^{39,40} Further studies are needed to investigate whether or not stem cells in tumors, which can carry tumorigenic potential and affect cancer patients' prognosis, have increased HIF1 α and GLUT-1 expression too.

In summary, the co-expression of increased levels of HIF1 α and GLUT-1 protein is significantly correlated with the prognosis of OSCC patients. We therefore suggest that co-expression of these proteins can be used as biomarker for treatment escalation and as an independent prognostic marker for OSCC patients.

Deleted: for early diagnostic studies

Acknowledgements

We would like to thank Mrs. Jana Beer from the Institute of Pathology/Martin Luther University Halle-Wittenberg for her excellent technical support in immunohistochemical staining. Furthermore, we are very thankful to Dr. P. Schmidt/Tumorcenter at the Medical Faculty of the University of Halle for helping us with clinical data for the OSCC patients. HT was supported by the Deutsche Krebshilfe (grant number: 107590). The authors are thankful to American Journal Experts for editing the manuscript.

Conflict of interest statement

All authors deny any actual or potential conflict of interest including any financial, personal or other relationships with other people or organizations within that could inappropriately influence this work.

References

1. Rogers SN, Brown JS, Wolgaar JA *et al.* Survival following primary surgery for oral cancer. *Oral Oncol* 2009; **45**: 201-211.
2. Lothaire P, Azambuja E, Dequanter D *et al.* Molecular markers of head and neck squamous cell carcinoma: Promising signs in need of prospective evaluation. *Head Neck* 2006; **28**: 256-269.
3. Vaupel P, Mayer A. Hypoxia in cancer: significance and impact on clinical outcome. *Cancer Metastasis Rev* 2007; **26**: 225–239.
4. Brahimi-Horn C, Pouyssegur J. The role of the hypoxia-inducible factor in tumor metabolism growth and invasion. *Bull Cancer* 2006; **93E** 73–80.
5. Semenza GL. Targeting HIF-1 for cancer therapy. *Nat Rev Cancer* 2003; **3**: 721-732.
6. Brahimi-Horn C, Pouyssegur J. Oxygen, a source of life and stress. *FEBS Lett* 2007; **581**: 3582–3591.
7. Brennan PA, Mackenzie N, Quintero M. Hypoxia-inducible factor 1 α in oral cancer. *J Oral Pathol Med* 2005; **34**: 385–389.
8. Wang GL, Jiang B-H, Rue EA, Semenza GL. Hypoxia-inducible factor 1 is a basic – helix – loop - helix – PAS heterodimer regulated by cellular O₂ tension. *Proc Natl Acad Sci USA* 1995; **92**: 5510–5514.
9. Wang GL, Semenza GL. Purification and characterization of hypoxia-inducible factor 1. *J Biol Chem* 1995; **270**: 1230-1237.
10. Rankin EB, Giaccia AJ: The role of hypoxie-inducible factors in tumorigenesis. *Cell Death Differ* 2008; **15**: 678–685.

11. Aebershold DM, Burri P, Beer KT *et al.* Expression of hypoxia-inducible factor 1 alpha: a novel predictive and prognostic parameter in the radiotherapy of oropharyngeal cancer. *Cancer Res* 2001; **61**: 2911 – 2916.
12. Koukourakis MI, Giatromanolaki A, Sivridis E *et al.* Hypoxia-inducible factor (HIF1A and HIF2A), angiogenesis, and chemoradiotherapy outcome of squamous cell head-and-neck cancer. *Int J Radiat Oncol Biol, Phys* 2002; **53**: 1192–1202.
13. Winter SC, Shah KA, Han C *et al.* The relation between hypoxia-inducible factor (HIF)-1 alpha and HIF-2 alpha expression with anemia and outcome in surgically treated head and neck cancer. *Cancer* 2006; **107**: 757–766.
14. Schrijvers ML, van der Laan BF, de Bock GH *et al.* Overexpression of intrinsic hypoxia markers HIF1alpha and CA-IX predict for local recurrence in stage T1-T2 glottic laryngeal carcinoma treated with radiotherapy. *Int J Radiat Oncol Biol Phys* 2008; **72**: 161-169.
15. Uehara M, Sano K, Ikeda H, Nonaka M, Asahina I. Hypoxia-inducible factor 1 alpha in oral squamous cell carcinoma and its relation to prognosis. *Oral Oncol* 2009; **45**: 241–246.
16. Roh S-H, Cho K-J, Kwon GY *et al.* The prognostic value of hypoxia markers in t2-staged oral tongue cancer. *Oral Oncol* 2009; **45**: 63–68.
17. Beasley NJP, Leek R, Alam M *et al.* Hypoxia-inducible Factors HIF-1 α and HIF-2 α in Head and Neck Cancer: Relationship to Tumor Biology and Treatment Outcome in Surgically Resected Patients. *Cancer Res* 2002; **62**: 2493–2497.
18. Fillies T, Werkmeister R, van Diest PJ, Brandt B, Joos U, Burger H. HIF1-alpha overexpression indicates a good prognosis in early stage squamous cell carcinomas of the oral floor. *BMC Cancer* 2005; **5**: 84.

19. Kyzas PA, Stefanou D, Batistatou A, Agnantis N J. Hypoxia-induced tumor angiogenic pathway in head and neck cancer: An in vivo study. *Cancer Letter* 2005; **225**: 297–304.
20. Gatenby RA, Gillies RJ. Why do cancers have high aerobic glycolysis? *Nat Rev Cancer* 2004; **4**: 891–899.
21. Joost HG, Thorens B. The extended GLUT-family of sugar/polyol transport facilitators: nomenclature, sequence characteristics, and potential function of its novel members (review). *Mol Membr Biol* 2001; **18**: 247–256.
22. Joost, HG, Bell GI, Best JD *et al.* Nomenclature of the GLUT/SLC2A family of sugar/polyol transport facilitators. *Am J Physiol Endocrinol Metab* 2002; **282**: 974–976.
23. Mueckler M, Caruso C, Baldwin SA *et al.* Sequence and structure of a human glucose transporter. *Science*. 1985; **229**: 941-945.
24. Airley RE, Mobasheri A. Hypoxic regulation of glucose transport, anaerobic metabolism and angiogenesis in cancer: novel pathways and targets for anticancer therapeutics. *Chemotherapy* 2007; **53**: 233-256.
25. Merrall NW, Plevin R, Gould GW. Growth factors, mitogens, oncogenes and the regulation of glucose transport. *Cell Signal* 1993; **5**: 667-675.
26. Jonathan, R. A., Wijffels, K. I., Peeters, W *et al.* The prognostic value of endogenous hypoxia-related markers for head and neck squamous cell carcinomas treated with ARCON. *Radiother Oncol* 2006; **79**: 288–297.
27. Kunkel M, Morgel M, Stockinger M, *et al.* Overexpression of GLUT-1 is associated with resistance to radiotherapy and adverse prognosis in squamous cell carcinoma of the oral cavity. *Oral Oncol* 2007; **43**: 796–803.
28. De Schutter H., Landuyt W, Verbeken E, Goethals L, Hermans R, Nuyts S. The prognostic value of the hypoxia markers CA IX and GLUT 1 and the cytokines VEGF

- and IL 6 in head and neck squamous cell carcinoma treated by radiotherapy +/- chemotherapy. *BMC Cancer* 2005; **5**: 42.
29. Eckert AW, Lautner MHW, Taubert H, Schubert J, Bilkenroth U. Expression of GLUT-1 is a prognostic marker for oral squamous cell carcinoma patients. *Oncol Rep* 2008; **20**: 1381–1385.
30. Dellas K, Bache M, Pigorsch SU *et al.* Prognostic Impact of HIF-1 α Expression in Patients with Definitive Radiotherapy for Cervical Cancer. *Strahlenther Onkol* 2008; **184**: 169–174.
31. Remmele W, Stegner HE. Recommendation for uniform definition of an immunoreactive score (IRS) for immunohistochemical estrogen receptor detection (ER-ICA) in breast cancer tissue. *Pathologe* 1987; **8**: 138-140.
32. Koukourakis MI, Bentzen SM, Giatromanolaki A *et al.* Endogenous markers of two separate hypoxia response pathways (hypoxia inducible factor 2 alpha and carbonic anhydrase 9) are associated with radiotherapy failure in head and neck cancer patients recruited in the CHART randomized trial. *J Clin Oncol.* 2006; **24**: 727-735.
33. Vaupel P: Hypoxia and Aggressive Tumor Phenotype: Implications for Therapy and Prognosis. *Oncologist* 2008; **13**: 21–26.
34. Denko NC: Hypoxia, HIF 1 and glucose metabolism in the solid tumor: *Nature Rev Cancer* 2008; **8**: 705–713.
35. Axelson H, Fredlund E, Ovenberger M, Landberg G, Pählman S. Hypoxia-induced dedifferentiation of tumor cells--a mechanism behind heterogeneity and aggressiveness of solid tumors. *Semin Cell Dev Biol.* 2005; **16**: 554-563.
36. Zhang CP, Zhu LL, Zhao T *et al.* Characteristics of neural stem cells expanded in lowered oxygen and the potential role of hypoxia-inducible factor-1Alpha. *Neurosignals.* 2006-2007; **15**: 259-265.

37. Ma T, Grayson WL, Fröhlich M, Vunjak-Novakovic G. Hypoxia and stem cell-based engineering of mesenchymal tissues. *Biotechnol Prog*. 2009; **25**: 32-42.
38. Theus MH, Wei L, Cui L *et al*. In vitro hypoxic preconditioning of embryonic stem cells as a strategy of promoting cell survival and functional benefits after transplantation into the ischemic rat brain. *Exp Neurol*. 2008; **210**: 656-670.
39. Lee SH, Heo JS, Han HJ. Effect of hypoxia on 2-deoxyglucose uptake and cell cycle regulatory protein expression of mouse embryonic stem cells: involvement of Ca²⁺/PKC, MAPKs and HIF-1alpha. *Cell Physiol Biochem* 2007; **19**: 269-282.
40. Zhao T, Zhang CP, Liu ZH *et al*. Hypoxia-driven proliferation of embryonic neural stem/progenitor cells--role of hypoxia-inducible transcription factor-1alpha. *FEBS J* 2008; **275**: 824-834.

| Patient characteristics | HIF1 α expression | | | GLUT-1 expression | | | HIF1 α /GLUT-1 co-expression | | | | |
|---|--------------------------|------------|-------------------|-------------------|------------|-------------------|-------------------------------------|---------------------------------------|---|---|---|
| | Cases | 0-4 low | 6-12 increased | Cases | 0-4 low | 6-12 increased | Cases | HIF1 α low GLUT-1 low | HIF1 α low GLUT-1 increased | HIF1 α increased GLUT-1 low | HIF1 α increased GLUT-1 increased |
| IRS | | | | | | | | | | | |
| No. | 82 | 35 | 47 | 79 | 45 | 33 | 79 | 22 | 23 | 11 | 23 |
| Age (in yrs) | | | | | | | | | | | |
| Mean | 60.1 | 61.1 | 59.2 | 59.4 | 62.5 | 56.4 | 59.3 | 63.4 | 59.9 | 58.4 | 55.6 |
| Gender | | | | | | | | | | | |
| Male | 60 | 24 | 36 | 57 | 36 | 21 | 57 | 17 | 19 | 5 | 16 |
| Female | 22 | 11 | 11 | 22 | 9 | 13 | 22 | 5 | 4 | 6 | 7 |
| Location of primary tumor | | | | | | | | | | | |
| tongue | 31 | 18 | 13 | 29 | 20 | 9 | 29 | 10 | 10 | 6 | 3 |
| hard and/or soft palate | 17 | 8 | 9 | 17 | 8 | 9 | 17 | 6 | 2 | 2 | 7 |
| floor of the mouth/lower alveolar ridge | 30 | 8 | 22 | 30 | 15 | 15 | 30 | 5 | 10 | 3 | 12 |
| buccal mucosa | 4 | 1 | 3 | 3 | 2 | 1 | 3 | 1 | 1 | 0 | 1 |
| Tumor size | | | | | | | | | | | |
| T1 | 22 | 12 | 10 | 22 | 15 | 7 | 22 | 9 | 6 | 3 | 4 |
| T2 | 31 | 16 | 15 | 30 | 19 | 11 | 30 | 9 | 10 | 6 | 5 |
| T3 | 10 | 4 | 6 | 9 | 5 | 4 | 9 | 2 | 3 | 2 | 2 |
| T4 | 19 | 3 | 16 | 18 | 6 | 12 | 18 | 2 | 4 | 0 | 12 |
| Lymph node stage | | | | | | | | | | | |
| N0 | 43 | 21 | 22 | 40 | 27 | 13 | 40 | 12 | 15 | 7 | 6 |
| N1 | 11 | 4 | 7 | 11 | 5 | 6 | 11 | 3 | 2 | 1 | 5 |
| N2 | 15 | 4 | 11 | 15 | 7 | 8 | 15 | 3 | 4 | 1 | 7 |
| N3 | 1 | 0 | 1 | 1 | 0 | 1 | 1 | 0 | 0 | 0 | 1 |
| NX (no lymph node classification) | 12 | 6 | 6 | 12 | 6 | 6 | 12 | 4 | 2 | 2 | 4 |
| Tumor stage | | | | | | | | | | | |
| I | 19 | 9 | 10 | 19 | 13 | 6 | 19 | 6 | 7 | 3 | 3 |
| II | 20 | 10 | 10 | 20 | 13 | 7 | 20 | 5 | 8 | 5 | 2 |
| III | 11 | 5 | 6 | 9 | 4 | 5 | 9 | 3 | 1 | 1 | 4 |
| IV | 32 | 11 | 21 | 31 | 15 | 16 | 31 | 8 | 7 | 2 | 14 |
| Histological grade | | | | | | | | | | | |
| G1 | 26 | 12 | 14 | 24 | 13 | 11 | 24 | 7 | 7 | 4 | 6 |
| G2 | 39 | 18 | 21 | 38 | 17 | 21 | 38 | 12 | 11 | 5 | 10 |
| G3 | 17 | 5 | 12 | 17 | 5 | 12 | 17 | 3 | 5 | 2 | 7 |
| Resection type | | | | | | | | | | | |
| R0 | 65 | 30 | 35 | 62 | 38 | 24 | 62 | 18 | 20 | 10 | 14 |
| R1 and R2 | 12 | 4 | 8 | 12 | 6 | 6 | 12 | 3 | 3 | 1 | 5 |
| Sample excision | 5 | 1 | 4 | 5 | 1 | 4 | 5 | 1 | 0 | 0 | 4 |
| Multimorbidity¹ | | | | | | | | | | | |
| yes | 31 | 14 | 17 | 31 | 16 | 15 | 31 | 7 | 9 | 7 | 8 |
| no | 51 | 21 | 30 | 48 | 29 | 19 | 48 | 15 | 14 | 4 | 15 |

| | | | | | | | | | | | |
|--|----|----|----|----|----|----|----|----|----|---|----|
| yes | 19 | 5 | 14 | 19 | 6 | 13 | 19 | 2 | 4 | 3 | 10 |
| no | 62 | 30 | 32 | 59 | 39 | 20 | 59 | 20 | 19 | 8 | 12 |
| unknown | 1 | 0 | 1 | 1 | 0 | 1 | 1 | 0 | 0 | 0 | 1 |
| Therapy | | | | | | | | | | | |
| surg | 45 | 22 | 23 | 43 | 28 | 15 | 43 | 13 | 15 | 8 | 7 |
| surg+radio, surg+chemo, surg+radio+chemo | 32 | 12 | 20 | 31 | 16 | 15 | 31 | 8 | 8 | 3 | 12 |
| radio, chemo | 5 | 1 | 4 | 5 | 1 | 4 | 5 | 1 | 0 | 0 | 4 |
| Patient follow-up | | | | | | | | | | | |
| Alive | 53 | 30 | 23 | 50 | 34 | 16 | 50 | 19 | 15 | 9 | 7 |
| Dead | 27 | 5 | 22 | 27 | 11 | 16 | 27 | 3 | 8 | 2 | 14 |
| Unknown | 2 | 0 | 2 | 2 | 0 | 2 | 2 | 0 | 0 | 0 | 2 |

¹Multimorbidity was classified with yes, when at least five secondary diagnoses additionally to the OSCC occurred in a patient (e.g. diabetes, high blood pressure, rheumatism, cardiac infarction, cardiac arrhythmia, abnormal blood lipometabolism).

Abbreviations: surg: surgical treatment; surg+radio: surgical and radiotherapy, surg+chemo: surgical and chemotherapy; surg+radio+chemo: surgical and radio and chemotherapy; radio, chemo: only radio or chemotherapy

Table 2. Multivariate Cox's-regression analysis: Correlation of disease specific survival with clinical factors and immunohistochemical results

| Kaplan-Meier Analysis (log-rank test) | | | | Cox's proportional-hazards regression analysis | | | |
|--|----|--------|----------------|--|--------------|---------------|--------------|
| Protein expression levels | n | months | P | univariate | | multivariate* | |
| | | | | RR | P | RR | P |
| GLUT-1 | | | | | | | |
| negative (IRS 0-2) | 32 | 52.4 | | * | | * | |
| weak (IRS 3-4) | 13 | 46.9 | | 1.41 | 0.61 | 1.15 | 0.85 |
| moderate (IRS 6-8) | 21 | 32.2 | 0.048 | 3.42 | 0.007 | 5.07 | 0.002 |
| strong (IRS 9-12) | 11 | 41.0 | | 2.02 | 0.25 | 2.59 | 0.16 |
| HIF1α | | | | | | | |
| negative (IRS 0-2) | 11 | 53.8 | | 1.36 | 0.73 | 1.69 | 0.573 |
| weak (IRS 3-4) | 24 | 54.3 | | * | | * | |
| moderate (IRS 6-8) | 38 | 38.5 | | 4.73 | 0.013 | 4.53 | 0.017 |
| strong (IRS 9-12) | 7 | 34.1 | 0.013 | 5.72 | 0.023 | 3.86 | 0.088 |
| HIF1α/GLUT-1 expression | | | | | | | |
| both HIF1 α and GLUT-1 low | 22 | 53.6 | | * | | * | |
| HIF1 α low & GLUT-1 increased | 23 | 48.8 | | 1.13 | 0.89 | 1.13 | 0.33 |
| HIF1 α increased & GLUT-1 low | 11 | 53.6 | | 2.21 | 0.25 | 1.67 | 0.58 |
| both HIF1 α and GLUT-1 increased | 21 | 24.3 | 0.00002 | 8.64 | 0.001 | 10.2 | 0.001 |

| Clinical factors and immunohistochemical results | RR (95% CI) | P |
|--|----------------------------|--------------|
| Lymph node stage | | |
| pN0 | * | * |
| pN1 | 0.87 (0.20-3.84) | 0.86 |
| pN2+pN3 | 5.52 (1.36-22.38) | 0.017 |
| pNX | 0.51 (0.057-4.47) | 0.549 |
| Multimorbidity | | |
| yes | 3.53 (1.38-9.05) | 0.009 |
| no | * | * |
| Recurrence | | |
| yes | 2.46 (1.03-5.89) | 0.043 |
| no | * | * |
| Therapy | | |
| surg | * | * |
| surg+radio, surg+chemo, surg+radio+chemo | 1.16 (0.32-4.25) | 0.825 |
| radio, chemo | 20.57 (1.47-287.50) | 0.025 |
| GLUT-1-expression | | |
| low | * | * |

| | | |
|---|--------------------------|--------------|
| increased | 1.76 (0.78-3.93) | 0.171 |
| HIF1α-expression | | |
| low | * | * |
| increased | 3.24 (1.16-9.01) | 0.024 |
| HIF1α/ GLUT-1-expression | | |
| both HIF1 α and GLUT-1 low | * | * |
| HIF1 α low & GLUT-1 increased | 0.85 (0.13-5.41) | 0.87 |
| HIF1 α increased & GLUT-1 low | 2.15 (0.56-8.25) | 0.265 |
| both HIF1 α and GLUT-1 increased | 5.13 (1.33-19.79) | 0.017 |

A backward stepwise Cox's regression model was applied. It eliminated stepwise the non significant factors.

Significant values are in bold face.

Abbreviations: "*": reference group(s); 95%CI: 95% Confidence interval; surg: surgical treatment; surg+radio: surgical and radiotherapy, surg+chemo: surgical and chemotherapy; surg+radio+chemo: surgical and radio and chemotherapy; radio, chemo: only radio or chemotherapy

Figure 1. Detection of expression of HIF1 α and GLUT-1 proteins in OSCC specimens

Figure 2. Association between HIF1 α /GLUT-1 expression and prognosis in OSCC patients*

*On multivariate Cox's proportional-hazards regression analysis

