



HAL
open science

Nuclear translocation of β -catenin and decreased expression of E-cadherin in HPV-positive tonsillar cancer: An early event in HPV-related tumor progression?

Markus Stenner, Basima Yosef, Christian U Huebbers, Simon Florian Preuss, Hans Peter Dienes, Ernst-Jan M Speel, Margarete Odenthal, Jens Peter Klussmann

► To cite this version:

Markus Stenner, Basima Yosef, Christian U Huebbers, Simon Florian Preuss, Hans Peter Dienes, et al.. Nuclear translocation of β -catenin and decreased expression of E-cadherin in HPV-positive tonsillar cancer: An early event in HPV-related tumor progression?. *Histopathology*, 2011, 58 (7), pp.1117. 10.1111/j.1365-2559.2011.03805.x . hal-00626292

HAL Id: hal-00626292

<https://hal.science/hal-00626292>

Submitted on 25 Sep 2011

HAL is a multi-disciplinary open access archive for the deposit and dissemination of scientific research documents, whether they are published or not. The documents may come from teaching and research institutions in France or abroad, or from public or private research centers.

L'archive ouverte pluridisciplinaire **HAL**, est destinée au dépôt et à la diffusion de documents scientifiques de niveau recherche, publiés ou non, émanant des établissements d'enseignement et de recherche français ou étrangers, des laboratoires publics ou privés.



Nuclear translocation of β -catenin and decreased expression of E-cadherin in HPV-positive tonsillar cancer: An early event in HPV-related tumor progression?

Journal:	<i>Histopathology</i>
Manuscript ID:	HISTOP-06-10-0330.R1
Wiley - Manuscript type:	Original Article
Date Submitted by the Author:	30-Aug-2010
Complete List of Authors:	Stenner, Markus; University of Cologne, ENT Yosef, Basima; University of Cologne, Pathology Huebbers, Christian; University of Cologne, Jean-Uhrmacher-Institute Preuss, Simon; University of Cologne, ENT Dienes, Hans; University of Cologne, Pathology Speel, Ernst-Jan; Maastricht University Medical Center, Molecular Cell Biology Odenthal, Margarete; University of Cologne, Pathology Klussmann, Jens; University of Giessen, ENT
Keywords:	HPV, metastasis, nuclear beta-catenin, p16, tonsillar cancer

SCHOLARONE™
Manuscripts

30.08.2010

Dear Editor,

Thank you very much for the work and the help with our manuscript. We were pleased to read the reviewers' comments, which were very helpful to revise our paper.

We would be grateful if you now consider this article to be published in *Histopathology*.

Here is our list of changes according to the reviewers' comments (all changes were made using the track changes mode in MS Word):

For Peer Review

Response to critiques

Referee 1:

"This is an interesting manuscript that examines the β catenin and Ecadherin expression in HPV positive tonsillar cancer."

(Response): -

"The assessment of the immunohistochemistry is subjective, but uses two independent observers with a consensus agreement on discrepant scoring. The manuscript would be enhanced by an indication of the inter-observer variation, using for example Kappa agreement scores."

(Response): We now introduced Cohen's kappa coefficient as a measure of inter-observer agreement for all evaluated immunohistochemical markers (p16, E-cadherin, β -catenin, vimentin). We furthermore note that all cases of discrepancies between the two experienced pathologists were seen by Hans Peter Dienes, the head of the Institute for Pathology at the University Hospital Cologne to come to a decision.

"The photomicrographs in Figure 1 show examples of the β catenin staining. The description of panel B is not accurate. The staining shows strong nuclear, cytoplasmic and membrane staining, not exclusive nuclear staining. In addition, the background staining is high when compared to the photomicrographs illustrated in A, C and D. Photomicrograph B raises the possibility that there are interpretive errors in the data."

(Response): We are very grateful to this reviewer, as we find a misleading labelling error concerning the different localisations of β -catenin staining. The cut-off point for the group with prominent nuclear expression of β -catenin was >50% of positive nuclei irrespective of membranous or cytoplasmic staining. We now addressed this in the text and accordingly changed the name of this group into "nuclear expression" wherever necessary. We corrected this error in the legend as well. Because of the high background signal, we chose another picture for prominent nuclear staining in primary tumors (Figure 1 B).

"Figure 3B states that there are 'scattered vimentin positive carcinoma cells within the tumour tissue' it is possible that these cells represent transiting immune cells."

(Response): All specimens were independently classified by two experienced pathologists under a microscope with magnification x400 (in contrast to mag. x100 in the figure), and positive cells within tumor tissue were rated as carcinoma cells. According to their common training the pathologists distinguished between immune cells and cancer cells during their evaluation. However, sections were additionally examined by Hans Peter Dienes, the head of the Institute for Pathology at the University Hospital Cologne, who finally decided whether a cell was counted as a vimentin-positive cancer cell or not.

Nevertheless we agree with your critique. Therefore, we now did an additional immunohistochemistry for all specimens with an antibody to the Leucocyte Common Antigen (LCA) which is commonly known to detect about 95% of human leucocytes. All specimens were again seen by the two independent pathologists, and we did not find any leucocytes within areas of tumor tissue. We attached at the end of this document representative sections of the LCA immunohistochemistry of the same patient seen in figure 3 B and addressed this aspect within "methods".

"The results section states that 'For further analyses, the patients were categorized due to their HPV status determined by the above mentioned HPV-specific PCR. Categorizing patients into HPV- and p16-positive ones and all others did not lead to any different results.' The data should be analysed using the molecular classification described by Smeets et al 2007 (Ref 18). This would allow the reader to clearly see the association between 'biologically relevant' HPV infection (p16+/HPV DNA+ cases) and E-cadherin/ β catenin expression."

(Response): To assess a directly carcinogenesis-related HPV involvement in FFPE specimens of HNSCC Smeets et al. propose a test algorithm of p16 immunohistochemistry followed by a HPV-specific

PCR as gold standard. In their series the sensitivity and specificity for active HPV infection of this approach was 100%. As proposed, we now re-classified our complete data into p16+/HPV-16 DNA+ cases and all others (named HPV-related and HPV-unrelated). The results section as well as the table and figures 2 and 4 have been rewritten. As stated before, this did not lead to any different results.

Associate Editor:

"This is a potentially interesting study providing novel data on HPV-related carcinoma of the oropharynx. I support the views of the main reviewer, including the comments on the photomicrographs which do not clearly demonstrate the features in the legends. The authors should also consider the following points:"

(Response): *(see statement concerning changes above)*

"The analysis of the results is based on dichotomous grouping of negative and positive cases, however, the methods indicates that scoring was based on 0, +, ++, +++. Was any degree of +/++/+++ regarded as positive for statistical analysis? or, was another threshold applied? Are 5% p16 positive carcinomas often HPV positive?"

(Response): After primary scoring of the immunohistochemical markers, a grouping was done. "0" was grouped as "negative" whereas "+ / ++ / +++" was grouped as "positive". Less than 5% positivity was graded as negative in case of p16, as described before (Preuss et al. 2008 Br J Cancer). We found only four cases with less than 5% p16-positivity and a positive PCR for HPV-16 DNA in primary tumors and only two cases in metastases.

"Is the use of categorical data the best way to look at differences in expression between primary tumours and metastases? It would be interesting the the categorical analysis were supported by a comparison based on continuous data, since it is not apparent how much difference there was between primary and metastatic tumours."

(Response): We made use of categorical data but used 4 categories as this is commonly done in literature and it gives some information on quantification. We admit that continuous data would be interesting, however we were not able re-evaluate all sections for continuous data.

"Table 1 is unnecessarily detailed - there are no other references to observations on individual cases, so grouped data could be substituted."

(Response): There truly are no other references to observations on individual cases. As grouped data for tumor grading, HPV status, age and gender is already mentioned in the text in "methods" and in (former) Table 2, we now left away (former) Table 1. For a better understanding, we added the information on patients' pT and pN status out of (former) Table 1 in the text in "methods" as well.

"Table 3 is probably not necessary as the data are either extracted from Table 2 or included in the text."

(Response): We now left away Table 2. All relevant information is stated in the text.

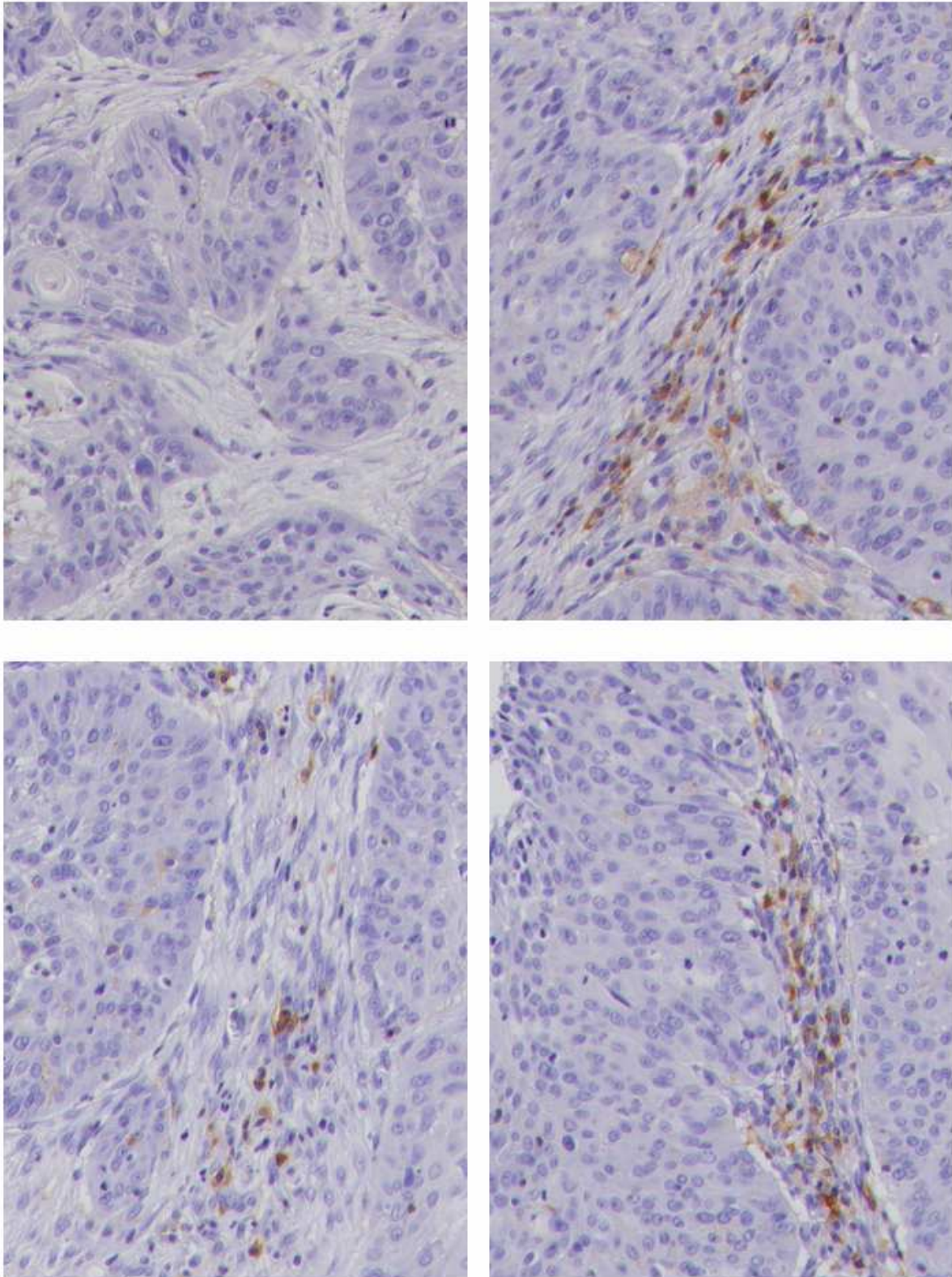


Figure: Expression of the marker protein LCA as seen in various representative sections of the same patient seen in original Figure 3 B, original magnification x400. In contrast to the carcinoma tissue, LCA-positive cells were only found within the connecting tissue.

Nuclear translocation of β -catenin and decreased expression of E-cadherin in HPV-positive tonsillar cancer: An early event in HPV-related tumor progression?

(Nuclear β -catenin and HPV in OSCC)

M. Stenner, M.D.¹

B. Yosef, M.Dent.D.²

C. U. Huebbers, Ph.D.³

S. F. Preuss, M.D.¹

H. P. Dienes, M.D.²

E. J. M. Speel, Ph.D.⁴

M. Odenthal, Ph.D.²

J. P. Klussmann, M.D.⁵

¹Department of Otorhinolaryngology, Head and Neck Surgery, School of Medicine
University Hospital of Cologne, Germany

²Department of Pathology, School of Medicine
University Hospital of Cologne, Germany

³Jean-Uhrmacher-Institute for Otorhinolaryngological Research
University of Cologne, Geibelstrasse 29-31, 50931 Cologne, Germany

⁴Department of Molecular Cell Biology, GROW-School for Oncology & Developmental Biology
Maastricht University Medical Center, The Netherlands

⁵Department of Otorhinolaryngology, Head and Neck Surgery, School of Medicine
University Hospital of Giessen, Germany

Key words: HPV, metastasis, nuclear β -catenin, p16, tonsillar cancer

Word count: Abstract 198; Manuscript 3.405

Deleted: 9

Deleted: 304

Corresponding author:

Markus Stenner, M.D.

Department of Otorhinolaryngology, Head and Neck Surgery, School of Medicine

University Hospital of Cologne

Kerpener Strasse 62

50937 Cologne, Germany

Phone: +49-221-478-4750

Fax: +49-221-478-4793

E-mail: markus.stenner@uk-koeln.de

ABSTRACT

Aims: High-risk human papillomaviruses (HPV) seem to be an important risk factor for tonsillar cancer. However, only few data exist concerning molecular changes during metastasis. **Methods and Results:** We examined 48 primary tonsillar carcinoma samples (25 HPV-16 DNA positive, 23 HPV-16 DNA negative) and their respective lymph node metastases for their HPV status and for the expression of p16, E-cadherin, β -catenin and vimentin. A positive HPV-specific PCR correlated significantly with p16 overexpression in both the primary tumor and metastasis ($p < 0.0001$ both). In HPV-unrelated patients the expression of E-cadherin was significantly less abundant in metastases than in primary tumors ($p < 0.001$). The expression of nuclear β -catenin was contrariwise significantly higher in metastases than in primary tumors ($p = 0.016$). Compared to HPV-unrelated patients, in HPV-related ones the nuclear localisation of β -catenin expression was already apparent in primary tumors ($p = 0.030$). The expression of vimentin significantly correlated with the grading of the primary tumor ($p = 0.021$). **Conclusions:** Our data newly indicate that the downregulation of E-cadherin together with an upregulation of nuclear β -catenin might be crucial steps during tumor progression of tonsillar cancer being already present in primary tumors in HPV driven cancers but become apparent in HPV-unrelated tumors later during the process of metastasizing.

Deleted: HPV-negative

Deleted: 7

Deleted: HPV-negative

Deleted: positive

Deleted: exclusive

Deleted: 4

Deleted: negative

INTRODUCTION

Head and neck squamous cell carcinoma (HNSCC) is the fifth most common malignancy worldwide¹. Among these, the oropharyngeal squamous cell carcinoma (OSCC) is the most common entity and the sixth most common cancer in the United States, with approximately 8,000-10,000 deaths each year². Tonsillar cancer is the most frequent OSCC. It is characterized by local invasiveness and a marked propensity for dissemination to cervical lymph nodes. Despite advances in surgery, radiation, and chemotherapy, the five-year survival rate has not improved significantly over the past several decades and it remains at about 50 to 55%³.

The development of tonsillar cancer is closely related to both intensity and duration of alcohol and tobacco consumption, which represent the most significant risk factors⁴. Since a few years, there is growing evidence, that high-risk human papillomaviruses (HPV) are an important risk factor for OSCC as well^{5, 6}. HPV can infect the epithelium of the upper aerodigestive tract in general, but the tonsil appears uniquely susceptible to transformation by the virus^{7, 8}. Although the genome of the prototypic high-risk types HPV-16 and -18 codes for several different proteins, two viral proteins, E6 and E7 are classified as oncogenes because they contribute to tumor progression by inactivating two tumor suppressor genes. E6 degrades p53 and E7 affects the retinoblastoma (Rb) protein, respectively^{9, 10}. A recent review of the prognostic significance of HPV in survival of head and neck cancer patients has shown that the majority of studies have reported better survival in those patients with HPV-positive HNSCC when compared to patients with HPV-negative tumors¹¹⁻¹³, even though HPV-related tumors are less differentiated than HPV-unrelated ones^{14, 15} and frequently appear with lymph node metastases. In OSCC the tumor suppressor

Deleted: negative

protein p16 is so consistently overexpressed in HPV-positive tumors as opposed to HPV-negative ones^{12, 16, 17} that it has been proposed as a surrogate marker for high-risk HPV infection. Therefore p16 immunostaining and subsequent HPV-PCR has been recommended to detect HPV-related primary HNSCC¹⁸. Only some studies exist describing the presence of HPV DNA in neck metastases of HNSCC^{19, 20} and a correlation of p16 expression and HPV status has so far only been shown once in metastases of the oropharynx²¹.

Lymph node metastasis seems to be the most important prognostic indicator for patients with OSCC²². Some of the properties of metastatic cells have been linked to downregulation of the epithelial cadherin (E-cadherin) glycoprotein²³⁻²⁵, and in OSCC several studies revealed that abnormal expression of E-cadherin correlates with lymph node metastasis^{26, 27}. Furthermore, E-cadherin was found to be a selective and strongly dominant prognostic factor in squamous cell carcinomas²⁸. E-cadherin-mediated cell adhesion requires intracellular attachment to the actin cytoskeleton by interaction with catenins. Especially the β -catenin is not only an important protein linked to epithelial adhesion molecules but may also act as an oncogene, becoming one of the key downstream effectors in the Wnt and Akt signaling pathway. Dimers of β -catenin and one of the members of the TCF/LEF (T cell factor/lymphoid enhancer factor) family function as a transcription factor when located to the nucleus. Amongst other genes it transactivates cyclin D1. Some studies reported that reduced assembly of membranous β -catenin and nuclear translocation was found frequently in invasive areas and metastases of HNSCC²⁹. Studies of epithelial malignancies have furthermore consistently demonstrated that loss of cell adhesion and the acquisition of mesenchymal features, a process termed epithelial-mesenchymal transition (EMT), precede their invasion and progression^{30, 31}. De Araujo et al.

demonstrated that the expression of the mesenchymal molecule vimentin was most marked in OSCC with high tumor grade³². In this context, a significant correlation between decreased E-cadherin and vimentin expression and aggressive tumor features including lymph node metastasis could recently be shown by immunophenotypic analysis of HNSCC³³. Underscoring the possible role of HPV for tumor progression in primary tumors, it remains unclear whether there is a link between HPV and tumor progression in metastases as well. In this context, it has recently been shown that HPV DNA could even be detected in histologically confirmed tumour-free neck lymph nodes of head and neck cancers³⁴.

Here we have studied the loss of cell adhesion and the acquisition of mesenchymal features in relation to the HPV status in primary tonsillar carcinomas and their respective metastases.

MATERIAL AND METHODS

Patient data

The study was conducted according to the Declaration of Helsinki on biomedical research involving human subjects. Written informed consent was obtained from each patient and the scientific protocol was approved by the Local Ethics Committee. In a retrospective design, we selected from previous studies^{35, 17} 48 primary tumor samples (25 HPV-16 DNA positive and 23 HPV-16 DNA negative) obtained at the time of surgical resection as well as respective lymph node metastasis samples acquired during the neck dissection of these patients. A neck dissection was performed in patients with primary tumor stages T2-T4. Basis of selection was the availability of sufficient fresh frozen tumor tissue with at least 70% tumor cells, enough high quality tumor DNA and assessment of the presence or absence of HPV sequences. HPV DNA was detected using a highly sensitive group-specific nested PCR with degenerate primers A5/A10 and A6/A8³⁶. HPV typing was performed as described previously⁶. All patients were treated at the Department of Otorhinolaryngology, Head and Neck Surgery, School of Medicine by JPK between 1997 and 2004. The treatment modality employed was definitive surgery with postoperative radiation or chemo radiation, and none of the samples examined were influenced by chemotherapeutic agents or preceding radiotherapy.

The patients' age ranged from 37 to 76 years (median 57 years) with a male to female ratio of 3 to 1. The classification of primary tumors and metastases as well as the histological grading was performed in a blinded manner following the World Health Organization 2005 criteria for squamous cell carcinomas of the oral mucosa.

The pathologic primary tumor and lymph node stages were as follows: pT1 13 (27.1%), pT2 26 (54.2%), pT3 8 (16.7%), pT4 1 (2.1%); pN1 18 (37.5%), pN2a 4

(8.3%), pN2b 22 (45.8%), pN2c 3 (6.3%), pN3 1 (2.1%). As tonsillar tumors tend to be non-keratinizing or basaloid, grading sometimes is difficult. Therefore, in 10 out of 48 cases, the grades 1-2 and 2-3 were introduced in which the assignment was unclear. All patients were cM0 as evaluated by means of a computed tomography scan of the thorax and an ultrasound examination of the abdomen.

Deleted: (Table 1)

Immunohistochemistry

Tissue specimens were fixed in 10% buffered formaldehyde and embedded in paraffin. Sections 4 µm thick were mounted on *Superfrost Plus* glass slides (Microm, Walldorf, Germany), deparaffinised and rehydrated using graded ethanols.

Immunostaining for p16, E-cadherin and vimentin was performed using the *DAKO Tech-Mate 500 Plus Immunostainer* (DAKO, Glostrup, Denmark). Antigen retrieval and antibody dilutions were optimized individually as follows. Using specific mouse monoclonal antibodies, a 1:100 dilution for p16 (clone DCS-50, NeoMarkers, Fremont, CA, USA), a 1:50 dilution for E-cadherin (clone NCH-38) and a 1:200 dilution for vimentin (clone Vim 3B4) (both DAKO) were applied for 25 minutes after microwave treatment twice for 7 minutes in citrate buffer (0.01 M, pH 6.0) at 600 W. Developing was initiated by incubating the sections for 25 minutes with a biotinylated rabbit anti-mouse secondary antibody (DAKO). Slides were then immersed in *Chem Mate Peroxidase-Blocking Solution* (DAKO) three times for 2.5 minutes to block endogenous peroxidase activity. After 25 minutes of incubation with streptavidin-horseradish peroxidase (DAKO) and subsequent staining with chromogen AEC (DAKO) for 10 minutes, sections were counterstained with haematoxylin (DAKO), dehydrated and mounted.

Immunohistochemical staining for β-catenin was performed using the ABC-method. Briefly, antigen retrieval was done using citrate buffer as mentioned above in a

microwave oven (600 W) 3 times for 5 minutes. Endogenous peroxidase activity was blocked by incubating the sections in 0.3% H₂O₂ in 0.001 M phosphate buffered saline for 30 minutes. This was followed by blocking avidin and biotin using the *Avidin-Biotin Blocking Kit* (Vector Laboratories, Burlingame, CA, USA). Primary monoclonal mouse antibody (BD Biosciences, Heidelberg, Germany) was applied at a dilution of 1:500 overnight at 4°C. A biotin-conjugated rabbit anti-mouse antibody (DAKO) was used as a secondary antibody at a dilution of 1:200 for 30 minutes. Avidin-biotin complex-peroxidase (Vector Laboratories) was used for antibody detection and visualization with AEC was done as described above.

For quality control of staining, positive and negative controls were included in each staining run. The positive controls were normal tonsils for p16, normal breast tissue for E-cadherin, colorectal tumors for β -catenin and lymphoma tissue for vimentin. The vascular walls in the examined slides served as an internal positive control for vimentin as well. Staining in the absence of primary antibodies served as negative controls, in which no staining reaction was seen.

Scoring of immunohistochemical staining

All sections were independently examined by two experienced pathologists participating in the education of pathology at the International Academia of Pathology (IAP), and they were blinded to the patients' clinical information. First of all, both examiners determined the areas of carcinoma tissue within the samples. Then the staining pattern was evaluated semi quantitatively by comparing the intensity and cellular localisation of immunostaining with positive and negative controls. To determine percentage labelling indices, for each section usually more than 1000 cells were analysed in 5 randomly selected fields of tumor tissue using high-power (40x objective and 10x ocular) magnification. For each antibody, levels of immunoreaction

Deleted: independent

Formatted: Font: 12 pt, Complex
Script Font: 12 pt

Deleted: who

were graded into 4 categories as follows: 0, <5%; 1+, 5-25%; 2+, 26-50%; 3+, >50% positive cells for E-cadherin, vimentin and p16, and 0, <1%; 1+, 1-10%; 2+, 11-25%; 3+, >25% positive cells for β -catenin, for practical and statistical purposes as based on the results. In tumors showing heterogeneity of staining, the immunostaining was judged according to the prominent pattern. Whenever there were some discrepancies in the evaluation between observers, a consensus was reached using a multiheaded microscope. [In case of vimentin, we did an additional immunohistochemistry for the leucocyte common antigen \(LCA\) to rule out immune cells within tumor tissue.](#)

Statistical analysis

All statistical analyses were performed using *SPSS 17.0* (SPSS Inc., Chicago, IL, USA) for *Microsoft Windows XP* (Microsoft Corporation, Redmont, WA, USA). The association between experimental findings and clinicopathological variables was analysed using the χ^2 -test for categorical data. In case of individual datasets of primary tumor and metastasis of the patients, a paired Student's t-test was applied whenever suitable. A p-value < 0.05 was considered to be statistically significant.

RESULTS

Correlation between a positive HPV status and p16 expression was significant for primary tumors ($p < 0.0001$) as well as for metastases ($p < 0.0001$). In primary tumors, 84% of HPV-positive ones were p16-positive and 91% of HPV-negative ones were p16-negative. In metastases, 89% of HPV-positive ones were p16-positive and 97% of HPV-negative ones were p16-negative. There were 3 out of 48 patients with a mismatch of HPV-status and p16 expression in their metastasis. These 3 patients belonged to the group of 6 patients with a mismatch in their primary tumor.

Deleted: (Table 2)

Significant differences comparing the individual datasets were found for the expression of p16 being lower in metastases (35%) than in primary tumors (48%; $p = 0.013$) (Table 1) and for the patients HPV status being less frequently positive in metastases (38%) than in primary tumors (52%; $p = 0.018$). In other words, 7 out of 25 HPV-positive primary tumors had an HPV-negative metastasis and 5 out of these 7 were p16-positive in their primary tumor and p16-negative in their metastasis. These cases were of low T and N classification, of high grade and presented vimentin levels above the average and a prominent nuclear β -catenin staining. All 23 HPV-negative primary tumors had a negative HPV-specific PCR of their respective metastasis, and all 25 p16-negative primary tumors had p16-negative respective metastases.

Deleted: (Tables 2, 3)

Deleted: nearly

Deleted: exclusive

For further analyses, according to Smeets et al.¹⁸, the patients were categorized into p16- and HPV-positive ones (p16+/HPV+) and all others. For better understanding, the first group was classified as HPV-related tumors. The remaining cases were summarized as HPV-unrelated. Comparing individual datasets, this HPV-relation was less frequent in metastases (33%) than in primary tumors (44%; $p = 0.024$).

Deleted: due to their HPV status determined by the above mentioned HPV-specific PCR. Categorizing patients into

Deleted: and p16-

Deleted:

Deleted: did not lead to any different results

All examined immunohistochemical markers could be detected in primary tumors and in metastases. The Cohen's kappa coefficients for the inter-observer agreements were as follows: 0.895 for p16, 0.690 for E-cadherin, 0.865 for β -catenin and 0.744 for vimentin. 13 out of 48 patients showed concurrent positive immunostaining for p16, β -catenin and vimentin both of the primary tumor and the metastasis respectively.

Deleted: There was no significant interobserver variability in the blinded analysis of the slides.

Expression of E-cadherin was significantly less abundant in metastases (21%) than in primary tumors (56%; $p < 0.001$) (Table 1). This tendency became even more obvious in the subgroup of patients with an N2b, N2c or N3 status. Here, E-cadherin expression again was lower in metastases (23%) than in primary tumors (73%; $p < 0.0001$). E-cadherin expression in metastases of T3/4 primary tumors was significantly lower (0%) compared to metastases of T1/2 primary tumors (26%; $p < 0.001$).

Deleted: 2

In HPV-unrelated primary tumors the protein expression of E-cadherin was higher (59%) than in HPV-related primary tumors (52%; $p > 0.05$) (Table 1), and the above observed significantly reduced expression of E-cadherin in metastases was seen only in HPV-unrelated patients ($p = 0.002$).

Deleted: negative

Deleted: 61

Deleted: positive

Deleted: 2

Deleted: negative

Deleted: ($p < 0.001$) (Table 3).

All primary tumors and all but one metastases were positively stained for β -catenin. In both primary tumors and metastases, three different patterns of β -catenin immunostaining were found: predominantly in the nucleus (more than 50% positively stained nuclei, irrespective of membranous staining), exclusively in the membranes or a combination of nuclear and membranous localisation (Table 1, Figure 1). For better understanding, these groups were classified as nuclear, membranous and combined.

Deleted: exclusively

Deleted: 2

Comparing individual datasets, a significant difference was found for a nuclear β -catenin expression being higher in metastases (46%) than in primary tumors (27%, $p = 0.002$) (Table 1). This was valid only for HPV-unrelated patients. Here, the protein expression of nuclear β -catenin was 44% in metastases and 15% in primary tumors ($p = 0.016$). In HPV-related primary tumors the nuclear localisation of β -catenin expression was significantly higher than in HPV-unrelated ones ($p = 0.030$) (Table 1). Looking at nuclear β -catenin-positive tumor samples, 69% of primary tumors and 36% of metastases were HPV-related whereas 31% of primary tumors and 64% of metastases were HPV-unrelated ($p = 0.060$).

The nuclear β -catenin expression significantly correlated contrary to the E-cadherin expression in the whole group ($n = 96$; $p = 0.017$) and in HPV-related primary tumors ($n = 21$; $p = 0.015$). In HPV-unrelated primary tumors one was found to be nuclear β -catenin-positive and E-cadherin-negative whereas in HPV-unrelated metastasis 13 were nuclear β -catenin-positive and E-cadherin-negative. In HPV-positive primary tumors 7 were found to be nuclear β -catenin-positive and E-cadherin-negative whereas in HPV-positive metastasis 6 were nuclear β -catenin-positive and E-cadherin-negative ($p = 0.008$) (Figure 2).

A significant correlation could be found between the expression levels of vimentin and the differentiation grade of the primary tumors ($p = 0.021$) with higher vimentin levels in less differentiated tumors (Table 1, Figure 3).

- Deleted: n exclusive
- Deleted: 5
- Deleted: 2
- Deleted: negative
- Deleted: 3
- Deleted: 3
- Deleted: 7
- Deleted: (Table 3)
- Deleted: positive
- Deleted: exclusive
- Deleted: negative
- Deleted: 4
- Deleted: 2
- Deleted: 77
- Deleted: 41
- Deleted: positive
- Deleted: 23
- Deleted: 59
- Deleted: negative
- Deleted: 39
- Deleted: There was no such correlation for nuclear β -catenin-negative tumor samples.
- Deleted: ,
- Deleted: negative tumor samples
- Deleted: 53
- Deleted: 20
- Deleted: and in HPV-negative metastases ($n = 30$; $p = 0.032$).
- Deleted: negative
- Deleted: negative
- Deleted: 6
- Deleted: 7
- Deleted: 21
- Deleted: 2

DISCUSSION

Examining the expression of mesenchymal and epithelial proteins as well as p16 in 48 tonsillar carcinomas and their respective metastases in relation to the patients' HPV status, our study revealed the following major findings. First, the process metastasis of tonsillar cancer is characterised by a downregulation of E-cadherin and an upregulation of nuclear β -catenin and seems to occur at different time points depending on the patients HPV status. Furthermore, the expression of the mesenchymal marker protein vimentin significantly correlates with the grading of tonsillar carcinomas (Figure 4). Second, metastasis of tonsillar cancer is accompanied by a loss of HPV and p16 in some cases. Third, we could show a strong correlation of p16 expression and the presence of HPV DNA also for lymph node metastases.

P16 can be used as a surrogate marker for the patients' HPV status in OSCC¹² and in HNSCC metastases³⁷. In our study we could confirm the strong correlation of p16 and the patients' HPV status not only for the primary tumor but for the first time for the metastasis of tonsil cancer as well. The signaling pathways, namely the pRb-pathway seems to work even in the partly disturbed molecular interior of the metastasis with the consequence of elevated p16 in HPV-positive metastases. However we observed a loss of HPV-DNA in 7 cases during metastasis. Interestingly, in most of these cases, the p16 expression was lost in metastases as well. It can be speculated that the loss of HPV-DNA during metastasis might be the consequence of loss of cellular DNA at sites with integrated HPV-DNA or more likely the consequence of loss of episomal HPV-sequences. Due to loss of E7 expression in these cases p16 might not be overexpressed anymore. For future analysis it will be

of great interest to collect more of these cases and examine them in more detail concerning the viral loss.

Dysfunction of E-cadherin-mediated cell adhesion results in an increased metastatic potential of cancer cells^{38, 39}. In our study E-cadherin expression was decreased in HPV-related primary tumors compared to HPV-unrelated ones. Furthermore, a decrease of E-cadherin during metastasis could be shown only for HPV-unrelated patients. This suggests, that parts of tumor progression during metastasis, characterized by downregulation of E-cadherin have already taken place in the primary tumor in HPV-related patients, whereas in HPV-unrelated patients these parts of tumor progression might happen later during the process of metastasis. Interestingly in a recent study with primary tumors we found a loss of chromosome 16q as a specific genetic change in HPV-related OSCC which might explain the E-cadherin inactivation in this study³⁵ since E-cadherin is located on chromosome 16q22.1⁴⁰.

Our data for the first time show a significantly increased expression of nuclear β -catenin in HPV-related primary tumors compared to HPV-unrelated ones. Furthermore, only within HPV-unrelated patients nuclear β -catenin is significantly increased in metastases compared to the corresponding primary tumors. This gives rise to the question, whether nuclear β -catenin plays a role in tumor progression at different time points in HPV-related and -unrelated patients as well. Acting as a cofactor for the LEF/TCF transcription factor, β -catenin activates target genes, including matrilysin, fibronectin, cyclin D1, c-myc and other oncogenes, resulting in deregulation of cell cycle progression and unscheduled proliferation⁴¹. In HPV-related cervical lesions, increased nuclear staining of β -catenin was detected in carcinoma samples, whereas in cervical dysplasia no nuclear staining was seen⁴². Uren et al.

Deleted: positive

Deleted: negative

Deleted: negative

Deleted: positive

Deleted: negative

Deleted: HPV-positive

Deleted: HPV-negative

Deleted: HPV-negative

Deleted: HPV-positive

Deleted: -

Deleted: negative

conclude, that high β -catenin levels together with activation of the Wnt pathway may serve as a marker to detect malignant progression in cervical cancer. Al Moustafa et al. could show, that overexpression of E6/E7 in combination with ErbB-2 activation downregulates E-cadherin and membranous β -catenin expression⁴³. This is accompanied by nuclear translocation of β -catenin, which is then acting as a transcriptional regulator with subsequent upregulation of oncoproteins being accountable for tumor progression. Analogical to the findings on E-cadherin our results suggest that this form of tumor progression characterized by elevated expression of nuclear β -catenin already takes place in the primary tumors of HPV-related patients whereas in HPV-unrelated ones it happens later during metastasis.

Deleted: HPV-positive

Deleted: HPV-negative

Taken together, the combination of decreasing E-cadherin and increasing nuclear β -catenin might reflect an important event in HPV-related tumor progression.

Deleted: of

Interestingly, recent studies on human colorectal carcinomas and endometrial carcinoma cells showed that p16 is under direct transcriptional control of nuclear β -catenin^{41, 44, 45}. Therefore it could be speculated that the p16 overexpression in HPV-related OSCC is not only depending on pRb inactivation by E7 but also a direct effect of nuclear β -catenin translocation. Here p16 overexpression does not lead to cell cycle suppression because of the disabled downstream effector pRb which is being blocked by E7, resulting in tumor progression. Elzagheid et al. observed a high nuclear expression of β -catenin in primary tumors and metastases being a significant predictor of a more favourable disease free survival in colorectal cancer⁴⁶ and recent studies have shown that p16 is a significant predictor for a favourable prognosis for OSCC which is in concordance with HPV DNA positivity in most cases^{11, 12}.

Immunostaining revealed that the expression of vimentin in primary tumor cells increased significantly with a higher grading. This gives an indication that epithelial cells undergo the mesenchymal activation process known as EMT⁴⁷. Taken together, the vimentin expression corresponding to the grading as well as an upregulation of nuclear β -catenin and a downregulation of E-cadherin during tumor progression our observations give evidence that EMT might play an early event in dedifferentiation and progression of tonsillar cancer.

In conclusion, we have newly identified possible molecular changes involved in tumor progression in tonsillar primary tumors and their respective metastases at different timepoints during metastasis depending on the patients HPV status.

REFERENCES

1. Forastiere A, Koch W, Trotti A, Sidransky D. Head and neck cancer. *N Engl J Med* 2001;345:1890-1900.
2. Meyers AD. Oral Cancer. *Otolaryngol Clin North Am* 2006;39(2):229-402.
3. Ragin CCR, Modugno F, Gollin SM. The Epidemiology and Risk Factors of Head and Neck Cancer: a Focus on Human Papillomavirus. *J Dent Res* 2007;86(2):104-114.
4. Gillison ML. Current topics in the epidemiology of oral cavity and oropharyngeal cancers. *Head Neck* 2007;29(8):779-92.
5. Gillison ML, D'Souza G, Westra W *et al*. Distinct risk factor profiles for human papillomavirus type 16-positive and human papillomavirus type 16-negative head and neck cancers. *J Natl Cancer Inst* 2008;100:407-420.
6. Klussmann JP, Weissenborn SJ, Wieland U *et al*. Prevalence, distribution, and viral load of human papillomavirus 16 DNA in tonsillar carcinomas. *Cancer* 2001;92(11):2875-84.
7. Venuti A., Badaracco G, Rizzo C, Mafera B, Rahimi S, Vigili M. Presence of HPV in head and neck tumors: high prevalence in tonsillar localization. *J Exp Clin Cancer Res* 2004;23(4):561-6.
8. Klussmann JP, Weissenborn SJ, Wieland U *et al*. Human papillomavirus-positive tonsillar carcinomas: a different tumor entity? *Med Microbiol Immunol* 2003;192(3):129-32.

9. Galloway DA, McDougall JK. The disruption of cell cycle checkpoints by papillomavirus oncoproteins contributes to anogenital neoplasia. *Semin Cancer Biol* 1996;7(6):309-15.
10. Scheffner M, Huibregtse JM, Vierstra RD, Howley PM. The HPV-16 E6 and E6-AP complex functions as a ubiquitin-protein ligase in the ubiquitination of p53. *Cell* 1993;75(3):495-505.
11. Ragin CC, Taioli E. Survival of squamous cell carcinoma of the head and neck in relation to human papillomavirus infection: review and meta-analysis. *Int J Cancer* 2007;121(8):1813-20.
12. Reimers N, Kasper HU, Weissenborn SJ *et al.* Combined analysis of HPV-DNA, p16 and EGFR expression to predict prognosis in oropharyngeal cancer. *Int J Cancer* 2007;120(8):1731-8.
13. Schlecht NF. Prognostic value of human papillomavirus in the survival of head and neck cancer patients: an overview of the evidence. *Oncol Rep* 2005;14:1239-47.
14. Badaracco G, Rizzo C, Mafera B *et al.* Molecular analyses and prognostic relevance of HPV in head and neck tumors. *Oncol Rep* 2007;17(4):931-9.
15. Wilczynski SP, Lin BT, Xie Y, Paz IB. Detection of human papillomavirus DNA and oncoprotein overexpression are associated with distinct morphological patterns of tonsillar squamous cell carcinoma. *Am J Pathol* 1998;152:145-156.
16. Li W, Thompson C, Cossart Y *et al.* The expression of key cell cycle markers and presence of HPV in squamous cell carcinoma of the tonsil. *Head Neck* 2004;26:1-9.

17. Klussmann JP, Gultekin E, Weissenborn SJ *et al.* Expression of p16 Protein Identifies a Distinct Entity of Tonsillar Carcinomas Associated with Human Papillomavirus. *Am J Pathol* 2003;162:747-753.
18. Smeets SJ, Hesselink AT, Speel EJ *et al.* A novel algorithm for reliable detection of human papillomavirus in paraffin embedded head and neck cancer specimen. *Int J Cancer* 2007;121(11):2465-72.
19. Hoffmann M, Gottschlich S, Görögh T *et al.* Human papillomaviruses in lymph node neck metastases of head and neck cancers. *Acta Otolaryngol* 2005;125(4):415-21.
20. Goldenberg D, Begum S, Westra WH *et al.* Cystic lymph node metastasis in patients with head and neck cancer: An HPV-associated phenomenon. *Head Neck* 2008;30(7):898-903.
21. Begum S, Gillison ML, Ansari-Lari MA, Shah K, Westra WH. Detection of human papillomavirus in cervical lymph nodes: a highly effective strategy for localizing site of tumor origin. *Clin Cancer Res* 2003;9(17):6469-75.
22. Tanaka N, Ogi K, Odajima T *et al.* pRb2/p130 protein expression is correlated with clinicopathologic findings in patients with oral squamous cell carcinoma. *Cancer* 2001;92:2117-2125.
23. Wijnhoven BP, Dinjens WN, Pignatelli M. E-cadherin-catenin cell-cell adhesion complex and human cancer. *Br J Surg* 2000;87(8):992-1005.
24. Vleminckx K, Vakaet L Jr, Mareel M, Fiers W, van Roy F. Genetic manipulation of E-cadherin expression by epithelial tumor cells reveals an invasion suppressor role. *Cell* 1991;66(1):107-19.

25. Georgioli A, Batistatou A, Manolopoulos L, Charalabopoulos K. Role and expression patterns of E-cadherin in head and neck squamous cell carcinoma (HNSCC). *J Exp Clin Cancer Res* 2006;25(1):5-14.
26. Kudo Y, Kitajima S, Ogawa I *et al.* Invasion and metastasis of oral cancer cells require methylation of E-cadherin and/or degradation of membranous beta-catenin. *Clin Cancer Res* 2004;10(16):5455-63.
27. Ghosh S, Munshi HG, Sen R *et al.* Loss of adhesion-regulated proteinase production is correlated with invasive activity in oral squamous cell carcinoma. *Cancer* 2002;95(12):2524-33.
28. Bosch FX, Andl C, Abel U, Kartenbeck J. E-cadherin is a selective and strongly dominant prognostic factor in squamous cell carcinoma: a comparison of E-cadherin with desmosomal components. *Int J Cancer* 2005;114(5):779-90.
29. van der Velden LA. Expression of Cytokeratin Subtypes and Vimentin in Squamous Cell Carcinoma of the Floor of the Mouth and the Mobile Tongue. *Otorhinolaryngol Nova* 2001;11:186-192.
30. Huber MA, Kraut N, Beug H. Molecular requirements for epithelial-mesenchymal transition during tumor progression. *Curr Opin Cell Biol* 2005;17:548-558.
31. Thiery JP. Epithelial-mesenchymal transitions in tumor progression. *Nat Rev Cancer* 2002;2:442-454.
32. de Araujo VC, Pinto Júnior DS, de Sousa SO, Nunes FD, de Araujo NS. Vimentin in oral squamous cell carcinoma. *Eur Arch Otorhinolaryngol* 1993;250(2):105-9.
33. Mandal M, Myers JN, Lippman SM *et al.* Epithelial to mesenchymal transition in head and neck squamous carcinoma: association of Src activation with E-

cadherin down-regulation, vimentin expression, and aggressive tumor features.

Cancer 2008;112(9):2088-100.

34. Hoffmann M, Orlamünder A, Sucher J *et al.* HPV16 DNA in histologically confirmed tumour-free neck lymph nodes of head and neck cancers. *Anticancer Res* 2006;26(1B):663-70.
35. Klussmann JP, Mooren JJ, Lehnen M *et al.* Genetic signatures of HPV-related and unrelated oropharyngeal carcinoma and their prognostic implications. *Clin Cancer Res* 2009;15(5):1779-86.
36. Wieland U, Brockmeyer NH, Weissenborn SJ *et al.* Imiquimod treatment of anal intraepithelial neoplasia in HIV-positive men. *Arch Dermatol* 2006;142:1438-44.
37. Begum S, Gillison ML, Nicol TL, Westra WH. Detection of human papillomavirus-16 in fine-needle aspirates to determine tumor origin in patients with metastatic squamous cell carcinoma of the head and neck. *Clin Cancer Res* 2007;13(4):1186-91.
38. Tanaka N, Odajima T, Ogi K, Ikeda T, Satoh M. Expression of E-cadherin, alpha-catenin, and beta-catenin in the process of lymph node metastasis in oral squamous cell carcinoma. *Br J Cancer* 2003;89(3):557-63.
39. Rimm DL, Sinard JH, Morrow JS. Reduced alpha-catenin and E-cadherin expression in breast cancer. *Lab Invest* 1995;72(5):506-12.
40. Berx G, Staes K, van Hengel J *et al.* Cloning and characterization of the human invasion suppressor gene E-cadherin (CDH1). *Genomics* 1995;26(2):281-9.
41. Jung A, Schrauder M, Oswald U *et al.* The invasion front of human colorectal adenocarcinomas shows co-localization of nuclear beta-catenin, cyclin D1, and p16INK4A and is a region of low proliferation. *Am J Pathol* 2001;159(5):1613-7.

42. Uren A, Fallen S, Yuan H *et al.* Activation of the canonical Wnt pathway during genital keratinocyte transformation: a model for cervical cancer progression. *Cancer Res* 2005;65(14):6199-206.
43. Al Moustafa AE, Foulkes WD, Benlimame N *et al.* E6/E7 proteins of HPV type 16 and ErbB-2 cooperate to induce neoplastic transformation of primary normal oral epithelial cells. *Oncogene* 2004;23(2):350-8.
44. Wassermann S, Scheel SK, Hiendlmeyer E *et al.* p16INK4a is a beta-catenin target gene and indicates low survival in human colorectal tumors. *Gastroenterology* 2009;136(1):196-205.
45. Saegusa M, Hashimura M, Kuwata T, Hamano M, Okayasu I. Induction of p16INK4A mediated by beta-catenin in a TCF4-independent manner: implications for alterations in p16INK4A and pRb expression during trans-differentiation of endometrial carcinoma cells. *Int J Cancer* 2006;119(10):2294-303.
46. Elzagheid A, Buhmeida A, Korkeila E, Collan Y, Syrjanen K, Pyrhonen S. Nuclear beta-catenin expression as a prognostic factor in advanced colorectal carcinoma. *World J Gastroenterol* 2008;14(24):3866-71.
47. Mannic LA. Expression of Cytokeratin Subtypes and Vimentin in Squamous Cell Carcinoma of the Floor of the Mouth and the Mobile Tongue. *Otorhinolaryngol Nova* 2001;11:186-192.

ACKNOWLEDGEMENTS

This work was supported by the program for Research & Education of the University Hospital of Cologne to H.P. Dienes and by funding from the Jean-Uhrmacher-Foundation.

We thank S. Sattler and K. Wendland for their excellent technical assistance.

Bassima Yosef holds a fellowship of the Syrian government.

There are no financial disclosures from any authors. There do not exist any conflicts of interest.

LEGENDS

Figure 1: Localisation of the marker protein β -catenin within carcinoma cells in primary tumors and metastases, original magnification x200. (A) exclusive membranous expression in primary tumor tissue; (B) nuclear expression in primary tumor tissue (short white arrows, exemplarily); (C) combined membranous (long black arrows, exemplarily) and nuclear (short white arrows, exemplarily) expression in primary tumor tissue; (D) combined membranous and nuclear expression in metastasis.

Deleted: exclusive

Figure 2: Distribution of tumor samples being E-cadherin-negative and β -catenin-positive in relation to the patients' HPV status.

Figure 3: Expression of the mesenchymal marker protein vimentin as seen in various differentiation grades of the primary tumor, original magnification x100. (A) G1, endothelial cells and connective tissue (long black arrows) are vimentin positive and carcinoma cells within the tumor tissue (short white arrows) are vimentin negative; (B) G2, scattered vimentin positive carcinoma cells within the tumor tissue (short white arrows); (C) G3, nearly all carcinoma cells are vimentin positive.

Figure 4: Diagram summarizing the main results concerning molecular changes during tumor progression and metastasis of HPV-related and -unrelated tonsillar carcinomas.

Deleted: positive

Deleted: negative

Table 1: Expression of p16, E-cadherin, β-catenin and vimentin in primary tumors and metastases.

Clinicopathological feature	n	p16			E-cadherin			β-catenin			β-catenin localisation				Vimentin		
		-	+	p	-	+	p	-	+	p	mem	nuc	both	p [#]	-	+	p
<i>Total</i>	96	56 (58%)	40 (42%)	>0.05	59 (61%)	37 (39%)	>0.05	1 (1%)	95 (99%)	>0.05	28 (29%)	35 (36%)	33 (34%)	>0.05	54 (56%)	42 (44%)	>0.05
<i>Primary tumors</i>	48	25 (52%)	23 (48%)	0.013[†]	21 (44%)	27 (56%)	<0.001[†]	0 (0%)	48 (100%)	>0.05	15 (31%)	13 (27%)	20 (42%)	0.002[†]	24 (50%)	24 (50%)	>0.05
<i>Metastases</i>	48	31 (65%)	17 (35%)		38 (79%)	10 (21%)		1 (2%)	47 (98%)	13 (27%)	22 (46%)	13 (27%)	30 (63%)		18 (38%)		
<i>p16 + / HPV +</i>	37				22 (60%)	15 (41%)	>0.05	0 (0%)	37 (100%)	>0.05	12 (32%)	17 (46%)	8 (22%)	>0.05	20 (54%)	17 (46%)	>0.05
<i>all others</i>	59				37 (63%)	22 (37%)		1 (2%)	58 (98%)		16 (27%)	18 (31%)	25 (42%)		34 (58%)	25 (42%)	
<i>Primary tumors</i>																	
G1, G1-2, G2	24	13 (54%)	11 (46%)	>0.05	13 (54%)	11 (46%)	>0.05	0 (0%)	24 (100%)	>0.05	6 (25%)	7 (29%)	11 (46%)	>0.05	16 (67%)	8 (33%)	0.021
G2-3, G3	24	12 (50%)	12 (50%)		8 (33%)	16 (67%)	0 (0%)	24 (100%)	9 (38%)	6 (25%)	9 (38%)	8 (33%)	16 (67%)				
<i>p16 + / HPV +</i>	21				10 (48%)	11 (52%)	>0.05	0 (0%)	21 (100%)	>0.05	7 (33%)	9 (43%)	5 (24%)	0.030	11 (52%)	10 (48%)	>0.05
<i>all others</i>	27				11 (41%)	16 (59%)		0 (0%)	27 (100%)		8 (30%)	4 (15%)	15 (56%)			13 (48%)	14 (52%)
<i>Metastases</i>																	
<p16 +="" +<="" hpv="" p=""></p16>	16				12 (75%)	4 (25%)	>0.05	0 (0%)	16 (100%)	>0.05	5 (31%)	8 (50%)	3 (19%)	>0.05	9 (56%)	7 (44%)	>0.05
all others	32				26 (81%)	6 (19%)		1 (3%)	31 (97%)		8 (25%)	14 (44%)	10 (31%)		21 (66%)	11 (34%)	

mem: membranous expression
nuc: nuclear expression
#: for nuclear β-catenin expression
†: by means of a paired Student's t-test
p-value named only if level of significance < 0.05
Percentage values rounded

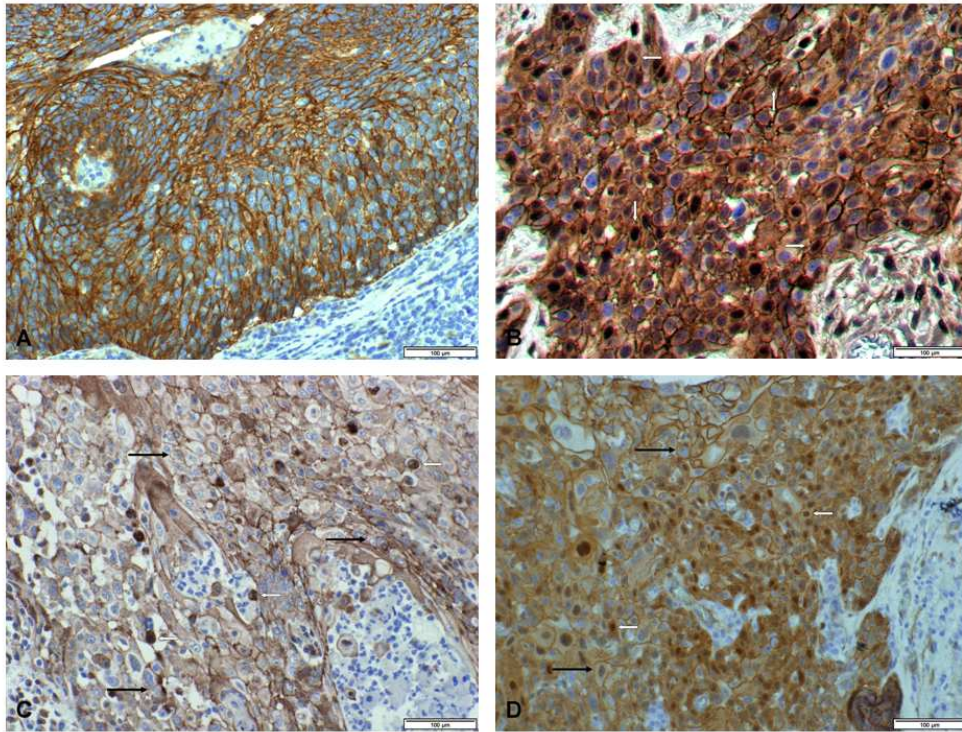


Figure 1
254x190mm (96 x 96 DPI)

Review

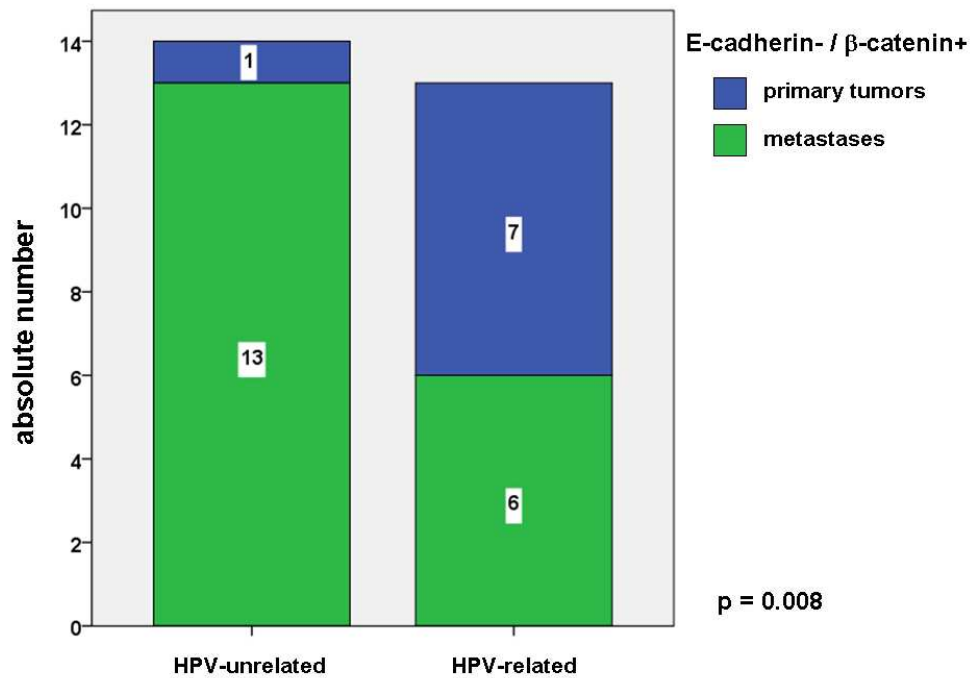


Figure 2
254x190mm (96 x 96 DPI)

review

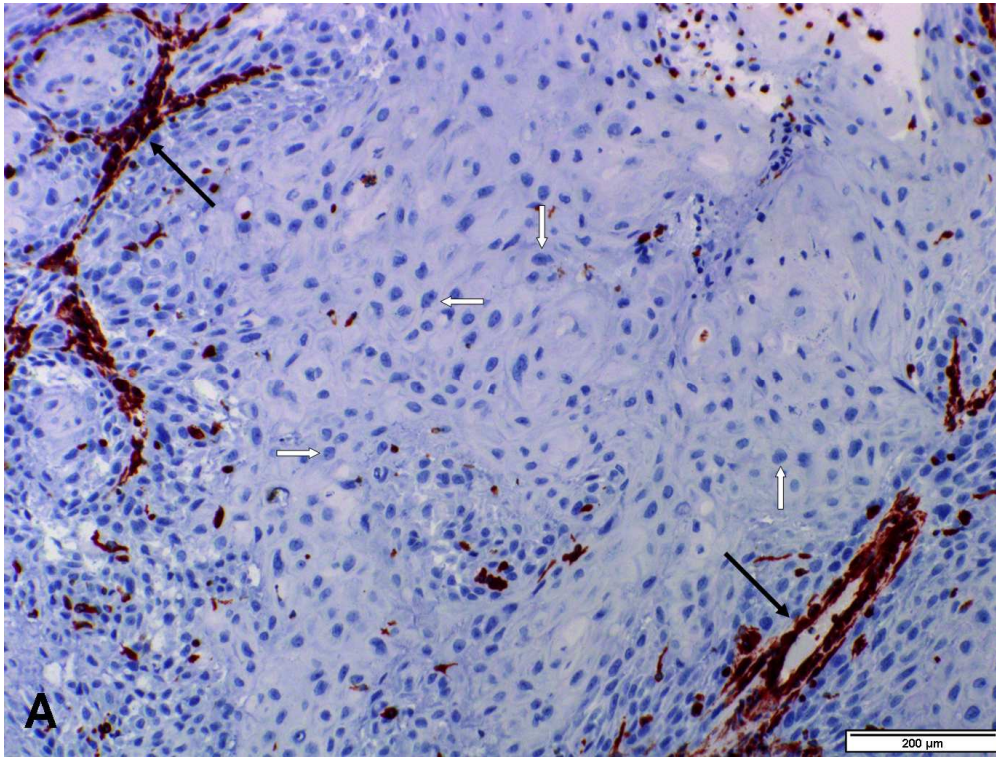


Figure 3 A
233x175mm (150 x 150 DPI)

Review

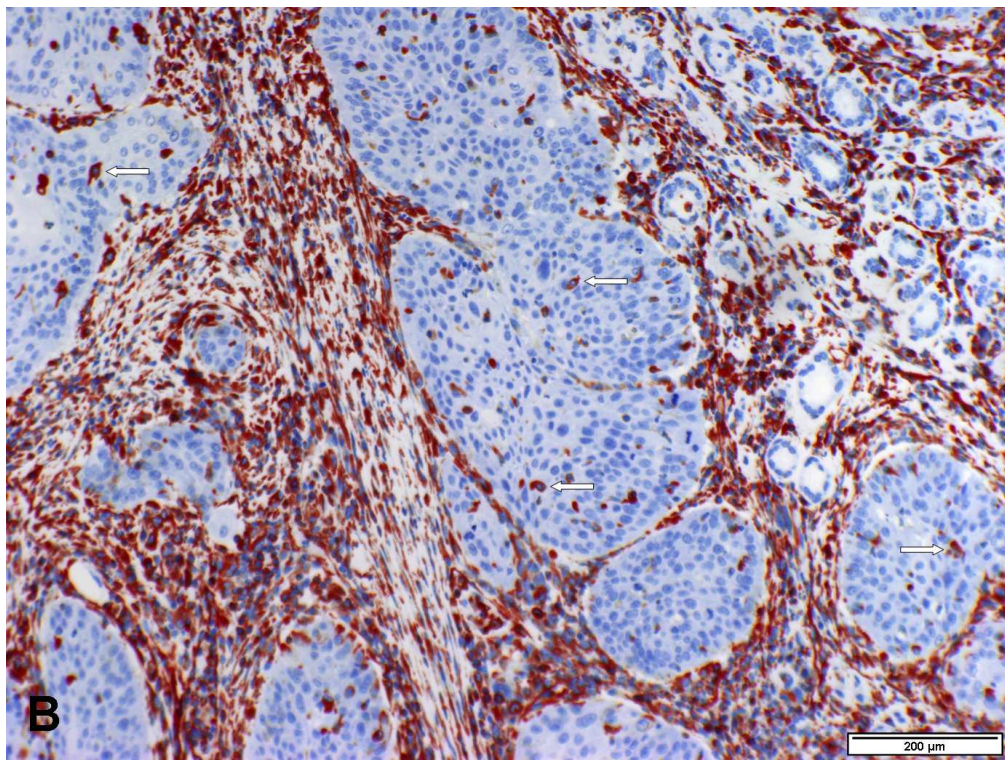


Figure 3 B
233x175mm (150 x 150 DPI)

Review

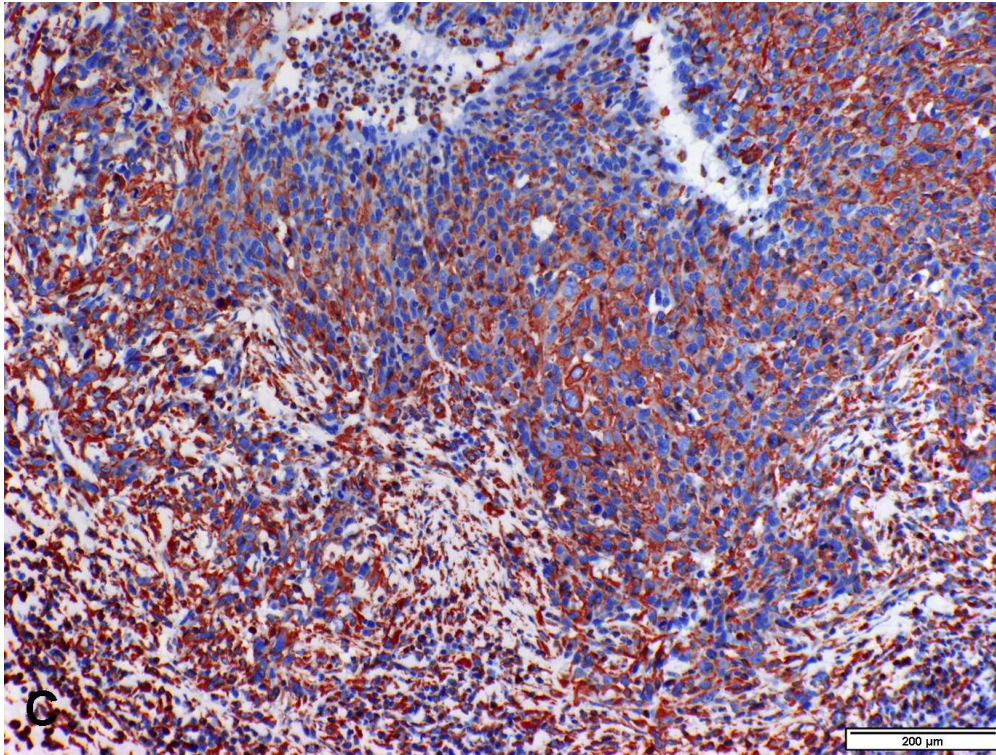


Figure 3 C
233x175mm (150 x 150 DPI)

Review

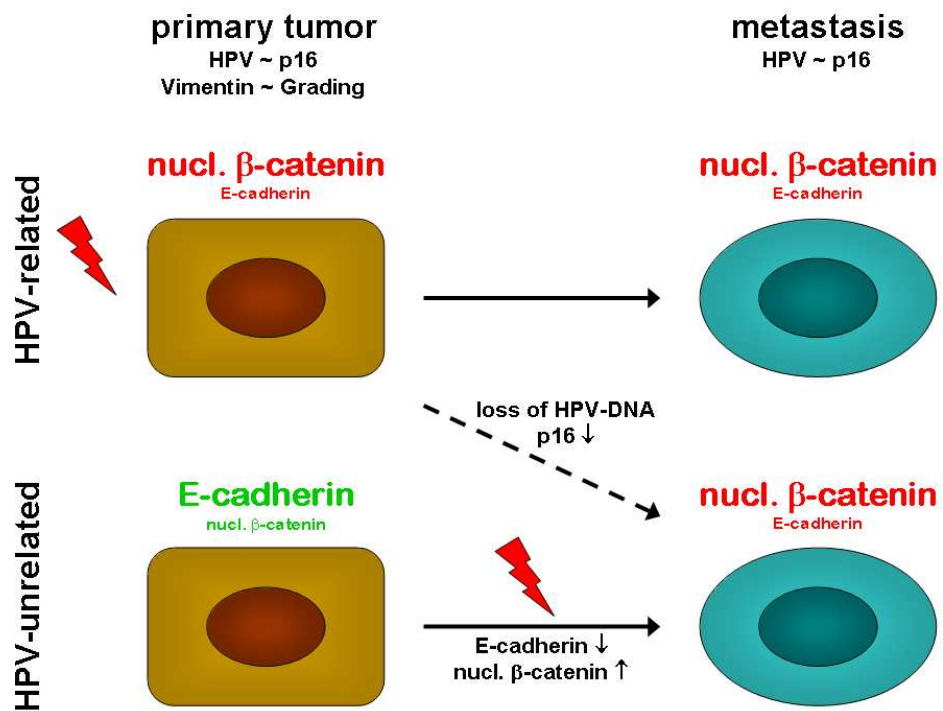


Figure 4
254x190mm (96 x 96 DPI)

Review