HAL
open science

Chronic Sclerosing Sialadenitis (Küttner Tumor) As a Member of IgG4-related Diseases: a Clinicopathological Study of 6 Cases From Central Europe

Jan Laco, Ales Ryska, Petr Celakovsky, Helena Dolezalova, Radovan Mottl, Lubos Tucek

To cite this version:

Jan Laco, Ales Ryska, Petr Celakovsky, Helena Dolezalova, Radovan Mottl, et al.. Chronic Sclerosing Sialadenitis (Küttner Tumor) As a Member of IgG4-related Diseases: a Clinicopathological Study of 6 Cases From Central Europe. Histopathology, 2011, 58 (7), pp.1157. 10.1111/j.1365-2559.2011.03833.x . hal-00626288

HAL Id: hal-00626288

https://hal.science/hal-00626288v1

Submitted on 25 Sep 2011

HAL is a multi-disciplinary open access archive for the deposit and dissemination of scientific research documents, whether they are published or not. The documents may come from teaching and research institutions in France or abroad, or from public or private research centers.

L'archive ouverte pluridisciplinaire **HAL**, est destinée au dépôt et à la diffusion de documents scientifiques de niveau recherche, publiés ou non, émanant des établissements d'enseignement et de recherche français ou étrangers, des laboratoires publics ou privés.

Histopathology

Chronic Sclerosing Sialadenitis (Küttner Tumor) As a Member of IgG4-related Diseases: a Clinicopathological Study of 6 Cases From Central Europe

Journal:	*Histopathology*
Manuscript ID:	HISTOP-04-10-0251.R2
Wiley - Manuscript type:	Original Article
Date Submitted by the Author:	10-Aug-2010
Complete List of Authors:	Laco, Jan; Charles University Faculty of Medicine and Faculty Hospital in Hradec Kralove, The Fingerland Department of Pathology Ryska, Ales; Charles University Faculty of Medicine and Faculty Hospital in Hradec Kralove, The Fingerland Department of Pathology Celakovsky, Petr; Charles University Faculty of Medicine and Faculty Hospital in Hradec Kralove, Department of Otorhinolaryngology Dolezalova, Helena; Charles University Faculty of Medicine and Faculty Hospital in Hradec Kralove, Department of Dentistry Mottl, Radovan; Charles University Faculty of Medicine and Faculty Hospital in Hradec Kralove, Department of Dentistry Tucek, Lubos; Charles University Faculty of Medicine and Faculty Hospital in Hradec Kralove, Department of Dentistry
Keywords:	salivary gland, chronic sclerosing sialadenitis, Küttner tumor, IgG4-plasma cells

SCHOLARONE™
Manuscripts

Chronic Sclerosing Sialadenitis (Küttner Tumor) As a Member of IgG4-related Diseases: a Clinicopathological Study of 6 Cases From Central Europe

Jan Laco[1] · Ales Ryska[1] · Petr Celakovsky[2] · Helena Dolezalova[3] · Radovan Mottl[3] · Lubos Tucek[3]

[1]The Fingerland Department of Pathology, Charles University Faculty of Medicine and Faculty Hospital in Hradec Kralove, Czech Republic
[2]Department of Otorhinolaryngology, Charles University Faculty of Medicine and Faculty Hospital in Hradec Kralove, Czech Republic
[3]Department of Dentistry, Charles University Faculty of Medicine and Faculty Hospital in Hradec Kralove, Czech Republic

Running title: Sclerosing Sialadenitis (Küttner Tumor)

Keywords: salivary gland, chronic sclerosing sialadenitis, Küttner tumor, IgG4-plasma cells

For Peer Review

Corresponding author:
Jan Laco, M.D., Ph.D.
The Fingerland Department of Pathology
Faculty Hospital in Hradec Kralove
Sokolska 581
500 05 Hradec Kralove
Czech Republic
Phone: 00420-495 832 548
Fax: 00420-495 832 004
E-mail: lacoj@lfhk.cuni.cz

Abstract

Chronic sclerosing sialadenitis (CSS) has been recently proposed to be member of IgG4-related disease in Japanese and American series. The aim of our study was to validate these results in a cohort of European patients.

Our CSS-series includes 4 females and 2 males, aged 32-76 years, all presenting with unilateral swelling of submandibular gland. Microscopically, all CSS-cases showed similar morphology – preservation of lobular architecture accentuated by cellular fibrous bands, dense lymphoplasmacytic inflammation and varied acinar atrophy. Ductal lymphocytes were detected in 3 cases. In 5 cases, the presence of intraductal secretory material accompanied by parenchymal neutrophils was observed. Obliterative phlebitis was seen in 3 cases. The inflammatory infiltrate was composed of T- and B-lymphocytes and polyclonal plasma cells. Median number of IgG-positive plasma cells per 1 HPF was 157; median number of IgG4-positive plasma cells per 1 HPF was 133. Median value of IgG4/IgG ratio was 0.84.

Ours is the first European series to prove that CSS belongs to the family of IgG4-related disease. Unlike prior studies, we found in CSS rarely described ductal lymphocytes and parenchymal neutrophils. CSS displays consistent morphology, with increased numbers of IgG4-positive plasma cells and should be regarded as member of IgG4-related disease group.

For Peer Review

Introduction

Chronic sclerosing sialadenitis (CSS), also known as "Küttner tumor", is the most common disease of the submandibular gland affecting middle-aged and elderly patients with slight male predominance.[1,2] It frequently manifests as a firm, painless swelling, clinically mimicking salivary neoplasm.[3] Sialomicroliths, which accumulate during secretory inactivity in normal salivary glands, are thought to play an important role in the pathogenesis of CSS.[4,5] Based on the results of two recent studies analysing a total of 25 cases,[6,7] it has been proposed that CSS may be a part of the spectrum of IgG4-related disease. IgG4-related disease is an expanding and frequently underdiagnosed condition comprising entities such as retroperitoneal and mediastinal fibrosis, Riedel´s thyroiditis, inflammatory pseudotumor of the orbit and some forms of interstitial pneumonia and tubulointerstitial nephritis (see review by Bateman and Deheragoda[8]).

Since the two aforementioned studies analyzed samples from Japanese and American populations[6,7] and there is no series from the European region, the aim of our study was to compare reported results with findings from a central European cohort and eventually to extend the spectrum of clinicopathologic features of IgG4-related disease.

For Peer Review

Materials and Methods

A total of 105 cases of chronic sialadenitis of the submandibular gland diagnosed over a period of 13 years (1998-2010) were retrieved from the archives of the Fingerland Department of Pathology. Six (5.7%) of the cases were originally diagnosed as chronic sclerosing sialadenitis (CSS)/Küttner tumor using the following criteria: presence of intensive lymphoplasmacellular inflammation, extensive fibrosis and acinar atrophy, without formation of obvious lymphoepithelial islands.[1] As controls, we examined 6 age and gender-matched consecutive cases of chronic sialadenitis-not otherwise specified (CSNOS), originally diagnosed in cases without features indicative of CSS (see above) and without obvious lymphoepithelial islands formation. Clinical information of the patients was obtained from clinical charts.

The tissue specimens were obtained during surgery performed at the Departments of Otorhinolaryngology and Dentistry, Medical Faculty and Faculty Hospital, Hradec Kralove. The samples were immediately fixed in 10% formalin, routinely processed, embedded in paraffin, and stained with hematoxylin-eosin and elastica-van Gieson. Paraffin-embedded tissue blocks (median 4 blocks per case; range 2-7) were available for immunohistochemical analysis in all cases.

Indirect immunohistochemistry was performed using monoclonal/polyclonal antibodies against CD20 (L26, 1:300), CD79α (JCB117, 1:100), CD3 (polyclonal, 1:200), CD138 (MI15, 1:50), immunoglobulin light chain kappa (BJK) (R10-21-F3, 1:400), immunoglobulin light chain lambda (BJL) (N10/2, 1:25), IgG (polyclonal, FLEX), IgG4 (HP6025, 1:100), and bcl-6 (PG-B6p, 1:5). The source of IgG4 was Invitrogen (Camarillo, USA), of BJL Diagnostic BioSystems (Pleasanton, USA), and that of the remaining antibodies was Dako (Glostrup, Denmark). Antigen retrieval was performed in a water bath for 40 minutes at 97°C in the target retrieval buffers at different pH values – pH 6.0 (buffer S1700) for CD20, CD79α, CD138, BJK and BJL and pH 9.9 (buffer S3308) for CD3, IgG4 and bcl-6. Endogenous peroxidase activity was inhibited by immersing the sections in 3% hydrogene peroxide. Finally the sections were incubated with EnVision™ Dual Link System-HRP (Dako). The reaction was visualized using diaminobenzidine. For detection of IgG, a ready-to-use system - EnVision™ FLEX Target Retrieval Solution High pH (Dako) was utilized.

The histopathologic evaluation was perfomed according to the guidelines proposed by Geyer *et al.*[7] Phlebitis was defined as perivenular inflammation; if associated with progressive destruction of the venular wall and obliteration of the lumen, it was classified as obliterative

For Peer Review

phlebitis. In addition, the presence of ductal lymphocytes (i.e. lymphocytes within the epithelium of smaller ducts without formation of obvious lymphoepithelial islands), parenchymal neutrophils (i.e. neutrophils within smaller ducts), intraductal secretory material with microcalcifications and periductal granulomas was recorded. The numbers of IgG and IgG4-positive plasma cells in three high-power fields (HPF, 10x eyepiece and 40x lens) were counted in the areas in which the inflammation was most intense. The counting was done in the same fields on the slides stained for IgG and IgG4. An IgG4/IgG ratio was calculated for each case.

As there were just 6 CSS-cases, only basic descriptive statistical analysis was performed.

For Peer Review

Results

Clinical data

The clinical data of the patients are shown in Table 1. The CSS series comprises 4 females and 2 males aged 32-76 years (mean 57±16 years; median 59 years). One of the patient with CSS had a history of Hashimoto thyroiditis with hypothyroidism. In the CSNOS group, there was one patient with Hashimoto thyroiditis and another with diabetes mellitus, type 1. None of the patients in either group had a history of IgG4-related disease.

All the CCS patients presented with a 2 to 9 months (mean 6±2 months; median 6 months) history of neck swelling, which was painful in only one case. The swelling was unilateral in all patients. The left submandibular gland was involved in 4 cases and the right, in 2 cases. None of the patients developed parotid gland lesions. Cervical lymphadenopathy was present in 2 patients. Serum IgG4 level was not measured in any of the patients. All of the patients underwent total submandibulectomy with local lymphadenectomy in 2 cases. There were 4 CSS patients with a clinical diagnosis of sialadenitis-not otherwise specified and 2 with sialolithiasis.

Although none of the patients received corticosteroid therapy postoperatively, none of them showed any of the IgG4-related disease during the follow-up period, which ranged from 14-89 months (mean 63 ± 26 months; median 69 months).

Gross findings

The resected submandibular glands of patients with CSS measured 45-60 mm in largest diameter. In one case, a sialolith measuring 4 mm was identified.

Microscopic findings

The microscopic findings are summarized in Table 2. In all cases, the inflammation was limited to the salivary gland without extension to periglandular tissue.

All the CSS cases showed similar morphologic features – preservation of lobular architecture, dense lymphoplasmacellular inflammation and variable degree of acinar atrophy and loss. In 3/6 of the cases, the entire gland was diffusely involved while in the remaining cases, the changes were focal, involving 70-90% of the gland parenchyma. The lobules were separated by cellular fibrous bands of varied thickness composed of plump fibroblasts intermixed with small lymphocytes and plasma cells (Fig. 1). The inflammatory infiltrate was severe in most cases and showed periductal and intralobular distribution. Plasma cell clusters were frequently present. Follicular hyperplasia was a consistent feature and it was considered

For Peer Review

to be florid in 3 cases. Ductal lymphocytes in intralobular ducts were seen in 3 cases (Fig 2). Ductal structure was generally preserved. Although there were some areas showing changes suggestive of lymphoepithelial island development, no well formed lymphoepithelial islands were seen. In 5/6 cases, dense eosinophilic secretory material was present within small intralobular ducts/acini. This was frequently accompanied by the presence of parenchymal neutrophils with occasional formation of intraluminal neutrophilic collections (Fig. 3). A microlith, located in a small intralobular duct, was seen in only one case. Eosinophils were generally inconspicuous and periductal granulomas were absent. In 4 cases, non-obliterative phlebitis of interlobular veins was observed and in 3 cases, obliterative phlebitis, confirmed using elastica staining, was seen (Fig. 4).

The CSNOS cases also showed preservation of lobular architecture, lymphoplasmacellular inflammation and varied degrees of acinar loss and atrophy. The changes were diffuse in 4 cases and focal in 2 (affecting 30% and 60% of the gland parenchyma in the 1st and 2nd cases, respectively). Unlike CSS, the fibrous bands in CSNOS were rather hypocellular and hyalinized without conspicuous inflammatory cells. The lymphoplasmacellular infiltrate was mild to moderate and, like CSS, had periductal and intralobular distribution. Follicular hyperplasia was seen in 4/6 cases but was never florid. No ductal lymphocytes were observed. In 2/6 cases, dense eosinophilic secretory material was present in small intralobular ducts. This was accompanied by the presence of parenchymal neutrophils in one case. Neither eosinophils nor periductal granulomas were present in any case. Non-obliterative and obliterative phlebitis were both absent.

Immunohistochemically, the lymphocytic infiltrate in both CSS and CSNOS was composed of both CD20/CD79α-positive B-lymphocytes and CD3-positive T-lymphocytes. The former formed lymphoid follicles while the latter were dispersed diffusely within the gland. The germinal center cells expressed bcl-6 protein. The CD138-positive plasma cells were polyclonal, expressing both kappa and lambda immunoglobulin light chains. The numbers of IgG- and IgG4-positive plasma cells per 1 HPF (Figs. 5 and 6) and the IgG4/IgG ratios are detailed in Table 2. In general, all three values were higher in CSS than in CSNOS.

For Peer Review

Discussion

Since the time the concept of IgG4-related disease was introduced by Yoshida *et al.*[9] in their work regarding autoimmune pancreatitis, several other entities have been recognized as being members of the IgG4-related disease family. These entities include, besides autoimmune pancreatitis,[10] retroperitoneal fibrosis (Ormond´s disease),[11] mediastinal fibrosis,[12] sclerosing thyroiditis,[13] certain forms of chronic gastritis, colitis and cholecystitis,[14] and inflammatory aortic aneurysm[15,16] Other examples are orbital inflammatory pseudotumor and certain forms of interstitial pneumonia, tubulointerstitial nephritis, chronic prostatitis, hepatitis, etc.[8] It has become evident, that all these conditions may manifest synchronously and/or metachronously even in the absence of autoimmune pancreatitis.[17] Interestingly, none of our patients had a history of IgG4-related disease. Neither did they develop other forms of IgG4-related disease during follow-up period.

The precise pathogenesis of IgG4-related disease remains poorly understood; no triggers have yet been identified. IgG4 is the rarest IgG subtype, accounting for up to 6% of total serum IgG.[18] Because of its intrinsic weakness caused by variable loss of covalent interaction between the heavy chains, IgG4 shows poor antigen binding and complement activation. About 75% of patients with some form of IgG4-related disease develop both increased serum IgG4 levels and high numbers of tissue IgG4-producing plasma cells, the latter being identified using immunohistochemistry.[8] While the originally proposed cut-off of > 10 IgG4-positive plasma cells per 1 high power field (HPF) was accepted as diagnostic for autoimmune pancreatitis,[19] recently suggested level of > 20 IgG4-positive plasma cells per 1 HPF was shown to increase the sensitivity and specificity to 43% and 100%, respectively.[10] Still it is unclear as to whether the IgG4-producing plasma cells play an etiological role or if they simply represent a diagnostically useful marker.

Most patients with IgG4-related disease would benefit from corticosteroid therapy.[8]

Chronic sclerosing sialadenitis (CSS) was first described as a cause of unilateral swelling of the submandibular gland by Küttner in 1896, hence the term “Küttner tumor“. As originally described, it predominantly involves the submandibular glands. CSS usually presents in middle aged or elderly patients with slight male predominance.[1] It frequently manifests as a firm swelling, clinically mimicking salivary gland neoplasm. Sialomicroliths, which accumulate during secretory inactivity of normal salivary glands, are considered to be etiologic factors in the development of CSS. Sialoliths on the other hand are thought to develop secondary to the sialadenitis.[4,5]

For Peer Review

To the best of our knowledge, the literature contains reports of only 28 cases of CSS recognized as IgG4-related disease. These 28 cases are from 2 larger series[6,7] reporting 13 and 12 cases respectively, 1 report of 2 cases,[20] and a case report describing salivary duct carcinoma arising in a background of CSS.[21] These cases include 1 Chinese, 13 American and 14 Japanese patients. No data on the European population is available so far. In general, the clinicopathological findings described in previous studies are in agreement with our current report. Thus, including our 6 cases, there are a total of 34 cases of CSS in the literature proven to be IgG4-related disease.

Of these 34 cases, 19 were male and 15 female, aged 27-76 years (mean 62 years). Two of them had underlying autoimmune disease (1 with Graves disease,[6] another, from our study, with Hashimoto thyroiditis). Nine patients experienced extrasalivary manifestation of IgG4-related disease with multiorgan involvement in 3 patients.[6] Sclerosing pancreatitis was the most common extrasalivary presentation (in 5 patients). The other forms of IgG4-related disease seen were sclerosing cholangitis, dacryadenitis, prostatitis, "lung and bilateral renal nodules", retroperitoneal fibrosis and generalized lymphadenopathy. Only 1 case of CSS occured in the parotid gland,[6] suggesting that the principal site of involvement is the submandibular gland. Cervical lymphadenopathy was encountered in 8 patients. When administered, corticosteroid therapy was beneficial for a majority of the CSS-patients.

The microscopic appearance of CSS was similar in all cases with preservation of lobular architecture, interlobular cellular fibrosis and intensive lymphoplasmacellular infiltrate with various degrees of acinar atrophy. The high cellularity of the interlobular fibrous tissue appears to be a characteristic feature of CSS as it contrasts with the rather hypocellular hyalinized fibrous bands without significant numbers of inflammatory cells seen in CSNOS. The inflammatory infiltrate was regarded to be severe in most cases of CSS with the presence of large activated follicles with germinal centres (florid follicular hyperplasia). In addition, both non-obliterative and obliterative forms of phlebitis were found in most of the CCS cases, the latter being easier appreaciated using elastica staining.

The less frequently observed findings included ductal lymphocytes (sometimes referred to as lymphocytic exocytosis) somewhat similar to that of developing lymphoepithelial islands. Well formed lymphoepithelial islands[22] (characteristic but not necessarily pathognomonic for Sjögren-type sialadenitis) were seen in only 2 cases[7] of the 34 cases. Parenchymal neutrophils (sometimes referred to as granulocytic epithelial lesion) with eosinophilic secretory material, presumably mucin, within small ducts/acini were sometimes seen. In addition, occasional microlith formation was observed.

For Peer Review

In one of our cases, a small stone was found on gross examination. We hypothesize that stones may develop in the setting of CSS, probably as a result of altered saliva production due to acinar injury. Therefore, all cases of "sialolithiasis" featuring any of the above listed findings should be tested for presence of IgG4-positive plasma cells.

The number of IgG4-positive plasma cells was consistently highly elevated in our cases as in all previous reports.[6,7,20,21] In the previous reports, the count of IgG4-positive plasma cells per 1 HPF ranged from 62 to 608 (mean about 180 / 1HPF) and in our study it ranged from 62 to 235 (mean 138 / 1HPF). In the previous reports, the IgG4/IgG ratio ranged from 0.40 to 1.00 (mean about 0.77) while in our study, it ranged from 0.61 to 0.92 (mean 0.79). These values are higher than the values from the control cases[6,7] in which the number of IgG4-positive plasma cells per 1 HPF did not exceed 44 (in our series 23) and the IgG4/IgG ratio 0.14 (in our series 0.26). Based on these findings, the cut-off > 50 IgG4-positive plasma cells per 1 HPF appears to be a reasonable threshold for the diagnosis of CSS, and produces a sensitivity and specificity of 100%.

In summary, we present results from 6 European cases of CSS which support and confirm findings from previous studies. CSS should be regarded as a part of the spectrum of IgG4-related disease. All cases of sialadenitis and/or sialolithiasis featuring any of the above mentioned histological findings should be tested for the presence of IgG4-producing plasma cells as the patients should be followed up to enable early detection of possible subsequent extrasalivary manifestations of IgG4-related disease. A majority of such patients would benefit from corticosteroid therapy.

For Peer Review

Acknowledgements

The authors thank Mrs. M. Zakova for her excellent technical support and Dr. F.A. Sobande for English language correction.

Supported by Research Project of the Ministry of Health of the Czech Republic No. 00179906.

For Peer Review

References

1. Ellis GL, Auclair PL. Tumor-like conditions. In Ellis GL, Auclair PL eds. *Tumors of the Salivary Glands.* AFIP Atlas of Tumor Pathology, 4th Series, Fascicle 9. Washington, DC: Armed Forces Institute of Pathology, 2008;481-514.

2. Isacsson G, Ahlner B, Lundquist PG. Chronic sialadenitis of the submandibular gland: a retrospective study of 108 cases. *Arch. Otorhinolaryngol.* 1981;**232**:91-100.

3. Chan JK. Kuttner tumor (chronic sclerosing sialadenitis) of the submandibular gland: an underdiagnosed entity. *Adv. Anat. Pathol.* 1998;**5**:239-251.

4. Harrison JD, Epivatianos A, Bhatia SN. Role of microliths in the aetiology of chronic submandibular sialadenitis: a clinicopathological investigation of 154 cases. *Histopathology* 1997;**31**:237-251.

5. Harrison JD. Causes, natural history, and incidence of salivary stones and obstructions. *Otolaryngol. Clin. North Am.* 2009;**42**:927-947.

6. Kitagawa S, Zen Y, Harada K *et al.* Abundant IgG4-positive plasma cell infiltration characterizes chronic sclerosing sialadenitis (Küttner´s tumor). *Am. J. Surg. Pathol.* 2005;**29**:783-791.

7. Geyer JT, Ferry JA, Harris NL *et al.* Chronic sclerosing sialadenitis (Küttner tumor) is an IgG4-associated disease. *Am. J. Surg. Pathol.* 2010;**34**:202-210.

8. Bateman AC, Deheragoda MG. IgG4-related systemic sclerosing disease – an emerging and under-diagnosed condition. *Histopathology* 2009;**55**:373-383.

9. Yoshida K, Toki F, Takeuchi T, Watanabe S, Shiratori K, Hayashi N. Chronic pancreatitis caused by an autoimmune abnormality: proposal of the concept of autoimmune pancreatitis. *Dig. Dis. Sci.* 1995;**40**:1561-1568.

10. Klöppel G, Sipos B, Zamboni G, Kojima M, Morohoshi T. Autoimmune pancreatitis: histo- and immunopathological features. *J. Gastroenterol.* 2007;**42** (Suppl. XVIII): 28-31.

11. Kamisawa T, Matsukawa M, Ohkawa M. Autoimmune pancreatitis associated with retroperitoneal fibrosis. *JOP* 2005;**6**:260-263.

12. Zen Y, Sawazaki A, Miyayama S, Notsumata K, Tanaka N, Nakanuma Y. A case of retroperitoneal and mediastinal fibrosis exhibiting elevated levels of IgG4 in the absence of sclerosing pancreatitis (autoimmune pancreatitis). *Hum. Pathol.* 2006;**37**:239-243.

13. Komatsu K, Hamano H, Ochi Y *et al.* High prevalence of hypothyroidism in patients with autoimmune pancreatitis. *Dig. Dis. Sci.* 2005;**50**:1052-1057.

14. Kamisawa T, Funata N, Hayashi Y *et al.* A new clinicopathological entity of IgG4-related autoimmune disease. *J. Gastroenterol.* 2003;**38**:982-984.

For Peer Review

15. Sakata N, Tashiro T, Uesugi N *et al.* IgG4-positive plasma cells in inflammatory abdominal aortic aneurysm: the possibility of an aortic manifestation of IgG4-related sclerosing disease. *Am. J. Surg. Pathol.* 2008;**32**:553-559.

16. Ishida M, Hotta M, Kushima R, Asai T, Okabe H. IgG4-related inflammatory aneurysm of the aortic arch. *Pathol. Int.* 2009;**59**:269-273.

17. Kamisawa T, Okamoto A. IgG4-related sclerosing disease. *World J. Gastroenterol.* 2008;**14**:3948-3955.

18. Van der Zee JS, Aalberse RC. Immunochemical characteristics of IgG4 antibodies. *N. Engl. Reg. Allergy Proc.* 1988;**9**:31-33.

19. Kamisawa T, Funata N, Hayashi Y *et al.* Close relationship between autoimmune pancreatitis and multifocal fibrosclerosis. *Gut* 2003;**52**:683-687.

20. Abe T, Sato T, Tomaru Y *et al.* Immunoglobulin G4-related sclerosing sialadenitis: report of two cases and review of the literature. *Oral Surg. Oral Med. Oral Pathol. Oral Radiol. Endod.* 2009;**108**:544-550.

21. Gill J, Angelo N, Yeong ML, McIvor N. Salivary duct carcinoma arising in IgG4-related autoimmune disease of the parotid gland. *Hum. Pathol.* 2009;**40**:881-886.

22. Ihrler S, Zietz C, Sendelhofert A, Riederer A, Löhrs U. Lymphoepithelial duct lesions in Sjögren-type sialadenitis. *Virchows Arch.* 1999;**434**:315-323.

For Peer Review

Tables

Table 1 Clinical data of the patients

	CSS (n = 6)	CSNOS (n = 6)
Sex (female : male)	4 : 2	4 : 2
Age (years) (mean ± SD)	57 ± 16	60 ± 10
Autoimmune disorder	1 (HT)	2 (DM, HT)
Symptoms duration (months) (mean ± SD)	6 ± 2	3 ± 2
Laterality (left : right)	4 : 2	3 : 3
Cervical lymphadenopathy	2	3

Abbrev.: CSS = chronic sclerosing sialadenitis; CSNOS = chronic sialadenitis-not otherwise specified; DM = diabetes mellitus, type 1; HT = Hashimoto thyroiditis; SD = standard deviation

For Peer Review

Table 2 Microscopic and immunohistochemical findings

	CSS (n = 6)	CSNOS (n = 6)
Involvement of the gland (focal : diffuse)	3 : 3	2 : 4
Cellular interlobular fibrosis	6	0
Hypocellular interlobular fibrosis	0	6
Periductal inflammation	6	3
Marked intralobular inflammation with plasma cells	6	3
Phlebitis	4	0
Obliterative phlebitis	3	0
Follicular hyperplasia	6	4
Florid follicular hyperplasia	3	0
Ductal lymphocytes	3	0
Parenchymal neutrophils	3	1
Intraductal dense eosinophilic secretory material	5	2
IgG plasma cell count / 1 HPF (median; range; mean ± SD)	157 (95-255) 167 ± 63	104 (50-132) 100 ± 30
IgG4 plasma cell count / 1 HPF (median; range; mean ± SD)	133 (62-235) 138 ± 70	9 (6-23) 12 ± 7
IgG4 / IgG ratio (median; range; mean ± SD)	0.84 (0.61-0.92) 0.79 ± 0.13	0.11 (0.06-0.26) 0.13 ± 0.08

Abbrev.: CSS = chronic sclerosing sialadenitis; CSNOS = chronic sialadenitis-not otherwise specified; HPF = high power field; SD = standard deviation

For Peer Review

Figure legends

Fig. 1 Dense chronic inflammation within lobules which are separated by variably thick fibrous septa in CSS (HE, original magnification ×40)

Fig. 2 Ductal lymphocytes – presence of intraepithelial lymphocytes resembling developing lymphoepithelial island in CSS (HE, original magnification ×300)

Fig. 3 Parenchymal neutrophils – small collections of neutrophils and dense eosinophilic secretory material in very atrophic parenchyma in CSS (HE, original magnification ×400)

Fig. 4 Obliterative phlebitis may be easily overlooked in the inflammatory background in CSS (HE, original magnification ×200). Inset: Elastica staining facilitates its recognition (original magnification ×200)

Fig. 5 Numerous IgG-positive plasma cells in CSS (original magnification ×400)

Fig. 6 Numerous IgG4-positive plasma cells in CSS (original magnification ×400)

For Peer Review

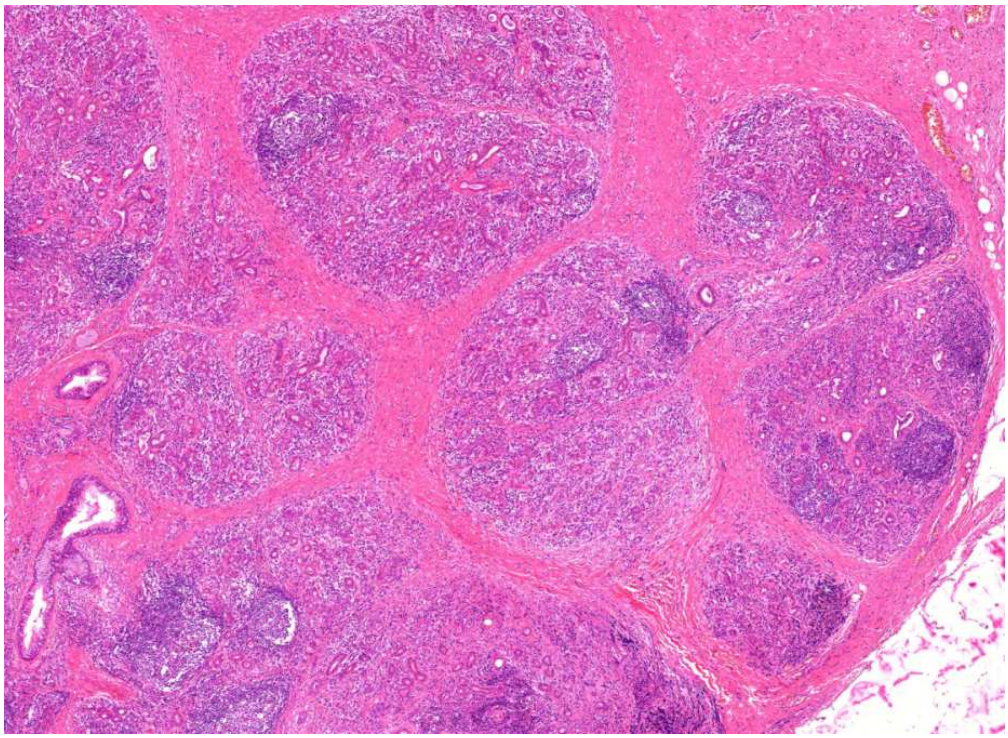

Fig. 1 Dense chronic inflammation within lobules which are separated by variably thick fibrous septa in CSS (HE, original magnification x40)
245x178mm (96 x 96 DPI)

Review

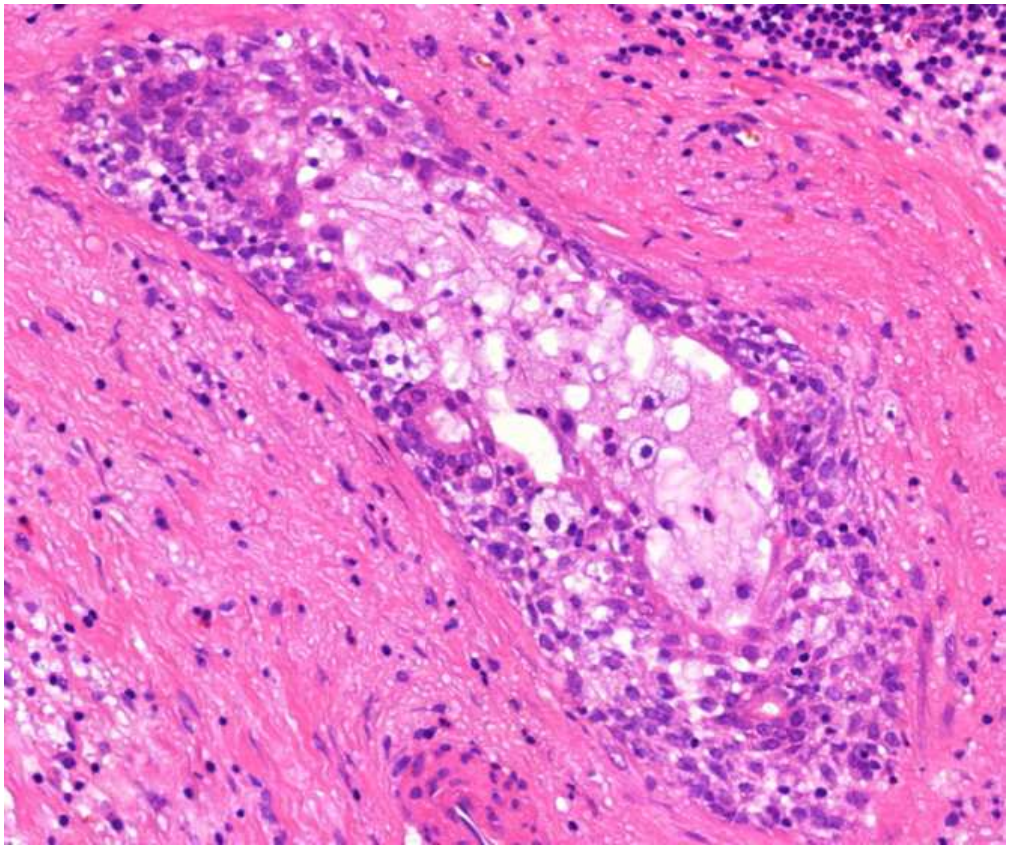

Fig. 2 Ductal lymphocytes – presence of intraepithelial lymphocytes resembling developing lymphoepithelial island in CSS (HE, original magnification x300)
176x148mm (96 x 96 DPI)

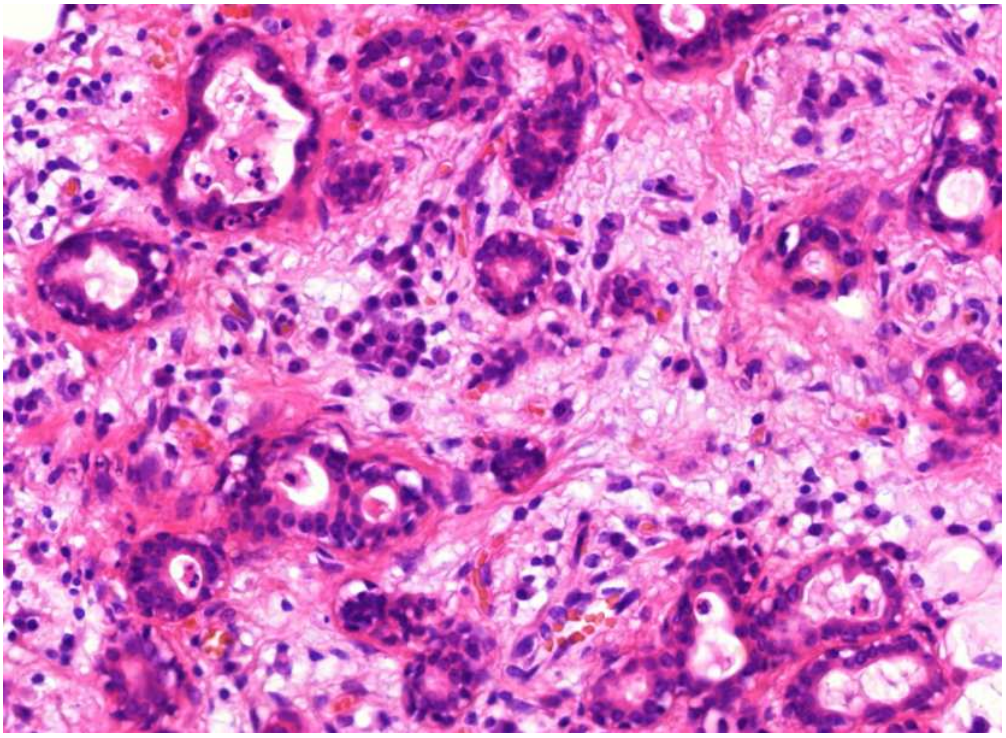

Fig. 3 Parenchymal neutrophils – small collections of neutrophils and dense eosinophilic secretory material in very atrophic parenchyma in CSS (HE, original magnification x400)
219x160mm (96 x 96 DPI)

eview

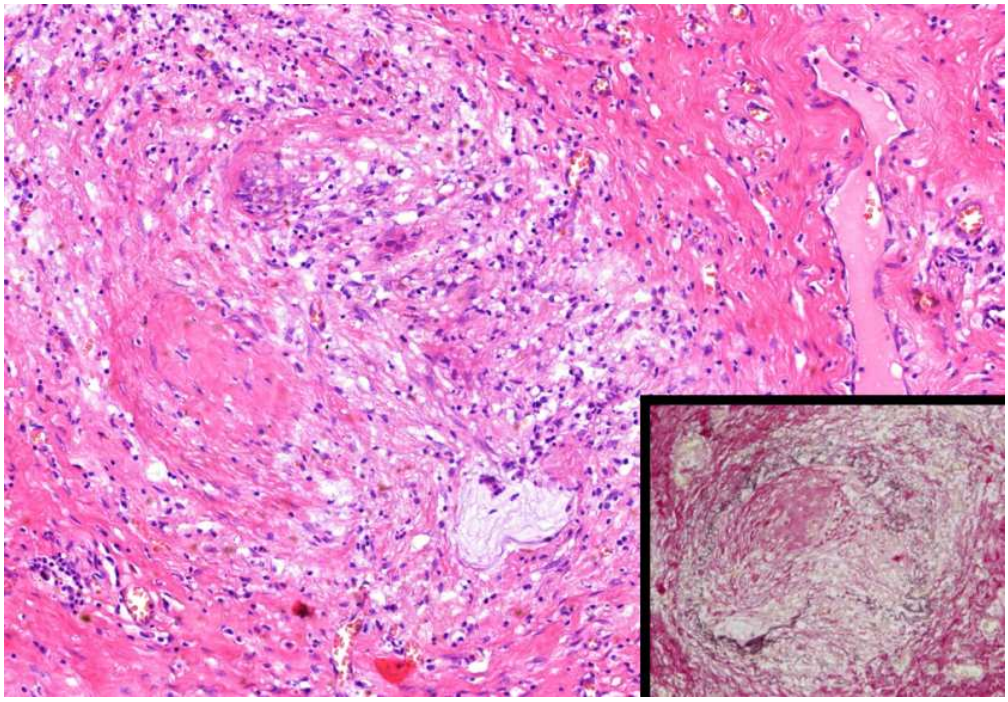

Fig. 4 Obliterative phlebitis may be easily overlooked in the inflammatory background in CSS (HE, original magnification x200). Inset: Elastica staining facilitates its recognition (original magnification x200)
221x153mm (96 x 96 DPI)

eview

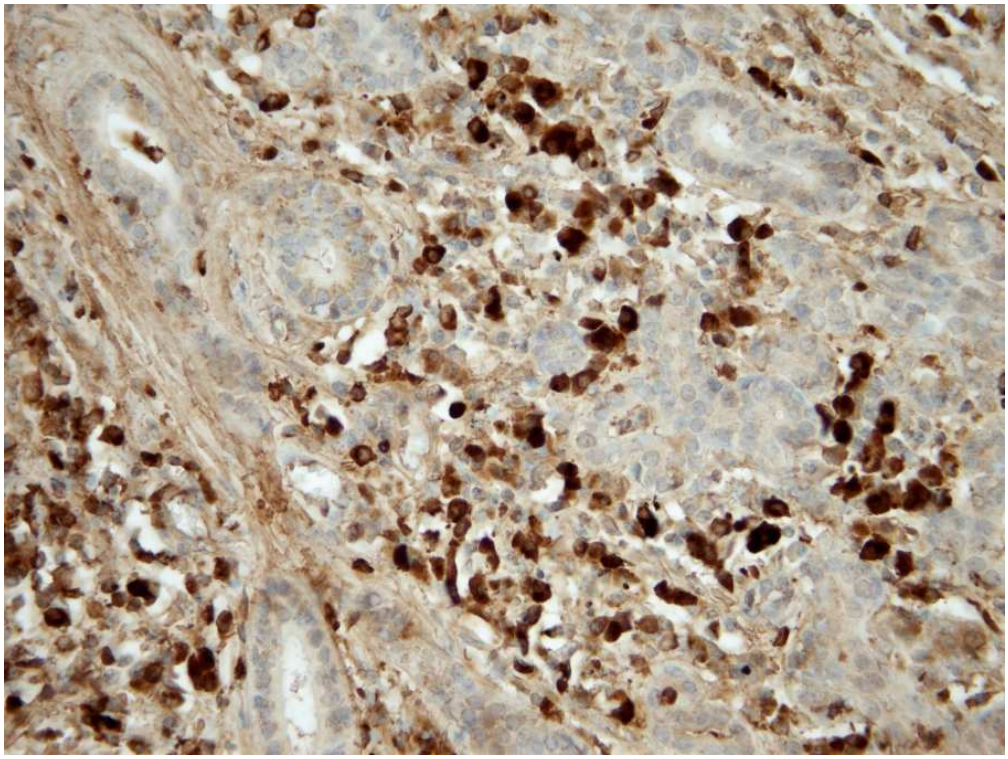

Fig. 5 Numerous IgG-positive plasma cells in CSS (original magnification x400)
153x115mm (150 x 150 DPI)

eview

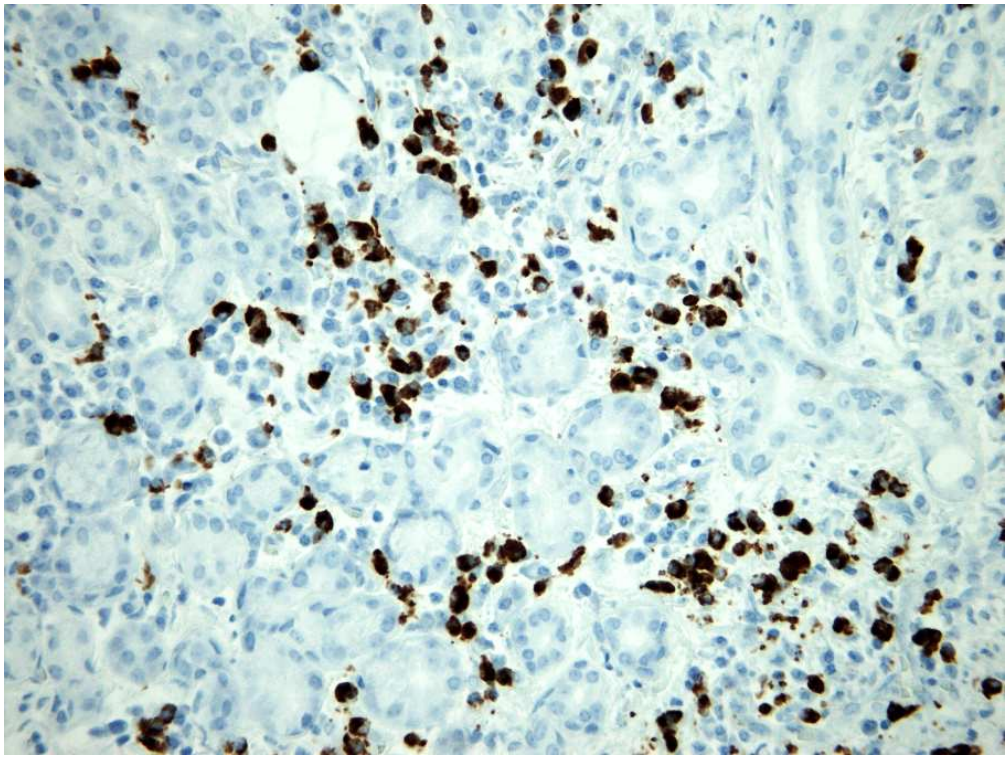

Fig. 6 Numerous IgG4-positive plasma cells in CSS (original magnification x400)
153x115mm (150 x 150 DPI)

eview