



**HAL**  
open science

## **A novel autosomal dominant condition consisting of congenital heart defects and low atrial rhythm maps to chromosome 9q**

A. V. Postma, J van de Meerakker, K van Engelen, I. Mathijssen, Dr. Lekanne, J Lam, Arthur Am Wilde, Marieke J.H. Baars, Marcel M.A.M. Mannens, Barbara Mulder, et al.

### ► To cite this version:

A. V. Postma, J van de Meerakker, K van Engelen, I. Mathijssen, Dr. Lekanne, et al.. A novel autosomal dominant condition consisting of congenital heart defects and low atrial rhythm maps to chromosome 9q. *European Journal of Human Genetics*, 2011, 10.1038/ejhg.2011.33 . hal-00620887

**HAL Id: hal-00620887**

**<https://hal.science/hal-00620887>**

Submitted on 9 Sep 2011

**HAL** is a multi-disciplinary open access archive for the deposit and dissemination of scientific research documents, whether they are published or not. The documents may come from teaching and research institutions in France or abroad, or from public or private research centers.

L'archive ouverte pluridisciplinaire **HAL**, est destinée au dépôt et à la diffusion de documents scientifiques de niveau recherche, publiés ou non, émanant des établissements d'enseignement et de recherche français ou étrangers, des laboratoires publics ou privés.

1 **A novel autosomal dominant condition consisting of congenital heart defects and low atrial**  
2 **rhythm maps to chromosome 9q**

3

4 J.B.A. van de Meerakker MSc\*<sup>1</sup>, K. van Engelen MD\*<sup>2, 3</sup>, I.B. Mathijssen MD<sup>3</sup>, R.H. Lekanne dit  
5 Deprez PhD<sup>3</sup>, J. Lam MD<sup>4</sup>, A.A.M. Wilde MD PhD<sup>2</sup>, M.J.H. Baars MD PhD<sup>3</sup>, M.M.A.M. Mannens  
6 PhD<sup>3</sup>, B.J.M Mulder MD PhD<sup>2</sup>, A.F.M. Moorman PhD<sup>1</sup>, A.V. Postma PhD<sup>#1</sup>

7 \* these authors contributed equally

8 <sup>1</sup>*Heart Failure Research Centre, Dept of Anatomy and Embryology, Academic Medical Centre,*  
9 *Amsterdam, The Netherlands*

10 <sup>2</sup>*Dept of Cardiology, Academic Medical Centre, Amsterdam, The Netherlands*

11 <sup>3</sup>*Dept of Clinical Genetics, Academic Medical Centre, Amsterdam, The Netherlands*

12 <sup>4</sup>*Dept of Pediatric Cardiology, Academic Medical Centre, Amsterdam, The Netherlands*

13 **short title:** CHD and Low Atrial Rhythm Map to Chromosome 9q

14

15 # corresponding author

16 Alex V. Postma

17 Department of Anatomy & Embryology

18 Heart Failure Research Center

19 L2-108-2, Academic Medical Center

20 Meibergdreef 15, 1105 AZ Amsterdam The Netherlands

21 email: a.v.postma@amc.uva.nl

22 fax: +(31)20-6976177

23 tel: +(31)20-5667822

24 tel: +(31)20-5664933

25

26 **Abstract**

27

28 Congenital Heart Defects (CHDs) occur mostly sporadic, but familial CHD cases have been reported.  
29 Mutations in several genes, including NKX2.5, GATA4 and NOTCH1 were identified in families and  
30 patients with CHD, but the mechanisms underlying CHD are largely unknown. We performed  
31 genome-wide linkage analysis in a large four-generation family with autosomal dominant CHD  
32 (including atrial septal defect type I and II, tetralogy of Fallot and persistent left superior vena cava)  
33 and low atrial rhythm, an unique phenotype that has not been described before. We obtained  
34 phenotypic information including electrocardiography, echocardiography and DNA of 23 family  
35 members. Genome-wide linkage analysis on 12 affected and 5 unaffected individuals and 1 obligate  
36 carrier demonstrated significant linkage only to chromosome 9q21-33 with a multipoint maximum LOD  
37 score of 4.1 at marker D9S1690, between markers D9S167 and D9S1682. This 48 cM critical interval  
38 corresponds to 39 Mb and contains 402 genes. Sequence analysis of nine candidate genes in this  
39 region (INVS, TMOD1, TGFBR1, KLF4, IPPK, BARX1, PTCH1, MEGF9 and S1PR3) revealed no  
40 mutations, nor were genomic imbalances detected using array CGH. In conclusion, we describe a  
41 large family with CHD and low atrial rhythm with a significant LOD score to chromosome 9q. The  
42 phenotype is representative of a mild form of left atrial isomerism or a developmental defect of the  
43 sinus node and surrounding tissue. Because the mechanisms underlying CHD are largely unknown,  
44 this study represents an important step towards the discovery of genes implied in cardiogenesis.

45

46

47 **Keywords: atrium; genetics; congenital heart defects; sinus node**

48

49 **1. Introduction**

50 Congenital Heart Defects (CHDs) are among the most common congenital defects, occurring with an  
51 incidence of 8/1000 live-births.<sup>1</sup> The aetiology of CHD is generally complex, environmental exposures,  
52 chromosomal abnormalities and gene defects can all contribute. Most CHD occur sporadic, but in  
53 recent years an increasing number of familial cases with various types of CHD have been reported.<sup>2-4</sup>  
54 Although, mutations in a several genes have been identified in a small subset of patients and families  
55 with CHD, e.g. NKX2.5<sup>2</sup>, GATA4<sup>3</sup> and NOTCH1<sup>5</sup>, the mechanisms underlying human cardiogenesis  
56 and CHDs remain largely unknown. Some CHD patients and families also display cardiac  
57 arrhythmias, which can occur due to the anatomical defect itself or sometimes due to surgical  
58 interventions.<sup>6</sup> Moreover, in some patients arrhythmias are the direct consequence of the underlying  
59 genetic defect, in absence of any structural defect.<sup>2,7</sup>

60 Ectopic atrial rhythms originate when a focus outside the sinus node takes over the  
61 pacemaker function. Consequently, the direction of atrial activation may be altered, which can be  
62 seen as an abnormal P wave axis on the electrocardiogram (ECG). The appearance of the P wave  
63 depends on the site of origin of the ectopic rhythm. The P wave can be decreased in amplitude, or it  
64 can be biphasic or negative in leads II, III and AVF. The rhythm is regular and the P-R interval is  
65 usually normal or, at times, prolonged.<sup>8</sup> Usually, ectopic atrial rhythms are hemodynamically  
66 insignificant. They can be isolated and idiopathic, especially in children, but can also co-occur with  
67 CHD.<sup>9</sup> A P wave frontal axis oriented in a superior direction, reflecting atrial pacemaker tissue located  
68 in the lower part of the atrium, is referred to as low atrial rhythm. These can be present due to sinus  
69 node dysfunction in patients with left atrial isomerism, a laterality disorder characterized by bilateral  
70 left-sidedness.<sup>9,10</sup>

71 Here we describe a large four-generation family with an autosomal dominant condition,  
72 comprising various types of CHD and low atrial rhythm, a unique phenotype not described before  
73 within a family. A genome wide linkage analysis yielded linkage to a region of 39 Mb on chromosome  
74 9q with a maximum LOD score of 4.1.

75

76 **2. Methods**

77 *2.1 Clinical details*

78 This study was approved by the Medical Ethical Committee at the Academic Medical Centre in  
79 Amsterdam. Written informed consent was obtained from all participants. Subjects were clinically  
80 evaluated by analysis of medical records, physical examination with attention to syndromic features,  
81 cardiologic examination, 12-lead electrocardiogram (ECG) and two-dimensional echocardiography.  
82 Previously performed ECGs were obtained from the medical records if available. The number of  
83 available ECGs ranged from one to 15 in the evaluated persons. One experienced pediatric  
84 cardiologist (JL) reviewed the ECGs and echocardiographic images. A total of 23 family members  
85 were examined. One patient (II-2) refused cardiologic examination for this study and therefore only  
86 previous medical records (including ECGs and echocardiography records) were obtained. We used  
87 Magnetic Resonance Imaging (MRI) for evaluation of situs in the proband (IV-10). Abdominal  
88 ultrasound for evaluation of abdominal situs was performed in three individuals and chest X-rays for  
89 evaluation of situs of the lungs were available for six individuals. Computed Tomography (CT) of the  
90 thorax was performed in patient III-3.

91 Low atrial rhythm was defined as a P wave frontal axis oriented in a superior direction. We  
92 defined the P wave frontal axis to be horizontal when it was approximately 0°, which is abnormal,  
93 though not a true low atrial rhythm. A wandering atrial pacemaker was defined as a change in P wave  
94 axis of 60° or more on subsequent ECGs.

95

96 *2.2 Linkage analysis, mutation screen and array comparative genomic hybridization*

97 Genomic DNA of family members was extracted from peripheral blood according to standard  
98 procedures. Linkage analysis was performed using the ABI linkage set v2.5 MD10 set on an ABI 3700  
99 Genetic Analyzer (Applied Biosystems).<sup>11</sup> Phenotype, genotype, and pedigree information were  
100 combined for multipoint linkage analysis with the use of the easyLinkage software package<sup>12</sup> running  
101 Simwalk v2.91<sup>13</sup> with the assumption of an autosomal dominant pattern of inheritance, a disease-  
102 allele frequency of 0.0001 and a penetrance of 0.9. Gene frequency was assumed to be equal  
103 between males and females. Both parametric and nonparametric linkage was calculated.

104 PCR amplification of all the coding exons of candidate genes INVS, S1PR3, TGFBR1, IPPK,  
105 BARX1, TMOD1, KLF4, MEGF9 and PTCH1 (only exon 12b, as this is specifically expressed in brain

106 and heart<sup>14</sup>), was performed using primers located in flanking intronic sequences (available on  
107 request). Subsequently, PCR products were analysed by direct sequencing, using the  
108 BigDye Terminator v3.1 Kit on an ABI 3700.

109 MLPA probes were designed for *INVS* and *TGFBR1* using MAPD, a probe design suite for  
110 multiplex ligation-dependent probe amplification assays<sup>15</sup>. The MLPA procedure and analysis were  
111 carried out as described<sup>16</sup>

112 Array CGH was performed using 4x180K slides (average 13kbp spacing between probes),  
113 AMADID 023363 (Agilent, Santa Clara, CA, USA) according to the manufacturer's protocol  
114 (Oligonucleotide Array-Based CGH for Genomic DNA Analysis V5.0 June 2007) with adaptations. No  
115 amplification or restriction was used on the genomic patient and reference DNA. Fluorescent labelling  
116 of gDNA was performed using the CGH labelling kit for Oligo Arrays (Enzo Life Sciences, Inc.  
117 Farmingdale, NY, USA) and purified using the MinElute PCR Purification Kit (Qiagen, Valencia, CA,  
118 USA). Hybridization was performed according to the manufacturer's protocol (Oligonucleotide Array-  
119 Based CGH for Genomic DNA Analysis V5.0 June 2007) and slides were scanned using an Agilent  
120 G2250C 2 µm scanner with Agilent Scan Control software (Version A.8.1.3.) using default settings.  
121 Spot intensities were measured with Agilent Feature Extraction software (V10.7) and further data  
122 analysis was performed using DNA Analytics software (V4.0.76) with algorithm ADM-2 using a filter of  
123 minimal 3 subsequent clones with a minimal absolute ratio of 0.3.

124

### 125 **3. Results**

#### 126 *3.1 Clinical details*

127 In the presented family, several individuals had CHD with or without low atrial rhythm, while others  
128 had isolated low atrial rhythm. The pedigree of the family is shown in Figure 1. Table 1 summarizes  
129 the clinical features of the family members.

130 The proband (IV-10) was diagnosed during her first year of life with an incomplete  
131 atrioventricular septal defect (AVSD), a common atrium and a small communication between the left  
132 and right ventricle. At 2.5 years of age she underwent surgical correction including septation of the  
133 monoatrium, leaving the coronary sinus draining into the left atrium. During the surgical procedure,  
134 the presence of bilateral left atria with bilateral left atrial appendages was observed. At 33 years of

135 age, she was asymptomatic. MRI at that age showed normal situs of the lungs and abdominal organs.  
136 ECG persistently showed left QRS axis deviation and low atrial rhythm.

137 The sister of the proband (IV-9) was asymptomatic. Echocardiography did not reveal any  
138 abnormalities, however, ECG at age 32 showed low atrial rhythm (Figure 3). The asymptomatic father  
139 of IV-9 and IV-10 (III-10) also had normal echocardiography, and low atrial rhythm with bradycardia  
140 (45/min) on ECG.

141 The paternal aunt of the proband (III-9) was diagnosed with congenital agenesis or  
142 malfunction of the sinus node at infant age because of bradycardia with AV-junctional escape rhythm  
143 and low atrial rhythm. At later age, she developed intermittent complete AV dissociation.  
144 Echocardiography repeatedly did not show any structural abnormalities. Because of chronic fatigue, a  
145 pacemaker was implanted at the age of 39 years. During implantation, the lead could not be placed in  
146 a stable position in the right atrial appendage and therefore this appendage was assumed to be  
147 absent. Normal situs of the lungs and abdominal organs were confirmed by chest X-ray and  
148 abdominal ultrasound. The 18 year old daughter of III-9 (IV-8) was born with a large incomplete AVSD  
149 and ASD II which were surgically corrected at the age of 8 months. At surgery, absence of the  
150 coronary sinus and a persistent left superior vena cava (LSVC) connecting directly with the left upper  
151 corner of the left atrium were noted. The right superior vena cava was hypoplastic and the  
152 brachiocephalic vein was absent. ECGs persistently showed low atrial rhythm. Situs of the lungs and  
153 abdomen was normal.

154 One of the paternal uncles of the proband (III-6) had tetralogy of Fallot (TOF) and LSVC  
155 draining into the coronary sinus, which was surgically corrected at the age of 27. P wave frontal axis  
156 was horizontal. Normal situs of the lungs and bronchi was present. In his 28 year old daughter (IV-5),  
157 a cardiac murmur was noticed shortly after birth and she was followed at a cardiology clinic until the  
158 age of 7 years. Echocardiography performed at age 20 showed mildly elevated pulmonary artery  
159 pressure, with unknown cause. Low atrial rhythm was also present.

160 The paternal grandfather of the proband (II-2) had a myocardial infarction at age 76. He  
161 received a pacemaker at age 84 because of atrial and ventricular arrhythmias with severe  
162 bradycardia. P wave frontal axis was horizontal. He developed atrial fibrillation at age 85. Chest X-  
163 rays showed normal situs of the lungs and bronchi.

164 His sister (II-1) showed low atrial rhythm on ECG at age 74. She developed atrial fibrillation  
165 when she was 77 years old. Echocardiography at this age showed dilated atria and mildly elevated  
166 pulmonary artery pressure, with normal left ventricular systolic function and diastolic dysfunction.  
167 Ultrasound showed normal abdominal situs. Two children of II-1 (III-1 and III-2) had died in the first  
168 months of life: III-1 was said to have had aortic hypoplasia, detected at autopsy. III-2 was said to have  
169 died of pneumonia.

170 The daughter of II-1 (III-3) was asymptomatic at age 57. Echocardiography and CT showed a  
171 LSVC draining into the coronary sinus (Figure 3), aberrant right subclavian artery arising from the  
172 aorta distal from the left subclavian artery (arteria lusoria) and elevated pulmonary artery pressure,  
173 while on ECG low atrial rhythm and paroxysmal supraventricular tachycardia were present.  
174 Pulmonary situs was normal. In the asymptomatic 28-year old daughter of III-3 (IV-1)  
175 echocardiography showed abnormal interventricular wall movements, but no ventricular septal defect  
176 or other structural abnormalities were seen. She did have low atrial rhythm. The son of III-3 (IV-2),  
177 who was also asymptomatic at age 25, showed a horizontal P wave frontal axis on ECG with normal  
178 echocardiography.

179 In the youngest son of II-1 (III-5), ECG at age 40 showed low atrial rhythm and 1<sup>st</sup> degree  
180 atrioventricular (AV) block. On echocardiography at the same age, a mildly dilated left ventricle was  
181 present as well as moderate regurgitation of calcified aortic and tricuspid valves. The 23 year old  
182 daughter of III-5 (IV-3) was diagnosed in her first year of life with ASD II, membrane in the left atrium,  
183 absent brachiocephalic vein, LSVC draining into the coronary sinus and a small right superior vena  
184 cava. ECGs persistently showed low atrial rhythm. Situs of the lungs and bronchi was normal. The  
185 other daughter of III-5 (IV-4) was diagnosed with frequent paroxysmal supraventricular tachycardia  
186 and atrial extrasystoles with the origin in the lower right atrium at birth, with normal sinus rhythm in  
187 between. She was on anti-arrhythmic medication until the current age of 17 years because of  
188 persistence of the tachycardia. Echocardiography showed no structural abnormalities and chest X-ray  
189 showed normal pulmonary situs.

190 At age 78, the asymptomatic brother of II-1 and II-2 (II-3) was found to have bradycardia with  
191 arrests up to 2.6 seconds with junctional escapes, atrial extrasystoles and non sustained ventricular  
192 tachycardia. He also had paroxysmal atrial fibrillation and complete right bundle branch block. P wave  
193 frontal axis was normal. Echocardiography at age 80 demonstrated left ventricular hypertrophy,



194 dilatation of the aortic root (42 mm) and mild prolapse of the mitral valve, but no congenital  
195 abnormalities.

196         Seven other family members were evaluated in this study (III-4, III-7, III-8, III-11, III-12, IV-6,  
197 IV-7), all with normal echocardiography and ECG. None of the individuals with an abnormal P wave  
198 axis had a wandering pacemaker. Clear dysmorphic features were not present in any of the family  
199 members.

200

### 201 *3.3 Linkage analysis and mutation screen*

202 Before performing a genome-wide linkage we excluded GATA4, TBX5 and NKX2-5 as the disease  
203 causing gene in this family by linkage analysis. In first linkage scenario, termed nuclear family,  
204 subjects were considered affected if they had a structural heart defect and/or low atrial rhythm.  
205 Therefore, genome-wide linkage was performed on 12 affected (II-1, III-3, III-5, III-6, III-9, III-10, IV-1,  
206 IV-3, IV-5, IV-8, IV-9 and IV-10), 5 unaffected individuals (III-4, III-7, III-8, IV-6, IV-7) and 1 obligate  
207 carrier (II-2) (Figure 1, Table 1). The analysis demonstrated significant linkage to a single locus on  
208 chromosome 9q shared by all affected individuals. This locus was absent from unaffected individuals  
209 (Figure 1). The shared locus has a multipoint maximum LOD-score of 4.1 at marker D9S1690, and is  
210 delineated by markers D9S167 and D9S1682 based on the haplotypes (Figures 1 and 2). No other  
211 loci with a LOD score higher than 1.0 were detected in this family genome wide.

212         To reduce the risk of phenocopies, individuals IV-2, IV-4 and II-3 (and therefore his children  
213 III-11 and III-12) were not included in the nuclear family linkage analysis. IV-2 was excluded because  
214 he had a horizontal P wave frontal axis, and although this is abnormal, it is not a clear low atrial  
215 rhythm. II-3 and IV-4 had significant rhythm and conduction abnormalities, but normal P wave frontal  
216 axes. In a second linkage scenario, termed extended family, we presumed IV-2, IV-4 and II-3 to be  
217 affected and III-11 and III-12 to be unaffected. We found that all affected carried to locus, however III-  
218 11 did as well, who had normal echocardiography and ECG. The maximal LOD-score for the  
219 extended family scenario is 4.45; the locus remained the same. A third linkage scenario, termed  
220 affected only, was run in which individuals II-1, III-3, III-5, III-6, III-9, III-10, IV-1, IV-3, IV-5, IV-8, IV-9  
221 and IV-10 were included as affected. The maximal LOD-score for this affected only scenario was 3.3  
222 also delineated by markers D9S167 and D9S1682

223

224

225           The shared locus comprises a 48 cM critical interval, that corresponds to 39 Mb and contains  
226 402 genes, of which 9 (INVS, TMOD1, TGFBR1, KLF4, IPPK, PTCH1, BARX1, MEGF9 and S1PR3)  
227 are known to be, directly or indirectly, involved in development and (left-right) patterning of the heart.  
228 Therefore, mutation analysis was performed in these genes in the proband (IV-10). Moreover, 10  
229 conserved non coding sequences within 5kb up- or downstream of candidate genes were also  
230 screened. Nonetheless, no mutations were identified by direct sequencing. Since large genomic  
231 rearrangements could also potentially underlie the phenotype, we also performed an array  
232 comparative genomic hybridization (array CGH) on III-6 and IV-10 using a 180K oligo array with  
233 genome-wide coverage. However, no genomic imbalances in or outside the co-segregating locus  
234 were detected, besides copy number variations also present in controls (data not shown). Moreover,  
235 MLPA analysis of the coding exons of INVS and TGFBR1 did not reveal genomic imbalances for  
236 these genes.

237

#### 238 **4. Discussion**

239           We describe a large family with an autosomal dominant condition with a wide spectrum of  
240 cardiovascular abnormalities. The phenotype comprises different types of CHD with an abnormal  
241 atrial rhythm. Remarkably, several family members have low atrial rhythm without detectable  
242 structural heart defects, suggesting that these individuals show a mild manifestation of the familial  
243 disorder. We identified a locus at chromosome 9q that co-segregates with this autosomal dominant  
244 disorder and we excluded several candidate genes present within the shared 39 Mb disease locus.

245           The presence of bilateral left atrial appendages in the proband in combination with low atrial  
246 rhythm, led us to hypothesize that the CHDs in this family might be the result of a defect in the  
247 establishment of left-right asymmetry, and might represent a mild or variant expression of left atrial  
248 isomerism. Left isomerism is a laterality disorder characterized by bilateral left sidedness, i.e. two  
249 morphologic left cardiac atria and atrial appendages, often in association with bilateral bilobed (left)  
250 lungs, isomerism of the bronchi, abdominal situs abnormalities, polysplenia and abnormalities of the  
251 large systemic veins.<sup>17,18</sup> The internal architecture of the heart is often disrupted as well, and different  
252 forms of CHD are observed in left atrial isomerism.<sup>17-19</sup> Besides CHD, the phenotype in this family is  
253 characterized by abnormal P wave frontal axis on ECG, typically present in left atrial isomerism due to

254 sinus node abnormalities. In normal hearts, the sinus node is located in the right atrium at the junction  
255 between the superior caval vein and the right atrial appendage, which results in a P wave frontal axis  
256 orientated leftward and inferiorly.<sup>20</sup> Histological studies in hearts with left atrial isomerism demonstrate  
257 absence, hypoplasia and/or ectopic location of nodal tissue in a large proportion of patients.<sup>21,22</sup> In  
258 correspondence with these histologic abnormalities, abnormal atrial rhythms are commonly found in  
259 patients with left atrial isomerism,<sup>10,23</sup> and a low atrial rhythm with a superior P wave frontal axis is  
260 frequently present.<sup>10,23</sup> In this family, four of the five individuals with CHD or isolated LSVC had low  
261 atrial rhythm, and one individual had a horizontal P wave axis. In addition, seven family members  
262 without detectable structural heart defects also showed low atrial rhythm, and two had a horizontal P  
263 wave axis. Indeed, rhythm and conduction disturbances have been described in patients with  
264 confirmed left isomerism *without* structural cardiac defects.<sup>24,25</sup> Taken together, the spectrum of CHD  
265 in this family is compatible with that seen in left isomerism. Importantly, we could not confirm signs of  
266 left isomerism outside the heart (e.g. polysplenia) in the investigated family members, though imaging  
267 of the abdomen and lungs was not available in all subjects, so we cannot rule out laterality defects in  
268 every individual. In conclusion, the phenotype of this family resembles a developmental laterality  
269 defect, though affected individuals only show a mild expression, which appears to be restricted to the  
270 heart.

271           Alternatively, the familial phenotype might represent an underlying developmental defect of  
272 the sinus node, as most family members have an abnormal low atrial rhythm, caused by a dominance  
273 of a pacemaker located in the lower part of the right atrium over the normal sinus node. In its earliest  
274 stages, when the heart is no more than a simple tube, a dominant pacemaker activity is already found  
275 in the entire systemic inflow region of the heart (both left- and right side). Subsequently, newly added  
276 myocardium at the inflow part, which differentiates from t-box transcription factor Tbx18 expressing  
277 precursor cells, will eventually give rise to the right-sided sinus node, among others<sup>26</sup>. The developing  
278 sinus node also expresses the t-box transcription factor Tbx3, which acts to repress differentiation into  
279 working myocardium by imposing a conduction system phenotype<sup>27</sup>. Thus, formation of the sinus  
280 nodes requires transcription factors such as Tbx18 and Tbx3, and knockout of these genes leads not  
281 only to under- or maldevelopment of the sinus node, but also to various forms of CHD<sup>26,27</sup>.  
282 Consequently, it is possible that the phenotype seen in the current family is the direct result of

283 developmental defects in the formation of the sinus node, possibly via pathways involving t-box  
284 transcription factors.

285           The co-segregating locus on chromosome 9q contains 402 genes (genome build 37), and  
286 some of these were selected as candidate genes based on current knowledge, literature and data  
287 mining analysis: inversin (*INVS*), transforming growth factor beta receptor 1 (*TGFB1*), tropomodulin  
288 1 (*TMOD1*), Kruppel-like factor 4 (*KLF4*), inositol 1,3,4,5,6-pentakisphosphate 2-kinase (*IPPK*), BARX  
289 homeobox 1 (*BARX1*), patched homolog 1 (*PTCH1*) and sphingosine 1-phosphate receptor 3  
290 (*S1PR3*), multiple epidermal growth factor-like domains 9 (*MEGF9*). The coding regions and selected  
291 conserved non coding regions of all these genes were sequenced, but no mutations were found. In  
292 addition, we looked for genome-wide genomic imbalances using array CGH, however none were  
293 identified. No other genes known to play a role in left-right patterning or cardiac development map to  
294 the 9q region. The best option to identify the causative gene or region on the 9q locus would be to  
295 fully sequence it, and although advances in next generation sequencing have been tremendous, it is  
296 currently far from trivial to sequence our 39 Mb-locus. Moreover, investigation of additional families  
297 with a similar phenotype might reduce the region of interest and could lead to the detection of the  
298 gene responsible for the phenotype in this family.

299           A concern of our study is the possibility of phenocopies. Ectopic atrial rhythms can be seen  
300 idiopathically in healthy individuals, especially in children. We cannot rule out that individuals in our  
301 family have P wave abnormalities due to other reasons than the familial genetic defect. To minimize  
302 the risk of phenocopies, we performed linkage analysis on the most affected patients, i.e. patients  
303 with low atrial rhythm, and excluded the patient with isolated horizontal P wave frontal axis as well as  
304 the patients with significant rhythm disturbances and normal P wave frontal axis. Those patients all  
305 carried the disease locus though, which implies that the familial disorder shows variable expression.  
306 Patient III-11, carrier of the risk allele, had normal echocardiography and ECG at age 45, which also  
307 indicates that the disorder is not 100% penetrant. Atrial fibrillation and other atrioventricular rhythm  
308 disturbances were mainly present in the older individuals in the family, suggesting age-dependant  
309 penetrance of these abnormalities. Though, since these abnormalities are common in the general  
310 population, it is unclear if they are part of the disease phenotype.

311

312 In conclusion, we present a large four-generation family in which a condition, comprising of congenital  
313 heart defects and low atrial rhythm, inherits as an autosomal dominant trait with variable expression,  
314 and which, to the best of our knowledge, has not been described before. A significant genome-wide  
315 linkage was demonstrated to a locus on chromosome 9q with a LOD-score of 4.1. Although we did  
316 not uncover a causative mutation in this family, the mapping of this locus represents an important step  
317 toward the discovery of genes implied in cardiac development. Identification of the disease-causing  
318 gene will allow genetic screening and will ultimately provide fundamental insights in human  
319 cardiogenesis.

320

### 321 **Acknowledgments**

322 We thank all family members for their kind participation. We also thank A. Ilgun, A. Mul, D. van Gent,  
323 S. de Jong, F. Salehi and F. Asidah for their excellent technical assistance, S. Romeih, and M.  
324 Groenink for the assessment of the MRI and CT images, and H.A.C.M. de Bruin-Bon for performing  
325 echocardiographic examinations. We thank dr. R.J. Oostra for helpful discussions.

326

### 327 **Funding sources**

328 AFMM is supported by grants from the Netherlands Heart Foundation (96.002) and the European  
329 Community's Sixth Framework Program contract ('HeartRepair' LSHM-CT-2005-018630).

330

### 331 **Competing Interest**

332 None declared.

333

334

335

### 336 **Legends**

337 Figure 1. Pedigree of the family, circles represent females, squares males. Unaffected individuals are  
338 depicted with empty symbols and deceased individuals are indicated by slashes with age of death in  
339 years. Right sided filled symbols denote individuals with low atrial rhythm, left sided filled symbols  
340 those with congenital heart defects or persistent left superior vena cava, right upper quarter filled  
341 symbols represent individuals with horizontal P wave frontal axis, left lower quarter filled symbols  
342 those with rhythm/conduction disturbances with normal P wave frontal axis. Dots denote obligate  
343 carriers. The proband is indicated by an arrow. Haplotypes are depicted under each individual, the

344 disease haplotype is demarcated by the box. For reasons of clarity not all parents are shown, markers  
345 according to the Marshfield map.

346

347 Figure 2. Graphs of the multipoint parametric (**A**) and nonparametric, NPL (**B**) LOD scores of  
348 microsatellite markers on chromosome 9 for various analysis scenarios. The area of linkage is  
349 enlarged, depicting the position of markers and candidate genes screened by sequencing.

350

351 Figure 3. ECG of patient IV-9 at age 32 years with isolated low atrial rhythm. The P wave is negative  
352 in leads II, III and aVF, as indicated by arrow. **B.** Transverse Computed Tomography image of  
353 individual III-3. Persistent left superior vena cava (arrow). AA, ascending aorta, DA, descending aorta.

354

Patient characteristics				Clinical features			Status in linkage analysis
	Sex/age	Age of diagnosis of CHD and/or low atrial rhythm	Age (years) at last available ECG	Low atrial rhythm	Rhythm/conduction disturbances	Congenital heart defects	Nuclear family scenario
II-1	F / 83	74 yrs	77	+	AF	-	Affected
II-2	M / 89	84 yrs	84	±	Bradycardia, atrial/ventricular arrhythmia, AF <sup>a</sup>	-	Obligate carrier
II-3	M / 87	78 yrs	80	-	Bradycardia, junctional escapes, AF, complete RBBB	-	Excluded
III-3	F / 57	50 yrs	57	+	Paroxysmal SVT	LSVC, aberrant right subclavian artery	Affected
III-4	M / 50		43	-	-	-	Not affected
III-5	M / 47	40 yrs	40	+	1st degree AV block, incomplete RBBB	-	Affected
III-6	M / 61	10 yrs	36	±	Complete RBBB	Tetralogy of Fallot, LSVC	Affected
III-7	M / 59		58	-	Sinus bradycardia	-	Not affected
III-8	M / 54		53	-	-	-	Not affected
III-9	F / 47	4 yrs	38	+	Bradycardia, atrial arrests with AV junctional escapes, intermittent complete AV dissociation	- <sup>b</sup>	Affected
III-10	M / 60	52 yrs	52	+	Bradycardia	-	Affected
III-11	F / 52		45	-	-	-	Excluded
III-12	F / 50		43	-	-	-	Excluded
IV-1	F / 28	21 yrs	28	+	-	-	Affected
IV-2	M / 25	24 yrs	24	±	-	-	Excluded
IV-3	F / 23	2 months	16	+	Incomplete RBBB	ASD II, membrane in left atrium, LSVC, absent brachiocephalic vein	Affected
IV-4	F / 17	birth	16	-	Chronic SVT; atrial extrasystoles	-	Excluded
IV-5	F / 28	4 yrs	28	+	Incomplete RBBB	<sup>c</sup>	Affected
IV-6	M / 34		33	-	-	-	Not affected
IV-7	F / 31		24	-	-	-	Not affected
IV-8	F / 18	< 0.5 yrs	18	+	Incomplete RBBB	Incomplete AVSD, ASD II, LSVC draining into left atrium, absent coronary sinus, absent brachiocephalic vein	Affected
IV-9	F / 36	32 yrs	32	+	-	-	Affected

IV-10	F / 33	< 0.5 yrs	33	+	Incomplete RBBB	Incomplete AVSD, common atrium, bilateral left atrial appendages	Affected
-------	--------	-----------	----	---	-----------------	---	----------

---

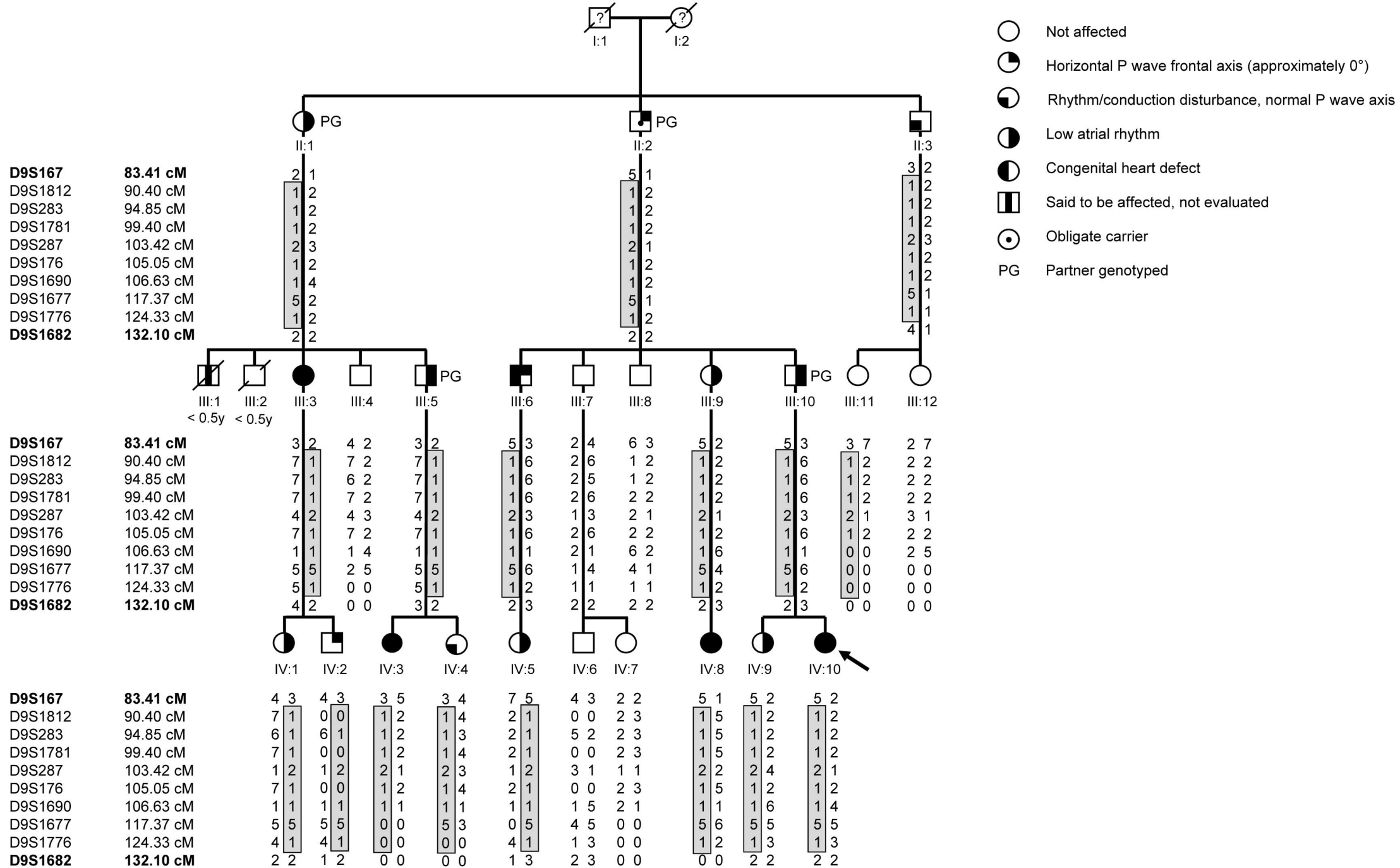
Low atrial rhythm + means that the P wave frontal axis was oriented superiorly; Low atrial rhythm ± means that the P wave frontal axis was horizontal (approximately 0°). AF, atrial fibrillation; RBBB, right bundle branch block; ASD II, secundum type atrial septal defect; AVSD, atrioventricular septal defect; SVT, supraventricular tachycardia; LSVC, persistent left superior vena cava; <sup>a</sup> After myocardial infarction, <sup>b</sup> Suspicion of abnormal atrial appendage, <sup>c</sup> Systolic murmur, for which cardiologic follow up until the age of 7 years, elevated pulmonary artery pressure at age 20, <sup>d</sup> Chest CT available.



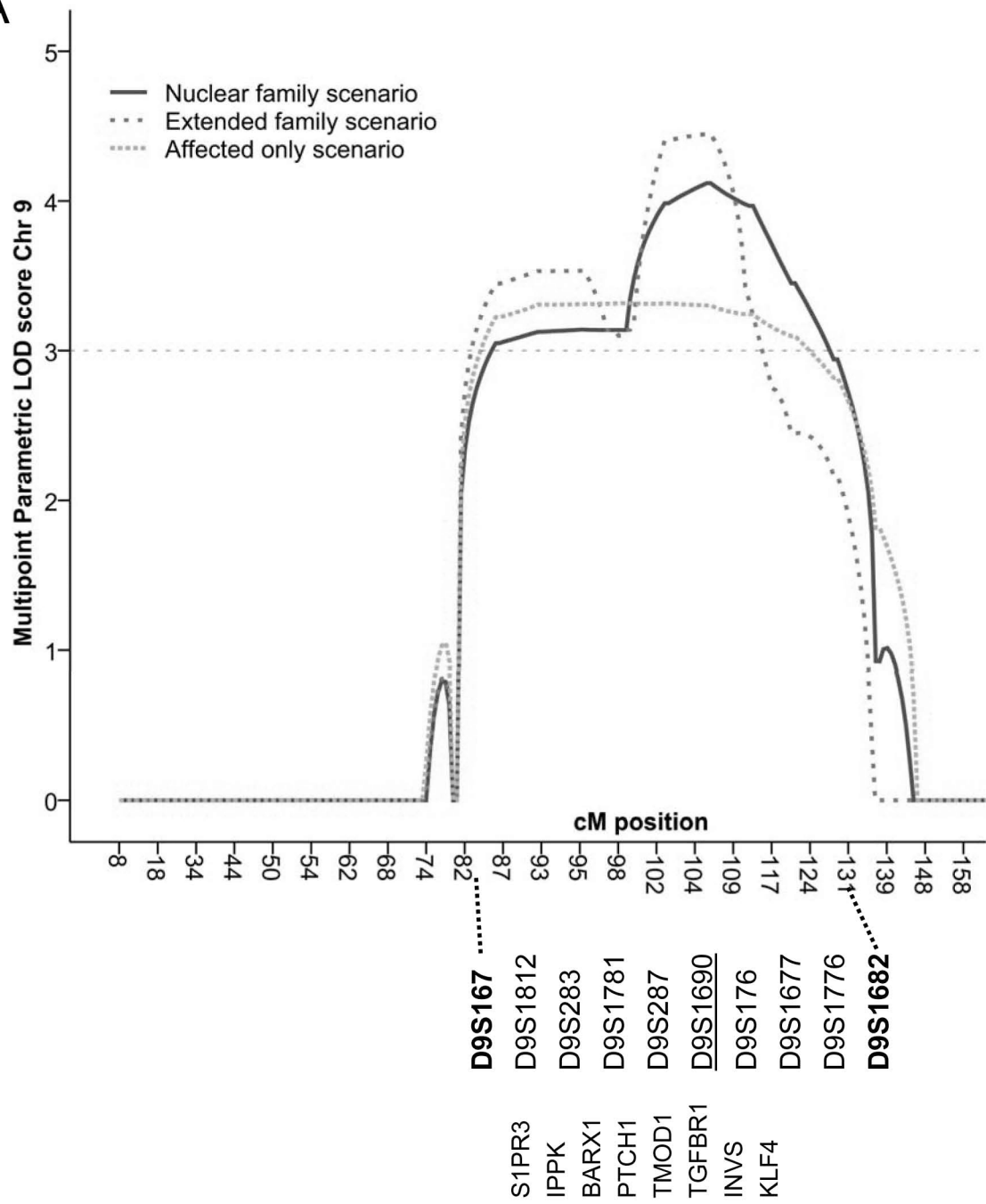
## References

1. Hoffman JI, Kaplan S: The incidence of congenital heart disease. *J Am Coll Cardiol* 2002; **39**: 1890-1900
2. Schott JJ, Benson DW, Basson CT, Pease W, Silberbach GM, Moak JP, *et al.*: Congenital heart disease caused by mutations in the transcription factor NKX2-5. *Science* 1998; **281**: 108-111
3. Garg V, Kathiriya IS, Barnes R, Schluterman MK, King IN, Butler CA, *et al.*: GATA4 mutations cause human congenital heart defects and reveal an interaction with TBX5. *Nature* 2003; **424**: 443-447
4. Benson DW, Sharkey A, Fatkin D, Lang P, Basson CT, McDonough B, *et al.*: Reduced penetrance, variable expressivity, and genetic heterogeneity of familial atrial septal defects. *Circulation* 1998; **97**: 2043-2048
5. Garg V, Muth AN, Ransom JF, Schluterman MK, Barnes R, King IN, *et al.*: Mutations in NOTCH1 cause aortic valve disease. *Nature* 2005; **437**: 270-274
6. Balaji S, Harris L: Atrial arrhythmias in congenital heart disease. *Cardiol Clin* 2002; **20**: 459-468, vii
7. Postma AV, van de Meerakker JB, Mathijssen IB, Barnett P, Christoffels VM, Ilgun A, *et al.*: A gain-of-function TBX5 mutation is associated with atypical Holt-Oram syndrome and paroxysmal atrial fibrillation. *Circ Res* 2008; **102**: 1433-1442
8. Fisch CK, S.B. (2000) Chapter 2: atrial arrhythmias. In: Fisch CK, S.B. (ed) *Electrocardiography of clinical arrhythmias*. Futura publishing company, Armonk NY
9. Walsh EP, Cecchin F: Arrhythmias in adult patients with congenital heart disease. *Circulation* 2007; **115**: 534-545
10. Momma K, Takao A, Shibata T: Characteristics and natural history of abnormal atrial rhythms in left isomerism. *Am.J.Cardiol.* 1990; **65**: 231-236
11. Reed PW, Davies JL, Copeman JB, Bennett ST, Palmer SM, Pritchard LE, *et al.*: Chromosome-specific microsatellite sets for fluorescence-based, semi-automated genome mapping. *Nat.Genet.* 1994; **7**: 390-395
12. Lindner TH, Hoffmann K: easyLINKAGE: a PERL script for easy and automated two-/multi-point linkage analyses. *Bioinformatics* 2005; **21**: 405-407
13. Sobel E, Lange K: Descent graphs in pedigree analysis: applications to haplotyping, location scores, and marker-sharing statistics. *Am.J.Hum.Genet.* 1996; **58**: 1323-1337
14. Uchikawa H, Toyoda M, Nagao K, Miyauchi H, Nishikawa R, Fujii K, *et al.*: Brain- and heart-specific Patched-1 containing exon 12b is a dominant negative isoform and is expressed in medulloblastomas. *Biochem Biophys Res Commun* 2006; **349**: 277-283
15. Zhi J, Hatchwell E: Human MLPA Probe Design (H-MAPD): a probe design tool for both electrophoresis-based and bead-coupled human multiplex ligation-dependent probe amplification assays. *BMC Genomics* 2008; **9**: 407
16. Koopmann TT, Alders M, Jongbloed RJ, Guerrero S, Mannens MM, Wilde AA, *et al.*: Long QT syndrome caused by a large duplication in the KCNH2 (HERG) gene undetectable by current polymerase chain reaction-based exon-scanning methodologies. *Heart Rhythm* 2006; **3**: 52-55
17. Peeters H, Devriendt K: Human laterality disorders. *Eur.J.Med.Genet.* 2006; **49**: 349-362

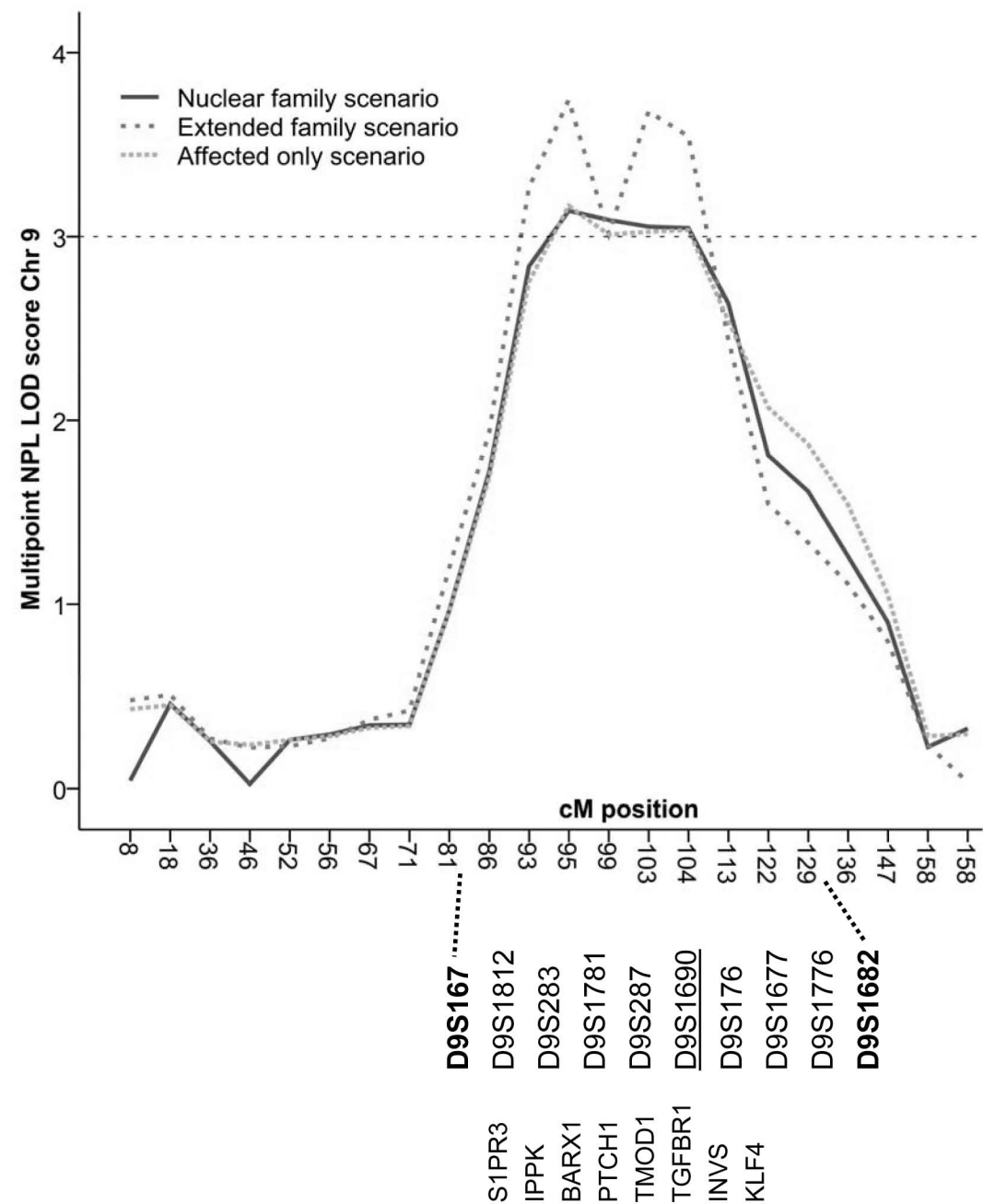
18. Norgard G, Berg A (2003) Isomerism (Heterotaxia). In: M.A.Gatzoulis, G.D.Webb, P.E.F.Daubeney (eds) *Diagnosis and management of adult congenital heart disease*. Churchill Livingstone, Edinburgh, pp 413-421
19. Webber SA, Uemura H, Anderson RH (2002) Isomerism of the atrial appendages. In: Anderson RH, Baker EJ, Macartney FJ, Rigby ML, Shinebourne EA, Tynan M (eds) *Paediatric Cardiology*, 2nd edn. Churchill Livingstone, pp 813-850
20. Johnson WH, Moller JH (2001) Diagnostic Methods. In: W.H.Johnson, J.H.Moller (eds) *Pediatric Cardiology*, 1 edn. Lippincot, Williams and Wilkins
21. Ho SY, Seo JW, Brown NA, Cook AC, Fagg NL, Anderson RH: Morphology of the sinus node in human and mouse hearts with isomerism of the atrial appendages. *Br.Heart J.* 1995; **74**: 437-442
22. Smith A, Ho SY, Anderson RH, Connell MG, Arnold R, Wilkinson JL, *et al.*: The diverse cardiac morphology seen in hearts with isomerism of the atrial appendages with reference to the disposition of the specialised conduction system. *Cardiol.Young*. 2006; **16**: 437-454
23. Wren C, Macartney FJ, Deanfield JE: Cardiac rhythm in atrial isomerism. *Am.J.Cardiol.* 1987; **59**: 1156-1158
24. Kakura H, Miyahara K, Sohara H, Amitani S, Koga M, Moriyama Y, *et al.*: Isolated levocardia associated with absence of inferior vena cava, lobulated spleen and sick sinus syndrome. A case report. *Jpn.Heart J.* 1998; **39**: 235-241
25. Wessels MW, De Graaf BM, Cohen-Overbeek TE, Spitaels SE, LE dG-dL, Ten Cate FJ, *et al.*: A new syndrome with noncompaction cardiomyopathy, bradycardia, pulmonary stenosis, atrial septal defect and heterotaxy with suggestive linkage to chromosome 6p. *Hum.Genet.* 2008; **122**: 595-603
26. Wiese C, Grieskamp T, Airik R, Mommersteeg MT, Gardiwal A, de Gier-de Vries C, *et al.*: Formation of the sinus node head and differentiation of sinus node myocardium are independently regulated by Tbx18 and Tbx3. *Circ Res* 2009; **104**: 388-397
27. Bakker ML, Boukens BJ, Mommersteeg MT, Brons JF, Wakker V, Moorman AF, *et al.*: Transcription factor Tbx3 is required for the specification of the atrioventricular conduction system. *Circ Res* 2008; **102**: 1340-1349



A



B



IV-9

