



Msx-1 is suppressed in Bisphosphonate exposed jaw bone- analysis of bone turnover related cell signalling

Falk Wehrhan, Peter Hyckel, Kerstin Amann, Jutta Ries, Philipp Stockmann,
Karl Andreas Schlegel, Friedrich Wilhelm Neukam, Emeka Nkenke

► To cite this version:

Falk Wehrhan, Peter Hyckel, Kerstin Amann, Jutta Ries, Philipp Stockmann, et al.. Msx-1 is suppressed in Bisphosphonate exposed jaw bone- analysis of bone turnover related cell signalling. Oral Diseases, 2011, 17 (4), pp.433. 10.1111/j.1601-0825.2010.01778.x . hal-00618503

HAL Id: hal-00618503

<https://hal.science/hal-00618503>

Submitted on 2 Sep 2011

HAL is a multi-disciplinary open access archive for the deposit and dissemination of scientific research documents, whether they are published or not. The documents may come from teaching and research institutions in France or abroad, or from public or private research centers.

L'archive ouverte pluridisciplinaire **HAL**, est destinée au dépôt et à la diffusion de documents scientifiques de niveau recherche, publiés ou non, émanant des établissements d'enseignement et de recherche français ou étrangers, des laboratoires publics ou privés.

ORAL DISEASES

Msx-1 is suppressed in Bisphosphonate exposed jaw bone-analysis of bone turnover related cell signalling

Journal:	<i>Oral Diseases</i>
Manuscript ID:	ODI-02-10-OM-1552.R1
Manuscript Type:	Original Manuscript
Date Submitted by the Author:	07-Oct-2010
Complete List of Authors:	Wehrhan, Falk; University of Erlangen-Nürnberg, Oral and Maxillofacial Surgery Hyckel, Peter; University of Jena, Department of Plastic Surgery/ St. Georg-hospital Eisenach Amann, Kerstin; University of Erlangen-Nurmeberg, Institute of Pathology Ries, Jutta; University of Erlangen-Nürnberg, Oral and Maxillofacial Surgery Stockmann, Philipp; University of Erlangen-Nürnberg, Oral and Maxillofacial Surgery Schlegel, Karl; University of Erlangen-Nürnberg, Oral and Maxillofacial Surgery Neukam, Friedrich; University of Erlangen-Nürnberg, Oral and Maxillofacial Surgery Nkenke, Emeka; University of Erlangen-Nürnberg, Oral and Maxillofacial Surgery
Keywords:	Craniofacial, Pathology, Surgery

SCHOLARONE™
Manuscripts

Msx-1 is suppressed in Bisphosphonate exposed jaw bone- analysis of bone turnover related cell signalling

Falk Wehrhan MD, DMD¹; Peter Hyckel MD, DMD, PhD²; Kerstin Amann MD, PhD³; Jutta Ries PhD¹; Phillip Stockmann, MD, DMD¹; Karl A. Schlegel MD, DMD, PhD¹; Friedrich W. Neukam, MD, DMD, PhD¹; Emeka Nkenke MD, DMD, PhD¹

¹ Department of Oral and Maxillofacial Surgery
University of Erlangen-Nuremberg

² Department of Plastic Surgery/ St. Georg-hospital Eisenach
University of Jena

³ Institute of Pathology
University of Erlangen-Nuremberg

running title: ONJ and Msx-1 expression

Keywords: ONJ, Msx-1, aminobisphosphonate, bone, jaw

authors email addresses: Falk.Wehrhan@uk-erlangen.de; Peter.Hyckel@med.uni-jena.de; Kerstin.Amann@uk-erlangen.de; Jutta.Ries@uk-erlangen.de; Phillip.Stockmann@uk-erlangen.de; Andreas.Schlegel@uk-erlangen.de; Friedrich.Neukam@uk-erlangen.de; Emeka.Nkenke@uk-erlangen.de

Corresponding author:
Falk Wehrhan MD, DMD
Department of Oral and Maxillofacial Surgery,
Friedrich-Alexander-University of Erlangen
Glueckstrasse 11, 91054 Erlangen, Germany
Phone: +49-9131-85-33616
Fax: +49-9131-85-34219
Email: Falk.Wehrhan@uk-erlangen.de

Date of submission: 04th of February 2010

Abstract

Objectives:

Bone-destructive disease treatments include bisphosphonates and antibodies against RANKL (aRANKL). Osteonecrosis of the jaw (ONJ) is a side-effect. Etiopathology models failed to explain their restriction to the jaw. The osteoproliferative transcription factor Msx-1 is expressed constitutively only in mature jaw bone. Msx-1 expression might be impaired in bisphosphonate-related ONJ. This study compared the expression of Msx-1, BMP-2 and RANKL, in ONJ-affected and healthy jaw bone.

Material and Methods:

An automated immunohistochemistry-based alkaline phosphatase-anti-alkaline phosphatase method was used on ONJ-affected and healthy jaw bone samples (n=20 each): cell-number ratio (labelling index, Bonferroni adjustment). Real-time RT-PCR was performed to quantitatively compare Msx-1, BMP-2, RANKL, and GAPDH mRNA levels.

Results:

Labeling indices were significantly lower for Msx-1 ($p<0.03$) and RANKL ($p<0.003$), and significantly higher ($p<0.02$) for BMP-2 in ONJ compared to healthy bone. Expression was 7-fold lower ($p<0.03$) for Msx-1, 22-fold lower ($p<0.001$) for RANKL, and 8-fold higher ($p<0.02$) for BMP-2 in ONJ bone.

Conclusions:

Msx-1, RANKL suppression and BMP-2 induction were consistent with the bisphosphonate-associated osteopetrosis and impaired bone remodelling in BP- and aRANKL-induced ONJ. Msx-1 suppression suggested a possible explanation of the exclusivity of ONJ in jaw bone. Functional analyzes of Msx-1- RANKL interaction during bone remodeling should be performed in the future.

1
2
3
4
5
6
7
8
9
10
11
12
13
14
15
16
17
18
19
20
21
22
23
24
25
26
27
28
29
30
31
32
33
34
35
36
37
38
39
40
41
42
43
44
45
46
47
48
49
50
51
52
53
54
55
56
57
58
59
60

Introduction

Bisphosphonates (BP) ameliorate bone-destructive disorders by inhibiting bone resorption. During the past decade, amino-BP treatments have increased by more than 100-fold, due to their excellent efficacy in preventing pain and skeletal events due to bone-invading malignancies (Schwabe U, 2005). In 2003, the first case of BP-associated osteonecrosis of the jaw (ONJ) was described. That report has been substantiated by an increasing number of case reports and studies that described ONJ as a critical complication associated with long-term intravenous amino-BP treatments (Marx, 2003). Thus, the incidence of ONJ appears to be increasing in proportion to the increasing application of BP treatment (Abu-Id et al., 2008). A related therapy is based on inhibiting the receptor activator for nuclear factor κ B ligand (RANKL), an osteoclast differentiation factor that stimulates bone resorption, with the humanized antibody, anti-RANKL (aRANKL). Recent clinical studies have shown that the occurrence of ONJ was also associated with aRANKL treatment; thus, both amino-BP and aRANKL treatments are associated with the development of ONJ (Taylor et al., 2009).

Numerous studies have attempted to describe the pathology that might explain the restriction of ONJ to the jaws, but currently, no generally accepted etiology of ONJ is available (Reid, 2009). Early descriptions of ONJ as an avascular necrosis have been revised due to recent demonstrations of patent vascularisation in ONJ (Hansen et al., 2006b). Indeed, amino-BP treatment was found to improve vascularisation of avascular bone in cases of femur head necrosis and to accelerate fracture repair in extracranial skeletal bone (Agarwala et al., 2002, Matos et al., 2007, Amanat et al., 2007). Several authors have reported an association between ONJ and local inflammation and infection; moreover, ubiquitous, intraoral actinomyces are commonly found in ONJ (Hansen et al., 2006a, Bisdas et al., 2008, Reid, 2009). However, there is no evidence of any specific flora associated with

the development of ONJ, even though ONJ progression and superinfection are promoted by gram-negative bacteria (Reid, 2009, Belibasakis et al., 2007).

Another assumption was that low bone turnover following BP therapy was associated with the clinical appearance of ONJ (Marx et al., 2005). Histomorphological changes similar to osteopetrosis were found to be restricted to the jaw bone following BP-therapy consistent to the first description of ONJ as local osteopetrosis of the jaw bone (Favia et al., 2009). Moreover, BP therapy-related generalised osteopetrosis of the axial skeleton has only been found in pre-adolescent patients (Whyte et al., 2008).

Previous research that assumed ONJ was restricted to the jaws had not considered a potential differential interaction between amino-BP and extracranial skeletal and maxillofacial bone. In vitro studies have shown that jaw-derived and extracranial osteoblasts responded differentially to pamidronate (Stefanik et al., 2008) and presented different patterns of proliferation and osseous differentiation marker expression (Matsubara et al., 2005). The jaw bone is derived from cranial neural crest cells (CNC); in contrast, extracranial bone is derived from mesenchymal stem cells (MsC); thus, the biologically unique features of CNC-derived bone should be considered in the etiopathology of ONJ (Chung et al., 2009). Msx-1 is a transcription factor that induces proliferation and inhibits terminal differentiation of osteoblasts (Roybal et al.). Related to their embryonic origin in CNC, osteoblasts derived from the first branchial arch (jaw bone) express Msx-1 throughout adolescence; in contrast, Msx-1 is downregulated in MsC-derived bone after maturation (Blin-Wakkach et al., 2001, Orestes-Cardoso et al., 2002). In jaw bone, Msx-1 was shown to be expressed

permanently, with the highest concentration in the periodontal ligament; however, in long extracranial bones, Msx-1 was shown to be only transiently reactivated during fracture repair (Orestes-Cardoso et al., 2002, Chung et al., 2009, Babajko et al., 2009) (Ruhin-Poncet et al., 2009).

Several studies have shown that Msx-1 regulation plays roles in both tooth development and adult

1
2
3
4
5
6
7
8
9
10
11
12
13
14
15
16
17
18
19
20
21
22
23
24
25
26
27
28
29
30
31
32
33
34
35
36
37
38
39
40
41
42
43
44
45
46
47
48
49
50
51
52
53
54
55
56
57
58
59
60

alveolar bone regeneration (Babajko et al., 2009, Maxson & Ishii, 2008). In CNC-derived bone Msx-1 was also coexpressed with RANKL in CNC-derived osteoblasts and chondroblast progenitors (Houpis et al., Idowu et al., 2008, Miah et al., 2004). Overexpression of Msx-1 has been postulated to cause cherubism, characterised by hyperproliferation and a honeycomb-like, cystic bone structure, which occurs exclusively in jaw bone (Hyckel et al., 2005, Ueki et al., 2001). In giant cell granuloma of the jaw bone, presenting identical patho-histologic appearance to cherubism overexpression of Msx-1 has been demonstrated (Houpis et al.). Considering the restriction of ONJ to the jaw bone, we hypothesised that the etiology of ONJ might be related to a BP-induced impairment of Msx-1 expression. Moreover, Msx-1 was shown to play a pivotal role in the modulation of bone morphogenetic protein-2 (BMP-2)-related bone homeostasis. This data has spurred interest in investigating the role of Msx-1 in other homeostatic disorders involving bone structures that express Msx-1, such as alveolar bone (Ruhin-Poncet et al., 2009, Gersch et al., 2005).

In this study, based on the facts that BP suppresses RANKL expression and BMP-2/4 and Msx-1 interact during bone homeostasis, we performed a comparative analysis of Msx-1, BMP-2/4, and RANKL gene and protein expression in samples of BP-induced ONJ and healthy jaw bones (Viereck et al., 2002, Nishida et al., 2003, Nishida et al., 2005, Tsubaki et al., 2008). We hypothesized that Msx-1 expression would be diminished in the ONJ-affected jaw bones.

Material and Methods:

Patients and material sampling

Jaw bone specimens from 40 patients were included in this study. Twenty were obtained from consecutive patients undergoing radical sequestrectomy for clinically and histologically evident ONJ. The ethical aspects of this study have been approved by the local ethical committee of the

University Erlangen-Nuremberg (Ref.-Nr. 4272). The surgical procedure and the patient data were documented previously (Stockmann et al., 2009). The specimens used in this study were part of the tissue samples provided for routine histopathological diagnostics, and each displayed the histopathological characteristics of ONJ. In addition, our criteria for including the specimen in this investigation were: prior intravenous application of either pamidronate or zoledronate for at least 12 months and clinical evidence of exposed jaw bone for at least 8 weeks. Any specimens from patients with former radiotherapy were excluded. All specimens were obtained during clinically routine procedures and harvested from the same tissues needed for standard diagnostics; therefore, no surgical procedure specific to this study was performed and no additional material was harvested from the patients. In the ONJ group bone tissue, adjacent to the necrotic, exposed jaw bone surface was used. The bone specimens were part of the material which was resected. The necrotic tissue itself was excluded from the analysis, only solid bone pieces were included in the investigation. Attached gingiva tissue was removed from the specimens.

The controls comprised 20 alveolar bone specimens, harvested during intraoral surgery procedures, from patients that did not have any BP-history and did not present any clinical signs of intraoral inflammatory processes or periodontitis. In the group of healthy jaw bone samples were harvested from bone material which was removed when bone surface was smoothened after dental extraction.

The average size of the 40 specimens used in this study was $5 \times 3 \times 3$ mm. Each group of 20 specimens was divided into 2 equal parts. One part was immediately shock frozen at -80°C , and the other was immersed in RNA preserving reagent (RNALater, Quiagen, Hilden, Germany) for 24 h at 4°C , and then frozen and stored at -80°C .

Immunohistochemical staining

In preparation for immunohistochemical staining, tissue samples were fixed in 4% formalin; then, samples were decalcified (10% EDTA, pH 7.4), paraffin-embedded, cut into serial sections with a

1
2
3
4
5
6
7
8
9
10
11
12
13
14
15
16
17
18
19
20
21
22
23
24
25
26
27
28
29
30
31
32
33
34
35
36
37
38
39
40
41
42
43
44
45
46
47
48
49
50
51
52
53
54
55
56
57
58
59
60

microtome (Leica, Nussloch, Germany), and dewaxed in graded alcohol. Immunohistochemical staining was performed with the alkaline phosphatase-anti-alkaline phosphatase (APAAP) method and an automated staining device (Autostainer plus, DakoCytomation, Hamburg, Germany), according to the manufacturer's instructions (Dako Real, Cat. K5005, DakoCytomation). Msx-1 was targeted with a polyclonal, rabbit-IgG, anti-human Msx-1 antibody (anti-Msx-1; M0944-100G, Sigma-Aldrich, Taufkirchen, Germany; dilution 1:100). BMP-2/4 was detected by a polyclonal, rabbit-IgG, anti-human BMP antibody (anti-human BMP 2/4, sc-9003, Santa Cruz, Santa Cruz, USA; dilution: 1:100). RANKL was targeted with a polyclonal, rabbit-anti-human RANKL antibody (sc-9073, Santa Cruz, dilution 1:100). Antibodies were incubated with tissue sections in the autostainer (20°C, 1h). The secondary antibody used for all primary antibodies, a biotinylated polyclonal, goat-anti-rabbit IgG (E 0466, DAKO, dilution 1:100), was applied according to the staining kit instructions. Visualisation of stained sections was performed with Fast Red solution, localised with biotin-associated activation (ChemMate-Kit, Dako), followed by incubation in hematoxylin for nuclear counterstaining. Two consecutive tissue samples were processed per immunohistochemical staining. One served as a negative control in each case (identical treatment, but replacement of the primary antibody with an istotype-IgG of the primary antibody). A known positive staining sample was also included in each series as a positive control.

Semiquantitative immunohistochemical analysis

Bone tissue sections were qualitatively evaluated under a bright-field microscope (Axioskop, Zeiss, Jena, Germany) at 100-400× magnification. We compared the numbers and localisations of stained osteocytes, osteoblasts, osteoblast progenitors, and fibroblasts in samples of ONJ-affected and healthy bone. In healthy bone, we observed bone trabecular, periosteal, and endosteal structures. In ONJ samples, we examined bone tissue attached to the necrotic bone defect. Within these areas, 3 visual fields per section for each sample were digitized at 200 × magnification with a CCD camera

(AxioCam 5, Zeiss, Jena, Germany) and Axiovision software (Axiovision, Zeiss, Jena, Germany). Randomised systematic subsampling was performed according to the method described by Weibel (Weibel, 1989). We performed semiquantitative analyses of the cytoplasmic expression of Msx-1, BMP-2/4, and RANKL to determine the labelling index; i.e., the ratio of positively stained cells to the total number of cells per visual field, multiplied by 100.

Quantitative mRNA analysis and real-time, reverse transcription, polymerase chain reaction

Frozen tissues were agitated (Mixer Mill, Quiagen, Hilden, Germany) in lysis buffer (RNeasy Kit, QIAGEN, Hilden, Germany), and total RNA was extracted from tissues with the RNeasy Kit according to the manufacturer's protocol. The mRNA detected with each probe was quantitatively measured with a commercial microfluid Lab-on-a-Chip kit (Agilent RNA 6000 Pico Kit Agilent, Waldbronn, Germany) and the Agilent 2100 Bioanalyzer (Agilent, Waldbronn, Germany). We synthesised cDNAs from total RNA with the High Capacity cDNA Archive Kit (Cat. 4322171; Applied Biosystems, CA, USA) according to the manufacturer's protocol. Real-time reverse transcription (RT) quantitative polymerase chain reaction (qPCR) analyses were performed with the QIAGEN kits: Hs_BMP2_1_SG QuantiTect Primer Assay (200) (Cat. GT00012544) to amplify BMP-2, Hs_MSX1_SG QuantiTect Primer Assay (200) (Cat. GT00224350) to amplify Msx-1, and Hs_TNFSF11_va.1_SG QuantiTect Primer Assay (200) (Cat. QT01011381) to amplify RANKL; for normalisation, we used the Hs_GAPDH_1_SG QuantiTect Primer Assay (200) (Cat. QT00079247), to amplify GAPDH. We performed relative quantifications of mRNA with the ABI Prism 7300 Sequence Detection System (Applied Biosystems). We performed PCR amplification with the QuantiTect TM SYBR® green PCR kit (Cat. 204143; QIAGEN). In total, 40 ng of cDNA was used for each PCR reaction in a total volume of 25 µl. Each PCR run included a 15 min activation time at 95°C, followed by 40 cycles of: denaturing at 94°C for 15 s, annealing at 55°C for 30 s, and extension at 72°C for 34 s. Undesired PCR side-products that might contribute to the

1
2
3
4
5
6
7
8
9
10
11
12
13
14
15
16
17
18
19
20
21
22
23
24
25
26
27
28
29
30
31
32
33
34
35
36
37
38
39
40
41
42
43
44
45
46
47
48
49
50
51
52
53
54
55
56
57
58
59
60

fluorescence signal were assessed by melting curve analysis after PCR. The quantities of MSX-1, BMP-2, and RANKL mRNA were analysed in duplicate, and normalised against GAPDH as an internal control gene. The mRNA from BP-affected tissue was expressed relative to the mRNA isolated from tissues from normal patients without ONJ. Relative gene expression was determined with the $\Delta\Delta C_t$ method. In order to exclude influences from other disorders that might be associated with the normal group of patients, RNA was isolated from healthy oral periosteum (pool of 15 patients) for calibration.

Statistical analysis

The labelling index per visual field of positively stained cells was used to analyse the immunohistochemical cytoplasmic staining and the spatial pattern of expression. To assess the relative gene expressions from the real- time RT-PCR products, we set the median gene expression levels of Msx-1, BMP-2, and RANKL observed in the pool of healthy oral periosteum as a calibrator. Then, the gene expressions in both the ONJ-affected and unaffected groups were expressed relative to the calibrator. Multiple measurements per study group were aggregated prior to analysis. The labelling indices and relative gene expression data were expressed as the median (ME) and the interquartile range (IQR). Graphical diagrams represented the median, the interquartile range, minimum (Min), and maximum (Max) values. Confirmatory comparisons between treatment and control groups were performed with generalised estimating equations (GEE) that used the “treatment modality”, and the “subject id” as independent factors for appropriate analysis of repeated measurements per individual. Multiple p values were adjusted according to Bonferroni by multiplying each p value obtained by the number of confirmatory tests performed (n=10). Two-sided adjusted p-values ≤ 0.05 were considered significant. All calculations were performed with SPSS 17.0 for Windows (SPSS Inc, Chicago, USA).

Results

Histochemical assessments revealed that all examined ONJ-affected samples displayed necrotic bone, represented by empty osteocyte lacunae, and vital bone zones. (Figs. 1C, 2C, 3C). The necrotic lesions consistently showed partial confluency, as described by other authors (6, 36). Inflammatory infiltrates, including multinucleated cells, were present in all ONJ-affected samples. Capillaries were observed in both ONJ-affected and normal bone samples.

Osteoblast Msx-1 expression and Msx-1-mRNA were reduced in ONJ-affected jaw bone

In the ONJ-affected bone, the density of cells that expressed Msx-1 was reduced compared to that observed in normal jaw bone (Fig. 1). However, the fact that Msx-1 protein was detected in both ONJ-affected and normal osteoblasts indicated that Msx-1 expression persisted in the jaw bone during adulthood, as described by other groups (Orestes-Cardoso et al., 2001, Babajko et al., 2009). In normal jaw bone, the Msx-1 staining density was higher in periosteal and endosteal cells compared to trabecular cells. Also, the fibrous tissue surrounding the bone trabeculae displayed nuclear and cytoplasmic Msx-1 staining. In the ONJ group, Msx-1 staining was rare in endosteal cells, and the fibroblasts in the fibrous and inflammatory tissue surrounding the bone trabeculae displayed reduced Msx-1 expression. Next, we assessed the number of osteoblasts, osteocytes, and endosteal cells that expressed Msx-1 compared to the total number of bone-related cells. This labeling index (ratio of Msx-1 expressing cells:total number of bone related cells) showed that the relative cellular Msx-1 expression in the ONJ group was significantly diminished ($p < 0.03$; ME: 19.01; IQR: 16.2) compared to that of normal bone (ME: 74.21; IQR: 32.0) (Fig. 1E). Next, we evaluated the relative levels of gene expression for Msx-1 (Fig. 1F). We used the mRNA of 15 healthy oral mucoperiosteal specimens as a calibrator, because Msx-1, BMP-2/4, and RANKL are constitutively expressed in oral mucoperiosteum (Babajko et al., 2009, Teot et al., 1996, Spencer et al., 2006, Leucht et al., 2008, Gersch et al., 2005). We found that Msx-1 mRNA-expression was

1
2
3
4
5
6
7
8
9
10
11
12
13
14
15
16
17
18
19
20
21
22
23
24
25
26
27
28
29
30
31
32
33
34
35
36
37
38
39
40
41
42
43
44
45
46
47
48
49
50
51
52
53
54
55
56
57
58
59
60

significantly reduced in ONJ-affected bone samples ($p<0.03$; ME: 1.81; range: 3.82) compared to normal jaw bone (ME: 12.39, range: 3.15). When the *Msx-1*-mRNA expression level in oral mucoperiosteum was set to unity (ME: 1.00, IQR: 1.72), we found that the mean *Msx-1* mRNA level was 7-fold lower in ONJ-affected than in healthy jaw bone.

BMP-2/4 expression and the density of connective tissue-related cells that expressed BMP-2/4 were increased in ONJ-affected bone

BMP-2/4 expression was detected in osteoblasts from both the healthy (Fig. 2A) and the ONJ-affected samples (Fig. 2C). The ONJ-affected jaw bone displayed a higher density of osteocytes that expressed BMP-2/4 compared to normal jaw bone. In addition, in ONJ-affected jaw bone, the periosteum and connective tissue adjacent to the bone margins displayed a higher density of cellular BMP-2/4 staining than samples of the extracellular matrix that covered the normal jaw bone. The median labeling index of osteoblasts and osteocytes that expressed BMP-2/4 was significantly higher in the ONJ-affected bone ($p<0.02$; ME: 60.43; IQR: 24.0) than in the control jaw bone (ME: 26.32; IQR: 16.0) (Fig. 2E). Moreover, BMP-2/4 mRNA expression was significantly elevated in the ONJ-bone ($p<0.02$; ME: 8.9; IQR: 6.1) compared to the control jaw bone (ME: 1.14; IQR: 1.07) (Fig. 2F). The BMP-2/4 mRNA expression was not significantly different between the control mucoperiosteum calibrator (ME: 0.84; IQR: 0.78) and normal jaw bone. The level of BMP-2 mRNA expression in ONJ-affected jaw bone was approximately 8-fold higher than in normal jaw bone.

Number of cells that expressed RANKL and RANKL-mRNA levels was dramatically reduced in the ONJ-affected bone

In normal jaw bone, RANKL expression was detected in the bone sections, including the periosteal soft tissue (Fig. 3A). However, in ONJ-affected jaw bone, RANKL was only sparsely expressed in

endosteal and periosteal cells (Fig. 3C). In the soft tissues of ONJ-affected samples, the spatial distribution of RANKL expressing cells was inhomogeneous compared to that observed in the normal jaw bone. Local concentrations of multinucleated cells that expressed RANKL were detected only at zones of osseous resorption in ONJ samples (Fig. 3C, D). The overall density of cells that expressed RANKL was significantly lower in the ONJ-affected compared to normal jaw bone. This was reflected in the significantly reduced labeling index for cytoplasmic RANKL in ONJ-affected ($p < 0.003$; ME: 22.63; IQR: 14) compared to normal jaw bone (ME: 53.45; IQR: 26) (Fig. 3E). RANKL mRNA expression was significantly lower ($p < 0.001$) in ONJ-affected samples (ME: 69.8; IQR: 135.3) than that detected in healthy jaw bone (ME: 1538.80; IQR: 1322.34) and mucoperiosteal tissue samples (ME: 1.00; IQR: 147.33) (Fig. 3F). The levels of RANKL mRNA were 22-fold lower in the ONJ-affected jaw bone compared to normal jaw bone.

Discussion

This study was the first to investigate the influence of BP on jaw bone specific osseous differentiation in ONJ. The results showed that expression of the osteoproliferative transcription factor Msx-1 was significantly diminished in ONJ-affected jaw bone at both the protein ($p < 0.03$) and mRNA ($p < 0.03$) levels. Furthermore, we found that the expression of RANKL was significantly reduced in the bone surrounding the ONJ lesion, and the expression of BMP-2/4 was significantly elevated. These results indicated that the remodeling is suppressed in BP-compromised jaw bone. The immunohistochemical and molecularbiological findings in this study were consistent with those found in osteopetrotic bone (Cohen, 2006). ONJ has previously been described to present histomorphology of local osteopetrosis (Favia et al., 2009, Marx et al., 2005) (Lesclois, 2009). The reduction of osteoclastic activity and overwhelming mineralization without adequate increase of blood supply was suggested to predispose to ischemic bone necrosis resulting in

1
2
3
4
5
6
7
8
9
10
11
12
13
14
15
16
17
18
19
20
21
22
23
24
25
26
27
28
29
30
31
32
33
34
35
36
37
38
39
40
41
42
43
44
45
46
47
48
49
50
51
52
53
54
55
56
57
58
59
60

secondary inflammation and bacterial superinfection as seen in ONJ (Favia et al., 2009) (Barry & Ryan, 2003). Indeed, osteopetrosis is a known endogenous disorder associated with exposed bone and osteomyelitis of the jaw bone (Barry & Ryan, 2003, Reid, 2009). Osteopetrosis-like lesions have been reported following oral application of white phosphorus (Abu-Id et al., 2008). It has been suggested that a BP-related loss of Msx-1, especially in the periodontal ligament, might be associated with some ONJ characteristics, including a sclerotic, non-healing extraction socket and periapical hypermineralised thin lines around dental roots (Chung et al., 2009, Babajko et al., 2009). The periodontal ligament has been found to harbour the highest endogenous concentration of Msx-1 in the jaw bone (Ishii et al., 2005)(Orestes-Cardoso et al., 2002, Orestes-Cardoso et al., 2001). In rat periodontal ligamentum cells, BP treatment caused recruitment of bone forming cells, induction of osseous differentiation markers osteopontin and bone sialoprotein, and reduction of periodontal ligamentum cell numbers (Lekic et al., 1997). Msx-1 has been reported to be critically involved in preventing terminal differentiation and stimulating proliferation of osteoblast progenitors; thus, the loss of Msx-1 is likely to be associated with poor osteoblast proliferation and overwhelming mineralisation in jaw bone (Newberry et al., 1997, Dodig et al., 1996). Msx-1 and Msx-2 functions have been shown to overlap in the developing jaw, but only Msx-1 expression continues into adulthood (Berdal et al., 2009). Msx-1 represses transcription of the terminal differentiation mediator osteocalcin by inhibiting the osteogenesis regulator, DLX5 (Hoffmann et al., 1994). Msx-1 has been shown to be overexpressed in giant cell granuloma (Houpis et al.). Msx-1 has been postulated to be causative involved in the development and progression of cherubism. Cherubism and giant cellular granuloma share both the histologic phenotype of hyperproliferation of non-mineralized bone tissue and their restriction to jaw bone (Hyckel et al., 2005, Ueki et al., 2001). BP-induced sclerotic changes and hypermineralisation of exposed alveolar bone are consistent with the loss of Msx-1 dependent osteocalcin repression (Favia et al., 2009) (Shirakabe et al., 2001). Furthermore, systemic osteopetrosis following Amino-BP therapy has only been

described in the premature, growing skeleton, consistent with the downregulation of Msx-1 in the extracranial skeleton after the maturation of bones (Whyte et al., 2008, Whyte et al., 2003).

BMP-2 is an essential osteoinductor and inducer of bone mineralisation. Our finding that BMP-2 expression was significantly higher at both the protein ($p<0.02$) and mRNA ($p<0.02$) levels in ONJ-affected bone is consistent with the clinical and radiologic observations that ONJ-affected jaw bone appears osteopetrotic (Marx et al., 2005). Experimental and clinical findings have shown that BMP-2 and Msx-1 expression are partially antagonistic during jaw bone and dental development (Dodig et al., 1996, Newberry et al., 1997). BMP-2 is a morphogen that inhibits proliferation and mediates osseous differentiation and mineralisation. Msx-1 has been found to modulate signalling downstream of BMP-2 by antagonising the expression of the osteogenesis regulator, DLX5 (Cohen, 2006) (Ryoo et al., 1997). Msx knockout animals showed unaltered BMP-2 expression (Aioub et al., 2007).

BP treatment has been shown to prevent osteoclast activation and bone resorption in malignancies and osteoporosis (Nishida et al., 2005, Viereck et al., 2002) primarily by suppressing RANKL activity. Thus, we were not surprised to find that the expression of RANKL was significantly reduced in ONJ-affected bone at both the protein ($p<0.003$) and mRNA ($p<0.001$) levels. Clinically, BP was also shown to enhance fracture repair of extracranial skeletal bone; this suggested that BP could differentially impact RANKL-mediated bone remodelling in jaw and extracranial bone structures, even though the RANK/RANKL-OPG system regulates both CNC-derived bone and MsC-derived osteoblasts (Agarwala et al., 2002, Amanat et al., 2007, Matos et al., 2007). Experimentally application of zoledronic acid induced inflammation of the jaw bone, but did not affect the axial skeleton (Senel et al.). The disparate effects of BP could be due to the parallel regulation of RANKL and Msx-1 expression in CNC-derived Msx-1 progenitors (Houpis et al., Idowu et al., 2008, Miah et al., 2004). Experimental disruption of Msx resulted in significantly reduced RANKL expression and osteopetrosis in the jaw bone of a mouse model (Aioub et al.,

1
2
3
4
5
6
7
8
9
10
11
12
13
14
15
16
17
18
19
20
21
22
23
24
25
26
27
28
29
30
31
32
33
34
35
36
37
38
39
40
41
42
43
44
45
46
47
48
49
50
51
52
53
54
55
56
57
58
59
60

2007). Despite our finding that RANKL expression was reduced throughout the ONJ-affected jaw bone, we observed histological evidence of osteoclast activity in the ONJ zone; this might be due to direct RANKL activation in osteoclasts by intraoral gram-negative bacteria, consistent with the findings from other groups (Bisdas et al., 2008, Reid, 2009, Belibasakis et al., 2007). The notion that local intraoral gram-negative bacteria might have induced bone resorption by the local activation of RANKL is supported by the clinical findings that periodontitis was reduced with application of the BP, alendronate (Menezes et al., 2005, Reddy et al., 2005).

The findings of this study may contribute to elucidate the differential impact of BP on CNC-derived jaw bone remodelling compared to mesoderm-derived extracranial bone. ONJ development is associated with impaired jaw bone turnover and local osteopetrosis; both these processes have been linked to the loss of Msx-1 in alveolar bone (Favia et al., 2009, Aioub et al., 2007). To our knowledge, this is the first study to investigate unique features of CNC-derived bone in connection with BP treatment. Msx-1 is also known to be a key regulator of the Vitamin D receptor. Therefore, understanding the clinical impact of Msx-1 could be of therapeutic relevance in other diseases associated with impaired bone homeostasis (Lezot et al., 2004). The association of ONJ with aRANKL therapy supports the suggestion that the mechanism underlying the restriction of ONJ to the jaws may be CNC-specific cell signalling alterations (Taylor et al., 2009, Stopeck et al., 2009, Henry et al., 2009). In agreement with leading international experts in the field of ONJ, we concluded that targeting the unique features of the jaw bone is a promising approach to elucidate the underlying pathologic mechanisms of ONJ (Khosla et al., 2007). Of note, BP and aRANKL had differential impacts on proliferation, vascularisation, and surface marker expression jaw bone compared to extracranial bone derived structures (Stefanik et al., 2008, Matsubara et al., 2005). This suggests that BP effects on Msx- and RANKL-related interactions in CNC- and MsC-derived osteoblasts, osteoclasts, and bone structures should be investigated in more detail in the future.

Acknowledgements

The authors thank Heidemarie Heider, Andrea Kosel, and Miriam Ramming for operating the immunohistochemistry autostainer. In addition, we would like to thank Andrea Krautheim-Zenk for help with the mRNA and RT-PCR processing. All authors declare no conflict of interests.

Funding: This investigation was funded by the ELAN-Fonds of the University of Erlangen-Nuremberg, Germany

Disclosure statement: All authors declare no disclosures.

1
2
3
4
5
6
7
8
9
10
11
12
13
14
15
16
17
18
19
20
21
22
23
24
25
26
27
28
29
30
31
32
33
34
35
36
37
38
39
40
41
42
43
44
45
46
47
48
49
50
51
52
53
54
55
56
57
58
59
60

References

Abu-Id MH, Warnke PH, Gottschalk J, Springer I, Wiltfang J, Acil Y, Russo PA and Kreusch T (2008). "Bis-phosphy jaws" - high and low risk factors for bisphosphonate-induced osteonecrosis of the jaw. *J Craniomaxillofac Surg* **36**: 95-103.

Agarwala S, Sule A, Pai BU and Joshi VR (2002). Alendronate in the treatment of avascular necrosis of the hip. *Rheumatology (Oxford, England)* **41**: 346-7.

Aioub M, Lezot F, Molla M, Castaneda B, Robert B, Goubin G, Nefussi JR and Berdal A (2007). Msx2 -/- transgenic mice develop compound amelogenesis imperfecta, dentinogenesis imperfecta and periodontal osteopetrosis. *Bone* **41**: 851-9.

Amanat N, McDonald M, Godfrey C, Bilston L and Little D (2007). Optimal timing of a single dose of zoledronic acid to increase strength in rat fracture repair. *J Bone Miner Res* **22**: 867-76.

Babajko S, Petit S, Fernandes I, Meary F, LeBihan J, Pibouin L and Berdal A (2009). Msx1 expression regulation by its own antisense RNA: consequence on tooth development and bone regeneration. *Cells, tissues, organs* **189**: 115-21.

Barry CP and Ryan CD (2003). Osteomyelitis of the maxilla secondary to osteopetrosis: report of a case. *Oral Surg Oral Med Oral Pathol Oral Radiol Endod* **95**: 12-5.

Belibasakis GN, Bostanci N, Hashim A, Johansson A, Aduse-Opoku J, Curtis MA and Hughes FJ (2007). Regulation of RANKL and OPG gene expression in human gingival fibroblasts and periodontal ligament cells by Porphyromonas gingivalis: a putative role of the Arg-gingipains. *Microbial pathogenesis* **43**: 46-53.

Berdal A, Molla M, Hotton D, Aioub M, Lezot F, Nefussi JR and Goubin G (2009). Differential impact of MSX1 and MSX2 homeogenes on mouse maxillofacial skeleton. *Cells, tissues, organs* **189**: 126-32.

Bisdas S, Chambron Pinho N, Smolarz A, Sader R, Vogl TJ and Mack MG (2008). Biposphonate-induced osteonecrosis of the jaws: CT and MRI spectrum of findings in 32 patients. *Clinical radiology* **63**: 71-7.

Blin-Wakkach C, Lezot F, Ghoul-Mazgar S, Hotton D, Monteiro S, Teillaud C, Pibouin L, Orestes-Cardoso S, Papagerakis P, Macdougall M, Robert B and Berdal A (2001). Endogenous Msx1 antisense transcript: in vivo and in vitro evidences, structure, and potential involvement in skeleton development in mammals. *Proc.Natl.Acad.Sci.U.S.A* **98**: 7336-7341.

Chung IH, Yamaza T, Zhao H, Choung PH, Shi S and Chai Y (2009). Stem cell property of postmigratory cranial neural crest cells and their utility in alveolar bone regeneration and tooth development. *Stem Cells* **27**: 866-77.

Cohen MM, Jr. (2006). The new bone biology: pathologic, molecular, and clinical correlates. *American journal of medical genetics* **140**: 2646-706.

Dodig M, Kronenberg MS, Bedalov A, Kream BE, Gronowicz G, Clark SH, Mack K, Liu YH, Maxon R, Pan ZZ, Upholt WB, Rowe DW and Lichtler AC (1996). Identification of a TAAT-containing motif required for high level expression of the COL1A1 promoter in differentiated osteoblasts of transgenic mice. *J.Biol.Chem.* **271**: 16422-16429.

Favia G, Pilolli GP and Maiorano E (2009). Histologic and histomorphometric features of bisphosphonate-related osteonecrosis of the jaws: An analysis of 31 cases with confocal laser scanning microscopy. *Bone*.

Gersch RP, Lombardo F, McGovern SC and Hadjiargyrou M (2005). Reactivation of Hox gene expression during bone regeneration. *J Orthop Res* **23**: 882-90.

Hansen T, Kunkel M, Kirkpatrick CJ and Weber A (2006a). Actinomyces in infected osteoradionecrosis--underestimated? *Human pathology* **37**: 61-7.

- Hansen T, Kunkel M, Weber A and James Kirkpatrick C (2006b). Osteonecrosis of the jaws in patients treated with bisphosphonates - histomorphologic analysis in comparison with infected osteoradionecrosis. *J Oral Pathol Med* **35**: 155-60.
- Henry D, vonMoos R, Vadhan-Raj S and al. e (2009). A double-blind, randomized study of denosumab versus zoledronic acid for the treatment of bone metastases in patients with advanced cancer (excluding breast and prostate cancer) or multiple myeloma. *Eur J Can Suppl* **7**.
- Hoffmann HM, Catron KM, van Wijnen AJ, McCabe LR, Lian JB, Stein GS and Stein JL (1994). Transcriptional control of the tissue-specific, developmentally regulated osteocalcin gene requires a binding motif for the Msx family of homeodomain proteins. *Proc Natl Acad Sci U S A* **91**: 12887-91.
- Houpis CH, Tosios KI, Papavasileiou D, Christopoulos PG, Koutlas IG, Sklavounou A and Alexandridis C Parathyroid hormone-related peptide (PTHrP), parathyroid hormone/parathyroid hormone-related peptide receptor 1 (PTHrP1), and MSX1 protein are expressed in central and peripheral giant cell granulomas of the jaws. *Oral Surg Oral Med Oral Pathol Oral Radiol Endod*.
- Hyckel P, Berndt A, Schleier P, Clement JH, Beensen V, Peters H and Kosmehl H (2005). Cherubism - new hypotheses on pathogenesis and therapeutic consequences. *J.Craniomaxillofac.Surg.* **33**: 61-68.
- Idowu BD, Thomas G, Frow R, Diss TC and Flanagan AM (2008). Mutations in SH3BP2, the cherubism gene, were not detected in central or peripheral giant cell tumours of the jaw. *Br J Oral Maxillofac Surg* **46**: 229-30.
- Ishii M, Han J, Yen HY, Sucov HM, Chai Y and Maxson RE, Jr. (2005). Combined deficiencies of Msx1 and Msx2 cause impaired patterning and survival of the cranial neural crest. *Development* **132**: 4937-50.
- Khosla S, Burr D, Cauley J, Dempster DW, Ebeling PR, Felsenberg D, Gagel RF, Gilsanz V, Guise T, Koka S, McCauley LK, McGowan J, McKee MD, Mohla S, Pendrys DG, Raisz LG, Ruggiero SL, Shafer DM, Shum L, Silverman SL, Van Poznak CH, Watts N, Woo SB and Shane E (2007). Bisphosphonate-associated osteonecrosis of the jaw: report of a task force of the American Society for Bone and Mineral Research. *J Bone Miner Res* **22**: 1479-91.
- Lekic P, Rubbino I, Krasnoshtein F, Cheifetz S, McCulloch CA and Tenenbaum H (1997). Bisphosphonate modulates proliferation and differentiation of rat periodontal ligament cells during wound healing. *Anat Rec* **247**: 329-40.
- Lesclous P (2009). Bisphosphonate-associated osteonecrosis of the jaw: a key role of inflammation? *Bone*.
- Leucht P, Kim JB, Amasha R, James AW, Girod S and Helms JA (2008). Embryonic origin and Hox status determine progenitor cell fate during adult bone regeneration. *Development* **135**: 2845-54.
- Lezot F, Coudert A, Petit S, Vi-Fane B, Hotton D, Davideau JL, Kato S, Descroix V, Pibouin L and Berdal A (2004). Does Vitamin D play a role on Msx1 homeoprotein expression involving an endogenous antisense mRNA? *The Journal of steroid biochemistry and molecular biology* **89-90**: 413-7.
- Marx RE (2003). Pamidronate (Aredia) and zoledronate (Zometa) induced avascular necrosis of the jaws: a growing epidemic. *J.Oral Maxillofac.Surg.* **61**: 1115-1117.
- Marx RE, Sawatari Y, Fortin M and Broumand V (2005). Bisphosphonate-induced exposed bone (osteonecrosis/osteopetrosis) of the jaws: risk factors, recognition, prevention, and treatment. *J Oral Maxillofac Surg* **63**: 1567-75.
- Matos MA, Araujo FP and Paixao FB (2007). The effect of zoledronate on bone remodeling during the healing process. *Acta Cir Bras* **22**: 115-9.
- Matsubara T, Suardita K, Ishii M, Sugiyama M, Igarashi A, Oda R, Nishimura M, Saito M, Nakagawa K, Yamanaka K, Miyazaki K, Shimizu M, Bhawal UK, Tsuji K, Nakamura K and Kato

- Y (2005). Alveolar bone marrow as a cell source for regenerative medicine: differences between alveolar and iliac bone marrow stromal cells. *J Bone Miner Res* **20**: 399-409.
- Maxson R and Ishii M (2008). The Bmp pathway in skull vault development. *Front Oral Biol* **12**: 197-208.
- Menezes AM, Rocha FA, Chaves HV, Carvalho CB, Ribeiro RA and Brito GA (2005). Effect of sodium alendronate on alveolar bone resorption in experimental periodontitis in rats. *J Periodontol* **76**: 1901-9.
- Miah SM, Hatani T, Qu X, Yamamura H and Sada K (2004). Point mutations of 3BP2 identified in human-inherited disease cherubism result in the loss of function. *Genes Cells* **9**: 993-1004.
- Newberry EP, Boudreaux JM and Towler DA (1997). Stimulus-selective inhibition of rat osteocalcin promoter induction and protein-DNA interactions by the homeodomain repressor Msx2. *J.Biol.Chem.* **272**: 29607-29613.
- Nishida S, Kikuichi S, Haga H, Yoshioka S, Tsubaki M, Fujii K and Irimajiri K (2003). Apoptosis-inducing effect of a new bisphosphonate, YM529, on various hematopoietic tumor cell lines. *Biol Pharm Bull* **26**: 96-100.
- Nishida S, Tsubaki M, Hoshino M, Namimatsu A, Uji H, Yoshioka S, Tanimori Y, Yanae M, Iwaki M and Irimajiri K (2005). Nitrogen-containing bisphosphonate, YM529/ONO-5920 (a novel minodronic acid), inhibits RANKL expression in a cultured bone marrow stromal cell line ST2. *Biochem Biophys Res Commun* **328**: 91-7.
- Orestes-Cardoso S, Nefussi JR, Lezot F, Oboeuf M, Pereira M, Mesbah M, Robert B and Berdal A (2002). Msx1 is a regulator of bone formation during development and postnatal growth: in vivo investigations in a transgenic mouse model. *Connect.Tissue Res.* **43**: 153-160.
- Orestes-Cardoso SM, Nefussi JR, Hotton D, Mesbah M, Orestes-Cardoso MD, Robert B and Berdal A (2001). Postnatal Msx1 expression pattern in craniofacial, axial, and appendicular skeleton of transgenic mice from the first week until the second year. *Dev.Dyn.* **221**: 1-13.
- Reddy GT, Kumar TM and Veena (2005). Formulation and evaluation of Alendronate Sodium gel for the treatment of bone resorptive lesions in Periodontitis. *Drug Deliv* **12**: 217-22.
- Reid IR (2009). Osteonecrosis of the jaw: who gets it, and why? *Bone* **44**: 4-10.
- Roybal PG, Wu NL, Sun J, Ting MC, Schafer CA and Maxson RE Inactivation of Msx1 and Msx2 in neural crest reveals an unexpected role in suppressing heterotopic bone formation in the head. *Dev Biol* **343**: 28-39.
- Ruhin-Poncet B, Ghouli-Mazgar S, Hotton D, Capron F, Jaafoura MH, Goubin G and Berdal A (2009). Msx and dlx homeogene expression in epithelial odontogenic tumors. *J Histochem Cytochem* **57**: 69-78.
- Ryoo HM, Hoffmann HM, Beumer T, Frenkel B, Towler DA, Stein GS, Stein JL, van Wijnen AJ and Lian JB (1997). Stage-specific expression of Dlx-5 during osteoblast differentiation: involvement in regulation of osteocalcin gene expression. *Mol Endocrinol* **11**: 1681-94.
- Schwabe U ZR (2005). Mineralstoffpräparate und Osteoporosemittel. In Schwabe U, Paffrath D (Eds), *Arzneiverordnungsreport 2005, Berlin Heidelberg: Springer 2005*: 755-756.
- Senel FC, Duman MK, Muci E, Cankaya M, Pampu AA, Ersoz S and Gunhan O Jaw bone changes in rats after treatment with zoledronate and pamidronate. *Oral Surg Oral Med Oral Pathol Oral Radiol Endod.*
- Shirakabe K, Terasawa K, Miyama K, Shibuya H and Nishida E (2001). Regulation of the activity of the transcription factor Runx2 by two homeobox proteins, Msx2 and Dlx5. *Genes Cells* **6**: 851-6.
- Spencer GJ, Utting JC, Etheridge SL, Arnett TR and Genever PG (2006). Wnt signalling in osteoblasts regulates expression of the receptor activator of NFkappaB ligand and inhibits osteoclastogenesis in vitro. *J Cell Sci* **119**: 1283-96.

- Stefanik D, Sarin J, Lam T, Levin L, Leboy PS and Akintoye SO (2008). Disparate osteogenic response of mandible and iliac crest bone marrow stromal cells to pamidronate. *Oral diseases* **14**: 465-71.
- Stockmann P, Vairaktaris E, Wehrhan F, Seiss M, Schwarz S, Spriewald B, Neukam FW and Nkenke E (2009). Osteotomy and primary wound closure in bisphosphonate-associated osteonecrosis of the jaw: a prospective clinical study with 12 months follow-up. *Support Care Cancer*.
- Stopeck A, Body J, Fujiwara Y and al. e (2009). Denosumab versus zoledronic acid for the treatment of breast cancer patients with bone metastases: results of a randomized phase 3 study. *Eur J Can Suppl* **7**.
- Taylor KH, Middlefell LS and Mizen KD (2009). Osteonecrosis of the jaws induced by anti-RANK ligand therapy. *Br J Oral Maxillofac Surg*.
- Teot LA, O'Keefe RJ, Rosier RN, O'Connell JX, Fox EJ and Hicks DG (1996). Extrasosseous primary and recurrent giant cell tumors: transforming growth factor-beta1 and -beta2 expression may explain metaplastic bone formation. *Hum.Pathol.* **27**: 625-632.
- Tsubaki M, Kato C, Nishinobo M, Ogaki M, Satou T, Ito T, Kusunoki T, Fujiwara K, Yamazoe Y and Nishida S (2008). Nitrogen-containing bisphosphonate, YM529/ONO-5920, inhibits macrophage inflammatory protein 1 alpha expression and secretion in mouse myeloma cells. *Cancer Sci* **99**: 152-8.
- Ueki Y, Tiziani V, Santanna C, Fukai N, Maulik C, Garfinkle J, Ninomiya C, doAmaral C, Peters H, Habal M, Rhee-Morris L, Doss JB, Kreiborg S, Olsen BR and Reichenberger E (2001). Mutations in the gene encoding c-Abl-binding protein SH3BP2 cause cherubism. *Nat Genet* **28**: 125-6.
- Viereck V, Emons G, Lauck V, Frosch KH, Blaschke S, Grundker C and Hofbauer LC (2002). Bisphosphonates pamidronate and zoledronic acid stimulate osteoprotegerin production by primary human osteoblasts. *Biochem.Biophys.Res.Comm.* **291**: 680-686.
- Weibel ER (1989). Measuring through the microscope: development and evolution of stereological methods. *J Microsc.* **155**: 393-403.
- Whyte MP, McAlister WH, Novack DV, Clements KL, Schoenecker PL and Wenkert D (2008). Bisphosphonate-induced osteopetrosis: novel bone modeling defects, metaphyseal osteopenia, and osteosclerosis fractures after drug exposure ceases. *J Bone Miner Res* **23**: 1698-707.
- Whyte MP, Wenkert D, Clements KL, McAlister WH and Mumm S (2003). Bisphosphonate-induced osteopetrosis. *N Engl J Med* **349**: 457-63.

1
2
3
4
5
6
7
8
9
10
11
12
13
14
15
16
17
18
19
20
21
22
23
24
25
26
27
28
29
30
31
32
33
34
35
36
37
38
39
40
41
42
43
44
45
46
47
48
49
50
51
52
53
54
55
56
57
58
59
60

Figure legends

Figure 1

Suppression of Msx-1 expression in ONJ-affected jaw bone.

Representative immunohistochemically stained (APAAP) tissue sections show cytoplasmic Msx-1 staining at x 200 magnification (A-D). Scale bars mark 100 μ m.

Figures 1A and 1B (detail of 1A in black rectangle) demonstrate Msx-1, accentuated at the transition zone between mineralized and non mineralized healthy jaw bone. Figures 1C and 1D (detail of 1C in black rectangle) show reduced expression of Msx-1 in ONJ-affected jaw bone.

Figure 1E shows the relative number of cells that expressed the Msx-1 protein. Labeling index was significantly reduced ($p < 0.03$) in ONJ-affected bone compared to normal bone (measured by immunohistochemistry).

The relative level of Msx-1 mRNA in ONJ-affected bone was 7-fold lower than that observed in normal bone samples ($p < 0.03$) (Fig. 1F). All samples were normalized to GAPDH expression, and the relative expression was calibrated to the Msx-1 mRNA concentrations found in healthy oral mucoperiosteal tissue samples.

Figure 2

Stimulation of BMP-2/4 expression in ONJ-affected jaw bone

Representative immunohistochemically stained (APAAP) tissue sections show BMP-2/4-staining at x 200 magnification (A-D). Scale bars mark 100 μ m.

Figures 2A and 2B (detail of 2A in black rectangle) show pronounced BMP-2/4 staining of periosteal and endosteal cells in healthy jaw bone. Figures 2C and 2D (detail of 2C in black rectangle) show more intense and more dense cellular staining for BMP-2/4 in ONJ-affected jaw bone derived periosteum and endosteum ($p < 0.02$).

Figure 2E shows the relative number of cells that expressed the BMP-2/4 protein. The labeling index was significantly reduced ($p < 0.03$) in ONJ-affected bone compared to normal bone (measured by immunohistochemistry).

In Fig. 2F the relative level of BMP-2 mRNA expression in ONJ-affected samples was 8-fold higher than that observed in controls ($p < 0.02$); this substantiated the observation of overwhelming mineralisation. All samples were normalized to GAPDH expression, and the relative expression was calibrated to the BMP-2 mRNA concentrations found in healthy oral mucoperiosteal tissue samples.

Figure 3

RANKL is dramatically suppressed in ONJ-affected jaw bone.

Representative immunohistochemically stained (APAAP) tissue sections show RANKL- staining at 200 x magnification. Scale bars mark 100 μm (A-D).

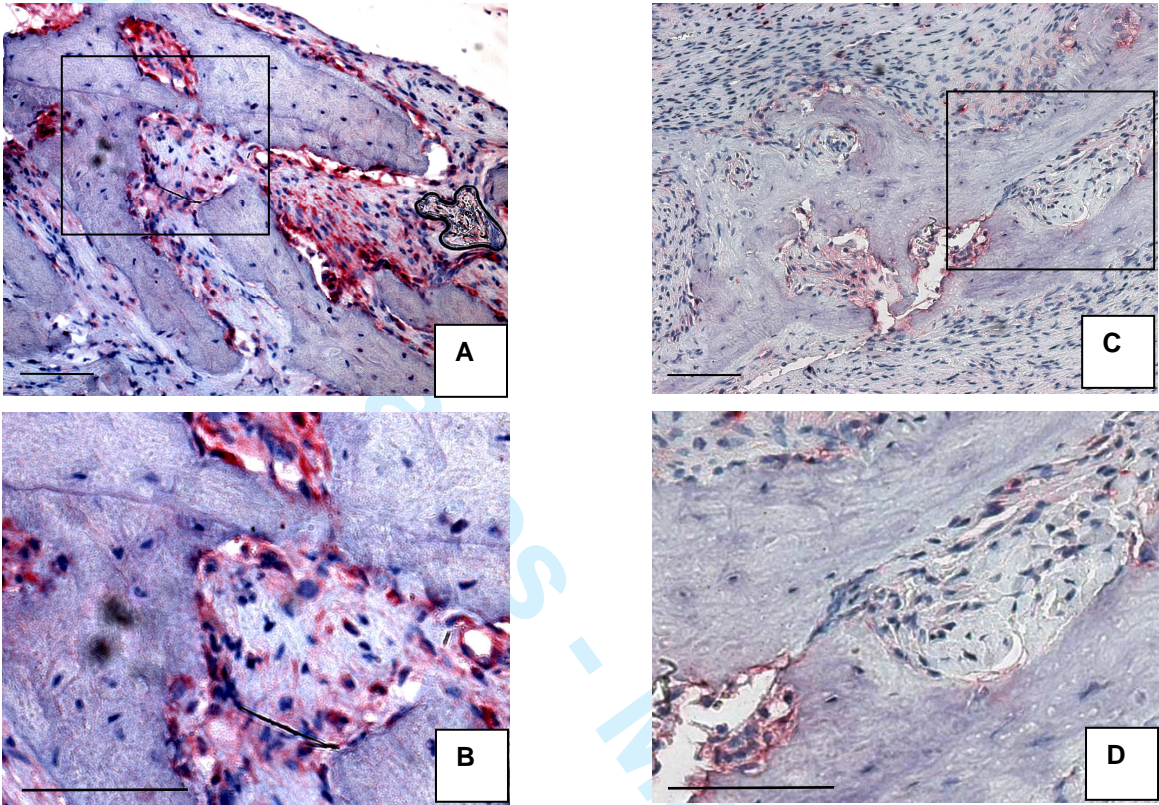
Figures 3A and 3B (detail of 3A in black rectangle) represent cytoplasmic RANKL-staining at the endosteal surface in healthy jaw bone. Figures 3C and 3D (detail of 3C in black rectangle) show a dramatically reduced number of RANKL-positive staining cells in ONJ-affected bone.

The relative level of cellular RANKL expression (labeling index) was significantly diminished in ONJ-affected samples compared to controls ($p < 0.003$) (Fig. 3E).

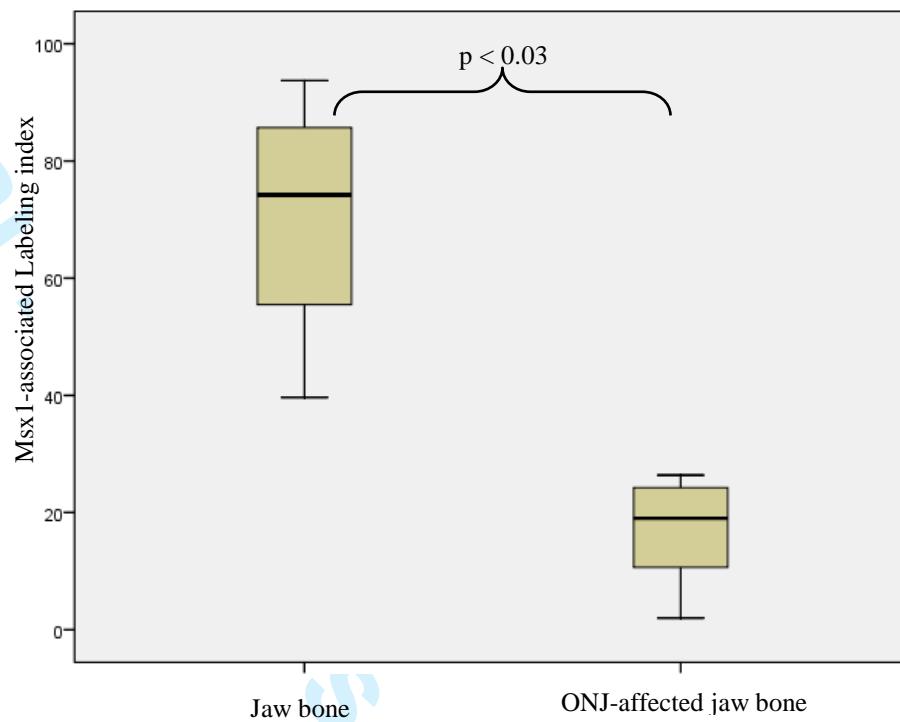
The mean RANKL mRNA level detected in ONJ-affected bone samples were nearly 22-fold lower than that of control bone ($p < 0.001$) (Fig. 3F). All samples were normalized to GAPDH expression, and the relative expression was calibrated to the RANKL mRNA concentrations found in healthy oral mucoperiosteal tissue samples.

1
2
3
4
5
6
7
8
9
10
11
12
13
14
15
16
17
18
19
20
21
22
23
24
25
26
27
28
29
30
31
32
33
34
35
36
37
38
39
40
41
42
43
44
45
46
47
48
49
50
51
52
53
54
55
56
57
58
59
60

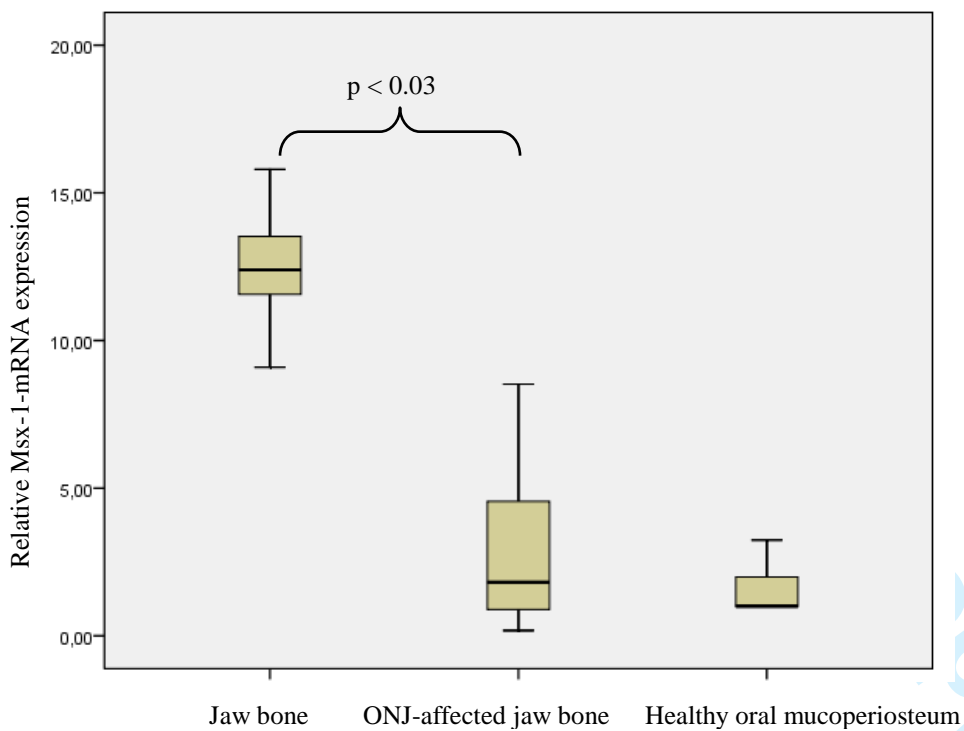
Figure 1



E.

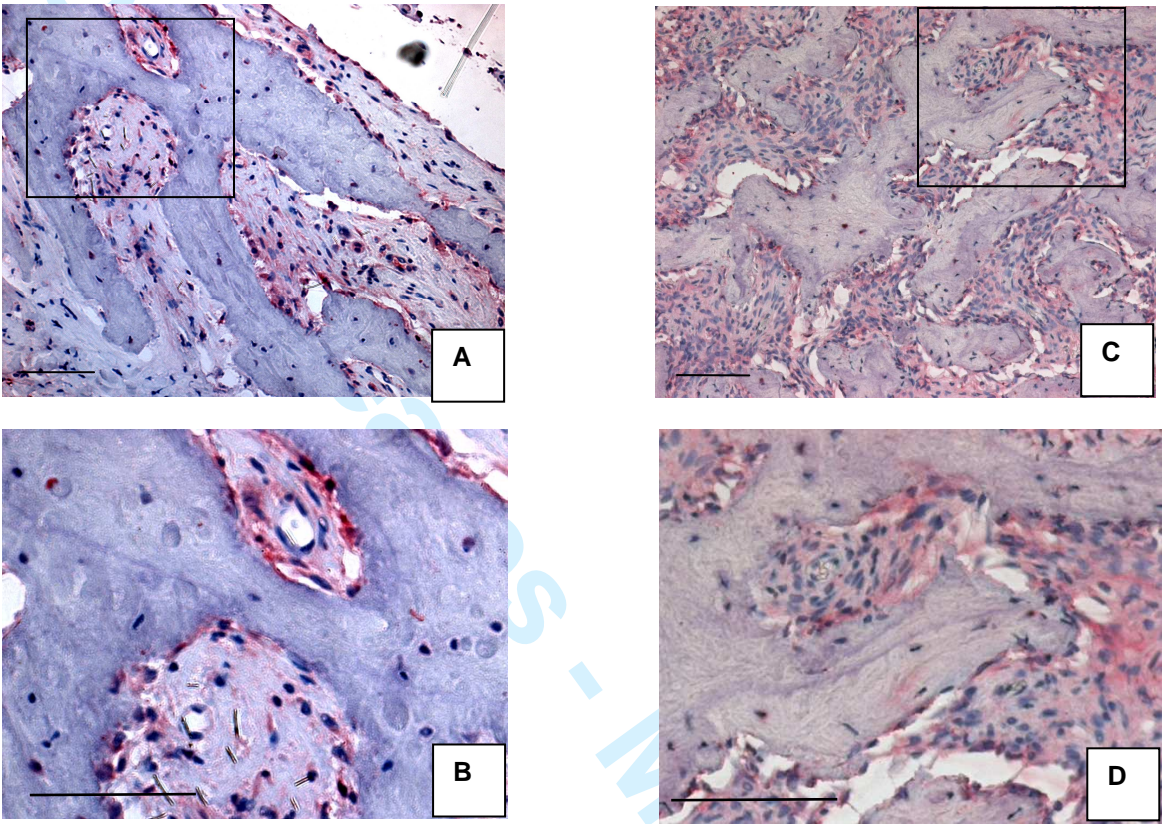


F.

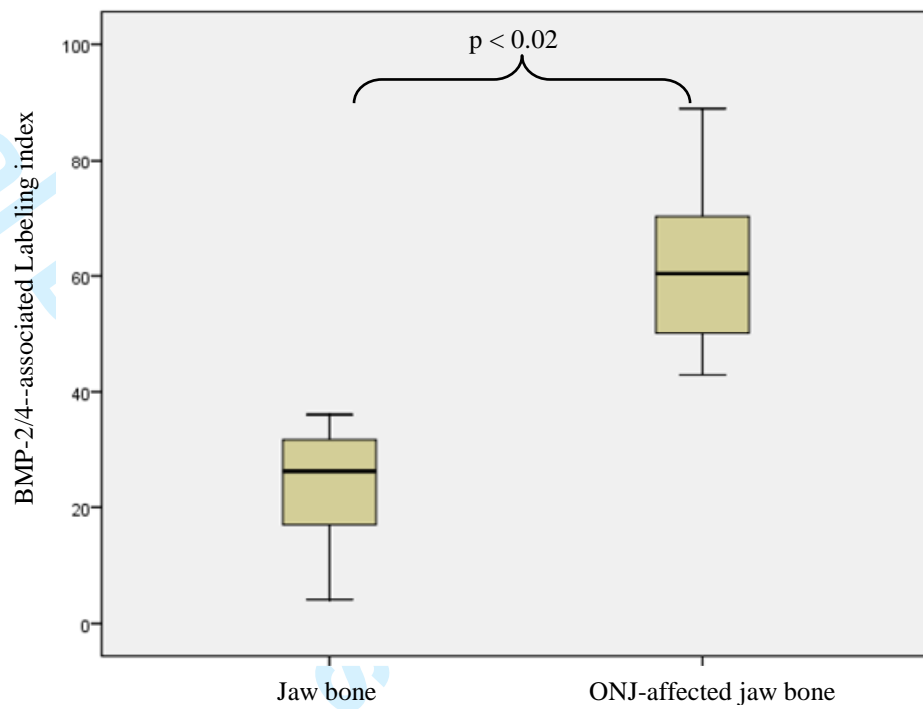


1
2
3
4
5
6
7
8
9
10
11
12
13
14
15
16
17
18
19
20
21
22
23
24
25
26
27
28
29
30
31
32
33
34
35
36
37
38
39
40
41
42
43
44
45
46
47
48
49
50
51
52
53
54
55
56
57
58
59
60

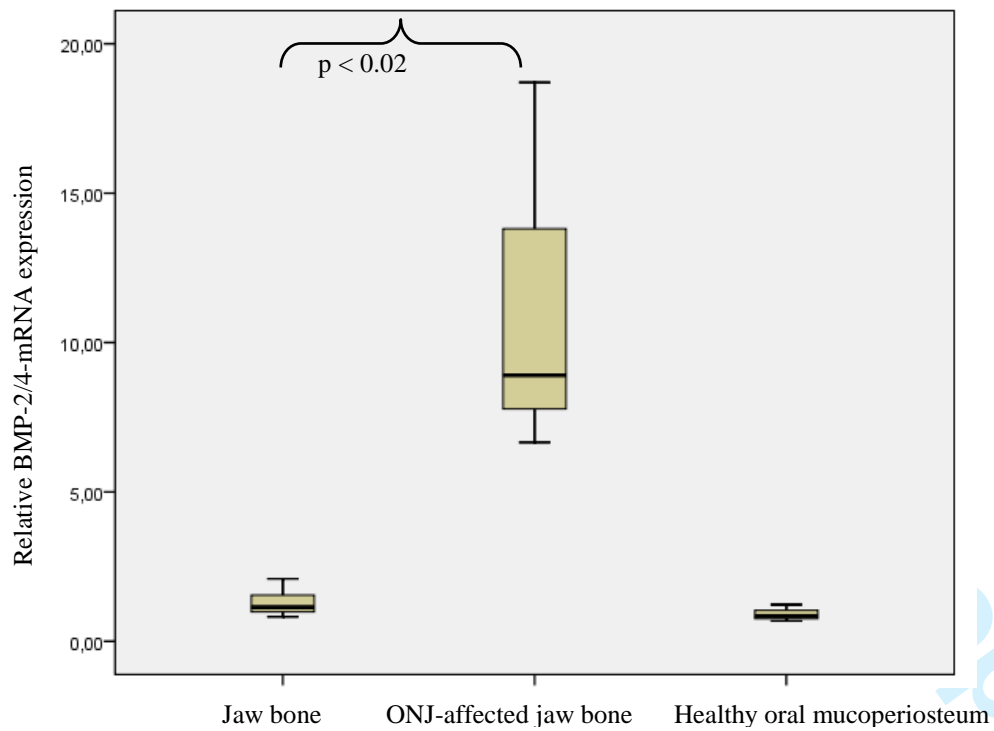
Figure 2



E.

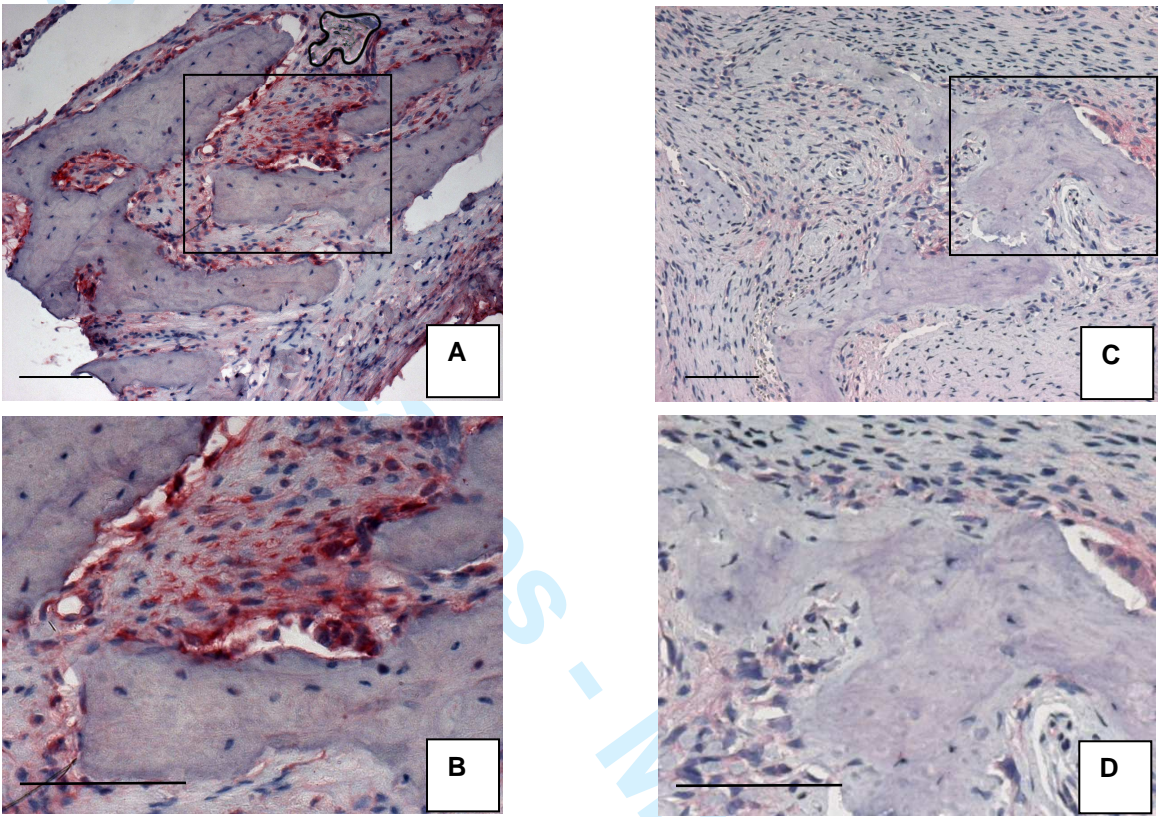


F.

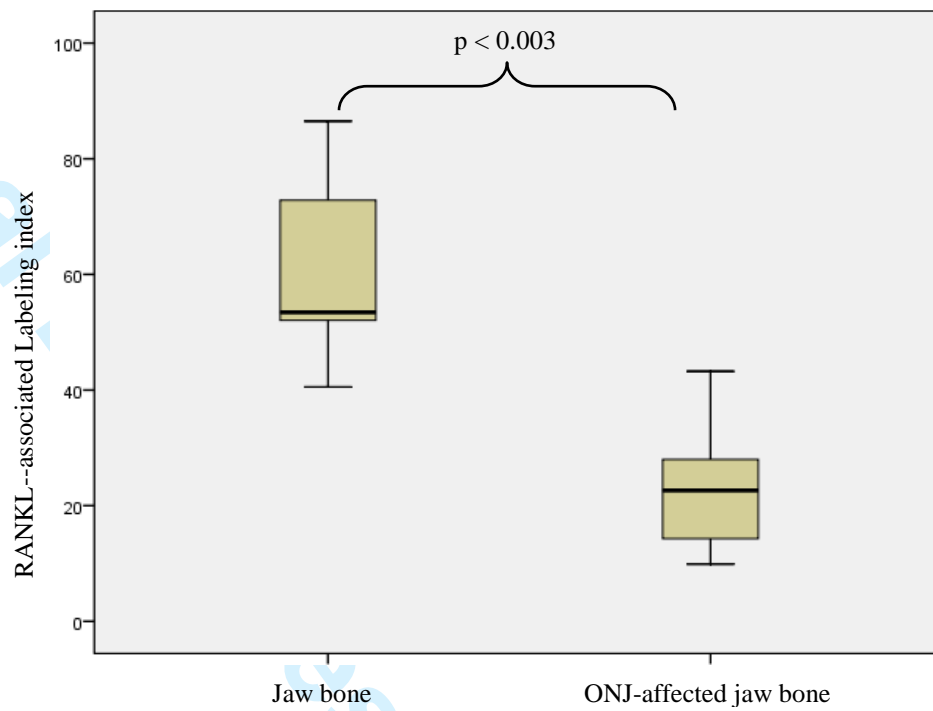


1
2
3
4
5
6
7
8
9
10
11
12
13
14
15
16
17
18
19
20
21
22
23
24
25
26
27
28
29
30
31
32
33
34
35
36
37
38
39
40
41
42
43
44
45
46
47
48
49
50
51
52
53
54
55
56
57
58
59
60

Figure 3



E.



F.

