HAL
open science

Randomized, double-blind comparison of indocyanine green with or without albumin premixing for near-infrared fluorescence imaging of sentinel lymph nodes in breast cancer patients

Merlijn Hutteman, J. Sven D. Mieog, Joost R. Vorst, Gerrit Jan Liefers, Hein Putter, Clemens W. G. M. Löwik, John V. Frangioni, Cornelis J. H. Velde, Alexander L. Vahrmeijer

To cite this version:

Merlijn Hutteman, J. Sven D. Mieog, Joost R. Vorst, Gerrit Jan Liefers, Hein Putter, et al.. Randomized, double-blind comparison of indocyanine green with or without albumin premixing for near-infrared fluorescence imaging of sentinel lymph nodes in breast cancer patients. Breast Cancer Research and Treatment, 2011, 127 (1), pp.163-170. 10.1007/s10549-011-1419-0 . hal-00618190

HAL Id: hal-00618190

https://hal.science/hal-00618190v1

Submitted on 1 Sep 2011

HAL is a multi-disciplinary open access archive for the deposit and dissemination of scientific research documents, whether they are published or not. The documents may come from teaching and research institutions in France or abroad, or from public or private research centers.

L'archive ouverte pluridisciplinaire **HAL**, est destinée au dépôt et à la diffusion de documents scientifiques de niveau recherche, publiés ou non, émanant des établissements d'enseignement et de recherche français ou étrangers, des laboratoires publics ou privés.

Randomized, double-blind comparison of indocyanine green with or without albumin premixing for near-infrared fluorescence imaging of sentinel lymph nodes in breast cancer patients

Merlijn Hutteman, M.Sc.[1,5,*], J. Sven D. Mieog, M.D.[1,*], Joost R. van der Vorst, M.D.[1], Gerrit-Jan Liefers, M.D., Ph.D.[1], Hein Putter, Ph.D.[2], Clemens W.G.M. Löwik, Ph.D.[3], John V. Frangioni, M.D., Ph.D.[4,5], Cornelis J.H. van de Velde, M.D., Ph.D.[1], Alexander L. Vahrmeijer, M.D., Ph.D.[1]

From the Leiden University Medical Center, Leiden, The Netherlands, [1] Departments of Surgery, [2] Medical Statistics, and [3] Endocrinology, and

From the Beth Israel Deaconess Medical Center, Boston, MA 02215, [4] Department of Radiology, [5] Division of Hematology/Oncology, Department of Medicine

[*]Both authors contributed equally to the study and share first authorship.

Corresponding author: Dr. Alexander L. Vahrmeijer, M.D., Ph.D.
Albinusdreef 2, 2300 RC Leiden
The Netherlands
Phone: +31715262309
Fax: +31715266750
Email: a.l.vahrmeijer@lumc.nl

Running Head: Randomized Comparison of NIR Fluorescent Lymphatic Tracers

Keywords: Near-Infrared Fluorescence Imaging, Image-Guided Surgery, Breast Cancer, Sentinel Lymph Node Mapping, Indocyanine Green, Albumin

Clinical Trial Registration: The Netherlands Trial Register NTR2482

Financial Disclosure: This work was supported in part by NIH grants R01-CA-115296 and R21-CA-130297, the Dutch Cancer Society grant UL2010-4732, the Nuts Ohra Fund, the "Maurits and Anna de Kock" Foundation and the American Women's Club of The Hague. J.S.D. Mieog is a MD-medical research trainee funded by The Netherlands Organisation for Health Research and Development (grant nr. 92003526).

CONFLICT OF INTEREST STATEMENT

Merlijn Hutteman, M.Sc.: None.

J. Sven D. Mieog, M.D.: None.

Joost R. van der Vorst, M.D.: None.

Gerrit-Jan Liefers, M.D., Ph.D.: None.

Hein Putter, Ph.D.: None.

Clemens W.G.M. Löwik, Ph.D.: None.

John V. Frangioni, M.D., Ph.D.: Mini-FLARE technology is owned by Beth Israel Deaconess Medical Center, a teaching hospital of Harvard Medical School. As inventor, Dr. Frangioni may someday receive royalties if products are commercialized. Dr. Frangioni is the founder and unpaid director of The FLARE Foundation, a non-profit organization focused on promoting the dissemination of medical imaging technology for research and clinical use.

Cornelis J.H. van de Velde, M.D., Ph.D.: None.

Alexander L. Vahrmeijer, M.D., Ph.D.: None.

ABSTRACT

Near-infrared (NIR) fluorescence imaging has the potential to improve sentinel lymph node (SLN) mapping in breast cancer. Indocyanine green (ICG) is currently the only clinically available fluorophore that can be used for SLN mapping. Preclinically, ICG adsorbed to human serum albumin (ICG:HSA) improves its performance as a lymphatic tracer in some anatomical sites. The benefit of ICG:HSA for SLN mapping of breast cancer has not yet been assessed in a clinical trial. We performed a double-blind, randomized study to determine if ICG:HSA has advantages over ICG alone. The primary endpoint was the fluorescence brightness, defined as the signal-to-background ratio (SBR), of identified SLNs. Clinical trial subjects were 18 consecutive breast cancer patients scheduled to undergo SLN biopsy. All patients received standard of care using ^{99m}Technetium-nanocolloid and patent blue. Patients were randomly assigned to receive 1.6 mL of 500 µM ICG:HSA or ICG that was injected periareolarly directly after patent blue. The Mini-Fluorescence-Assisted Resection and Exploration (Mini-FLARE) imaging system was used for NIR fluorescence detection and quantitation. SLN mapping was successful in all patients. Patient, tumor and treatment characteristics were equally distributed over the treatment groups. No significant difference was found in SBR between the ICG:HSA group and the ICG alone group (8.4 vs. 11.3, respectively, $P = 0.18$). In both groups, the average number of detected SLNs was 1.4 ± 0.5 SLNs per patient ($P = 0.74$). This study shows that there is no direct benefit of premixing ICG with HSA prior to injection for SLN mapping in breast cancer patients, thereby reducing the cost and complexity of the procedure. With these optimized parameters that eliminate the necessity of HSA, larger trials can now be performed to determine patient benefit.

INTRODUCTION

Sentinel lymph node (SLN) mapping is currently regarded as standard of care in staging of the axilla in breast cancer patients with clinically negative axillary lymph nodes [1]. In general, a combination of radioactive colloid and blue dye is used for SLN mapping. Using this combination, identification rates of 95% to 97% are achieved [2-5]. The use of only one of these two detection methods results in significantly lower identification rates [2-5]. Both detection methods possess certain disadvantages. Radioactive colloids require involvement of a nuclear medicine physician, can be difficult to localize with a handheld gamma probe, and the time-window for SLN identification is limited due to the short half-life (6 hours) of ^{99m}Technetium. Blue dyes cannot be seen through skin and fatty tissue, and permit only limited visualization of afferent lymphatic vessels and the SLN.

Optical imaging using the near-infrared (NIR) fluorescence lymphatic tracer indocyanine green (ICG) enables real-time transcutaneous and intraoperative visualization of lymphatic channels and SLNs [6-13]. Therefore, NIR fluorescence imaging could provide an alternative for, or an addition to, conventional techniques used for SLN mapping. Recently, our group has demonstrated that NIR fluorescence performed equally well as the combination of radioactive colloid and blue dye in SLN mapping of breast cancer patients [14].

ICG is currently the only clinically available NIR lymphatic tracer. However, due to its relatively low fluorescence brightness and its small hydrodynamic diameter, which permits flow through the SLN to higher tier nodes, it is not an optimal lymphatic tracer. Preclinical work has demonstrated that adsorption of ICG to human serum albumin (HSA, complex is ICG:HSA), by simply mixing it, increases the fluorescence intensity and the hydrodynamic diameter, thereby providing improved detection and better retention in the SLN in certain anatomical sites, such as the intestine [15]. Another parameter that must be considered when using ICG or ICG:HSA is the effect of fluorescence quenching, which results in a decrease in fluorescence intensity as the concentration of ICG (or ICG:HSA) is increased above 50 μM. The use of 50 μM ICG for SLN imaging, however, is suboptimal, because ICG will be diluted once taken up by the lymphatic system. To assess the magnitude of this *in vivo* dilution effect, our group has conducted a dose-finding study to demonstrate that the optimal concentration of ICG:HSA for NIR-based SLN mapping in breast cancer patients lies between 400 μM and 800 μM [14].

A theoretical disadvantage of the use of ICG alone is poor retention of the lymphatic tracer in the SLN, which as a consequence results in fluorescent staining of higher tier nodes and background staining of the axilla. Although not compared directly, studies using ICG alone reported a higher average number of identified

SLNs (range = 1.8-5.4; aggregate average = 3.4) [6-10], than with the use of ICG:HSA (aggregate: 1.5) [11,14]. However, comparison of these data is difficult because the concentration of ICG used was significantly higher (typically 6.4 mM) than in the trials using ICG:HSA (10 µM to 1000 µM).

Although we have obtained good results with the use of ICG:HSA for SLN mapping in breast cancer patients, the use of albumin adds cost and complexity to the procedure. Moreover, the use of human blood products, such as HSA, poses regulatory hurdles in certain countries, such as the United States. Therefore, the use of ICG alone would be favorable. After intravenous administration, ICG binds rapidly and completely to plasma proteins [16]. Lymph fluid has a similar protein constitution as serum, albeit in a lower concentration (20.6 g/L for lymph fluid versus 73.7 g/L for plasma) [17]. After intradermal or subcutaneous injection, ICG could theoretically bind to these proteins, eliminating the need for premixing ICG and HSA. We therefore hypothesized that ICG alone could render the same fluorescence intensity in SLNs as ICG:HSA, and tested this hypothesis in a double-blind randomized trial.

METHODS

Preparation of Indocyanine Green adsorbed to Human Serum Albumin: ICG (25 mg vials) was purchased from Pulsion Medical Systems (Munich, Germany) and was resuspended in 10 cc of sterile water for injection to yield a 2.5 mg/ml (3.2 mM) stock solution. To obtain a 500 µM dilution, 7.8 mL of the 3.2 mM ICG solution was diluted in 50 cc vial of sterile water for injection or 50 cc vial of Cealb (20% human serum albumin, Sanquin, Amsterdam, The Netherlands) for the preparation of ICG alone or ICG:HSA, respectively. Prior to the addition of ICG, 7.8 mL was drawn from the 50 cc vials. In a previous study, we determined that the optimal dose of ICG:HSA lies between 400 µM and 800 µM [14]. A dose of 500 µM was chosen because it requires minimal manipulation of ICG and albumin volumes.

Intraoperative Near-Infrared Imaging System (Mini-FLARE): SLN mapping was performed using the Mini-Fluorescence-Assisted Resection and Exploration (Mini-FLARE) image-guided surgery system as described earlier [14]. Briefly, the system consists of two wavelength isolated light sources: a "white" light source, generating 26,600 lx of 400-650 nm light, and a "near-infrared" light source, generating 7.7 mW/cm^2 of 760 nm light. Color video and NIR fluorescence images are simultaneously acquired and displayed in real-time using custom optics and software that separate the color video and NIR fluorescence images. A pseudo-colored (lime green) merged image of the color video and NIR fluorescence images is also displayed. The imaging head is attached to a flexible gooseneck arm, which permits positioning of the imaging head at extreme angles virtually anywhere over the surgical field. For intraoperative use, the imaging head and imaging system pole stand are wrapped in a sterile shield and drape (Medical Technique Inc., Tucson, AZ).

Clinical Trial: The double-blind, randomized, single-institution, non-inferiority trial comparing ICG:HSA with ICG alone was approved by the Medical Ethics Committee of the Leiden University Medical Center and was performed in accordance with the ethical standards of the Helsinki Declaration of 1975. All patients planning to undergo a sentinel lymph node procedure whether for invasive breast cancer or for high-risk carcinoma *in situ* were eligible for participation in the study. Patients had clinically negative axillary nodes as assessed by palpation and ultrasonography. Exclusion criteria were pregnancy, lactation or an allergy to iodine, shellfish, or indocyanine green.

All patients gave informed consent and were anonymized. Patients were randomized by the Department of Clinical Pharmacy. Treatment allocation was performed by block randomization. Patients received the standard-of-care sentinel lymph node procedure. For our institution, this implies one periareolar injection of approximately 100 MBq ^{99m}Technetium-nanocolloid (mean ± S.D. = 96.6 ± 14.7 MBq, no difference between treatment groups [P = 0.47]) the day before surgery. Before the start of the operation, one mL of patent blue V was injected. Directly after patent blue injection, the surgeon injected a total of 1.6 mL of 500 µM ICG:HSA or ICG alone. Both dyes were injected intradermally and periareolarly at four sites. Gentle pumping pressure was applied to the injection site for 1 min. After surgical scrub and sterile covering of the operation field, NIR fluorescence imaging was performed with the imaging head of the Mini-FLARE at approximately 30 cm distance to the surgical field. Camera exposure times were between 5 to 200 msec. A SLN exhibiting a signal-to-background ratio (SBR) ≥ 1.1 *in situ* was considered positive by NIR fluorescence. Both the surgeon and the Mini-FLARE operator, who was responsible for analyzing the data, were blinded to the treatment allocation.

Routine histopathological frozen analysis of SLNs was performed during surgery. SLNs were fixed in formalin and embedded in paraffin for routine hematoxylin and eosin staining and immunohistopathological staining for AE1/AE3 at three levels, with an interval of 150 to 250 µm, according to the Dutch guidelines for SLN analysis. Patients underwent an axillary lymph node dissection if the SLN was found to contain metastases. If isolated tumor cells were found (< 0.2 mm), no axillary lymph node dissection was performed.

Power Calculation and Statistical Analysis: A power calculation based on data from our previous study [14] revealed that 18 patients are needed to achieve 91% power to detect non-inferiority using a one-sided, two-sample t-test (α = 0.025) with a margin of equivalence of 5.0 while assuming no difference between the SBRs of ICG:HSA and ICG alone. For statistical analysis, SPSS statistical software package (Version 16.0, Chicago, IL) was used. Graphs were generated using GraphPad Prism Software (Version 5.01, La Jolla, CA). To compare the SBR and the number of SLNs identified between ICG:HSA and ICG alone, a one-sided, two-sample t-test was performed. $P < 0.05$ was considered significant.

RESULTS

Eighteen consecutive breast cancer patients undergoing standard-of-care SLN mapping were randomized to ICG:HSA or ICG alone for the NIR-based SLN imaging. Patient, tumor, and treatment characteristics were equally distributed over the treatment groups (Table 1). Use of the Mini-FLARE during surgery did not interfere with the standard of care. Average time between lymphatic tracer injection and skin incision was 15.6 ± 2.2 minutes (Table 2). In all patients (N = 18), NIR fluorescence imaging enabled visualization of one or more SLNs (Figure 1). In the ICG:HSA group (N = 8 subjects), a total of 11 SLNs were identified (average per patient = 1.4 ± 0.5); 9 (82%) were radioactive, 8 (73%) were blue and 11 (100%) were NIR fluorescent. In the ICG alone group (N = 10 subjects), a total of 14 SLNs were identified (average per patient = 1.4 ± 0.5); 14 (100%) were radioactive, 10 (71%) were blue and 14 (100%) were NIR fluorescent. The average number of SLNs identified was not significantly different between both groups ($P = 0.74$).

The primary endpoint of this study was the average brightness of the SLN in both groups, expressed in signal-to-background ratio (SBR). The results are presented in Table 2. The average SBR of ICG:HSA (8.4 ± 3.6) and ICG alone (11.3 ± 4.8) was not significantly different ($P = 0.18$). However, in the ICG alone group, the afferent lymphatics were significantly better visualized percutaneously compared to the ICG:HSA group ($P = 0.004$; Table 2 and Figure 1).

In all patients, the NIR fluorescence signal in the SLN was detected earlier in the procedure before patent blue was visualized. Average time between skin incision and resection of the first SLN was 11.0 ± 4.1 minutes and was not different between both groups (t-test, $P = 0.74$). No adverse reactions associated with the use of ICG, ICG:HSA, or Mini-FLARE occurred.

DISCUSSION

The use of NIR fluorescence for SLN mapping has several advantages over conventional methods, such as better tissue penetration when compared to blue dyes, and lack of ionizing radiation and real-time visualization when compared to radiotracers. A number of clinical studies have been published on the use of NIR fluorescence in the SLN procedure in breast cancer, all of which use ICG, which is currently clinically available [6,9,11,12,14]. Preclinical studies indicated that adsorption of ICG to human serum albumin (HSA, complex is ICG:HSA), by simply mixing it, increases the fluorescence intensity and the hydrodynamic diameter, thereby providing improved detection and better retention in the SLN [15]. Our group has subsequently conducted a dose-finding study and demonstrated that the optimal concentration of ICG:HSA for NIR-based SLN mapping in breast cancer patients lies between 400 µM and 800 µM [14]. Indeed, above 800 µM ICG:HSA, the fluorescent intensity dropped due to quenching. Based on these results a concentration of 500 µM ICG:HSA, which requires minimal manipulation of albumin volumes and uses only one vial of ICG, was chosen for further studies to identify whether premixing with albumin indeed increases the fluorescent intensity of the node in a clinical setting. In the current study, SLN mapping after ICG or ICG:HSA injection was successful in all patients. ICG showed a comparable or even slightly increased (though not significantly) brightness than ICG:HSA while identifying an equal average number of SLNs. Although no macrometastases in the SLNs were observed in the current study, our previous study showed that tumor-positive SLNs were also detected by NIR fluorescence, signifying ICG uptake [14]. However, lymph node macrometastases continue to be a contraindication for SLN mapping and preoperative staging of the axilla remains pivotal to minimize false negatives.

The results of our study are discordant with preclinical work in intestine, which suggested an improvement in fluorescent brightness and retention in the SLN by premixing ICG with HSA [15]. Although the current study was powered to determine non-inferiority in SBR of ICG alone when compared to ICG:HSA, it was not formally powered to assess the secondary endpoint, average number of SLNs identified. However, power analysis using data from our previous study [14] demonstrated that a difference of at least one additional SLN identified per patient could be detected with 90% power with the current sample size. The discrepancy between the current clinical results and these preclinical experiments could be caused by the increased distance that the injected dye has to travel, as the preclinical studies were performed in the bowel of healthy pigs [15]. Lymph fluid contains a high concentration of albumin, among other proteins; therefore, a longer traveling distance could aid ICG in adsorbing to albumin or other proteins, as it would after intravenous injection [18],

diminishing the need for premixing ICG with HSA. This observation implies that premixing might prove to be useful in other cancer types (such as colon cancer, for example), where ICG is less likely to completely adsorb to proteins before the SLN is reached. Therefore, the use of ICG:HSA or ICG alone should be tested for every anatomical site.

Although the fluorescent brightness did not differ significantly between both groups, ICG alone showed significantly improved percutaneous visibility of lymphatic channels when compared to ICG:HSA (Figure 1). It has been shown that in plasma, ICG preferably binds to α_1-lipoprotein and γ-globulin, despite the higher concentration of albumin [19]. Previous experiments have shown a higher increase in quantum yield when ICG is mixed with serum, in comparison to HSA [15]. Therefore, the observed differences in visualization of lymphatics could likely be attributable to the protein constitution of lymph fluid. The high albumin content (20%) of ICG:HSA could also be a contributing factor, as the increased hydrodynamic diameter and higher viscosity could diminish ICG uptake in lymphatic channels. It should be noted that the anatomical variation (amount of tissue overlying the lymphatic channels) is also a major influencing factor and may be primarily responsible for the observed difference.

An optimal lymphatic tracer is non-toxic, has a high quantum yield (i.e., brightness), migrates quickly to the SLN, and does not migrate to higher tier nodes. If a tracer migrates to higher tier nodes, non-sentinel lymph nodes could incorrectly be identified as SLNs, causing more nodes than necessary to be resected. ICG is far from optimal; in aqueous solution the quantum yield is relatively low and due to its small hydrodynamic diameter, it can flow to higher tier nodes, as is the case with blue dyes. The synthesis and clinical introduction of an optimal probe will be the subject of future studies and will greatly help to confirm the clinical benefit of NIR fluorescence imaging in the SLN procedure [15,20].

In the current study, NIR fluorescence after ICG injection could consistently be visualized before the blue dye could be observed, which is consistent with earlier findings [14]. Therefore, NIR fluorescence imaging has the potential to replace blue dyes in SLN mapping of breast cancer patients. Furthermore, as NIR fluorescence light penetrates relatively deep into tissue, it can potentially replace radiocolloids in SLN mapping in a selected group of patients, for example those with a low body mass index. A clinical trial on omitting blue dyes and using NIR fluorescence without the need for radiocolloids is currently ongoing (NTR2674).

In conclusion, this double-blind, randomized trial showed no advantage of ICG:HSA in comparison to ICG alone for the SLN procedure. To reduce the cost and complexity of the procedure, a dose of 500 µM ICG alone (1.6 ml) is recommended for NIR fluorescence SLN mapping in breast cancer patients. Therefore, this

study has determined the optimal parameters that can be used to validate this technique in a larger series in order to investigate patient benefit.

ACKNOWLEDGMENTS

We thank the following individuals for the contribution to this study: Gemma Ranke, Elly Krol-Warmerdam, Annemarie Voet-van den Brink, Gerlinda van Gent-de Bruijn (Breast Cancer Unit) and Linda van der Hulst (Central Pharmacy). We thank Lindsey Gendall for editing. This work was supported in part by NIH grants R01-CA-115296 and R21-CA-130297, the Dutch Cancer Society grant UL2010-4732, the Nuts Ohra Fund, the "Maurits and Anna de Kock" Foundation and the American Women's Club of The Hague. J.S.D. Mieog is a MD-medical research trainee funded by The Netherlands Organisation for Health Research and Development (grant nr. 92003526).

REFERENCES

1. Cox CE, Pendas S, Cox JM, Joseph E, Shons AR, Yeatman T, Ku NN, Lyman GH, Berman C, Haddad F, Reintgen DS (1998) Guidelines for sentinel node biopsy and lymphatic mapping of patients with breast cancer. Ann Surg 227:645-651
2. Goyal A, Newcombe RG, Chhabra A, Mansel RE (2006) Factors affecting failed localisation and false-negative rates of sentinel node biopsy in breast cancer--results of the ALMANAC validation phase. Breast Cancer Res Treat 99:203-208
3. Krag DN, Anderson SJ, Julian TB, Brown AM, Harlow SP, Ashikaga T, Weaver DL, Miller BJ, Jalovec LM, Frazier TG, Noyes RD, Robidoux A, Scarth HM, Mammolito DM, McCready DR, Mamounas EP, Costantino JP, Wolmark N (2007) Technical outcomes of sentinel-lymph-node resection and conventional axillary-lymph-node dissection in patients with clinically node-negative breast cancer: results from the NSABP B-32 randomised phase III trial. Lancet Oncol 8:881-888
4. Zavagno G, De Salvo GL, Scalco G, Bozza F, Barutta L, Del BP, Renier M, Racano C, Carraro P, Nitti D (2008) A Randomized clinical trial on sentinel lymph node biopsy versus axillary lymph node dissection in breast cancer: results of the Sentinella/GIVOM trial. Ann Surg 247:207-213
5. Straver ME, Meijnen P, van Tienhoven G, van de Velde CJ, Mansel RE, Bogaerts J, Duez N, Cataliotti L, Klinkenbijl JH, Westenberg HA, van der Mijle H, Snoj M, Hurkmans C, Rutgers EJ (2010) Sentinel Node Identification Rate and Nodal Involvement in the EORTC 10981-22023 AMAROS Trial. Ann Surg Oncol 17:1854-61
6. Kitai T, Inomoto T, Miwa M, Shikayama T (2005) Fluorescence navigation with indocyanine green for detecting sentinel lymph nodes in breast cancer. Breast Cancer 12:211-215
7. Murawa D, Hirche C, Dresel S, Hunerbein M (2009) Sentinel lymph node biopsy in breast cancer guided by indocyanine green fluorescence. Br J Surg 96:1289-1294
8. Tagaya N, Yamazaki R, Nakagawa A, Abe A, Hamada K, Kubota K, Oyama T (2008) Intraoperative identification of sentinel lymph nodes by near-infrared fluorescence imaging in patients with breast cancer. Am J Surg 195:850-853
9. Hirche C, Murawa D, Mohr Z, Kneif S, Hunerbein M (2010) ICG fluorescence-guided sentinel node biopsy for axillary nodal staging in breast cancer. Breast Cancer Res Treat 121:373-8
10. Hojo T, Nagao T, Kikuyama M, Akashi S, Kinoshita T (2010) Evaluation of sentinel node biopsy by combined fluorescent and dye method and lymph flow for breast cancer. Breast 19:210-3

11. Troyan SL, Kianzad V, Gibbs-Strauss SL, Gioux S, Matsui A, Oketokoun R, Ngo L, Khamene A, Azar F, Frangioni JV (2009) The FLARE intraoperative near-infrared fluorescence imaging system: a first-in-human clinical trial in breast cancer sentinel lymph node mapping. Ann Surg Oncol 16:2943-2952
12. Sevick-Muraca EM, Sharma R, Rasmussen JC, Marshall MV, Wendt JA, Pham HQ, Bonefas E, Houston JP, Sampath L, Adams KE, Blanchard DK, Fisher RE, Chiang SB, Elledge R, Mawad ME (2008) Imaging of lymph flow in breast cancer patients after microdose administration of a near-infrared fluorophore: feasibility study. Radiology 246:734-741
13. Tanaka E, Choi HS, Fujii H, Bawendi MG, Frangioni JV (2006) Image-guided oncologic surgery using invisible light: completed pre-clinical development for sentinel lymph node mapping. Ann Surg Oncol 13:1671-1681
14. Mieog JS, Troyan SL, Hutteman M, Donohue KJ, van der Vorst JR, Stockdale A, Liefers GJ, Choi HS, Gibbs-Strauss SL, Putter H, Gioux S, Kuppen PJ, Ashitate Y, Löwik CW, Smit VT, Oketokoun R, Ngo LH, van de Velde CJ, Frangioni JV, Vahrmeijer AL (2011) Towards Optimization of Imaging System and Lymphatic Tracer for Near-Infrared Fluorescent Sentinel Lymph Node Mapping in Breast Cancer. Ann Surg Oncol. In press
15. Ohnishi S, Lomnes SJ, Laurence RG, Gogbashian A, Mariani G, Frangioni JV (2005) Organic alternatives to quantum dots for intraoperative near-infrared fluorescent sentinel lymph node mapping. Mol Imaging 4:172-181
16. Cherrick GR, Stein SW, Leevy CM, Davidson CS (1960) Indocyanine green: observations on its physical properties, plasma decay, and hepatic extraction. J Clin Invest 39:592-600
17. Fogh-Andersen N, Altura BM, Altura BT, Siggaard-Andersen O (1995) Composition of interstitial fluid. Clin Chem 41:1522-1525
18. Moody ED, Viskari PJ, Colyer CL (1999) Non-covalent labeling of human serum albumin with indocyanine green: a study by capillary electrophoresis with diode laser-induced fluorescence detection. J Chromatogr B Biomed Sci Appl 729:55-64
19. Sauda K, Imasaka T, Ishibashi N (1986) Determination of protein in human serum by high-performance liquid chromatography with semiconductor laser fluorometric detection. Anal Chem 58:2649-2653
20. Hutteman M, Choi HS, Mieog JS, van der Vorst JR, Ashitate Y, Kuppen PJ, van Groningen MC, Lowik CW, Smit VT, van de Velde CJ, Frangioni JV, Vahrmeijer AL (2010) Clinical Translation of Ex Vivo

Sentinel Lymph Node Mapping for Colorectal Cancer Using Invisible Near-Infrared Fluorescence Light. Ann Surg Oncol. Epub ahead of print

TABLES

Table 1 – Patient and Tumor Characteristics

	ICG:HSA (N = 8)		ICG alone (N = 10)		
Characteristic	**N**	**%**	**N**	**%**	**P**
Age (Median, Range)	59.5 (38-72)		57.5 (40-73)		0.99
Menopausal State					0.74
- Premenopausal	3	37.5	3	30	
- Postmenopausal	5	62.5	7	70	
Body Mass Index (median, range)	26 (20-41)		23.5 (21-30)		0.26
Skin Type					0.40
- II	2	25	1	10	
- III	6	75	9	90	
Previous Procedure of Breast					0.12
- Breast Implants	1		0		
- Breast Reduction	0		1		
- Lumpectomy	2		0		
- Radiotherapy	0		1		
- Neoadjuvant Chemotherapy	1		0		
Multifocality	0		0		1.00
Tumor side					0.81
- Left	2	25	3	30	
- Right	6	75	7	70	
Tumor localization					0.23
- Upper Outer	6	75	4	40	
- Lower Outer	0	0	1	10	
- Lower Medial	1	12.5	2	20	
- Upper Medial	0	0	3	30	
- Central	1	12.5	0	0	
Type of Operation					0.15
- Mastectomy	3	37.5	1	10	
- Wide Local Excision	4	50	9	90	
- SNB Only	1	12.5	0	0	
Pathological Tumor Size (Median, Range)	7 (5-11)		12 (8-15)		0.13
Histological Type					0.62
- Infiltrating Ductal Adenocarcinoma	7	87.5	7	70	
- Infiltrating Lobular Adenocarcinoma	0	0	1	10	
- Ductal Carcinoma In Situ	1	12.5	1	10	
- Other	0	0	1	10	
Histological Grade					0.15
- I	1	16.7	3	33.3	
- II	2	33.3	5	55.6	
- III	3	50	1	11.1	

Abbreviations: ICG:HSA = indocyanine green adsorbed to human serum albumin
Skin type = American Academy of Dermatology Skin Types I-VI:
I. Pale, white skin: always burns easily; never tans (Celtic, Scandinavian, and infants)
II. White: usually burns easily; tans minimally (Northern European)
III. White (average): sometimes burns; tans gradually to light brown (Central European)
IV. Beige or lightly tanned: burns minimally; always tans to moderately brown (Mediterranean, Asian)
V. Moderate brown or tanned: rarely burns; tans well (South American, Indian, Native American)
VI. Dark brown or black: never burns; deeply pigmented (African, African-American, Aborigine)

Table 2 – SLN Identification Results

Characteristic	Total (18 Subjects) N	%	ICG:HSA (8 Subjects) N	%	ICG alone (10 Subjects) N	%	P
Number of SLNs Identified	25		11		14		
Number of SLNs Identified per Patient							0.91
- One SLN	11	61	5	63	6	60	
- Two SLNs	7	39	3	37	4	40	
Average Number of SLNs Identified ± S.D.	1.4 ± 0.5		1.4 ± 0.5		1.4 ± 0.5		0.92
Method of Detection							
- Radioactive	23	92	9	82	14	100	0.18
- Blue	18	72	8	73	10	71	1.00
- NIR Fluorescent	25	100	11	100	14	100	1.00
Signal-to-Background Ratio	10.0 ± 4.4		8.4 ± 3.6		11.3 ± 4.8		0.18
Percutaneous NIR Fluorescent Lymph Drainage Visualization							0.004
- Yes	10	56	1	13	9	90	
- Partially[a]	3	17	3	38	0	0	
- No	5	28	4	50	1	10	
Average Time between Injection and Skin Incision ± S.D. (minutes)	15.6 ± 2.2		15.3 ± 1.7		15.9 ± 2.6		0.55
Average Time between Skin Incision and SLN Resection ± S.D. (minutes)	11.0 ± 4.1		10.6 ± 5.1		11.3 ± 3.3		0.74
Histology							0.44
- Negative	24	96	10	91	14	100	
- Isolated Tumor Cells	1	4	1	9	0	0	
- Macrometastases	0	0	0	0	0	0	
Axillary Lymph Node Dissection							1.00
- No	18	100	8	100	10	100	
- Yes	0	0	0	0	0	0	

Abbreviations: ICG:HSA = indocyanine green adsorbed to human serum albumin; S.D. = standard deviation; SLN = sentinel lymph node.

[a] Partial percutaneous visualization was noted when lymphatic channels could be visualized percutaneously from the injection site, but did not reach the axilla.

FIGURE CAPTIONS

Fig. 1 - NIR fluorescence imaging during sentinel lymph node mapping in breast cancer patients

a. ICG:HSA. In the upper panel, the periareolar injection site (arrow) is shown, but percutaneously, no lymphatic channel can be visualized. In the lower panel, identification of the SLN (arrow) and an afferent lymphatic channel (open arrowhead) with NIR fluorescence imaging is demonstrated 27 min after injection of 1.6 mL of 500 µM ICG:HSA. Camera exposure times were 60 msec (top row) and 150 msec (bottom row). Scale bars represent 1 cm.

b. ICG alone. In the upper panel, the periareolar injection site (arrow) and a lymphatic channel (arrowhead) are clearly visualized. In the lower panel, identification of the SLN (arrow) and an afferent lymphatic channel (open arrowhead) with NIR fluorescence imaging is demonstrated 28 min after injection of 1.6 mL of 500 µM ICG. Camera exposure times were 30 msec (top row) and 100 msec (bottom row). Scale bars represent 1 cm.

Figure 1
Hutteman and Mieog et al.

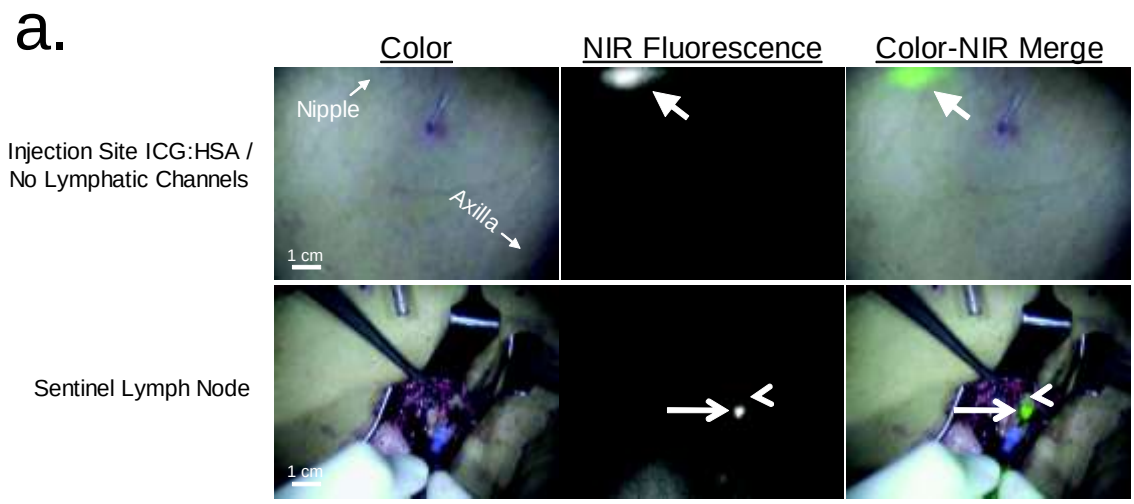

c.

Figure 1
Hutteman and Mieog et al.

b.

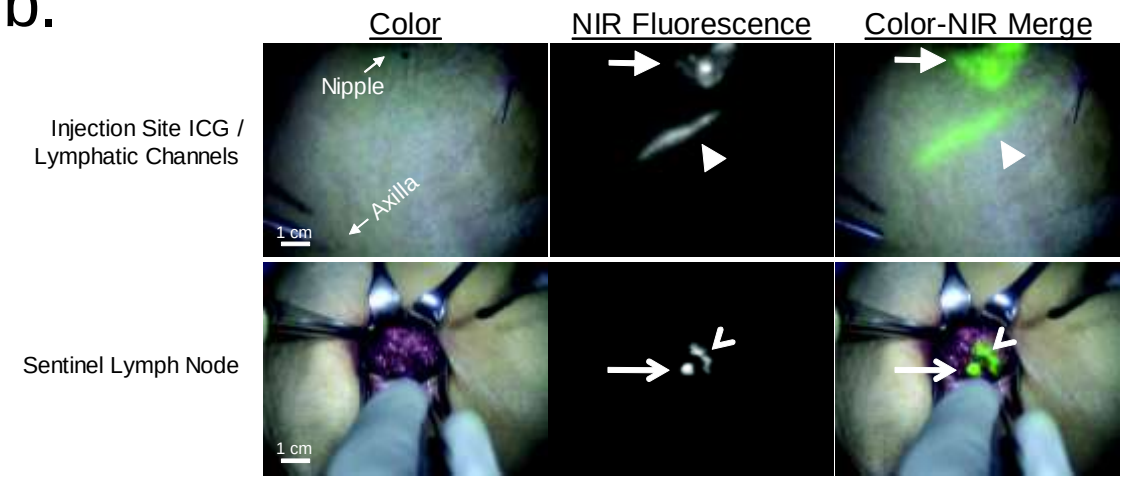

d.