



GERMLINE GAIN-OF-FUNCTION MUTATIONS of ALK DISRUPT CENTRAL NERVOUS SYSTEM DEVELOPMENT

Loic de Pontual, Dania Kettaneh, Chris Gordon, Myriam Oufadem, Nathalie Boddaert, Melissa Less, Laurent Balu, Eric Lachassinne, Andy Petros, Julie Mollet, et al.

► To cite this version:

Loic de Pontual, Dania Kettaneh, Chris Gordon, Myriam Oufadem, Nathalie Boddaert, et al.. GERMLINE GAIN-OF-FUNCTION MUTATIONS of ALK DISRUPT CENTRAL NERVOUS SYSTEM DEVELOPMENT. Human Mutation, 2011, 32 (3), pp.272. 10.1002/humu.21442 . hal-00616287

HAL Id: hal-00616287

<https://hal.science/hal-00616287>

Submitted on 22 Aug 2011

HAL is a multi-disciplinary open access archive for the deposit and dissemination of scientific research documents, whether they are published or not. The documents may come from teaching and research institutions in France or abroad, or from public or private research centers.

L'archive ouverte pluridisciplinaire **HAL**, est destinée au dépôt et à la diffusion de documents scientifiques de niveau recherche, publiés ou non, émanant des établissements d'enseignement et de recherche français ou étrangers, des laboratoires publics ou privés.



GERMLINE GAIN-OF-FUNCTION MUTATIONS of ALK DISRUPT CENTRAL NERVOUS SYSTEM DEVELOPMENT



Journal:	<i>Human Mutation</i>
Manuscript ID:	humu-2010-0563.R2
Wiley - Manuscript type:	Rapid Communication
Date Submitted by the Author:	20-Dec-2010
Complete List of Authors:	de Pontual, Loic; Service de Pédiatrie Kettaneh, Dania; INSERM U781 Gordon, Chris; INSERM U781 Oufadem, Myriam; INSERM U781 Boddaert, Nathalie; INSERM U781 Less, Melissa; great ormond street, clinical genetic Balu, Laurent; reanimation pédiatrique Lachassinne, Eric; Hopital JeanVerdier Petros, Andy; great ormond street, clinical genetic Mollet, Julie; INSERM U781 Wilson, LC; great ormond street, clinical genetic Munnich, Arnold; INSERM U781 Brugière, Laurence; service d'oncologie pédiatrique Delattre, Olivier; institut Curie VEKEMANS, Michel; INSERM U781 Etchevers, Heather; INSERM U781 LYONNET, Stanislas; Hôpital Necker-Enfants Malades, APHP, Genetics; Université René Descartes; INSERM U781, Genetics Janouex Larosey, Isabelle; institut Curie AMIEL, Jeanne; INSERM U781
Key Words:	ALK, neuroblastoma, neurodevelopment, syndrome with cancer

SCHOLARONE™
Manuscripts

GERMLINE GAIN-OF-FUNCTION MUTATIONS of *ALK* DISRUPT CENTRAL
NERVOUS SYSTEM DEVELOPMENT

Loïc de Pontual^{1,2}, Dania Kettaneh¹, Christopher T. Gordon¹, Myriam Oufadem¹, Nathalie
Boddaert³, Melissa Lees⁴, Laurent Balu⁵, Eric Lachassinne², Andy Petros⁶, Julie Mollet⁹,
Louise C. Wilson⁴, Arnold Munnich^{1,7}, Laurence Brugière⁸, Olivier Delattre⁹, Michel
Vekemans^{1,7}, Heather Etchevers¹, Stanislas Lyonnet^{1,7},
Isabelle Janoueix-Lerosey⁹, Jeanne Amiel^{1,7}

¹Université Paris Descartes, INSERM U-781, Paris, France

²Service de Pédiatrie, Hôpital Jean Verdier, AP-HP, Bondy, France

³Service de Radiologie Pédiatrique, INSERM U-1000, Hôpital Necker-Enfants Malades, AP-
HP, Paris, France

⁴Department of Clinical Genetics, Great-Ormond Street Hospital for Children, London, UK

⁵Service de Réanimation Pédiatrique, Hôpital Bicêtre, AP-HP, Kremlin-Bicêtre, France

⁶Paediatric and Neonatal Intensive Care Unit, Great Ormond Street Hospital for Children,
London, UK

⁷Département de Génétique, Faculté de Médecine ; AP-HP, Hôpital Necker-Enfants Malades,
Paris, France

⁸Service d'Oncologie Pédiatrique, Institut Gustave Roussy, Villejuif, France

⁹INSERM U-830, Institut Curie, Paris, France

Running title: *ALK* mutation and central nervous system development

Correspondence should be addressed to Jeanne Amiel

Département de Génétique, Hôpital Necker-Enfants Malades

149, rue de Sèvres, 75743 Paris Cedex 15, France.

Tel: 33 1 44495648

Fax: 33 1 44495150

Email: jeanne.amiel@inserm.fr

Abstract

Neuroblastoma (NB) is a frequent embryonal tumour of sympathetic ganglia and adrenals with extremely variable outcome. Recently, somatic amplification and gain-of-function mutations of the anaplastic lymphoma receptor tyrosine kinase (*ALK*, MIM 105590) gene, either somatic or germline, were identified in a significant proportion of NB cases.

Here we report a novel syndromic presentation associating congenital NB with severe encephalopathy and abnormal shape of the brainstem on brain MRI in two unrelated sporadic cases harbouring *de novo*, germline, heterozygous *ALK* gene mutations. Both mutations are gain-of-function mutations that have been reported in NB and NB cell lines. These observations further illustrate the role of oncogenes in both tumour predisposition and normal development, and shed light on the pleiotropic and activity-dependent role of *ALK* in humans. More generally, missing germline mutations relative to the spectrum of somatic mutations reported for a given oncogene may be a reflection of severe effects during embryonic development, and may prompt mutation screening in patients with extreme phenotypes.

Introduction

Neuroblastoma (NB; MIM 256700) is the most frequent extra-cranial solid tumour in children. Both familial cases with vertical transmission, and predisposition in chromosomal and monogenic syndromes, have long supported the involvement of genetic factors. Several NB predisposing genes were recently identified, such as *PHOX2B*, *CREBBP*, *NSD1*, *HRAS*, *NFI* and *ALK*. The last three genes encode proteins involved in the RAS/MAPK pathway [Chiarle, et al., 2008; Palmer, et al., 2009] and *ALK* is a downstream target of *PHOX2B* [Bachetti, et al., 2010].

ALK, a tyrosine kinase receptor gene of the insulin receptor family, is activated by fusion with various partners in anaplastic large cell lymphomas, inflammatory myofibroblastic tumours and in some lung cancers [Chiarle, et al., 2008]. Recently, somatic amplification and gain-of-function mutations of *ALK* were identified in about 2-4 and 7-10% of NB cases respectively [Chen, et al., 2008; Janoueix-Lerosey, et al., 2008; Mosse, et al., 2008; De Brouwer, et al., 2010]. Germline gain-of-function mutations have also been reported in half of the familial cases of NB tested thus far [Janoueix-Lerosey, et al., 2008; Mosse, et al., 2008]. *ALK* is preferentially expressed in the central and peripheral nervous systems during development but its role in the normal development of the nervous system remains speculative [Iwahara, et al., 1997; Vernersson, et al., 2006; Hurley, et al., 2006]. Indeed, familial *ALK* gain-of-function mutations predispose to isolated NB, but are not associated with developmental anomalies, and *Alk*^{-/-} mice have no obvious embryonic phenotype. However, behavioural impairment has been described in the *Alk*^{-/-} mice, a phenotype attributed to neurochemical alterations in the hippocampi and basal cortex [Bilsland, et al., 2008].

Here we report two unrelated cases with an association of congenital NB and severe encephalopathy characterised by a specific abnormal shape of the brainstem on brain

1
2
3 magnetic resonance imaging (MRI). In both cases we identified a heterozygous, germline *de*
4
5 *novo* missense mutation located in the tyrosine kinase domain (TKD) of ALK at positions
6
7 previously identified as somatic mutational hot-spots in NB and NB cell lines.
8
9

10 11 12 13 14 15 **Patients and Methods**

16
17 Case1, a female, was the second child born to unrelated healthy parents, aged 29 and
18
19 31 years at the time of birth, with no relevant family medical history. She was born at term by
20
21 caesarean section with normal birth parameters following an uneventful pregnancy (BW :
22
23 3100 g, BL : 46 cm, OFC : 34 cm). She was hypotonic, hypomotile and presented with major
24
25 feeding difficulties, no sucking and swallowing reflexes, episodes of abdominal distension
26
27 and apneas. Mechanical ventilation and tube feeding were required. An adrenal NB with
28
29 pelvic extension was diagnosed at three days of life. Levels of urinary catecholamine and its
30
31 metabolites were raised. Rapid tumour progression led to chemotherapy by vincristine and
32
33 cyclophosphamide with no improvement of the tumour mass or catecholamine excretion. Boli
34
35 of corticosteroids were delivered and plasmapheresis performed with the hypothesis of a
36
37 paraneoplastic syndrome, but no neurological improvement was seen.
38
39
40
41
42

43
44 There was no congenital malformation or morphologic abnormality at clinical
45
46 examination except for a high arched palate. Neurologic development was poor. She could fix
47
48 and follow with normal eye movements and remained hypotonic with little spontaneous
49
50 movements, sucking and swallowing were absent, she experienced severe episodes of
51
52 desaturation and sweating and she displayed hyperextension of the limbs. A tracheostomy
53
54 tube was inserted at six weeks of age. Osteotendinous reflexes were present. A deceleration of
55
56 the head circumference's growth was noticeable with OFC of 39 cm (5th centile) at four
57
58
59
60

1
2
3
4
5
6
7
8
9
10
11
12
13
14
15
16
17
18
19
20
21
22
23
24
25
26
27
28
29
30
31
32
33
34
35
36
37
38
39
40
41
42
43
44
45
46
47
48
49
50
51
52
53
54
55
56
57
58
59
60

months. She died at age four and a half months from a severe apnea with no attempt at resuscitation. Necropsy was not performed.

The tumour was classified as stage 3 by histology [Brodeur, et al., 1993]. Neither *MYCN* amplification nor 1p36 deletion were detected by FISH. No antineuronal antibodies were secreted in the CSF. A computerised tomography (CT) scan showed no spinal cord compression. Meta-iodo-benzyl-guanidine (MIBG) scintiscan showed no bone fixation. Electromyography and muscle histology were within the normal limits. Electroencephalography (EEG) showed slow activity without epilepsy. Auditory evoked potential was normal. Histological examination of a rectal biopsy showed normal enteric plexuses eliminating Hirschsprung disease as the cause of abdominal distension. Blood karyotype and a comparative genomic hybridization (CGH)-array with a 650 kb resolution showed normal chromosomes 46, XX. Brain magnetic resonance imaging (MRI) was performed at three days and again at 15 weeks of age. At the latter time point, an abnormal shape of the brainstem was noted with an enlarged medulla oblongata eclipsing the ovoid form of the pons. In retrospect, the same image was present from birth (Figure 1A).

Case 2, a female, was the first child born to unrelated healthy parents with no relevant family medical history. Intra-uterine growth retardation and sinusoidal cardiotocograph led to emergency Caesarean section at 31 weeks gestation (BW 1300 g, and a head circumference of 28.5 cm; both at approximately the 25th centile). Paternal and maternal ages at time of birth were 42 and 37 years respectively. Hypotonia with little spontaneous movements, poor sucking, gastro-oesophageal reflux and distended abdomen were noted at birth. She presented daily episodes of desaturation and tracheobronchomalacia necessitating respiratory support and a tracheostomy tube was inserted at age three months. A thoraco-abdominal CT scan at age three weeks showed bilateral large heterogeneous and calcified adrenal masses. She

underwent four courses of chemotherapy leading to a reduction in the size of the tumours, but a MIBG scintiscan showed uptake of dye in the right hemithorax that was later confirmed by CT scan. She had a patent foramen ovale with prolonged QT segments on electrocardiography. Bilateral hernias were surgically repaired at age two months. She was kept on nasogastric feeds for persistent difficulties in swallowing. Intermittent abdominal distension remained unexplained; a contrast enema showed no obstruction and endoscopic intestinal biopsies were normal. Temperature instability was also observed. At age five months, she developed abnormal movements of the right arm and leg. Repeated EEGs failed to show focal epileptiform activity and seizures arising from the brainstem were hypothesised. Although initially normal, cranial ultrasound showed an ischaemic cortical lesion on the right inferior parietal lobe. Growth parameters had all fallen below the 0.4th centile by age five months. At nine months, she could fix, had a left convergent squint with normal fundi and responded to sound. Sensory motor deficit was suspected. She died at age nine months following a decision to withdraw intensive care. Necropsy was not performed.

In retrospect, the brain MRIs performed at age six and 15 weeks showed a brainstem shape very similar to that observed in case 1 (Figure 1B). At histology, both adrenal biopsies showed infiltrating islands of undifferentiated neuroblasts. FISH analysis identified four copies of the *MYCN* gene, trisomy of chromosomes 1 and 9 and tetrasomy of chromosome 17.

Blood samples for both cases were obtained with informed consent and DNA was extracted according to standard protocols. Direct sequencing of the *ALK* and *PHOX2B* genes was performed on both strands as previously described using the Big Dye Terminator Cycle Sequencing kit (Applied Biosystems) and was analyzed on an ABI 3100 automated sequencer.

1
2
3
4
5
6
7
8
9
10
11
12
13
14
15
16
17
18
19
20
21
22
23
24
25
26
27
28
29
30
31
32
33
34
35
36
37
38
39
40
41
42
43
44
45
46
47
48
49
50
51
52
53
54
55
56
57
58
59
60

Results

No nucleotidic variation of the *PHOX2B* gene was found. A heterozygous variation of the *ALK* gene was identified in each case (c.3733T>G, p.F1245V in case 1 and c.3520T>G, p.F1174V in case 2; numbering is based on the cDNA sequence from NM_004304.3 (ALK_v001), Figure 2). Each missense mutation altered a conserved amino acid within the intracellular TKD of the protein at a position already found mutated in several NB cell lines and tumours (reviewed in [Palmer, et al., 2009] and [Janoueix-Lerosey, et al., 2010]). Both mutations occurred *de novo*. A paternal contribution to the child genotype was confirmed for nine unlinked and polymorphic CA repeat microsatellite markers in case 1 and 2 (data available on request).

Discussion

In both cases described in this report, we identified a *de novo* heterozygous germline *ALK* gene mutation. Importantly, mutations at position p.F1174 and p.F1245 have been reported already (with substitution for I, C, V and L amino acids in both cases), but were invariably somatic [De Brouwer, et al., 2010; Janoueix-Lerosey, et al., 2010; Palmer, et al., 2009]. However, the missense mutations p.G1128A, p.R1192P and p.R1275Q, lying in the TKD of ALK, have been reported in familial cases segregating NB predisposition with incomplete penetrance and without presenting any neurological symptoms, and have not been reported as somatic mutations [Janoueix-Lerosey, et al., 2008; Mosse, et al., 2008]. Conversely, both children reported here presented with multifocal NB of neonatal onset and, severe, non epileptic encephalopathy with a fatal outcome. They were initially referred for possible central congenital hypoventilation syndrome (CCHS, Ondine’s curse MIM209880) due to episodes of apnoeas and desaturation, abdominal distension and NB. However, these episodes were independent of the sleep-wake state and direct sequencing of the *PHOX2B*

gene failed to identify a coding sequence mutation. Opsomyoclonic syndrome had also been considered but electroencephalographic recordings showed no epilepsy and eye movements were normal. Moreover, plasmapheresis and corticosteroids did not lead to neurological improvement. Compression by the abdominal mass and Hirschsprung disease were also considered as explanations for the episodes of abdominal distension. An alternative hypothesis is enteric nervous system dysfunction given that *Alk* is expressed in the developing gut in mice [Vernersson, et al., 2006]. The brainstem anomaly in the two patients reported here does not seem progressive, although this could not be assessed fully, given that both patients died at an early age. Nonetheless, the medulla oblongata was enlarged from birth in both cases. The presence of this feature upon brain MRI may be a good indication of an *ALK* germline mutation in a newborn with severe encephalopathy and brainstem dysfunction of unknown cause with or without NB. Indeed, whether neonatal NB is a consistent feature of the syndrome remains to be defined. The differential diagnosis would be a tumour of the medulla (more often a pilocytic astrocytoma), but enlargement would be asymmetric and presenting hypointensity on T1-weighted images.

There is a sharp contrast between the brain phenotype of the patients described in this report, and that of patients with Cardio-Facio-Cutaneous syndromes, in which germline gain-of-function mutations in several genes involved in the RAS signalling pathway have been described, and for whom absolute or relative macrocephaly is the rule (see [Tidyman and Rauen, 2009] for review). This is particularly true for Costello syndrome, which is ascribed to *HRAS* gain-of-function mutations, with amino acid substitution hotspots at codons p.G12 and p.G13 [Aoki, et al., 2005]. Interestingly, a progressive enlargement of the cerebellum leading to posterior fossa crowding and cerebellar tonsillar herniation has been described in a majority of patients with Costello syndrome, while the shape of the brainstem remains normal [Gripp, et al., 2010].

1
2
3
4
5
6
7
8
9
10
11
12
13
14
15
16
17
18
19
20
21
22
23
24
25
26
27
28
29
30
31
32
33
34
35
36
37
38
39
40
41
42
43
44
45
46
47
48
49
50
51
52
53
54
55
56
57
58
59
60

ALK is an extremely conserved tyrosine kinase receptor of the insulin receptor family with Midkine and Pleiotrophin as putative ligands in mammals. Ligand binding leads to ALK heterodimerisation, autophosphorylation and activation of the RAS/MAPK, phosphoinositide-3 kinase (PI3K)/AKT, JAK/STAT3 or PLC γ pathways, promoting proliferation, differentiation or survival [Chiarle, et al., 2008; Palmer, et al., 2009; Wasik, et al., 2009]. Fusion proteins arising from somatic rearrangements have been reported in anaplastic large cell lymphomas and other tumours (reviewed in [Palmer, et al., 2009]). In NB and NB cell lines, both *ALK* amplification and gain-of-function missense mutations of conserved codons of the TKD have been reported [Chen, et al., 2008; George, et al., 2008; Janoueix-Lerosey, et al., 2008; Passoni, et al., 2009]. Some experimental data indicate variable oncogenic potential of ALK mutants with p.F1174L having an increased transforming capacity compared to p.R1275Q and p.K1062M [Chen, et al., 2008; De Brouwer, et al., 2010]. Altogether, these observations suggest different effects on ALK signalling for different mutations, with variable biological consequences. An interesting possibility is that there is an ALK activity threshold, above which CNS development would be impaired, but which is not reached by all ALK gain-of-function mutations reported thus far. Animal models are not yet available but knock-in mice bearing mutations at codon p.F1174 and p.R1245 are being generated in several groups. In the CNS of mice, *Alk* is expressed in several thalamic and hypothalamic nuclei, the pons, the medulla oblongata and the ventral horn of the spinal cord [Vernersson *et al.*, 2006]. It will be of high interest to explore the consequences of endogenous expression of mutant ALK on both neurological function and anatomic development of the pons, medulla and motor neurons.

There is a growing list of genes for which somatic and germline gain-of-function mutations have been reported in tumours (of various types) and syndromes respectively

(Table 1). Interestingly, tumour predisposition burdens a minority of these syndromes. The repertoire of mutations and the relative proportion of each nucleotidic variation (and amino acid substitution) are different between somatic and germline cases. As a general rule, mutations exhibiting the highest activating effect *in vitro* are prevalent in the somatic repertoire and absent from its germline counterpart. The *HRAS* gene stands as a paradigm. Somatic gain-of-function mutations at codons p.G12, p.G13 and p.Q61 are found in various tumours, whereas germline mutations at codon p.Q61 have not been reported in patients with Costello syndrome. Moreover, when considering amino acid changes at codon 12, p.G12V is far more frequent somatically than p.G12S (and leading to a greater activation [Fasano, et al., 1984]), while in Costello syndrome p.G12S is the most common substitution, with p.G12V having been reported only twice; both of these patients had a severe phenotype [van der Burgt, et al., 2007]. Most interestingly, two “missing germline mutations” at codon 61 (Q61R and Q61K) of *HRAS* have been identified in 5/30 spermatocytic seminomas (a rare testicular germ cell tumour of late-age onset) [Goriely, et al., 2009]. We thus speculate that such mutations are to be found in the germline but probably lead to an extreme, possibly foetal lethal phenotype, distinct from Costello syndrome.

Here we report a novel syndrome with predisposition to NB due to constitutive *ALK* gain-of-function mutations. In doing so, we provide evidence that normal CNS development requires regulation of *ALK* activity, with a threshold being exceeded for some mutations only, and therefore we add *ALK* to the list of oncogenes with important roles in normal development.

1
2
3
4
5
6
7
8
9
10
11
12
13
14
15
16
17
18
19
20
21
22
23
24
25
26
27
28
29
30
31
32
33
34
35
36
37
38
39
40
41
42
43
44
45
46
47
48
49
50
51
52
53
54
55
56
57
58
59
60

Acknowledgments :

This work is supported by grants from the Agence Nationale de la Recherche (ANR), the Foundation pour la Recherche Médicale (FRM), the INCa-DHOS, the Institut National du Cancer, the Ligue Nationale contre le Cancer (Equipe labellisée), the Association Hubert Gouin, Les Bagouz à Manon, les amis de Claire, and Enfance et Santé.

For Peer Review

Table and Figures

Figure 1: Brain MRI of the two patients and three controls.

Note the abnormal shape of the brainstem with enlarged medulla oblongata eclipsing the ovoid form of the pons (arrows) on brain MRI (T1-weighted sagittal images) in both cases (top) as compared to controls (bottom, arrowheads).

A) patient 1, B) patient 2, C) antenatal MRI of a control foetus at 34 weeks gestation, D-E) controls.

Figure 2: *ALK* gene mutations.

2A. A constitutional heterozygous missense variation of the *ALK* gene having occurred *de novo* was identified in each case (c.3733T>G, p.F1245V in case 1 and c.3520T>G, p.F1174V in case 2, with numbering based on the cDNA sequence from NM_004304.3 (*ALK_v001*). There are no evidence that the *ALK* mutations are present in mosaic state. Indeed mutant allele is not under-represented compared to wild-type allele. Residue F1245 is located in the catalytic loop and residue F1174 in the C helix of the TKD [Bossi, et al., 2010; Lee, et al., 2010].

2B. Published *ALK* mutations in NB (adapted from (Janoueix-Lerosey, et al., 2010) with permission). Mutations are indicated by arrows, with the number of mutations identified at each position to date indicated underneath. The mutations are mainly located in the TK domain, with two hotspots at positions 1174 and 1275.

References

- Aoki Y, Niihori T, Kawame H, Kurosawa K, Ohashi H, Tanaka Y, Filocamo M, Kato K, Suzuki Y, Kure S and others. 2005. Germline mutations in HRAS proto-oncogene cause Costello syndrome. *Nat Genet* 37:1038-40.
- Bachetti T, Di Paolo D, Di Lascio S, Mirisola V, Brignole C, Bellotti M, Caffa I, Ferraris C, Fiore M, Fornasari D and others. 2010. PHOX2B-mediated regulation of ALK expression: in vitro identification of a functional relationship between two genes involved in neuroblastoma. *PLoS One* 5: e13108
- Bilsland JG, Wheeldon A, Mead A, Znamenskiy P, Almond S, Waters KA, Thakur M, Beaumont V, Bonnert TP, Heavens R and others. 2008. Behavioral and neurochemical alterations in mice deficient in anaplastic lymphoma kinase suggest therapeutic potential for psychiatric indications. *Neuropsychopharmacology* 33:685-700.
- Bossi RT, Saccardo MB, Ardini E, Menichincheri M, Rusconi L, Magnaghi P, Orsini P, Avanzi N, Borgia AL, Nesi M and others. 2010. Crystal structures of anaplastic lymphoma kinase in complex with ATP competitive inhibitors. *Biochemistry* 49:6813-25.
- Brodeur GM, Pritchard J, Berthold F, Carlsen NL, Castel V, Castelberry RP, De Bernardi B, Evans AE, Favrot M, Hedborg F and others. 1993. Revisions of the international criteria for neuroblastoma diagnosis, staging, and response to treatment. *J Clin Oncol* 11:1466-77.
- Chen Y, Takita J, Choi YL, Kato M, Ohira M, Sanada M, Wang L, Soda M, Kikuchi A, Igarashi T and others. 2008. Oncogenic mutations of ALK kinase in neuroblastoma. *Nature* 455:971-4.
- Chiarle R, Voena C, Ambrogio C, Piva R, Inghirami G. 2008. The anaplastic lymphoma kinase in the pathogenesis of cancer. *Nat Rev Cancer* 8:11-23.
- De Brouwer S, De Preter K, Kumps C, Zabrocki P, Porcu M, Westerhout EM, Lakeman A, Vandesompele J, Hoebeeck J, Van Maerken T and others. 2010. Meta-analysis of neuroblastomas reveals a skewed ALK mutation spectrum in tumors with *MYCN* amplification. *Clin Cancer Res* 16:4353-62.
- Fasano O, Aldrich T, Tamanoi F, Taparowsky E, Furth M, Wigler M. 1984. Analysis of the transforming potential of the human H-ras gene by random mutagenesis. *Proc Natl Acad Sci U S A* 81:4008-12.
- George RE, Sanda T, Hanna M, Frohling S, Luther W, 2nd, Zhang J, Ahn Y, Zhou W, London WB, McGrady P and others. 2008. Activating mutations in ALK provide a therapeutic target in neuroblastoma. *Nature* 455:975-8.
- Goriely A, Hansen RM, Taylor IB, Olesen IA, Jacobsen GK, McGowan SJ, Pfeifer SP, McVean GA, Meyts ER, Wilkie AO. 2009. Activating mutations in FGFR3 and HRAS reveal a shared genetic origin for congenital disorders and testicular tumors. *Nat Genet* 41:1247-52.
- Gripp KW, Hopkins E, Doyle D, Dobyns WB. 2010. High incidence of progressive postnatal cerebellar enlargement in Costello syndrome: brain overgrowth associated with HRAS mutations as the likely cause of structural brain and spinal cord abnormalities. *Am J Med Genet A* 152A:1161-8.
- Hofstra RM, Landsvater RM, Ceccherini I, Stulp RP, Stelwagen T, Luo Y, Pasini B, Hoppener JW, van Amstel HK, Romeo G and others. 1994. A mutation in the RET proto-oncogene associated with multiple endocrine neoplasia type 2B and sporadic medullary thyroid carcinoma. *Nature* 367:375-6.

- Hurley SP, Clary DO, Copie V, Lefcort F. 2006. Anaplastic lymphoma kinase is dynamically expressed on subsets of motor neurons and in the peripheral nervous system. *J Comp Neurol* 495:202-12.
- Iwahara T, Fujimoto J, Wen D, Cupples R, Bucay N, Arakawa T, Mori S, Ratzkin B, Yamamoto T. 1997. Molecular characterization of ALK, a receptor tyrosine kinase expressed specifically in the nervous system. *Oncogene* 14:439-49.
- Janoueix-Lerosey I, Lequin D, Brugieres L, Ribeiro A, de Pontual L, Combaret V, Raynal V, Puisieux A, Schleiermacher G, Pierron G and others. 2008. Somatic and germline activating mutations of the ALK kinase receptor in neuroblastoma. *Nature* 455:967-70.
- Janoueix-Lerosey I, Schleiermacher G, Delattre O. 2010. Molecular pathogenesis of peripheral neuroblastic tumors. *Oncogene* 29:1566-79.
- Kranendijk M, Struys EA, van Schaftingen E, Gibson KM, Kanhai WA, van der Knaap MS, Amiel J, Buist NR, Das AM, de Klerk JB and others. IDH2 mutations in patients with D-2-hydroxyglutaric aciduria. *Science* 330:336.
- Lee CC, Jia Y, Li N, Sun X, Ng K, Ambing E, Gao MY, Hua S, Chen C, Kim S and others. 2010. Crystal structure of the ALK (anaplastic lymphoma kinase) catalytic domain. *Biochem J* 430:425-37.
- Mosse YP, Laudenslager M, Longo L, Cole KA, Wood A, Attiyeh EF, Laquaglia MJ, Sennett R, Lynch JE, Perri P and others. 2008. Identification of ALK as a major familial neuroblastoma predisposition gene. *Nature* 455:930-5.
- Mulligan LM, Kwok JB, Healey CS, Elsdon MJ, Eng C, Gardner E, Love DR, Mole SE, Moore JK, Papi L and others. 1993. Germ-line mutations of the RET proto-oncogene in multiple endocrine neoplasia type 2A. *Nature* 363:458-60.
- Niihori T, Aoki Y, Narumi Y, Neri G, Cave H, Verloes A, Okamoto N, Hennekam RC, Gillesen-Kaesbach G, Wiczorek D and others. 2006. Germline KRAS and BRAF mutations in cardio-facio-cutaneous syndrome. *Nat Genet* 38:294-6.
- Palmer RH, Vernersson E, Grabbe C, Hallberg B. 2009. Anaplastic lymphoma kinase: signalling in development and disease. *Biochem J* 420:345-61.
- Passoni L, Longo L, Collini P, Coluccia AM, Bozzi F, Podda M, Gregorio A, Gambini C, Garaventa A, Pistoia V and others. 2009. Mutation-independent anaplastic lymphoma kinase overexpression in poor prognosis neuroblastoma patients. *Cancer Res* 69:7338-46.
- Reardon W, Winter RM, Rutland P, Pulleyn LJ, Jones BM, Malcolm S. 1994. Mutations in the fibroblast growth factor receptor 2 gene cause Crouzon syndrome. *Nat Genet* 8:98-103.
- Rousseau F, Bonaventure J, Legeai-Mallet L, Pelet A, Rozet JM, Maroteaux P, Le Merrer M, Munnich A. 1994. Mutations in the gene encoding fibroblast growth factor receptor-3 in achondroplasia. *Nature* 371:252-4.
- Tartaglia M, Mehler EL, Goldberg R, Zampino G, Brunner HG, Kremer H, van der Burgt I, Crosby AH, Ion A, Jeffery S and others. 2001. Mutations in PTPN11, encoding the protein tyrosine phosphatase SHP-2, cause Noonan syndrome. *Nat Genet* 29:465-8.
- Tidyman WE, Rauen KA. 2009. The RASopathies: developmental syndromes of Ras/MAPK pathway dysregulation. *Curr Opin Genet Dev* 19:230-6.
- van der Burgt I, Kupsky W, Stassou S, Nadroo A, Barroso C, Diem A, Kratz CP, Dvorsky R, Ahmadian MR, Zenker M. 2007. Myopathy caused by HRAS germline mutations: implications for disturbed myogenic differentiation in the presence of constitutive HRas activation. *J Med Genet* 44:459-62.

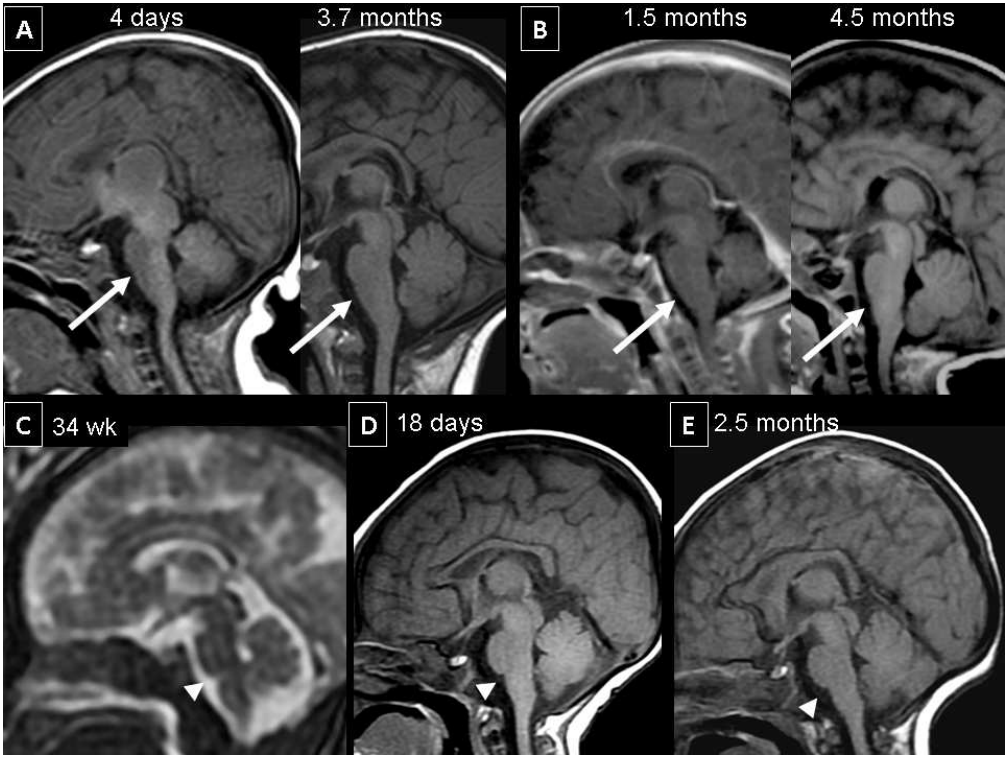
1
2
3
4
5
6
7
8
9
10
11
12
13
14
15
16
17
18
19
20
21
22
23
24
25
26
27
28
29
30
31
32
33
34
35
36
37
38
39
40
41
42
43
44
45
46
47
48
49
50
51
52
53
54
55
56
57
58
59
60

Vernersson E, Khoo NK, Henriksson ML, Roos G, Palmer RH, Hallberg B. 2006. Characterization of the expression of the ALK receptor tyrosine kinase in mice. *Gene Expr Patterns* 6:448-61.

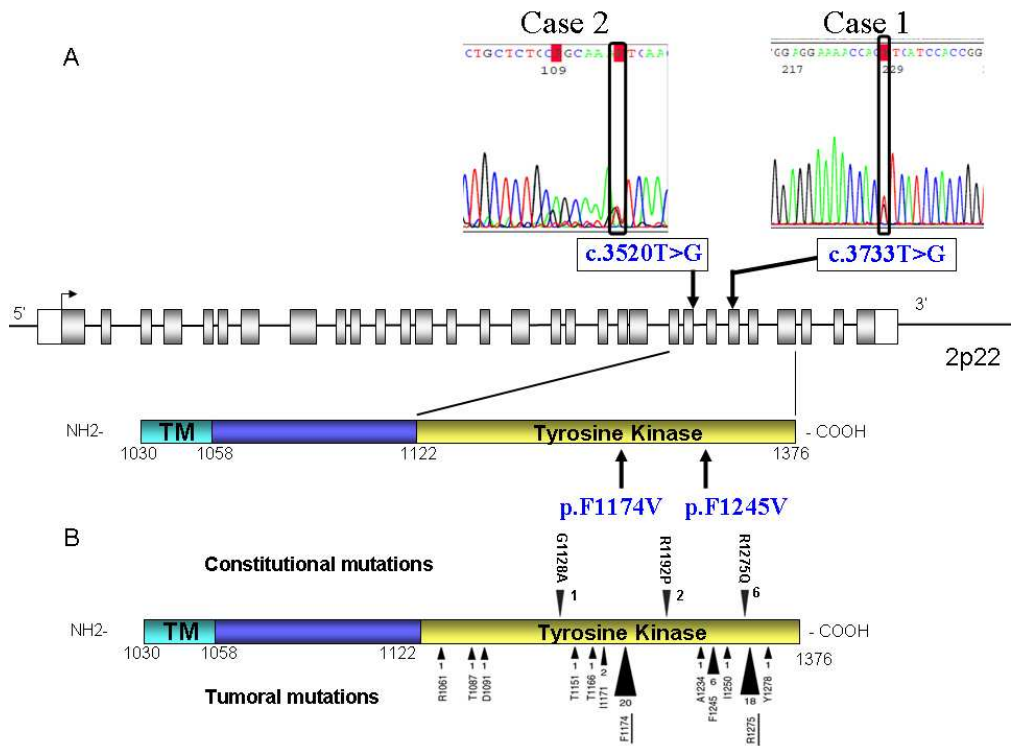
Wasik MA, Zhang Q, Marzec M, Kasprzycka M, Wang HY, Liu X. 2009. Anaplastic lymphoma kinase (ALK)-induced malignancies: novel mechanisms of cell transformation and potential therapeutic approaches. *Semin Oncol* 36:S27-35.

Wilkie AO, Slaney SF, Oldridge M, Poole MD, Ashworth GJ, Hockley AD, Hayward RD, David DJ, Pulleyn LJ, Rutland P and others. 1995. Apert syndrome results from localized mutations of FGFR2 and is allelic with Crouzon syndrome. *Nat Genet* 9:165-72.

For Peer Review



254x190mm (96 x 96 DPI)



254x190mm (96 x 96 DPI)

Gene	MIM	Somatic mutation / tumour predisposition	Germline mutation / Syndromes	Reference
<i>RET</i>	164761	Thyroid	MEN2A / MEN2B*	[Mulligan, et al., 1993; Hofstra, et al., 1994]
<i>FGFR3</i>	134934	Bladder / Skin / Haematopoietic	Achondroplasia / TD	[Rousseau, et al., 1994]
<i>FGFR2</i>	176943	Uterus / Skin / Testicle	Crouzon / Apert / Pfeiffer	[Reardon, et al., 1994; Wilkie, et al., 1995]
<i>HRAS</i>	190020	Bladder / Thyroid / Skin	Costello*	[Aoki, et al., 2005]
<i>KRAS</i>	190070	Colon / Pancreas / Lung	Noonan / CFC	[Niihori, et al., 2006]
<i>BRAF</i>	164757	Colon / Thyroid / Skin	CFC	[Niihori, et al., 2006]
<i>PTPN11</i>	176876	Haematopoietic	Noonan	[Tartaglia, et al., 2001]
<i>IDH2</i>	147650	CNS / Haematopoietic	D2 Hydroxyglutaric Aciduria	[Kranendijk, et al.]
<i>ALK</i>	105590	PNS	Congenital encephalopathy	this report

Table 1: List of genes for which somatic and germline gain-of-function mutations have been reported in tumours and syndromes respectively.

Syndromes predisposing to tumours are indicated with an asterisk. Several cases of leukemia have been reported in CFC. A paternal age effect is observed for germline mutations of *RET*, *FGFR2*, *FGFR3*, *HRAS* and *PTPN11*.

1
2
3
4
5
6
7
8
9
10
11
12
13
14
15
16
17
18
19
20
21
22
23
24
25
26
27
28
29
30
31
32
33
34
35
36
37
38
39
40
41
42
43
44
45
46
47

For Peer Review