



HAL
open science

Radiotherapy and breast reconstruction: a meta-analysis

M Barry, M. R. Kell

► **To cite this version:**

M Barry, M. R. Kell. Radiotherapy and breast reconstruction: a meta-analysis. *Breast Cancer Research and Treatment*, 2011, 127 (1), pp.15-22. 10.1007/s10549-011-1401-x . hal-00616236

HAL Id: hal-00616236

<https://hal.science/hal-00616236>

Submitted on 20 Aug 2011

HAL is a multi-disciplinary open access archive for the deposit and dissemination of scientific research documents, whether they are published or not. The documents may come from teaching and research institutions in France or abroad, or from public or private research centers.

L'archive ouverte pluridisciplinaire **HAL**, est destinée au dépôt et à la diffusion de documents scientifiques de niveau recherche, publiés ou non, émanant des établissements d'enseignement et de recherche français ou étrangers, des laboratoires publics ou privés.

RADIOTHERAPY AND BREAST RECONSTRUCTION: A META-ANALYSIS

M Barry and M.R. Kell.

Department of Breast Surgery, BreastCheck, Mater Misericordiae University
Hospital, Dublin. Ireland.

Address Correspondence to:

Malcolm R. Kell

Department of Breast Surgery,

Mater Misericordiae University Hospital,

Dublin,

Ireland.

Telephone: 00353-87-9687626

Email: Malcolm.kell@nhs.uk

Keywords: Postmastectomy radiotherapy, immediate and delayed breast reconstruction, prosthetic breast reconstruction, autologous breast reconstruction, postoperative morbidity.

Introduction: The optimum sequencing of breast reconstruction (BR) in patients receiving postmastectomy radiation therapy (PMRT) is controversial.

Methods: A comprehensive search of published **studies** that examined **postoperative morbidity** following immediate or delayed breast reconstruction with combined radiotherapy was performed. Medical (MEDLINE & EMBASE) databases were searched and cross-referenced for appropriate studies where morbidity following BR was the primary outcome measured.

Results: 1,105 patients were identified from **11** appropriately selected studies. Patients undergoing PMRT and BR are more likely to suffer morbidity compared to patients not receiving PMRT ((OR) = 4.2; 95% CI, 2.4-7.2(no PMRT vs. PMRT)). Reconstruction technique was also examined with outcome when PMRT was delivered after BR and this demonstrated that autologous reconstruction is associated with less morbidity in this setting ((OR) = 0.21; (95% CI, 0.1-0.4 (autologous vs. implant based)). Delaying BR until after PMRT had no significant effect on outcome ((OR) =0.87; 95% CI, 0.47-1.62 (delayed vs. immediate)).

Conclusions: PMRT has a detrimental effect on BR outcome. These results suggest that where immediate reconstruction is undertaken with the necessity of PMRT, an autologous flap results in less morbidity when compared to implant based reconstruction.

INTRODUCTION:

Breast conservation surgery provides excellent locoregional control with improved quality of life when compared with mastectomy [1]. However many patients still require mastectomy as the optimum therapeutic cancer procedure, and many opt to undergo immediate breast reconstruction [2]. It is therefore essential that an appropriate strategy be proposed regarding the timing of reconstruction and postoperative radiotherapy. The enthusiasm for post-mastectomy breast reconstruction aims to achieve good functional aesthetic outcome and maintain their quality of life, without negatively affecting the prognosis or detection of cancer recurrence [3].

The Danish Breast Cancer Cooperative Group, 82b and 82c, trials in conjunction with findings from the Canadian trial, collectively demonstrate that patients randomised to receive post-mastectomy radiation have a lower 10-year rate of local regional recurrence **and an additional survival advantage associated with post-mastectomy radiotherapy** [4, 5]. Based on these, and similar studies, there are now clear guidelines regarding the indications for post-mastectomy radiation which are; large tumour size, direct involvement of the skin, and 4 or more metastatic axillary lymph nodes [6-8]. However, despite reducing loco-regional recurrences and increasing disease-free survival [9], post mastectomy radiotherapy may negatively affect reconstruction outcome.

As a consequence, several studies have demonstrated that immediate breast reconstructions in irradiated patients are associated with the potential for

significant postoperative morbidity [10, 11]. As a result, breast reconstruction may be delayed until the final pathological results are available from the mastectomy specimen and the indication for radiotherapy can be established.

Immediate breast reconstruction without radiotherapy, offers enhanced aesthetic and safe oncological outcomes, is more cost-effective and provides a positive psychological effect [12-16]. Despite this, less than 20% of patients having a mastectomy have immediate breast reconstruction in the United States [2]. This may be due to patient choice or possibly apprehension on the part of the surgeon that radiotherapy maybe required postoperatively which potentially could compromise the reconstruction. Radiotherapy can cause unpredictable changes in all tissues and prosthetic materials [17]. It has a biphasic nature with the acute effects occurring over days to weeks and a delayed response, which can occur from months to years after completion of the therapy [18]. The acute phase usually involves acute inflammatory changes which may lead to desquamation or even necrosis of tissue [19]. The delayed phase involves atrophy, fibrosis and inhibition of normal wound healing mechanisms [19]. Furthermore, opponents of immediate breast reconstruction, suggest it may alter chest wall anatomy and therefore distort the geometrics of the radiation field design leading to under/overdosing the targeted and underlying tissues [20, 21]. However, Stralman et al demonstrated a loco-regional recurrence rate of 6% in 100 patients who had a mastectomy with immediate (implant/autologous) reconstruction followed by radiotherapy

with a mean follow up of 108+/- 26 months. This suggests, there is no significant decrease in efficacy or delivery of radiation post-immediate implant or autologous reconstruction [22]. Furthermore, Huang et al, compared the incidence of local recurrence and distant metastasis of post-mastectomy radiotherapy for breast cancer patients with and without immediate TRAM flap reconstruction. They reported no statistical differences in the incidences of locoregional recurrence or distant metastasis between the TRAM flap and the non-TRAM flap patients [23].

Therefore, the objective of this meta-analysis is to examine the published evidence on whether patients requiring post-mastectomy radiotherapy should have an immediate or delayed reconstruction and whether a prosthesis or autologous reconstruction is associated with the **optimum outcome in terms of postoperative morbidity**.

METHODS:

Identification of studies

MEDLINE and **EMBASE** were searched by entering the following in the searching algorithm: breast reconstruction AND (surgery OR radiation) AND (clinical trial OR randomized controlled trial OR double-blind OR single-blind OR random OR randomized OR placebo **OR retrospective study OR prospective study**). English was set as a language restriction. The latest search was performed on January 1, 2010. Two authors (M.B. and M.R.K.) independently examined the title and abstract of citations and the full texts of potentially eligible trials were obtained and disagreements were resolved by discussion.

Eligibility Criteria

All trials whether randomized or non-randomized, prospective or retrospective were eligible that examined the effects of radiotherapy on immediate or delayed breast reconstruction using either a prosthesis or autologous tissue (Latissimus Dorsi (LD) or Transversus Rectus Abdominis Muscle (TRAM). Case series or reports were not included. Studies where the data could not be accurately extracted were also excluded.

Data Extraction and Outcomes

The following information regarding each eligible trial was recorded: authors' names, journal, patient numbers, timing and method of reconstruction, addition of radiotherapy and the post-operative complication rate. The primary end point of

this meta-analysis was postoperative morbidity including capsular contracture, fibrosis, fat necrosis, surgical site infections requiring removal of prosthesis/re-operation (see tables 2, 4 and 6).

Statistical Analysis

For post-operative complications in each study, the odds ratio (O.R.) of the simple proportions of events was estimated with its variance and 95% CI. Heterogeneity between the O.R.s for the same outcome between studies was assessed by use of the X^2 – based Q statistic [24]. Data were then combined across studies by the use of general variance methods with fixed and random effects models [14]. Analyses were conducted using StatsDirect version 2.5.6 (StatsDirect Ltd, Chesire, United Kingdom) and SPSS version 12.0 (SPSS, Inc, Chicago, IL). All statistical tests were two tailed.

RESULTS:

Eligible Studies

20 potentially eligible studies were identified that examined the effects of radiotherapy on immediate or delayed breast reconstructions. 9 studies were excluded from the meta-analysis due to **low numbers (e.g. n < 15) or incomplete data set regarding postoperative morbidity**. Of the 11 studies selected, 4 were studies that examined the effects of RT on immediate BR using implant or expanders. 4 were studies that examined the effects of RT on immediate BR using either a prosthesis or autologous flap. Finally 4 remaining studies evaluated the effects of RT on immediate versus delayed autologous BR. (See Consort flow of study selection (Figure 1)).

A total of 1,105 patients were identified from 11 selected studies [10, 11, 15, 22, 25-31]. These were subsequently divided into 3 cohorts for subgroup analyses. The first group (n = 424) were patients' with **immediate** BR using a prosthesis alone with/without RT. The second subgroup (n = 380) compared patients with **immediate** autologous BR versus prosthesis alone in the presence of RT. The last subgroup analysis (n = 301) compared the effects of RT on immediate versus delayed autologous BR.

Postoperative complications in BR in the presence of RT

Patients undergoing PMRT and **immediate** BR (n = 196) are more likely to suffer morbidity when compared to patients not receiving PMRT (n = 229) ((OR) = 4.2; 95% CI, 2.4-7.2(no PMRT vs. PMRT) see figure 2.). Finally reconstruction

technique was examined when PMRT was delivered after BR and this demonstrated that autologous reconstruction is the superior reconstruction technique **in terms of postoperative morbidity** ((OR) = 0.20; (95% CI, 0.1-0.4 (autologous vs. implant based) see figure 3). **Postoperative morbidity was defined in terms of capsular contracture, infection, fat necrosis, fibrosis and the necessity to re-operate on the patient. The rates of these complications are displayed in tables 2, 4 and 6.** Interestingly, the effect of delaying BR until after PMRT had no significant effect on outcome ((OR) =0.87; 95% CI, 0.47-1.62 (delayed vs. immediate) see figure 4.).

DISCUSSION:

The findings of this meta-analysis, that an immediate BR using a prosthesis only in the presence of RT is associated with an increased risk of postoperative complications ((OR) = 4.2; 95% CI, 2.4-7.2(no PMRT vs. PMRT)), is supported by Aschermann et al, who conducted a retrospective review of 104 patients (123 breasts) who underwent mastectomy followed by implant breast reconstruction and demonstrated that complications requiring prosthetic device removal or replacement, as well as total complications, were more frequent in breasts that received radiation than breasts that did not (18.5 percent versus 4.2 percent for complications requiring prosthetic removal or replacement, $p < \text{or} = 0.025$, and 40.7 percent versus 16.7 percent for total complications, $p < \text{or} = 0.01$) [32]. On analysis of table 1 and 2 below, it is apparent that patients with immediate implant based reconstructions, receiving radiotherapy have significantly greater incidences of complications, compared to those who did not receive radiotherapy.

Immediate breast reconstruction following a skin-sparing mastectomy has a number of advantages over the delayed reconstruction. Firstly, it provides a more enhanced aesthetic result due to preservation of the infra-mammary fold, allowing a more natural appearance and there is also the option to adjust the position of the scar [14]. More importantly for the patient, it provides enormous psychosocial benefits by restoring femininity and improving vitality, sexuality and quality of life [14]. In the absence of implants, immediate breast reconstruction

has a very favourable morbidity profile even when exposed to adjuvant radiotherapy [23]. Moreover, it is oncologically safe with an acceptable local recurrence rate [23]. Despite this, advocates of delayed breast reconstruction suggest that there are two main problems with immediate breast reconstruction in the presence of radiotherapy. Firstly, radiation therapy can adversely affect the cosmetic outcome and cause increased postoperative complications [33]. Secondly, immediate breast reconstruction can impair the efficacy and delivery of radiotherapy [33]. Autologous reconstructions have a more predictable response than implants to radiotherapy however the exact sequencing of this therapy is contentious. Kronowitz et al, suggested the concept of the delayed-immediate breast reconstruction as a potential solution [34]. This involves placing a tissue expander at the time of a skin-sparing mastectomy and waiting for the final pathological results of the specimen. If radiotherapy is not required, an immediate reconstruction is proposed and if radiotherapy is required, a delayed reconstruction is advised. Unfortunately, this requires two operations, which are associated with significant psychological and cost implications.

McKeown et al, demonstrated that patient satisfaction with cosmetic outcome was similar between patients undergoing immediate and delayed reconstruction (autologous LD) plus radiotherapy [35]. Interestingly, they also noted that most patients in retrospect would have preferred an immediate reconstruction [35]. In a prospective study by Thomson that assessed 73 women post immediate implant-assisted LD or autologous LD reconstruction with or without radiotherapy, there was no difference between the groups in terms of overall

cosmetic outcome as determined by the patients. When a panel of independent cosmetic assessors reviewed the photographic evidence at different intervals over a defined time period, they concluded that while radiotherapy had an adverse effect on aesthetic outcome ($p=0.0002$) this was more obvious in the implant-assisted LD group [12].

Kroll and colleagues, reviewed 1,384 free-flap procedures performed for reconstruction of the breast or of head and neck defects. They assessed the effects of prior irradiation of the recipient site on the incidence of total flap loss which were more common in flaps transferred to previously irradiated sites [36]. It is evident from this study (table 5 and 6) that exposure of an autologous flap to radiotherapy increases the postoperative complication rates irrespective of whether an immediate or delayed reconstruction is performed (30.1% versus 32.1% respectively).

The potential limitations of this study are that patient selection criteria for either prosthetic-based or autologous BR were poorly defined and may have differed between centers and time periods. There was also variation in the RT treatments used in terms of both dose and use of a boost. It is possible that the incidence of postoperative BR complication rates varies with the dose of RT used and this could not be assessed in our analysis.

Finally, in addition to selecting the appropriate timing of radiotherapy and reconstruction, appropriate patient selection is also paramount to consistently obtain successful outcomes. A BMI of less than 30 is associated with a better outcome in all reconstructive surgical procedures [37]. A history of smoking and

diabetes are also poor prognostic indicators for myocutaneous flap viability [38]. Patient selection for reconstruction was not stated in many of the studies involved in this meta-analysis and therefore could not be included.

Conclusion:

Post-mastectomy radiation, irrespective of the method of reconstruction, increases the incidence of postoperative complications however, this study has demonstrated that in this setting, an autologous flap offers a more favourable outcome in terms of morbidity than expander/implant reconstruction. There is a paucity of high quality conclusive data regarding the correct sequencing of breast reconstruction and radiotherapy. The majority of studies involve small numbers of patients in single centres with retrospective analysis. Multicenter randomised controlled trials with longer follow-up times and better specified parameters are necessary to validate any future strategies regarding the optimum timing of radiotherapy and breast reconstruction. Unfortunately, these studies are difficult to perform, as it is difficult to ethically justify demanding that patients undergo an immediate versus a delayed reconstructive procedure due to a randomisation process. Therefore, in the absence of level I evidence, the current data suggests that immediate breast reconstruction with PMRT may be undertaken though morbidity is higher with either immediate or delayed technique. The timing and effect of radiotherapy on breast reconstruction must be discussed to ensure informed opinion and consent of the patient. The patient's expectations, preferences, motivations as well as their level of understanding should be explored to enhance postoperative satisfaction and quality of life [39].

Figure 1. Quorum diagram: Consort flow of study selection.

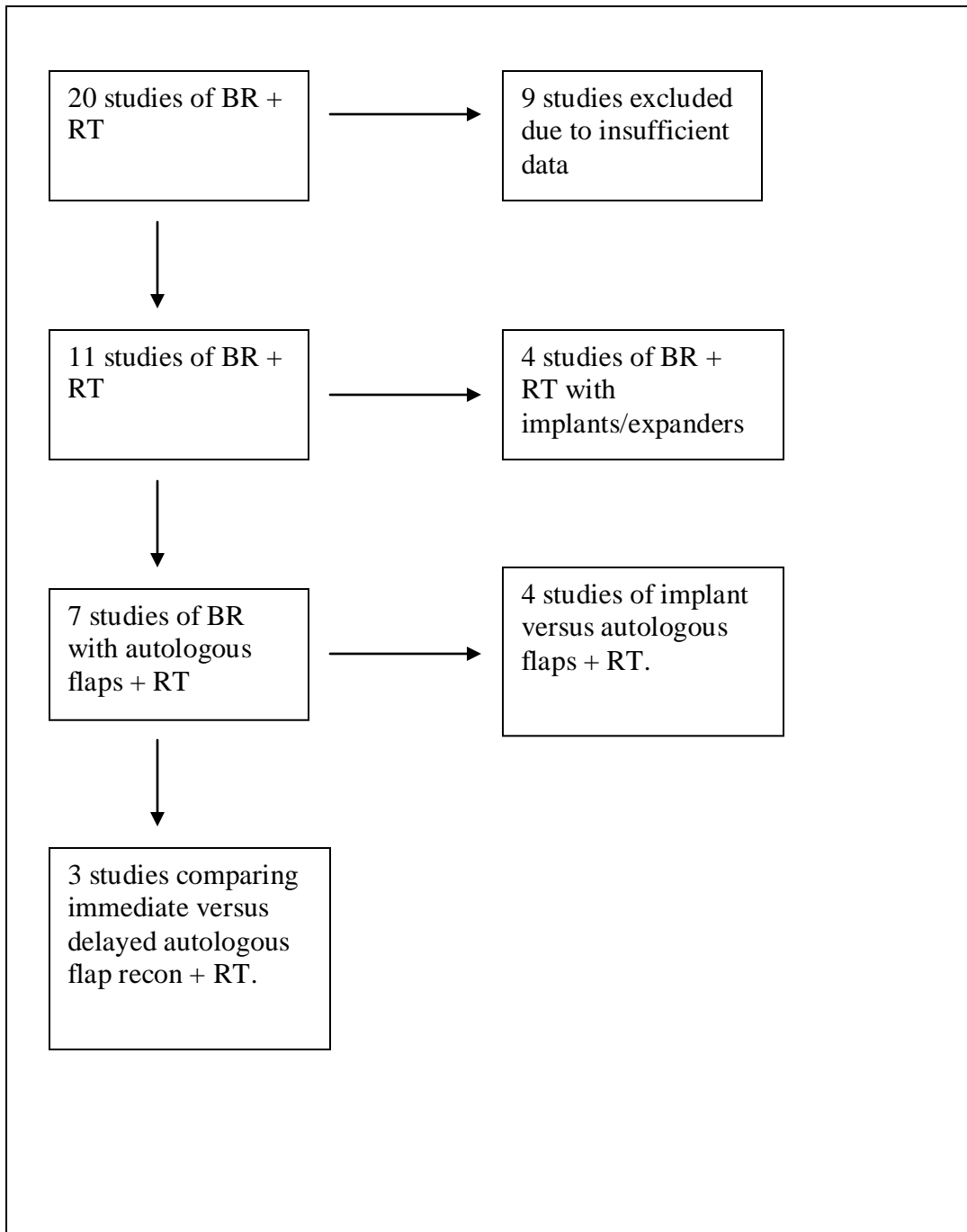


Table 1. Effect of radiotherapy on immediate implant/expander based breast reconstruction.

Author	TOR	Patient No.	MOR	Radiotherapy	Complications
Tallet [25]	Immediate	55	Implant	Yes	51%
	Immediate	22	Implant	No	14%
Krueger [26]	Immediate	19	Implant/Ex	Yes	68%
	Immediate	62	Implant/Ex	No	31%
Cordeiro [27]	Immediate	81	Implant/Ex	Yes	68%
	Immediate	75	Implant/Ex	No	40%
Whitfield [28]	Immediate	41	Implant	Yes	19.5%
	Immediate	69	Implant	No	0%
TOTAL	Immediate	196	Implant/Ex	Yes	51.6%
TOTAL	Immediate	228	Implant/Ex	No	21.2%

TOR = timing of reconstruction, MOR = Method of reconstruction, Ex = Expander, cc = capsular contraction.

Table 2: Postoperative complications in patients undergoing immediate breast reconstruction with an expander/implant with or without post-mastectomy radiotherapy.

Author	MOR	Patients	RT	CC %	Inf. %	Nec. %	Reop%
Tallet	E/I	55	Yes	29%	9%	12.7%	3.6%
[25]		22	No	0%	9%	0%	4.5%
Krueger	E/I	19	Yes	26%	37%	N/A	37%
[26]		62	No	10%	19%	N/A	8%
Cordeiro	E/I	81	Yes	1.2%	3.7%	N/A	5%
[27]		75	No	3.7%	0.9%	N/A	0.7%
Whitfield	E/I	41	Yes	19.5%	N/A	N/A	N/A
[28]		69	No	0%	N/A	N/A	N/A

MOR = Method of reconstruction, RT = Radiotherapy, CC = Capsular contracture, Inf = Infection, Nec = Necrosis, Re-op = Reoperation.

Figure 2: Meta-analysis of data comparing immediate BR using prosthesis only treated with RT.

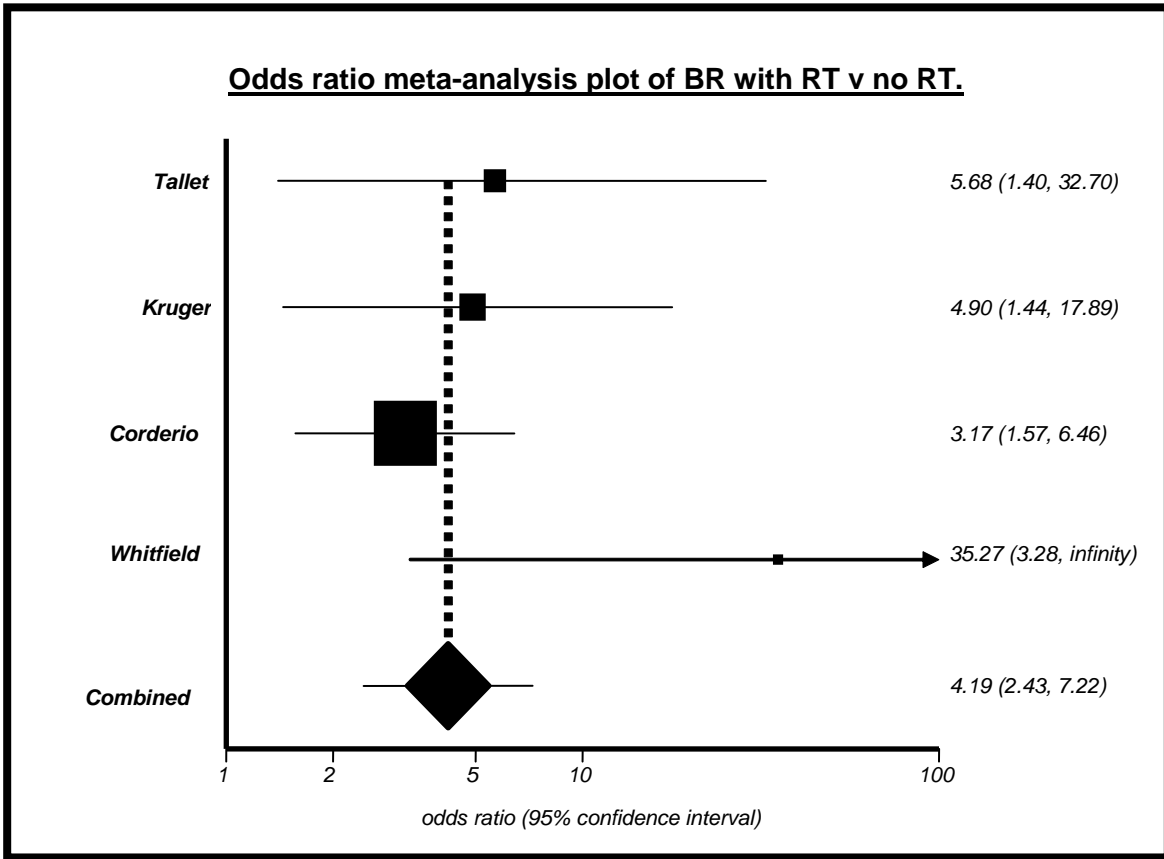


Table 3: Effect of radiotherapy on implant versus autologous breast reconstruction.

Author	TOR	Patient No	MOR	Radiation	Complications
Anderson [11]	Immediate	35	Autolog.	Yes	0%
	Immediate	50	Implant/Ex	Yes	5%
Jhaveri [29]	Immediate	23	Autolog.	Yes	8.7%
	Immediate	69	Implant	Yes	55%
Wong [10]	Immediate	47	Autolog	Yes	9%
	Immediate	15	Implant based	Yes	40%
Stralman [22]	Immediate	59	Autolog	Yes	13.5%
	Immediate	82	Implant	Yes	34%
TOTAL	Immediate	164	Autolog	Yes	7.8%
TOTAL	Immediate	216	Implant	Yes	33.5%

TOR = timing of reconstruction, MOR = Method of reconstruction, Ex = Expander, Autolog. = Autologous reconstruction.

Table 4: Postoperative complications in patients undergoing post-mastectomy radiotherapy with either immediate implant or immediate autologous breast reconstruction.

Author	N=	MOR	RT	CC.%	Inf.%	Fib %	FN%	Reop%
Anderson [11]	35	Autol	Yes	0%	0%	5.7%	17.2%	0%
	50	E/I	Yes	4%	4%	0%	0%	33%
Jhaveri [29]	23	Autol	Yes	0%	0%	N/A	N/A	0%
	69	E/I	Yes	42.9%	28.6%	N/A	N/A	20.3%
Wong [10]	47	Autol	Yes	0%	8.5%	N/A	N/A	21.3%
	15	E/I	Yes	40%	13.3%	N/A	N/A	66.6%
Stralman [22]	59	Autol	Yes	0%	N/A	N/A	N/A	13.5%
	82	E/I	Yes	17%	N/A	N/A	N/A	34.1%

N = Number of patients, MOR = Method of reconstruction, RT = Radiotherapy, CC = Capsular contracture, Inf = Infection, Fib = Fibrosis, FN = Fat necrosis, Reop = Re-operation.

Figure 3: Meta-analysis of data comparing immediate autologous versus prosthetic BR in the presence of postoperative RT.

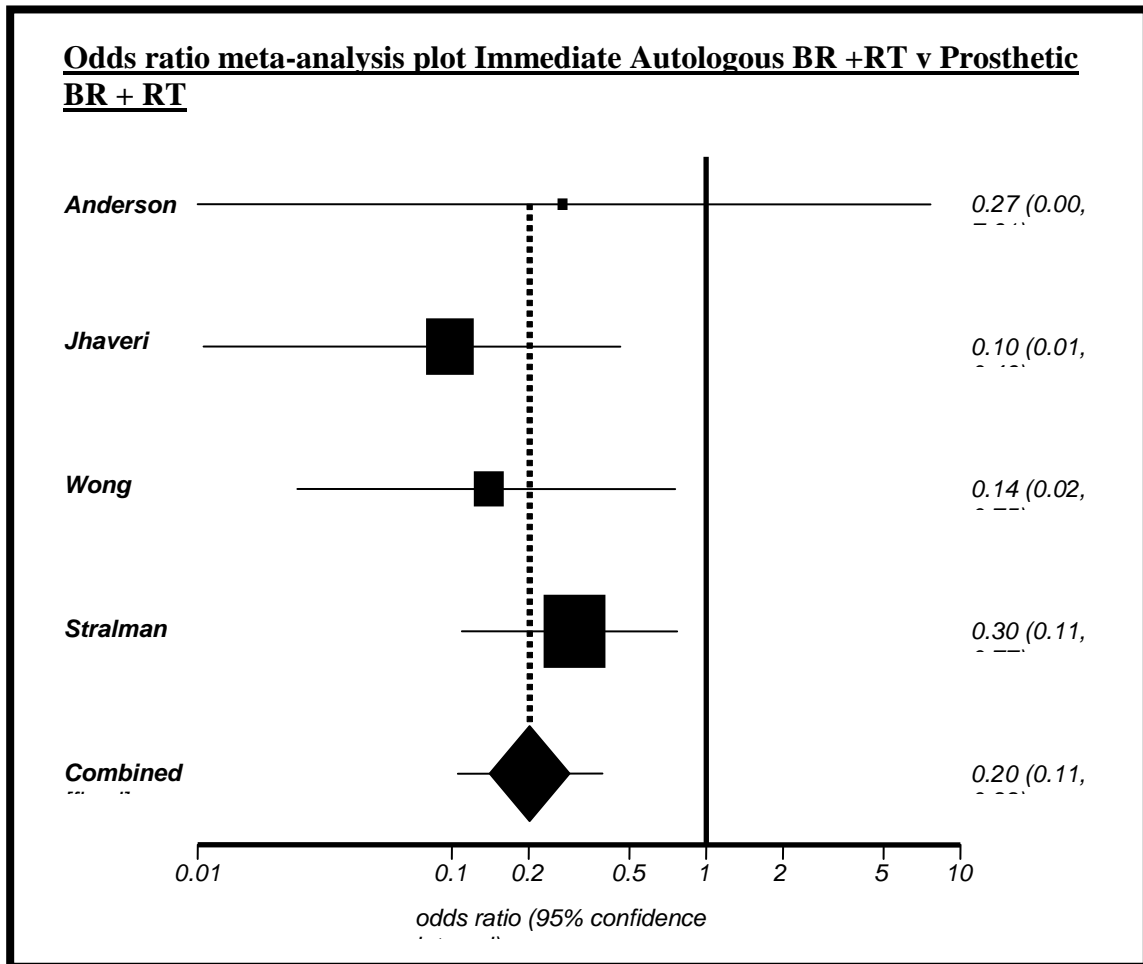


Table 5: Effects of radiotherapy on immediate and delayed autologous flaps.

Author	TOR	Patient No	MOR	Radiotx	Comp.
Williams [30]	Immediate	19	pTRAM	Yes	31%
	Delayed	108	pTRAM	Yes	25%
Tran [31]	Immediate	32	fTRAM	Yes	9.4%
	Delayed	70	fTRAM	Yes	14.3%
Spear [15]	Immediate	34	pTRAM	Yes	50%
	Delayed	38	pTRAM	Yes	57.1%
TOTAL	Immediate	85	TRAM	Yes	30.1%
TOTAL	Delayed	216	TRAM	Yes	32.1%

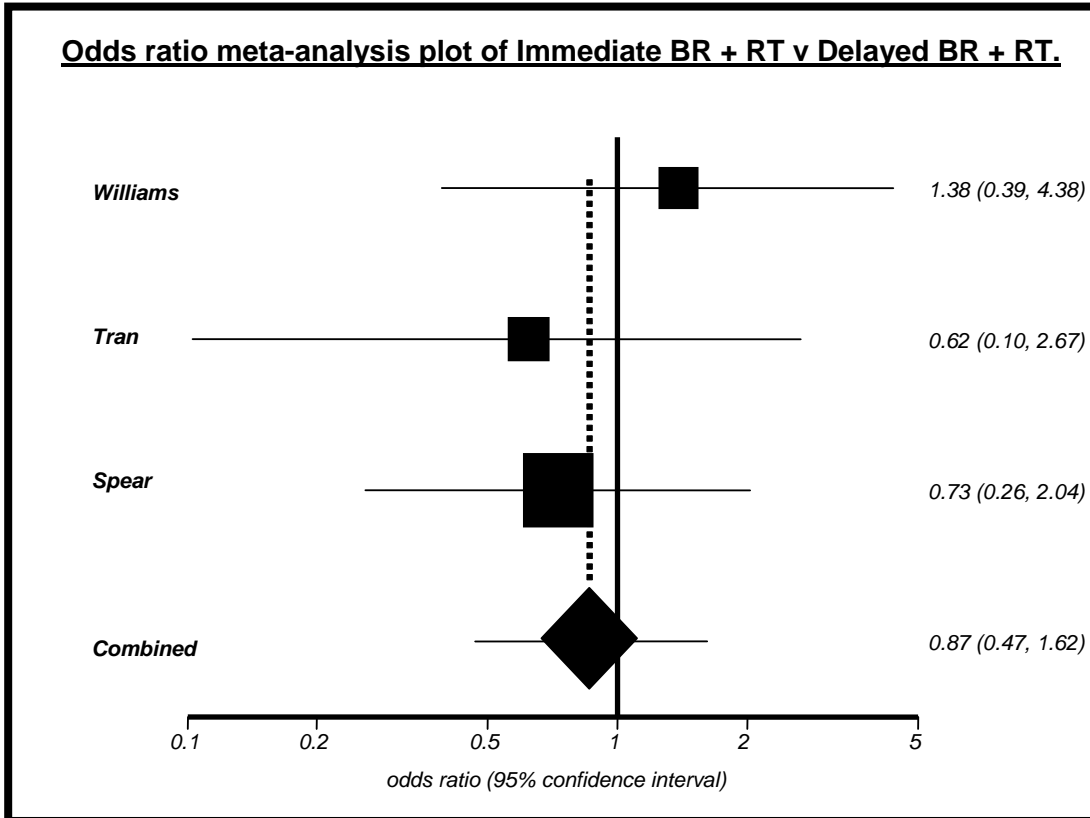
TOR = timing of reconstruction, MOR = Method of reconstruction, Radiotx = Radiotherapy, Comp = complications, pTRAM = pedicled TRAM, fTRAM = free TRAM.

Table 6: Postoperative complications in patients undergoing either immediate or delayed TRAM breast reconstruction with radiotherapy.

Author	TOR	Patients	RT	Fib	FN	Inf	Re-op
Williams [30]	Immed	19	Yes	10.5%	15.8%	5.3%	N/A
	Delay	108	Yes	0%	17.6%	6.6%	N/A
Tran [31]	Immed	32	Yes	75%	43.8%	N/A	9.4%
	Delay	70	Yes	0%	8.6%	N/A	0%
Spear [15]	Immed	34	Yes	N/A	23.7%	5.3%	0%
	Delay	38	Yes	N/A	23.8%	4.8%	2.4%

TOR = Type of reconstruction, RT = Radiotherapy, Fib = Fibrosis, FN = Fat necrosis, Inf = Infection, Re-op = Re-operation, Immed = Immediate reconstruction, Delay = Delayed reconstruction, N/A = Not available.

Figure 4. Meta-analysis of immediate versus delayed autologous breast reconstruction with combined radiotherapy.



References:

1. Fisher B, Anderson S, Bryant J, et al. Twenty-year follow-up of a randomized trial comparing total mastectomy, lumpectomy and lumpectomy plus irradiation for the treatment of invasive breast cancer. *N Eng J Med.* 2002;347:1233-1241.
2. Chevray PM. Timing of breast reconstruction: immediate versus delayed. *Cancer J.* 2008 Jul-Aug;14(4):223-9.
3. Meretoja TJ, von Smitten KA, Leidenius MH, Svarvar C, Heikkila PS, Jahkola TA. Local recurrence of stage 1 and 2 breast cancer after skin sparing mastectomy and immediate breast reconstruction in a 15 year series. *Eur J Surg Oncol.* 2007;33:1142-5.
4. Overgaard M, Hansen PS, Overgaard J, et al. Postoperative radiotherapy in high risk premenopausal women with breast cancer who receive adjuvant chemotherapy. *N Engl J Med.* 1997;337: 949-955.
5. Ragaz K, Jackson SM, Le N, et al. Adjuvant radiotherapy and chemotherapy in node positive premenopausal women with breast cancer. *N Engl J Med.* 1997;337: 956-962.

6. Recht A, Edge SB, Solin LJ, et al. Postmastectomy radiotherapy: clinical practice guidelines of the American Society of Clinical Oncology. *J Clin Oncol* 2001; 19: 1539-1569.
7. Harris JR, Halpin-Murphy P, McNeese M et al. Consensus Statement on postmastectomy radiation therapy. *Int J Radiat Oncol Biol Phys* 1999;44:989-990
8. Rutqvist LE, Rose C, Cavallin-Ståhl E. A systematic overview of radiation therapy effects in breast cancer. *Acta Oncol.* 2003;42(5-6):532-45.
9. Truong PT, Woodward WA, Bucholz TA, Optimizing locoregional control and survival for women with breast cancer: a review of current developments in postmastectomy radiation. *Expert Rev Anticancer Ther.* 2006; 6: 205-216.
10. Wong JS, Ho AY, Kaelin CM, Bishop KL, Silver B, Gelman R, Harris JR, Hergueter CA. Incidence of major corrective surgery after post-mastectomy breast reconstruction and radiation therapy. *Breast J.* 2008 Jan-Feb;14(1):49-54.
11. Anderson PR, Hanlon AL, Fowble BL, McNeeley SW, Freedman GM. Low complication rates are achievable after postmastectomy breast reconstruction and radiation therapy. *Int J Radiat Oncol Biol Phys.* 2004 Jul 15;59(4):1080-7.

12. Thomson HJ, Potter S, Greenwood RJ, Bahl A, Barker J, Cawthorn SJ, Winters ZE. A prospective longitudinal study of cosmetic outcome in immediate latissimus dorsi breast reconstruction and the influence of radiotherapy. *Ann Surg Oncol*. 2008 Apr;15(4):1081-91. Epub 2008 Jan 26.
13. Miller MJ, Rock CS, Robb GL. Aesthetic breast reconstruction using a combination of free transverse rectus abdominis musculocutaneous flaps and breast implants. *Ann Plast Surg*. 1996 Sep;37(3):258-64.
14. Kroll SS, Marchi M. Immediate reconstruction: Current status in cancer management. *Tex Med* 1991;87: 67-72.
15. Spear SL, Ducic I, Low M, Cuoco F. The effect of radiation on pedicled TRAM flap breast reconstruction: outcomes and implications. *Plast Reconstr Surg*. 2005 Jan;115(1):84-95.
16. Dean C, Chetty U, Forrest AP. Effects of immediate breast reconstruction on psychosocial morbidity after mastectomy. *Lancet* 1983; 1: 459-62.
17. Bloomer WD, Hellman S. Normal tissue responses to radiation therapy. *N Engl J Med* 1975; 293:80-83.

18. Fajardo LF, Berthrong M. Radiation injury in surgical pathology: part I. *Am J Surg Pathol* 1978; 2:159-199.
19. Fajardo LF. Morphologic patterns of radiation injury. *Front Radiat Ther Oncol* 1989; 23:75-84.
20. Kronowitz SJ, Robb GL. Breast reconstruction with postmastectomy radiation therapy: current issues. *Plast Reconstr Surg.* 2004 Sep 15;114(4):950-60.
21. Buchholz TA, Kronowitz SJ, Kuerer HM. Immediate breast reconstruction after skin-sparing mastectomy for treatment of advanced breast cancer: radiation oncology considerations. *Ann Surg Oncol.* 2002; 9: 820-821.
22. Strålman K, Mollerup CL, Kristoffersen US, Elberg JJ. Long-term outcome after mastectomy with immediate breast reconstruction. *Acta Oncol.* 2008;47(4):704-8.
23. Huang CJ, Hou MF, Lin SD et al. Comparison of local recurrence and distant metastases between breast cancer patients after postmastectomy radiotherapy with and without immediate TRAM flap reconstruction. *Plast Reconstr Surg.* 2006;118(5): 1079-86.

24. Lau J, Ioannidis JP, Schmid CH. Quantitative synthesis in systematic reviews. *Ann Intern Med.* 127: 820-826, 1997.

25. Tallet AV, Salem N, Moutardier V, et al. Radiotherapy and immediate two stage breast reconstruction with a tissue expander and implant: complications and aesthetic results. *Int J Radiat Oncol Biol Phys.* 2003. 1;57(1) : 136-42.

26. Krueger EA, Wilkins EG, Strawderman M, et al. Complications and patient satisfaction following expander/implant breast reconstruction with and without radiotherapy. *Int J Radiat Oncol Biol Phys* 2001. 1;49(3) :713-21.

27. Cordeiro PG, Pusic AL, Disa JJ, et al. Irradiation after immediate tissue expander/implant breast reconstruction: outcomes, complications, aesthetic results, and satisfaction among 156 patients. *Plast Reconstr Surg* 2004. 113(3) : 877-81.

28. Whitfield GA, Horan G, Irwin MS, et al. Incidence of severe capsular contracture following implant-based immediate breast reconstruction with or without postoperative chest wall radiotherapy using 40 Gray in 15 fractions. *Radiother Oncol* 2009. 90;141-147.

29. Jhaveri JD, Rush SC, Kostroff K, Derisi D, Farber LA, Maurer VE, Bosworth JL. Clinical outcomes of postmastectomy radiation therapy after immediate breast reconstruction. *Int J Radiat Oncol Biol Phys*. 2008 Nov 1;72(3):859-65.
30. Williams JK, Carlson GW, Bostwick J 3rd, Bried JT, Trimble J, Mackay G. The effects of radiation treatment after TRAM flap breast reconstruction. *Plast Reconstr Surg* 1997. Oct 100(5); 1153-1160.
31. Tran NV, Chang DW, Gupta A, Kroll SS, Robb GL. Comparison of immediate and delayed free TRAM flap breast reconstruction in patients receiving postmastectomy radiation therapy. *Plast Reconstr Surg*. 2001 Jul;108(1):78-82.
32. Ascherman JA, Hanasono MM, Newman MI, Hughes DB. Implant reconstruction in breast cancer patients treated with radiation therapy. *Plast Reconstr Surg*. 2006 Feb;117(2):359-65.
33. Motwani SB, Strom EA, Schechter NR, Butler CE, Lee GK, Langstein HN, Kronowitz, SJ, Meric-Bernstam F, Ibrahim NK, Buchholz TA. The impact of immediate breast reconstruction on the technical delivery of postmastectomy radiotherapy. *Int J Radiat Oncol Biol Phys*. 2006 Sep 1;66(1):76-82.

34. Kronowitz SJ, Hunt KK, Kuerer HM, Babiera G, McNeese MD, Buchholz TA, Strom EA, Robb GL. Delayed-immediate breast reconstruction. *Plast Reconstr Surg*. 2004 May;113(6):1617-28.

35. McKeown DJ, Hogg FJ, Brown IM, Walker MJ, Scott JR, Weiler-Mithoff The timing of autologous latissimus dorsi breast reconstruction and effect of radiotherapy on outcome. *J Plast Reconstr Aesthet Surg*. 2008 Feb 7.

36. Kroll SS, Robb GL, Reece GP, Miller MJ, Evans GR, Baldwin BJ, Wang B, Schusterman MA. Does prior irradiation increase the risk of total or partial free-flap loss? *J Reconstr Microsurg*. 1998 May;14(4):263-8.

37. Chang DW, Wang B, Robb GL, et al. Effect of obesity on flap and donor site complications in free transverse rectus abdominis myocutaneous flap breast reconstruction. *Plast Reconstr Surg*. 2000; 105: 1640-1648.

38. Chang DW, Reece GP, Wang B. Effect of smoking on complications in patients undergoing free TRAM flap breast reconstruction. *Plast Reconstr Surg* 2000;105:2374-2380.

39. Saulis AS, Mustoe TA, Fine NA. A retrospective analysis of patient satisfaction with immediate postmastectomy breast reconstruction: comparison of three common procedures. *Plast Reconstr Surg* 2007;119: 1669-78.