HAL
open science

A kidney transplant patient with pure red cell aplasia: first things first!

Dries Deeren

To cite this version:

Dries Deeren. A kidney transplant patient with pure red cell aplasia: first things first!. Annals of Hematology, 2010, 90 (8), pp.991-992. 10.1007/s00277-010-1126-7 . hal-00615411

HAL Id: hal-00615411

https://hal.science/hal-00615411

Submitted on 19 Aug 2011

HAL is a multi-disciplinary open access archive for the deposit and dissemination of scientific research documents, whether they are published or not. The documents may come from teaching and research institutions in France or abroad, or from public or private research centers.

L'archive ouverte pluridisciplinaire **HAL**, est destinée au dépôt et à la diffusion de documents scientifiques de niveau recherche, publiés ou non, émanant des établissements d'enseignement et de recherche français ou étrangers, des laboratoires publics ou privés.

Title page

A kidney transplant patient with pure red cell aplasia: first things first!

Dries Deeren, MD

Department of Hematology

H.-Hartziekenhuis Roeselare-Menen vzw

Wilgenstraat 2

B-8800 Roeselare

Belgium

E-mail: ddeeren@hhr.be

Telephone: +32 51 237437

Fax: +32 51 237931

Running title: allopurinol-induced PRCA

Abstract page

No abstract required.

Keywords:

Allopurinol

Kidney failure, chronic

Kidney transplantation

Red-cell aplasia, pure

Letter to the Editor

Acquired pure red cell aplasia (PRCA) is a rare cause of anemia characterized by the virtual absence of erythroid precursors in the bone marrow. The other cell lineages are normal. Adult acquired PRCA is most often idiopathic, although an underlying cause can be found in some patients. Large granular lymphocyte leukemia, myelodysplasia, thymoma, chronic lymphocytic leukemia, allogeneic stem cell transplantation, anti-erythropoietin antibodies secondary to treatment with recombinant human erythropoietin, drugs, viral infections and autoimmune diseases have all been associated with PRCA [1].

One of the most important aspects of initial management is the cessation of possible offending drugs, although only a minority of patients will respond to this approach alone. However, when PRCA is diagnosed in a kidney transplant patient, several of the possible causes may seem more likely, and this vital step in the treatment is forgotten.

In April 2010 a 53-year-old kidney transplant patient was referred because of anaemia, not responsive to darbepoietin. Darbepoietin was started because of this anaemia. The hemoglobin had been decreasing for more than one year, and had reached 6.5 g/dL. The rest of the blood count was unremarkable. The creatinine level was stable at 2.2 mg/dL. There were no signs of haemolysis nor bleeding, and upper and lower gastrointestinal endoscopy revealed no abnormalities. There was no reticulocytosis, vitamin or iron deficiency. Bone marrow examination showed as the only abnormality the absence of red cell precursors, compatible with PRCA.

An evaluation for the classical causes of PRCA was negative, except for one iatrogenic cause. The patient had been taking allopurinol at the relatively high dose of 300 mg/day - considering the kidney function - for several years before the hemoglobin level started to decrease. Allopurinol was stopped immediately and packed cells were transfused. Very soon, many reticulocytes were released in the peripheral blood and the hemoglobin level

rose (Fig 1). Allopurinol was never reintroduced. Five months later, the hemoglobin level stays normal, and there have been no other health problems.

Although there are reports on allopurinol-induced PRCA [2-4], this cause of PRCA is relatively unknown. This case illustrates that simple causes have to be ruled out first, even in complex patients after kidney transplantation. There is no standard treatment for PRCA except for red cell transfusions, although several drugs have been reported to be effective in selected cases [1]. Cessation of the offending drug is not only of critical importance, but also the easiest, least expensive and one of the few evidence based treatment options.

This case also demonstrated that the indication and dosage adjustment should be carefully evaluated before starting allopurinol therapy in patients with chronic kidney disease.

References

1. Fisch P, Handgretinger R, Schaefer HE (2000) Pure red cell aplasia. Br J Haematol 111:1010-22.

2. Chao SC, Yang CC, Lee JY (2005) Hypersensitivity syndrome and pure red cell aplasia following allopurinol therapy in a patient with chronic kidney disease. Ann Pharmacother 39:1552-6.

3. Lin YW, Okazaki S, Hamahata K, Watanabe K, Usami I, Yoshibayashi M, et al (1999) Acute pure red cell aplasia associated with allopurinol therapy. Am J Hematol 61:209-11.

4. Shankar P, Aish L, Hassoun H (2003) Allopurinol-induced pure red cell aplasia. Am J Hematol 73:69.

Figures

Figure legends

Figure 1

Evolution of the hemoglobin level from December 1st until June 1st 2010. The last dose of allopurinol was taken on April 7th 2010.

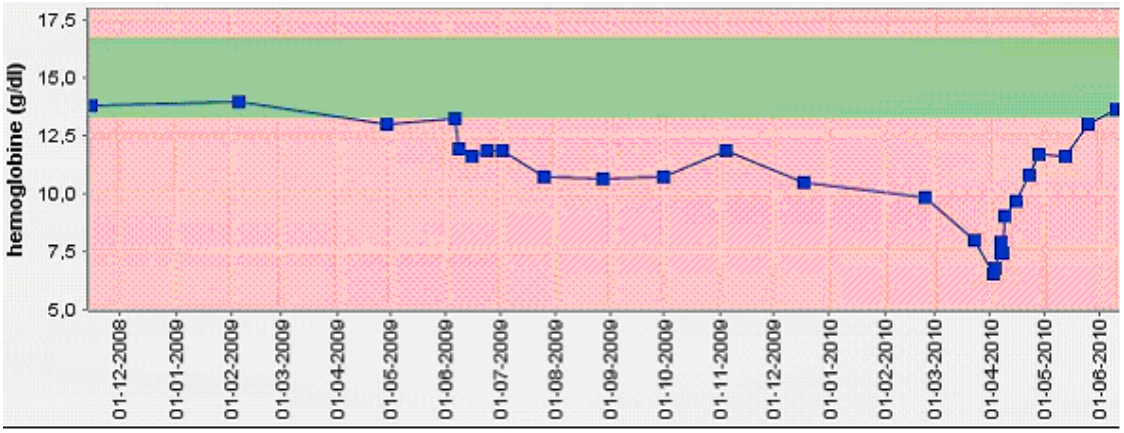
hemoglobine (g/dl)
17,5
15,0
12,5
10,0
7,5
5,0
01-12-2008
01-01-2009
01-02-2009
01-03-2009
01-04-2009
01-05-2009
01-06-2009
01-07-2009
01-08-2009
01-09-2009
01-10-2009
01-11-2009
01-12-2009
01-01-2010
01-02-2010
01-03-2010
01-04-2010
01-05-2010
01-06-2010