



Novel mutations in TTC37 associated with Tricho-Hepato-Enteric syndrome

Alexandre Fabre, Christine Martinez-Vinson, Bertrand Roquelaure, Chantal Missirian, Nicolas Andre, Anne Breton, Alain Lachaux, Odul Egritas, Virginie Colomb, Julie Lemale, et al.

► To cite this version:

Alexandre Fabre, Christine Martinez-Vinson, Bertrand Roquelaure, Chantal Missirian, Nicolas Andre, et al.. Novel mutations in TTC37 associated with Tricho-Hepato-Enteric syndrome. *Human Mutation*, 2011, 32 (3), pp.277. 10.1002/humu.21420 . hal-00614846

HAL Id: hal-00614846

<https://hal.science/hal-00614846>

Submitted on 17 Aug 2011

HAL is a multi-disciplinary open access archive for the deposit and dissemination of scientific research documents, whether they are published or not. The documents may come from teaching and research institutions in France or abroad, or from public or private research centers.

L'archive ouverte pluridisciplinaire **HAL**, est destinée au dépôt et à la diffusion de documents scientifiques de niveau recherche, publiés ou non, émanant des établissements d'enseignement et de recherche français ou étrangers, des laboratoires publics ou privés.



Novel mutations in TTC37 associated with Tricho-Hepato-Enteric syndrome



Journal:	<i>Human Mutation</i>
Manuscript ID:	humu-2010-0401.R1
Wiley - Manuscript type:	Research Article
Date Submitted by the Author:	04-Oct-2010
Complete List of Authors:	<p>Fabre, Alexandre; Hôpital d'enfants de la Timone, Service de Pédiatrie Multidisciplinaire</p> <p>Martinez-Vinson, Christine; Hôpital Robert Debré, Centre de Référence pour les Maladies Digestives Rares de l'enfant, APHP,, Gastroentérologie et Nutrition Pédiatrique</p> <p>Roquelaure, Bertrand; hôpital d'enfants de la Timone, Service de pédiatrie multidisciplinaire</p> <p>Missirian, Chantal; Hôpital d'enfants de la Timone, Laboratoire de Cytogénétique</p> <p>Andre, Nicolas; Hôpital d'enfants de la Timone, Service d'oncologie pédiatrique</p> <p>Breton, Anne; Hôpital des Enfants, Gastro-entérologie, Hépatologie, Nutrition, Diabétologie</p> <p>Lachaux, Alain; hôpital Femme-Mère-Enfant du CHU de Lyon, Hepatologie Gastroentérologie et Nutrition</p> <p>Egritas, Odul; Gazi University School of Medicine, Department of Pediatric Gastroenterology</p> <p>Colomb, Virginie; Hôpital Necker-Enfants Malades, Centre de Référence pour les Maladies Digestives Rares de l'enfant, APHP, Gastroentérologie et Nutrition Pédiatrique</p> <p>Lemale, Julie; Hôpital Armand Trousseau, APHP, Gastroentérologie et Nutrition Pédiatrique</p> <p>Cezard, Jean-Pierre; Hôpital Robert Debré, Centre de Référence pour les Maladies Digestives Rares de l'enfant, APHP, Gastroentérologie et Nutrition Pédiatrique</p> <p>Goulet, Olivier; Hôpital Necker-Enfants Malades, Centre de Référence pour les Maladies Digestives Rares de l'enfant, APHP, Gastroentérologie et Nutrition Pédiatrique</p> <p>Sarles, Jacques; hôpital d'enfants de la Timone, Service de pédiatrie multidisciplinaire</p> <p>Levy, Nicolas; UMR 910, Faculté de médecine, université de la Méditerranée</p> <p>Badens, Catherine; UMR 910, Faculté de Médecine, Université de la Méditerranée</p>

1
2
3
4
5
6
7
8
9
10
11
12
13
14
15
16
17
18
19
20
21
22
23
24
25
26
27
28
29
30
31
32
33
34
35
36
37
38
39
40
41
42
43
44
45
46
47
48
49
50
51
52
53
54
55
56
57
58
59
60

Key Words:	Syndromic diarrhea, Tricho-hepato-enteric syndrome, TTC37, intractable diarrhea, Woolly hair, Thespin, Stankler syndrome

SCHOLARONE™
Manuscripts

For Peer Review

Novel mutations in *TTC37* associated with Tricho-Hepato-Enteric syndrome

Alexandre Fabre^{1,2}, Christine Martinez-Vinson³, Bertrand Roquelaure¹, Chantal Missirian⁴,
Nicolas André⁵, Anne Breton⁶, Alain Lachaux⁷, Egritas Odul⁸, Virginie Colomb⁹, Julie
Lemale¹⁰, Jean-Pierre Cézard³, Olivier Goulet⁹, Jacques Sarles¹, Nicolas Levy^{2,11}, Catherine
Badens^{2,11}.

1 Service de Pédiatrie Multidisciplinaire, 2 Laboratoire de Génétique Moléculaire, Hôpital
d'enfants de la Timone, Marseille, 3 Service de Gastro-entérologie, Hôpital Robert Debré,
Paris, 4 Laboratoire de cytogénétique, Hôpital d'enfants de la Timone, Marseille, 5 Service de
Pédiatrie Oncologique, Hôpital d'enfants de la Timone, Marseille, 6 Service d'Hépatologie et
Maladies Métaboliques, Hôpital d'enfant de Toulouse, 7 Unité Fonctionnelle de Nutrition,
Hôpital Femme Mère Enfant de Lyon, 8 Gazi University School of Medicine, Department of
Pediatric Gastroenterology, Ankara, Turkey, 9 Service de Gastro-entérologie, Hôpital Necker-
Enfants Malades, Paris, 10 Gastroentérologie et Nutrition Pédiatrique, Hôpital Armand
Trousseau, Paris, 11 Unité Inserm U910, Faculté de Médecine, Université de la Méditerranée,
Marseille, France.

Key words: Syndromic Diarrhea, Intractable diarrhea, Tricho-Hepato-Enteric syndrome,
Stankler syndrome, *TTC37*, woolly hair,

Corresponding author :

Dr Catherine Badens
Laboratoire de Génétique moléculaire
Département de Génétique
Hôpital de la Timone
13385 Marseille cedex 5
France

1
2
3
4
5
6
7
8
9
10
11
12
13
14
15
16
17
18
19
20
21
22
23
24
25
26
27
28
29
30
31
32
33
34
35
36
37
38
39
40
41
42
43
44
45
46
47
48
49
50
51
52
53
54
55
56
57
58
59
60

Abstract

The Tricho-Hepato-Enteric (THE) syndrome is an autosomal recessive condition marked by early and intractable diarrhea, hair abnormalities and immune defects. Mutations in *TTC37* which encodes the putative protein Thespin, have recently been associated with THE syndrome. In this paper, we extend the pattern of *TTC37* mutations by the description of 11 novel mutations in 9 patients with a typical THE syndrome. The mutations were spread along the gene sequence, none of them being recurrent. Different types of mutation were observed: frameshift mutations, splice site altering mutations or missense mutations, most of them leading to the creation of a premature stop codon. Concurrently, we investigated the pattern of *TTC37* expression in a panel of normal human tissues and showed that this gene is widely expressed, with high levels in vascular tissues, lymph node, pituitary, lung and intestine. In contrast, *TTC37* is not expressed in the liver, an organ which is not consistently affected in THE syndrome. Lastly, we suggested a model for the putative structure of the unknown Thespin protein.

Introduction

The Tricho-Hepato-Enteric syndrome (THE syndrome, OMIM n°222470) also known as Syndromic Diarrhea, is a rare and severe autosomal recessive condition which associates intractable diarrhea with facial dysmorphism, intrauterine growth retardation, immunodeficiency with low serum concentrations of immunoglobulins, and hair abnormalities characterized by woolly hair (Girault et al., 1994; Verloes et al., 1997). Parenteral nutrition is usually started in the first weeks of life and maintained all life long in most cases. The liver failure is inconstant and when present, it is observed initially or later on in life. In the past, the presence or absence of liver failure led one to describe 2 different syndromes but it is now admitted that the 2 entities represent 2 sides of the same disease (Fabre et al, 2007, Goulet et al, 2008). Death can occur early in life even though some patients can reach the third decade.

In the past few years, we collected samples for 12 patients from 11 families, all presenting a typical phenotype of THE syndrome. We first excluded several functional candidate genes (Fabre et al, 2009) and then performed a linkage analysis in order to unravel the genetic basis of this syndrome. In 2 of the 3 consanguineous families, homozygosity mapping identified a 5Mb region in 5q as a potential locus for the disease.

Very recently, Hartley et al described molecular defects causative for THE syndrome in *TTC37* (NM_014639), a gene encoding for a putative protein named Thespin. Their study reported 9 mutations transmitted in a recessive pattern in 12 patients presenting this syndrome.

Since *TTC37* maps in 5q, we assumed that this gene may be responsible for the disease in some of our patients and so performed systematic sequencing of genomic DNA samples. In this paper, we describe 11 novel *TTC37* mutations in 9 patients out of 12 and provide clinical

data for mutated and non mutated patients together with normal patterns of *TTC 37* expression in several tissues.

Material and methods:

Patients

Patients and family members were assessed under approved human subject protocols and all participants provided informed consent.

Molecular studies

DNA was isolated from blood via a standard manufacturer’s protocol (QIAamp DNA blood minikit, QIAgen). To analyse the *TTC37* gene, direct sequencing was performed, after PCR amplification of the 43 exons and intronic flanking sequences, on an ABI 3130XL (Applied Biosystems).

The *TTC37* genomic sequence from GenBank accession numbers NM_014639 was used as reference sequence. Detailed protocols and primer sequences are available on request. Two non-mutated patients and one heterozygous were tested by CGH array using the commercial Agilent 2x400K SurePrint G3 Human CGH Microarray (Agilent Technologies) array with the overall median probe spacing of 5,3 kb. Total RNA from 3 patient samples was prepared from lymphoblastoid cells and reverse transcribed using M-MLV (Sygma). Normal expression pattern was investigated by qPCR on a panel of normal transcripts from various tissues (Rapid-Scan cDNA panel, OriGene) using a probe located on exon-intron junction 35-36 of *TTC37* and compared to *GAPDH* expression in duplex reactions. qPCR were done in triplicates and 2 sets of experiments were performed.

Bioinformatics analysis

The topology of normal and mutated Thespin protein was analysed using the algorithms proposed at TMPred (http://www.ch.embnet.org/software/TMPRED_form.html), TOPPRED

(<http://www.mobyle.pasteur.fr/cgi-bin/portal.py?form=Toppred>), PSORT II (<http://psort.ims.u-tokyo.ac.jp>) and SMART (http://smart.embl.de/smart/show_motifs.pl) Predicted effects of missense mutations were obtained on Polyphen website (<http://genetics.bwh.harvard.edu/pph>).

Results

Patients phenotype

The clinical features of the 12 patients are summarised in table 1. Detailed clinical data were previously published for 3 of them (Fabre et al, 2007, Egritas et al 2010). All the 12 patients presented the 3 major signs of THE syndrome i.e. dysmorphism, hair abnormalities and intractable diarrhea. Among the 12 patients, one died of septicemia at age 10, 2 have stopped parenteral nutrition and 1 never required it.

Identification and characterization of novel TTC37 mutations in THE patients

Screening for mutations of *TTC37* coding sequence and intron-exon junctions of DNA samples from THE patients identified 10 novel non ambiguous mutations in homozygous or compound heterozygous condition, in 8 (out of 12) patients. In addition, one patient presented only a heterozygous missense mutation. The mutations were spread along the gene: 3 were nonsense or frameshift mutations in the coding sequence leading to premature stop codon, 5 were mutations affecting splice sites either by substitution or deletion and 3 were missense mutations. All the parents of mutated patients were investigated and carried a mutation in heterozygous condition. The location and predicted consequences of the mutations on protein expression or function are reported in table 2.

Two of the 3 patients without mutation and the one with a single heterozygous mutation were investigated by whole genome CGH array with 17 probes mapping in TTC37. No CNV of the *TTC37* region or of other regions could be identified.

The effects of splice sites mutations on sequence transcripts were analysed by direct sequencing of RNA transcripts from lymphoblastoid cells, for 3 patients. The tested samples exhibited abnormal sequence due to the modification of splicing: skipping exon 23 in the case of the c.2515+1 C>G mutation, leading to a frameshift and creation of a premature stop codon (figure 1a); skipping exon 25 in the case of the c.2577-3_-7delTTTT, leading to the deletion of 19 amino-acids in frame (figure 1b); cryptic splice activation in exon 42 in case of the c.4620+1 G>C mutation promoting an alternative splicing and the replacement of the 41 terminal amino-acids by 61 others.

Pattern of expression

Quantitative expression in normal tissues was assessed in a panel of 48 different tissues and revealed that *TTC37* is widely expressed with the highest levels observed in vascular tissues, lymph node, pituitary, lung and intestine. Noticeably, we did not find any expression in the liver (figure 2).

Bioinformatics

In silico protein predictions were performed to propose a putative structure for Thespin and to evaluate the potential effect of *TTC37* mutations identified in this study. The algorithm results are in accordance to predict that Thespin is mostly cytosolic and may contain 4 transmembrane domains (Figure 3). With all algorithms used in this study, several tetratricopeptide repeats (TPR) domains are predicted and their number varies from 5 to 22.

Discussion

Mutations previously identified in THE syndrome are heterogeneous and include frameshift, nonsense and splice site mutations. Here, we describe further 11 different mutations that add heterogeneity to the molecular genetics of THE syndrome (figure 3). These 11 novel mutations, in addition to the 9 mutations previously described, indicate strongly that *TTC37* is the main gene responsible for THE syndrome. There is no clear hot spot region for mutations

even though, in 70% of the mutated alleles (Hartley et al 2010 and our study), the mutation is localised in the 3' half of the gene. Most of the mutations are nonsense, frameshift or splice mutations that are predicted to produce premature stop codon. At least, 2 of the 3 missense mutations might affect splicing as well, as they are located in the vicinity of splice sites. For one of the patients, a single missense mutation in heterozygous condition has been identified to date. As we exclude the presence of an intragenic deletion or duplication on the other allele, we assume that a non-identified intronic substitution producing an aberrant splicing is probably associated with the missense mutation.

The phenotypes of the 3 patients who did not carry any mutation in *TTC37* have been carefully re-evaluated and were confirmed as being typical THE syndrome, suggesting strongly that at least one other gene may be implicated in this disease.

Multi-tissue transcript expression analysis showed wide expression of *TTC37* mRNA with a high expression level in intestinal tissue but not in the liver, indicating that liver dysfunction observed in THE syndrome is probably secondary to another genetic cause or to long term parenteral nutrition. More surprising is the high level of expression observed in vein, arteria and lung as no abnormalities have been noticed in these tissues.

Up to date, the function of Thespin is unknown. We identified orthologs of human *TTC37* using HomoloGene (www.ncbi.nlm.nih.gov/homologene) and found a nucleotide sequence conservation in canis (92%), bos (92%), rattus (83%), mus (82%), gallus (66%), danio (55%) and drosophila (27%) in favour of an essential role for Thespin.

Protein motifs and domains are predicted in Thespin by several algorithms such as TMPred, PSORT and TOPPRED. Four transmembrane domains located in the C-terminal half of the protein are predicted, the last one in the C-terminal part being predicted with a stronger score. The putative protein also contains several tetratricopeptide repeats (TPR) domains which are structural motifs consisting of 34 Amino acid residues and found in over 300 human proteins

1
2
3
4
5
6
7
8
9
10
11
12
13
14
15
16
17
18
19
20
21
22
23
24
25
26
27
28
29
30
31
32
33
34
35
36
37
38
39
40
41
42
43
44
45
46
47
48
49
50
51
52
53
54
55
56
57
58
59
60

(D'andrea et al, 2003). Despite the fact that the amino-acids are poorly conserved, these motifs assemble into a characteristic Helix-Turn-Helix structure. The basic function of these TPR motifs is to mediate protein-protein interactions and therefore, can be involved in a variety of biological process such as cell-cycle regulation, transcriptional control, protein transport or folding. Consequently, no hint is given by the presence of TPR domains regarding a specific function. Interestingly, one of the splice site mutations of this series leads to a deletion of 19 residues in frame, following the skipping of exon 25. This deletion does not modify the predicted transmembrane domains but deleted several putative TPR domains of the C-terminal part, suggesting a major functional role for these structures.

Beside the TPR domains, neither the gene nor its derived protein show any significant sequence similarity to other known human DNA or protein sequences. In the literature, mutations in other TPRs containing proteins have been described as causative in several neurological human diseases such as Leber congenital amaurosis (Sohocki et al, 2000) or CMT type 4C (Senderek et al, 2003) but no clear link can be made between these proteins and their putative function.

Collectively, our results confirmed the role of *TTC37* in THE syndrome, extended the pattern of mutations associated with this syndrome and provided new data on the normal expression pattern of *TTC37* and the putative structure of Thespin. Assigning an unknown protein to a specific disease as done for THE syndrome, may enable one to describe new protein functions and will lead surely to characterize the localisation and functional properties of Thespin.

Acknowledgements

We are grateful to the patients and family members for their participation in the study and warmly acknowledge Patrice Bourgeois, Pierre Cau and Claudine Schiff for their helpful discussion, Benedicte Arnaud-Pigneur and Noël Peretti for providing patient samples. This work was supported by the Assistance Publique-Hôpitaux de Marseille (AORC 2009).

References

- D'Andrea LD, Regan L. 2003. TPR proteins: the versatile helix. *Trends Biochem Sci.* 28(12):655-62.
- Egritas O, Dalgic B, Onder M Tricho-hepato-enteric syndrome presenting with mild colitis. 2009 *Eur J Pediatr.* 168(8):933-5.
- Fabre A, Andre N, Breton A, Broué P, Badens C, Roquelaure B. 2007. Intractable diarrhea with "phenotypic anomalies" and tricho-hepato-enteric syndrome: two names for the same disorder. *Am J Med Genet A.* 143(6):584-8.
- Fabre A, Roquelaure B, Lacoste C André N, Sarles J, Breton A, Martinez-Vinson C, Cezard JP, Colomb V, Goulet O, Levy N, Badens C. 2009. Exclusion of *EGFR*, *HRAS*, *DSP*, *JUP*, *CTNNB1*, *PLEC1* and *EPPK1* as functional candidate genes in 7 families with Syndromic Intractable Diarrhea. *J Pediatr Gastroenterol Nutr.* 48(4):501-3.
- Girault D, Goulet O, Le Deist F, Brousse N, Colomb V, Cesarini JP, de Potter S, Canioni D, Griscelli C, Fischer A. 1994 Intractable infant diarrhea associated with phenotypic abnormalities and immunodeficiency. *J Pediatr.* 125:36-42.
- Goulet O, Vinson C, Roquelaure B, Brousse N, Bodemer C, Cézard JP. 2008. Syndromic (phenotypic) diarrhea in early infancy. *Orphanet J Rare Dis.* 28;3:6.
- Hartley JL, Zachos NC, Dawood B, Donowitz M, Forman J, Pollitt RJ, Morgan NV, Tee L, Gissen P, Kahr WH, Knisely AS, Watson S, Chitayat D, Booth IW, Protheroe S, Murphy S, de Vries E, Kelly DA, Maher ER. 2010. Mutations in *TTC37* cause trichohepatoenteric syndrome (phenotypic diarrhea of infancy). *Gastroenterology.* 138:2388-98.
- Senderek J, Bergmann C, Stendel C, Kirfel J, Verpoorten N, De Jonghe P, Timmerman V, Chrast R, Verheijen MH, Lemke G, Battaloglu E, Parman Y, Erdem S, Tan E, Topaloglu H, Hahn A, Müller-Felber W, Rizzuto N, Fabrizi GM, Stuhmann M, Rudnik-Schöneborn S, Züchner S, Michael Schröder J, Buchheim E, Straub V, Klepper J, Huehne K,

1
2
3
4
5
6
7
8
9
10
11
12
13
14
15
16
17
18
19
20
21
22
23
24
25
26
27
28
29
30
31
32
33
34
35
36
37
38
39
40
41
42
43
44
45
46
47
48
49
50
51
52
53
54
55
56
57
58
59
60

Rautenstrauss B, Büttner R, Nelis E, Zerres K. 2003. Mutations in a gene encoding a novel SH3/TPR domain protein cause autosomal recessive Charcot-Marie-Tooth type 4C neuropathy. *Am J Hum Genet.* 73:1106-19.

Sohocki MM, Bowne SJ, Sullivan LS, Blackshaw S, Cepko CL, Payne AM, Bhattacharya SS, Khaliq S, Qasim Mehdi S, Birch DG, Harrison WR, Elder FF, Heckenlively JR, Daiger SP. 2000. Mutations in a new photoreceptor-pineal gene on 17p cause Leber congenital amaurosis. *Nat Genet.* 24:79-83.

Verloes A, Lombet J, Lambert Y, Hubert AF, Deprez M, Fridman V, Gosseye S, Rigo J, Sokal E. 1997. Tricho-Hepato-Enteric Syndrome: Further Delineation of a Distinct Syndrome With Neonatal Hemochromatosis Phenotype, Intractable Diarrhea, and Hair Anomalies. *Am J Med Genet.* 68:391–395.

Legends

Figure 1:

Sequencing analysis of transcripts in 2 patients with splice mutations:

a: scheme representation of the splice site mutation c.2515+1 C>G, cDNA PCR amplification with primers located in exon 22 and 24 for the homozygous patient, his heterozygous mother and a normal control and sequence obtained for the patient showing exon 23 skipping.

b: scheme representation of the splice site mutation c.2577-3_-7delTTTTT, cDNA PCR amplification with primers located in exon 23 and 26 for the homozygous patient and a normal control and sequence (forward and reverse) obtained for the patient showing exon 25 skipping.

Figure 2:

qPCR analysis on normal human tissues: 48 tissues have been tested, 34 are shown on the graph. Experiments have been done twice with probe located on exons 35-36 junction. RQ: Relative Quantification to GAPDH expression.

Figure 3:

a: Scheme representation of *TTC37* with mutations described previously (underneath) and in our study (above); red: non sense or frameshift, blue missense, green: splicing mutations.

b: Model of human Thespin as predicted by TMPred algorithm.

	Patients with mutations in TTC37	Patients without mutations in TTC37	Hartley et al. 2010
Number of patients (families)	9 (8)	3 (3)	12 (11)
Consanguinity	4/8	1/3	7/11
Median age	10 y	11 y	3 y
Male/female	4/5	0/3	6/6
Hair abnormalities	9/9	3/3	12/12
Dysmorphism	9/9	3/3	12/12
Intractable diarrhea	9/9	3/3	12/12
Onset in the first month	7/9	2/3	NR
Parenteral nutrition	9/9	2/3	12/12
Immunodeficiency	9/9	2/3	12/12
IUGR	7/9	2/3	10/11
Weight<3percentile	6/9	2/3	NR
Liver involvement	4/9 (initial 1/4)	2/3 (initial 2/3)	5/10
Mental retardation	5/8	2/3	7/9

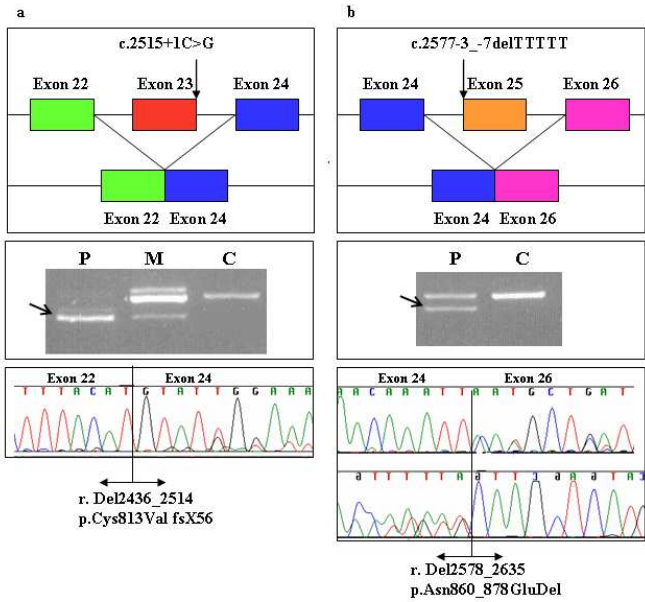
Table 1:

Clinical features of the 12 patients of this study and the 12 previously published by Hartley et al, 2010. Facial dysmorphism is characterized by hypertelorism, broad flat nasal bridge, prominent forehead; Observed hair abnormalities are sparse, fragile and uncombable hair with trichorrhexis nodosa. NR: not reported

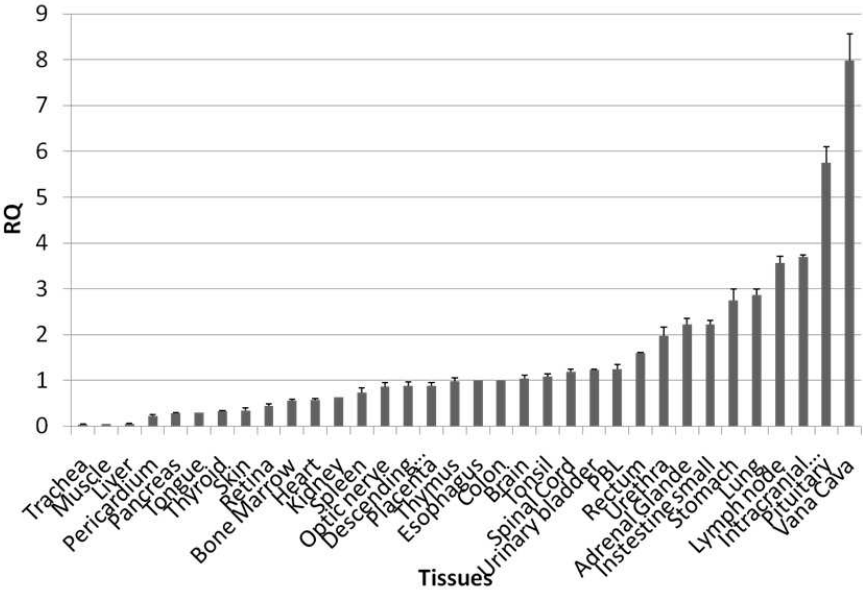
Table 2. Mutations in *TTC37*, geographical origin and consanguinity in the families of the patients with THE syndrome (NM_014639; NP_055454)

Family identifier (number of affected individuals)	Mutation 1	Mutation 2	Consanguinity	Geographical origin
1 (2)	c.326_330delTGCCT p.Leu96TrpfsX10	c.326_330delTGCCT p.Leu96TrpfsX10	Yes	Middle-East
2 (1)	c.1168delA p.Val390PheFsX419	c.3564-2A>G (nd)	No	France
3 (1)	c.2515+1G>C p.Cys813ValfsX56	c.2515+1G>C p.Cys813ValfsX56	Yes	North Africa
4 (1)	c.2577-3_- 7DelTTTTT p.Asn860_878GluDel	c.4620+1G>C p.Trp1524_1564 DelIns61	No	France
5 (1)	c.3015-1C>T nd	c.4454T>G p.Leu1485Arg, possibly damaging	No	France
6 (1)	c.3808C>G p.Pro1270Ala, probably damaging	c.3808C>G p.Pro1270Ala, probably damaging	Yes	North Africa
7 (1)	c.3960C>A p.Tyr1320X	c.3960C>A p.Tyr1320X	Yes	North Africa
8 (1)	c.3230C>A p.Alala1077Asp, probably damaging		No	France

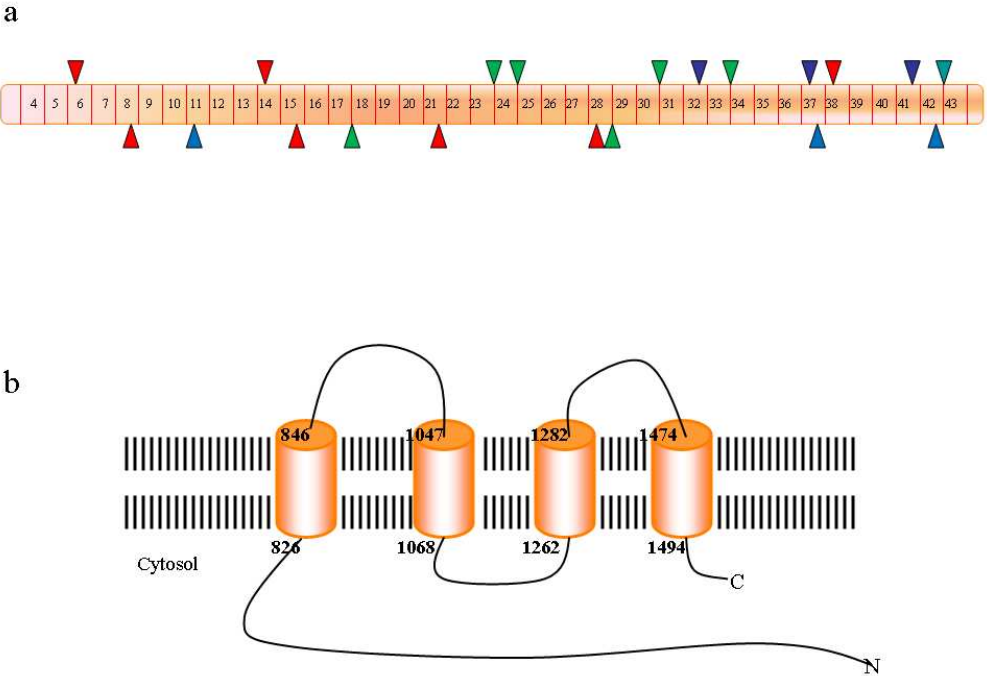
Regarding missense mutations, predictions at the protein level, were done using Polyphen algorithm. For frameshift mutations, predictions are theoretical and for splice site mutations, experimental at the transcript level. Nucleotide numbering reflects cDNA numbering with +1 corresponding to the A of the ATG translation initiation codon in the reference sequence. The initiation codon is codon 1.



254x190mm (96 x 96 DPI)



254x190mm (96 x 96 DPI)



254x190mm (96 x 96 DPI)