HAL
open science

Differential expression of the nuclear receptors FXR and PXR for grading dysplasia in patients with Barrett's oesophagus

Anouk van de Winkel, Katinka van Zoest, Herman van Dekken, Leon M Moons, Ernst J Kuipers, Luc van Der Laan

To cite this version:

Anouk van de Winkel, Katinka van Zoest, Herman van Dekken, Leon M Moons, Ernst J Kuipers, et al.. Differential expression of the nuclear receptors FXR and PXR for grading dysplasia in patients with Barrett's oesophagus. Histopathology, 2011, 58 (2), pp.246. 10.1111/j.1365-2559.2011.03743.x . hal-00614752

HAL Id: hal-00614752

https://hal.science/hal-00614752v1

Submitted on 16 Aug 2011

HAL is a multi-disciplinary open access archive for the deposit and dissemination of scientific research documents, whether they are published or not. The documents may come from teaching and research institutions in France or abroad, or from public or private research centers.

L'archive ouverte pluridisciplinaire **HAL**, est destinée au dépôt et à la diffusion de documents scientifiques de niveau recherche, publiés ou non, émanant des établissements d'enseignement et de recherche français ou étrangers, des laboratoires publics ou privés.

Histopathology

Differential expression of the nuclear receptors FXR and PXR for grading dysplasia in patients with Barrett's oesophagus

Journal:	*Histopathology*
Manuscript ID:	HISTOP-10-09-0581.R1
Manuscript Type:	Original Article
Date Submitted by the Author:	10-Dec-2009
Complete List of Authors:	van de Winkel, Anouk; Erasmus MC, Gastroenterology & Hepatology van Zoest, Katinka; Erasmus MC, Gastroenterology & Hepatology van Dekken, Herman; Erasmus MC, Pathology Moons, Leon; Erasmus MC, Gastroenterology & Hepatology Kuipers, Ernst; Erasmus MC, Internal Medicine van der Laan, Luc; Erasmus MC, Surgery
Keywords:	Barrett's oesophagus, Biomarker, Dysplasia, Farnesoid X receptor, Pregnane X receptor

scholarONE™
Manuscript Central

Differential expression of the nuclear receptors FXR and PXR for grading dysplasia in patients with Barrett's oesophagus

Anouk van de Winkel,[1*] Katinka P.M. van Zoest,[1] Herman van Dekken,[2] Leon M.G Moons,[1] Ernst J. Kuipers,[1,3] and Luc J.W. van der Laan[4]

Departments of [1]Gastroenterology and Hepatology, [2]Pathology, [3]Internal Medicine and [4]Surgery, Erasmus MC - University Medical Centre Rotterdam, Rotterdam, the Netherlands

Key words: Oesophageal Adenocarcinoma; Barrett's Oesophagus; Biomarker; Dysplasia; Farnesoid X Receptor (FXR); Immunohistochemistry; Pregnane X Receptor

Running title: FXR and PXR in grading BO patients

*Correspondence to: Anouk van de Winkel

Department of Gastroenterology and Hepatology, Room L-463,

Erasmus MC - University Medical Center Rotterdam,

's-Gravendijkwal 230, 3015 CE Rotterdam, the Netherlands

E-mail: A.vandewinkel@erasmusmc.nl

Phone: +31-10-7034810

Fax: +31-10-7032793

For Peer Review

ABSTRACT

Aims: To investigate expression of nuclear receptors FXR and PXR as a diagnostic tool to improve grading of dysplasia in Barrett's oesophagus patients.

Methods and Results: Immunostaining was analyzed on a total of 192 biopsy samples of of 22 Barrett's patients with no dysplasia (ND), 17 with low grade dysplasia (LGD), 20 high grade dysplasia (HGD), and 24 with adenocarcinoma. Nuclear FXR expression was observed in 15/22 (68%) ND cases versus 5/60 (8%) patients with dysplasia or adenocarcinoma (p<0.001). FXR expression was highly specific for non-dysplastic tissue. Nuclear PXR was expressed in 16/20 (80%) HGD cases versus 2/16 (13%) LGD cases (PPV 89%). Upon examining adjacent tissue taken from HGD and adenocarcinoma patients, PXR expression was high in samples of all tissue types. **Conclusions:** Nuclear receptors are differentially expressed during neoplastic progression with FXR-positivity being useful to distinguish ND from dysplasia and adenocarcinoma. PXR nuclear expression is able to separate HGD from LGD and ND. The combination of FXR and PXR appears to have diagnosticand possibly prognostic value as well, but future prospective studies are required to investigate their predictive power for dysplastic progression in Barret's oesophagus.

Deleted: FXR and PXR

Deleted: histological

Deleted: Immunohistochemistry

Deleted: performed

Deleted: for FXR and PXR

Deleted: 83

Deleted: oesophagus

Deleted: either

Deleted: out

Deleted: ; n=22

Deleted: ; n=17

Deleted: ; n=20

Deleted: or

Deleted: (n=24)

Deleted: ¶
Results:

Deleted: p<0.001

Deleted: generally absent in all tissue samples of ND and LGD patients, but

Deleted: all

Deleted: samples of HGD and adenocarcinoma patients. ¶

Deleted: Nuclear FXR expression is common in ND tissue, but expression is lost during progression to dysplasia and cancer. Nuclear PXR expressed only in HGD and adenocarcinoma patients and appeared to be a field effect.

Deleted: appears valuable as a diagnostic tool and future studies need to investigate their role and predictive power for dysplastic progression in Barrett's oesophagus patients

Deleted: .

For Peer Review

INTRODUCTION

Barrett's oesophagus (BO) is an acquired condition of metaplasia in which the stratified squamous epithelium of the lower oesophagus is replaced by specialized intestinal-like epithelium harbouring goblet cells.[1-3] The incidence of BO and oesophageal adenocarcinoma have both increased rapidly since the 1970s and remain on the rise in the Western world.[4-7] Patients with BO have 30- to 125-fold increased risk of oesophageal adenocarcinoma relative to the general population.[4, 8-10] Annual risk is estimated at a mere 0.2% to 2.1%.[10-12] Endoscopic surveillance is performed to detect early stages that lead to adenocarcinoma.[12, 13] The current marker for incipient malignancy in the oesophagus is dysplasia, defined as the neoplastic proliferation within epithelial glands without affecting the basal membrane.

Neoplastic progression in BO follows a multistep sequence from intestinal metaplasia to low-grade dysplasia (LGD), high-grade dysplasia (HGD) until finally, adenocarcinoma.[2, 8, 14] At present it is unclear which factors control the rate of neoplastic progression in BO.[15] The presence and grade of dysplasia in random biopsies obtained during endoscopy are currently the best indicators of cancer risk in BO patients.[16] Patients with HGD have a high risk of developing adenocarcinoma warranting surgery or endoscopic mucosectomy.[17, 18] LGD on the other hand is more indolent.[19, 20] The initial diagnosis of LGD was expected to confer a two-fold increased risk of neoplastic progression as compared to BO without dysplasia.[19, 21-25] A major complication of using histology for grading dysplasia is that its assessment is subject to intraobserver and interobserver variation.[26, 27] The use of tissue biomarkers in addition to histology may improve the diagnosis of dysplasia and risk prediction in BO patients.[19, 24, 28] A considerable number of biomarkers have been suggested.[29] These include tumour cell markers, [30] and markers identifying genetic abnormalities,[31] DNA hypermethylation[32] and aberrant cell cycling.[33] Current biomarkers are not applied in clinical practice due to lack of

For Peer Review

reliability. This highlights the need for further research into new biomarkers to predict neoplastic progression.

It is known that the exposure of the oesophageal lining to bile acids plays an important role in development and neoplastic progression of BO. Evidence suggests that detoxifying mechanisms in the oesophagus fail to prevent injury to the oesophageal mucosa.[34] This draws attention upon receptors involved in bile-induced signalling. Two nuclear receptors, the bile acid receptor Farnesoid X Receptor (FXR) and the xenobiotic sensor Pregnane X Receptor (PXR) have been identified.[35-37] They are abundantly expressed in the liver and intestine where they act as detoxifiers and regulate xenobiotic and bile acid homeostasis.[36, 38-41] In the human colon, the expression of FXR has been shown to progressively decrease as normal mucosa advances towards adenocarcinoma.[42] In the oesophagus, overexpression of FXR in BO compared to normal squamous epithelium and adenocarcinoma was reported.[43, 44] These studies further suggested that FXR expression contributes to the regulation of bile acid signalling and apoptosis in BO. We previously found that PXR mRNA levels in the oesophagus are higher in Barrett's epithelium than in normal squamous epithelium, and that polymorphisms in the PXR gene are associated with the presence of BO (van de Winkel et al, submitted for publication). The aim of the present study was to investigate the expression of PXR and FXR during progression to dysplasia and cancer. Hereto, their presence and localisation was evaluated by immunohistochemistry in surveillance biopsies taken from BO patients with different stages of progression.

For Peer Review

MATERIALS AND METHODS

Patient samples

Biopsy specimens from 83 BO patients (73% male; mean age 65 yrs, range 38-87) with different stages of progression were selected. Patients were assessed at the endoscopy unit of the Erasmus Medical Center Rotterdam and had endoscopically confirmed BO. From each patient, multiple biopsies were collected at the same distance from the z-line. The number of biopsies taken was approximately four per patient, and varied between one and eight biopsies. For each patient, all biopsy specimens were embedded in one single block of paraffin and were therefore stained and analyzed in one slide. Histologic diagnosis was made by two experienced gastrointestinal pathologists (HvD and HvdV). All patients had specialized intestinal metaplasia and were graded according to the most severe stage found. Cases on which agreement could not be reached or that were indefinite for dysplasia were excluded from this study. The four groups included BO without dysplasia (ND; n=22), LGD (n=17), HGD (n=20), or adenocarcinoma (n=24). Patient characteristics are given in Table 1. No significant differences in age or gender were found between the groups. This study was approved by the review board of the Erasmus Medical Centre Rotterdam, the Netherlands.

Immunohistochemical stainings

From the formalin-fixed, paraffin-embedded tissue blocks, sequential sections were sliced and mounted on adhesive slides (Starfrost, Berlin, Germany). After deparaffinization in xylene and dehydration in alcohol, endogenous peroxidase was inactivated by incubation with 1% hydrogen peroxidase in methanol for 20 min. Antigen retrieval was performed by boiling the sections for 10 min in Tris/EDTA pH 9.0 (for FXR) or in Glycine-HCl/EDTA pH 3.5 (for PXR). Sections were treated with 10% normal human plasma/10% goat serum to block non-specific staining. Anti human FXR/NR1H4 antibody (1:150; R&D Systems, Japan) was

For Peer Review

incubated for 1hr at RT, followed by polyclonal goat anti-mouse (1:200; Dako, Denmark). The PXR antibody (1:200; clone poly6169, Biolegend, San Diego) was incubated over night at 4°C and then 30 min at RT with a polyclonal goat anti-rabbit (1:200; Dako, Denmark). After 45 min of incubation with streptavidin HRP (Dako, Denmark), FXR was visualized using 3-amino-9- ethylcarbazole and for PXR diaminobenzidine was used as a substrate. As a negative control the first antibody was omitted and an isotype control was included. Tissue of terminal ileum was taken as a positive control. Sections were evaluated at a 400-fold magnification using light microscopy (Axioskop 20, Zeiss) by two independent observers (AW, KZ). At least 100 cells were counted in representative areas of a longitudinally sectioned crypt or high power field. The scored percentages of positive nuclei were categorised as follows: no expression (<1%), mild (1-25%), moderate (26-50%) or high expression (>50%).[30, 45] Pictures were taken and analyzed using Nikon software (NisElements 2008).

Deleted: Tissue of terminal ileum was taken as a positive control and for

Statistical Evaluation

The Mann-Whitney Test was applied for comparison of immunostaining results between groups. The Spearman correlation coefficient was used to evaluate significance of overall trends along the metaplasia-dysplasia-adenocarcinoma axis. To evaluate the utility of the markers, we constructed receiver operating characteristic (ROC) curves. All statistical analyses were conducted using SPSS v11.0 (SPSS, Chicago, IL) and 2-tailed significance was taken as $p<0.05$.

For Peer Review

RESULTS

FXR nuclear expression distinguishes LGD from ND

Figure 1 shows FXR staining in ND (A), LGD (B), HGD (C) and adenocarcinoma (D). Nuclear FXR was typically expressed in ND patients (15/22; 68%), and was not or infrequently found in the tissue of LGD (3/17; 18%), HGD (0/19; 0%) and adenocarcinoma (2/24; 8%) patients ($p<0.001$ for overall trend; Figure 1E). Of FXR-positive ND cases almost 50% had moderate to high FXR expression levels (Figure 1F). The expression in LGD, HGD, and AC cases did not exceed the level of mild expression. FXR expression had a specificity of 82% in separating LGD from ND. This yielded a positive predictive value of 83%. ROC analysis confirmed that nuclear FXR expression was accurate in separating LGD from ND with an area under curve of 0.769 ($p=0.004$; Figure 2).

Differences in PXR nuclear expression between HGD and LGD

Figure 3 shows a representative PXR staining of ND (A), LGD (B), HGD (C), and adenocarcinoma (D) tissue. PXR expression was observed in only 4/21 (19%) ND and 2/16 (13%) LGD patients. In contrast, PXR-positive nuclei were present in tissue of 16/20 (80%) HGD and 17/22 (77%) adenocarcinoma patients ($p<0.001$; Figure 3E). The level of PXR expression was significantly higher in adenocarcinoma than HGD patients ($p=0.022$; Figure 3F). Grading LGD and HGD based on nuclear PXR expression complied in 89% of all cases with histologic grading. This conferred a specificity of 88%. ROC-curves yielded an area under curve of 0.852, indicating that PXR-positivity is a strong indicator of HGD (Figure 4).

Nuclear FXR and PXR expression in tissue adjacent to tissue of histologic diagnosis

Nuclear FXR and PXR expression was examined in biopsy samples of the same patients taken directly adjacent to the biopsy on which histologic diagnosis was based. The percentage of

For Peer Review

patients that had FXR-positivity in adjacent tissue is shown in Figure 5A. In cases where adjacent normal squamous biopsy specimen was available, analysis showed FXR-positive nuclei in 38% of LGD, 38% of HGD and 67% of adenocarcinoma patients. Adjacent ND tissue was positive for nuclear FXR expression in 80% of LGD, 62% of HGD and 75% of adenocarcinoma cases (Figure 5A).

PXR expression was completely absent in the adjacent normal squamous tissue of ND and LGD patients (Figure 5B). In adjacent ND tissues from LGD patients only 1/9 (11%) expressed PXR. In HGD patients analyzed cases did express PXR in the adjacent squamous tissue (4/8; 50%) and in the nearby ND tissue (4/7; 57%). In adenocarcinoma patients high PXR expression was found in adjacent normal squamous (12/14; 86%), ND (8/9; 89%), and in HGD (8/13; 62%) tissue (Figure 5B).

Overall these data show that FXR expression significantly differs between areas of dysplasia and adjacent ND and normal squamous tissue, whereas PXR expression is similar in all tissue samples of an individual patient.

Decision chart based on FXR and PXR distribution

Figure 6 shows a decision chart for using PXR and FXR as a diagnostic tool. FXR positive cases are likely to be ND. In the FXR-negative cases, PXR-positivity in any of the tissue is an indication for HGD or adenocarcinoma. Cases that have no FXR or PXR expression are classified as LGD patients. This decision chart can be used in addition to histology for classifying disease progression in BO patients. It offers potential clinical value in improving the accuracy of dysplasia grading especially by addressing the issue of sampling error.

For Peer Review

DISCUSSION

In this study we have investigated the expression of FXR and PXR in different stages of neoplastic progression in BO and their value as potential biomarkers. Nuclear expression of FXR was clearly present in 68% of ND cases, but detected in only few patients with dysplasia or adenocarcinoma. In contrast, nuclear PXR was specifically expressed in oesophageal tissue of patients with HGD and adenocarcinoma, but not in patients with ND or LGD. Staining for PXR allowed an appropriate distinction between LGD and HGD in 83% of all cases, taking histology as a gold standard. As histology experiences difficulty in diagnosing dysplasia, the combined use of FXR and PXR could contribute to an accurate and reliable distinction between stages of dysplasia. This improvement is especially important when considering enhancement of risk stratification and cost-effectiveness in endoscopic surveillance strategies.

In FXR-negative dysplasia and adenocarcinoma patients surrounding ND and normal squamous tissue was found positive for FXR. This underlines a highly grade and tissue specific regulation. The observed loss of nuclear FXR suggests it is inactivated in dysplastic and adenocarcinoma tissue. This can be accounted to either hypermethylation of the gene or mutational events.

Nuclear PXR was absent in all tissue types of ND and LGD patients. In HGD and adenocarcinoma patients PXR was highly expressed in all tissues with different stages of progression. Considering this data it appears that PXR is the result of a field effect of the adenocarcinoma. Therefore, the six ND and LGD patients that expressed PXR may actually be HGD cases that were missed because of sampling error. PXR expression could also address the issue of diagnosing those cases classified by pathologists as indefinite for dysplasia.

In a recent retrospective multicenter study,[46] investigators demonstrated that a model of eight methylation biomarkers predicted 50% of progressors to HGD and adenocarcinoma that

For Peer Review

would not have been diagnosed earlier without using these biomarkers. Based on our findings it is encouraging to evaluate FXR and PXR expression as a diagnostic tool. New prospective studies with long follow-up need to focus on risk prediction of FXR and PXR in BO patients.

In conclusion, FXR is expressed in the nuclei of ND tissue, but expression is lost during progression to dysplasia and cancer. Nuclear expression of PXR appears to be a field effect. It is high in all oesophageal tissue of HGD and adenocarcinoma patients and is nowhere present in LGD and ND patients. The combination of FXR and PXR may prove valuable as a diagnostic tool and future studies are encouraged to investigate their role and predictive power in BO patients.

For Peer Review

REFERENCES

1. Jankowski JA, Harrison RF, Perry I, Balkwill F, Tselepis C. Barrett's metaplasia. *Lancet* 2000 Dec 16;**356**(9247);2079-2085.

2. Haggitt RC. Barrett's esophagus, dysplasia, and adenocarcinoma. *Hum Pathol* 1994 Oct;**25**(10);982-993.

3. Wang KK, Sampliner RE. Updated guidelines 2008 for the diagnosis, surveillance and therapy of Barrett's esophagus. *Am J Gastroenterol* 2008 Mar;**103**(3);788-797.

4. Falk GW. Barrett's esophagus. *Gastroenterology* 2002 May;**122**(6);1569-1591.

5. Falk GW. Barrett's esophagus-is it bad for your health? *Am J Gastroenterol* 2005 Dec;**100**(12);2622-2623.

6. van Soest EM, Dieleman JP, Siersema PD, Sturkenboom MC, Kuipers EJ. Increasing incidence of Barrett's oesophagus in the general population. *Gut* 2005 Aug;**54**(8);1062-1066.

7. Pera M, Cameron AJ, Trastek VF, Carpenter HA, Zinsmeister AR. Increasing incidence of adenocarcinoma of the esophagus and esophagogastric junction. *Gastroenterology* 1993 Feb;**104**(2);510-513.

8. Hameeteman W, Tytgat GN, Houthoff HJ, van den Tweel JG. Barrett's esophagus: development of dysplasia and adenocarcinoma. *Gastroenterology* 1989 May;**96**(5 Pt 1);1249-1256.

9. Cameron AJ, Carpenter HA. Barrett's esophagus, high-grade dysplasia, and early adenocarcinoma: a pathological study. *Am J Gastroenterol* 1997 Apr;**92**(4);586-591.

10. Drewitz DJ, Sampliner RE, Garewal HS. The incidence of adenocarcinoma in Barrett's esophagus: a prospective study of 170 patients followed 4.8 years. *Am J Gastroenterol* 1997 Feb;**92**(2);212-215.

11. Hage M, Siersema PD, van Dekken H, Steyerberg EW, Dees J, Kuipers EJ. Oesophageal cancer incidence and mortality in patients with long-segment Barrett's

For Peer Review

oesophagus after a mean follow-up of 12.7 years. *Scand J Gastroenterol* 2004 Dec;**39**(12);1175-1179.

12. Corley DA, Levin TR, Habel LA, Weiss NS, Buffler PA. Surveillance and survival in Barrett's adenocarcinomas: a population-based study. *Gastroenterology* 2002 Mar;**122**(3);633-640.

13. Streitz JM, Jr., Andrews CW, Jr., Ellis FH, Jr. Endoscopic surveillance of Barrett's esophagus. Does it help? *J Thorac Cardiovasc Surg* 1993 Mar;**105**(3);383-387; discussion 387-388.

14. Schlemper RJ, Riddell RH, Kato Y *et al.* The Vienna classification of gastrointestinal epithelial neoplasia. *Gut* 2000 Aug;**47**(2);251-255.

15. di Pietro M, Peters CJ, Fitzgerald RC. Clinical puzzle: Barrett's oesophagus. *Dis Model Mech* 2008 Jul-Aug;**1**(1);26-31.

16. Sharma P, Sidorenko EI. Are screening and surveillance for Barrett's oesophagus really worthwhile? *Gut* 2005 Mar;**54 Suppl 1**;i27-32.

17. Buttar NS, Wang KK, Lutzke LS, Krishnadath KK, Anderson MA. Combined endoscopic mucosal resection and photodynamic therapy for esophageal neoplasia within Barrett's esophagus. *Gastrointest Endosc* 2001 Dec;**54**(6);682-688.

18. Weston AP, Sharma P, Topalovski M, Richards R, Cherian R, Dixon A. Long-term follow-up of Barrett's high-grade dysplasia. *Am J Gastroenterol* 2000 Aug;**95**(8);1888-1893.

19. Montgomery E, Goldblum JR, Greenson JK *et al.* Dysplasia as a predictive marker for invasive carcinoma in Barrett esophagus: a follow-up study based on 138 cases from a diagnostic variability study. *Hum Pathol* 2001 Apr;**32**(4);379-388.

20. Burke AP, Sobin LH, Shekitka KM, Helwig EB. Dysplasia of the stomach and Barrett esophagus: a follow-up study. *Mod Pathol* 1991 May;**4**(3);336-341.

For Peer Review

21. Sharma P, Falk GW, Weston AP, Reker D, Johnston M, Sampliner RE. Dysplasia and cancer in a large multicenter cohort of patients with Barrett's esophagus. *Clin Gastroenterol Hepatol* 2006 May;**4**(5);566-572.

22. Conio M, Blanchi S, Lapertosa G *et al.* Long-term endoscopic surveillance of patients with Barrett's esophagus. Incidence of dysplasia and adenocarcinoma: a prospective study. *Am J Gastroenterol* 2003 Sep;**98**(9);1931-1939.

23. Dulai GS, Shekelle PG, Jensen DM *et al.* Dysplasia and risk of further neoplastic progression in a regional Veterans Administration Barrett's cohort. *Am J Gastroenterol* 2005 Apr;**100**(4);775-783.

24. Skacel M, Petras RE, Gramlich TL, Sigel JE, Richter JE, Goldblum JR. The diagnosis of low-grade dysplasia in Barrett's esophagus and its implications for disease progression. *Am J Gastroenterol* 2000 Dec;**95**(12);3383-3387.

25. Reid BJ, Levine DS, Longton G, Blount PL, Rabinovitch PS. Predictors of progression to cancer in Barrett's esophagus: baseline histology and flow cytometry identify low- and high-risk patient subsets. *Am J Gastroenterol* 2000 Jul;**95**(7);1669-1676.

26. Kerkhof M, van Dekken H, Steyerberg EW *et al.* Grading of dysplasia in Barrett's oesophagus: substantial interobserver variation between general and gastrointestinal pathologists. *Histopathology* 2007 Jun;**50**(7);920-927.

27. Montgomery E, Bronner MP, Goldblum JR *et al.* Reproducibility of the diagnosis of dysplasia in Barrett esophagus: a reaffirmation. *Hum Pathol* 2001 Apr;**32**(4);368-378.

28. Sharma P. Low-grade dysplasia in Barrett's esophagus. *Gastroenterology* 2004 Oct;**127**(4);1233-1238.

29. Kerkhof M, Kusters JG, van Dekken H, Kuipers EJ, Siersema PD. Biomarkers for risk stratification of neoplastic progression in Barrett esophagus. *Cell Oncol* 2007;**29**(6);507-517.

For Peer Review

30. van Dekken H, Hop WC, Tilanus HW *et al.* Immunohistochemical evaluation of a panel of tumor cell markers during malignant progression in Barrett esophagus. *Am J Clin Pathol* 2008 Nov;**130**(5);745-753.

31. Krishnadath KK, Tilanus HW, van Blankenstein M *et al.* Accumulation of genetic abnormalities during neoplastic progression in Barrett's esophagus. *Cancer Res* 1995 May 1;**55**(9);1971-1976.

32. Schulmann K, Sterian A, Berki A *et al.* Inactivation of p16, RUNX3, and HPP1 occurs early in Barrett's-associated neoplastic progression and predicts progression risk. *Oncogene* 2005 Jun 9;**24**(25);4138-4148.

33. Gray MR, Hall PA, Nash J, Ansari B, Lane DP, Kingsnorth AN. Epithelial proliferation in Barrett's esophagus by proliferating cell nuclear antigen immunolocalization. *Gastroenterology* 1992 Dec;**103**(6);1769-1776.

34. Zollner G, Marschall HU, Wagner M, Trauner M. Role of nuclear receptors in the adaptive response to bile acids and cholestasis: pathogenetic and therapeutic considerations. *Mol Pharm* 2006 May-Jun;**3**(3);231-251.

35. Makishima M, Okamoto AY, Repa JJ *et al.* Identification of a nuclear receptor for bile acids. *Science* 1999 May 21;**284**(5418);1362-1365.

36. Kliewer SA, Moore JT, Wade L *et al.* An orphan nuclear receptor activated by pregnanes defines a novel steroid signaling pathway. *Cell* 1998 Jan 9;**92**(1);73-82.

37. Zhang F, Altorki NK, Wu YC, Soslow RA, Subbaramaiah K, Dannenberg AJ. Duodenal reflux induces cyclooxygenase-2 in the esophageal mucosa of rats: evidence for involvement of bile acids. *Gastroenterology* 2001 Dec;**121**(6);1391-1399.

38. Lehmann JM, McKee DD, Watson MA, Willson TM, Moore JT, Kliewer SA. The human orphan nuclear receptor PXR is activated by compounds that regulate CYP3A4 gene expression and cause drug interactions. *J Clin Invest* 1998 Sep 1;**102**(5);1016-1023.

For Peer Review

39. Bertilsson G, Heidrich J, Svensson K *et al.* Identification of a human nuclear receptor defines a new signaling pathway for CYP3A induction. *Proc Natl Acad Sci U S A* 1998 Oct 13;**95**(21);12208-12213.

40. Blumberg B, Sabbagh W, Jr., Juguilon H *et al.* SXR, a novel steroid and xenobiotic-sensing nuclear receptor. *Genes Dev* 1998 Oct 15;**12**(20);3195-3205.

41. Repa JJ, Mangelsdorf DJ. The role of orphan nuclear receptors in the regulation of cholesterol homeostasis. *Annu Rev Cell Dev Biol* 2000;**16**;459-481.

42. De Gottardi A, Touri F, Maurer CA *et al.* The bile acid nuclear receptor FXR and the bile acid binding protein IBABP are differently expressed in colon cancer. *Dig Dis Sci* 2004 Jun;**49**(6);982-989.

43. De Gottardi A, Dumonceau JM, Bruttin F *et al.* Expression of the bile acid receptor FXR in Barrett's esophagus and enhancement of apoptosis by guggulsterone in vitro. *Mol Cancer* 2006;**5**;48.

44. Capello A, Moons LM, Van de Winkel A *et al.* Bile acid-stimulated expression of the farnesoid X receptor enhances the immune response in Barrett esophagus. *Am J Gastroenterol* 2008 Jun;**103**(6);1510-1516.

45. Sikkema M, Kerkhof M, Steyerberg EW *et al.* Aneuploidy and overexpression of Ki67 and p53 as markers for neoplastic progression in Barrett's esophagus: a case-control study. *Am J Gastroenterol* 2009 Nov;**104**(11);2673-2680.

46. Jin Z, Cheng Y, Gu W *et al.* A multicenter, double-blinded validation study of methylation biomarkers for progression prediction in Barrett's esophagus. *Cancer Res* 2009 May 15;**69**(10);4112-4115.

For Peer Review

Table 1 BO patient characteristics

	ND (*n=22*)	*LGD* (*n=17*)	*HGD* (*n=20*)	*adenocarcinoma* (*n=24*)	*Total* (*n=83*)
Age, y (range)	63 (38-87)	68 (44-86)	67 (46-82)	62 (38-81)	65 (38-87)
Gender, %male	68	71	80	74	73

No significant differences were found between groups with respect to age or gender

For Peer Review

FIGURE LEGENDS

Figure 1. FXR staining in ND, LGD, HGD and adenocarcinoma patients. Nuclear FXR was present in most cases of ND (A), but not in tissue of LGD (B), HGD (C) or adenocarcinoma patients (D). E) Quantification showed that significantly more cases of ND had nuclear FXR expression compared to LGD (p<0.001). F) The percentage of cases with moderate or high FXR expression levels was significantly higher in ND patients than in patients with more progressive stages of neoplasia (p=0.001).

Figure 2. Receiver operating curve (ROC) of FXR nuclear expression comparing LGD and ND. In the ROC-curve, 1% of FXR positive nuclei was taken as a cut-off to obtain the most sensitive and specific classification. The ROC-curve shows that the absence of nuclear FXR expression is an accurate tool to separate LGD from ND (p=0.004).

Figure 3. PXR staining in ND, LGD, HGD and adenocarcinoma patients. Nuclear PXR was not expressed in ND (A) or LGD (B) tissue, but was observed in HGD (C) and adenocarcinoma (D) tissue. E) Quantification showed that significantly more cases of HGD had nuclear PXR expression compared to LGD (p<0.001). F) High PXR expression levels were found more often in adenocarcinoma (AC) than in HGD patients (p=0.022).

Figure 4. Receiver operating curve (ROC) depicts the accuracy of PXR nuclear expression as a marker for dysplasia by evaluating its sensitivity and specificity. Taking 1% of PXR positive nuclei as a cut-off rendered the most sensitive and specific classification of HGD from LGD. The AUC for this criterion was 0.852 (p<0.001).

Figure 5. FXR and PXR expression in adjacent tissue to the biosy of histologic diagnosis. A) The left panel shows FXR nuclear staining (positive samples/total samples) in biopsy specimen adjacent to the specimen of histological diagnosis (below dotted line). Bar graphs on the right show the percentage of FXR-positivity for adjacent normal squamous (NSq) tissue and adjacent ND tissue

For Peer Review

for each patient group. Though loss of nuclear FXR was observed in diagnostic specimens of LGD, HGD and AC patients, expression remained significantly higher in adjacent NSq and ND tissue (* p<0.05, p<0.01). The FXR-positivity in NSq and ND tissues did not differ between patient groups. B) The left panel shows PXR nuclear staining (positive samples/total samples) in biopsy specimen adjacent to the specimen of histological diagnosis (below dotted line). Bar graphs on the right show the percentage of PXR-positivity for adjacent NSq tissue and adjacent ND tissue for each patient group. Nuclear PXR expression in HGD and AC patients was also found elevated in adjacent NSq and ND tissue. The percentage of PXR-positivity in NSq and ND tissue of HGD and AC patients was significantly higher then in these tissue types found in LGD and ND patients (* p<0.05).

Figure 6. Decision chart combining FXR and PXR results as tool for histologic grading. FXR positivity in tissue of histologic diagnosis is indicative for ND. Of the FXR negative cases, PXR positivity in any of the specimen taken during biopsy is an indication for HGD or adenocarcinoma whereas PXR negative cases are likely to be LGD patients.

Deleted: ¶

Formatted: English (U.K.)

Deleted: **Figure 5 FXR and PXR expression in tissue of histologic diagnosis and in biopsy specimen taken directly adjacent to this tissue.** A) The figure on the left shows FXR-positivity (n/n) in biopsy specimen on which histologic diagnosis was based (ovals above dotted line), as well as biopsy specimen adjacent to these (ovals below dotted line). For each type of tissue, the percentage of FXR-positive cases is represented by a bar graph to the right of this figure. Where a loss of nuclear FXR was observed in LGD, HGD, and adenocarcinoma tissue, expression was still high in adjacent normal squamous (NSq) and ND tissue of these patients (* p<0.05). FXR-positivity in NSq and ND tissues did not differ between patient groups. B) The figure on the left shows PXR-positivity (n/n) in biopsy specimen on which histologic diagnosis was based (ovals above dotted line), as well as biopsy specimen adjacent to these (ovals below dotted line). The bar graphs on the right reflect the percentage of PXR-positive cases per tissue type. Nuclear PXR expression in HGD and adenocarcinoma patients was also found in adjacent NSq and ND tissue. Adjacent NSq and ND tissue of LGD and ND patients was generally negative for nuclear PXR expression.¶

For Peer Review

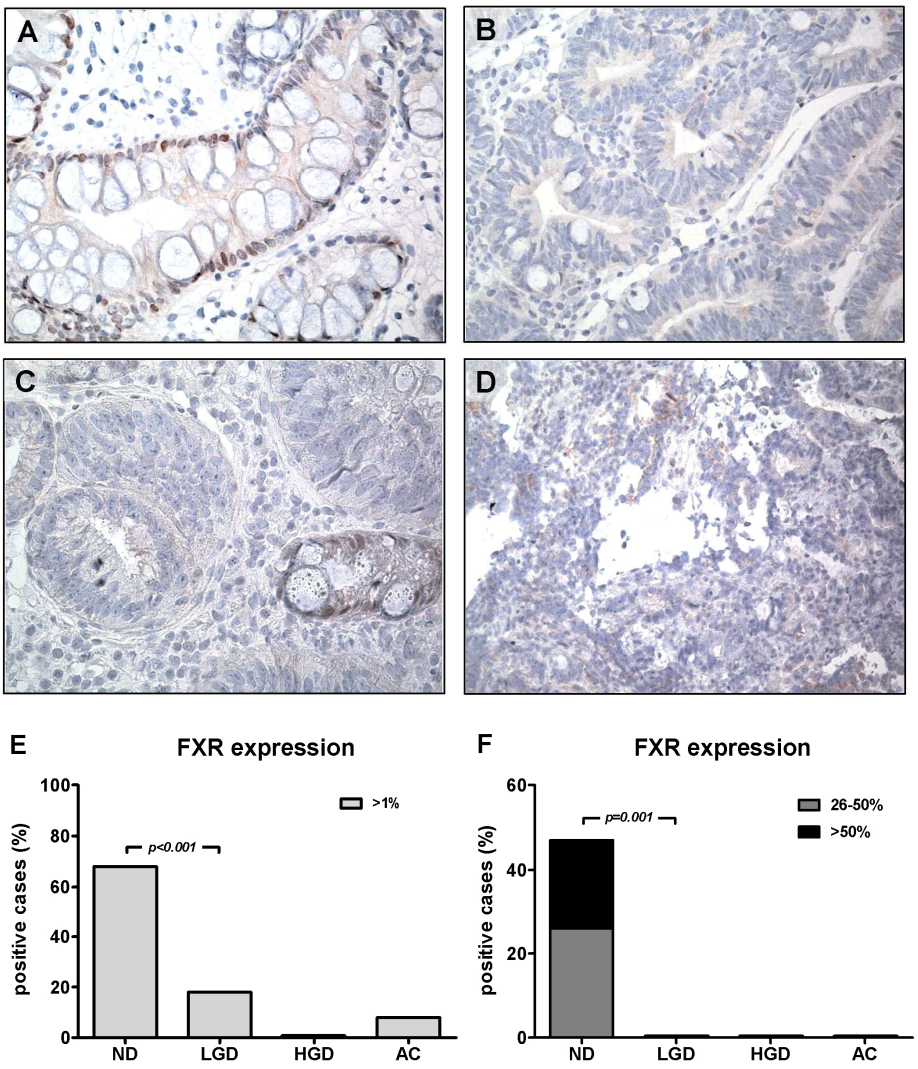

Figure 1 FXR staining in ND, LGD, HGD and adenocarcinoma patients. Nuclear FXR was present in most cases of ND (A), but not in tissue of LGD (B), HGD (C) or adenocarcinoma patients (D). E) Quantification showed that significantly more cases of ND had nuclear FXR expression compared to LGD ($p<0.001$). F) The percentage of cases with moderate or high FXR expression levels was significantly higher in ND patients than in patients with more progressive stages of neoplasia ($p=0.001$).
193x212mm (300 x 300 DPI)

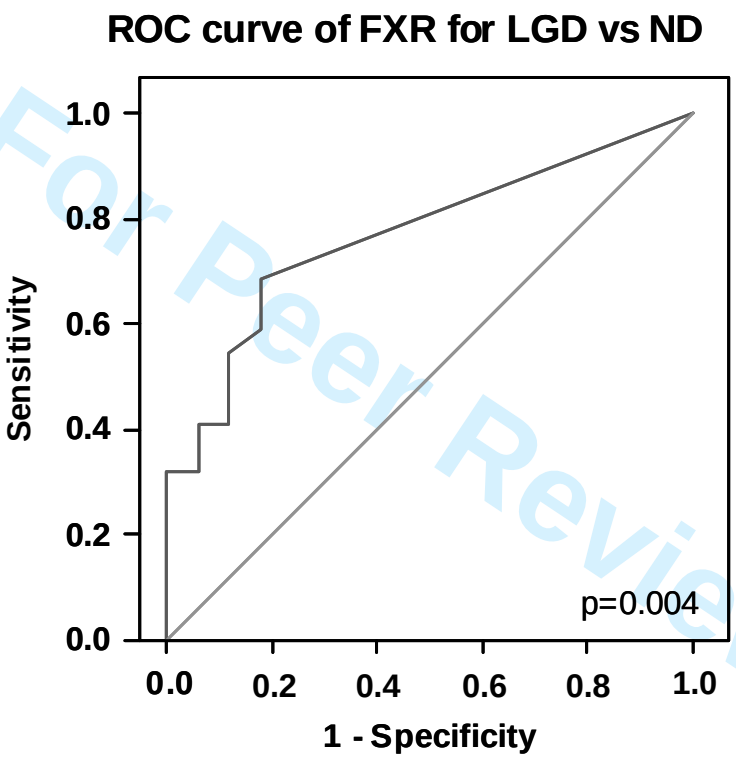

For Peer Review

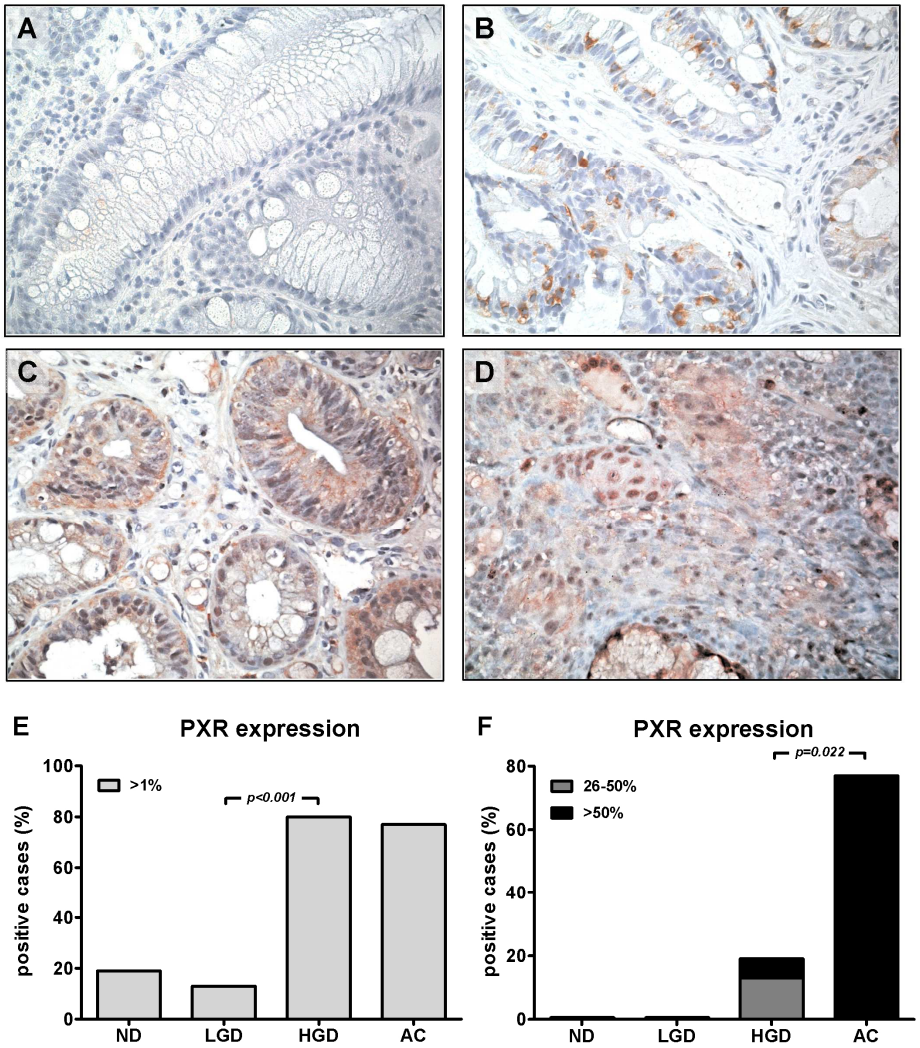

Figure 3 PXR staining in ND, LGD, HGD and adenocarcinoma patients. Nuclear PXR was not expressed in ND (A) or LGD (B) tissue, but was observed in HGD (C) and adenocarcinoma (D) tissue. E) Quantification showed that significantly more cases of HGD had nuclear PXR expression compared to LGD ($p<0.001$). F) High PXR expression levels were found more often in adenocarcinoma (AC) than in HGD patients ($p=0.022$).
194x211mm (300 x 300 DPI)

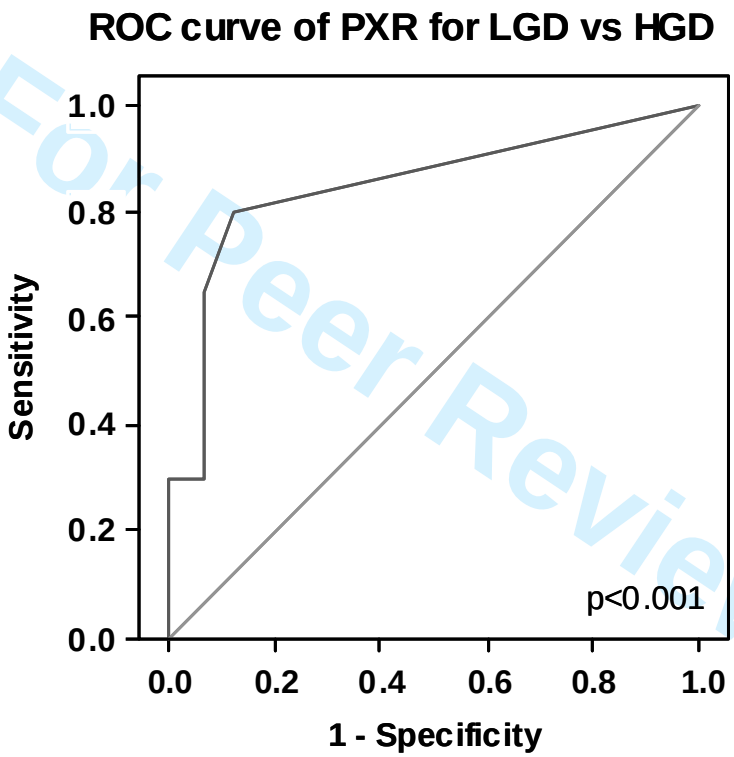

For Peer Review

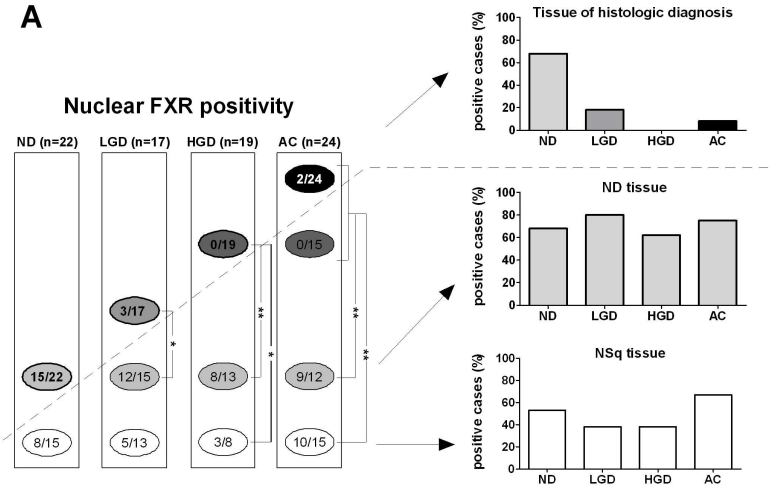

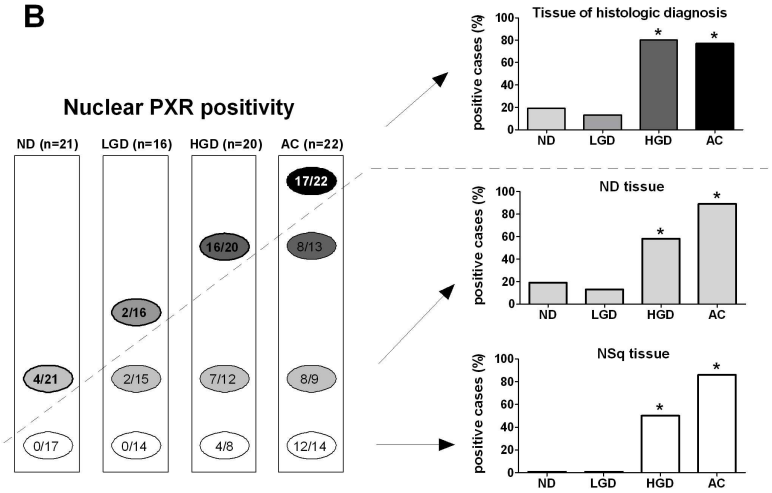

Figure 5. FXR and PXR expression in adjacent tissue to the biosy of histologic diagnosis. A) The left panel shows FXR nuclear staining (positive samples/total samples) in biopsy specimen adjacent to the specimen of histological diagnosis (below dotted line). Bar graphs on the right show the percentage of FXR-positivity for adjacent normal squamous (NSq) tissue and adjacent ND tissue for each patient group. Though loss of nuclear FXR was observed in diagnostic specimens of LGD, HGD and AC patients, expression remained significantly higher in adjacent NSq and ND tissue (* $p<0.05$, $p<0.01$). The FXR-positivity in NSq and ND tissues did not differ between patient groups. B) The left panel shows PXR nuclear staining (positive samples/total samples) in biopsy specimen adjacent to the specimen of histological diagnosis (below dotted line). Bar graphs on the right show the percentage of PXR-positivity for adjacent NSq tissue and adjacent ND tissue for each patient category. Nuclear PXR expression in HGD and AC patients was also found elevated in adjacent NSq and ND tissue. The percentage of PXR-positivity in NSq and ND tissue of HGD and AC patients was significantly higher then in these tissue types found in LGD and ND patients (* $p<0.05$).

181x270mm (300 x 300 DPI)

For Peer Review

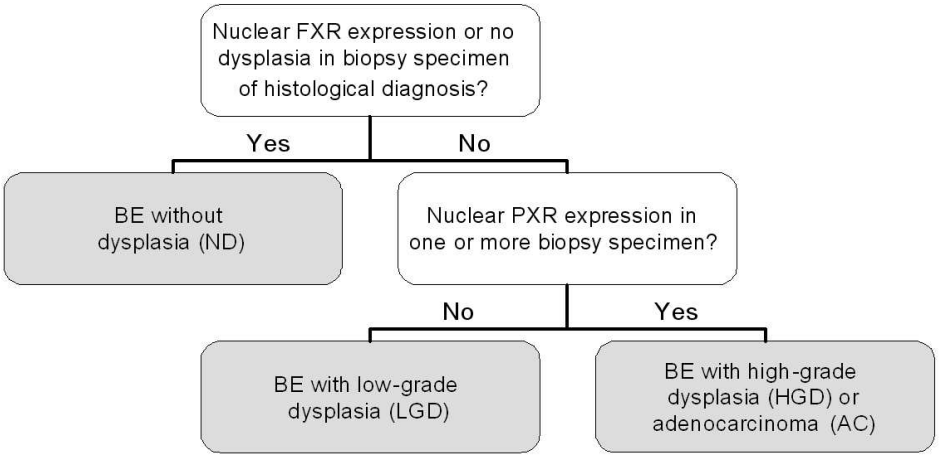

Figure 6. Decision chart combining FXR and PXR results as tool for histologic grading. FXR positivity in tissue of histologic diagnosis is indicative for ND. Of the FXR negative cases, PXR positivity in any of the specimen taken during biopsy is an indication for HGD or adenocarcinoma whereas PXR negative cases are likely to be LGD patients.
102x53mm (300 x 300 DPI)

r Review