



Changes in the expression of Oestrogen Receptors and E-cadherin as molecular markers of progression from normal epithelium to invasive cancer in elderly patients with vulvar squamous cell carcinoma: a pilot study

Journal:	<i>Histopathology</i>
Manuscript ID:	HISTOP-09-09-0515.R2
Manuscript Type:	Original Article
Date Submitted by the Author:	23-Mar-2010
Complete List of Authors:	Zannoni, Gian Franco; Catholic University of the Sacred Heart, Histopathology Prisco, Maria Grazia; Catholic University of the Sacred Heart, Obstetrics and Gynecology Vellone, Valerio Gaetano; Catholic University of the Sacred Heart, Histopathology; Catholic University of the Sacred Heart, Obstetrics and Gynecology De Stefano, Ilaria; Catholic University of the Sacred Heart, Obstetrics and Gynecology Scambia, Giovanni; Catholic University of the Sacred Heart, Obstetrics and Gynecology Gallo, Daniela; Catholic University of the Sacred Heart, Obstetrics and Gynecology
Keywords:	Vulva , Premalignancy, Cancer, Oestrogen , E-cadherin



Changes in the expression of Oestrogen Receptors and E-cadherin as molecular markers of progression from normal epithelium to invasive cancer in elderly patients with vulvar squamous cell carcinoma: a pilot study

Gian Franco Zannoni^{1*}, Maria Grazia Prisco^{2*}, Valerio Gaetano Vellone^{1,2}, Ilaria De Stefano², Giovanni Scambia², Daniela Gallo².

¹Department of Histopathology, ²Department of Obstetrics and Gynaecology, Catholic University of the Sacred Heart, Rome, Italy

*These Authors contribute equally to this work.

Running title: Oestrogen receptors in vulvar cancer

Correspondence to:

Dr. Daniela Gallo

Department of Obstetrics and Gynaecology

Catholic University of the Sacred Heart, Rome, Italy

Largo A. Gemelli, 8 - 00168 - Rome - Italy

Tel. +39 06 3013337

FAX +39 06 3051160

e-mail: d.gallo@rm.unicatt.it

ABSTRACT

Aim-The most common vulvar squamous cell carcinoma (conventional SCC) occurs in elderly women and develops following a HPV-negative pathway. Since the highest incidence of conventional SCC is observed in patients with low oestrogen levels (postmenopausal women), we sought to investigate whether hormonal factors could play a role in the development of cancer.

Methods and Results-The expression profile of oestrogen receptor α (ER α), ER β , and PR, in a section containing both normal and tumour tissue, as well as the SCC-associated vulvar lesion, was evaluated in thirty-four elderly patients. Besides, since recent studies have identified E-cadherin as a novel transcriptional target of oestrogen signalling, the modulation of this Epithelial-Mesenchymal-Transition (EMT) marker was studied. Finally, the expression of the proliferation marker Ki67 and of the apoptotic marker p53 was assessed. Results showed that changes in both ER α and ER β expression characterize the transition from normal epithelium to cancer in patients with vulvar SCC: ER α was lost in cancer, while ER β decreased, mainly showing cytoplasmic localization. A reduction in the expression of E-cadherin was also observed in tumours, compared with normal epithelium. **Conclusion**-Data from the present pilot study puts the ER signalling pathway into the spotlight as a potentially important player in vulvar carcinogenesis.

Key words: Vulva, Premalignancy, Cancer, Oestrogen , E-cadherin.

INTRODUCTION

It has been estimated that in 2002 vulvar cancer represented about 3% of all gynaecologic cancers. It accounted for 26,800 cases, with the incidence rate higher than 1.5 per 100,000 women in North America, South America and Europe, and lower than 1.0 per 100,000 in developing countries.¹ According to NCI's SEER Cancer Statistics Review, an estimated 3,460 cases of vulvar cancer were expected to be diagnosed in the USA in 2009, with about 900 women dying of it (<http://www.cancer.gov/cancertopics/types/vulvar>). Notably, vulvar carcinoma is encountered most frequently in post menopause, with more than 50% of cases diagnosed over the age of 70, and incidence rate peaking in women aged 75 and older.¹ There are two different types of vulvar SCC. The less common one consists of mainly non-keratinizing carcinomas, and mainly affects younger women. It is caused by infection with high-risk human papillomavirus (HPV), predominantly HPV 16 and 18, and it is associated with usual vulvar intraepithelial neoplasia (VIN, also known as Bowenoid or classic VIN, basaloid or warty subtype).² On the other hand, the most common vulvar SCC occurs in elderly women, leads to mostly differentiated keratinizing SCC, and develops following a HPV-negative pathway. Its premalignancy, differentiated (or simplex) VIN (dVIN) can be difficult to distinguish from benign vulvar lesion or normal epithelium;² dVIN is highly proliferative, and it is assumed that it might rapidly progress into an invasive neoplasm, since it is seldom found without vulvar carcinoma, and it is often adjacent to HPV-negative vulvar SCC.^{3,4} Within recent years, it has also clearly emerged that HPV-negative invasive SCC in elderly women is often associated with squamous cell hyperplasia (SCH) or lichen sclerosus (LS) in the adjacent tissue. The nature of this interrelationship is obscure, and these two conditions are usually considered to be of a fully benign, non-neoplastic nature. Indeed, longitudinal studies report only a slight tendency for LS to evolve into SCC (2–6%); similarly, some Authors claim a role for SCH in the development of HPV-negative vulvar SCC, but the exact pathway remains to be elucidated.² Overall, relatively little is known about molecular changes in the genesis of vulvar cancer, and only a few studies have fully taken into account the heterogeneous nature of this form of neoplasia; in

particular the exact pathogenesis from LS to differentiated VIN, and subsequent SCC, is unknown. The lack of knowledge of vulvar SCC oncogenesis, and the malignant potential of preneoplastic lesions, result into the absence of an evidence-based protocol for the optimal treatment and follow-up of patients.

In this context, we have been intrigued by the observation that the highest incidence of conventional keratinizing SCC is observed in patients with low oestrogen physiological state (postmenopausal women), this suggesting that hormonal factors could actually play a role in the development of cancer. It has been previously reported that the epithelial malignancies arising from the vulva are usually not hormonally sensitive, since no ER α expression was recorded in vulvar cancer.⁵ However, the recent discovery of a second oestrogen receptor, termed ER β , has shed new light on the oestrogen signalling pathway, powerfully indicating that the mechanism of oestrogen action is far more complex than anticipated. Human ER β has a structure highly homologous to the previously known human ER (now termed ER α), and oestrogen are known to bind ER β with affinity similar to ER α . Both isoforms regulate gene transcription by direct binding to the oestrogen-regulated element (ERE), or indirectly, by protein-protein interaction with transcription factor activator protein-1 (AP-1), and Sp1: depending on cell type, promoter context, and ligand, ER β may antagonize ER α -induced transactivation.⁶ Both oestrogen receptors have been identified in the normal vulvar epithelium, by biochemical, immunohistochemical, and molecular techniques,^{7,8} but, so far, no studies have investigated their possible role in the transition from normal epithelium to invasive vulvar cancer.

The aim of the present study was to examine the modulation of ER α , ER β and PR in the normal vulva and in the SCC developing in elderly patients, extending the evaluation to vulvar lesions adjacent to SCC. In addition, since recent studies have identified E-cadherin as a novel transcriptional target of oestrogen signalling,^{9,10} the expression of this EMT marker was also studied. The expression of proliferation marker Ki67, and apoptotic marker p53 was assessed, and used as molecular indication of vulvar premalignant and malignant lesions. The results obtained

suggest that changes in the expression and localization of oestrogen receptors might be key events in human vulvar tumorigenesis, although further studies are needed to confirm these preliminary observation, and to clarify the involved pathways. In addition, it would be helpful to verify whether routine assessment of their expression might serve as a marker of risk of disease progression.

For Peer Review

MATERIAL AND METHODS

This study was conducted on 34 patients who underwent surgical resection of vulvar cancer at the Gynaecologic Oncology Unit, Catholic University of Rome. In our Institution a written informed consent is routinely requested to patients for collection of their clinical data, and paraffin embedded sections for research use. Vulvar specimens included exclusively wide excisions, hemivulvectomy and radical vulvectomy undertaken for cure. No patient received preoperative chemotherapy or radiotherapy. Carcinomas were graded according to Frankman and colleagues¹¹ into grade 1 well differentiated neoplasms (G1), grade 2 moderately differentiated (G2) and grade 3 poorly differentiated (G3). Staging of vulvar SCCs was performed according to the FIGO Classification.¹² A representative block containing both normal and tumour tissue, as well as the SCC-associated vulvar lesion, was chosen for each patient. None of the samples displayed morphological evidence of HPV infection. Median age was 73 years (range 62–87). The patients, all in menopause for at least 10 years, had never undergone hormone replacement therapy. The body mass index (BMI) was calculated using the National Institutes of Health on-line BMI calculator (<http://www.nhlbisupport.com/bmi/>). Median BMI was 28.3 (range 20–33.2). Information concerning depth of invasion and nodal metastases was obtained from a review of pathology reports. The overall characteristics of the patients are listed in Table 1A.

Immunohistochemistry

Three-micrometer-thick paraffin sections were mounted on Superfrost coated slides and dried overnight. The sections were deparaffinised in xylene and rehydrated in graded solutions of ethanol; the endogenous peroxidase was blocked with 3% H₂O₂ for 5 min. Conditions for antigen retrieval, incubation times and primary antibodies used are described in Table 1B. To reduce non specific binding, the sections were incubated with 20% normal goat serum for 30 min, at room temperature. Sections were incubated with the secondary anti-mouse/rabbit EnVision System-HRP (DakoCytomation, Carpinteria, CA, USA) for 30 min, at room temperature. The slides were

developed with diaminobenzidine (DAB substrate System, DakoCytomation), counterstained with Mayer's Haematoxylin, dehydrated in ethanol and xylene and finally mounted.

Evaluation of immunohistochemical staining

The analysis of all tissue sections was performed by two of the authors (GFZ and VGV). In case of disagreement, sections were submitted to a rejoin evaluation by a multiheaded microscope. Expression was evaluated by considering the percentage of cells exhibiting immunoreaction as well as the intracellular localization of signalling. In normal tissues and in SCC-associated vulvar lesions, analysis was restricted to the epithelial component, where the number of positive (brown stained) cells in a random field of 300 cells was counted; the reactivity pattern of cell positivity was also recorded (i.e. basal, lower-, middle-, upper-third of the epithelium, or diffuse). In tumours, the number of positive cells was counted in five separate fields of 100 cells each (total number 500 tumour cells). Ki67 and p53 staining index was expressed as the mean percentage of positively stained nuclei in relation to the total number of epithelial- or tumour-cell nuclei considered. E-cadherin staining index was expressed as the mean percentage of cells with positive membrane staining in relation to the total number of epithelial- or tumour-cell nuclei considered. Scoring of ERs and PR was evaluated as previously reported^{13,14}. Briefly, the mean percentage of stained cells (both nuclear and cytoplasmic staining) was categorized as follows: 0=0%, 1=1-10%, 2=11-33%, 3=34-66%, 4=67-100%. The intensity of staining was also evaluated, and graded from 0-3, where 0=no staining, 1=weak staining, 2=moderate staining, and 3=strong staining. The two values obtained were multiplied to calculate a receptor score (maximum value 12).

Statistical analysis

Statistical analysis was performed using the GraphPad Prism5 Software. Differences between NE and SCC in the percentage of Ki67-, p53-, ER α -, ER β -, and E-cadherin-immunoreactive cases (categorical data) were analysed by the Chi-squared test; quantitative assessment of expression was analysed by the two-sided T-test, or by the nonparametric, two-sided Mann-Whitney test, as appropriate. Data relative to SCC-associated vulvar lesions was not statistically evaluated, due to

the different lesion distribution in our case series. Data is reported as mean \pm SEM. $P < 0.05$ was used as the critical level of significance.

For Peer Review

RESULTS

A representative block containing both normal and tumour tissue, as well as the SCC-associated vulvar lesion, was chosen for each patient. Squamous multilayered epithelium devoid of relevant inflammation, and displaying normally oriented cellular maturation, was considered normal epithelium (NE). Squamous cell hyperplasia (SCH) was identified by epithelial hyperplasia and hyperkeratosis, increased mitotic figures in basal and prickly cell layers, and mild dermal chronic inflammation, with no atypia. Lichen sclerosus (LS) was identified by severe hyperkeratosis, thin epidermis and presence of a homogenized band of dense fibrosis at papillary dermis. Differentiated VIN (dVIN) was identified by variable hyperplasia, keratinisation and parabasal atypia. Squamous cell carcinoma was identified by variable cytologic atypia, high mitotic rate, infiltrative pattern, and presence of keratin pearls. Representative pictures of histopathological features are reported in Figure 1A.

Ki67

Ki67 is a nuclear antigen expressed in cells during proliferative activity (Fig. 1B). In NE, 62% of cases showed Ki67 positivity, with a mean value of $2.1 \pm 0.2\%$ labelled cells (Fig. 1C); positivity was restricted to the lower third of the epithelium and consistently characterized by a negative basal cell layer. Very strong Ki67-staining was observed in all SCCs (100%), with a mean value of $32.6 \pm 3.0\%$ labelled cells (Fig. 1C). These differences achieved statistical significance ($p < 0.001$).

Ki67 expression was recorded in 94, 100 and 100% of SCHs, LSs and dVINs adjacent to SCC, with mean values of 8.2 ± 3 , 3.2 ± 1.0 , and $13.6 \pm 3.0\%$ labelled cells, respectively (Fig. 1C). Notably, positivity in SCHs was almost confined to the lower third of the epithelium, with basal layer cells occasionally stained; in LSs, basal layer cells were consistently stained; in dVINs immunopositivity was seen in both the lower and the middle third of the epithelium, with noticeable staining in the basal layer in all cases.

p53

p53 immunoreactivity was recognized as a nuclear staining signal (Fig. 2A). In NE, 32% of cases were positive for p53, with a mean value of $2.5 \pm 0.3\%$ labelled cells (Fig. 2B); positivity was restricted to the lower third of the epithelium, showing expression in the basal layer only in 5 cases. All but one SCCs showed immunopositivity (97%), with a mean value of $66 \pm 5.2\%$ labelled cells (Fig. 2B). These differences achieved statistical significance ($p < 0.001$). The absence of p53 expression in one of the SCCs could be due to several factors, as a complete gene deletion, or a frameshift, or a nonsense gene mutation, which has altered the structure of the p53 protein, so that it is no longer detectable by the primary antibody used.

p53 expression was recorded in 31, 80 and 100% of SCHs, LSs and dVINs adjacent to SCC, with mean values of 6.0 ± 1.0 , 14.5 ± 6.0 , and $46.0 \pm 4.0\%$ labelled cells, respectively (Fig. 2B). Positivity in lesions was mainly evident in the lower and the middle third of the epithelium, with basal cell layer labelling observed in LSs and dVINs; in dVINs, p53 staining occasionally extended to the upper epithelium.

ER α

ER α immunoreactivity was recognized as a nuclear staining signal (Fig. 3A). In NE, 44% of cases showed expression, with a mean receptor score value of 4.6 ± 0.8 (Fig. 3B). Positivity was evident in the lower and the middle third of the epithelium, with basal cells consistently stained (Fig. 3A). Conversely, only one case was stained in SCCs ($p < 0.001$ vs NEs), with a receptor score of 9 (Fig. 3B).

Immunopositivity for ER α was recorded in 31, and 20 % of SCHs, and LSs adjacent to SCC, with receptor score values of 7.2 ± 1.8 , and 3, respectively. Signal was evident in the lower and the middle third of the epithelium. No expression was seen in dVINs associated with SCC (Fig. 3B). A really intriguing finding was observed in one case, which showed an abrupt interruption of labelling at the point of morphological transition from NE to dVIN (Fig. 3C).

ER β

N-terminal-specific polyclonal ER β antibody, which would recognize all ER β isoforms, was used in this study. In NE, strong ER β staining was found in all examined specimens, although with a different intracellular localization: 79% of cases showed an exclusively nuclear localization, 6% showed only cytoplasmic staining, and 15% exhibited both nuclear and cytoplasmic staining, (Fig. 4A and B). The corresponding mean receptor score values were 10.2 ± 0.6 , 8.5 ± 0.5 , and 12.0 ± 0 for nuclear, cytoplasmic and nuclear/cytoplasmic localization, respectively (Fig. 4A and B). In all cases examined positivity extended to the whole epithelium. On the other hand, 82% of SCC cases showed low cytoplasmic immunopositivity, while the remaining 18% exhibited nuclear/cytoplasmic localization ($p<0.001$ vs NEs), with a receptor score of 6.3 ± 0.7 , and 9.7 ± 1.4 , respectively (Fig. 4A and B).

Immunopositivity for ER β in the SCHs adjacent to SCC was seen to be nuclear in 25%, cytoplasmic in 50%, and nuclear/cytoplasmic in 25% of cases; the mean receptor score was 7.5 ± 0.9 , 5.7 ± 1.1 , and 8.0 ± 4.0 in the different intracellular compartments, respectively (Fig. 4B). In LSs, staining was nuclear in 40%, cytoplasmic in 20%, and nuclear/cytoplasmic in 40% of cases; the receptor score was 7.3 ± 3.3 , 8.0, and 3.0 ± 0 , in the different intracellular compartments (Fig. 4B). Finally, in dVINs, staining was cytoplasmic in 23%, and nuclear/cytoplasmic in 77% of cases, with a mean receptor score of 7.3 ± 2.4 and 8.0 ± 1.2 , in the different intracellular compartments (Fig. 4B). In all lesions examined, staining covered the entire epithelium.

PR (A+B)

An antibody which would recognize the N-terminal region of both PRA and PRB isoforms, was used in this study. In keeping with previous findings¹⁵, we found only occasional PR-positive cells in the epithelium of either normal tissues, SCC-associated vulvar lesions or SCCs examined. Due to the scantiness, it was not possible to perform quantification (Fig. 4C).

E-cadherin

E-cadherin immunoreactivity was recognized as a membrane staining signal (Fig. 5A). In NE, all cases (100%) showed positivity, with a mean value of $77.4\pm 2.3\%$ labelled cells, mainly in the lower and the middle third of the epithelium, and with expression in the basal cell layer; staining intensity was low to moderate (Fig. 5A and B). Conversely, only 26% of cases were stained in SCCs, with a mean value of $26.7\pm 7.9\%$ labelled cells (Fig. 5A and B). These differences achieved statistical significance ($p<0.001$).

All SCC-associated vulvar lesions displayed immunopositivity for E-cadherin in the lower and the middle third of the epithelium, with mean values of 60.0 ± 4.4 , 48.0 ± 10.0 , and $57.7\pm 4.9\%$ labelled cells, in SCHs, LSs, and dVINs, respectively (Fig. 5B).

DISCUSSION

Results from the present study demonstrated that changes in both ER α and ER β protein expression tightly characterize the transition from normal epithelium to invasive cancer in elderly patients with vulvar squamous cell carcinomas. These changes were associated with a significant reduction in the expression of E-cadherin in tumours when compared to normal epithelium.

ER β was the predominant steroid receptor in normal vulvar epithelium, with almost all patients showing strong nuclear positivity; on the other hand, positivity for ER α was limited to only 44% of cases. Overall, our data is in keeping with previous findings showing that ER β prevails over ER α in the vulvar epidermis as in the skin.^{8,16,17}

One of the most striking observations to emerge in our study was the shift from a mainly nuclear to a mainly cytoplasmic ER β staining in the transition from normal epithelium to vulvar malignancy, this change being associated with a reduced protein expression. A deregulated profile was also noticed in SCC-associated vulvar lesions. Cytoplasmic ER β staining has been reported in several studies and it is likely to be genuine and not a staining artefact. Indeed, other Authors have already reported a cytoplasmic ER β localization in different tumours, as breast¹⁸ and lung¹⁹, suggesting that, in cancer cells, endogenous ER β could be sequestered in the cytoplasm by a splice variant of metastatic tumour antigen-1 (MTA1s).¹⁹ Besides, a decreased ER β expression compared with normal tissue has been observed also for other cancers, as mammary,²⁰ prostatic,²¹ ovarian,²² and colorectal carcinoma.²³ Noteworthy, we have recently reported that a reduction in the ER β levels of mouse skin high-risk papillomas (pre-malignant lesions progressing to skin SCC) could, at least partially, account for an increased susceptibility to skin SCC observed in ovariectomized female mice when compared to intact controls.²⁴

A clear reduction in the percent of ER α immunoreactive specimens was another significant finding observed in the present study, when comparing NEs to SCCs, with the same trend noticed in SCC-associated vulvar lesions, particularly dVINs, which were always negative. Overall, our data is in

keeping with previous results showing that expression of ER α is completely lost in vulvar cancer, which, for this reason, is considered not hormonally sensitive.⁵

What mechanism accounts for the altered expression of ERs in tumours, and what mechanism allows ERs dysfunction, especially loss of expression, to promote tumour progression, remain open questions. In order to partially address this issue, we evaluated the profile of E-cadherin expression in NEs, SCC-associated vulvar lesions, and tumours. It has long been recognized that the cell–cell adhesion receptor, E-cadherin, is an important determinant of tumour progression, serving as a suppressor of invasion and metastasis in many contexts. Accordingly, loss of E-cadherin function has been found widespread in sporadically arising epithelial tumours and is thought to be an important step in the development of most, if not all, epithelial-derived tumour types.²⁵ Besides, and importantly, there is a growing body of evidence supporting the existence of a strong connection between oestrogen signalling and E-cadherin expression, although the molecular mechanisms and the final outcomes of this connection remain ambiguous. A most credited hypothesis suggests that unliganded- and liganded- ER α exert opposite effects on E-cadherin gene transcription (stimulation and inhibition, respectively), while ER β always acts to maintain high E-cadherin protein level.^{9,10,26}

In this context, we could speculate that the deregulation in oestrogen receptor expression observed in vulvar cancer can be a key event in suppressing E-cadherin levels in tumour cells, thus promoting cancer progression. However, further studies are warranted to support this hypothesis, and clarify the mechanisms responsible for the decreased expression of ERs in tumours. Besides, also the possible role of different endogenous oestrogen levels on the final vulvar tumour outcome should be addressed in greater detail in future studies. Indeed, the possibility of non-ovarian sources of oestrogen could not be excluded in our study since more than 80% of patients were overweight or obese (according to their BMIs), and data stratification according to BMI values was hardly achievable, considering the limited number of case series, and the homogenous distribution of patients.

Other findings observed in the present study confirm previous literature data. As expected, a very low positivity of Ki67 and p53 was noticed in NEs, while a high positivity of both proteins was seen in SCCs, in keeping with findings by other Authors.^{27,28} Interestingly, we noticed that NEs adjacent to dVINs tended to show higher levels of both proteins (data not shown), this suggesting that normal-looking epithelium of cancer patients can harbour occult genetic alterations, which can function as markers of disease extension. As expected, and consistently to previous data, a tendency towards a deregulated expression pattern was also observed in SCC-associated vulvar lesions (particularly LSs and dVINs)^{27,28}, where, however, a possible effect of the close tumour microenvironment cannot be discounted. **In this regard, in order to ensure that a non-invasive lesion is being assessed, future studies should examine cases of dVIN distant from invasive cancers or not concurrently associated with tumour.**

In conclusion, data from the present study, although needing a confirm in a larger population, has led us to the striking results that ERs expression is altered when vulva turn cancerous, thus putting the ER signalling pathway into the spotlight as a potentially important player in vulvar carcinogenesis. Assessment of the oestrogen receptor status profile should now be considered in translational arms of vulvar cancer trials, where its potential clinical role can be addressed more rigorously. Besides, additional experimental studies are needed to understand the molecular basis of this disease.

Author Disclosure

GF Zannoni, MG Prisco, VG Vellone, I De Stefano, G. Scambia, and D Gallo, no conflicts of interest.

For Peer Review

Acknowledgements

We thank Dr. Ferdinando Coronetta (Department of Obstetrics and Gynecology, Catholic University of the Sacred Heart, Rome, Italy) for his skilful technical assistance in the experiments.

For Peer Review

REFERENCES

1. Sankaranarayanan R, Ferlay J. Worldwide burden of gynaecological cancer: The size of the problem. *Best Pract Res Clin Obstet Gynaecol.* 2006; **20**; 207-25.
2. van de Nieuwenhof HP, van der Avoort IA, de Hullu JA. Review of squamous premalignant vulvar lesions. *Crit Rev Oncol Hematol.* 2008; **68**; 131-56. Review.
3. Yang B, Hart WR. Vulvar intraepithelial neoplasia of the simplex (differentiated) type: a clinicopathologic study including analysis of HPV and p53 expression. *Am J Surg Pathol.* 2000; **24**; 429-41.
4. Fox H, Wells M. Recent advances in the pathology of the vulva. *Histopathology.* 2003; **42**; 209-16.
5. Mosny DS, Brito F, Bender HG. Immunohistochemical investigations of estrogen receptors in normal and neoplastic squamous epithelium of the vulva. *Reprod Med.* 1990; **35**; 1005-7.
6. Heldring N, Pike A, Andersson S, et al. Estrogen receptors: how do they signal and what are their targets. *Physiol Rev.* 2007; **87**; 905-31. Review.
7. Schwartz PE. The oestrogen receptor (ER) in vulva, vagina and ovary. *Eur J Cancer.* 2000; **36** Suppl 4; S31-2.
8. Taylor AH, Guzail M, Al-Azzawi F. Differential expression of oestrogen receptor isoforms and androgen receptor in the normal vulva and vagina compared with vulval lichen sclerosus and chronic vaginitis. *Br J Dermatol.* 2008; **158**; 319-28.
9. Helguero LA, Lindberg K, Gardmo C, Schwend T, Gustafsson JA, Haldosén LA. Different roles of estrogen receptors alpha and beta in the regulation of E-cadherin protein levels in a mouse mammary epithelial cell line. *Cancer Res.* 2008; **68**; 8695-704.
10. Park SH, Cheung LW, Wong AS, Leung PC. Estrogen regulates Snail and Slug in the down-regulation of E-cadherin and induces metastatic potential of ovarian cancer cells through estrogen receptor alpha. *Mol Endocrinol.* 2008; **22**; 2085-98.

11. Frankman O, Kabulski Z, Nilsson B, Silfverswärd C. Prognostic factors in invasive squamous cell carcinoma of the vulva. *Int J Gynaecol Obstet*. 1991; **36**; 219-28
12. Vulva. In: *American Joint Committee on Cancer: AJCC Cancer Staging Manual*. 6th ed. New York, NY: Springer, 2002; 243-9.
13. Hayat MA. Estrogens. In: *Microscopy, immunohistochemistry, and antigen retrieval methods for light and electron microscopy*. Kluwer Academic/Plenum Publishers, New York, NY, 2002; 276-277.
14. Gallo D, Zannoni GF, Martinelli E, et al. Estradiol and phytoestrogens differently influence the rodent postmenopausal mammary gland. *Menopause*. 2006;**13** ;72-9.
15. Hodgins MB, Spike RC, Mackie RM, MacLean AB. An immunohistochemical study of androgen, oestrogen and progesterone receptors in the vulva and vagina. *Br J Obstet Gynaecol* 1998; **105**; 216-22.
16. Johannesson U, Sahlin L, Masironi B, Rylander E, Bohm-Starke N. Steroid receptor expression in the vulvar vestibular mucosa--effects of oral contraceptives and menstrual cycle *Contraception*. 2007; **76**; 319-25.
17. Thornton MJ. The biological actions of estrogens on skin. *Exp Dermatol*. 2002; **11**; 487-502. Review.
18. Shaaban AM, Green AR, Karthik S, et al. Nuclear and cytoplasmic expression of ERbeta1, ERbeta2, and ERbeta5 identifies distinct prognostic outcome for breast cancer patients. *Clin Cancer Res*. 2008; **14**; 5228-35
19. Zhang G, Liu X, Farkas AM, et al. Estrogen receptor beta functions through nongenomic mechanisms in lung cancer cells. *Mol Endocrinol*. 2009; **23**; 146-56.
20. Roger P, Sahla ME, Makela S, Gustafsson JA, Baldet P, Rochefort H. Decreased expression of estrogen receptor beta protein in proliferative preinvasive mammary tumors. *Cancer Res*. 2001; **61**; 2537-41

21. Horvath LG, Henshall SM, Lee CS, et al. Frequent loss of estrogen receptor-beta expression in prostate cancer. *Cancer Res.* 2001; **61**; 5331–5.
22. Lazennec G. Estrogen receptor beta, a possible tumor suppressor involved in ovarian carcinogenesis. *Cancer Lett.* 2006; **231**; 151-7. Review.
23. Foley EF, Jazaeri AA, Shupnik MA, Jazaeri O, Rice LW. Selective loss of estrogen receptor beta in malignant human colon. *Cancer Res.* 2000; **60**; 245–8.
24. Mancuso M, Gallo D, Leonardi S, et al. Modulation of basal and squamous cell carcinoma by endogenous estrogen in mouse models of skin cancer. *Carcinogenesis.* 2009; **30**; 340-7.
25. Jeanes A, Gottardi CJ, Yap AS. Cadherins and cancer: how does cadherin dysfunction promote tumor progression? *Oncogene.* 2008; **27**; 6920-9. Review.
26. Cardamone MD, Bardella C, Gutierrez A, et al. ERalpha as ligand-independent activator of CDH-1 regulates determination and maintenance of epithelial morphology in breast cancer cells. *Proc Natl Acad Sci U S A.* 2009; **106**; 7420-5.
27. Chiesa-Vottero A, Dvoretzky PM, Hart WR. Histopathologic study of thin vulvar squamous cell carcinomas and associated cutaneous lesions: a correlative study of 48 tumors in 44 patients with analysis of adjacent vulvar intraepithelial neoplasia types and lichen sclerosus. *Am J Surg Pathol.* 2006; **30**; 310-8.
28. van der Avoort IA, van der Laak JA, Paffen A, et al. MIB1 expression in basal cell layer: a diagnostic tool to identify premalignancies of the vulva. *Mod Pathol.* 2007; **20**; 770-8.

Legends to figures

Figure 1 - A) HE staining of normal vulvar epithelium (NE), squamous cell hyperplasia (SCH), lichen sclerosus (LS), differentiated vulvar intraepithelial neoplasia (dVIN), and squamous cell carcinoma (SCC). Magnification 10x, inset 40x. **B)** Representative pictures for Ki-67 immunostaining showing very low expression in NE, and diffusely strong positive expression in SCC. Magnification 10x, inset 40x. **C)** *Upper left and right* - Bar chart showing the percentage of Ki67 immunoreactive specimens in NE and SCC, and the % of positive cells in immunoreactive specimens (mean \pm SEM). ***= $p < 0.001$ vs NE. *Lower left and right* - Bar chart showing the percentage of Ki67 immunoreactive specimens in SCH, LS, and dVIN, and the % of Ki67 positive cells in immunoreactive specimens (mean \pm SEM).

Figure 2 - A) Representative pictures for p53 immunostaining showing no expression in NE, and diffusely strong positive expression in SCC. Magnification 10x, inset 40x. **B)** *Upper left and right* - Bar chart showing the percentage of p53 immunoreactive specimens in NE and SCC, and the % of positive cells in immunoreactive specimens (mean \pm SEM). ***= $p < 0.001$ vs NE. *Lower left and right* - Bar chart showing the percentage of p53 immunoreactive specimens in SCH, LS, and dVIN, and the % of positive cells in immunoreactive specimens (mean \pm SEM). See Figure 1 for legend.

Figure 3 - A) Representative pictures for ER α immunostaining showing nuclear protein expression in NE (high-labelled specimen), and no expression in SCC. Magnification 10x, inset 40x. **B)** *Upper left and right* - Bar chart showing the percentage of ER α immunoreactive specimens in NE and SCC, and the receptor score of immunoreactive specimens (mean \pm SEM). ***= $p < 0.001$ vs NE. *Lower left and right* - Bar chart showing the percentage of ER α immunoreactive specimens in SCH, LS, and dVIN, and the receptor score of immunoreactive specimens (mean \pm SEM). **C)** A single case showing an abrupt interruption of ER α labelling in the epithelium at the point of transition from NE to dVIN (note the positive staining in the stroma). See Figure 1 for legend.

Figure 4 - A) Representative pictures for ER β immunostaining showing a strong and mainly nuclear protein expression in normal epithelial cells, while reduced expression, mainly cytoplasmic, was evident in SCC. Magnification 10x, inset 40x. **B)** *Upper left and right* – All the examined samples were positive for ER β . Bar chart showing the distribution of nuclear, cytoplasmic, and nuclear/cytoplasmic ER β staining in NE and in SCC, and the receptor score of immunoreactive specimens (mean \pm SEM). ***= $p < 0.001$ vs NE. *Lower left and right* - Bar chart showing the distribution of nuclear, cytoplasmic, and nuclear/cytoplasmic ER β staining in SCH, LS, and dVIN, and the receptor score of the immunoreactive specimens (mean \pm SEM). **C)** Scanty/absent PR immunoreactivity was observed in both NE and SCC.

Figure 5 - A) Representative pictures for E-cadherin immunostaining showing high expression in NE, and no expression in SCC. Magnification 10x, inset 40x. **B)** *Upper left and right* - Bar chart showing the percentage of E-cadherin immunoreactive specimens in NE and SCC, and the % of positive cells in immunoreactive specimens (mean \pm SEM). ***= $p < 0.001$ vs NE. *Lower left and right* - Bar chart showing the percentage of E-cadherin immunoreactive specimens in SCH, LS, and dVIN, and the % of positive cells in immunoreactive specimens (mean \pm SEM). See Figure 1 for legend.

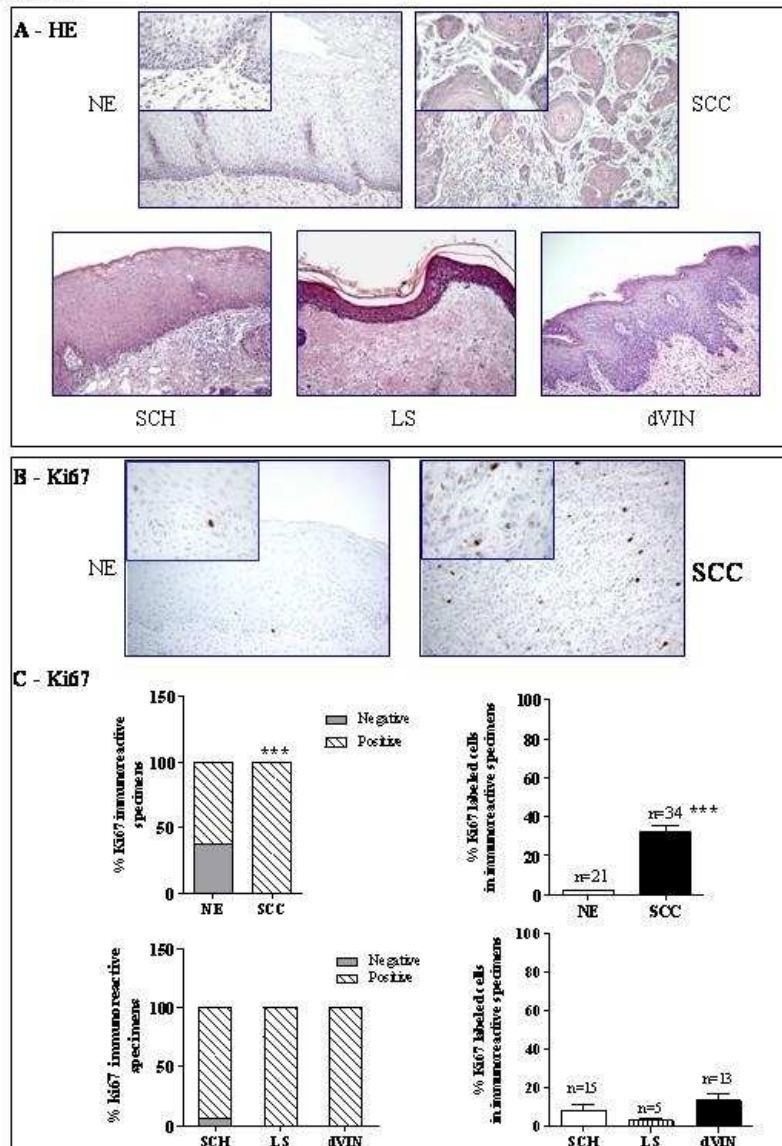
TABLE 1A Clinical-pathological features of our sample series

Features	No. of cases (%)
Normal epithelium	34
Squamous cell carcinoma (SCC)	34
with associated squamous cell hyperplasia (SCH)	16
with associated lichen sclerosus (LS)	5
with associated differentiated vulvar intraepithelial neoplasia (dVIN)	13
Median Age (range)	73 (62-87)
Median Body Mass Index (range)	28.3 (20-33.2)
Stage	
IA	1 (3)
IB	3 (9)
II	12 (35)
III	13 (38)
IVA	3 (9)
IVB	2 (6)
Grade	
1	1 (3)
2	15 (44)
3	18 (53)
Loco regional Lymph node status	
Negative	10 (29)
Positive	17 (50)
Unknown node status (no lymphadenectomy)	7 (21)

TABLE 1B Antibodies used, antigen retrieval and incubation times used for immunohistochemistry.

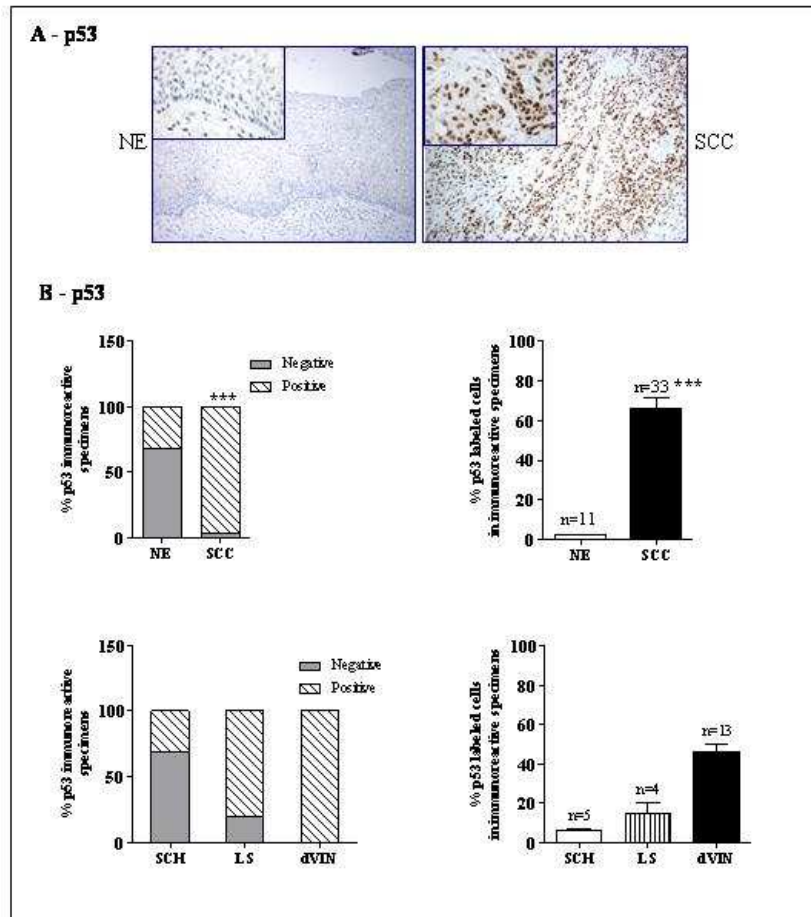
Antigen	Source	Clone	Working dilution	Antigen retrieval	Incubation time
p53	DakoCytomation	DO-7	1/50	Microwave (EDTA, pH 8.0)	1 h R.T.
Ki67	DakoCytomation	MIB-1	1/50	Microwave (Citrate, pH 6.0)	1 h R.T.
ER α	Biocare (Concord, CA, USA)	6F11	1/100	Microwave (Tris- EDTA, pH 9.0)	O.N. 4 °C
ER β	Santa Cruz (Santa Cruz, CA, USA)	H-150	1/200	Microwave (Citrate, pH 6.0)	O.N. 4 °C
PR (A+B)	Novocastra (Newcastle, UK)	16 and SAN27	1/100	Microwave (Citrate, pH 6.0)	O.N. 4 °C
E-cadherin	Santa Cruz	G-10	1/50	Microwave (Citrate, pH 6.0)	O.N. 4 °C

Figure 1



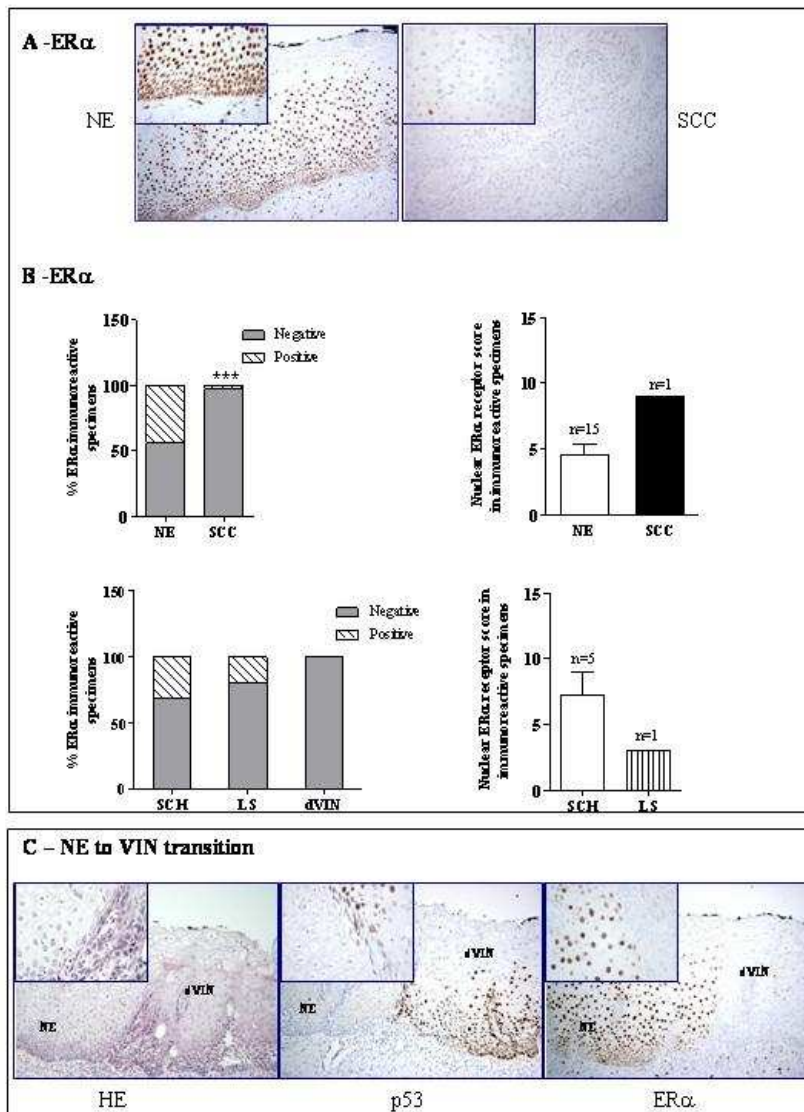
190x275mm (72 x 72 DPI)

Figure 2



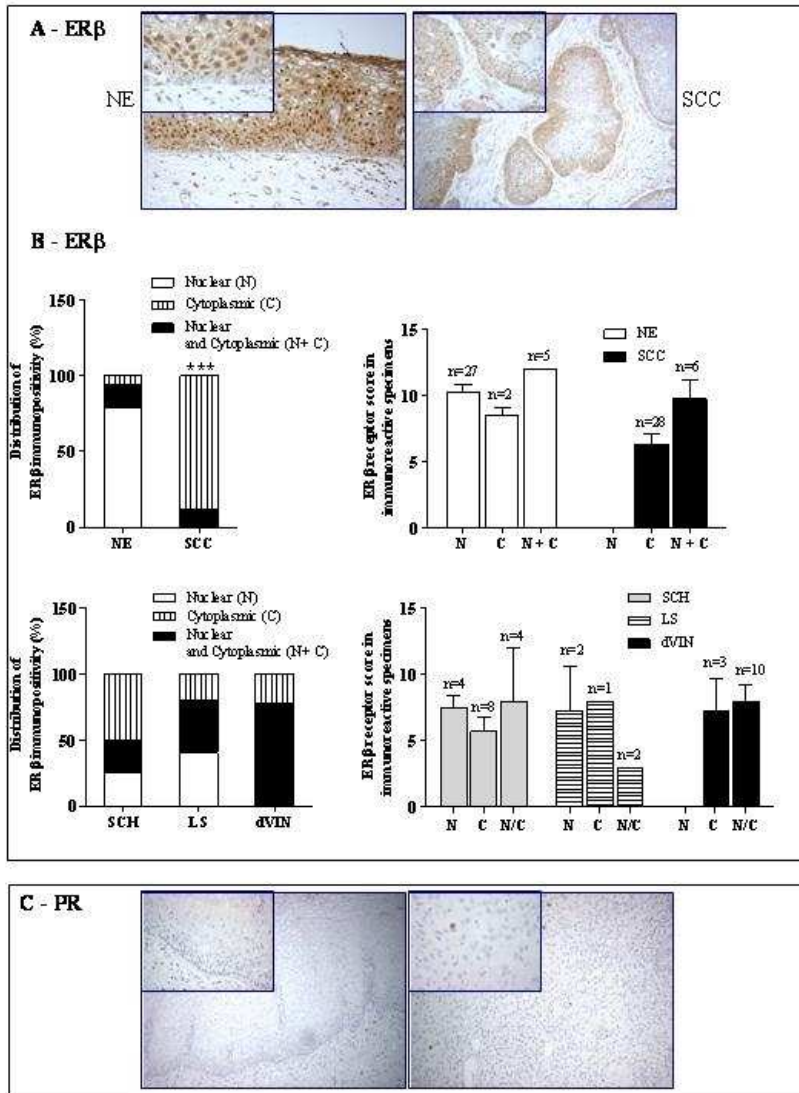
190x275mm (72 x 72 DPI)

Figure 3



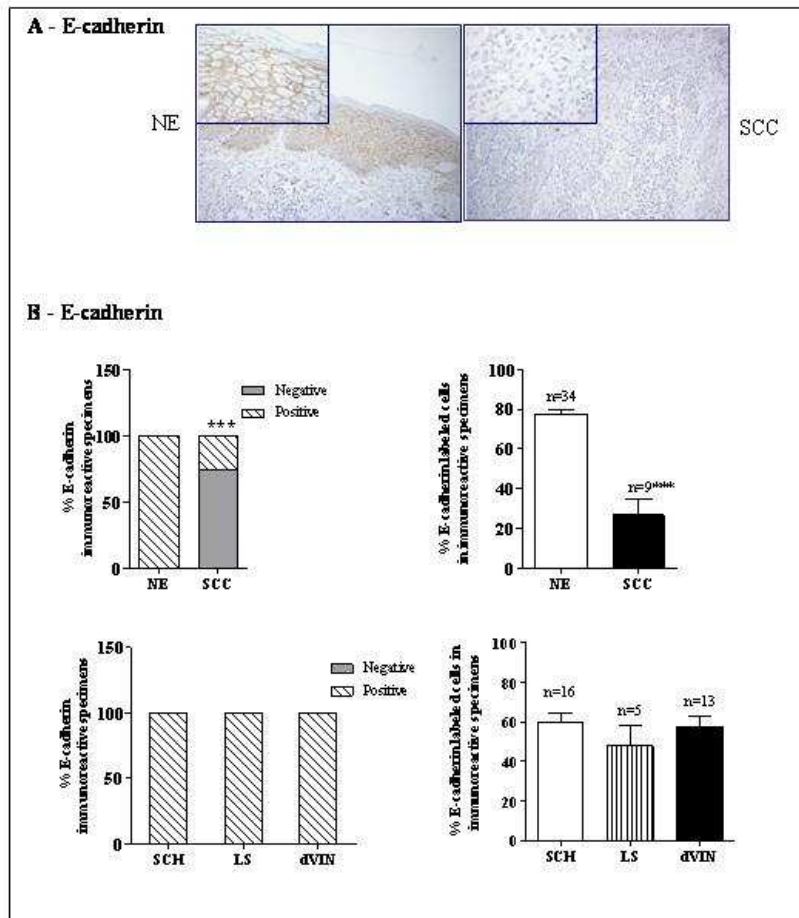
190x275mm (72 x 72 DPI)

Figure 4



190x275mm (72 x 72 DPI)

Figure 5



190x275mm (72 x 72 DPI)