



HAL
open science

Metopic and sagittal synostosis in Greig cephalopolysyndactyly syndrome: five cases with intragenic mutations or complete deletions of *GLI3*

Andrew Om Wilkie, Jane A Hurst, Dagan Jenkins, Pradeep Vasudevan, Maria Kirchhoff, Flemming Skovby, Claudine Rieubland, Sabina Gallati, Olaf Rittinger, David Johnson, et al.

► To cite this version:

Andrew Om Wilkie, Jane A Hurst, Dagan Jenkins, Pradeep Vasudevan, Maria Kirchhoff, et al.. Metopic and sagittal synostosis in Greig cephalopolysyndactyly syndrome: five cases with intragenic mutations or complete deletions of *GLI3*. *European Journal of Human Genetics*, 2011, 10.1038/ejhg.2011.13 . hal-00614743

HAL Id: hal-00614743

<https://hal.science/hal-00614743>

Submitted on 16 Aug 2011

HAL is a multi-disciplinary open access archive for the deposit and dissemination of scientific research documents, whether they are published or not. The documents may come from teaching and research institutions in France or abroad, or from public or private research centers.

L'archive ouverte pluridisciplinaire **HAL**, est destinée au dépôt et à la diffusion de documents scientifiques de niveau recherche, publiés ou non, émanant des établissements d'enseignement et de recherche français ou étrangers, des laboratoires publics ou privés.

Metopic and sagittal synostosis in Greig cephalopolysyndactyly syndrome: five cases with intragenic mutations or complete deletions of *GLI3*

Jane A Hurst^{1,2}, Dagan Jenkins³, Pradeep C Vasudevan⁴, Maria Kirchhoff⁵, Flemming Skovby⁵, Claudine Rieubland⁶, Sabina Gallati⁶, Olaf Rittinger⁷, Peter M Kroisel⁸, David Johnson², Leslie G Biesecker⁹, Andrew OM Wilkie^{*,1,2,3}

¹Department of Clinical Genetics and ²Craniofacial Unit, Oxford Radcliffe Hospitals NHS Trust, Oxford, UK; ³Weatherall Institute of Molecular Medicine, University of Oxford, Oxford, UK; ⁴Department of Clinical Genetics, University Hospitals of Leicester NHS Trust, Leicester, UK; ⁵Department of Clinical Genetics, University Hospital of Copenhagen, Copenhagen, Denmark; ⁶Oberärztin Humangenetik, Medizinische Universitäts-Kinderklinik Inselspital, Bern, Switzerland; ⁷Children's Hospital, Paracelsus Medical University, Salzburg, Austria; ⁸Institute of Human Genetics, Medical University of Graz, Graz, Austria; ⁹National Human Genome Research Institute, Bethesda, USA

*Correspondence to Prof Andrew OM Wilkie

Weatherall Institute of Molecular Medicine

John Radcliffe Hospital

Headington

Oxford OX3 9DS, UK

Tel: +44 1865 222619

Fax: +44 1865 222500

Email: awilkie@hammer.imm.ox.ac.uk

Running title : *GLI3* mutations and craniosynostosis

Abstract

Greig cephalopolysyndactyly syndrome (GCPS) is a multiple congenital malformation characterised by limb and craniofacial anomalies, caused by heterozygous mutation or deletion of *GLI3*. We report four boys and a girl who presented with trigonocephaly due to metopic synostosis, in association with pre- and post-axial polydactyly and cutaneous syndactyly of hands and feet. Two cases had additional sagittal synostosis. None had a family history of similar features. In all five children the diagnosis of GCPS was confirmed by molecular analysis of *GLI3* (two had intragenic mutations and three had complete gene deletions detected on array comparative genomic hybridisation), thus highlighting the importance of trigonocephaly or overt metopic or sagittal synostosis as a distinct presenting feature of GCPS. These observations confirm and extend a recently proposed association of intragenic *GLI3* mutations with metopic synostosis; moreover the three individuals with complete deletion of *GLI3* were previously considered to have Carpenter syndrome, highlighting an important source of diagnostic confusion.

Key words: trigonocephaly, metopic synostosis, sagittal synostosis, Greig cephalopolysyndactyly syndrome, *GLI3*, Carpenter syndrome

Introduction

In 1926, Greig¹ first described the condition now known as Greig cephalopolysyndactyly syndrome (GCPS, MIM 175700) in a mother and daughter with digital malformations and an unusual skull shape. The syndrome is inherited in an autosomal dominant pattern and presents with characteristic limb and craniofacial anomalies. It is highly penetrant but there is both inter- and intra-familial variability of the features.^{2,3} In the extremities there may be both preaxial and postaxial polydactyly with broad or duplicated thumbs, broad or duplicated halluces, postaxial polydactyly of hands and feet and cutaneous syndactyly of the fingers or toes. Craniofacial features include macrocephaly, prominent or broad forehead with frontal bossing, a broad base to the nose and a wide nasal bridge. Some affected individuals have learning difficulties. Developmental anomalies of the corpus callosum and mild cerebral ventriculomegaly are recognised associations. To our knowledge, trigonocephaly was described only twice in possible GCPS cases before molecular confirmation became available.^{4,5}

Following the recognition that GCPS was associated with rearrangements and translocations of 7p14.1,⁶⁻⁹ heterozygous *GLI3* mutations and deletions were identified as the cause of GCPS by Vortkamp *et al* in 1991.^{10,11} The *GLI3* gene encodes a zinc finger transcription factor that is a downstream mediator of the sonic hedgehog (SHH) pathway. In the presence of SHH, full length *GLI3* acts as a transcriptional activator, whereas in the absence of SHH, *GLI3* is cleaved to produce a repressor.¹² The phenotype of GCPS is attributable to functional haploinsufficiency of *GLI3*; when this is caused by heterozygous deletion at 7p14.1, additional developmental delay may be attributable to the deletion of contiguous gene(s).^{13,14}

Here we describe five unrelated individuals (four boys and a girl) with *GLI3* mutation-proven GCPS and a typical pattern of pre- and post-axial polydactyly, all of

whom had trigonocephaly caused by metopic synostosis, confirming that this is a non-random association. The key clinical features and results of molecular genetic analyses are summarised in Table 1.

Case reports

Patient 1 This boy (Figure 1a-c), the third child of healthy unrelated parents, was tabulated (subject G31) in the report by Johnston *et al.*¹⁵ He was born at term by normal vaginal delivery weighing 4132 g (95th centile) and noted to have a prominent metopic ridge. At 10.5 months his occipito-frontal circumference (OFC) was 48 cm (90th centile) and inner canthal distance 2.9 cm (95th centile). He had bilateral postaxial polydactyly type B of the fingers and preaxial polydactyly of the feet, with cutaneous syndactyly between the hallux and second toe and partial cutaneous syndactyly of second and third toes. Cranial computed tomography (CT) scan showed metopic and sagittal synostosis. He attained his developmental milestones normally. Corrective surgery was performed on the hands and feet at 10 months and 1 year, respectively, and trigonocephaly correction at the age of 2 years.

DNA sequencing showed a heterozygous nonsense mutation in exon 10 of *GLI3* (c.1728C>A, p.Y576X),¹⁵ which was not present in either parent. This mutation is predicted to truncate *GLI3* in the zinc finger motif and falls within the mutation spectrum previously described as associated with GCPS.^{15,16}

Patient 2 This boy (Figure 1d-f) was included in the series of patients with metopic synostosis reported by Kini *et al.*¹⁷ He was referred for craniofacial assessment at 3 years with trigonocephaly. He had healthy unrelated white British parents. He was born at term weighing 3260 g (25th centile), and was noted to have limb malformations and a trigonocephalic appearance. He had partially duplicated thumbs,

bilateral postaxial polydactyly type B of the hands and bilateral preaxial polydactyly of the halluces with cutaneous syndactyly between the duplicated halluces and the second and third toes, which have required multiple corrective surgical procedures. At 4.2 years his OFC was 52 cm (75th centile) and developmental milestones were normal. Three-dimensional cranial CT scanning demonstrated metopic synostosis. He underwent fronto-orbital advancement and remodelling at the age of 4.5 years because of parental concerns about his appearance.

DNA sequencing showed a heterozygous *de novo* 1 bp insertion after nucleotide 1793 in exon 11 of *GLI3*, causing a frameshift [c.1793dupA, p.N598KfsX7], which was not present in either parent. Similar to patient 1, this mutation is predicted to truncate *GLI3* within the zinc finger motif.

Patient 3 This girl (Figure 1g-i) was born at term to unrelated parents, with a birth weight of 2440 g (<3rd centile), length 48 cm (10th centile) and OFC 32.8 cm (3rd centile). She had broad thumbs and halluces, partial cutaneous syndactyly between the first and second toes bilaterally and between the second and third toes on the right, and a trigonocephalic shape to the forehead. A cranial CT scan confirmed metopic synostosis. Additional features were a ventricular septal defect (VSD) which closed spontaneously, moderate developmental delay (see Table 1 for details), and dysmorphic facial features (narrow palpebral fissures, a broad nasal bridge). At 15 years she was 160 cm tall (50th centile) and weight was 68 kg (91st centile). The karyotype was normal (46,XX).

A clinical diagnosis of Carpenter syndrome^{18,19} was suggested but DNA sequencing of the open reading frame of *RAB23* was normal. Array comparative genomic hybridisation (aCGH; Agilent 244K array) showed an 8.3 Mb deletion at 7p12.3-p14.1 [(40845981_40855164)_(49136714_49160830); hg18 assembly],

encompassing *GLI3* and 59 flanking RefSeq genes, which was not present in either parent (Figure 2a).

Patient 4 This boy (Figure 1j-l) was the first child born at 39 weeks to unrelated parents after a normal pregnancy, with a birth weight of 3560g (50th centile), length of 50 cm (50th centile), and head circumference of 34 cm (20th centile). The hands were normal. He had bilateral duplication of the halluces and syndactyly between the second and third toes. His head shape was abnormal with a combination of scaphocephaly and trigonocephaly. Radiology confirmed synostosis of the sagittal and metopic sutures and he had surgical correction at the age of 8 months. Additional features included laryngomalacia, atrial septal defect (ASD), VSD, and patent ductus arteriosus (PDA). He developed seizures at the age of 3 years and has severe global developmental delay (Griffiths Quotient 26 aged 4 years). Ophthalmologic examination showed horizontal nystagmus and mild optic nerve hypoplasia. His brain magnetic resonance imaging and karyotype (46,XY) were normal.

A clinical diagnosis of Carpenter syndrome was proposed, but in view of the similar clinical features to Patient 3, aCGH was performed. This showed a heterozygous 6.8 Mb deletion (39,130,081-45,492,392; hg18) of the region 7p13-p14.1, encompassing *GLI3* and 51 flanking RefSeq genes, which was not present in either parent (not illustrated).

Patient 5 This boy (Figure 1m-o) was the first child of healthy unrelated parents. He was born at term with normal length (53 cm, 90th centile), weight (3350 g, 50th centile) and OFC (33.5 cm, 10th centile). At the age of 2 weeks he was noticed to have trigonocephaly with a metopic ridge, large anterior fontanelle, low frontal hairline and upslanting palpebral fissures. X-ray confirmed premature synostosis of the metopic

suture. Additional dysmorphic facial features included a flat nasal bridge and broad nasal base. His ears had poorly formed and overfolded helices. In his hands, the thumbs were proximally inserted with broadening of the terminal phalanx and he had bilateral preaxial polydactyly of the halluces with cutaneous syndactyly of the second and third toes. His cranial ultrasound demonstrated mild ventriculomegaly and a small corpus callosum. Fundoscopy was normal. Echocardiography showed a double outlet right ventricle (DORV) with pulmonary stenosis. He had delayed motor development; he did not sit until 2 years of age and at 3.5 years was able to walk with one hand held. He had a vocabulary of about 15 words but had better receptive language skills. The karyotype was normal (46,XY).

A clinical diagnosis of Carpenter syndrome was proposed, but in view of the similar clinical features to previous cases, aCGH was performed. This demonstrated a 6.0 Mb deletion (39,213,707-45,251,621, hg18 build) at 7p13-p14.1 encompassing *GLI3* and 51 other RefSeq genes, which was not present in either parent (Figure 2c).

Discussion

This series of five patients with *GLI3* mutations associated with synostosis of the midline cranial sutures (metopic in all five cases and additional sagittal synostosis in two cases), establishes this as an important, low frequency association of GCPS. It confirms and extends the recent reports of McDonald-McGinn *et al.*,²⁰ who described two cases of metopic synostosis associated with intragenic truncating mutations of *GLI3*, and Johnston *et al.*,¹⁵ which tabulated (but did not comment on) three *GLI3* mutation positive cases with craniosynostosis - comprising Patient 1 presented here, one subject (G5-2, frameshift mutation) with metopic synostosis, and one (G34-2, missense mutation) with sagittal synostosis associated with agenesis of the corpus callosum and mild ventricular prominence.

Mutations in *GLI3*, which contains 15 exons and spans 280 kb, have been described not only in GCPS but also in Pallister-Hall syndrome (PHS), in preaxial polydactyly type IV, and in one patient previously diagnosed as acrocallosal syndrome.^{21,22} Although GCPS and PHS share some overlapping features (notably polydactyly), they are usually readily distinguished clinically. The distinction between GCPS and preaxial polydactyly type IV is based on the absence of any craniofacial features or learning difficulties in the latter condition. GCPS is caused by inactivating mutations and deletions^{13,14} that lead to haploinsufficiency, whereas PHS is caused by frameshift, nonsense and splicing mutations in the middle third of the gene, corresponding to exon 14 and parts of exons 13 and 15.^{15,16} Two of the five children reported here with GCPS had intragenic *GLI3* mutations causing premature truncation of the protein; these were located in exons 10 and 11, the region encoding the zinc finger domain, and these mutations are expected to cause GCPS. Other recently described *GLI3* mutations associated with metopic or sagittal synostosis^{15,20} were in different exons (6, 14 or 15); both mutations reported by Johnston *et al*¹⁵ were familial, but no other mutation-positive family member (total of four individuals) had craniosynostosis. Together with the identification of three complete deletions reported here, this reinforces the conclusion that midline synostosis is a low frequency association of GCPS, rather than representing a distinct genotypic or phenotypic subgroup. The single report of GCPS (case 2) in a consecutive series of 110 individuals with metopic synostosis¹⁷ indicates that *GLI3* mutations are rare in this group of patients overall.

In children with GCPS due to large chromosomal deletions, additional clinical features may be attributable to haploinsufficiency of contiguous genes in the region of 7p14.1. Multiple genes may contribute to the more severe developmental delay in these children, and deletion of *GCK* (which occurred in Patients 3-5) is potentially

associated with maturity onset diabetes of the young (MODY) type 2.¹³ In each of Patients 3-5, the combination of craniosynostosis and developmental delay had led to a presumptive diagnosis of Carpenter syndrome and referral for genetic testing. Carpenter syndrome is an autosomal recessive condition caused by biallelic mutations in *RAB23*.^{18,19} Compared to GCPS, craniosynostosis is a more consistent and severe component of Carpenter syndrome, but there is overlap of the polysyndactyly features. Other clinical features that would suggest Carpenter syndrome, rather than GCPS contiguous gene syndrome, are additional fusion of coronal or lambdoid sutures, high birth weight, umbilical hernia and hypogenitalism in males; these were all absent in Patients 3-5. Congenital heart disease, a recognised feature of Carpenter syndrome, was present in all three patients with *GLI3* deletions. Guzzetta *et al*⁵ considered both GCPS and Carpenter syndrome in the differential diagnosis of a child with polysyndactyly with trigonocephaly and partial agenesis of the corpus callosum; in the light of the new data, a *GLI3* deletion may be the most likely causation. Indeed, Patient 5 exhibited hypoplasia of the corpus callosum, a feature that could also cause confusion with acrocallosal syndrome.²¹

There has been debate whether craniosynostosis is a feature of GCPS. The early report of Hootnick and Holmes⁴ described trigonocephaly and metopic synostosis. Most authors describe a broad and or prominent forehead as a consistent part of the facial gestalt, but not metopic synostosis. Craniosynostosis was mentioned as being present in 5% of patients in the first edition of Cohen's monograph on craniosynostosis,²³ but in the second edition it was stated that no cases had been molecularly proven.²⁴ The current series of five patients, with the four other recently reported cases,^{15,20} now confirms that premature fusion of midline cranial sutures (metopic in 8/9 and sagittal in 3/9), is a feature of GCPS and is found in children both with intragenic mutations and contiguous deletions involving *GLI3*. The synostosis

caused significant trigonocephaly, requiring cranial surgery in four of the five patients presented here. Whereas metopic synostosis usually leads to significant hypotelorism, this was not evident in some cases probably owing to the counteracting effect of the *GLI3* mutation, which is associated with widely spaced eyes and macrocephaly.^{2,3}

Synostosis affecting the midline sutures (both metopic and sagittal) is heterogeneous in aetiology but shares several epidemiological characteristics:²⁵ several mechanisms may contribute to their association with *GLI3* mutations. Fetal head constraint is a predisposing factor in non-syndromic cases,^{25,26} and the macrocephaly normally associated with GCPS would be expected to enhance this effect. A wide variety of chromosome abnormalities are associated with syndromic midline synostosis, suggesting that in cases with megabase-sized deletions, reduced transduction of stretch forces exerted by the growing brain may represent a non-specific contributing factor.²⁷ However gene-specific mechanisms may also play a role, because mice homozygous null for the orthologous Gli3 protein have craniosynostosis, although surprisingly this affects the lambdoid sutures; by contrast the metopic and sagittal sutures are widened, with islands of ossification.²⁸ The excess of males (four cases) over females (one case) in our series is typical of metopic synostosis as a whole.¹⁷

In conclusion, two particular clinical management issues arise from our observations. First, all children with GCPS should be examined for evidence of trigonocephaly and/or scaphocephaly to exclude the possibility of a co-existing craniosynostosis. Second, in patients in whom a diagnosis of Carpenter syndrome is being considered, the possibility of a *GLI3* deletion should be included in the differential diagnosis and specifically sought using aCGH or comparable technique.

Conflict of Interest

The authors declare no conflict of interest.

Acknowledgements

We thank all the families for their participation in this study, Sandra Bigi, Bruce Castle, Shincy John, Michael Parker and Oliver Quarrell for help with gathering clinical information and Bernard Conrad, Jennifer Johnston and Tracy Lester for assistance with molecular analysis. This work was supported by grants to AOMW from the Wellcome Trust (078666) and the Medical Research Council (80106).

References

1. Greig DM: Oxycephaly. *Edinburgh Med J* 1926; **33**: 189-218.
2. Fryns JP, Van Noyen G, Van Den Berghe H: The Greig polysyndactyly craniofacial dysmorphism syndrome: variable expression in a family. *Eur J Pediat* 1981; **136**: 217-220.
3. Baraitser M, Winter RM, Brett EM: Greig cephalopolysyndactyly: report of 13 affected individuals in three families. *Clin Genet* 1983; **24**: 257-265.
4. Hootnick D, Holmes LB: Familial polysyndactyly and craniofacial anomalies. *Clin Genet* 1972; **3**: 128-134.
5. Guzzetta G, Lecora M, Rossi G, Berni canai M, Andria G: Polysyndactyly and trigonocephaly with partial agenesis of corpus callosum. *Clin Dysmorphol* 1996; **5**: 179-182.
6. Tommerup N, Nielsen F: A familial reciprocal translocation t(3;7)(p21.1;p13) associated with the Greig polysyndactyly-craniofacial anomalies syndrome. *Am J Med Genet* 1983; **16**: 313-321.
7. Brueton L, Huson SM, Winter RM, Williamson R: Chromosomal localisation of a developmental gene in man: direct DNA analysis demonstrates that Greig cephalopolysyndactyly maps to 7p13. *Am J Med Genet* 1988; **31**: 799-804.
8. Drabkin H, Sage M, Helms C *et al*: Regional and physical mapping studies characterizing the Greig polysyndactyly 3;7 chromosome translocation, t (3;7) (p21.1;p13). *Genomics* 1989; **4**: 518-529.
9. Pettigrew AL, Greenberg F, Caskey CT, Ledbetter DH: Greig syndrome associated with an interstitial deletion of 7p: confirmation of the localization of Greig syndrome to 7p13. *Hum Genet* 1991; **87**: 452-456.
10. Vortkamp A, Gessler M, Grzeschik KH: GLI3 zinc-finger gene interrupted by translocations in Greig syndrome families. *Nature* 1991; **352**: 539-540.

11. Vortkamp A, Franz, T, Gessler M, Grzeschik KH: Deletion of *GLI3* supports the homology of the human Greig cephalopolysyndactyly syndrome (GCPS) and the mouse mutant extra toes (*Xt*). *Mamm Genome* 1992; **3**: 461-463
12. Biesecker LG: What you can learn from one gene: *GLI3*. *J Med Genet* 2006; **43**: 465-469.
13. Kroisel PM, Petek E, Wagner K: Phenotype of five patients with Greig syndrome and microdeletion of 7p13. *Am J Med Genet* 2001; **102**: 243-249.
14. Johnston JJ, Olivos-Glander I, Turner J *et al*: Clinical and molecular delineation of the Greig cephalopolysyndactyly contiguous gene deletion syndrome and its distinction from acrocallosal syndrome. *Am J Med Genet* 2003; **123A**: 236-242.
15. Johnston JJ, Sapp JC, Turner JT, *et al*: Molecular analysis expands the spectrum of phenotypes associated with *GLI3* mutations. *Hum Mutat* 2010; **10**: 1142-1154.
16. Johnston JJ, Olivos-Glander I, Killoran C *et al*: Molecular and clinical analyses of Greig cephalopolysyndactyly and Pallister-Hall syndromes: robust phenotype prediction from the type and position of *GLI3* mutations. *Am J Hum Genet* 2005; **76**: 609-622.
17. Kini U, Hurst JA, Byren JC, Wall SA, Johnson D, Wilkie AOM: Etiological heterogeneity and clinical characteristics of metopic synostosis: evidence from a tertiary craniofacial unit. *Am J Med Genet* 2010; **152A**:1383-1389.
18. Jenkins D, Seelow D, Jehee FS *et al*: *RAB23* mutations in Carpenter syndrome imply an unexpected role for hedgehog signaling in cranial-suture development and obesity. *Am J Hum Genet* 2007; **80**: 1162–1170.
19. Jenkins D, Baynam G, De Catte L *et al*: Carpenter syndrome: extended *RAB23* mutation spectrum and analysis of nonsense-mediated mRNA decay. *Hum Mutat* 2011; in press.

20. McDonald-McGinn DM, Feret H, Nah H-D, Bartlett SP, Whitaker LA, Zackai EH. Metopic craniosynostosis due to mutations in GLI3: a novel association. *Am J Med Genet* 2010 **152A**: 1654-1660.
21. Elson E, Perveen R, Donnai D, Wall S, Black GC: De novo GLI3 mutation in acrocallosal syndrome: broadening the phenotypic spectrum of GLI3 defects and overlap with murine models. *J Med Genet* 2002; **39**: 804-806.
22. Cohen MM Jr: Editorial: perspectives on craniosynostosis *Am J Med Genet A*; 2005; **136**: 313-326.
23. Cohen MM Jr: Craniosynostosis: Diagnosis, Evaluation, and Management. 1st ed. New York, Raven Press, 1986.
24. Cohen MM Jr, MacLean RE: Craniosynostosis: Diagnosis, Evaluation, and Management. 2nd ed. New York, Oxford University Press, 2000.
25. Lajeunie E, Crimmins DW, Arnaud E, Renier D: Genetic considerations in nonsyndromic midline craniosynostoses: a study of twins and their families. *J Neurosurg* 2005; **103(4 Suppl)**: 353-6.
26. Sanchez-Lara PA, Carmichael SL, Graham JM Jr *et al*: Fetal constraint as a potential risk factor for craniosynostosis. *Am J Med Genet* 2010 152A:394-400
27. Wilkie AOM, Byren JC, Hurst JA *et al*: Prevalence and complications of single gene and chromosomal disorders in craniosynostosis. *Pediatrics* 2010; **126**: e391-e400.
28. Rice DPC, Connor EC, Veltmaat JM *et al*: *Gli3*^{Xi2J/Xi2J} mice exhibit lambdoid suture craniosynostosis which results from altered osteoprogenitor proliferation and differentiation. *Hum Mol Genet* 2010; **19**: 3457-3467.

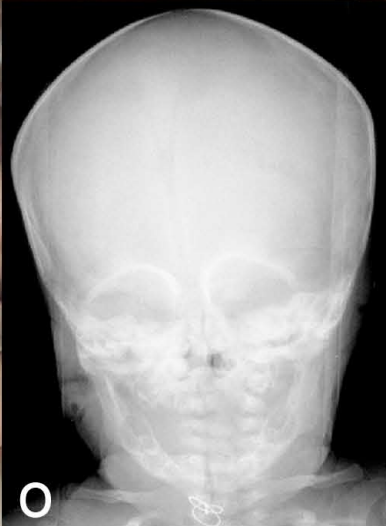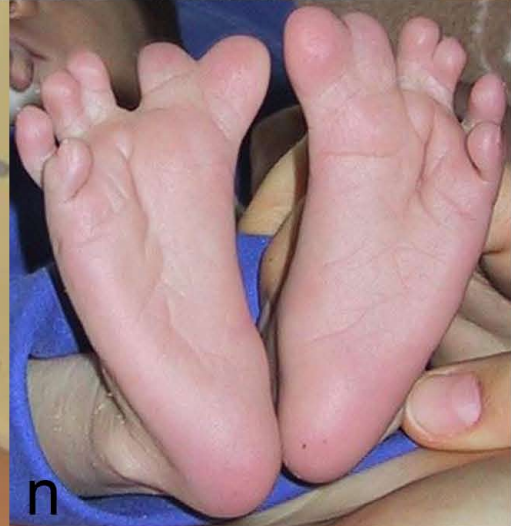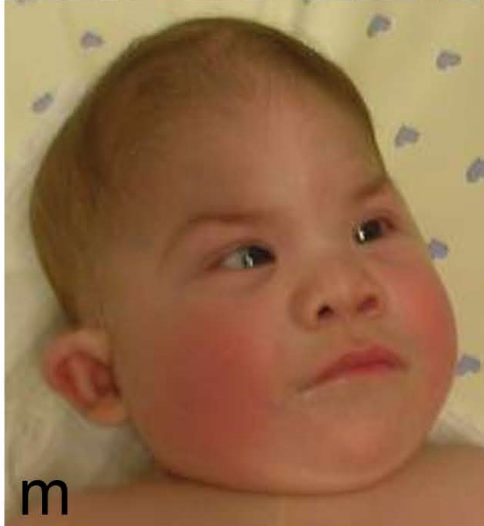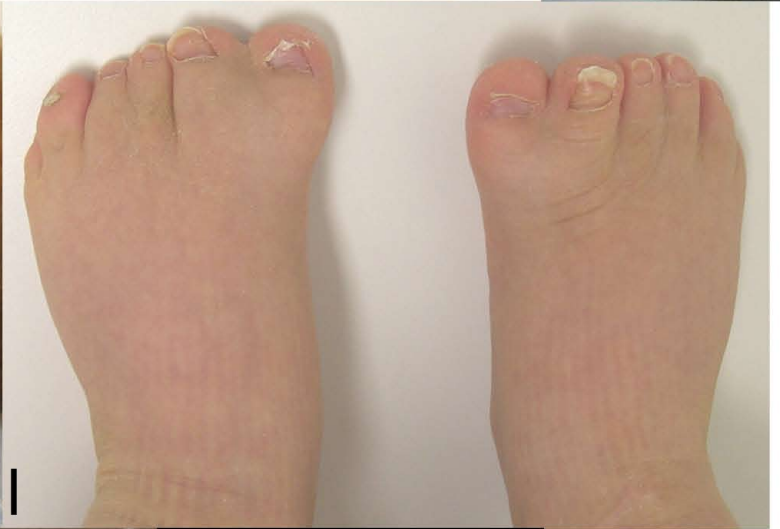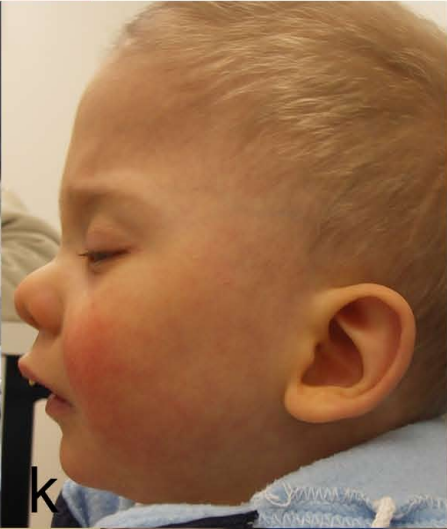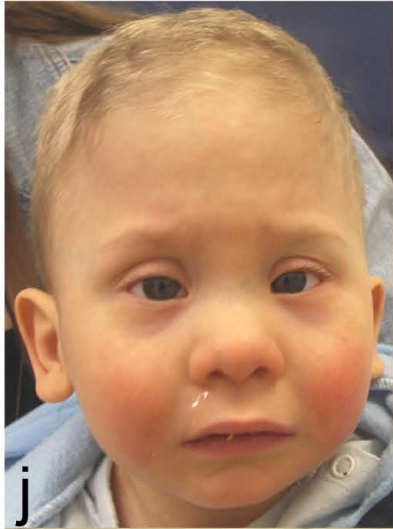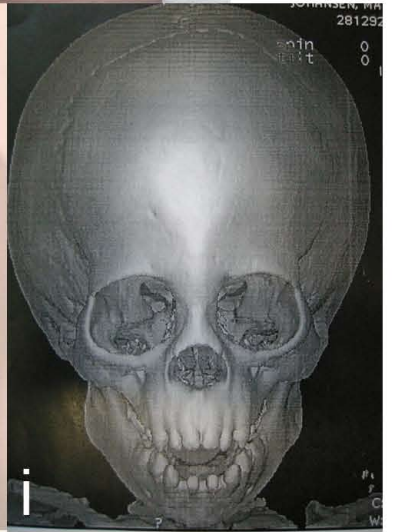
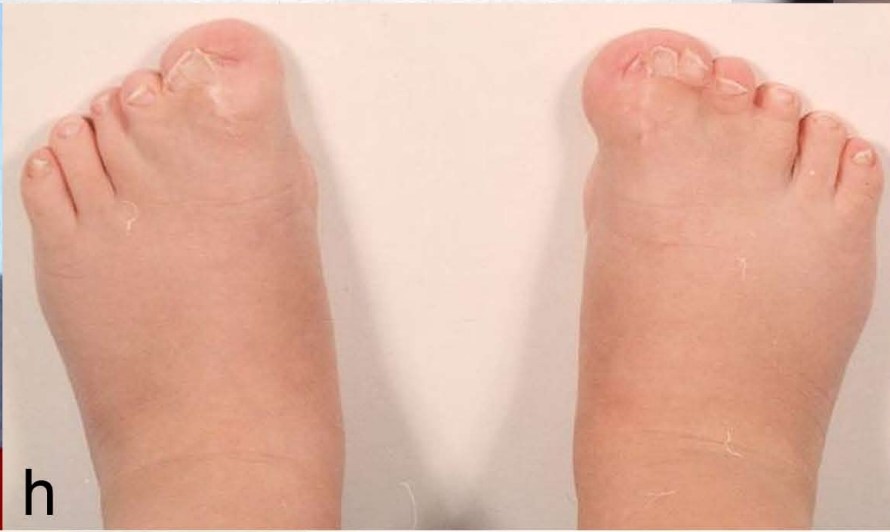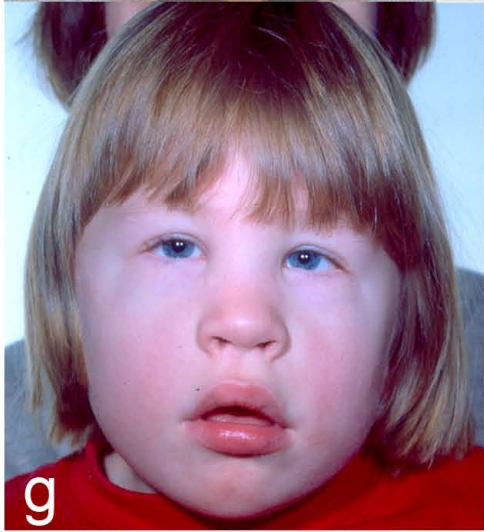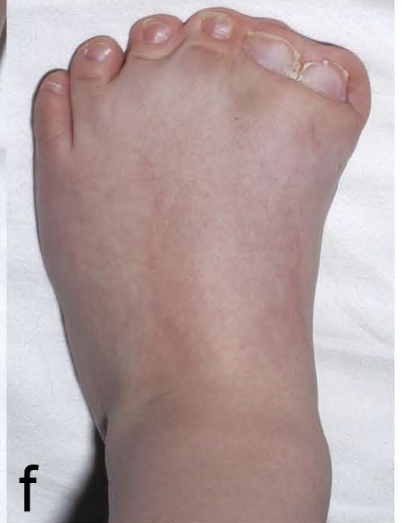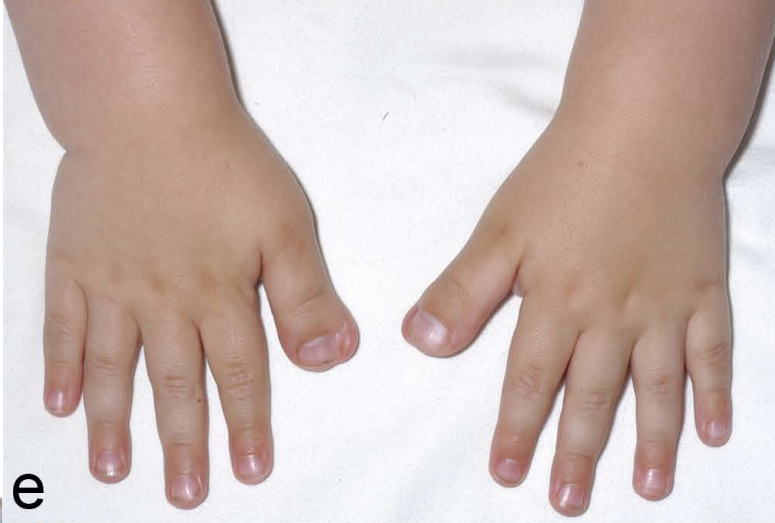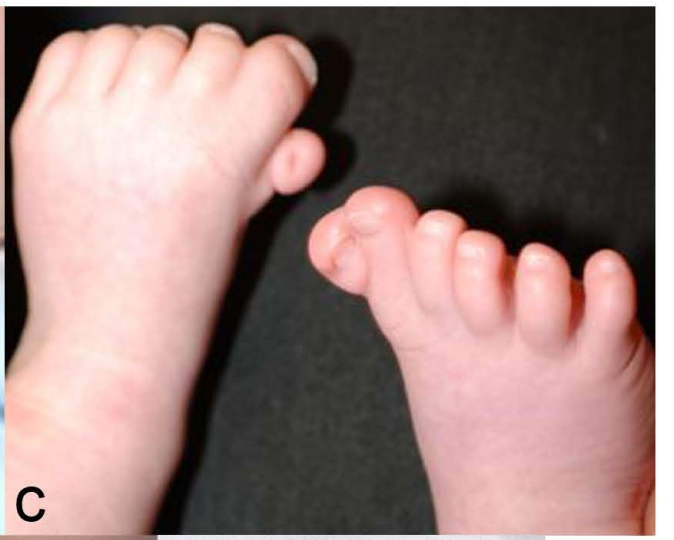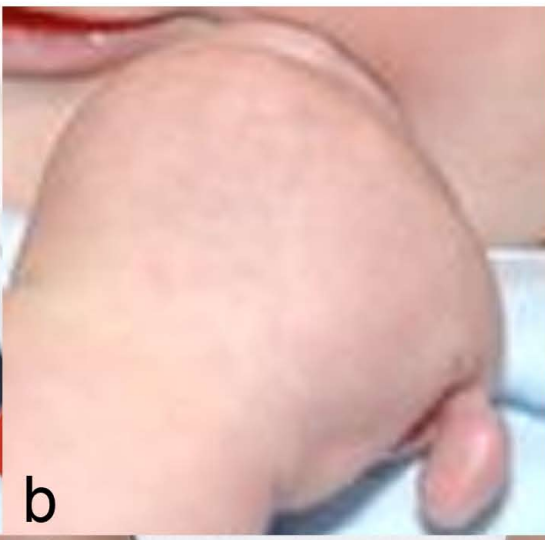
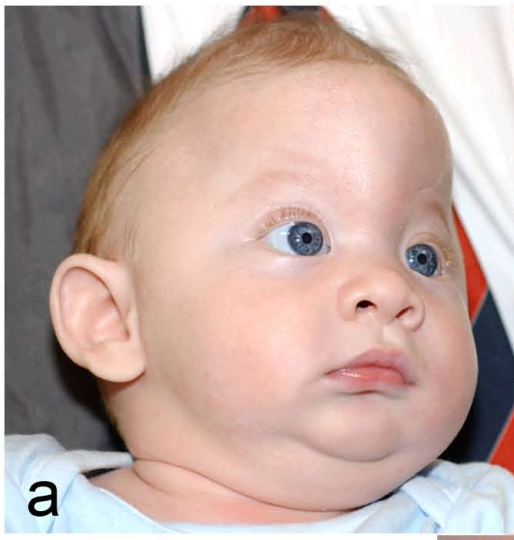Table 1. Clinical features and results of *GLI3* testing in Patients 1-5

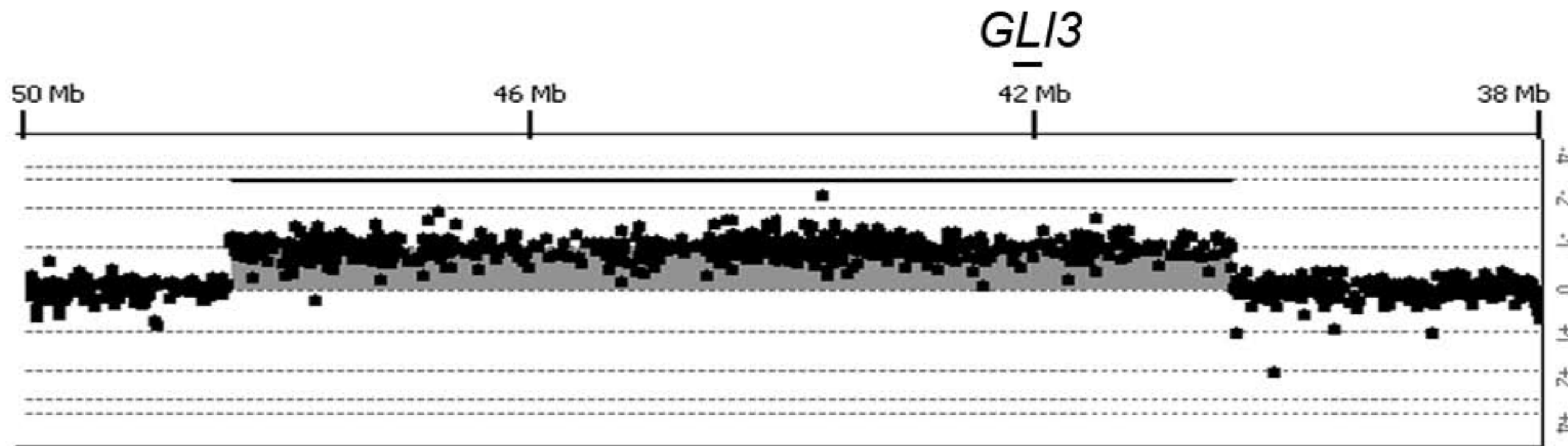
	Patient 1	Patient 2	Patient 3	Patient 4	Patient 5
Sex	Male	Male	Female	Male	Male
<i>GLI3</i> testing	c.1728C>A, p.Y576X	c.1793dupA, p.N598KfsX7	8.3 Mb deletion 7p12.3-p14.1	6.8 Mb deletion 7p13-p14.1	6.0 Mb deletion 7p13-p14.1
Family history	No	No	No	No	No
Parental ages	Mother 32 yr Father 34 yr	Mother 22 yr Father 22 yr	Mother 25 yr Father 25 yr	Mother 19 yr Father 23 yr	Mother 29 yr Father 29 yr
OFC	Prior to surgery: 48 cm at 10.5 mo (90 th centile)	Prior to surgery: 52 cm at 4 yr 3mo (75 th centile)	Birth: 32.8 cm (5th centile)	Birth: 34 cm (20 th centile)	Birth 33.5 cm (10 th centile)
Trigonocephaly	Yes	Yes	Yes	Yes and scaphocephaly	Yes
Craniosynostosis	Metopic and sagittal	Metopic	Metopic	Metopic and sagittal	Metopic
Structural brain anomaly	No	No	Bilateral frontal and parietal atrophy	No	Hypoplasia corpus callosum Mild cerebral ventricular dilatation
Development	Normal	Normal	Delayed	Delayed	Delayed
Sat			1 yr	14 months	2 yr
Walked			2.5 yr	Not walking independently at 5 yr 9 mo	3.5 yr
Speech at 3 years			10-12 words	< 5 words	15 words
Schooling			At 15 yr approx equivalent to average 7 yr	Special schooling	-
Thumb	Normal	Partially duplicated	Broad	Normal	Broad
Finger poly/syndactyly	Postaxial polydactyly type B	Postaxial polydactyly type B	No	No	No
Hallux	Duplicated (separate preaxial digit on left)	Duplicated, with complete cutaneous syndactyly	Broad	Duplicated, with partial cutaneous syndactyly	Duplicated, with partial cutaneous syndactyly
Toe cutaneous poly/syndactyly	Complete cutaneous syndactyly hallux and second toe. Partial syndactyly second/ third toes	Complete cutaneous syndactyly hallux and second toe. Partial syndactyly second-fourth toes	Partial cutaneous syndactyly between hallux/second/third toes	Partial syndactyly second/third toes	Partial syndactyly second/third toes
Other anomalies	No	No	Short palpebral fissures, flat nasal bridge and broad base, thick lips Hypermetropia and squint. Small VSD (closed spontaneously)	Telecanthus, bilateral ptosis, anteverted nares, large mouth. Laryngomalacia, VSD, ASD and PDA Seizures age 3 years	Flat nasal bridge and broad base. DORV with pulmonary stenosis.

Abbreviations: VSD: ventricular septal defect, ASD: atrial septal defect, PDA: patent ductus arteriosus, DORV: double outlet right ventricle

Figure 1 Clinical features of patients with trigonocephaly and mutations of *GLI3*. (a-c), face (aged 11 weeks), right hand and feet of Patient 1. (d-f), face (aged 3.1 years), hands and feet of Patient 2. (g-i), face (aged 6 years), feet and CT scan of Patient 3. (j-l) face (postoperative, aged 3 years) and feet of Patient 4. (m-o) face (aged 2 weeks), feet and skull radiograph of Patient 5. Note trigonocephalic appearance (a,d,g,i,m), except in Patient 4, who was postoperative (j). Dysmorphic features (narrow, upslanted palpebral fissures, broad flat nasal bridge, downturned corners of mouth) are more marked in individuals with deletions (g,j,m). Postaxial polydactyly of the fingers was present only in Patient 1 (b), and partially duplicated thumbs in Patient 2 (e), but all patients had foot abnormalities (c,f,h,l,n). Note supero-medial extension of orbits on the skull radiograph (o), caused by premature metopic suture fusion.

Figure 2 Array CGH analysis of Patients 3 and 5 with deletions including *GLI3*. (a), Patient 3 with deletion of 8.3 Mb. (b) Patient 5 with deletion of 6.0 Mb. Both deletions include the *GLI3* gene (position shown at top).



a**b**