HAL
open science

PERI-OPERATIVE MANAGEMENT OF OPHTHALMIC PATIENTS TAKING ANTI-THROMBOTIC THERAPY

Gregory Lip

To cite this version:

Gregory Lip. PERI-OPERATIVE MANAGEMENT OF OPHTHALMIC PATIENTS TAKING ANTI-THROMBOTIC THERAPY. International Journal of Clinical Practice, 2011, 65 (3), pp.361. 10.1111/j.1742-1241.2010.02538.x . hal-00614654

HAL Id: hal-00614654

https://hal.science/hal-00614654v1

Submitted on 14 Aug 2011

HAL is a multi-disciplinary open access archive for the deposit and dissemination of scientific research documents, whether they are published or not. The documents may come from teaching and research institutions in France or abroad, or from public or private research centers.

L'archive ouverte pluridisciplinaire **HAL**, est destinée au dépôt et à la diffusion de documents scientifiques de niveau recherche, publiés ou non, émanant des établissements d'enseignement et de recherche français ou étrangers, des laboratoires publics ou privés.

THE INTERNATIONAL JOURNAL OF
CLINICAL PRACTICE

PERI-OPERATIVE MANAGEMENT OF OPHTHALMIC PATIENTS TAKING ANTI-THROMBOTIC THERAPY

Journal:	*International Journal of Clinical Practice*
Manuscript ID:	IJCP-06-10-0335.R2
Wiley - Manuscript type:	Non-Systematic Review
Date Submitted by the Author:	17-Sep-2010
Complete List of Authors:	Lip, Gregory; City Hospital, University Department of Medicine
Specialty area:	

SCHOLARONE™
Manuscripts

For Review Only

Review

PERI-OPERATIVE MANAGEMENT OF OPHTHALMIC PATIENTS TAKING ANTI-THROMBOTIC THERAPY

Gregory YH Lip* [1]

Omar M Durrani* [2]

Vanessa Roldan[3]

Peck Lin Lip[2]

Francisco Marin[4]

Tristan Q Reuser[5]

[1]Haemostasis Thrombosis and Vascular Biology Unit, University of Birmingham Centre for Cardiovascular Sciences, City Hospital, Birmingham, UK

[2] Birmingham & Midlands Eye Centre, City Hospital, Birmingham, UK

[3] Centro Regional de Hemodonación, C/ Ronda de Garay s/n, Murcia 30002, Spain.

[4] Department of Cardiology. Hospital Universitario Virgen de la Arrixaca. Murcia. Spain.

[5]Heartlands & Solihull NHS Trust, Birmingham, and The Midlands Eye Institute, Solihull, UK

[*Prof Lip and Mr Durrani are joint 1st authors, with equal contributions to the work]

Correspondence: **Professor GYH Lip**

Tel: +44 121 5075080; Fax +121 554 4083; g.y.h.lip@bham.ac.uk

Competing Interests - None to declare, for all authors

For Peer Review Only

Abstract

Background. Increasing number of patients presenting for ophthalmic surgery are using oral anti-coagulant and anti-platelet therapy. The current practice of discontinuing these drugs pre-operatively due to a presumed increased risk of bleeding may not be evidence-based and could pose a significant risk to the patient's health.

Objective. To provide an evidence-based review on the peri-operative management of ophthalmic patients that are taking anti-thrombotic therapy. In addition, we briefly discuss the underlying conditions that necessitate the use of these drugs, as well as management of the operative field in anti-coagulated patients.

Methods. A semi-systematic review of literature was performed. The databases searched included MEDLINE, EMBASE, database of abstracts of reviews of effects (DARE), Cochrane controlled trial register and Cochrane systematic reviews. In addition, the bibliographies of the included papers were also scanned for evidence.

Results The published data suggests that aspirin did not appear to increase the risk of serious post-operative bleeding in any type of ophthalmic surgery. Topical, sub-tenon, peri-bulbar and retrobulbar anesthesia appear to be safe in patients on anti-thrombotic (warfarin and aspirin) therapy. Warfarin does not increase the risk of significant bleeding in most types of ophthalmic surgery when the INR was within the therapeutic range.

Conclusion. Current evidence supports the continued use of aspirin and with some exceptions, warfarin in the peri-operative period. The risk of thrombosis-related complications on disruption of anticoagulation may be higher than the risk of significant bleeding by continuing its use for most types of ophthalmic surgery.

Key words: aspirin, warfarin, anticoagulation, ophthalmic surgery

For Peer Review Only

Take Home messages

- Increasing number of patients presenting for ophthalmic surgery are using oral anti-coagulant and anti-platelet therapy.

- The current practice of discontinuing these drugs pre-operatively due to a presumed increased risk of bleeding may not be evidence-based and could pose a significant risk to the patient's health.

- Current evidence supports the continued use of aspirin and with some exceptions, warfarin in the peri-operative period.

- The risk of thrombosis-related complications on disruption of anticoagulation may be higher than the risk of significant bleeding by continuing its use for most types of ophthalmic surgery.

For Peer Review Only

Introduction

Increasing number of patients presenting for ophthalmic surgery are using oral anti-coagulant and anti-platelet therapy.[1] Common medical conditions, such as atrial fibrillation and valvular heart disease, require the use of anticoagulants (e.g. warfarin), whilst antiplatelet therapy is used in high risk populations to reduce vascular events.[2-3] For example, there are one million people in America who are receiving warfarin, making it the 46th most commonly prescribed drug in USA in 1993.[4]

As patients over the age of 65 years are twice as likely to have some form of surgery as compared to those under that age the true importance of managing peri-operative anti-thrombotic therapy becomes clear. These drugs are routinely discontinued pre-operatively due to a perceived increased risk of severe bleeding intra and post-operatively, a practice which is generally not based on published evidence and the potential risks to the patient may be poorly understood (Table 1). Nonetheless, the risk of peri-operative bleeding in patients on anti-coagulants is dependant on multiple factors including the patient's age, other systemic diseases (cancer), the type of surgery as well as the INR.[5-7] The underlying clinical state, the type of surgery and the phenomenon of rebound hypercoagulability on interruption of warfarin contributes to the risk of thrombosis-related complications.

The aim of this overview is to provide a semi-systematic review of the current published evidence on the peri-operative management of anti-coagulant and anti-platelet therapy. In particular, we will review the risk of significant bleeding in patients on anti-coagulant

For Peer Review Only

and anti-platelet therapy and determine what types of ophthalmic procedures are safer than others. We will also assess the risks of thrombosis-related complications associated with short-term modification of these drugs and stratify the risk on the basis of underlying systemic disease. Management of the surgical field in ophthalmic patients on anti-coagulants will be summarized.

Methods used in undertaking this overview, as well as a brief overview of the indications for anti-thrombotic therapy[7-19] are provided as web-only supplementary material.

Altering anti-thrombotic therapy and the risk of thrombotic complications

The risks of thrombotic complications on one hand and bleeding on the other are dependent on multiple factors, including the type of anti-thrombotic therapy, the type and duration of surgery and rebound hypercoagulability that may be associated with stopping warfarin.

Aspirin users may be placed in two broad overlapping groups: those with significant cardiovascular risk factors where aspirin plays a significant cardioprotective and anti-thrombotic role, and those taking aspirin to keep the circulation "healthy". There is no published evidence to suggest that aspirin use in the latter group is beneficial. In the former group, in addition to the cardio-protective effect, aspirin reduces the risk of stroke by an average of 22%[2,21]. Of note, current guidelines recommended dual antiplatelet therapy after coronary stenting especially with drug eluting stents, as early antiplatelet discontinuation may increase the risk of stent thrombosis[22]

For Peer Review Only

The clinical relevance of rebound hypercoagulability is disputed by many authorities, though there is evidence to suggest that the risk of thromboembolism is increased on abrupt cessation of warfarin by a combination of this phenomenon and the pro-thrombotic effect of surgery.[22-23] Laboratory studies show increased levels of prothrombin, fibrin and thrombin activation in the early period after abrupt cessation of warfarin.[23-24] Post-operative changes in haemostatic markers also suggest that surgery itself may increase the thrombophilic risk.[25] Furthermore, high levels of a fibrin degradation product, fibrin D-dimer, may actually be predictive of the risk of post-operative thrombosis[26-27].

An overview of studies examining the effect of altering antithrombotic therapy and the risk of thrombotic complications suggests a greater risk for patients with mitral valve disease, combined mitral and aortic prosthetic valves and atrial fibrillation. The exact thrombotic risk is dependent on multiple factors including the underlying systemic condition requiring anti-coagulation, duration of disruption and the use of bridging therapy (Table 3).[28-32] All these studies (either retrospective or prospective) have relatively small numbers. High quality prospective randomised studies are therefore needed to better define this risk. A meta-analysis of studies reporting thromboembolic complications describes 29 thrombotic events, including seven strokes in 1868 patients (1.6%; 95% CI, 1.0-2.1%) receiving oral anticoagulation and undergoing surgery or invasive procedures.[33]

For Peer Review Only

Antithrombotic therapy use, surgery & the risk of bleeding complications

A recent systematic review by Dunne and Turpie[33] identified 31 studies relating to long-term oral anti-coagulants and surgery, and reported that the quality of evidence was generally poor. They concluded that most patients can undergo cutaneous, dental, ophthalmic surgery, arthrocentesis, and upper gastrointestinal endoscopy without alteration to oral anticoagulants. For other invasive surgery, they recommend withholding oral anticoagulants and the use of heparin as bridging therapy[32,33]. The perioperative management of antithrombotic therapy has been the subject of an American College of Chest Physicians Evidence-Based Clinical Practice Guideline (8th Edition; ACCP8)[34].and broadly recommends an approach based on thromboembolic risk. For example, in those at high risk for thromboembolism, ACCP8 recommends bridging anticoagulation with therapeutic-dose subcutaneous (SC) Low molecular weight heparin (LMWH) and IV unfractionated heparin (IV UFH) over no bridging during temporary interruption of warfarin therapy, whist in patients at moderate risk, bridging anticoagulation with therapeutic-dose SC LMWH, therapeutic-dose IV UFH, or low-dose SC LMWH is also recommended, over no bridging during temporary interruption of warfarin therapy. In patients with a mechanical heart valve or atrial fibrillation or venous thromboembolism at low risk for thromboembolism, low-dose SC LMWH or no bridging is recommended.

Cataract surgery

Cataract surgery is one of the most commonly performed surgical procedures with over 200.000 procedures carried out in the United Kingdom in the last year. Most of the patients are elderly and a significant minority are on anticoagulants[1,33,34]. The use of

For Peer Review Only

aspirin, clopidogrel and warfarin in the peri-operative period in patients undergoing cataract surgery does not appear to be associated with an increased risk of significant bleeding complications [1,33-38].

For example, one prospective study of 1383 patients investigated the bleeding risk of local anaesthetic infiltration in patients using aspirin, warfarin and other non steroidal anti-inflammatory drugs (NSAIDS) and undergoing a variety of ocular procedures.[35] The overall risk of bleeding was found to be 4% (minor to moderate): there were no cases of retro-bulbar hemorrhage. Another large study investigating the risks of complications from the peri-operative use of anti-coagulant in 19,283 patients undergoing cataract surgery did not find an increase in the rates of haemorrhage in patients using warfarin or aspirin: 22.2% of patients were using aspirin while 4% were on warfarin pre-operatively[33]. Aspirin was discontinued by 22% of users two weeks pre-operatively while 28.3% of warfarin users discontinued its use four days before surgery. Retrobulbar and/or peribulbar anesthesia was used in 73.9% while the rest had topical and/or sub-tenon blocks, and continued use of antithrombotic therapy (aspirin, warfarin) was recommended, as the rate of adverse bleeding events is not increased by their use. Interestingly, the rate of thrombotic complications was much higher on interruption of anti-coagulants than the rate of bleeding complications on continued use in the study population.[38] Indeed, Gainey et al[39] did not find a difference in the haemorrhage rate of patients irrespective of whether warfarin was continued or stopped before surgery. In patients who are undergoing cataract removal and are receiving vitamin K antagonists (VKAs), the ACCP8 guidelines recommend continuing warfarin around the time of the procedure[34].

For Peer Review Only

One study of patients undergoing cataract surgery found a greater incidence of subconjunctival hemorrhage in patients who were receiving either clopidogrel or warfarin compared to aspirin or no antithrombotic drugs, although there were no sight-threatening bleeding complications[40].

Vitreoretinal surgery

Vitreoretinal surgery, though more invasive than cataract surgery, also appears to be safe in patients taking aspirin. For example, Narendran and Williamson[41] did not find an increased rate of bleeding complications in patients taking aspirin; however, only 7 patients in the study were taking warfarin, making it difficult to draw any firm conclusions from the higher bleeding rate in this sub-group. Fu at al.[42] reported 25 patients on warfarin undergoing vitreoretinal surgery, where the only reported complication was of one patient undergoing scleral buckling and external drainage of subretinal fluid where intraoperative subretinal haemorrhage was associated with the drainage procedure. The preoperative INR in this case was 2.7. Another retrospective study identified 54 patients who underwent 57 vitreoretinal surgical procedures while on warfarin anticoagulation therapy with an therapeutic INR[43]. There were no intraoperative hemorrhagic complications and only 4 postoperative haemorrhages, all of them resolved spontaneously.

Glaucoma surgery

Trabeculectomy also appears to be safe in patients taking aspirin. In a retrospective study, Cobb et al.[44] reported that patients on aspirin had a postoperative hyphaema rate which was twofold compared to non-aspirin users, but there was no significant difference in surgical outcome when comparing intraocular pressures (IOP) at 2 years; however,

For Peer Review Only

patients on warfarin had serious haemorrhagic complications (INR ranged from 1.5 to 4.5). In their small series, all 5 patients on warfarin developed clinically significant hyphaema, 2 of whom required surgical evacuation. Within 1 year, 4 cases needed antiglaucoma medication as IOP exceeded 21mmHg.

Lacrimal surgery

Lacrimal surgery can be associated with blood loss, sometimes significant[45,46]. In endonasal lacrimal surgery, visualisation is essential, and even a little blood loss will affect outcomes. Good hemostasis is therefore essential not only per-operatively, but also to prevent bleeding in the immediate postoperative period. Poor visibility during the operation correlates with poor outcomes.

Oculoplastic, Oro-facial & cutaneous surgery

Oro-facial and cutaneous surgery, including general plastic surgery and dermatologic procedures (eg. Moh's surgery) are broadly similar to oculoplastic and adnexal surgery, and evidence from these specialties are relevant to ophthalmologists.

Only one study investigating oculoplastic surgery in anti-coagulated patients was identified.[47] The authors concluded that the incidence of serious haemorrhagic complications was low.

Cutaneous surgery generally appears safe in anti-coagulated patients.[48] There is broad consensus that oral anticoagulants do not significantly increase the risk of bleeding and that stopping anticoagulant therapy does not offer significant benefits. [49-52] The rate of

For Peer Review Only

bleeding complications in anti-coagulated patients may be higher than those on aspirin but serious problems are uncommon.[53]

Meticulous hemostasis with or without topical hemostatic agents like autologous fibrin glue or similar commercially available products and the use of pressure dressings post-operatively, further reduce this risk. One prospective study by Billingsley et al[53] found no difference between patients on warfarin, aspirin and controls. A retrospective review of 586 patients undergoing Moh's micrographic surgery reports a serious bleeding rate of 1.6% in patients taking warfarin and aspirin, although there was no difference between the treated (oral anticoagulants (OAC) continued) and untreated groups (OAC stopped).[54] Major thrombotic episodes including pulmonary embolism and thrombosis of prosthetic valve have also been reported when anticoagulant therapy was withheld prior to surgery.[55] Finally, a recent meta-analysis of complications attributed to anticoagulation in patients following cutaneous surgery reported that patients taking warfarin were nearly seven times as likely to have a moderate-to-severe complication whereas patients taking aspirin were more than two-fold (but not statistically significant) to have a moderate-to-severe complication compared to controls[56].

Oral and dental surgery

There is evidence that oral and dental surgery is safely carried out in chronically anti-coagulated patients. A prospective randomised study comparing bleeding complications in patients continued on warfarin to those that had warfarin reduced or warfarin added found no statistically significant difference in the rate of bleeding complications.[57] Another randomised controlled trial[58] of 109 patients, comparing the discontinuation of warfarin two days pre-operatively with continued anti-coagulation did not find a

For Peer Review Only

significant difference in the rate of post-operative bleeding, whereby the incidence of bleeding was 26% in the intervention group compared to 14% in the control group. Thus, for the management of anti-coagulated patients undergoing dental extraction, warfarin and aspirin should not be withdrawn as the benefits are low while the risks are high[59] Topical hemostatic agents like platelet rich fibrin gel could be used in patients at a higher risk of bleeding.[60]

Five trials (a total of 553 patients) were included in a recent meta-analysis that evaluated the effect of continuing warfarin therapy on the bleeding risk of patients undergoing elective dental surgery[61]. Perioperative continuation of warfarin with patients' usual dose was not associated with an increased risk for clinically significant non major bleeding or an increased risk for minor bleeding compared with interrupting warfarin therapy (either partial or complete).

For Peer Review Only

Modification of antithrombotic therapy

For most types of surgical procedures, the risks of interrupting anti-coagulation outweigh its benefits, but clinical needs may at times dictate disruption of warfarin or aspirin. If the INR is within the therapeutic range (2-3.5), discontinuing warfarin for three to four days will allow the INR to drop below 2.0. For those with INRs higher than the therapeutic range (ie >3.5), a longer period may be required. Consulting a cardiologist or a clinical haematologist is highly recommended in these cases.

A population of patients that deserves special consideration are patients on antiplatelet therapy related to coronary artery disease, since such patients are common, and often require chronic treatment. Indeed, a cardiologist should always be consulted where patients with coronary artery disease are on treatment with aspirin + clopidogrel (dual antiplatelet therapy) for an acute coronary syndrome or after recent stent implantation (whether drug eluting (DES) or bare metal stent (BMS) implantation.). In such patients, the risk of recurrent cardiac ischaemia or stent thrombosis is real, and non-urgent surgery (including ophthalmic procedures) should be delayed where possible, especially since the potential for bleeding with dual antiplatelet therapy may be as high as that seen with warfarin. The risk of thrombosis diminishes with time, and dual antiplatelet therapy is mandated for 4 weeks after elective BMS implantation, and for 6-12 months after DES implantation or an acute coronary syndrome. If urgent surgery is needed and cannot be delayed, and where the bleeding risk is significant, clopidogrel should be discontinued for 5 days, and restarted as soon as possible post-procedure[34].

Elective surgery should be delayed if it has been less than a month since the thrombotic episode. Bridging therapy with low molecular weight heparin should only be instituted in patients at a moderate to high risk of thrombotic complications (table 3).[34,62] Aspirin or clopidogrel is generally stopped 7 days prior to surgery. One prospective controlled trial suggests that stopping aspirin 48 hours before surgery is just as effective as seven days.[63]

Urgent reversal of warfarin anticoagulation

In patients needing urgent surgery, two options are available to rapidly reduce the INR. Vitamin K (phytonadione) is a fat soluble vitamin that is required for synthesis and biologic activity of coagulation factors II, VII, IX and X as well as Proteins C and S. Warfarin inhibits the γ-carboxylation of the coagulation factors and limits their ability to bind calcium and form clots. A small dose (2.5-5 mg) of either oral or intravenous vitamin K will reverse the effects of warfarin within 24 to 36 hours.[64-66] Intramuscular Vitamin K injection should be avoided because of erratic absorption and the risk of hematoma formation. For life-threatening situations with a need for emergency surgery, guidelines recommend the use of fresh frozen plasma (FFP) to treat warfarin overdosage only where there is severe bleeding or prothrombin complex concentrates (PCCs) are unavailable.

For Peer Review Only

Management of the operative field

While continuing anti-coagulants in the therapeutic range does not increase the risk of serious bleeding in most types of surgery, persistent bleeding or oozing from the operative site may be more than just an annoyance. In cutaneous, oculoplastic and lacrimal surgery, important tissue planes may be obscured and the risk of graft failure increased due to hematoma formation. Orbital, oto-laryangatologic and other "key-hole" procedures may become impossible because of poor view, and dangerous if associated with significant bleeding post-op. Simple steps such as meticulous surgical technique and a good understanding of local anatomy reduce surgical trauma. Also, hypotensive anesthesia is an excellent way of reducing intraoperative bleeding in most types of surgery but post operative bleeding is a risk as potential bleeding sites may not be identified.[67,68] Local infiltration with adrenaline is a tried and tested method of achieving local hemostasis and is especially useful in cutaneous, oculoplastic, and lacrimal surgery, and a dilution of 1:80,000 to 1:200,000 is effective when infiltrated about 10 minutes before surgery.[69] Radiofrequency cutting diathermy also reduces bleeding at the operative site by cauterizing the wound at the time of incision.[70] CO2 laser in the cutting mode works on a similar principal and can minimize bleeding.[71]

Topical hemostatic agents

Fibrin Sealants enhance hemostasis at the operative site by duplicating the last phase of blood clot formation. A mixture of fibrinogen, thrombin, ionized calcium and factor XIII are applied locally. Thrombin converts fibrinogen in to fibrin and activates factor XIII. This results in cross-linking of fibrin and increased clot strength. During the healing process, this material is gradually absorbed and may actually enhance wound healing.[72]

For Peer Review Only

The preparations may be autologous, homologous and derived from pooled donors or bovine sources. To prepare the autologous gel, the patient needs to come to the hospital a few days before the procedure and give about 100-300ml of blood which is then processed to recover platelet rich fibrin glue and thrombin.[73] When this gel is applied to the operative field, the platelets come in contact with thrombin/calcium it results in their activation and coagulum formation. The platelets interdigitate with the fibrin web and develop an adhesive haemostatic layer. Platelet activation also releases highly active vasoconstrictors, including serotonin, thromboxane and platelet derived growth factor (PDGF). In addition to haemostasis, it also promotes wound healing and has "tissue glue" properties.[73,74] Commercially available topical agents tend to be more effective as they contain much higher concentrations of clotting factors.[75]

The homologous products are screened for all currently known infectious agents but concerns remain. Bovine products like FlowSeal Matrix™ are another alternative. They are derived from closed herds that are screened for all known infections including prion diseases but the possibility of (rare) allergic reactions must be kept in mind.

A systemic review of randomised controlled trials of fibrin sealants by Carless et al[76] suggests that these agents reduce the rate of blood loss as well as reducing the need for transfusion. A multi-centre study comparing the efficacy of fibrin sealant with conventional topical haemostatic agents in emergency re-sternotomy and redo cardiac surgery found these agents to control bleeding within five minutes of application in 92.6% of patients compared to 12.4% in the conventional group.[77]

For Peer Review Only

Floseal Matrix™ is a bovine derived two component (gelatin matrix and thrombin) haemostatic agent, which is effective in stopping bleeding following endonasal surgery in an average of 2.5 minutes.[78] A recent randomised controlled trial found it to be safe and effective in controlling post-operative bleeding following adenoid surgery in children.[79] It does not appear to alter wound healing or flap survival in clinical studies but delayed mucosal healing and increased scarring was reported in one animal study.[80,81]

Though there is no published evidence of the use of these topical products in orbital surgery, a recent study of trans-sphenoidal surgery found Flowseal to be effective in controlling severe bleeding where standard methods had failed.[82] Tisseal™, another topical agent is effective as hemostatic agent and tissue glue.[83] One of the major benefits of this product is the ability to vary the clotting rate by changing the dilution of the thrombin in the preparation.

Haemostatic sponges have been around for a long time and are used either alone or after soaking them in thrombin.[84] They work primarily by activating platelets and providing scaffolding for clot formation.[85] Bone wax is a useful and cheap alternative for controlling moderate bleeding from bone.[84]

Conclusions

Even with the limited quality and quantity of evidence we are able to draw certain conclusions from the available data (Table 4). Figure 1 provides an algorithm for management of warfarinized patients undergoing ophthalmic surgery.

For Peer Review Only

While aspirin does not appear to be associated with an increased risk of significant bleeding in patients undergoing any type of ophthalmic surgery or infiltration of local anesthesia, no evidence of excessive thromboembolism on its discontinuation was identified. In procedures where oozing at the operative site may be detrimental to surgical outcome, aspirin may be discontinued in the peri-operative period in patients without significant cardio-vascular risk factors. The risk of significant bleeding in patients using warfarin and undergoing ophthalmic surgery appears to be relatively low when the INR is within the therapeutic range, whilst the probability of thromboembolism on its interruption appears to be much higher. Peri-operative modification of warfarin needs to be done cautiously and in close discussion with a cardiologist and/or clinical haematologist. Reducing the warfarin dose pre-operatively to bring down the INR to the lower limit of the therapeutic range is a safer alternative to disrupting it and exposing the patient to a risk of thromboembolism. There is also insufficient evidence to make precise recommendations about the newer anti-platelet drugs like clopidogrel and prasugrel.

For Peer Review Only

Limitations

This overview highlights the heterogeneity of the data, with limited data from robust large randomised controlled trials, and dependence on case series.

In summary, most types of ophthalmic surgery appear to be safe in anti-coagulated patients. When the disruption to warfarin is considered essential, it should be for the minimal possible time with low molecular weight heparin 'bridging; cover during the period of cessation as the risk of thrombophilia on interrupting oral anticoagulants appears to be higher than the risk of post-operative bleeding. The constant oozing of blood at the surgical field can also be proactively managed by a combination of local measures. The question of the best practice in the peri-operative management of chronically anti-coagulated patient is perhaps too important to ignore and well planned prospective studies are still needed.

For Peer Review Only

ACKNOWLEDGEMENTS

We thank Fariha Shafi, Usman Mahmood and Anu Pherwani, for assistance with literature reviews.

REFERENCES

1. Katz J, Feldman MA, Bass EB, Lubomski LH, Tielsch JM, Petty BG, et al. Risks and benefits of anticoagulant and antiplatelet medication use before cataract surgery. Ophthalmology 2003;110:1784-88.
2. Kitchin AH, Milnes JS. Longitudinal survey of ischaemic heart disease in a randomly selected sample of the older population. Br Heart J 1997;39:889-93.
3. Secondary prevention in non-rheumatic atrial fibrillation after transient ischaemic attack or minor stroke. EAFT (European Atrial Fibrillation Trial) Study Group. Lancet 1993;342:1255-62.
4. Fihn SD, Callahan CM, Martin DC, McDonell MB, Henikoff JG, White RH. The risk for and severity of bleeding complications in elderly patients treated with warfarin. The National Consortium of Anticoagulation Clinics. Ann Intern Med. 1996;124970-9.
5. Schulman S, Beyth RJ, Kearon C, Levine MN; American College of Chest Physicians. Hemorrhagic complications of anticoagulant and thrombolytic treatment: American College of Chest Physicians Evidence-Based Clinical Practice Guidelines (8th Edition). Chest. 2008 Jun;133(6 Suppl):257S-298S.
6. Palareti G, Cosmi B. Bleeding with anticoagulation therapy - who is at risk, and how best to identify such patients. Thromb Haemost. 2009 Aug;102(2):268-78.
7. Hughes M, Lip GY; Guideline Development Group for the NICE national clinical guideline for management of atrial fibrillation in primary and secondary care. Risk factors for anticoagulation-related bleeding complications in patients with atrial fibrillation: a systematic review. QJM. 2007 Oct;100(10):599-6
8. Lagerstedt CI, Olsson CG, Fagher BO, Oqvist BW, Albrechtsson U. Need for long-term anticoagulant treatment in symptomatic calf-vein thrombosis. Lancet 1985;2:515-8.
9. Levine MN, Hirsh J, Gent M, Turpie AG, Weitz J, Ginsberg J, et al. Optimal duration of oral anticoagulant therapy: a randomized trial comparing four weeks with three months of warfarin in patients with proximal deep vein thrombosis. Thromb Haemost 1995;74:606-11.

For Peer Review Only

10. Coon WW, Willis PW, 3rd. Recurrence of venous thromboembolism. Surgery 1973;73:823-7.

11. Optimum duration of anticoagulation for deep-vein thrombosis and pulmonary embolism. Research Committee of the British Thoracic Society. Lancet 1992;340:873-6.

12. Lip GY, Lim HS. Atrial fibrillation and stroke prevention. Lancet Neurol. 2007 Nov;6(11):981-93

13. Stroke Risk in Atrial Fibrillation Working Group. Independent predictors of stroke in patients with atrial fibrillation: a systematic review. Neurology. 2007 Aug 7;69(6):546-54.

14. Cannegieter SC, Rosendaal FR, Briet E. Thromboembolic and bleeding complications in patients with mechanical heart valve prostheses. Circulation 1994;89:635-41.

15. Stein PD, Alpert JS, Bussey HI, Dalen JE, Turpie AG. Antithrombotic therapy in patients with mechanical and biological prosthetic heart valves. Chest 2001;119:220S-27S.

16. Bonow RO, Carabello B, de Leon AC, Edmunds LH, Jr., Fedderly BJ, Freed MD, et al. ACC/AHA Guidelines for the Management of Patients With Valvular Heart Disease. Executive Summary. A report of the American College of Cardiology/American Heart Association Task Force on Practice Guidelines (Committee on Management of Patients With Valvular Heart Disease). J Heart Valve Dis 1998;7:672-707.

17. Greaves M, Cohen H, MacHin SJ, Mackie I. Guidelines on the investigation and management of the antiphospholipid syndrome. Br J Haematol 2000;109:704-15.

18. Khamashta MA. Management of antiphospholipid syndrome. CPD Rheumatology 1999;1:22-23.

19. Khamashta MA. Management of thrombosis in the antiphospholipid syndrome. Lupus 1996;5:463-66.

For Peer Review Only

20. Munoz-Rodriguez F, Font J, Cervera R, Reverter JC, TAssies D, Espinosa G, et al. Clinical study and follow-up of 100 patients with the antiphospholipid syndrome. Semin Arthritis Rheum.1999;29:182-90.

21. Ginsberg JS, Wells PS, Brill-Edwards P, Donovan D, Moffat K, Johnston M, et al. Antiphospholipid antibodies and venous thromboembolism. Blood 1995;86:3685-91.

22. Grines CL, Bonow RO, Casey DE Jr, Gardner TJ, Lockhart PB, Moliterno DJ, O'Gara P, Whitlow P; American Heart Association; American College of Cardiology; Society for Cardiovascular Angiography and Interventions; American College of Surgeons; American Dental Association; American College of Physicians. Prevention of premature discontinuation of dual antiplatelet therapy in patients with coronary artery stents: a science advisory from the American Heart Association, American College of Cardiology, Society for Cardiovascular Angiography and Interventions, American College of Surgeons, and American Dental Association, with representation from the American College of Physicians. J Am Coll Cardiol 2007; 49:734-9.

23. Palareti G, Legnani C, Poller L, Thomson J. Warfarin withdrawal. Pharmacokinetic-pharmacodynamic considerations and evidence for "rebound" hypercoagulability after stopping anticoagulants. Clin Pharmacokinet 1996;30:300-13.

24. Genewein U, Haeberli A, Straub PW, Beer JH. Rebound after cessation of oral anticoagulant therapy: the biochemical evidence. Br J Haematol 1996;92:479-85.

25. Palareti G, Legnani C, Guazzaloca G, Frascaro M, Grauso F, De Rosa F, et al. Activation of blood coagulation after abrupt or stepwise withdrawal of oral anticoagulants--a prospective study. Thromb Haemost 1994;72:222-6.

26. Kluft C, Verheijen JH, Jie AF, Rijken DC, Preston FE, Sue-Ling HM, et al. The postoperative fibrinolytic shutdown: a rapidly reverting acute phase pattern for the fast-acting inhibitor of tissue-type plasminogen activator after trauma. Scand J Clin Lab Invest 1985;45:605-10.

27. Rowbotham BJ, Whitaker AN, Harrison J, Murtaugh P, Reasbeck P, Bowie EJ. Measurement of crosslinked fibrin derivatives in patients undergoing abdominal

For Peer Review Only

surgery: use in the diagnosis of postoperative venous thrombosis. Blood Coagul Fibrinolysis 1992;3:25-31.

28. Lip GY, Lowe GD. Fibrin D-dimer: a useful clinical marker of thrombogenesis? Clin Sci (Lond) 1995;89:205-14.

29. Carrel TP, Klingenmann W, Mohacsi PJ, Berdat P, Althaus U. Perioperative bleeding and thromboembolic risk during non-cardiac surgery in patients with mechanical prosthetic heart valves: an institutional review. J Heart Valve Dis 1999;8:392-8.

30. Katholi RE, Nolan SP, McGuire LB. Living with prosthetic heart valves. Subsequent noncardiac operations and the risk of thromboembolism or hemorrhage. Am Heart J 1976;92:162-7.

31. Katholi RE, Nolan SP, McGuire LB. The management of anticoagulation during noncardiac operations in patients with prosthetic heart valves. A prospective study. Am Heart J 1978;96:163-5.

32. Tinmouth AH, Morrow BH, Cruickshank MK, Moore PM, Kovacs MJ. Dalteparin as periprocedure anticoagulation for patients on warfarin and at high risk of thrombosis. Ann Pharmacother 2001;35:669-74.

33. Dunn AS, Turpie AG. Perioperative management of patients receiving oral anticoagulants: a systematic review. Arch Intern Med 2003;163:901-8.

34. Douketis JD, Berger PB, Dunn AS, Jaffer AK, Spyropoulos AC, Becker RC, Ansell J; The perioperative management of antithrombotic therapy: American College of Chest Physicians Evidence-Based Clinical Practice Guidelines (8th Edition). Chest. 2008 Jun;133(6 Suppl):299S-339S.

35. Kallio H, Paloheimo M, Maunuksela EL. Haemorrhage and risk factors associated with retrobulbar/peribulbar block: a prospective study in 1383 patients. Br J Anaesth 2000;85:708-11.

36. Carter K, Miller KM. Phacoemulsification and lens implantation in patients treated with aspirin or warfarin. J Cataract Refract Surg 1998;24:1361-4.

37. Shuler JD, Paschal JF, Holland GN. Antiplatelet therapy and cataract surgery. J Cataract Refract Surg 1992;18:567-71.

For Peer Review Only

38. Katz J, Feldman MA, Bass EB, Lubomski LH, Tielsch JM, Petty BG, et al. Risks and benefits of anticoagulant and antiplatelet medication use before cataract surgery. Ophthalmology 2003;110:1784-8.

39. Gainey SP, Robertson DM, Fay W, Ilstrup D. Ocular surgery on patients receiving long-term warfarin therapy. Am J Ophthalmol 1989;108:142-6.

40. Kumar N, Jivan S, Thomas P, et al. Sub-Tenon's anesthesia with aspirin, warfarin, and clopidogrel. J Cataract Refract Surg 2006; 32:1022–102.

41. Narendran N, Williamson TH. The effects of aspirin and warfarin therapy on haemorrhage in vitreoretinal surgery. Acta Ophthalmol Scand 2003;81:38-40.

42. Fu AD, McDonald HR, Williams DF, Cantrill HL, Ryan EH, Johnson RN, Ai E, Jumper JM. Anticoagulation with warfarin in vitreoretinal surgery. *Retina* 2007;**27**:290-295

43. Dayani PN, Grand MG. Maintenance of warfarin anticoagulation for patients undergoing vitreoretinal surgery. Arch Ophtalmol 2006; 124:1558-1565.

44. Cobb CJ, Chakrabarti S, Chadha V, Sanders R. The effect of aspirin and warfarin therapy in trabeculectomy. *Eye* 2007;**21**:598-603

45. Hannah IT, Powrle S, Rose GE. Open lacrimal surgery: a comparison of admission outcome and complications after planned day case or inpatient management. Br J Ophthalmol 1998;82:392-396

46. Hurwitz JJ. The lacrimal system, Lippincott-Raven 1996, 262-268.

47. Custer PL, Trinkaus KM. Hemorrhagic complications of oculoplastic surgery. Ophthal Plast Reconstr Surg 2002;18:409-15.

48. Otley CC. Continuation of medically necessary aspirin and warfarin during cutaneous surgery. Mayo Clin Proc 2003;78:1392-6.

49. Kargi E, Babuccu O, Hosnuter M, Babuccu B, Altinyazar C. Complications of minor cutaneous surgery in patients under anticoagulant treatment. Aesthetic Plast Surg 2002;26:483-5.

50. Shalom A, Wong L. Outcome of aspirin use during excision of cutaneous lesions. Ann Plast Surg 2003;50:296-8.

For Peer Review Only

51. Ah-Weng A, Natarajan S, Velangi S, Langtry JA. Preoperative monitoring of warfarin in cutaneous surgery. Br J Dermatol 2003;149:386-9.

52. Alcalay J. Cutaneous surgery in patients receiving warfarin therapy. Dermatol Surg 2001;27:756-8.

53. Billingsley EM, Maloney ME. Intraoperative and postoperative bleeding problems in patients taking warfarin, aspirin, and nonsteroidal antiinflammatory agents. A prospective study. Dermatol Surg 1997;23:381-3; discussion 84-5.

54. Otley CC, Fewkes JL, Frank W, Olbricht SM. Complications of cutaneous surgery in patients who are taking warfarin, aspirin, or nonsteroidal anti-inflammatory drugs. Arch Dermatol 1996;132:161-6.

55. Alam M, Goldberg LH. Serious Adverse Vascular Events Associated With Perioperative Interruption of Antiplatelet and Anticoagulant Therapy. Dermatol Surg 2002;28:992-98.

56. Lewis KG, Dufresne RG Jr. A meta-analysis of complications attributed to anticoagulation among patients following cutaneous surgery. Dermatol Surg. 2008 Feb;34(2):160-4.

57. Souto JC, Oliver A, Zuazu-Jausoro I, Vives A, Fontcuberta J. Oral surgery in anticoagulated patients without reducing the dose of oral anticoagulant: a prospective randomized study. J Oral Maxillofac Surg 1996;54:27-32; discussion 323.

58. Evans IL, Sayers MS, Gibbons AJ, Price G, Snooks H, Sugar AW. Can warfarin be continued during dental extraction? Results of a randomized controlled trial. Br J Oral Maxillofac Surg 2002;40:248-52.

59. Carter G, Goss AN, Lloyd J, Tocchetti R. Current concepts of the management of dental extractions for patients taking warfarin. Aust Dent J 2003;48:89-96; quiz 138.

60. Della Valle A, Sammartino G, Marenzi G, Tia M, Espedito di Lauro A, Ferrari F, et al. Prevention of postoperative bleeding in anticoagulated patients undergoing oral surgery: use of platelet-rich plasma gel. J Oral Maxillofac Surg 2003;61:1275-8.

For Peer Review Only

61. Nematullah A, Alabousi A, Blanas N, Douketis JD, Sutherland SE. Dental surgery for patients on anticoagulant therapy with warfarin: a systematic review and meta-analysis. J Can Dent Assoc 2009; 75:41

62. Spandorfer JM, Lynch S, Weitz HH, Fertel S, Merli GJ. Use of enoxaparin for the chronically anticoagulated patient before and after procedures. Am J Cardiol 1999;84:478-80, A10.

63. Matsuzaki K, Okabe H, Kajihara N, Haraguchi N, Nagano I, Tatewaki H, et al. [A prospective study on the timing of discontinuation of aspirin before coronary artery bypass grafting]. Nippon Kyobu Geka Gakkai Zasshi 1997;45:1710-4.

64. Heit JA. Perioperative management of the chronically anticoagulated patient. J Thromb Thrombolysis 2001;12:81-7.

65. Crowther MA, Julian J, McCarty D, Douketis J, Kovacs M, Biagoni L, et al. Treatment of warfarin-associated coagulopathy with oral vitamin K: a randomised controlled trial. Lancet 2000;356:1551-3.

66. Crowther MA, Wilson S. Vitamin K for the treatment of asymptomatic coagulopathy associated with oral anticoagulant therapy. J Thromb Thrombolysis 2003;16:69-72.

67. Ewards MW, Jr., Flemming DC. Deliberate hypotension. Surg Clin North Am 1975;55:947-57.

68. Shepherd J. Hypotensive anaesthesia and blood loss in orthognathic surgery. Evid Based Dent 2004;5:16.

69. Rasgon BM, Cruz RM, Hilsinger RL, Jr., Korol HW, Callan E, Wolgat RA, et al. Infiltration of epinephrine in tonsillectomy: a randomized, prospective, double-blind study. Laryngoscope 1991;101:114-8.

70. Liboon J, Funkhouser W, Terris DJ. A comparison of mucosal incisions made by scalpel, CO2 laser, electrocautery, and constant-voltage electrocautery. Otolaryngol Head Neck Surg 1997;116:379-85.

71. Goldbaum AM, Woog JJ. The CO2 laser in oculoplastic surgery. Surv Ophthalmol 1997;42:255-67.

72. Matras H. Fibrin seal: the state of the art. J Oral Maxillofac Surg 1985;43:605-11.

For Peer Review Only

73. Man D, Plosker H, Winland-Brown JE. The use of autologous platelet-rich plasma (platelet gel) and autologous platelet-poor plasma (fibrin glue) in cosmetic surgery. Plast Reconstr Surg 2001;107:229-37; discussion 38-9.

74. Anitua E, Andia I, Ardanza B, Nurden P, Nurden AT. Autologous platelets as a source of proteins for healing and tissue regeneration. Thromb Haemost 2004;91:4-15.

75. Laitakari K, Luotonen J. Autologous and homologous fibrinogen sealants: adhesive strength. Laryngoscope 1989;99:974-6.

76. Carless PA, Anthony DM, Henry DA. Systematic review of the use of fibrin sealant to minimize perioperative allogeneic blood transfusion. Br J Surg 2002;89:695-703.

77. Rousou J, Levitsky S, Gonzalez-Lavin L, Cosgrove D, Magilligan D, Weldon C, et al. Randomized clinical trial of fibrin sealant in patients undergoing resternotomy or reoperation after cardiac operations. A multicenter study. J Thorac Cardiovasc Surg 1989;97:194-203.

78. Baumann A, Caversaccio M. Hemostasis in endoscopic sinus surgery using a specific gelatin-thrombin based agent (FloSeal). Rhinology 2003;41:244-9.

79. Mathiasen RA, Cruz RM. Prospective, randomized, controlled clinical trial of a novel matrix hemostatic sealant in children undergoing adenoidectomy. Otolaryngol Head Neck Surg 2004;131:601-5.

80. Jorgensen S, Bascom DA, Partsafas A, Wax MK. The effect of 2 sealants (FloSeal and Tisseel) on fasciocutaneous flap revascularization. Arch Facial Plast Surg 2003;5:399-402.

81. Maccabee MS, Trune DR, Hwang PH. Effects of topically applied biomaterials on paranasal sinus mucosal healing. Am J Rhinol 2003;17:203-7.

82. Ellegala DB, Maartens NF, Laws ER, Jr. Use of FloSeal hemostatic sealant in transsphenoidal pituitary surgery: technical note. Neurosurgery 2002;51:513-5; discussion 15-6.

83. Vogel A, O'Grady K, Toriumi DM. Surgical tissue adhesives in facial plastic and reconstructive surgery. Facial Plast Surg 1993;9:49-57.

For Peer Review Only

84. Schonauer C, Tessitore E, Barbagallo G, Albanese V, Moraci A. The use of local agents: bone wax, gelatin, collagen, oxidized cellulose. Eur Spine J 2004;13 Suppl 1:S89-96.

85. Weaver FA, Hood DB, Zatina M, Messina L, Badduke B. Gelatin-thrombin-based hemostatic sealant for intraoperative bleeding in vascular surgery. Ann Vasc Surg 2002;16:286-93.

86. Assia EI, Raskin T, Kaiserman I, al e. Effect of aspirin intake on bleeding during cataract surgery. J Cataract Refract Surg 1998;24:1243-46.

87. Cannon PD, Dharmar VT. Minor oral surgical procedures in patients on oral anticoagulants--a controlled study. Aust Dent J 2003;48:115-8.

88. Devani P, Lavery KM, Howell CJ. Dental extractions in patients on warfarin: is alteration of anticoagulant regime necessary? Br J Oral Maxillofac Surg 1998;36:107-11.

89. Hall DL, Steen WH, Jr., Drummond JW, Byrd WA. Anticoagulants and cataract surgery. Ophthalmic Surg 1988;19:221-2.

90. McCormack P, Simcock PR, Tullo AB. Management of the anticoagulated patient for ophthalmic surgery. Eye 1993;7:749-50.

91. McMahon LB. Anticoagulants and cataract surgery. J Cararact Refract Surg 1988;14:569-71.

92. Morris A, Elder MJ. Warfarin therapy and cataract surgery. Clin Experiment Ophthalmol 2000;28:419-22.

93. Roberts CW, Wood SM, Turner L. Cataract surgery in anticoagulated patients. J Cararact Refract Surg 1991;17:309-12.

94. Robinson GA, Nylander A. Warfarin and cataract extraction. Br J Ophthalmol 1989;73:702-3.

95. Rotenstreich Y, Rubowitz A, Segev F, Jaeger-Roshu S, Assia EI. Effect of warfarin therapy on bleeding during cataract surgery. J Cataract Refract Surg 2001;27:1344-6.

For Peer Review Only

96. Saitoh AK, Saitoh A, Taniguchi H, Amemiya T. Anticoagulation therapy and ocular surgery. Ophthalmic Surg Lasers 1998;29:909-15.

97. Schanbacher CF, Bennett RG. Postoperative stroke after stopping warfarin for cutaneous surgery. Dermatol Surg 2000;26:785-9.

For Peer Review Only

Table 1. Potential problems in interrupting anti-coagulant therapy

- Delay in urgent surgery
    - 3-5 days with warfarin
    - 1-2 weeks with aspirin & clopidogrel
- The need to admit patients to administer bridging heparin therapy
- Risk of thrombosis-related complications: several days needed to re-establish therapeutic INR
- Rebound hypercoagulability on disrupting warfarin

For Peer Review Only

Box

Grades of Evidence	
I	Strongest evidence usually consisting of randomised controlled trials and well conducted meta-analysis.
II	Studies that provide significant evidence but with some deficiencies (non-randomised comparative trials, cohort and case-control studies as well as case-series with significant numbers).
III	Weaker evidence consisting of small non-comparative case series and case reports
Recommendations	
A	Very important or crucial to good clinical outcome.
B	Moderate importance to clinical outcome
C	Considered relevant but not definitely related to the clinical outcome.

For Peer Review Only

Table 2. Evidence included in this systematic review of antithrombotic therapy

Author	N	Type of surgery	Antithrombotic agent	Findings	Comment	Level of Evidence
Ah-Weng A, 2003[51]	68rx	Cutaneous	Warfarin	No serious significant bleeding in warfarinized patient (median INR 3.4)		III
Alam M, 2002[55]	2	Cutaneous	Aspirin, Clopidogrel	Thrombophilia on disruption of warfarin	Two cases	III
Alcalay J, 2001[52]	32	Cutaneous	Warfarin	Warfarin can be continued		II
Assia EI, 1998[7]	61	Cataract	Aspirin	Peri-operative aspirin use appears safe in cataract surgery		II
Billingsley EM, 1997[53]		Cutaneous	Warfarin, anti-platelet & NSAIDS	Bleeding risk not increased		II
Cannon PD, 2003[87]	70	Oral	Warfarin	Dental extraction safe in anti-coagulated patients	Average INR in treated group was 3.4. Duration of post-op follow-up was five days. No statistical analysis	II
Carter K, 1998[36]	87/81	Ophthalmic	Aspirin	No serious bleeding from surgery or local anesthesia including retrobulbar injection		III
Carrel TP, 1999[29]	235	multiple	warfarin	Thromboembolic complications may occur up to one month after surgery	Patients with mitral prosthetic valves and atrial fibrillation are at the highest risk for thrombosis.	III
Custer PL, 2002[47]		Oculoplastic	Warfarin, anti-platelet			II
Devani P, 1998[88]	65	Oral	Warfarin	No significant post-op bleeding with INR up to 4	Case-controlled study	II
Dunn AS, 2003[33]	1868	Meta-analysis	Warfarin	Cataract surgery safe in anti-coagulated patients		II
Evans IL, 2002[58]	109	Oral	Warfarin	Higher rate of bleeding in warfarinized group		II

For Peer Review Only

Gainey SP, 1989[39]	50	Ophthalmic	Warfarin	Higher rate of haemorrhagic complications in anti-coagulated patients		III
Hall, DL, 1988[89]	49	Ophthalmic	Warfarin	Cataract surgery safe in anti-coagulated patients. 3 patients had hyphaema with good visual outcome	Warfarin not stopped for surgery. Retrobulbar and peribulbar blocks	III
Kallio H, 2000[35]	1383	Ophthalmic	Warfarin, anti-platelet	Peribulabar and retrobulbar anaesthesia is safe in patients usinga aspirin, NSAIDS or warfarin	Thromboplastin time measured rather than INR	II
Kargi E, 2002[41]	102	Cutaneous	Warfarin, Aspirin	Warfarin use associated with significantly higher risk of bleeding complications	Aspirin was not associated with increased bleeding.	II
Katholi RE, 1976[30]	111	multiple	warfarin	Two deaths on caseation of warfarin	Mitral or combined prosthetic valves associated with high risk of thromboembolism	II
Katz J, 2003[38]	19,354	Ophthalmic	Warfarin, Aspirin	Bleeding risk is not increased in patients that continued to use aspirin/warfarin intraoperatively.	INR levels for warfarinized patients not mentioned. Seven day post-op follow-up.	II
McCormack P, 1993[90]	41	Ophthalmic	Warfarin	No major haemorrhagic complication due anesthesia or surgery	Warfarin not discontinued. INR range 1.1-4.9	III
McMahon LB, 1988[91]	22/28	Ophthalmic	Warfarin	No major bleeding complication	Warfain continued per-operatively	III
Morris A, 2000[92]	28	Ophthalmic	Warfarin	Cataract surgery safe in anti-coagulated patients	Mean INR 1.52	III
Narendran N, 2003[41]	541	Vitreo-retinal	Warfarin, aspirin	Aspirin does not increase the risk of intra or post-op bleeding. Warfarin carries a higher risk (RR 6.1)	Of nine post-op bleeds, eight occurred in non-anti-coagulated patients	III
Otley CC, 1996[54]	653	Cutaneous	Warfarin, anti-platelet	Anti-coagulants did not increase the bleeding risk compared to controls	Stopping anti-coagulants did not reduce the risk of bleeding	III
Palareti G, 1994[23]	32	Multiple	Warfarin	Two of 17 patients had thrombotic events	Abrupt cessation of	II

For Peer Review Only

				following abrupt cessation of warfarin	warfarin results in increased circulating activated coagulation products	
Roberts CW, 1991[93]	31	Cataract	Anti-coagulants			III
Robinson GA, 1989[94]	10	Cataract	Warfarin	No major haemorrhagic complication due anesthesia or surgery	Warfarin not discontinuedINR not mentioned.	III
Rotenstreich, Y 2001[95]	25	Cataract	Warfarin	Cataract surgery safe in warfarinized patients	INR range 1.8-3.2	II
Saitoh, AK, 1998[96]	50	Cataract	Aspirin, warfarin, Ticlopidine	Increased risk of bleeding with Ticlopidine. None with aspirin, warfarin		III
Schambacher CF, 2000[97]	2	Cutaneous	Warfarin	Stroke occurred on cessation of warfarin	Warfarin re-started immediately post-op: stroke occurred one week later	III
Shuler JD, 1992[37]	60	Ophth	Aspirin			II
Shalom A, 2003[50]	253	Cutaneous	Aspirin	Patients on aspirin required greater intra-operative effort to achieve hemostasis. No major difference in haemorrhagic complication (wound dehiscence, hematoma).	No statistical analysis	II
Souto JC, 1996[57]	92	Oral	Warfarin	Warfarin should be continued for oral surgery	92 patients randomised to six study arms	II

For Peer Review Only

Table 3. Systemic disease and the risk of thrombosis

Venous thrombosis > 3/12 ago	Low risk
Non-valvular atrial fibrillation	
Bio-prosthetic valve	↓
Aortic prosthetic valve	Moderate risk
Atrial fibrillation	
Mitral valve	High risk
Recurrent arterio/venous thrombophilia	↓
Venous thrombosis < 1/12	

For Peer Review Only

Table 4.

Evidence based recommendations for peri-operative management of warfarin and aspirin.

Aspirin or warfarin should not be discontinued prior to peri-ocular infiltration of local anesthetic (sub-tenon, peri-bulbar or retro-bulbar).	A (II)
In the presence of vasculopathic risk factors, aspirin should not be stopped prior to any type of ophthalmic surgery.	B (II)
Cataract surgery can be safely carried out in patients taking aspirin or warfarin.	A (II)
*With the exception of vitreo-retinal surgery, warfarin should be continued in patients undergoing ophthalmic surgery as the risk of thrombophilia is higher than the risk of significant bleeding.	B (II)
Peri-operative modification of anti-coagulants should only be carried out after advice from a cardiologist/ clinical hematologist.	A ( )
#In moderate to high risk patients, rather than stopping warfarin pre-operatively, its dose should be modified to reduce the INR to the lower end of the therapeutic range.	A ( )

* No evidence found regarding glaucoma filtration surgery
\# Therapeutic INR range: 2-3.5

For Peer Review Only
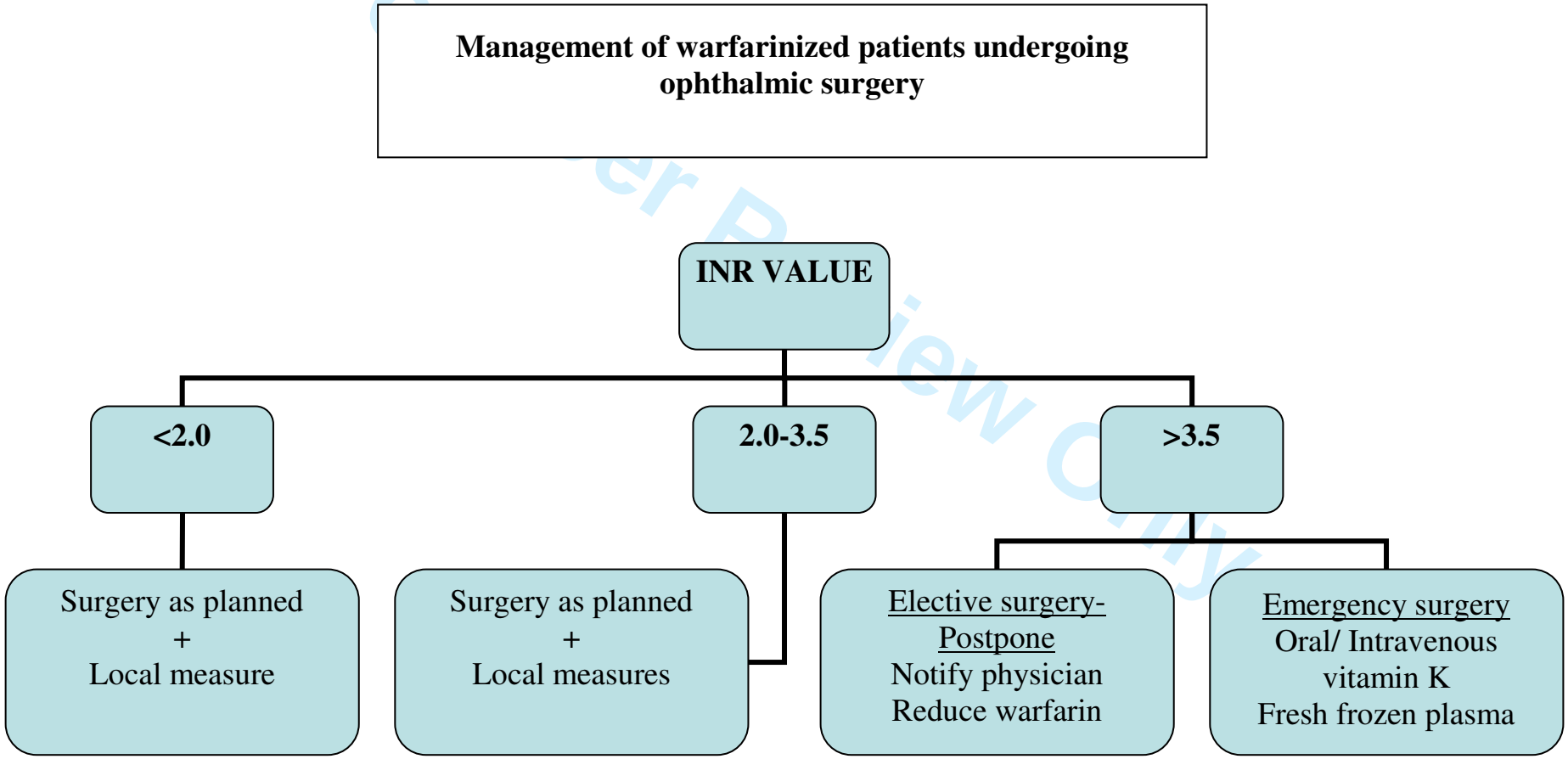
Figure 1. Management of warfarinized patients undergoing ophthalmic surgery