



HAL
open science

The clinical spectrum of missense mutations of the first aspartic acid of cbEGF-like domains in fibrillin-1 including a recessive family

Yvonne Hilhorst-Hofstee, Marry Eb Rijlaarsdam, Arthur Jha Scholte, Marietta Swart-van den Berg, Michel Im Versteegh, Iris van Der Schoot-van Velzen, Hans-Joachim Schäbitz, Emilia Bijlsma, Marieke J Baars, Wilhelmina S. Kerstjens-Frederikse, et al.

► To cite this version:

Yvonne Hilhorst-Hofstee, Marry Eb Rijlaarsdam, Arthur Jha Scholte, Marietta Swart-van den Berg, Michel Im Versteegh, et al.. The clinical spectrum of missense mutations of the first aspartic acid of cbEGF-like domains in fibrillin-1 including a recessive family. *Human Mutation*, 2010, 31 (12), <10.1002/humu.21372>. <hal-00613753>

HAL Id: hal-00613753

<https://hal.science/hal-00613753v1>

Submitted on 6 Aug 2011

HAL is a multi-disciplinary open access archive for the deposit and dissemination of scientific research documents, whether they are published or not. The documents may come from teaching and research institutions in France or abroad, or from public or private research centers.

L'archive ouverte pluridisciplinaire **HAL**, est destinée au dépôt et à la diffusion de documents scientifiques de niveau recherche, publiés ou non, émanant des établissements d'enseignement et de recherche français ou étrangers, des laboratoires publics ou privés.



HAL Authorization



The clinical spectrum of missense mutations of the first aspartic acid of cbEGF-like domains in fibrillin-1 including a recessive family

Journal:	<i>Human Mutation</i>
Manuscript ID:	humu-2010-0053.R2
Wiley - Manuscript type:	Mutation in Brief
Date Submitted by the Author:	20-Aug-2010
Complete List of Authors:	Hilhorst-Hofstee, Yvonne; Leiden University Medical Center, Clinical Genetics Rijlaarsdam, Marry; Leiden University Medical Center, Pediatric Cardiology Scholte, Arthur; Leiden University Medical Center, Cardiology Swart-van den Berg, Marietta; Leiden University Medical Center, Ophthalmology Versteegh, Michel; Leiden University Medical Center, Cardiothoracic surgery van der Schoot-van Velzen, Iris; Leiden University Medical Center, Clinical Genetics Schäbitz, Hans-Joachim; Allgemeinmedizin Bijlsma, Emilia; Leiden University Medical Center, Clinical Genetics Baars, Marieke; Academic Medical Center Amsterdam, Clinical Genetics Kerstjens-Frederikse, Wilhelmina; University Medical Center Groningen, Medical Genetics Giltay, Jacques; University Medical Center Utrecht, Medical Genetics Hamel, Ben; University Medical Centre, Human Genetics Breuning, Martijn; Leiden University Medical Center, Clinical Genetics Pals, Gerard; VU University Medical Center, Clinical Genetics
Key Words:	Marfan syndrome, fibrillin-1 (FBN1) gene, cbEGF domain, pathogenesis, autosomal recessive inheritance

SCHOLARONE™
Manuscripts

1
2
3
4
5
6
7
8
9
10
11
12
13
14
15
16
17
18
19
20
21
22
23
24
25
26
27
28
29
30
31
32
33
34
35
36
37
38
39
40
41
42
43
44
45
46
47
48
49
50
51
52
53
54
55
56
57
58
59
60

For Peer Review

MUTATION IN BRIEF

HUMAN MUTATION

For Peer Review

Received 2 February 2010; accepted revised manuscript 15 September 2010.

© 2010 WILEY-LISS, INC.

1
2
3
4
5
6
7
8
9
10
11
12
13
14
15
16
17
18
19
20
21
22
23
24
25
26
27
28
29
30
31
32
33
34
35
36
37
38
39
40
41
42
43
44
45
46
47
48
49
50
51
52
53
54
55
56
57
58
59
60

MUTATION IN BRIEF

HUMAN MUTATION

The Clinical Spectrum of Missense Mutations of the First Aspartic Acid of cbEGF-like Domains in Fibrillin-1 Including a Recessive Family



Yvonne Hilhorst-Hofstee¹, Marry EB Rijlaarsdam², Arthur JHA Scholte³, Marietta Swart-van den Berg⁴, Michel IM Versteegh⁵, Iris van der Schoot-van Velzen¹, Hans-Joachim Schäbitz⁶, Emilia K Bijlsma¹, Marieke J Baars⁷, Wilhelmina S Kerstjens-Frederikse⁸, Jacques C Giltay⁹, Ben C Hamel¹⁰, Martijn H Breuning¹, and Gerard Pals¹¹

*1*Department of Clinical Genetics, *2*Department of Pediatric Cardiology, *3*Department of Cardiology, *4*Department of Ophthalmology and *5*Department of Cardiothoracic Surgery, Leiden University Medical Center, Leiden, the Netherlands; *6*Bielefeld, Deutschland; *7*Department of Clinical Genetics, *8*Academic Medical Center, Amsterdam, The Netherlands; *8*Department of Genetics, University Medical Center Groningen, University of Groningen, Groningen, The Netherlands; *9*Department of Medical Genetics, University Medical Center Utrecht, Utrecht, The Netherlands; *10*Department of Human Genetics, Radboud University Nijmegen Medical Center, Nijmegen, The Netherlands; *11*Department of Clinical Genetics, Center for Connective Tissue Research, VU University Medical Center, Amsterdam, the Netherlands

*Correspondence to Yvonne Hilhorst-Hofstee, MD, Department of Clinical Genetics, Leiden University Medical Center, K5R, Albinusdreef 2, 2333 ZA LEIDEN, THE NETHERLANDS.

Phone: +31715268033; Fax: +31715266749; E-mail: hilhorst@lumc.nl

Communicated by Reed E. Pyeritz

ABSTRACT: Marfan syndrome (MFS) is a dominant disorder with a recognizable phenotype. In most patients with the classical phenotype mutations are found in the fibrillin-1 gene (*FBNI*) on chromosome 15q21. It is thought that most mutations act in a dominant negative way or through haploinsufficiency. In 9 index cases referred for MFS we detected heterozygous missense mutations in *FBNI* predicted to substitute the first aspartic acid of different calcium-binding Epidermal Growth Factor-like (cbEGF) fibrillin-1 domains. A similar mutation was found in homozygous state in 3 cases in a large consanguineous family. Heterozygous carriers of this mutation had no major skeletal, cardiovascular or ophthalmological features of MFS. In the literature 14 other heterozygous missense mutations are described leading to the substitution of the first aspartic acid of a cbEGF domain and resulting in a Marfan phenotype. Our data show that the phenotypic effect of aspartic acid substitutions in the first position of a cbEGF domain can range from asymptomatic to a severe neonatal phenotype. The recessive nature with reduced expression of *FBNI* in one of the families suggests a threshold model combined with a mild functional defect of this specific mutation. ©2010 Wiley-Liss, Inc.

KEY WORDS: Marfan syndrome, fibrillin-1, *FBNI* gene, autosomal recessive inheritance, pathogenesis

Received 2 February 2010; accepted revised manuscript 15 September 2010.

© 2010 WILEY-LISS, INC.

INTRODUCTION

Human fibrillin-1 is a large protein of approximately 350 kD and member of a family of extracellular cysteine-rich glycoproteins. Since 1991 mutations in the fibrillin-1 (*FBN1*) gene have been found to be responsible for Marfan syndrome (MFS; MIM# 134797) (Kainulainen et al., 1990; Dietz et al., 1991). Fibrillin-1 is characterized by a highly conserved modular domain organization. The most prominent domain is the Epidermal Growth Factor-like (EGF) domain present 46 times and containing six highly conserved cysteine residues stabilizing the structure by three disulfide bonds. Of these EGF domains, 43 have a consensus sequence for calcium binding (cb) in the N-terminal pocket of the domain which may mediate protein-protein interactions. The EGF domains are interrupted by seven transforming growth factor (TGF)-binding protein domains characterized by 8 cysteine residues involved in intra-domain disulfide bonds (Pereira et al., 1993; Robinson et al., 2006). In the last update of the Universal Marfan Database – *FBN1* (UMD-*FBN*; <http://www.umd.be>) (Faivre et al., 2007) 803 different mutations are reported. Most of the mutations are missense mutations (56%) mainly substituting or creating a cysteine in a cbEGF domain. Other mutations are frameshift mutations, splice mutations and nonsense mutations. About 14% of mutations are recurring.

All cbEGF domains start with a highly conserved aspartic acid, which is crucial for binding of a positively charged Ca^{2+} ion (Whiteman et al., 2007). We have identified 10 index cases with a substitution of the first aspartic acid substitution of a cbEGF domain and reviewed a further 14 published cases. Most of them exhibit a complete MFS phenotype. Surprisingly, in one family the substitution only led to MFS in homozygous state in three family members, whereas 13 family members carrying the heterozygous mutation do not have Marfan syndrome after thorough clinical examination.

There is still a lot of debate how mutations in *FBN1* result in the MFS phenotype, but increasing evidence for different models is emerging. Possible explanations for the observed extreme variation in expression of the substitution of the first aspartic acid of a cbEGF domain are discussed. The observation of recessive inheritance of an expected dominant mutation also underscores the fact that mutations which are predicted to have a pathogenic effect, may not always lead to clinical symptoms.

PATIENTS AND METHODS

Patients

The patients were referred for DNA analysis of the fibrillin-1 gene to confirm the clinical diagnosis of MFS. Case 1, 2, 5, 7, 9 and 10 fulfilled the clinical Ghent criteria (De Paepe A. et al., 1996) for the diagnosis MFS. All index patients fulfilled the Ghent criteria when the finding of a pathogenic mutation in *FBN1* was included.

Case 9 belongs to a large Turkish pedigree (Figure 1, III-1). She was examined at the age of 22 years. At the age of 6 weeks she was operated on a right sided hernia inguinalis. She was diagnosed with bilateral subluxation of the lens when she was 3 years old. From that time on she has been operated several times for retinal detachments and lens luxation. At the age of 14 years an aortic root replacement was performed for progressive aortic root dilatation and aortic valve regurgitation. A spontaneous pneumothorax occurred at the age of 16 years.

Clinical examination at the age of 18 years showed a marfanoid habitus, slight downslanting of palpebral fissures and a high and gothic palate. Despite long fingers, wrist and thumb signs were negative. She exhibited limited extension of her elbows, mild asymmetry of the chest, and bilateral flat feet. Her skin showed several striae on the chest, shoulders, hips and lower back. Her length was 179.5 cm (+3,7SD for Turkish descent) and an arm span of 175 cm (within normal limits). The brother of case 9 (III-3) was a 13 year old boy with Marfan syndrome. He had mild skeletal manifestations of Marfan (pes planus), a mildly dilated aortic root, ectopia lentis and dural ectasia with an anterior sacral meningocele. Furthermore he suffered from recurrent episodes of intracranial hypertension treated by drainage of cerebrospinal fluid. He has been described in a case report (Hilhorst-Hofstee et al., 2008).

The third patient (II-15) died at the age of 22 years. His case history was obtained from the medical records. At the age of 2 years bilateral subluxation of lenses was diagnosed. He developed severe aortic and mitral valve regurgitation with an aneurysm of the aortic root. He had skeletal involvement and an anterior sacral meningocele. When he was 17 years of age an aortic root replacement was performed with reconstruction of the aortic and mitral

4 Hilhorst-Hofstee Y et al.

valve. Due to progressive aortic regurgitation, a re-operation was performed a year later. He died at the age of 22 after a second episode of ventricular fibrillation.

All heterozygous family members had a thorough skeletal, cardiologic and ophthalmologic examination including anthropometric measurements, echocardiography and slit lamp evaluation (Table 1). Only the mother and father of case 9 had an MRI evaluation for dural ectasia. The obtained clinical data of all family members are summarized in Table 1. The father of case 9 (II-6) had no clinical signs of Marfan syndrome. The mother (II-7) was tall, with a height on +2.5 SD but with normal body proportions. She had no other skeletal, ocular or cardiovascular involvement, but had several striae on the lumbar region and around the knees. Furthermore she suffered from spontaneous pneumothorax at the age of 21 years. An MRI-scan showed a dural ectasia at S2 with otherwise a normal dural sac. The father and mother of II-15 did not exhibit any signs of Marfan syndrome. None of the nine other heterozygous family members had a major criterion in one of the organ systems. Some were found to have a non-specific or minor sign. Individual II-1 has an arm span to height ratio of 1.06 and a mild dilatation of the abdominal aorta. II-4 had recurrent inguinal hernias but this was during a period of performing heavy physical labor. II-8 had an arm span to height ratio of 1.07 and bilateral flat feet. II-9 had reduced extension of the elbows.

The clinical data of cases 1- 10 and published cases are summarized in Table 2 together with the molecular data.

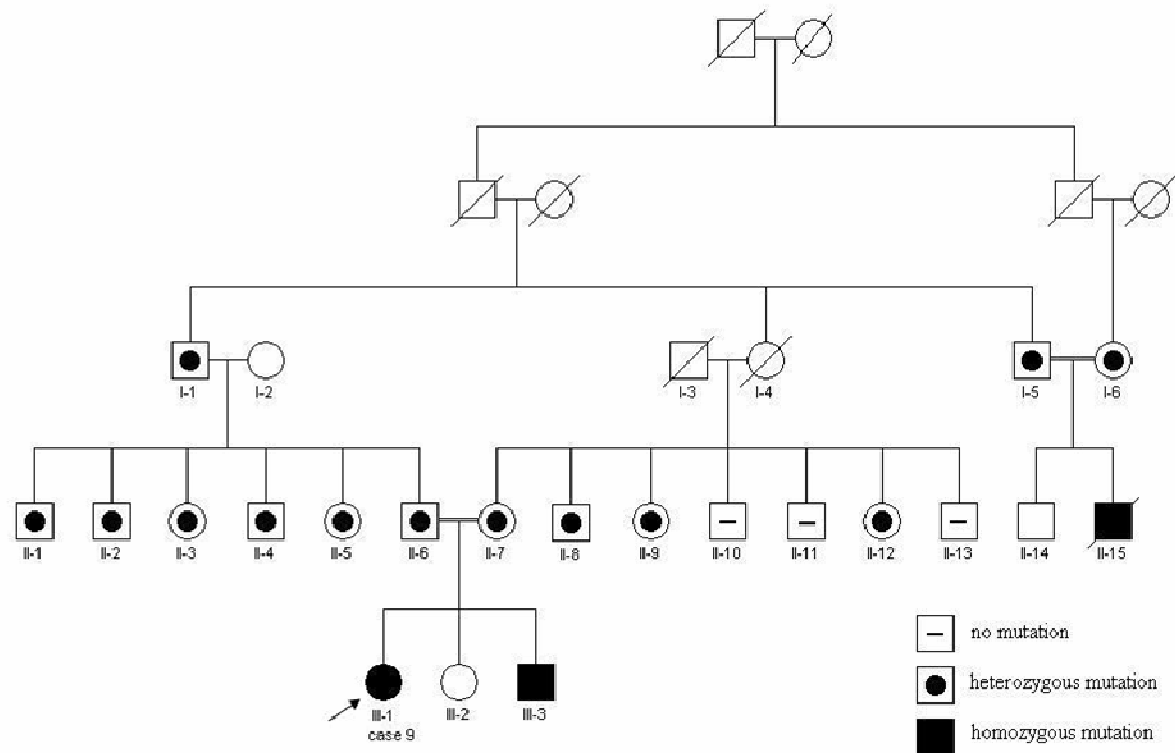


Figure 1. Pedigree of the family of case 9. Squares, male subjects; circles, female subjects. Affected subjects with a homozygous mutation (c.7454A>T) are represented by solid symbols. Presence or absence of the heterozygous mutation is represented by an open symbol with a black dot or a minus symbol respectively.

Table 1. Summary of the clinical features in the family of case 9

	III-1 Case 9	III-3	II-6	II-7	II-15	I-5	I-6	I-1	II-1	II-2	II-3	II-4	II-5	II-8	II-9	II-12
Age at examination (years)	22	10	42	43	9	57	56	61	44	41	37	35	33	55	48	37
Sex	F	M	M	F	M	M	F	M	M	M	F	M	F	M	F	F
height (cm)	180,9	150,5	167,1	174,4	135,0	164,0	157,5	166,0	167,5	174,5	167,0	188,5	161,0	181,0	164,7	161,0
height SDS (for Turkish descent)	3,7	1,6	-1,2	2,5	-0,2	-1,7	-0,6	-1,4	-1,1	0,1	1,1	2,5	0,8	1,2	0,7	0,2
arm span : height ratio	0,97	1,02	1,04	1,00	1,00	1,01	1,03	1,01	1,06	1,04	0,98	0,99	1,02	1,07	1,02	1,03
sitting height : height ratio	0,515	0,488	0,536	0,513	np	0,535	0,528	0,519	0,527	0,517	0,531	0,516	0,523	0,482	0,520	0,526
sitting height : height ratio SDS	-0,8	-2,0	1,6	-0,8	np	1,5	0,2	0,3	1,0	0,3	0,3	0,2	0,0	-1,8	-0,4	0,0
Skeletal system	involv	involv	none	none	involv	none	none	none	none	none	none	none	none	involv	none	none
major																
pectus carinatum	no	no	no	no	yes	no	no	no	no	no	no	no	no	no	no	no
pectus excavatum requiring surgery	no	no	no	no	no	no	no	no	no	no	no	no	no	no	no	no
sitting height : height ratio <2 SD or armspan : height ratio >1.05	no	yes	no	no	np	no	no	no	yes	no	no	no	no	yes	no	no
wrist and thumbsigns	no	no	no	no	no	no	no	no	no	no	no	no	no	no	no	no
scoliosis of >20° or spondylolisthesis	no	no	no	no	np	no	no	no	no	no	no	no	no	no	no	no
reduced extension at the elbow (<170°)	yes	no	no	yes	np	no	no	no	no	no	no	no	no	no	yes	no
pes planus	yes	yes	no	no	yes	no	no	no	no	no	no	yes	no	yes	no	no
protrusio acetabulae	np	np	np	np	np	np	np	np	np	np	np	np	np	np	np	np
minor																
pectus excavatum of moderate severity	no	no	no	no	yes	no	no	no	no	no	no	no	no	no	no	no
joint hypermobility	no	no	no	no	np	no	no	no	no	no	no	no	no	no	no	no
highly arched palate with crowding	yes	no	no	no	yes	no	no	no	no	no	no	no	no	no	no	no
facial appearance	yes	no	no	no	yes	no	no	no	no	no	no	no	no	no	no	no
Ocular system	major	major	none	none	major	none	none	none	none	none	none	none	none	none	none	none
major																
ectopia lentis	yes	yes	no	no	yes	no	no	no	no	no	no	no	no	no	no	no
minor																
abnormally flat cornea	np	np	np	np	np	no	no	no	no	no	no	no	no	no	no	no
increased axial length of globe	np	np	np	np	np	np	np	np	np	np	np	np	no	no	no	no
hypoplastic iris or ciliary muscle	np	np	no	no	yes	no	no	no	no	no	no	no	no	no	no	no

6 Hilhorst-Hofstee Y et al.

Table 1. Continued

	III-1 Case 9	III-3	II-6	II-7	II-15	I-5	I-6	I-1	II-1	II-2	II-3	II-4	II-5	II-8	II-9	II-12
Cardiovascular system	major	major	none	none	major	none	none	none	involv	none	none	none	none	none	none	none
major																
Z-score aortic root diameter	10,5 ¹	4	0.3	-1.4	>2 ²	-0.9	-0.8	-1.8	1.4	-1.1	-0.8	-2.9	-2.5	0.4	0.5	0.8
dilatation ascending aorta	yes (arr)	yes	no	no	yes (arr)	no	no	no	no	no	no	no	no	no	no	no
dissection of ascending aorta	no	no	no	no	no	no	no	no	no	no	no	no	no	no	no	no
minor																
mitral valve prolaps	yes	yes	no	no	yes	no	no	no	no	no	no	no	no	no	no	no
dilatation of main pulmonary artery	no	no	no	no	np	no	no	no	no	no	no	no	no	no	no	no
calcification of the mitral annulus < 40 years	no	no	no	no	np	no	no	np	no	no	no	no	no	no	no	no
dilatation or dissection of descending aorta < 50 years	no	no	np	no	np	no	no	no	yes	no	no	no	no	no	no	no
Pulmonary system	involv	none	none	involv	none	none	none	none	none	none	none	none	none	none	none	none
minor																
spontaneous pneumothorax or apical blebs	yes	no	no	yes	no	no	no	no	no	no	no	no	no	no	no	no
Skin and integument	involv	none	none	involv	np	none	none	none	none	none	involv	involv	none	none	none	none
minor																
striae atrophicae	yes	no	no	yes	np	no	no	no	no	no	yes	no	no	no	no	no
recurrent or incisional herniae	no	no	no	no	np	no	no	no	no	no	no	yes ³	no	no	no	no
Dura	np	major	none	major	np	np	np	np	np	np	np	np	np	np	np	np
major																
lumbosacral dural ectasia	np	yes	no	yes	np	np	np	np	np	np	np	np	np	np	np	np
Family or genetic history	major⁴	major⁴	major⁴	major⁴	major⁴	major⁴	major⁴	major⁴	major⁴	major⁴	major⁴	major⁴	major⁴	major⁴	major⁴	major⁴
major																
1st degree relative with Marfan syndrome	no	yes	yes	yes	no	yes	yes	no	no	no	no	no	no	no	no	no
pathogenic mutation in <i>FBN1</i>	hom	hom	het	het	hom	het	het	het	het	het	het	het	het	het	het	het

F female; M male; involve involvement; np not performed; arr aortic root replacement; hom homozygous c.7454A>T *FBN1* mutation; het heterozygous c.7454A>T *FBN1* mutation; Z-score related to body surface area and age according to Roman et al. (Roman et al., 1989); 1) aortic root measurement at the age of 14 years just before aortic root replacement; 2) no exact measurement available; 3) recurrent inguinal hernias during a period of heavy duty; 4) major criterion on the basis of a first degree affected family member or the presence of a pathogenic *FBN1* mutation.

Molecular studies

DNA was extracted from peripheral blood or paraffin embedded tissue, using standard techniques, analyzed by DHPLC and direct DNA sequencing as described previously (Matyas et al., 2002).

The reference sequence used to describe the mutations is the *FBN1* cDNA GenBank reference sequence: NM_000138.3. Nucleotide numbering reflects cDNA numbering with +1 corresponding to the A of the ATG translation initiation codon in the reference sequence, according to journal guidelines (www.hgvs.org/mutnomen).

Skin biopsies of case 1, 9 and her mother and case 10 were available. Fibroblasts were cultured and mRNA was isolated from confluent monolayers. For each individual two RNA isolations were performed: one cell culture of each was incubated with cycloheximide (0.25 mg/ml) for 4.5 hours prior to RNA isolation, to prevent possible nonsense mediated decay (NMD) of aberrantly spliced mRNA.

RNA was isolated using the RNA isolation minikit (Qiagen) according to the manufacturers instructions. Full length single stranded cDNA was prepared with oligo-dT-primer and SuperscriptTMII RT reverse transcriptase (Invitrogen). To detect possible splice errors, the complete coding sequence of *FBN1* was analyzed by direct sequencing in 24 overlapping PCR fragments. The primers for overlapping fragments were positioned in different exons, to avoid allele dropout in case of exon skipping. For analysis of the mutation in exon 60, primers in exon 55 (forward) and 63 (reverse) were used.

Primer sequences are given in Supp. Table S1.

RESULTS

Heterozygous mutations leading to a substitution of the first aspartic acid of a cbEGF domain were found in nine index cases and a homozygous mutation was found in 1 index case. These mutations and 14 comparable mutations described in the literature or in the UMD-*FBN1* (UMD-*FBN1*; <http://www.umd.be>) are listed in Table 2. The phenotypes were classical MFS in 15 cases, neonatal MFS in two cases, thoracic aortic aneurysm in one case and lens luxation with striae in one case. In four cases described in the literature the phenotype is not clear.

The mutation was de novo in cases 2, 4, 5, and 8. In case 1, 3 and 6 parental DNA was not available. In case 1 five sibs were tested negative for the mutation. In case 6 the parents and seven sibs had no clinical symptoms of MFS. Case 7 has an affected sister with the same mutation. Their father died as a consequence of his third aortic dissection when he was 52 years of age. He was thought to have MFS. The mother of case 10 is probably affected but was not molecularly tested. Of the published mutations three were de novo, three were familial and in eight inheritance was unknown (Table 2).

Using DHPLC for mutation scanning of all 65 exons of *FBN1*, initially no mutation was found in case 9. As the parents are consanguineous, a recessive mutation was suspected. Testing one of the parents, a heterozygous mutation was detected in exon 60: c.7454A>T, leading to the amino acid substitution p.Asp2485Val. This mutation was found in a homozygous state in the patients III-1, III-3 and II-15. The parents (II-6 and II-7) of patients III-1 and III-3 are first cousins. The parents of patient II-15 are distantly related and both are related to II-6 and II-7 (Figure 1). In the parents of patients III-1, III-3 and II-15 and 9 family members the mutation was heterozygous. The mutation was not detected in 1000 Caucasian and 60 Turkish control chromosomes.

Sequence analysis of cDNA, made from mRNA from cultured fibroblasts of case 1, case 9 and her mother, and case 10 showed no evidence of erroneous splicing of exon 60. Treatment with cycloheximide, to prevent possible nonsense mediated decay of erroneously spliced mRNA, gave the same results. Fibroblasts of the other patients were not available.

8 Hilhorst-Hofstee Y et al.

Table 2. Published and observed missense mutations leading to the substitution of the first aspartic acid of a cbEGF domain

Nucleotide change	Amino acid change	Exon	cbEGF domain	Diagnosis	Phenotype	Reference	Aberant mRNA splicing	Predicted aberant mRNA splicing ^a	Inheritance
c.1468G>T	p.Asp490Tyr	11	#3	Classical MFS	ard, el, sk	(Hayward and Brock, 1997)	np	yes	Unknown
c.2168A>C	p.Asp723Ala	18	#7	Severe classical MFS	ard,.mvp, el, myop, sk	(Dietz et al., 1993)	np	no	De novo
c.2168A>T	p.Asp723Val	18	#7	Classical MFS	ard,.mvp, el, sk, myop	(Katzke et al., 2002)	np	no	De novo
c.2728G>A	p.Asp910Asn	22	#10	Classical MFS	unknown	UMD	np	yes	Unknown
c.3209A>G	p.Asp1070Gly	26	#12	Neonatal MFS	unknown	UMD	np	no	Unknown
c.3338A>G	p.Asp1113Gly	27	#13	Phenotype unknown	unknown	(Liu et al., 1997)	np	no	Unknown
c.3463G>A	p.Asp1155Asn	27	#14	Thoracic aortic aneurysm	ard,.mvp, diss	(Milewicz et al., 1996)	no	yes	De novo
c.3464A>G	p.Asp1155Gly	28	#14	Classical MFS	ard, el	Case 1	no	no	Parents not available, 5 sibs neg for mutation
c.3712G>A	p.Asp1238Asn	29	#16	Phenotype unknown	unknown	(Yuan et al., 1999)	np	no	Unknown
c.3713A>G	p.Asp1238Gly	30	#16	Classical MFS	ard,.mvp, sk	(Tiecke et al., 2001)	np	no	Familial
c.3964G>A	p.Asp1322Asn	31	#18	Neonatal MFS	ard, mi, ti, myop, sk	Case 2	np	yes	De novo
c.4210G>T	p.Asp1404Tyr	33	#20	Classical MFS	ard, el, sk	(Hayward et al., 1997)	yes	yes	Familial
c.5422G>C	p.Asp1808His	43	#26	Lens luxation and striae	el, str	Case 3	np	no	Parents not available
c.5671G>A	p.Asp1891His	45	#28	Classical MFS	ard, sk	Case 4	np	no	De novo
c.5788G>C	p.Asp1930His	45	#29	Classical MFS	ard, el, sk	Case 5	np	yes	De novo
c.5788G>A	p.Asp1930Asn	46	#29	Phenotype unknown	unknown	(Liu et al., 1997)	np	yes	Unknown
c.5788G>A	p.Asp1930Asn	46	#29	Classical MFS	ard, el, sk, de, str	Case 6	np	yes	Parents not available
c.6037G>T	p.Asp2013 Tyr	48	#31	Classical MFS	ard, el, sk, de, str	Case 7	np	yes	Familial
c.6379G>T	p.Asp2127Tyr	51	#32	Classical MFS	ard, el	(Matsukawa et al., 2001)	np	yes	Familial
c.6381T>A	p.Asp2127Glu	52	#32	Classical MFS	ard, sk	(Kainulainen et al., 1994)	np	no	Familial
c.7331A>G	p.Asp2444Gly	59	#38	Classical MFS	ard, sk	Case 8	np	no	De novo
c.7454A>T	p.Asp2485Val	60	#39	Classical MFS in homozygous state	ard, el, sk, str, her, pn	Case 9	no	no	Familial
c.7819G>A	p.Asp2607Asn	62	#42	Classical MFS	ard,.mvp, sk	Case 10	no	no	Mother suspect for MFS
c.7820A>G	p.Asp2607Gly	63	#42	Phenotype unknown	unkown	(Liu et al., 1997)	np	no	Unknown

UMD Universal Marfan Database – *FBN1* (UMD-*FBN1*; <http://www.umd.be>); cbEGF calcium binding Epidermal Growth Factor domain; bp basepair; np not performed; neg negative; pos positive; ard aortic root dilatation; diss aortic dissection;.mvp mitral valve prolapse, mi mitral valve insufficiency; el ectopia lentis; pal high arched palate; ti tricuspid valve insufficiency; myop high myopia; ar arachnodactyly; hm hypermobility; contr contractures; str striae; her hernia; sk skeletal involvement; de dural ectasia; pn pneumothorax; unknown. The gray row represents the recessive mutation described in this article.

Mutation numbering refers to the *FBN1* cDNA GenBank reference sequence: NM_000138.3, with the A of the ATG translation initiation codon as nucleotide +1 (www.hgvs.org/mutnomen).^a) Alamut mutation interpretation software version 1.5; Interactive Biosoftware, Rouen France.

DISCUSSION

We identified a heterozygous substitution of the first aspartic acid of a cbEGF domain in *FBN1* in nine index patients and a homozygous substitution in one index patient with MFS. Reviewing the literature we found 12 reports of substitution of the first aspartic acid, and a further two unpublished cases are quoted in the UMD database (UMD-*FBN*; <http://www.umd.be>) (Collod-Beroud et al., 2003) as summarized in Table 2. All 10 index patients found in our center fulfilled the Ghent criteria when the finding of a pathogenic mutation was included. Of the 14 published cases, eight were reported to have a classical Marfan phenotype, one was a neonatal Marfan and one had a thoracic aortic aneurysm. Of four cases the phenotype was not reported. In all cases the acidic amino acid aspartic acid is replaced by a nonpolar or noncharged polar amino acid, apart from one mutation where aspartic acid is replaced by another acidic amino acid (p.Asp2127Glu) (Kainulainen et al., 1994). The codons of the first aspartic acids in the cbEGF domains always contain the last base of one exon and the first two bases of the next. Consequently, mutations of these codons may affect splicing. Aberrant splicing was excluded in cases 1, 9, and 10 and in one of the published cases (Milewicz et al., 1996). The mutation c.4210G>T was shown to destroy a donor splice site with abnormal splicing as a consequence (Hayward et al., 1997). Of the 19 cases in which no cDNA analysis was performed, prediction software predicted aberrant splicing in eight cases (Table 2). Exon skipping, as a result of these mutations, may have more severe effects than missense mutations, because the exons are all in frame and consequently, skipping will lead to a shorter protein that may exert a dominant negative effect (Robinson et al., 2002).

There are several reasons to argue that a substitution of the first aspartic acid of a cbEGF domain will lead to a MFS phenotype in the heterozygous state. Calcium binding of cbEGF domains is necessary for stabilization of the secondary structure, prevention of proteolytic degradation and for protein-protein interaction (Dietz et al., 1993; Handford et al., 1991; Cooke et al., 1987). The first aspartic acid of a cbEGF domain is highly conserved in evolution and in the human fibrillin-1 gene all cbEGF domains start with an aspartic acid, which is crucial for binding of a positively charged Ca^{2+} ion (Figure 2) (Whiteman et al., 2007). Furthermore mutations of the first amino acid of a cbEGF domain of coagulation factor IX in haemophilia B have been proven to reduce calcium binding even if the aspartic acid is replaced by the acidic amino acid glutamic acid (Handford et al., 1991; Winship and Dragon, 1991). The finding of 23 MFS or MFS-like cases with a heterozygous substitution of an aspartic acid in this position of the cbEGF domain underscores the crucial role of this amino acid. In this view the recessive nature of the mutation p.Asp2485Val in the family of case 9 came as a surprise. The family of case 9 (Figure 1) has been thoroughly investigated. Patients III-1 (case 9), III-3 and II-15 have the classical type of Marfan syndrome according to the Ghent criteria (De Paepe A. et al., 1996). Based on the pedigree with three affected patients and healthy consanguineous parents recessive inheritance could be expected. This was confirmed by finding a homozygous missense mutation in all three affected patients. The four unaffected parents and nine other unaffected relatives were found to be carriers of the mutation. Unexpectedly in none of the investigated heterozygous carriers obvious signs of Marfan syndrome could be found. Only after thorough clinical examination one of them (II-7) was found to have a dural ectasia at S2, which as yet is considered a major symptom in the Ghent criteria. Together with the family history and some minor signs (pneumothorax, striae and reduced extension of the elbows) this classifies II-7 as having Marfan syndrome. However, compared to the homozygous cases, the cardinal Marfan features in the skeletal, cardiac and ophthalmological systems are absent.

10 Hilhorst-Hofstee Y et al.

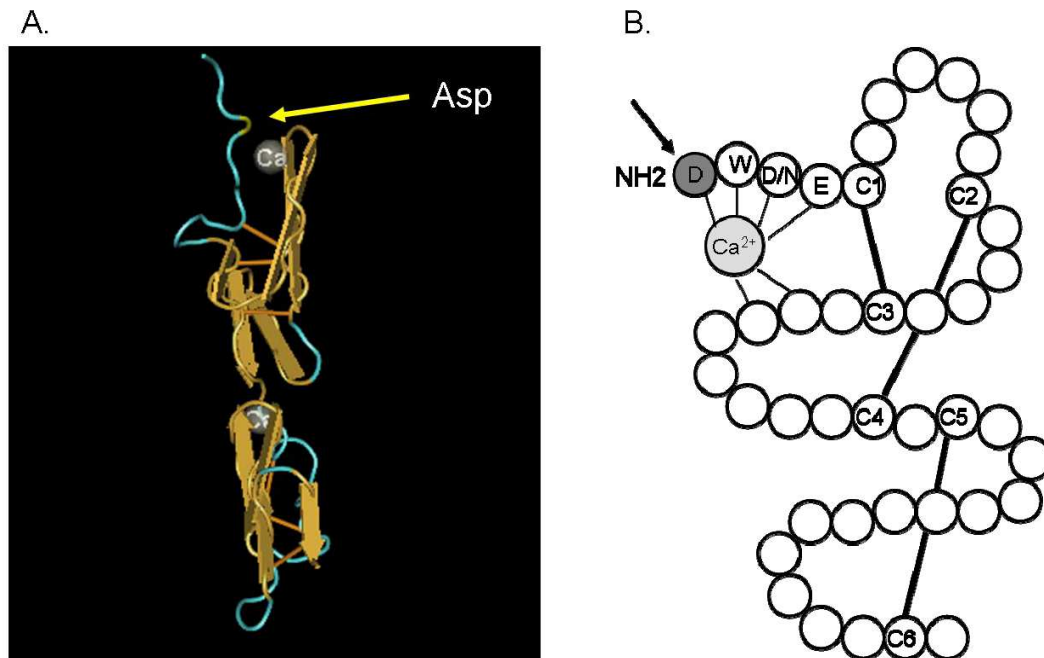


Figure 2. Class I cbEGF domain showing the position of the first Asp in relation to the calcium molecule. (A) 3D picture of a cbEGF domain of fibrillin-1. The yellow arrow points to the first Asp. Picture derived from the NCBI database (<http://www.ncbi.nlm.nih.gov/>) (Downing et al., 1996). (B) cbEGD like domain (Handford et al., 1991). The arrow points to the first aspartic acid residue. Solid lines are the disulphide bridges between cysteine residues.

To our knowledge very little is known about recessive *FBNI* mutations. Only one family has been reported in which Marfan syndrome was found in two affected cousins homozygous for a *FBNI* mutation while the four normal parents were heterozygous carriers, indicating recessive inheritance of the syndrome (De Vries et al., 2007). The mutation is located in exon 11 and leads to an amino-acid substitution creating a cysteine. Like us the authors expected this mutation to have a dominant effect in the heterozygous state. Two of the parents were sibs and exhibited minor signs of Marfan syndrome (increased arm span to height ratio and a highly arched palate). No other family members have been investigated. Only one other probably recessively inherited form of Marfan syndrome has been described but could not be proven by molecular analysis as the gene was not yet known (Fried and Krakowsky, 1977).

Three families have been described in the literature in which both parents are affected with more severely affected children. The first is an Italian couple of first cousins, both affected with Marfan syndrome, who had 4 affected children. Two of the four affected children showed more severe manifestations than other affected family members, presumably due to homozygosity (Capotorti L. et al., 1959). In 1984, Chemke described a family with Marfan syndrome. Two sibs suffered from a severe phenotype reminiscent of neonatal Marfan syndrome. Their parents were cousins and had a much milder phenotype. Remarkable is that the probably homozygous sibs were the only patients in the family with ectopia lentis (Chemke et al., 1984). In 1988 a severely affected boy has been described (Schollin et al., 1988). Both parents were affected and were found to carry a missense mutation in *FBNI*. Compound heterozygosity was identified in the severely affected child (Karttunen et al., 1994).

In the recessive family described here the heterozygous mutation does not exert an important effect on the phenotype. Only in the homozygous state the abnormal fibrillin causes the classical clinical phenotype of Marfan syndrome. This observation together with the few other described families with bi-allelic inheritance, may support both alternative pathogenetic models of Marfan syndrome. A dominant negative effect of *FBNI* mutations has been the leading hypothesis for the pathogenesis of Marfan syndrome for a long time. However, several manifestations of Marfan syndrome like bone overgrowth, craniofacial features, lung disease, and muscle and fat hypoplasia could not be explained by a structurally abnormal protein. The observation that fibrillin interacts with a variety of proteins, including the latent TGF β binding proteins (LTBP's) has lead to several investigations

Mutations of First Aspartic Acid of cbEGF-like Domains in *FBNI* 11

1
2
3 indicating that fibrillin-1 can interact with TGF β signaling (Annes et al., 2003; Azhar et al., 2003; Isogai et al.,
4 2003; Hubmacher et al., 2006; Kaartinen and Warburton, 2003; Loeys et al., 2006; Neptune et al., 2003; Ng et al.,
5 2004; Ten Dijke and Arthur, 2007).

6 According to splice site prediction software (Alamut mutation interpretation software version 1.5; Interactive
7 Biosoftware, Rouen, France) the c.7454A>T mutation, found in the family described here, is not predicted to cause
8 erroneous splicing. This was confirmed by cDNA studies, showing no evidence of splice error. The position of the
9 mutation (exon 60) may explain the lack of expression as mutations in the more C-terminal end of the gene are
10 expected to give a milder phenotype (Faivre et al., 2007; Robinson et al., 2002). However the mutation in case 10
11 is even more terminal and still leads to a classical MFS phenotype.

12 Hutchinson et al. (Hutchinson et al., 2003) hypothesized that variable expression of the normal *FBNI* allele
13 could moderate the phenotypic effect of the mutant allele. A compensatory higher level of *FBNI* expression from
14 the normal allele would explain a milder phenotype. As the normal alleles are inherited from 5 different parents in
15 our recessive family, this mechanism is highly unlikely.

16 We hypothesize that the p.Asp2485Val mutation acts as a hypomorphic allele with a minimal dominant
17 negative effect. Reduction of gene expression of both alleles could be the main determinant of the phenotype in
18 homozygotes. The observation of only one major clinical sign in one of the heterozygotes (dural ectasia in II-7,
19 Figure 1) and no major clinical signs in 12 other heterozygotes could be explained by sufficient gene expression
20 with only a mild functional defect of the mutant allele product. This was also shown in a mouse model, however in
21 this model the mutation had a severe dominant negative effect (Pereira et al., 1997). In this model with a deletion
22 of 272 amino acids in the central part of fibrillin-1, a tenfold reduction in expression of the mutant allele was
23 shown in heterozygous mice, resulting in a normal phenotype. Homozygous mutant mice however died shortly
24 after birth due to severe vascular complications. The other mouse model of Pereira was a targeted *FBNI* mutation
25 leading to 15% expression of a normal product with no abnormal phenotype in heterozygous mice, while mice
26 homozygous for this mutation have severe abnormalities comparable with the neonatal MFS phenotype. These
27 mouse models suggests that there is a threshold of expression of the normal allele below which the abnormal
28 phenotype will develop (Pereira et al., 1999; Dietz and Mecham, 2000).

29 To understand the exact pathogenetic mechanism expression studies and studies on protein synthesis, secretion
30 and matrix incorporation of the Asp2486Val mutation are necessary For comprehensive studies of this type, a
31 mouse model should be created.

32 The finding of a homozygous substitution of A>T, as described here, has implications for mutation screening in
33 MFS. Homozygous substitutions will not have an effect on denaturation of double stranded DNA, because the
34 basepair remains the same. Consequently, heteroduplex based testing, such as DHPLC, working with the principle
35 of differential denaturation of double stranded heteroduplex DNA, cannot detect this mutation in homozygous
36 state. Formerly, based on the presumed dominant inheritance mode, only heterozygous mutations were expected.
37 Now it is clear that recessive inheritance is also possible and mutations may have been missed in similar cases,
38 because heteroduplex based testing has been used until recently in many large diagnostic centers. Most
39 laboratories nowadays use direct sequencing, which avoids this problem.

40 In conclusion we have shown that the first aspartic acid of a cbEGF domain in *FBNI* is important for the
41 function of fibrillin-1, but may not always lead to a clinical effect in the heterozygous state. This underscores that
42 missense mutations must be interpreted with care.
43
44

45 46 47 ACKNOWLEDGMENTS

48 We thank the patients and their families for their very kind cooperation, Prof. Dr. E. Bakker for his helpful
49 suggestions and Jacqueline Egthuijsen for technical assistance.
50

51 52 53 REFERENCES

- 54 Annes JP, Munger JS, Rifkin DB. 2003. Making sense of latent TGFbeta activation. *J Cell Sci* 116:217-224.
55 Azhar M, Schultz JJ, Grupp I, Dorn GW, Meneton P, Molin DG, Gittenberger-de Groot AC, Doetschman T. 2003.
56 Transforming growth factor beta in cardiovascular development and function. *Cytokine Growth Factor Rev* 14:391-407.
57
58
59
60

12 Hilhorst-Hofstee Y et al.

- 1
2
3 Capotorti L., Gaddini de Benedetti R, Rizzo P. 1959. Contribution to the study of the heredity of Marfan's syndrome:
4 description of a family tree of 4 generations with marriage between consanguineous parents. *Acta Genet Med Gemellol*
5 8:455-482.
- 6
7 Chemke J, Nisani R, Feigl A, Garty R, Cooper M, Barash Y, Duksin D. 1984. Homozygosity for autosomal dominant Marfan
8 syndrome. *J Med Genet* 21:173-177.
- 9
10 Collod-Beroud G, Le Bourdelles S, Ades L, Ala-Kokko L, Booms P, Boxer M, Child A, Comeglio P, De Paepe A, Hyland JC,
11 Holman K, Kaitila I, Loeys B, Matyas G, Nuytinck L, Peltonen L, Rantamaki T, Robinson P, Steinmann B, Junien C,
12 Beroud C, Boileau C. 2003. Update of the UMD-FBN1 mutation database and creation of an FBN1 polymorphism database.
13 *Hum Mutat* 22:199-208.
- 14
15 Cooke RM, Wilkinson AJ, Baron M, Pastore A, Tappin MJ, Campbell ID, Gregory H, Sheard B. 1987. The solution structure
16 of human epidermal growth factor. *Nature* 327:339-341.
- 17
18 De Paepe A., Devereux RB, Dietz HC, Hennekam RC, Pyeritz RE. 1996. Revised diagnostic criteria for the Marfan syndrome.
19 *Am J Med Genet* 62:417-426.
- 20
21 De Vries BB, Pals G, Odink R, Hamel BC. 2007. Homozygosity for a FBN1 missense mutation: clinical and molecular
22 evidence for recessive Marfan syndrome. *Eur J Hum Genet* 15:930-935.
- 23
24 Dietz HC, Cutting GR, Pyeritz RE, Maslen CL, Sakai LY, Corson GM, Puffenberger EG, Hamosh A, Nanthakumar EJ,
25 Curristin SM, . 1991. Marfan syndrome caused by a recurrent de novo missense mutation in the fibrillin gene. *Nature*
26 352:337-339.
- 27
28 Dietz HC, McIntosh I, Sakai LY, Corson GM, Chalberg SC, Pyeritz RE, Francomano CA. 1993. Four novel FBN1 mutations:
29 significance for mutant transcript level and EGF-like domain calcium binding in the pathogenesis of Marfan syndrome.
30 *Genomics* 17:468-475.
- 31
32 Dietz HC, Mecham RP. 2000. Mouse models of genetic diseases resulting from mutations in elastic fiber proteins. *Matrix Biol*
33 19:481-488.
- 34
35 Downing AK, Knott V, Werner JM, Cardy CM, Campbell ID, Handford PA. 1996. Solution structure of a pair of calcium-
36 binding epidermal growth factor-like domains: implications for the Marfan syndrome and other genetic disorders. *Cell*
37 85:597-605.
- 38
39 Faivre L, Collod-Beroud G, Loeys BL, Child A, Binquet C, Gautier E, Callewaert B, Arbustini E, Mayer K, Arslan-Kirchner
40 M, Kiotsekoglou A, Comeglio P, Marziliano N, Dietz HC, Halliday D, Beroud C, Bonithon-Kopp C, Claustres M, Muti C,
41 Plauchu H, Robinson PN, Ades LC, Biggin A, Benetts B, Brett M, Holman KJ, De Backer J, Coucke P, Francke U, De
42 Paepe A, Jondeau G, Boileau C. 2007. Effect of mutation type and location on clinical outcome in 1,013 probands with
43 Marfan syndrome or related phenotypes and FBN1 mutations: an international study. *Am J Hum Genet* 81:454-466.
- 44
45 Fried K, Krakowsky D. 1977. Probable autosomal recessive Marfan syndrome. *J Med Genet* 14:359-361.
- 46
47 Handford PA, Mayhew M, Baron M, Winship PR, Campbell ID, Brownlee GG. 1991. Key residues involved in calcium-
48 binding motifs in EGF-like domains. *Nature* 351:164-167.
- 49
50 Hayward C, Porteous ME, Brock DJ. 1997. Mutation screening of all 65 exons of the fibrillin-1 gene in 60 patients with Marfan
51 syndrome: report of 12 novel mutations. *Hum Mutat* 10:280-289.
- 52
53 Hilhorst-Hofstee Y, Kroft LJ, Pals G, Van Vugt JP, Overweg-Plandsoen WC. 2008. Intracranial hypertension in 2 children with
54 marfan syndrome. *J Child Neurol* 23:954-955.
- 55
56 Hubmacher D, Tiedemann K, Reinhardt DP. 2006. Fibrillins: from biogenesis of microfibrils to signaling functions. *Curr Top*
57 *Dev Biol* 75:93-123.
- 58
59 Hutchinson S, Furger A, Halliday D, Judge DP, Jefferson A, Dietz HC, Firth H, Handford PA. 2003. Allelic variation in normal
60 human FBN1 expression in a family with Marfan syndrome: a potential modifier of phenotype? *Hum Mol Genet* 12:2269-
2276.
- Isogai Z, Ono RN, Ushiro S, Keene DR, Chen Y, Mazzieri R, Charbonneau NL, Reinhardt DP, Rifkin DB, Sakai LY. 2003.
Latent transforming growth factor beta-binding protein 1 interacts with fibrillin and is a microfibril-associated protein. *J
Biol Chem* 278:2750-2757.
- Kaartinen V, Warburton D. 2003. Fibrillin controls TGF-beta activation. *Nat Genet* 33:331-332.

Mutations of First Aspartic Acid of cbEGF-like Domains in *FBN1* 13

- 1
2
3 Kainulainen K, Karttunen L, Puhakka L, Sakai L, Peltonen L. 1994. Mutations in the fibrillin gene responsible for dominant
4 ectopia lentis and neonatal Marfan syndrome. *Nat Genet* 6:64-69.
- 5
6 Kainulainen K, Pulkkinen L, Savolainen A, Kaitila I, Peltonen L. 1990. Location on chromosome 15 of the gene defect causing
7 Marfan syndrome. *N Engl J Med* 323:935-939.
- 8
9 Karttunen L, Raghunath M, Lonnqvist L, Peltonen L. 1994. A compound-heterozygous Marfan patient: two defective fibrillin
10 alleles result in a lethal phenotype. *Am J Hum Genet* 55:1083-1091.
- 11
12 Loeys BL, Schwarze U, Holm T, Callewaert BL, Thomas GH, Pannu H, De Backer JF, Oswald GL, Symoens S, Manouvrier S,
13 Roberts AE, Faravelli F, Greco MA, Pyeritz RE, Milewicz DM, Coucke PJ, Cameron DE, Braverman AC, Byers PH, De
14 Paepe AM, Dietz HC. 2006. Aneurysm syndromes caused by mutations in the TGF-beta receptor. *N Engl J Med* 355:788-
15 798.
- 16
17 Matyas G, De Paepe A, Halliday D, Boileau C, Pals G, Steinmann B. 2002. Evaluation and application of denaturing HPLC for
18 mutation detection in Marfan syndrome: Identification of 20 novel mutations and two novel polymorphisms in the *FBN1*
19 gene. *Hum Mutat* 19:443-456.
- 20
21 Milewicz DM, Michael K, Fisher N, Coselli JS, Markello T, Biddinger A. 1996. Fibrillin-1 (*FBN1*) mutations in patients with
22 thoracic aortic aneurysms. *Circulation* 94:2708-2711.
- 23
24 Neptune ER, Frischmeyer PA, Arking DE, Myers L, Bunton TE, Gayraud B, Ramirez F, Sakai LY, Dietz HC. 2003.
25 Dysregulation of TGF-beta activation contributes to pathogenesis in Marfan syndrome. *Nat Genet* 33:407-411.
- 26
27 Ng CM, Cheng A, Myers LA, Martinez-Murillo F, Jie C, Bedja D, Gabrielson KL, Hausladen JM, Mecham RP, Judge DP,
28 Dietz HC. 2004. TGF-beta-dependent pathogenesis of mitral valve prolapse in a mouse model of Marfan syndrome. *J Clin*
29 *Invest* 114:1586-1592.
- 30
31 Pereira L, Andrikopoulos K, Tian J, Lee SY, Keene DR, Ono R, Reinhardt DP, Sakai LY, Biery NJ, Bunton T, Dietz HC,
32 Ramirez F. 1997. Targetting of the gene encoding fibrillin-1 recapitulates the vascular aspect of Marfan syndrome. *Nat*
33 *Genet* 17:218-222.
- 34
35 Pereira L, D'Alessio M, Ramirez F, Lynch JR, Sykes B, Pangilinan T, Bonadio J. 1993. Genomic organization of the sequence
36 coding for fibrillin, the defective gene product in Marfan syndrome. *Hum Mol Genet* 2:1762.
- 37
38 Pereira L, Lee SY, Gayraud B, Andrikopoulos K, Shapiro SD, Bunton T, Biery NJ, Dietz HC, Sakai LY, Ramirez F. 1999.
39 Pathogenetic sequence for aneurysm revealed in mice underexpressing fibrillin-1. *Proc Natl Acad Sci U S A* 96:3819-3823.
- 40
41 Robinson PN, Arteaga-Solis E, Baldock C, Collod-Beroud G, Booms P, De Paepe A, Dietz HC, Guo G, Handford PA, Judge
42 DP, Kielty CM, Loeys B, Milewicz DM, Ney A, Ramirez F, Reinhardt DP, Tiedemann K, Whiteman P, Godfrey M. 2006.
43 The molecular genetics of Marfan syndrome and related disorders. *J Med Genet* 43:769-787.
- 44
45 Robinson PN, Booms P, Katzke S, Ladewig M, Neumann L, Palz M, Pregla R, Tiecke F, Rosenberg T. 2002. Mutations of
46 *FBN1* and genotype-phenotype correlations in Marfan syndrome and related fibrillinopathies. *Hum Mutat* 20:153-161.
- 47
48 Roman MJ, Devereux RB, Kramer-Fox R, O'Loughlin J. 1989. Two-dimensional echocardiographic aortic root dimensions in
49 normal children and adults. *Am J Cardiol* 64:507-512.
- 50
51 Schollin J, Bjarke B, Gustavson KH. 1988. Probable homozygotic form of the Marfan syndrome in a newborn child. *Acta*
52 *Paediatr Scand* 77:452-456.
- 53
54 Ten Dijke P, Arthur HM. 2007. Extracellular control of TGFbeta signalling in vascular development and disease. *Nat Rev Mol*
55 *Cell Biol* 8:857-869.
- 56
57 Whiteman P, Willis AC, Warner A, Brown J, Redfield C, Handford PA. 2007. Cellular and molecular studies of Marfan
58 syndrome mutations identify co-operative protein folding in the cbEGF12-13 region of fibrillin-1. *Hum Mol Genet* 16:907-
59 918.
- 60
Winship PR, Dragon AC. 1991. Identification of haemophilia B patients with mutations in the two calcium binding domains of
factor IX: importance of a beta-OH Asp 64----Asn change. *Br J Haematol* 77:102-109.

14 Hilhorst-Hofstee Y et al.

Supp. Table S1. Primers for cDNA sequencing of *FBN1*: F=forward; R=reverse; numbers refer to position in cDNA sequence

fragment	primename	Sequence 5' > 3'	Length bp
1	FBN1F1	ATGCGTCGAGGGCGTCTGCT	384
	FBN1R384	GCTACCTCCATTCATACAGCGA	
2	FBN1F318	GATAGCTCCTTCCTGTGGCTCC	406
	FBN1R728	CCGTGCGGATATTTGGAATG	
3	FBN1F657	CCCCTGTGAGATGTGTCCTG	407
	FBN1R1064	TTGGTTATGGACTGTGGCAGC	
4	FBN1F1012	ACAGCTCTGACAAACGGGCG	384
	FBN1R1396	TGCAGCGTCCATTTTGACAG	
5	FBN1F1358	GCCAGTTGGTCCGCTATCTC	330
	FBN1R1688	ACATGAAAGCCCGCATTACAC	
6	FBN1F1609	AATGGCCGGATCTGCAATAA	398
	FBN1R2007	CTGGCCTCTTGTATCCACCA	
7	FBN1F1927	CTGGCTGTGGGTCTGGATGG	362
	FBN1R2289	GCAGTTTTCCAGTTGAATCC	
8	FBN1F2212	ATCTGTGAAAACCTTCGTGGGA	399
	FBN1R2611	AGGTGGCTCCATTGATGTGA	
9	FBN1F2458	GTCTGCAAGAACAGCCAGG	357
	FBN1R2815	TGGGACACTGACACTTGAATGA	
10	FBN1F2699	TACTCAAGAATTAAGGAACA	525
	FBN1R3224	CGGCATTCTGCAATGTCTGTGC	
11	FBN1F3141	CATTGGCAGCTTTAAGTGCAGG	460
	FBN1R3621	ACCACCATTTCATTATGCTGCA	
12	FBN1F3558	CCATTCAACTCCCGATAGGCT	335
	FBN1R3893	TTTTACAGGTCCCCTTAGGC	
13	FBN1F3783	CAGGTGCTTGTGTTATGATG	392
	FBN1R4173	GCACAGACAGCGTAAGA	
14	FBN1F4062	GATTGGAGATGGCATTAAAGTGC	451
	FBN1R4513	TGTTGACACAGTCCCCTGCA	
15	FBN1F4425	CTACGAACTGGACAGAAGCGG	593
	FBN1R5018	ATACAGGTGTAGTTGCCAACGG	
16	FBN1F4910	ACTACCTGAATGAAGATACACG	626
	FBN1R5536	GACCTGTGGAGGTGAAGCGGTAG	
17	FBN1F5348	TCAACATGGTTGGCAGCTTCC	476
	FBN1R5824	AAAGATTCCCATTTCCTACTGC	
18	FBN1F5722	ACAATTGGTTCCTTCAACTG	356
	FBN1R6074	GCACAAATTTCTGGCTCTT	
19	FBN1F5973	CTTGGATGGGTCTACAGATGC	579
	FBN1R6552	CACATTCTGCAGGTTCATT	
20	FBN1F6466	GGTTATACTCTAGCGGGAATG	450
	FBN1R6937	TCCCACGGGTGTTGAGGCAGCG	
21	FBN1F6842	AGCGGAGACCTGATGGAGAGG	645
	FBN1R7487	CAGTTGTGTTGCTTGGTTGCA	
22	FBN1F7429	CAAGAGGATGGAAGGAGCTGC	476
	FBN1R7905	GAAGTTCATACTGGAAGCCG	
23	FBN1F7785	CTACCTCCAGCACTACCACTGG	384
	FBN1R8169	GTAGCCATTGATCTTCACTCG	
24	FBN1F8024	CACCTGGTTACTTCCGCATAGG	672
	FBN1R8696	ATGATTCTGATTGGGGGAAAA	