



HAL
open science

CHD7 mutations and CHARGE syndrome: the clinical implications of an expanding phenotype

Jorieke E.H. Bergman, Nicole Janssen, Lies H. Hoefsloot, Marjolijn C.J. Jongmans, Robert M.W. Hofstra, Conny M.A. van Ravenswaaij

► **To cite this version:**

Jorieke E.H. Bergman, Nicole Janssen, Lies H. Hoefsloot, Marjolijn C.J. Jongmans, Robert M.W. Hofstra, et al.. CHD7 mutations and CHARGE syndrome: the clinical implications of an expanding phenotype. *Journal of Medical Genetics*, 2011, 48 (5), pp.334. 10.1136/jmg.2010.087106 . hal-00613261

HAL Id: hal-00613261

<https://hal.science/hal-00613261>

Submitted on 4 Aug 2011

HAL is a multi-disciplinary open access archive for the deposit and dissemination of scientific research documents, whether they are published or not. The documents may come from teaching and research institutions in France or abroad, or from public or private research centers.

L'archive ouverte pluridisciplinaire **HAL**, est destinée au dépôt et à la diffusion de documents scientifiques de niveau recherche, publiés ou non, émanant des établissements d'enseignement et de recherche français ou étrangers, des laboratoires publics ou privés.

**CHD7 mutations and CHARGE syndrome:
the clinical implications of an expanding phenotype**

**JEH Bergman,¹ N Janssen,¹ LH Hoefsloot,² MCJ Jongmans,² RMW Hofstra,¹ CMA
van Ravenswaaij-Arts¹**

¹ Department of Genetics, University Medical Centre Groningen, University of Groningen, Groningen, the Netherlands; ² Department of Human Genetics, Radboud University Nijmegen Medical Centre, Nijmegen, the Netherlands

* Correspondence to: C.M.A. van Ravenswaaij-Arts, Department of Genetics, University Medical Centre Groningen, P.O. Box 30.001, 9700 RB Groningen, the Netherlands, c.m.a.van.ravenswaaij@medgen.umcg.nl, telephone number +31-503617229, fax number +31-503617231.

Keywords: CHARGE syndrome, CHD7, phenotypic spectrum

Word count: 3623 (2000-5000)

ABSTRACT

Background CHARGE syndrome is a highly variable, multiple congenital anomaly syndrome, of which the complete phenotypic spectrum was only revealed after identification of the causative gene in 2004. CHARGE is an acronym for ocular coloboma, congenital heart defects, choanal atresia, retardation of growth and development, genital hypoplasia and ear anomalies associated with deafness. This typical combination of clinical features is caused by autosomal dominant mutations in the *CHD7* gene.

Objective This review explores the emerging phenotypic spectrum of *CHD7* mutations, with a special focus on the mild end of the spectrum.

Methods We evaluated the clinical characteristics in our own cohort of 280 *CHD7*-positive patients and in previously reported patients with *CHD7* mutations and compared these with previously reported patients with CHARGE syndrome but an unknown *CHD7* status. We then further explored the mild end of the phenotypic spectrum of *CHD7* mutations.

Results We discuss that CHARGE syndrome is primarily a clinical diagnosis. In addition, we propose guidelines for *CHD7* analysis and indicate when evaluation of the semicircular canals is helpful in the diagnostic process. Finally, we give updated recommendations for clinical surveillance of patients with a *CHD7* mutation, based on our exploration of the phenotypic spectrum and on our experience in a multidisciplinary outpatient clinic for CHARGE syndrome.

Conclusion CHARGE syndrome is an extremely variable clinical syndrome. *CHD7* analysis can be helpful in the diagnostic process, but the phenotype cannot be predicted from the genotype.

INTRODUCTION

The first patients with what later became known as CHARGE syndrome (OMIM #214800) were described in 1961.[1, 2] In 1979, two independent clinicians recognised that coloboma, choanal atresia and congenital heart defects clustered together in several patients.[3, 4] The acronym CHARGE dates from 1981 and summarises some of the cardinal features: ocular coloboma, congenital hear defects, choanal atresia, retardation of growth and/or development, genital anomalies and ear anomalies associated with deafness.[5] In 2004, mutations in the *CHD7* gene were identified as the major cause and ‘CHARGE association’ was changed to ‘CHARGE syndrome’.[6] CHARGE syndrome occurs in approximately 1 in 10,000 newborns.[7] The inheritance pattern is autosomal dominant with variable expressivity. Almost all mutations occur *de novo*, but parent-to-child transmission has occasionally been reported.[8] In this review, we explore the phenotypic spectrum of *CHD7* mutations with special focus on the mild end of the spectrum. In the light of this expanding phenotype, we discuss whether CHARGE syndrome is a clinical or a molecular diagnosis, we propose guidelines for *CHD7* analysis, and give updated recommendations for the clinical surveillance of *CHD7*-positive patients.

BACKGROUND

Clinical diagnosis

Before discovery of the causative gene, CHARGE syndrome was a clinical diagnosis (Figure 1). Pagon was the first to introduce diagnostic criteria for CHARGE syndrome in 1981,[5] but these criteria are no longer in use. At present, the clinical criteria by Blake and Verloes are used in conjunction (Table 1).[9, 10]

Table 1 Clinical criteria for CHARGE syndrome

	Major criteria	Minor criteria	Inclusion rule
Blake[#][9]	<ol style="list-style-type: none"> 1. Coloboma, microphthalmia 2. Choanal atresia or stenosis* 3. Characteristic external ear anomaly, middle/inner ear malformations, mixed deafness 4. Cranial nerve dysfunction 	<ol style="list-style-type: none"> 1. Cardiovascular malformations 2. Tracheo-oesophageal defects 3. Genital hypoplasia or delayed pubertal development 4. Cleft lip and/or palate 5. Developmental delay 6. Growth retardation 7. Characteristic face 	<p>Typical CHARGE: 4 major <i>or</i> 3 major + 3 minor</p>
Verloes[10]	<ol style="list-style-type: none"> 1. Ocular coloboma 2. Choanal atresia 3. Hypoplastic semicircular canals 	<ol style="list-style-type: none"> 1. Heart or oesophagus malformation 2. Malformation of the middle or external ear 3. Rhombencephalic dysfunction including sensorineural deafness 4. Hypothalamo-hypophyseal dysfunction (gonadotropin or growth hormone deficiency) 5. Mental retardation 	<p>Typical CHARGE: 3 major <i>or</i> 2 major + 2 minor</p> <p>Partial CHARGE: 2 major + 1 minor</p> <p>Atypical CHARGE: 2 major + 0 minor <i>or</i> 1 major + 3 minor</p>

Updated by a consortium in 2006 and 2009.[11]

* Cleft palate can be substituted for choanal atresia, since these anomalies rarely occur together.[12]

The Blake criteria[9] were slightly adjusted by a consortium and last updated in 2009.[11] These criteria encompass four major and seven minor criteria. The four major criteria are coloboma, choanal atresia, cranial nerve dysfunction and abnormalities of the inner, middle, or external ear. At least four major, or three major and three minor, criteria must be present in order to diagnose CHARGE syndrome. In 2005, Verloes proposed renewed criteria.[10] He included semicircular canal defects as a major criterion, as these defects were shown to be a very specific and consistent feature in CHARGE syndrome.[13] Verloes also anticipated broadening of the phenotypic spectrum and reduced the number of features necessary for CHARGE diagnosis (to only three major, or two major and two minor, criteria) and he made his criteria less age- and sex-dependent. A common feature of both sets of criteria is that either coloboma or choanal atresia (which can sometimes be replaced by cleft palate, Table 1[12]) must be present in order to diagnose CHARGE syndrome.

Molecular diagnosis

Nowadays, CHARGE syndrome can also be diagnosed by a molecular genetic test. The *CHD7* gene, mutated in the majority of patients with CHARGE syndrome, consists of 37 coding exons and one non-coding exon.[6] The gene encodes for a 2997 amino-acid-long protein that belongs to the Chromodomain Helicase DNA binding (CHD) family.[14] CHD7 can form complexes with different proteins thereby ensuring specific binding to different enhancer regions leading to time- and tissue-specific regulation of gene expression.[15] One example is the association of CHD7 with BPAF (polybromo- and

BRG1-associated factor containing complex) that is essential for neural crest gene expression and cell migration.[16] This is in line with previous assumptions that many of the congenital defects seen in CHARGE syndrome may be neural crest related.[17] CHD7 was also shown to associate with rDNA and was therefore suggested to play a role as positive regulator of rRNA synthesis.[18]

Haploinsufficiency of the *CHD7* gene leads to CHARGE syndrome and, as expected, most patients are found to have truncating *CHD7* mutations.[19-24] Missense mutations occur in a minority of patients and partial or full deletions of the *CHD7* gene are rare events.[6, 19, 23, 25-31] Most *CHD7* mutations occur *de novo*. There are no mutational hotspots and recurrent mutations are rare.[20] No clear genotype-phenotype correlation exists, although it seems that missense mutations in general are associated with a milder phenotype.[20]

CHD7 analysis detects mutations in more than 90% of patients fulfilling the clinical criteria for CHARGE syndrome. The lack of mutation detection in the remaining 5–10% of patients suggests genetic heterogeneity. The *SEMA3E* gene was proposed as a candidate gene, but it seems to play a minor role as only two *SEMA3E* alterations have been described in patients with CHARGE syndrome.[32] Besides genetic heterogeneity, it is also possible that mutations in intronic regions, 5' or 3' untranslated regions, or in regulatory elements of *CHD7* underlie the *CHD7*-negative cases. Phenocopies of CHARGE or CHARGE-like syndrome can be due to teratogen exposure (e.g., thalidomide, retinoic acid and maternal diabetes) or chromosomal aberrations.[8]

PHENOTYPIC SPECTRUM OF PATIENTS WITH A MUTATION IN THE *CHD7* GENE

Phenotypic spectrum in our *CHD7*-positive cohort compared to two other cohorts

Our *CHD7*-positive cohort consists of patients who had *CHD7* analysis done in Nijmegen, the Netherlands. In Nijmegen, *CHD7* analysis was performed in 863 patients

suspected of CHARGE syndrome and 360 *CHD7* mutations were found (360/863 = 42%). The mutations were scattered throughout the entire coding region and splice sites of the *CHD7* gene. One third of the mutations were found in exon 2, 3, 30 and 31 (34% of mutations, 33% of genomic size). However, exons 8, 12, 26, 30 and 36 showed a remarkably high number of mutations relative to their genomic size (19% of mutations, 9% genomic size). No mutations were found in exon 6, 7, 20 and 28, but these exons comprise only 3% of the coding genome of *CHD7*. Apart from the high number of mutations in exon 2 (the largest exon), this is not in accordance with a previous report (n=91).[33] Most mutations were nonsense (38%) or frameshift mutations (32%). Missense mutations and splice site mutations occurred in 13% and 17%, respectively and deletions were rarely present (<1%). The phenotypic spectrum of the missense mutations was more variable and on average milder when compared to the truncating mutations.

In Table 2 we present an overview of the clinical features of 280 of our *CHD7*-positive patients, the *CHD7*-positive cohort reported in the literature (reviewed by Zentner n=254[24]) and a cohort of patients clinically diagnosed with CHARGE syndrome, but of whom the *CHD7* status is unknown (n=124[7, 34]). We only included 280 of our 360 *CHD7*-positive patients, because clinical data were lacking in the other 80 patients. The phenotypes of 64 of the 280 patients have been published previously (Table 2).[20, 26, 35-40]

Table 2 Clinical features of patients with a *CHD7* mutation compared to clinically diagnosed patients with CHARGE syndrome

Feature	Our <i>CHD7</i>-positive cohort (n=280)	<i>CHD7</i>-positive cohort from the	CHARGE patients before <i>CHD7</i>
----------------	--	---	---

		literature (n=254) [#]	discovery (n=124) [†]
External ear anomaly	224/231 [^] 97% (80-98%) [†]	214/235 91%	74/77 96%
Cranial nerve dysfunction (VII, VIII and others)	173/174 99% (62-100%)	?	107/124 86%
Semicircular canal anomaly	110/117 94% (39-98%)	94/96 98%	12/12 100%
Coloboma	189/234 81% (68-84%)	190/253 75%	96/124 77%
Choanal atresia	99/179 55% (35-71%)	95/247 38%	76/124 61%
Cleft lip and/or palate	79/163 48% (28-70%)	79/242 33%	22/124 18% [«]
Feeding difficulties necessitating tube feeding	90/110 82% (32-93%)	?	40/47 85%
Facial palsy	80/121 66% (29-85%)	72/187 39%	17/47 36%
Anosmia on formal smell testing	24/30 80%	?	?
Genital hypoplasia	118/145 81% (42-90%)	116/187 62%	45/124 36% [«]
Congenital heart defect	191/252	193/250	105/124

	76% (68-78%)	77%	85% [⊘]
Tracheo-oesophageal anomaly	42/146 29% (15-63%)	35/185 19%	22/124 18%
Developmental delay	Delayed motor milestones 147/149 99% (53-99%) Intellectual disability 108/134 74% (39-91%)	Developmental delay 107/141 76%	Developmental delay 47/47 100%
Growth retardation	35/94 37% (13-79%)	101/141 72%	80/124 65%

[#] *CHD7*-positive cohort from the literature as reviewed by Zentner 2010.[24] This cohort partially overlaps with our *CHD7*-positive cohort because the phenotypes of 64 of our patients were published previously.[20, 26, 35-40]

* Cohort of patients with clinically diagnosed CHARGE syndrome reported by Tellier in 1998 and Issekutz in 2005, before *CHD7* analysis was possible.[7, 34]

[^] Frequencies are represented as the number of patients with a particular feature / the total number of patients that were tested for that particular feature

[†] The range of percentages presented between brackets was calculated as: (positive / total) x 100% - (positive + unknown / total) x 100% (for further explanation see text)

[⊘] Outside the frequency range of patients with a *CHD7* mutation

The clinical features of the *CHD7*-positive patients, previously reported or presented here, are rarely completely known. When calculating the percentage of

patients who exhibit a certain feature, the incompleteness of the clinical data will have a major effect on the accuracy of the percentage. In order to compensate for this inaccuracy, we also calculated the frequency range. The minimum frequency is defined as the number of patients with a particular feature divided by the total number of patients in the cohort. The maximum frequency is defined as the number of patients with a particular feature plus patients for whom it is unknown whether they have the feature, divided by the total number of patients in the cohort.

Four features are almost always present in patients with a *CHD7* mutation: external ear anomalies, cranial nerve dysfunction, semicircular canal hypoplasia, and delayed attainment of motor milestones (Table 2). The characteristic external ear anomaly consists of triangular conchae or cup-shaped ears (Figure 1) and occurs in more than 90% of patients with a *CHD7* mutation. The second feature, cranial nerve dysfunction, is present in more than 95% of patients. The seventh and eighth cranial nerves are most often affected leading to facial palsy and sensorineural hearing loss, respectively. Dysfunction of other cranial nerves can also occur. The third feature, semicircular canal hypoplasia, is not always assessed, but when investigated it is found to be present in over 90% of patients. The high frequency of semicircular canal hypoplasia is reflected in the delayed attainment of motor milestones (often scored as developmental delay in previous papers), that is almost universally present in patients with CHARGE syndrome. A delay in speech development is also common in these patients who suffer from multiple sensory impairment (e.g. blindness and/or deafness).[41, 42] In our cohort, approximately 75% of patients had intellectual disability, indicating that one quarter had a normal intelligence.

Two features seem to occur more frequently since *CHD7* analysis has become available as a diagnostic tool in CHARGE syndrome (Table 2). These are cleft lip and/or palate and genital hypoplasia; in the study by Tellier[34], the percentages of these two

features were below our frequency range. The most likely explanation is that in the past, patients with cleft palate, and thus often without choanal atresia were not recognised as having CHARGE syndrome. Mutation analysis enables a diagnosis in these clinically less typical patients. The higher prevalence of genital hypoplasia in patients with a *CHD7* mutation can be explained by a higher mean age in the patients for whom molecular studies have been performed, but it may also be due to an increased awareness that genital hypoplasia is a frequent feature in patients with a *CHD7* mutation.

One feature seems to occur less frequently since *CHD7* analysis became available: congenital heart defects were present in 76% of *CHD7*-positive patients and in 85% of patients with a clinical diagnosis of CHARGE syndrome. The most likely explanation is that the clinical diagnosis was more readily made in hospitalised children with a heart defect and that, like children with cleft palate, children without a heart defect were more likely to remain unrecognised as having CHARGE syndrome prior to *CHD7* analysis.

Exploration of the mild end of the phenotypic spectrum of *CHD7* mutations

Patients with a typical presentation of CHARGE syndrome are easily clinically recognised, but those who are mildly affected can be missed, as the mild end of the CHARGE spectrum is only recently starting to emerge. Several studies have shown that an increasing number of patients with a *CHD7* mutation do not fulfil the clinical criteria, as they do not have coloboma or choanal atresia or cleft palate.[20] Exploration of the mild end of the CHARGE spectrum can be undertaken in four ways: by studying familial CHARGE syndrome, by evaluating very mildly affected patients who are picked up with *CHD7* analysis, by performing *CHD7* analysis in cohorts of patients with only one

CHARGE feature, and finally by studying syndromes that show clinical overlap with CHARGE syndrome (e.g., 22q11 deletion syndrome and Kallmann syndrome).

Familial CHARGE syndrome

Very mildly affected patients with CHARGE syndrome can be identified by studying familial CHARGE syndrome. In the literature, only 16 families have been described with recurrence of molecularly confirmed CHARGE syndrome.[20, 21, 23, 37, 43-45] These families include seven sib-pairs, three monozygotic twin-pairs, and six two-generation families. In this review, we describe another two-generation family from our *CHD7*-positive cohort, making a total of 17 families (Table 3).

Table 3 Familial CHARGE syndrome

Reference	Fulfilling clinical criteria			Segregation	
	Sib-pairs	<i>CHD7</i> mutation	Sib 1		Sib 2
1. Wincent 2008[23]		c.4015C>T; p.R1339X	+ (case 11a)	+ (case 11b)	Father no mutation
2. Pauli 2009[44]		c.7302dupA	+ (girl)	+ (boy)	Germline mosaicism in father
3. Lalani 2006[21]		p.W2332X	+ (died)	- (case CHA76)	Parents no mutation
4. Jongmans		c.2442+5G>C	- (case 1)	+ (case 2)	Mother no

2008[37]					mutation
5. Jongmans	c.2520G>A;	+ (case 3)	+ (case 4)		Somatic
2008[37]	p.W840X				mosaicism in father
6. Jongmans	c.1610G>A;	+ (case 5)	+ (case 6)		Parents no
2008[37]	p.W537X				mutation
7. Jongmans	c.5982G>A;	+ (case 29)	+ (case 30)		Somatic
2006[20]	p.W1994X				mosaicism in mother
Monozygotic					
twins		Twin 1	Twin 2		
1. Wincent	c.5428C>T;	+ (case 13a)	+ (case 13b)		<i>De novo</i>
2008[23]	p.R1810X				
2. Lalani	p.E1271X	+ (case A)	+ (case B)		Unknown
2006[21]					
3. Jongmans	c.5752_5753	+ (case 26)	- (case 27)		Parents were
2006[20]	dupA; p.T1918fs				not tested
Parent -					
child		Child 1	Child 2	Parent	
1. Vuorela	c.4795C>T;	+ (case 1)	+ (case 2)	- (case 3)	<i>De novo</i> in
2008[45]	p.Q1599X				father*

2. Delahaye 2007[43]	c.2501C>T; p.S834F	+ (case A III-2)	+ (case A III-3)	- (case A II-2)	<i>De novo</i> in mother
3. Delahaye 2007[43]	c.469>T; p.R157X	+ (B III-1)	+ (B III-3)	- (B II-2)	<i>De novo</i> in father
4. Lalani 2006[21]	p.R2319S	- (case CHA166)		-	Unknown
5. Jongmans 2008[37]	c.6322G>A; p.G2108R	- (case 7)		- (case 8)	<i>De novo</i> in mother*
6. Jongmans 2008[37]	c.6322G>A; p.G2108R	- (case 9)	+ (case 10)	- (case 11)	<i>De novo</i> in mother
7. This study	c.7769del	-	-	-	Unknown
Total clinical criteria positive		Children 24/32		Parents 0/7	

* Somatic mosaicism was excluded (the *CHD7* mutation was present in both peripheral blood lymphocytes and buccal cells).

+, fulfilling the criteria, -, not fulfilling the clinical criteria of Blake and/or Verloes.[9, 10]

Of the 39 *CHD7*-positive individuals, only 24 (62%) fulfilled the clinical criteria for CHARGE syndrome as defined by either Blake or Verloes.[9, 10] Atypical CHARGE patients are most frequently seen in the two-generation families. Often, the mildly affected individuals were recognised only after a *CHD7* mutation was found in a more severely affected family member. The most mildly affected patients described in the literature had dysmorphic ears and balance disturbance as the only manifestations of CHARGE syndrome. Somatic mosaicism was considered unlikely in two of the very mildly affected parents, because the *CHD7* mutation was found in different tissues.[37,

45] The monozygotic twin-pairs showed strikingly discordant features and underscore the great intra-familial variability seen in CHARGE syndrome.[20, 21, 23] This variability might be explained by differential epigenetic regulation or fluctuating embryonic *CHD7* levels in relation to a time- and tissue-dependent critical threshold during embryonic development.

Mildly affected patients from our *CHD7*-positive cohort

The most widely used criteria are those of Blake/Lalani.[9, 10] Interestingly, 18 out of the 131 (14%) *CHD7*-positive patients that could be scored for these criteria had only one or two major Blake features and thus could not be clinically diagnosed as having CHARGE syndrome. Based on the presence of none, or only one major Verloes feature, as many as 17% (22/124 patients) could not be clinically diagnosed with CHARGE syndrome using the Verloes criteria. The phenotypes of the three most mildly affected (previously unpublished) patients are presented below.

The first patient had abnormal external ears and a congenital heart defect but no other features of CHARGE syndrome. She had normal semicircular canals, no cranial nerve dysfunction and a normal pubertal development. She had a *de novo* pathogenic missense mutation in the *CHD7* gene that had not been described before (c.4406A>G, p.Tyr1469Cys in exon 19).

The second patient had mild semicircular canal anomalies and a mild hearing loss. His external ears were normal. He was only recognised as having CHARGE syndrome after a *CHD7* splice site mutation was found in his more severely affected children (Table 3, two-generation family from this study).

The third patient was diagnosed with Kallmann syndrome and had sensorineural hearing loss. After a *de novo* pathogenic missense mutation in the *CHD7* gene (c.6322G>A, p.Gly2108Arg in exon 31) was identified, a CT scan of his temporal bone

was re-evaluated and semicircular canal hypoplasia was seen. He had normal external ears.

***CHD7* analysis in cohorts of patients with only one CHARGE feature**

Some authors have undertaken *CHD7* screening in patients with only one CHARGE syndrome feature, e.g., cleft lip and/or palate,[46] congenital heart disease,[47] or scoliosis.[48] These studies did not identify pathogenic *CHD7* mutations. The general impression is that in the absence of other CHARGE features, the chance of finding a *CHD7* mutation is very low.

Studies in syndromes that overlap with CHARGE syndrome

Thus far, two clinically overlapping syndromes have been studied in relation to *CHD7* mutations: velocardiofacial syndrome (VCFS) and Kallmann syndrome.

Velocardiofacial or 22q11 deletion syndrome, shares many features with CHARGE syndrome, including congenital heart defects, cleft palate, developmental delay, renal anomalies, growth retardation, ear anomalies, hearing loss, hypoglycaemia and lymphopenia.[49] Especially thymus aplasia and hypoparathyroidism are increasingly recognised in CHARGE syndrome and mark the clinical overlap with the DiGeorge phenotype of 22q11 deletions.[50, 51] In approximately 85% of VCFS patients, a common 3 Mb heterozygous deletion of 22q11.2 is present, resulting in *TBX1* haploinsufficiency. Mutations in the *TBX1* gene are present in a minority of VCFS patients. Array CGH in a cohort of VCFS patients without 22q11 deletion or *TBX1* mutation revealed one heterozygous deletion encompassing the *CHD7* gene in a patient with features typical of VCFS.[52] This patient had a learning difficulty with speech delay, severe feeding difficulties, a congenital heart defect (interruption of the aortic arch, coarctation of the aorta, bicuspid aortic valve, ventricular and atrial septal defect), long

slender fingers and low-set, over-folded ear helices. The patient did not have coloboma, choanal atresia or cleft palate, but did have typical CHARGE ears with triangular conchae. To our knowledge, *CHD7* sequence analysis has not yet been performed in a cohort of VCFS patients without deletion or mutation of *TBX1*. In Figure 2 we illustrate how difficult it can be to distinguish between CHARGE syndrome and 22q11 deletion syndrome. The phenotypic similarity between VCFS and CHARGE syndrome is also apparent in mice with haploinsufficiency of *Tbx1* and *Chd7*.^[52] Both genes are required in pharyngeal ectoderm for fourth pharyngeal artery development. In addition, both genes are important in development of the thymus and semicircular canals. The *Tbx1* and *Chd7* gene were shown to interact in mice, but a direct regulatory effect of *Chd7* on *Tbx1* expression could not be demonstrated.^[52]

Kallmann syndrome usually presents as the combination of hypogonadotropic hypogonadism (HH) and anosmia. Both features also occur in the majority of patients with CHARGE syndrome.^[53-56] Other features that can be present in both syndromes are hearing loss, cleft lip/palate and renal malformations. Two studies have been performed in which patients with normosmic HH or Kallmann syndrome were screened for *CHD7* mutations. *CHD7* mutations were reported in seven out of 197 patients with normosmic HH or Kallmann syndrome,^[57] in three out of 36 patients with Kallmann syndrome (confirmed by a smell test), but in none of 20 patients with normosmic HH.^[58] The second study showed that after thorough clinical examination of the *CHD7*-positive Kallmann patients, other CHARGE features were universally present. The authors concluded that these patients represent the mild end of the CHARGE phenotypic spectrum, as we also demonstrated in our patient who was referred with Kallmann syndrome (see the section “Mildly affected patients from our own *CHD7* positive cohort”).

CHD7 AND CHARGE SYNDROME: THE CLINICAL IMPLICATIONS

Based on the studies conducted after the identification of *CHD7* and summarised above, we discuss whether CHARGE syndrome is a clinical or molecular diagnosis, propose a new guideline for *CHD7* analysis, and give recommendations for clinical surveillance of *CHD7*-positive patients.

CHARGE syndrome, a clinical or molecular diagnosis?

In our opinion, CHARGE syndrome is primarily a clinical diagnosis. If patients fulfil the clinical criteria of Blake or Verloes and chromosomal aberrations and teratogenic exposure effects fully explaining the clinical features have been ruled out, then they have CHARGE syndrome, irrespective of the results of *CHD7* analysis. On the other hand, patients who do not completely fulfil the clinical criteria should not be excluded from *CHD7* analysis. If a mutation is found in these patients, clinical follow-up and genetic counselling should be performed as in clinically diagnosed patients with CHARGE syndrome.

Guideline for *CHD7* analysis

Considering the broad phenotypic spectrum, it is evident that *CHD7* analysis should not be restricted to patients fulfilling the clinical criteria for CHARGE syndrome. Coloboma and choanal atresia (or cleft palate) are not always present in CHARGE syndrome. Therefore patients with other CHARGE features, but without those cardinal features, should not be excluded from *CHD7* analysis. When a patient is suspected of CHARGE syndrome, the external ears, cranial nerve function and semicircular canals should be thoroughly examined, as these features occur in the great majority of patients with a *CHD7* mutation (Table 2).

We propose a guideline for *CHD7* analysis in Figure 3. In our experience, imaging of the semicircular canals is not an easy routine in daily clinical practice, especially in children in whom sedation can be complicated (see clinical surveillance and Table 4). Therefore, in our guideline we have indicated when imaging of the semicircular canals is needed to support the decision for *CHD7* analysis. We based our guideline on the clinical features that were present in our *CHD7*-positive patients (n=280). When applying our guideline, *CHD7* analysis would not have been recommended in one of our patients. This patient is the first patient described in “Mildly affected patients from our own *CHD7* positive cohort” and is extremely mildly affected. A prospective study is needed to evaluate the usefulness of this guideline in clinical practice.

Clinical surveillance of patients with a *CHD7* mutation or typical CHARGE syndrome

Ideally, follow-up of patients with a *CHD7* mutation or typical CHARGE syndrome should be done by an expert multidisciplinary team, because this approach will ensure optimal treatment of this very complex patient group. In the Netherlands, several specialities are involved in the CHARGE outpatient clinic of the University Medical Centre Groningen: clinical genetics, paediatric endocrinology, ENT, speech and occupational therapy, ophthalmology, child and youth psychiatry, social paediatrics, gynaecology, endocrinology, paediatric cardiology, neuroradiology and dentistry. In Table 4, we show updated recommendations for clinical surveillance of patients with a *CHD7* mutation based on the experiences of our CHARGE outpatient clinic, on the clinical features in our *CHD7*-positive cohort (Table 2), and on a literature review.

Table 4 Clinical surveillance of patients with a *CHD7* mutation

Evaluation	Tests	Treatment / advice	Be aware of
Ophthalmology	Full ophthalmological examination including fundoscopy	Tinted spectacles for photophobia (iris coloboma) Artificial tears in case of facial palsy Correction of refraction errors	Retinal detachment (in case of retinal coloboma)
ENT, audiology, occupational/ speech therapy, gastroenterology	Multidisciplinary evaluation: Assess patency of choanae (CT scan or nasal endoscopy) Evaluation for cleft palate and tracheo-oesophageal anomalies Audiometry (BAER), tympanometry Temporal bone CT scan (pathology of middle ear, inner ear, cranial nerves, semicircular canals, aberrant course of blood vessels or cranial	Surgical correction of choanal atresia Hearing aids, ventilation tubes Sign language and speech training GERD: Nissen fundoplication, antispasmodics Gastrostomy / tracheotomy in case of severe swallowing	Respiratory aspiration (recurrent pneumonias) Aberrant course of blood vessels or cranial nerves when surgery for cochlear implants Obstructive sleep apnoea

	nerves)	problems
	Cranial nerve function tests	Surgery of tracheo-oesophageal
	Swallowing studies, pH monitoring, reflux scan in	abnormalities
	case of feeding/swallowing difficulties	Advice concerning anosmia
	University of Pennsylvania Smell Identification	
	Test	

Paediatrics/ endocrinology	Renal ultrasound, voiding cysto-urethrogram in	Early treatment of bladder
	case of urinary infections	infections (especially in case of
	Immunological studies in case of recurrent	unilateral renal agenesis or
	infections or suspected hypocalcaemia	vesico-urethral reflux)
	Follow up of growth and development (growth	Growth hormone treatment if
	hormone stimulation test if indicated)	growth hormone deficiency is
	Monitor cryptorchidism	present
	Gonadotropin levels (age 6-8 weeks) and follow	Orchidopexy when indicated
	up of pubertal development	Gonadotropin treatment in case
	DEXA scan (when suspected for osteoporosis)	of hypogonadotropic

	Monitor for scoliosis	hypogonadism Corset or surgery when severe progressive scoliosis is present	
Cardiology	Cardiac evaluation including ultrasound	Cardiac surgery and/or antibiotic prophylaxis	
Anaesthesiology	Extensive preoperative assessment	Combine surgical procedures whenever possible Longer surveillance after surgery	Postoperative complications (due to aspiration/cranial nerve dysfunction) Problems with intubation
Neurology	Cerebral MRI scan (including visualisation of olfactory bulbs, and inner ear if no temporal bone CT scan has been performed) EEG (only when clinically seizures are observed)	Anticonvulsants if overt epilepsy seen	

Behaviour, developmental and educational services	Extensive multidisciplinary evaluation of developmental and sensory impairments and behavioural problems Use formal tests in order to screen for autism spectrum, obsessive compulsive disorders and ADHD Perform IQ tests regularly	Integrated individualised therapy with special attention for optimising communication
Physiotherapy	Assessment of balance problems, motor delay, visiospatial coordination and hypotonia	Therapy for hypotonia and devices to overcome balance impairment
Genetics	<i>CHD7</i> analysis (when no <i>CHD7</i> mutation or deletion is found, perform array CGH)	Genetic counselling, options for prenatal diagnosis Intra-familial variability in CHARGE syndrome

ADHD, attention deficit hyperactivity disorder; BAER, brain stem auditory evoked response; array CGH, array comparative genomic hybridisation; ENT, ear nose throat; GERD, gastro-oesophageal reflux disease

An ultrasound of the heart and kidneys should be done in all patients, because mild congenital anomalies can remain undetected until adulthood, but may have therapeutic consequences (e.g. early treatment of urinary tract infections in case of renal anomalies).

Cranial nerve investigation is important. Dysfunction of the seventh, ninth and tenth cranial nerve can lead to severe feeding and swallowing problems, can result in respiratory aspiration and post-operative complications, and might be involved in sudden death.[59-62]

Hypogonadotropic hypogonadism (HH) should be diagnosed at an early stage, because patients are at risk for osteoporosis if hormone replacement therapy is not started in time. We recently demonstrated that anosmia and HH are 100% correlated in CHARGE syndrome and we proposed smell testing as a predictive test for HH.[63]

Last, but not least, an individualised educational program is needed in order to fully stimulate the intellectual potential of a child with CHARGE syndrome and to manage behavioural problems.[64-68] Clinicians should be aware that semicircular canal hypoplasia, a very frequent feature in CHARGE syndrome, causes balance problems and therefore a delay in motor development. This motor retardation may erroneously lead to the suspicion of intellectual disability, although approximately 25% of patients have a normal intelligence.

In addition, identifying a *CHD7* mutation gives further tools for genetic counselling of both the parents and the patients themselves. When the *CHD7* mutation has occurred *de novo* in the index patient, the recurrence risk for the parents is 2–3% because both germline and somatic mosaicism have been described in CHARGE syndrome.[20, 37, 45] Patients themselves, when fertile with or without appropriate hormone replacement therapy, have a 50% chance of transmitting the *CHD7* mutation to their offspring. The

severity of CHARGE syndrome in offspring can not be predicted, because intra-familial variability is large. Prenatal diagnosis, either by molecular analysis or ultrasound, and pre-implantation genetic diagnosis, when appropriate, should be discussed with parents and patients.

CONCLUSIONS

CHARGE syndrome is extremely variable, an observation that has been strongly underscored since the discovery of the *CHD7* gene. The phenotype cannot be predicted from the genotype, as exemplified by intra-familial variability. CHARGE syndrome remains primarily a clinical diagnosis, but molecular testing can confirm the diagnosis in mildly affected patients. Guidelines for *CHD7* analysis in individuals suspected of having CHARGE syndrome are proposed in Figure 3. In addition, updated guidelines for the surveillance of patients with a *CHD7* mutation or typical CHARGE syndrome are presented in Table 4.

Acknowledgements: We are indebted to the patients for cooperating in this study. We thank the Netherlands Organisation for Health Research (ZonMW 92003460 to JEHB) for financial support and thank Jackie Senior for editing the manuscript.

Competing interests: None declared.

Exclusive licence statement: The Corresponding Author has the right to grant on behalf of all authors and does grant on behalf of all authors, an exclusive licence (or non-exclusive for government employees) on a worldwide basis to the BMJ Publishing Group Ltd and its Licensees to permit this article (if accepted) to be published in Journal of Medical Genetics and any other BMJ PGL products to exploit all subsidiary rights, as

set out in our licence (<http://group.bmj.com/products/journals/instructions-for-authors/licence-forms>).

Ethics committee approval: not necessary. Clinical information was collected with informed consent and subsequently used strictly anonymously according to local ethical regulations, except for some individual patients who might be identifiable in the paper, but who all gave their consent.

REFERENCES

1. Angelman H. Syndrome of coloboma with multiple congenital abnormalities in infancy. *Br Med J* 1961;**1**:1212-4.
2. Edwards JH, Finlay HVL, Young RB. Coloboma with Multiple Congenital Anomalies. *Br Med J* 1961;**2**:586-7.
3. Hall BD. Choanal atresia and associated multiple anomalies. *J Pediatr* 1979;**95**:395-8.
4. Hittner HM, Hirsch NJ, Kreh GM, Rudolph AJ. Colobomatous microphthalmia, heart disease, hearing loss, and mental retardation--a syndrome. *J Pediatr Ophthalmol Strabismus* 1979;**16**:122-8.
5. Pagon RA, Graham JM, Jr., Zonana J, Yong SL. Coloboma, congenital heart disease, and choanal atresia with multiple anomalies: CHARGE association. *J Pediatr* 1981;**99**:223-7.
6. Vissers LE, van Ravenswaaij CM, Admiraal R, Hurst JA, De Vries BB, Janssen IM, van der Vliet WA, Huys EH, de Jong PJ, Hamel BC, Schoenmakers EF, Brunner HG, Veltman JA, van Kessel AG. Mutations in a new member of the chromodomain gene family cause CHARGE syndrome. *Nat Genet* 2004;**36**:955-7.
7. Issekutz KA, Graham JM, Jr., Prasad C, Smith IM, Blake KD. An epidemiological analysis of CHARGE syndrome: preliminary results from a Canadian study. *Am J Med Genet A* 2005;**133**:309-17.

8. Sanlaville D, Verloes A. CHARGE syndrome: an update. *Eur J Hum Genet* 2007;**15**:389-99.
9. Blake KD, Davenport SL, Hall BD, Hefner MA, Pagon RA, Williams MS, Lin AE, Graham JM, Jr. CHARGE association: an update and review for the primary pediatrician. *Clin Pediatr (Phila)* 1998;**37**:159-73.
10. Verloes A. Updated diagnostic criteria for CHARGE syndrome: a proposal. *Am J Med Genet A* 2005;**133**:306-8.
11. Lalani SR, Hefner MA, Belmont JW, Davenport SLH. CHARGE Syndrome. GeneReviews 2009; Internet Communication
<http://www.ncbi.nlm.nih.gov/bookshelf/br.fcgi?book=gene&part=charge> (accessed November 2010)
12. Blake KD, Prasad C. CHARGE syndrome. *Orphanet J Rare Dis* 2006;**1**:34.
13. Admiraal RJ, Joosten FB, Huygen PL. Temporal bone CT findings in the CHARGE association. *Int J Pediatr Otorhinolaryngol* 1998;**45**:151-62.
14. Woodage T, Basrai MA, Baxevanis AD, Hieter P, Collins FS. Characterization of the CHD family of proteins. *Proc Natl Acad Sci USA* 1997;**94**:11472-7.
15. Layman WS, Hurd EA, Martin DM. Chromodomain proteins in development: lessons from CHARGE syndrome. *Clin Genet* 2010;**78**:11-20.

16. Bajpai R, Chen DA, Rada-Iglesias A, Zhang J, Xiong Y, Helms J, Chang CP, Zhao Y, Swigut T, Wysocka J. CHD7 cooperates with PBAF to control multipotent neural crest formation. *Nature* 2010;**463**:958-62.
17. Siebert JR, Graham JM, Jr., MacDonald C. Pathologic features of the CHARGE association: support for involvement of the neural crest. *Teratology* 1985;**31**:331-6.
18. Zentner GE, Hurd EA, Schnetz MP, Handoko L, Wang C, Wang Z, Wei C, Tesar PJ, Hatzoglou M, Martin DM, Scacheri PC. CHD7 functions in the nucleolus as a positive regulator of ribosomal RNA biogenesis. *Hum Mol Genet* 2010;**19**:3491-501.
19. Aramaki M, Udaka T, Kosaki R, Makita Y, Okamoto N, Yoshihashi H, Oki H, Nanao K, Moriyama N, Oku S, Hasegawa T, Takahashi T, Fukushima Y, Kawame H, Kosaki K. Phenotypic spectrum of CHARGE syndrome with CHD7 mutations. *J Pediatr* 2006;**148**:410-4.
20. Jongmans MC, Admiraal RJ, van der Donk KP, Vissers LE, Baas AF, Kapusta L, van Hagen JM, Donnai D, de Ravel TJ, Veltman JA, Geurts van Kessel A, De Vries BB, Brunner HG, Hoefsloot LH, van Ravenswaaij CM. CHARGE syndrome: the phenotypic spectrum of mutations in the CHD7 gene. *J Med Genet* 2006;**43**:306-14.
21. Lalani SR, Safiullah AM, Fernbach SD, Harutyunyan KG, Thaller C, Peterson LE, McPherson JD, Gibbs RA, White LD, Hefner M, Davenport SL, Graham JM, Bacino CA, Glass NL, Towbin JA, Craigen WJ, Neish SR, Lin AE, Belmont JW. Spectrum

of CHD7 mutations in 110 individuals with CHARGE syndrome and genotype-phenotype correlation. *Am J Hum Genet* 2006;**78**:303-14.

22. Lee YW, Kim SC, Shin YL, Kim JW, Hong HS, Lee YK, Ki CS. Clinical and genetic analysis of the CHD7 gene in Korean patients with CHARGE syndrome. *Clin Genet* 2009;**75**:290-3.
23. Wincent J, Holmberg E, Stromland K, Soller M, Mirzaei L, Djureinovic T, Robinson KL, Anderlid BM, Schoumans J. CHD7 mutation spectrum in 28 Swedish patients diagnosed with CHARGE syndrome. *Clin Genet* 2008;**74**:31-8.
24. Zentner GE, Layman WS, Martin DM, Scacheri PC. Molecular and phenotypic aspects of CHD7 mutation in CHARGE syndrome. *Am J Med Genet A* 2010;**152A**:674-86.
25. Arrington CB, Cowley BC, Nightingale DR, Zhou H, Brothman AR, Viskochil DH. Interstitial deletion 8q11.2-q13 with congenital anomalies of CHARGE association. *Am J Med Genet A* 2005;**133**:326-30.
26. Bergman JE, de Wijs I, Jongmans MC, Admiraal RJ, Hoefsloot LH, Ravenswaaij-Arts CM. Exon copy number alterations of the CHD7 gene are not a major cause of CHARGE and CHARGE-like syndrome. *Eur J Med Genet* 2008;**51**:417-25.
27. Hurst JA, Meinecke P, Baraitser M. Balanced t(6;8)(6p8p;6q8q) and the CHARGE association. *J Med Genet* 1991;**28**:54-5.

28. Johnson D, Morrison N, Grant L, Turner T, Fantes J, Connor JM, Murday V. Confirmation of CHD7 as a cause of CHARGE association identified by mapping a balanced chromosome translocation in affected monozygotic twins. *J Med Genet* 2006;**43**:280-4.
29. Udaka T, Okamoto N, Aramaki M, Torii C, Kosaki R, Hosokai N, Hayakawa T, Takahata N, Takahashi T, Kosaki K. An Alu retrotransposition-mediated deletion of CHD7 in a patient with CHARGE syndrome. *Am J Med Genet A* 2007;**143**:721-6.
30. Vuorela P, Ia-Mello S, Saloranta C, Penttinen M, Poyhonen M, Huoponen K, Borozdin W, Bausch B, Botzenhart EM, Wilhelm C, Kaariainen H, Kohlhase J. Molecular analysis of the CHD7 gene in CHARGE syndrome: identification of 22 novel mutations and evidence for a low contribution of large CHD7 deletions. *Genet Med* 2007;**9**:690-4.
31. Wincent J, Schulze A, Schoumans J. Detection of CHD7 deletions by MLPA in CHARGE syndrome patients with a less typical phenotype. *Eur J Med Genet* 2009;**52**:271-2.
32. Lalani SR, Safiullah AM, Molinari LM, Fernbach SD, Martin DM, Belmont JW. SEMA3E mutation in a patient with CHARGE syndrome. *J Med Genet* 2004;**41**:e94.
33. Sanlaville D, Audollent S, Goudefroye G, Amiel J, Abadie V, Baumann C, Dollfus H, Genevieve D, Thauvin C, Marlin S, Toutain A, Cruaud C, Etchevers HC, Weissenbach J, Munnich A, Attie-Bitach T, Lyonnet S. CHARGE syndrome:

genotype-phenotype correlations and mutational hot-spots at the CHD7 locus.

Poster presented as part of the American Society of Human Genetics conference, New Orleans, Louisiana, USA, 9-13 October 2006. Abstract no.1943.

34. Tellier AL, Cormier-Daire V, Abadie V, Amiel J, Sigaudy S, Bonnet D, Lonlay-Debeney P, Morrissette-Durand MP, Hubert P, Michel JL, Jan D, Dollfus H, Baumann C, Labrune P, Lacombe D, Philip N, LeMerrer M, Briard ML, Munnich A, Lyonnet S. CHARGE syndrome: report of 47 cases and review. *Am J Med Genet* 1998;**76**:402-9.
35. Bech AP, op den Akker JO, Matthijsse PR. Isolation of the left subclavian artery from the pulmonary artery in a patient with CHARGE association. *Congenit Anom (Kyoto)* 2010;**50**:200-2.
36. Douglas AG, Lam W. Extending the phenotypic spectrum of CHARGE syndrome: a case with preaxial polydactyly. *Clin Dysmorphol* 2009;**19**:33-4.
37. Jongmans MC, Hoefsloot LH, van der Donk KP, Admiraal RJ, Magee A, van de Laar I, Hendriks Y, Verheij JB, Walpole I, Brunner HG, van Ravenswaaij CM. Familial CHARGE syndrome and the CHD7 gene: a recurrent missense mutation, intrafamilial recurrence and variability. *Am J Med Genet A* 2008;**146**:43-50.
38. Van de Laar I, Dooijes D, Hoefsloot L, Simon M, Hoogeboom J, Devriendt K. Limb anomalies in patients with CHARGE syndrome: an expansion of the phenotype. *Am J Med Genet A* 2007;**143**:2712-5.

39. Pedersen AM, Skovby F. [Molecular diagnosis of CHARGE syndrom]. *Ugeskr Laeger* 2007;**169**:402-6.
40. Writzl K, Cale CM, Pierce CM, Wilson LC, Hennekam RC. Immunological abnormalities in CHARGE syndrome. *Eur J Med Genet* 2007;**50**:338-45.
41. Goldson E, Smith AC, Stewart JM. The CHARGE association. How well can they do? *Am J Dis Child* 1986;**140**:918-21.
42. Money J, Norman BF. Pedagogical handicap associated with micropenis and other CHARGE syndrome anomalies of embryogenesis: four 46, XY cases reared as girls. *Am J Psychother* 1988;**42**:354-79.
43. Delahaye A, Sznajer Y, Lyonnet S, Elmaleh-Berges M, Delpierre I, Audollent S, Wiener-Vacher S, Mansbach AL, Amiel J, Baumann C, Bremond-Gignac D, Attie-Bitach T, Verloes A, Sanlaville D. Familial CHARGE syndrome because of CHD7 mutation: clinical intra- and interfamilial variability. *Clin Genet* 2007;**72**:112-21.
44. Pauli S, Pieper L, Haeberle J, Grzmil P, Burfeind P, Steckel M, Lenz U, Michelmann HW. Proven germline mosaicism in a father of two children with CHARGE syndrome. *Clin Genet* 2009;**75**:473-9.
45. Vuorela PE, Penttinen MT, Hietala MH, Laine JO, Huoponen KA, Kaariainen HA. A familial CHARGE syndrome with a CHD7 nonsense mutation and new clinical features. *Clin Dysmorphol* 2008;**17**:249-53.

46. Felix TM, Hanshaw BC, Mueller R, Bitoun P, Murray JC. CHD7 gene and non-syndromic cleft lip and palate. *Am J Med Genet A* 2006;**140**:2110-4.
47. Qi Q, Yi L, Yang C, Chen H, Shen L, Mo X, Hu Y, Wang Y. [Mutation analysis of the CHD7 gene in patients with congenital heart disease.]. *Zhonghua Yi Xue Yi Chuan Xue Za Zhi* 2008;**25**:637-41.
48. Gao X, Gordon D, Zhang D, Browne R, Helms C, Gillum J, Weber S, Devroy S, Swaney S, Dobbs M, Morcuende J, Sheffield V, Lovett M, Bowcock A, Herring J, Wise C. CHD7 Gene Polymorphisms Are Associated with Susceptibility to Idiopathic Scoliosis. *Am J Hum Genet* 2007;**80**:957-65.
49. Jyonouchi S, McDonald-McGinn DM, Bale S, Zackai EH, Sullivan KE. CHARGE (coloboma, heart defect, atresia choanae, retarded growth and development, genital hypoplasia, ear anomalies/deafness) syndrome and chromosome 22q11.2 deletion syndrome: a comparison of immunologic and nonimmunologic phenotypic features. *Pediatrics* 2009;**123**:e871-e877.
50. Inoue H, Takada H, Kusuda T, Goto T, Ochiai M, Kinjo T, Muneuchi J, Takahata Y, Takahashi N, Morio T, Kosaki K, Hara T. Successful cord blood transplantation for a CHARGE syndrome with CHD7 mutation showing DiGeorge sequence including hypoparathyroidism. *Eur J Pediatr* 2010;**169**:839-44.
51. Sanlaville D, Etchevers HC, Gonzales M, Martinovic J, Clement-Ziza M, Delezoide AL, Aubry MC, Pelet A, Chemouny S, Cruaud C, Audollent S, Esculpavit C, Goudefroye G, Ozilou C, Fredouille C, Joye N, Morichon-Delvallez N, Dumez Y,

Weissenbach J, Munnich A, Amiel J, Encha-Razavi F, Lyonnet S, Vekemans M, Attie-Bitach T. Phenotypic spectrum of CHARGE syndrome in fetuses with CHD7 truncating mutations correlates with expression during human development. *J Med Genet* 2006;**43**:211-7.

52. Randall V, McCue K, Roberts C, Kyriakopoulou V, Beddow S, Barrett AN, Vitelli F, Prescott K, Shaw-Smith C, Devriendt K, Bosman E, Steffes G, Steel KP, Simrick S, Basson MA, Illingworth E, Scambler PJ. Great vessel development requires biallelic expression of *Chd7* and *Tbx1* in pharyngeal ectoderm in mice. *J Clin Invest* 2009;**119**:3301-10.
53. Asakura Y, Toyota Y, Muroya K, Kurosawa K, Fujita K, Aida N, Kawame H, Kosaki K, Adachi M. Endocrine and radiological studies in patients with molecularly confirmed CHARGE syndrome. *J Clin Endocrinol Metab* 2008;**93**:920-4.
54. Blustajn J, Kirsch CF, Panigrahy A, Netchine I. Olfactory anomalies in CHARGE syndrome: imaging findings of a potential major diagnostic criterion. *Am J Neuroradiol* 2008;**29**:1266-9.
55. Chalouhi C, Faulcon P, Le Bihan C, Hertz-Pannier L, Bonfils P, Abadie V. Olfactory evaluation in children: application to the CHARGE syndrome. *Pediatrics* 2005;**116**:e81-e88.
56. Pinto G, Abadie V, Mesnage R, Blustajn J, Cabrol S, Amiel J, Hertz-Pannier L, Bertrand AM, Lyonnet S, Rappaport R, Netchine I. CHARGE syndrome includes

hypogonadotropic hypogonadism and abnormal olfactory bulb development. *J Clin Endocrinol Metab* 2005;**90**:5621-6.

57. Kim HG, Kurth I, Lan F, Meliciani I, Wenzel W, Eom SH, Kang GB, Rosenberger G, Tekin M, Ozata M, Bick DP, Sherins RJ, Walker SL, Shi Y, Gusella JF, Layman LC. Mutations in CHD7, encoding a chromatin-remodeling protein, cause idiopathic hypogonadotropic hypogonadism and Kallmann syndrome. *Am J Hum Genet* 2008;**83**:511-9.
58. Jongmans MC, Ravenswaaij-Arts CM, Pitteloud N, Ogata T, Sato N, Claahsen-van der Grinten HL, van der Donk K, Seminara S, Bergman JE, Brunner HG, Crowley WF, Jr., Hoefsloot LH. CHD7 mutations in patients initially diagnosed with Kallmann syndrome--the clinical overlap with CHARGE syndrome. *Clin Genet* 2009;**75**:65-71.
59. Bergman JE, Blake KD, Bakker MK, du Marchie Sarvaas GJ, Free RH, Ravenswaaij-Arts CM. Death in CHARGE syndrome after the neonatal period. *Clin Genet* 2010;**77**:232-40.
60. Dobbelsteyn C, Marche DM, Blake K, Rashid M. Early oral sensory experiences and feeding development in children with CHARGE syndrome: a report of five cases. *Dysphagia* 2005;**20**:89-100.
61. Dobbelsteyn C, Peacocke SD, Blake K, Crist W, Rashid M. Feeding Difficulties in Children with CHARGE Syndrome: Prevalence, Risk Factors, and Prognosis. *Dysphagia* 2008;**23**:127-35.

62. Sporik R, Dinwiddie R, Wallis C. Lung involvement in the multisystem syndrome CHARGE association. *Eur Respir J* 1997;**10**:1354-5.
63. Bergman JE, Bocca G, Hoefsloot LH, Meiners LC, Ravenswaaij-Arts CM. Anosmia Predicts Hypogonadotropic Hypogonadism in CHARGE Syndrome. *J Pediatr* 2010; *Epub ahead of print.*
64. Brown D. CHARGE syndrome "behaviors": challenges or adaptations? *Am J Med Genet A* 2005;**133**:268-72.
65. Hartshorne TS, Hefner MA, Davenport SL. Behavior in CHARGE syndrome: introduction to the special topic. *Am J Med Genet A* 2005;**133**:228-31.
66. Hartshorne TS, Grialou TL, Parker KR. Autistic-like behavior in CHARGE syndrome. *Am J Med Genet A* 2005;**133**:257-61.
67. Johansson M, Gillberg C, Rastam M. Autism spectrum conditions in individuals with Mobius sequence, CHARGE syndrome and oculo-auriculo-vertebral spectrum: Diagnostic aspects. *Res Dev Disabil* 2010;**31**:9-24.
68. Souriau J, Gimenes M, Blouin C, Benbrik I, Benbrik E, Churakowskyi A, Churakowskyi B. CHARGE syndrome: developmental and behavioral data. *Am J Med Genet A* 2005;**133**:278-81.

FIGURE LEGENDS

Figure 1 Overview of features occurring in CHARGE syndrome[#]

Major features

- Coloboma the of iris (A) and/or retina, with or without microphthalmia, often only visible by fundoscopy
- Choanal atresia (B, unilateral) or stenosis
- Characteristic ear anomaly (C): cup shaped ear with triangular conchae and small/absent ear lobes. Middle or inner ear malformations may be present as well.
- Semicircular canal hypoplasia or aplasia (D arrow, semicircular canal aplasia of the left ear on a coronal CT scan)
- Cranial nerve dysfunction: oculomotor dysfunction (III/VI), less powerful chewing (V), facial palsy (VII)(E, right-sided^{*}), hearing loss/vestibular problems (VIII), swallowing and feeding problems (IX/X)

Minor features/occasional findings

- Hypothalamo-hypophyseal dysfunction: gonadotropin deficiency (hypogonadotropic hypogonadism), growth hormone deficiency
- Other congenital anomalies: cleft lip/palate, congenital heart defects, tracheo-oesophageal anomalies, kidney anomalies, brain anomalies (including olfactory bulb hypoplasia), lacrimal duct atresia
- Developmental delay: delayed motor development and/or cognitive delay
- Characteristic face: broad forehead, square face, facial asymmetry
- Other features: behavioural problems, sleep disturbance, scoliosis, respiratory aspiration, gastro-oesophageal reflux, postoperative complications, sudden

death, obstructive sleep apnoea, enuresis nocturnal, hockey stick palmar crease, webbed neck/sloping shoulders

Rare features

Immune deficiency, limb anomalies, epilepsy, oligodontia, anal atresia

Frequencies are shown in Table 2

* Informed consent was obtained for publication of the photograph

Figure 2 Patient with typical CHARGE syndrome and a 22q11 deletion*

This 3.5 year-old girl presented with retinal and iris coloboma, unilateral choanal stenosis, abnormal semicircular canals, mixed hearing loss, pulmonary valve stenosis and simple ears. Clinically she has typical CHARGE syndrome, but neither a *CHD7* mutation nor a deletion could be detected by sequence analysis and MLPA.[26] Subsequently, array CGH was performed (Agilent 180 K custom HD-DGH microarray) and revealed a *de novo* 3 Mb 22q11.2 loss, suggestive for the typical DiGeorge/velocardiofacial syndrome deletion.

* Informed consent was obtained for publication of the photographs

Proposal for lay out of Figure 1 and 2 (the photographs were separately submitted from the legends)

Figure 1 overview of features occurring in CHARGE syndrome#

<p>Major features</p> <ul style="list-style-type: none"> • Coloboma the of iris (A) and/or retina, with or without microphthalmia, often only visible by fundoscopy • Choanal atresia (B, unilateral) or stenosis • Characteristic ear anomaly (C): cup shaped ear with triangular conchae and small/absent ear lobes. Middle or inner ear malformations may be present as well. • Semicircular canal hypoplasia or aplasia (D arrow, semicircular canal aplasia of the left ear on a coronal CT scan) • Cranial nerve dysfunction: oculomotor dysfunction (III/VI), less powerful chewing (V), facial palsy (VII)(E, right-sided), hearing loss/vestibular problems (VIII), swallowing and feeding problems (IX/X) <p>Minor features/occasional findings</p> <ul style="list-style-type: none"> • Hypothalamo-hypophyseal dysfunction: gonadotropin deficiency (hypogonadotropic hypogonadism), growth hormone deficiency • Other congenital anomalies: cleft lip/palate, congenital heart defects, tracheo-oesophageal anomalies, kidney anomalies, brain anomalies (including olfactory bulb hypoplasia), lacrimal duct atresia • Developmental delay: delayed motor development and/or cognitive delay • Characteristic face: broad forehead, square face, facial asymmetry • Other features: behavioural problems, sleep disturbance, scoliosis, respiratory aspiration, gastro-oesophageal reflux, postoperative complications, sudden death, obstructive sleep apnoea, enuresis nocturnal, hockey stick palmar crease, webbed neck/sloping shoulders <p>Rare features</p> <p>Immune deficiency, limb anomalies, epilepsy, oligodontia, anal atresia</p>	
---	--

Frequencies are shown in Table 2

Figure 2 Patient with typical CHARGE syndrome and a 22q11 deletion

<p>This 3.5 year-old girl presented with retinal and iris coloboma, unilateral choanal stenosis, abnormal semicircular canals, mixed hearing loss, pulmonary valve stenosis and simple ears. Clinically she has typical CHARGE syndrome, but neither a <i>CHD7</i> mutation nor a deletion could be detected by sequence analysis and MLPA.[25] Subsequently, array CGH was performed (Agilent 180 K custom HD-DGH microarray) and revealed a <i>de novo</i> 3 Mb 22q11.2 loss, suggestive for the typical DiGeorge/velocardiofacial syndrome deletion.</p>	
---	--

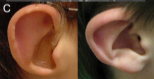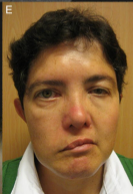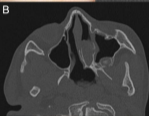
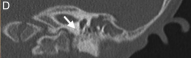
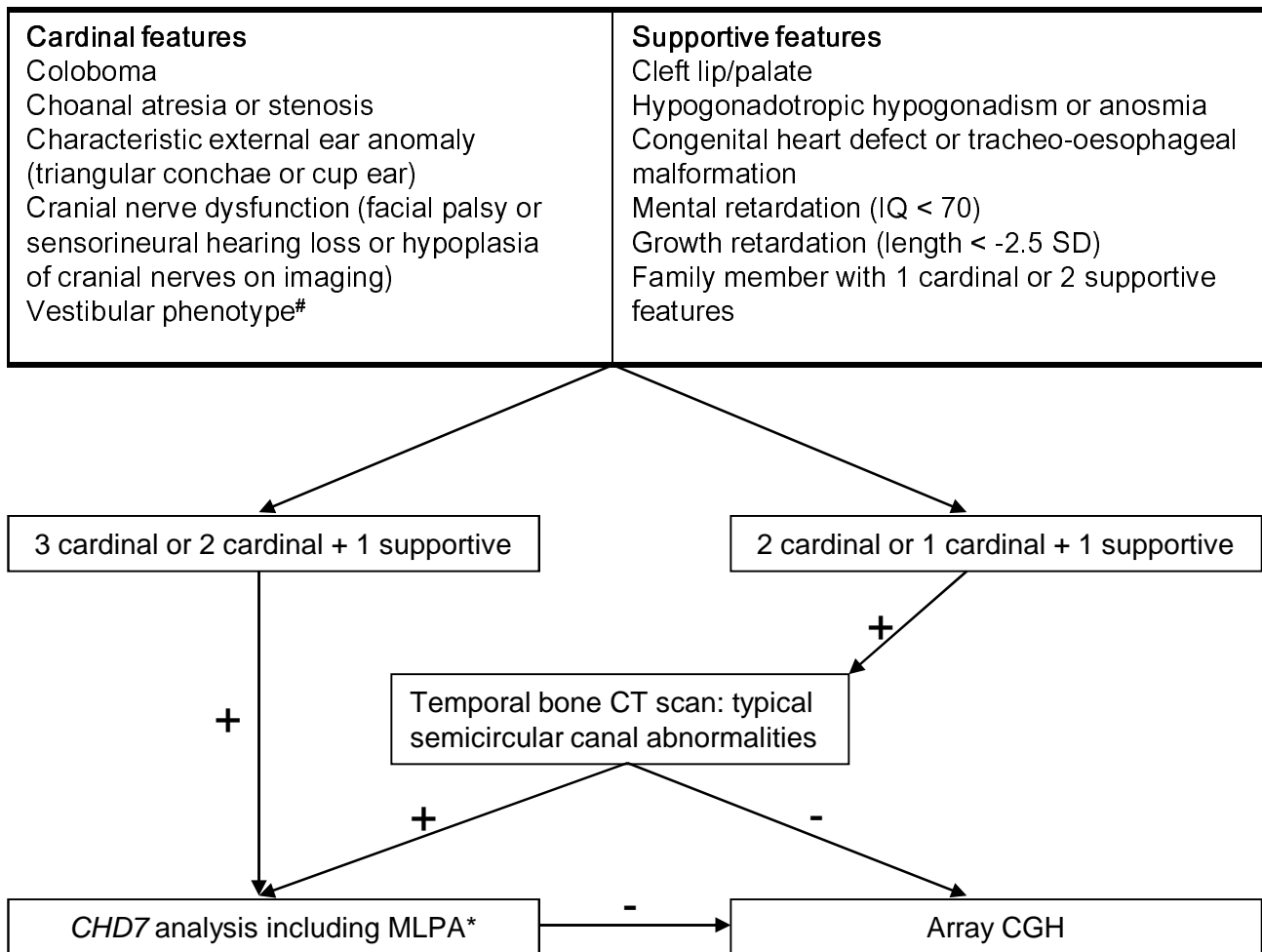




Figure 3 Guideline for *CHD7* analysis in patients suspected of CHARGE syndrome



[#] A convincing history of vestibular problems (e.g., five-point crawl) or abnormal vestibular test or semicircular canal hypoplasia.

^{*} If clinical presentation is very atypical, it is recommended to perform array CGH first

Patients with velocardiofacial syndrome, but without a mutation or deletion of the *TBX1* gene, are also good candidates for *CHD7* analysis