



**HAL**  
open science

## **Bilateral anterior uveitis secondary to erlotinib**

Lik Thai Lim, Robert Alexander Blum, Chee Peng Cheng, Abdul Hanifudin

► **To cite this version:**

Lik Thai Lim, Robert Alexander Blum, Chee Peng Cheng, Abdul Hanifudin. Bilateral anterior uveitis secondary to erlotinib. *European Journal of Clinical Pharmacology*, 2010, 66 (12), pp.1277-1278. <10.1007/s00228-010-0873-7>. <hal-00613127>

**HAL Id: hal-00613127**

**<https://hal.science/hal-00613127v1>**

Submitted on 3 Aug 2011

**HAL** is a multi-disciplinary open access archive for the deposit and dissemination of scientific research documents, whether they are published or not. The documents may come from teaching and research institutions in France or abroad, or from public or private research centers.

L'archive ouverte pluridisciplinaire **HAL**, est destinée au dépôt et à la diffusion de documents scientifiques de niveau recherche, publiés ou non, émanant des établissements d'enseignement et de recherche français ou étrangers, des laboratoires publics ou privés.



HAL Authorization



### Bilateral anterior uveitis secondary to erlotinib

Journal:	<i>European Journal of Clinical Pharmacology</i>
Manuscript ID:	EJCP-2010-0234
Type of submission:	Letter
Date Submitted by the Author:	26-Jun-2010
Complete List of Authors:	Lim, Lik Thai; Tennent Institute of Ophthalmology, Glasgow, UK, Eye department, Gartnavel General Hospital, Glasgow, UK. Blum, Robert; Tennent Institute of Ophthalmology, Glasgow, UK, Eye department, Gartnavel General Hospital, Glasgow, UK Cheng, Chee Peng; Tennent Institute of Ophthalmology, Glasgow, UK, Eye department, Gartnavel General Hospital, Glasgow, UK Hanifudin, Abdul; Hairmyers Hospital, Eye Dept.

Review

1  
2  
3 **Title page**

4  
5 **Adverse drug reaction**

6  
7  
8 **Title: Bilateral anterior uveitis secondary to erlotinib.**

9  
10 Lik Thai Lim<sup>1</sup>, Robert Blum<sup>1</sup>, Chee Peng Cheng<sup>1</sup>, Abdul Hanifudin<sup>2</sup>

- 11  
12  
13 1. Ophthalmology Department, Gartnavel General Hospital, Glasgow, UK.  
14 2. Ophthalmology Department, Hairmyers Hospital, UK.  
15

16 Corresponding author:

17  
18 Lik Thai Lim

19  
20 Ophthalmology Department, Gartnavel General Hospital, Great Western Road, Glasgow G12 0YN, UK.  
21

22  
23 E-mail: [likthai@doctors.org.uk](mailto:likthai@doctors.org.uk)  
24

25  
26 Tel: 447843617788  
27

28  
29 Fax: 44141-2112054  
30

31 All the authors declare that there are no conflict of interest and no financial and proprietary interest in the  
32 writing of this article.  
33

34 This article received no funding.  
35

36 Competing interest: None declared.  
37  
38  
39  
40

41 **Word count:** 566 words  
42  
43  
44  
45

46 **Keywords:** erlotinib; anterior uveitis; red eyes; side effects.  
47  
48  
49  
50  
51  
52  
53  
54  
55  
56  
57  
58  
59  
60

Dear Editor,

**Title: Bilateral anterior uveitis secondary to erlotinib.**

We would like to report the first case of bilateral severe anterior uveitis secondary to erlotinib. Erlotinib is an EGFR inhibitor which can contain the cancer cells.<sup>[1]</sup> It is licensed for use in patients with non-small cell lung carcinoma (NSCLC) in the UK, as a secondary treatment, for those patients who fail to respond to chemotherapy.<sup>[2]</sup>

**Case history**

A 63-year-old lady presented to eye casualty with a five-day history of bilateral red watery (non-discharging) eyes, accompanied by photophobia, reduced vision and a dull ache in both eyes. The best corrected visual acuity (BCVA) was Snellen acuity of 6/24 in the right eye and 6/12 in the left. She was diagnosed with non-small cell lung carcinoma (NSCLC) about nine months previously and had not responded to standard chemotherapy. Other than the NSCLC, there was no significant past medical history. She was commenced on erlotinib (150mg OD PO) about six weeks prior to her presentation to the eye clinic. Her other medications were loperamide and oxytetracycline. During the fifth week of erlotinib treatment, she developed dull, aching, red, watery eyes with reduced vision. At the same time she also developed diarrhoea, frontal headache, nausea and mouth irritation.

Ocular examination revealed bilateral severe anterior uveitis with almost complete posterior synechiae (Figure 1). The anterior chamber examination revealed fine keratic precipitates, cells (3+), and flare (2+). There was no hypopyon. Fundus examination was unremarkable. There was no clinical evidence of ocular metastases. She was treated appropriately with regular topical ocular steroid (prednisolone acetate 1%) and mydrilate (atropine 1%). Subsequently the posterior synechiae and the anterior uveitis resolved after two weeks.

In view of the history, it is very likely that the bilateral anterior uveitis was secondary to the erlotinib. However, this side effect has not been reported in the medical literature.

This is therefore the first reported case of bilateral anterior uveitis secondary to erlotinib. This episode was reported to the Medicines and Healthcare product Regulatory Agency of the UK (MHRA) (Yellow form).

**Discussion**

Epidermal growth factor receptor (EGFR) is known to be involved in the growth and proliferation of various forms of cancer cells, including non-small cell lung carcinoma. One method of containing the cancer cells is to inhibit their growth and spread. Erlotinib is an EGFR inhibitor aimed at containing the proliferation and dissemination of various cancer cells, including non-small cell lung carcinoma (NSCLC).<sup>[1]</sup> In the UK, erlotinib is used as a second line medication for NSCLC in patients unresponsive to standard chemotherapy.<sup>[2]</sup>

Erlotinib can be an effective treatment to contain NSCLC but the side effects of this drug can also be debilitating. Common ocular side effects of erlotinib include conjunctivitis, keratoconjunctivitis sicca and keratitis. Other common systemic side effects include mouth irritation, nausea, headaches, rash, diarrhoea, itching, dry skin, indigestion, altered skin sensation and depression.<sup>[3,4]</sup>

1  
2  
3 The less common ocular side effects include eyelash changes and ulceration and corneal perforation (1 in 10  
4 000).<sup>[3,4]</sup>  
5  
6

7 An extensive literature search found no reports of bilateral anterior uveitis as a side effect of erlotinib. It is clear  
8 from the history that all of the ocular and systemic symptoms occurred simultaneously during the fifth week of  
9 erlotinib therapy. It can therefore be inferred that the anterior uveitis was a complication of erlotinib therapy.  
10  
11

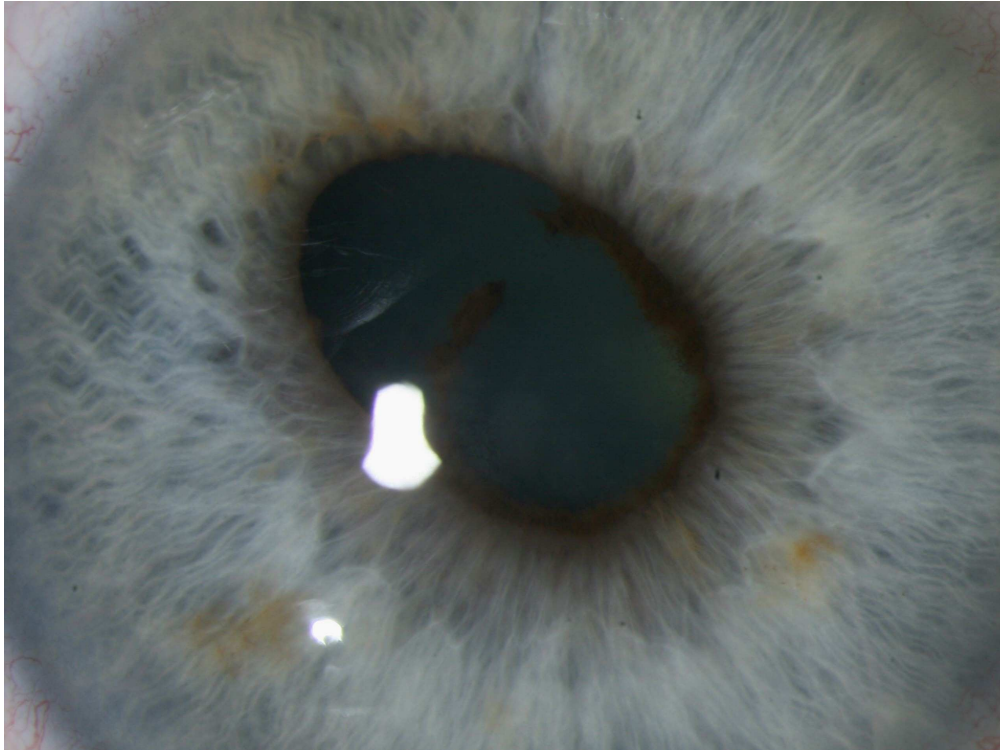
12 In conclusion, the treating physician must bear in mind the possibility of anterior uveitis as a potential side  
13 effect of erlotinib therapy. A prompt referral to the ophthalmology department for management is necessary for  
14 any patient who develops symptoms of uveitis while on erlotinib.  
15  
16  
17  
18  
19  
20  
21

## 22 References

- 23 1. Raymond E, Faivre S, Armand J. (2000) Epidermal growth factor receptor tyrosine kinase as a target  
24 for anticancer therapy". *Drugs* 60 Suppl 1: 15–23; discussion 41–2.
- 25 2. <http://www.nice.org.uk/guidance/index.jsp?action=byID&o=11714> (2008). Accessed 27 June 2010.
- 26 3. Román Pérez-Soler, M.D. (2004) Selected Highlights. *Lung Cancer Frontiers* 22 (16): 3238–3247.
- 27 4. Thomas L. Petty, M.D. (2003). Determinants of Tumor Response and Survival With Erlotinib in  
28 Patients With Non—Small-Cell Lung Cancer. *Journal of Clinical Oncology* 1 (17): 3–4.  
29  
30  
31  
32  
33  
34  
35  
36  
37  
38

39 Legend to figure:

40  
41 Figure 1 One of the pupils showing almost complete posterior synechiae due to anterior uveitis.  
42  
43  
44  
45  
46  
47  
48  
49  
50  
51  
52  
53  
54  
55  
56  
57  
58  
59  
60



One of the pupils showing almost complete posterior synechiae due to anterior uveitis.  
900x673mm (72 x 72 DPI)

Review

1  
2  
3  
4  
5  
6  
7  
8  
9  
10  
11  
12  
13  
14  
15  
16  
17  
18  
19  
20  
21  
22  
23  
24  
25  
26  
27  
28  
29  
30  
31  
32  
33  
34  
35  
36  
37  
38  
39  
40  
41  
42  
43  
44  
45  
46  
47  
48  
49  
50  
51  
52  
53  
54  
55  
56  
57  
58  
59  
60