



**HAL**  
open science

## **Surgical treatment of Spheno-Orbital Meningiomas**

Peerooz Saeed, Wouter van Furth, Michael Tanck, Nicole Freling, Jan Willem Berkelbach van Der Berkelbach van Der Sprenkel, Lucas Stalpers, Jakobus Overbeeke, Maarten Mourits

► **To cite this version:**

Peerooz Saeed, Wouter van Furth, Michael Tanck, Nicole Freling, Jan Willem Berkelbach van Der Berkelbach van Der Sprenkel, et al.. Surgical treatment of Spheno-Orbital Meningiomas. *British Journal of Ophthalmology*, 2011, 95 (7), pp.996. 10.1136/bjo.2010.189050 . hal-00608987

**HAL Id: hal-00608987**

**<https://hal.science/hal-00608987>**

Submitted on 17 Jul 2011

**HAL** is a multi-disciplinary open access archive for the deposit and dissemination of scientific research documents, whether they are published or not. The documents may come from teaching and research institutions in France or abroad, or from public or private research centers.

L'archive ouverte pluridisciplinaire **HAL**, est destinée au dépôt et à la diffusion de documents scientifiques de niveau recherche, publiés ou non, émanant des établissements d'enseignement et de recherche français ou étrangers, des laboratoires publics ou privés.

## **Surgical treatment of sphenoorbital meningioma**

Competing interest: None to declare.

### **Abstract**

**Purpose:** To evaluate the outcome of surgery and radiotherapy in the treatment of sphenoorbital meningioma (SOM).

**Method:** A retrospective study of 66 consecutive cases treated with surgery for SOM with a minimum follow-up of 4 years. Clinical and radiological information were compared before and after the following surgical approaches: frontotemporal craniotomy, frontotemporal craniotomy combined with orbitozygomatic resection, and extended lateral orbitotomy alone.

**Results:** The median age at presentation was 46 (range, 26–68) years and the median follow-up after surgery was 102 (48–288) months. In total, 48 (73%) patients showed preoperative visual deterioration, with visual field defects. All patients had proptosis at presentation (mean±SD = 6.4±3.0 mm). Surgery for patients with SOM arrested visual deterioration in 61% and improved vision in 30% of cases. Furthermore, a substantial reduction of proptosis was achieved in 85% of patients. The proptosis in our group was reduced by 2.6±2.6 mm. There was no correlation between surgical approach and proptosis reduction ( $P = 0.125$ ). The recurrence rate was 17%. Only one of 15 patients who underwent radiotherapy showed signs of recurrence.

**Conclusions:** The surgical aims in the treatment of SOM should be the restoration of visual acuity and reduction of proptosis, rather than complete tumour removal. The surgical approach can be tailored to individual cases. We recommend radiotherapy in cases of subtotally removed SOM.

## **Introduction**

Sphenoorbital meningiomas (SOM) originate from the dura of the sphenoid wing, involve the orbit and cause visual deterioration and proptosis.<sup>1-12</sup> Given their extensive dural and orbital involvement, adequate resection of SOM is difficult, leading to a recurrence rate of up to 50%.<sup>13-15</sup> The main aim of surgery is to restore the deteriorated vision and treat proptosis.<sup>1-12</sup> Adequate treatment strategies and surgical approaches remain controversial. Some authors have reported that longstanding tumour-related proptosis cannot be treated surgically and that it should therefore not be attempted.<sup>16</sup> Others advocate early, aggressive surgical therapy as the initial treatment.<sup>17</sup> Postoperative radiotherapy is recommended for subtotally removed or recurrent SOMs,<sup>18</sup> although little information is available regarding the efficacy and side effects of this treatment.

This study was performed to evaluate different surgical approaches used in two centres over a period of two decades. We studied long-term surgical outcomes and the effects and complications associated with postoperative radiotherapy in SOM.

## **Patients and Methods**

We examined the records of 90 patients treated between 1980 and 2007 at the Orbital Centre of the Academic Medical Centre, University of Amsterdam ( $n = 61$ ), and at the

University Medical Centre in Utrecht ( $n = 29$ ) with a diagnosis of SOM.

Sixty-six patients in this group underwent surgery at the Orbital Centre of the Academic Medical Centre, University of Amsterdam ( $n = 40$ ), and the University Medical Centre in Utrecht ( $n = 26$ ). Fifty-one patients with optic neuropathy combined with disfiguring proptosis and 15 with disfiguring proptosis were indicated for surgery. Twenty-three patients underwent no surgery due to stable visual acuity and the absence of optic neuropathy. Despite visual deterioration in the amblyopic eye, one patient declined surgical intervention. Only patients who underwent surgery were included in this study.

The clinical history, surgical approach, and outcome were obtained retrospectively from a review of patient charts and imaging. Our analysis considered neurological symptoms and their duration, ophthalmological examinations, consisting of testing the patient's visual acuity (Snellen notation) and pupil responses, funduscopy, tonometry, and Goldmann or Humphrey perimetry for visual field defects. Ocular motility was also evaluated.

Diplopia was considered present when the patient experienced double vision (in any gaze direction) that disappeared with one eye closed. The degree of proptosis was determined using a Hertel exophthalmometer. In Amsterdam, an Oculus Hertel (Oculus Optikgeräte GmbH, Wetzlar, Germany) was used and in Utrecht, a Zeiss Hertel (Carl Zeiss, Jena, Germany) was used.

All patients underwent preoperative computed tomography (CT) or magnetic resonance imaging (MRI;  $n = 51$ ) with contrast. Imaging was scheduled immediately after surgery, at 3 and 12 months postoperatively, and annually thereafter for 5 years, and then at longer intervals, depending on the presence or absence of residual or recurrent tumours.

In patients who underwent radiotherapy, tear production was assessed using the Schirmer test and corneal dryness was classified as no corneal change, corneal stippling, limited to the inferior periphery, more extended stippling, ulceration and clouding postradiation cataract. When necessary, fluorescein angiography was performed to evaluate any postradiation retinopathy. After radiotherapy, all patients underwent detailed endocrinological testing.

### ***Surgical procedures***

Frontotemporal (pterional) craniotomy was performed as described.<sup>19</sup> The greater wing of the sphenoid ridge was removed to the lateral limit of the lesser wing. When hyperostotic, the anterior clinoid was removed extradurally and the superior orbital fissure (SOF) was unroofed. The optic canal was unroofed, either intra- or extradurally, and the inferior optic strut was removed. When intracranial or intraorbital soft tissue was present, it was resected.

Orbitozygomatic craniotomy (OZ)<sup>20</sup> is an extension of the frontotemporal approach. The superior and lateral orbital rims were mobilised with additional removal of part of the lateral wall along the zygoma and orbital roof, which provides access to the floor of the anterior and middle cranial fossae. This was performed in either one or two pieces, with the superior and lateral rim.

Extended lateral orbitotomy was performed through either a coronal or lid crease incision. In this approach, the classical lateral orbitotomy bone incision described by Berke was enlarged from the deep sphenoid wing up to the SOF.<sup>21,22</sup>

### ***Reconstruction***

Periorbital reconstruction was not performed. The superior and lateral orbital rim bone was reattached. The roof and lateral wall of the orbit were routinely reconstructed with a split cranial bone graft and secured to the orbital rim by titanium miniplates. In two cases, this was performed using titanium mesh. Dural defects were reconstructed with autologous galea grafts, which included convexity and basal defects. If there was a large cavity between the orbital and dural reconstruction and the cranioplasty, an autologous fat graft, harvested from the abdomen, was used to fill this and prevent a postoperative pseudomeningocele. The temporal muscle was resuspended and sutured meticulously.

### ***Radiotherapy***

Postoperatively, 15 patients underwent radiotherapy of 54 Gy in 1.8-Gy fractions. The inclusion criteria for radiotherapy were large rest tumour and involvement of the cavernous sinus, while the exclusion criteria were the presence of diabetes mellitus and hypertension.

### ***Statistical Analyses***

Visual acuity and pre- and postoperative proptosis are described as means $\pm$ SD.

Differences between the three different surgical approaches were compared using the Kruskal–Wallis test. Proptosis reduction was compared between the three approaches with correction for preoperative proptosis (nonparametric ANOVA). All analyses were carried out using the SPSS software (ver. 16 for Windows; SPSS, Chicago, IL, USA). In all analyses,  $P < 0.05$  was deemed to indicate statistical significance.

## **Results**

The median age at presentation was 46 (range, 26–68) years. The study population consisted of 61 (92%) females and five (8%) males. The left and right orbits were involved in 35 and 31 patients, respectively. The median follow-up after surgery was 102 months (48–288 months) and the median period between presentation and surgery was 24 months (1–119 months). In total, 51 (77%) patients had preoperative progressive visual deterioration with visual field defects. Three patients had no light perception (NLP) preoperatively. All patients had proptosis at presentation, with a mean of  $5.89 \pm 2.89$  mm (mean  $\pm$  SD). At presentation, seven (11%) patients had diplopia and 19 (29%) had headaches or retrobulbar pain.

## ***Surgery***

The surgical approach was frontotemporal craniotomy in 45 patients and this approach was combined with orbitozygomatic resection in 10 patients. Forty-six patients in this group had optic neuropathy due to compression of the optic nerve, five had disfiguring proptosis with hyperostosis of the optic canal and four had proptosis combined with retrobulbar pain. As all of these 55 patients had disfiguring proptosis, this was also addressed at the time of surgery.

An extended lateral orbitotomy was performed in 11 patients. Patients in this group had only disfiguring proptosis and two had severe proptosis with stretching of the optic nerve.

### *Craniotomies*

Fifty-five patients underwent a large unilateral frontotemporal craniotomy, followed by removal of additional tumour-infiltrated bone *via* an extradural approach in all cases. Ten procedures also included OZ resection. The orbital roof was resected in 49 cases and the lateral orbital wall was removed in 35. The optic canal and SOF were opened and decompressed in 51 and 29 cases, respectively. After opening the orbit, periorbital resection or stripping was necessary in 32 procedures. Extensive en plaque dural involvement was found in 45 cases; resection of the convexity-dura was necessary in 39 cases.

Reconstruction was performed in 9 of 10 patients treated via the frontotemporal approach in combination with OZ. The reconstruction used calvarial bone in seven patients and titanium mesh in two; both the lateral and orbital roof were reconstructed in all nine patients (Fig. 1).

### *Orbitotomy*

In 11 patients who underwent lateral orbitotomy, the lateral wall of the orbit until the SOF was removed; in five cases, the orbital roof was also partially removed. In six procedures, periorbital resection was also performed due to tumour infiltration. In five cases in which there was infiltration of the ocular muscles, only the exophytic tumour was removed. None of these patients underwent reconstruction. All lateral orbitotomies were performed by orbital surgeons (Fig. 1).

### *Radiotherapy*

Fifteen patients underwent secondary radiotherapy after surgical excision. All 15 had



significant residual tumours, which also involved the cavernous sinus in four cases. Two patients underwent radiotherapy after debulking of a recurrent lesion. Only one of these patients showed further recurrence after follow-up for 38 months. In four patients, the tumour volume was reduced to less than 10%. In all four, there was significant soft tissue involvement.

### ***Outcome***

#### *Visual acuity*

Forty (61%) patients showed either stabilisation of their visual acuity or an improvement of less than two lines on the Snellen chart. Three eyes from this group maintained a visual acuity of NLP (no light perception). Fifteen had a visual acuity of more than 0.8 preoperatively, which remained stable postoperatively. Twenty (30%) had improved visual acuity. Eight improved by more than four lines on the Snellen chart and 12 others by more than two lines.

There was no significant difference ( $P = 0.195$ ) in postoperative vision between the different approaches. All except two patients with visual deterioration underwent decompression of the optic canal through a craniotomy. The two exceptions had proptosis of more than 10 mm with stretching of the optic nerve and underwent only extended lateral orbitotomy with total removal of the lateral orbital wall.

#### *Proptosis*

The mean proptosis, measured with a Hertel exophthalmometer, in this group was  $6.4 \pm 3.0$  mm preoperatively and  $3.8 \pm 2.3$  mm postoperatively. The mean reduction in proptosis was  $2.6 \pm 2.6$  mm. Seventeen orbits showed a proptosis reduction of more than

5 mm, while ten showed no change in proptosis compared with preoperative values. One patient who underwent no reconstruction of the orbit developed enophthalmos of 2 mm. Fifty patients had a residual proptosis exceeding 2 mm. Patients who underwent lateral orbitotomy and combined craniotomy and OZ had the greatest mean preoperative proptosis of  $7.9\pm 3.4$  and  $7.7\pm 2.9$  mm, respectively. The mean proptosis with frontotemporal craniotomy only was  $5.9\pm 2.9$  mm. However, there was no significant ( $P = 0.125$ ) difference in the postoperative reduction in proptosis among the approaches (Fig. 2).

### *Diplopia*

New diplopia was observed in 40 patients; it was transient in 32 cases. Two patients showed no eye movement in the first weeks after surgery; in both patients, the lateral wall was removed completely. Within 6 months, eye movement recovered completely, with no diplopia. Eight patients (12%) still showed diplopia; three of these underwent strabismus surgery with satisfactory results. In six patients after a frontotemporal craniotomy, the cause of the diplopia was third nerve palsy; thus, no strabismus surgery was performed. Ptosis surgery was performed in one patient with partial third nerve palsy and no diplopia. Nine patients with diplopia in the primary position preoperatively still had diplopia postoperatively and underwent surgical correction.

### *Pain*

Of 19 patients with retrobulbar pain after surgery, 16 had no further pain. All of these patients underwent craniotomies.

## ***Complications***

### *Surgery*

Five patients developed subgaleal cerebrospinal fluid (CSF) accumulation, which regressed spontaneously in four cases; one patient required surgical revision of the dural leak and placement of a lumboperitoneal shunt. After craniotomies, permanent third nerve palsies were seen in six cases, and fourth and sixth nerve palsies occurred in one patient each. Permanent trigeminal and facial nerve palsies were present in six and three patients, respectively.

In two patients who underwent OZ, the lateral excursion of the mandible was reduced by approximately 50%.

### *Radiotherapy*

Three patients developed severe punctate keratopathy necessitating the daily use of lubricants. One patient also developed radiation retinopathy, but had stable visual acuity of 0.5 after laser treatment. During follow-up, one patient developed pituitary function impairment. There was no death due to treatment or SOM in this study population.

### ***Recurrence***

Eleven (17%) patients showed recurrence (regrowth). The median time between surgery and recurrence was 46 months (10–108 months). Macroscopic radical excision was achieved in only six patients. Of 61 patients with rest tumour, 15 underwent radiotherapy. Despite the larger size of the rest tumour in this group, only one of these 15 patients (7%) showed recurrence.

The signs of recurrence in four patients were a combination of visual deterioration and increased proptosis, while four patients showed only a mild increase in proptosis (< 3 mm). Four patients with visual deterioration underwent second craniotomy—two had improved visual acuity and two other patients with NLP underwent two other debulking surgeries and the affected eye was ultimately enucleated because of corneal ulceration caused by proptosis.

## **Discussion**

Symptom-oriented surgery for SOM is directed primarily at optic nerve decompression when there is decreased visual acuity. In our series, the visual acuity improved in 30% of cases and remained the same in 61% of cases. The cause of optic neuropathy was addressed and treated in all of the patients with optic neuropathy. This was probably related to the degree and period of optic nerve compression. In our series, the proptosis was reduced by a mean of 2.6 mm from preoperative values, ranging from 2 to 14 mm. Seventeen (26%) patients showed a marked reduction in proptosis by more than 5 mm and up to 11 mm. Excluding one case of enophthalmos, residual proptosis was present in 50 (76%) of the remaining patients. Nevertheless, 85% showed an improvement of more than 2 mm. All patients in our series underwent periodical proptosis measurements with a Hertel exophthalmometer. There have been only a few previous attempts to quantify postoperative proptosis in SOM.<sup>2,5,12</sup> Ringel *et al.* reported improvement of proptosis in 43 of 56 patients (77%) with no change in proptosis in the remaining 13 patients (23%).<sup>2</sup> A recent study quantified the proptosis by MRI and reported significant residual proptosis in 53% of cases.<sup>5</sup> We believe that the cause of this significant residual proptosis was long-standing congestion and fibrosis, resulting in less mobile orbital

contents. Despite this residual proptosis in the surgical treatment of SOM, the proptosis improves in most cases. Surgery also seemed to be effective at relieving pain associated with SOM; 16 of the 19 patients with reported pain showed no sign of pain postoperatively. We believe that pain is an underreported symptom in these series.

Our recurrence rate of 17% was consistent with other recently published series with long-term follow-up.<sup>1-12</sup> These recurrence rates are much lower than those in earlier studies, which reported recurrence rates of 30–50%.<sup>13-14</sup> Maroon *et al.* listed the following reasons for the high recurrence rate in SOM: failure to diagnose the tumour early because the symptoms were confused with those of other clinical entities, such as fibrous dysplasia and Graves' disease; inadequate resection, due to the involvement of important neurovascular structures; and the surgeon's concern of iatrogenic death and serious complications in radical resections.<sup>18</sup>

New imaging techniques appear to have improved the early diagnosis and effective surgical resection. To resect SOM, different surgical approaches are used, including transzygomatic, pterional, frontotemporal, and combined transcranial-transmalar and craniorbital approaches. All of these approaches allow sufficient access to the orbit and middle fossa base for bony and soft-tissue tumour resection and decompression of the SOF and optic canal.<sup>19,20,23,24</sup> Extended lateral orbitotomy or total lateral orbitotomy has been used routinely for severe cases of Graves' orbitopathy and tumours in the orbital apex. This approach is effective in patients with SOM in which the main symptom is disfiguring proptosis, without involving the risks of a craniotomy.<sup>21,22,25,26</sup> Recently, Lund reported 12 patients with SOM who underwent endoscopic endonasal medial orbital wall decompression and decompression of the optic canal in eight patients with opticopathy and visual deterioration.<sup>27</sup> In these

patients, the opticopathy improved and the visual acuity improved by 1–4 lines on the Snellen chart.

Depending on the extent of the orbital wall and roof resection, most authors recommend firm reconstruction of the orbital walls to avoid pulsating enophthalmos and diplopia.

Maroon *et al.* reported 200 cases of orbital wall and roof resection without reconstruction, in which no cases showed permanent pulsating enophthalmos.<sup>18</sup> DeMonte *et al.* concluded that partial or complete orbital roof resection, isolated or combined with lateral or medial orbital wall defects, did not require routine reconstruction when the periorbita was not resected.<sup>28</sup> We advocate reconstruction of the orbital roof and the lateral orbital rim. We consider reconstruction of the lateral orbital wall to be unnecessary in most cases. Studies of orbital decompression in Graves' orbitopathy have shown that lateral wall decompression can reduce the proptosis by up to 2 mm.<sup>29,30</sup> As significant residual proptosis was present with all surgical approaches in SOM in these series, no further reconstruction of the lateral orbital wall may contribute to further proptosis reduction, while reconstruction of the orbit roof is sufficient to avoid pulsating enophthalmos. Techniques have improved since 1952, when Castellano *et al.* reported a high surgical mortality rate (20%) associated with SOM and concluded that SOM should be used only as a last resort.<sup>16</sup> Although the mortality rate has decreased, some recent studies still reported mortality rates of 3–6%.<sup>2,3,11,26</sup> Other complications, such as vision loss and transient (6–84%) or permanent (7–30%) cranial nerve deficits, are frequent.<sup>1–12</sup> Although life-threatening complications were not seen in this series, postoperative visual deterioration occurred in 6 of 66 cases (9%),

oculomotor nerve palsy in 5 of 66 cases (7%) patients, and facial nerve palsy in 3 of 66 cases (5%).

Radiotherapy is often used to treat SOM. Peele *et al.* delivered a total dose of 45 Gy to subtotally or recurrent SOMs and none of the 42 patients in the radiation treatment group experienced recurrence during an observation period of 4.2 years, whereas 21 of the 44 patients in the non-radiation treatment group later presented with recurrent tumour growth.<sup>31</sup>

Another study indicated a decrease in size of skull base meningiomas in 51% of patients, stabilisation in 47% of cases and increased tumour size in 2% of cases.<sup>32</sup> In our series, postoperative radiotherapy in subtotally removed SOM resulted in a reduction in tumour size and stabilisation in 27% and 67% of cases, respectively.

In conclusion, the aim of surgery in the treatment of SOM should be restoration of visual acuity and reduction of proptosis, rather than complete bony tumour removal. The surgical approach can be tailored to individual cases. Decompression of the optic canal can be achieved either through a combined frontotemporal approach and OZ or a frontotemporal approach alone. However, the frontotemporal approach combined with OZ in these series was not associated with better visual or proptosis outcome.

When the major symptom is proptosis without optic canal stenosis, extended lateral orbitotomy alone can be preformed to avoid the complications of a craniotomy. As the majority of SOMs are resected subtotally, postoperative radiotherapy may provide better control of tumour growth. As retrospective studies, by their nature, have potential bias, these case series should be followed in future by prospective studies.





## References

1. Shrivastava RK, Sen C, Costantino PD, Della-Rocca R: Sphenoorbital meningiomas: Surgical limitations and lessons learned in their long-term management. *J Neurosurg* 103:491–497, 2005.
2. Ringel F, Cedzich C, Schramm J: Microsurgical technique and results of a series of 63 sphenoorbital meningiomas. *Neurosurgery* 60 [Suppl 2]: 2007.
3. Carrizo A, Basso A: Current surgical treatment for sphenoorbital meningiomas. *Surg Neurol* 50:574–578, 1998
4. Sandalcioglu IE, Gasser T, Mohr C, Stolke D, Wiedemayer H: Sphenoorbital meningiomas: interdisciplinary surgical approach, resectability and long-term results. *J Craniomaxillofac Surg* 33:260–266, 2005.
5. Scarone P, Leclercq D, Héran F, Robert G: Long-term results with exophthalmos in a surgical series of 30 sphenoorbital meningiomas. Clinical article. *J Neurosurg* 111(5):1069–77, 2009.
6. Honeybul S, Neil-Dwyer G, Lang DA, Evans BT, Ellison DW: Sphenoid wing meningioma *en plaque*: a clinical review. *Acta Neurochir (Wien)* 143:749–758, 2001.
7. Roser F, Nakamura M, Jacobs C, Vorkapic P, Samii M: Sphenoid wing meningiomas with osseous involvement. *Surg Neurol* 64:37–43, 2005.
8. De Jesús O, Toledo MM: Surgical management of meningioma *en plaque* of the sphenoid ridge. *Surg Neurol* 55:265–69, 2001.
9. Schick U, Bleyen J, Bani A, Hassler W: Management of meningiomas *en plaque* of the sphenoid wing. *J Neurosurg* 104: 208–214, 2006.
10. Mourits MP, van der Sprenkel JW: Orbital meningiomas, the Utrecht experience.

- Orbit 20:25–33, 2001.
11. Pompili A, Derome PJ, Visot A, Guiot G: Hyperostosing meningiomas of the sphenoid ridge-clinical features, surgical therapy, and long-term observations: review of 49 cases. *Surg Neurol* 17:411–416, 1982.
  12. Heufelder MJ, Sterker I, Trantakis C, *et al.*: Reconstructive and ophthalmologic outcomes following resection of sphenoid-orbital meningiomas. *Ophthal Plast Reconstr Surg* 5(3):223–6, 2009.
  13. Abbott KH, Glass B: Pterional meningioma *en plaque*; report of a case of thirty-six years' duration. *J Neurosurg* 12:50–52, 1955.
  14. Adegbite AB, Khan MI, Paine KW, Tan LK: The recurrence of intracranial meningiomas after surgical treatment. *J Neurosurg* 58: 51–56, 1983.
  15. Cophignon J, Lucena J, Clay C, Marchac D: Limits to radical treatment of sphenoid-orbital meningiomas. *Acta Neurochir Suppl (Wien)* 28:375–380, 1979
  16. Castellano F, Guidetti B, Olivecrona H: Pterional meningiomas *en plaque*. *J Neurosurg* 9:188–196, 1952.
  17. Bikmaz K, Mrak R, Al-Mefty O: Management of bone-invasive, hyperostotic sphenoid wing meningiomas. *J Neurosurg* 107:905–912, 2007.
  18. Maroon JC, Kennerdell JS, Vidovich DV, Abla A, Sternau L: Recurrent sphenoid-orbital meningioma. *J Neurosurg* 80:202–208, 1994
  19. Yasargil MG: *Microneurosurgery*, Vol. 1. Stuttgart: Georg Thieme Verlag, 1984, pp 208–271.
  20. Al-Mefty O, Anand VK: Zygomatic approach to skull-base lesions. *J Neurosurg* 73:668–673, 1990.
  21. Rootman J, Stewart B, Goldberg RA: *Orbital Surgery*, Lippincott-Raven,

- Philadelphia (1995), pp. 303–333.
22. Kennerdell JS, Maroon JC, Malton ML: Surgical approaches to orbital tumors. *Clin Plast Surg* 15(2):273–282, 1988.
  23. Al-Mefty O: Supraorbital-pterional approach to skull base lesions. *Neurosurgery* 21:474–477, 1987.
  24. Hassler WE, Eggert H: Extradural and intradural microsurgical approaches to lesions of the optic canal and the superior orbital fissure. *Acta Neurochir (Wien)* 74:87–93, 1985.
  25. Kim JW, Yates BS, Goldberg RA: Total lateral orbitotomy. *Orbit* 28(6):320–7, 2009.
  26. Mariniello G, Maiuri F, Strianese D, Donzelli R, Iuliano A, Tranfa F, de Divitiis E, Bonavolontà G: Spheno-orbital meningiomas: surgical approaches and outcome according to the intraorbital tumor extent. *Zentralbl Neurochir* 69(4):175–81, 2008.
  27. Lund VJ, Rose GE: Endoscopic transnasal orbital decompression for visual failure due to sphenoid wing meningioma. *Eye (Lond)*. 20(10):1213-9, 2006
  28. DeMonte F, Tabrizi P, Culpepper SA, Suki D, Soparkar CN, Patrinely JR: Ophthalmological outcome after orbital entry during anterior and anterolateral skull base surgery. *J Neurosurg* 97:851–856, 2002.
  29. Goldberg RA, Kim AJ, Kerivan KM: The lacrimal keyhole, orbital door jamb and basin of the inferior orbital fissure. Three areas of deep bone in the lateral orbit. *Arch Ophthalmol* 116:1618–1624, 1998.
  30. Baldeschi L, MacAndie K, Hintschich C, Wakelkamp IM, Prummel MF, Wiersinga WM: The removal of the deep lateral wall in orbital decompression: its contribution to exophthalmos reduction and influence on consecutive diplopia. *Am J Ophthalmol* 140(4):642–7, 2005.

31. Peele KA, Kennerdell JS, Maroon JC, Kalnicki S, Kazim M, Gardner T, *et al.*: The role of postoperative irradiation in the management of sphenoid wing meningiomas. A preliminary report. *Ophthalmology* 103:1761–1767, 1996.
32. Goldsmith BJ, Wara WM, Wilson CB, Larson DA: Postoperative irradiation for subtotally resected meningiomas. A retrospective analysis of 140 patients treated from 1967 to 1990. *J Neurosurg* 80:195–201, 1994.

#### Licence for Publication

“The Corresponding Author has the right to grant on behalf of all authors and does grant on behalf of all authors, an exclusive licence (or non exclusive for government employees) on a worldwide basis to the BMJ Publishing Group Ltd. and its Licensees to permit this article (if accepted) to be published in BJO editions and any other BMJ PGL products to exploit all subsidiary rights, as set out in our licence(<http://group.bmj.com/products/journals/instructions-for-authors/licence-forms>).”

**Table 1.** Visual outcome after treatment of sphenoorbital meningiomas

Treatment Modality	No. of patients ( <i>n</i> = 66)	Outcome of treatment (no. of cases)		
		Improvement	Stable/No significant change	Significant deterioration
VA TX				
1.0 – 0.8	20	0	19	1
0.7 – 0.4	25	12	10	3
0.3 – 0.1	18	8	8	2
NLP	3	0	3	0
Type of surgery				
Frontotemporal	45	16	24	5
Frontotemporal + OZ	10	4	6	1
lateral orbitotomy	11	1	10	0
Radiotherapy	15	0	15	0

VA = Visual acuity; TX = Treatment; OZ = Orbitozygomatic resection

Fig. 1

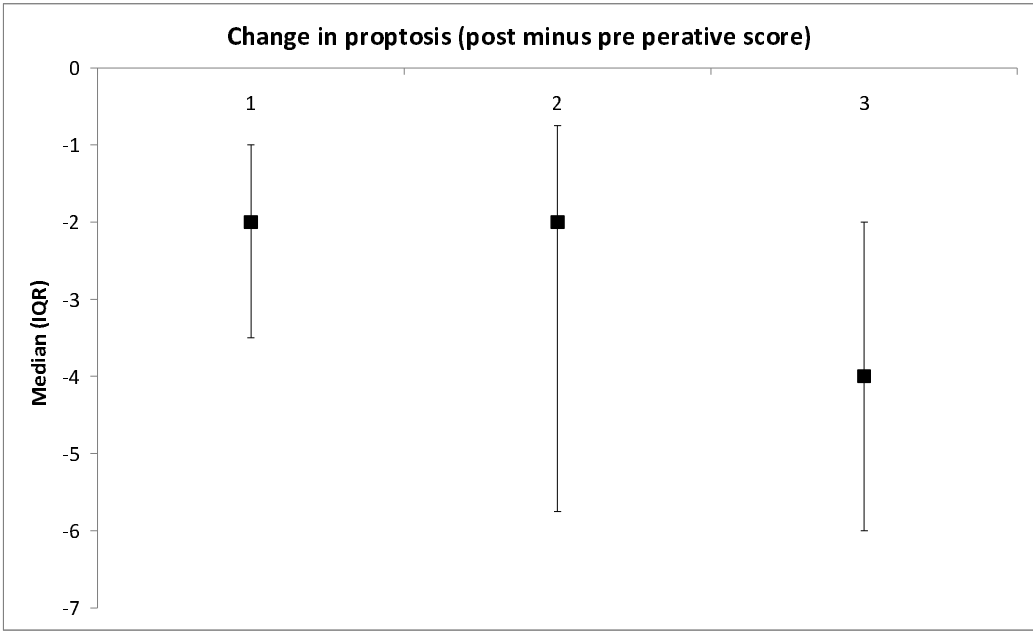
A–B

Preoperative and postoperative T1-weighted MR fat suppression sequences obtained post-Gd administration, showing a sphenoorbital meningioma before and after frontotemporal craniotomy combined with orbitozygomatic resection.

C–D

Preoperative and postoperative CT scan axial views showing a sphenoorbital meningioma before and after extended lateral orbitotomy.

**Figure -2 Proptosis reduction in three different surgical approaches**



1. Frontotemporal craniotomy 2. Frontotemporal craniotomy combined with orbitozygomatic resection 3. Extended lateral orbitotomy





