



Mucosal healing with methotrexate in Crohn's disease: a prospective comparative study with azathioprine and infliximab

David Laharie, Armel Reffet, Genevieve Belleannée, Edouard Chabrun, Clement Subtil, Sylvie Razaire, Maylis Capdepon, Victor de Ledinghen

► To cite this version:

David Laharie, Armel Reffet, Genevieve Belleannée, Edouard Chabrun, Clement Subtil, et al.. Mucosal healing with methotrexate in Crohn's disease: a prospective comparative study with azathioprine and infliximab. *Alimentary Pharmacology and Therapeutics*, 2011, 33 (6), pp.714. 10.1111/j.1365-2036.2010.04569.x . hal-00608946

HAL Id: hal-00608946

<https://hal.science/hal-00608946>

Submitted on 16 Jul 2011

HAL is a multi-disciplinary open access archive for the deposit and dissemination of scientific research documents, whether they are published or not. The documents may come from teaching and research institutions in France or abroad, or from public or private research centers.

L'archive ouverte pluridisciplinaire **HAL**, est destinée au dépôt et à la diffusion de documents scientifiques de niveau recherche, publiés ou non, émanant des établissements d'enseignement et de recherche français ou étrangers, des laboratoires publics ou privés.

Mucosal healing with methotrexate in Crohn's disease: a prospective comparative study with azathioprine and infliximab

Journal:	<i>Alimentary Pharmacology & Therapeutics</i>
Manuscript ID:	APT-1048-2010.R1
Wiley - Manuscript type:	Original Scientific Paper
Date Submitted by the Author:	16-Dec-2010
Complete List of Authors:	Laharie, David; CHU Bordeaux, Gastroenterology; CHU Bordeaux, Gastroenterology Reffet, Armel; CHU Bordeaux, Gastroenterology Belleannée, Genevieve; CHU Bordeaux, Pathology Chabrun, Edouard; CHU Bordeaux, Gastroenterology Subtil, Clement; CHU Bordeaux, Gastroenterology Razaire, Sylvie; CHU Bordeaux, Gastroenterology Capdepon, Maylis; CHU Bordeaux, Gastroenterology de Ledinghen, Victor; CHU Bordeaux, Gastroenterology
Keywords:	Inflammatory bowel disease < Disease-based, Crohn's disease < Disease-based, Inflammation < Topics, Biologics (IBD) < Topics

**Mucosal healing with methotrexate in Crohn’s disease: a prospective comparative study
with azathioprine and infliximab**

David Laharie ^{1,2}, Armel Reffet ¹, Geneviève Belleannée ³, Edouard Chabrun ¹, Clément Subtil ¹, Sylvie Razaire ¹, Maylis Capdepon ¹, Victor de Lédighen ¹.

¹ CHU de Bordeaux, Hôpital Haut-Lévêque, Service d’Hépatogastroentérologie, Pessac, F-33600 France, F-33075; Université Victor Segalen Bordeaux 2, Bordeaux, F-33076, France.

² Inserm, U853, Bordeaux, F-33076 France; Univ Bordeaux 2, Bordeaux, F-33076 France.

³ CHU de Bordeaux, Hôpital Haut-Lévêque, Laboratoire d’Anatomo-pathologie, Pessac, F-33600 France, F-33075.

Corresponding author:

David Laharie, CHU de Bordeaux, Hôpital Haut-Lévêque, Service d’Hépatogastroentérologie, Pessac, F-33600 France.

Fax: +33 557 656 445

Tel: +33 557 656 438

e-mail: david.laharie@chu-bordeaux.fr

Running head: mucosal healing with methotrexate

Word count: abstract 211; manuscript: 3620

Keywords: Crohn’s disease; mucosal healing; methotrexate; azathioprine; infliximab.

Abstract

Background: Mucosal healing (MH) has become a new therapeutic goal in Crohn's disease (CD) and can be achieved with azathioprine (AZA) or biologics. Methotrexate (MTX) is an effective drug for both the induction and maintenance of remission in CD. However, MH with MTX has been poorly investigated.

Aim: to assess the MH rate in patients with CD with clinical response to MTX as compared to AZA or infliximab (IFX).

Methods: From October 2007 to May 2009, consecutive patients with CD were prospectively enrolled into a single centre study when they met the following criteria: previous identification of mucosal ulcerations with ileo-colonoscopy, clinical remission within at least three months with MTX, AZA or IFX monotherapy, usual indication for colonoscopy in CD (dysplasia/cancer screening, suspected stenosis) excluding assessment for MH. MH was defined as absence of mucosal ulceration in all segments.

Results: Fifty-one patients with CD (38 female; median age: 42 years) were included: 18 receiving MTX, 18 AZA, and 15 IFX. MH was achieved in 2/18 (11%) with MTX, in 9/18 (50%) with AZA ($p = 0.011$ vs. MTX) and in 9/15 (60%) with IFX ($p = 0.008$ vs. MTX).

Conclusion: In patients with CD in sustained clinical remission, MH is less frequently achieved with MTX as compared to AZA or IFX.

Introduction:

The natural history of Crohn’s disease is characterized by active and remitting periods ¹. For a long time, medical treatment was solely focused on clinical symptoms, aiming to control disease flare and prevent relapse. Healing the gut mucosa was not considered as a therapeutic goal because of the poor correlation between symptom improvement and mucosal healing and the inefficacy of conventional drugs such as steroids to cure endoscopic lesions ².

During the past decade, new data have highlighted the significance of mucosal healing in Crohn’s disease. Firstly, the disappearance of endoscopic inflammatory lesions seems to be related with better long-term disease outcomes - less hospitalization and abdominal surgery ³⁻⁵. Secondly, the absence of mucosal healing in asymptomatic patients is associated with higher relapse rate ⁵ as positively shown in two recent prospective studies including patients treated with infliximab and immunosuppressants ^{6,7}. Lastly, retrospective data suggested that Crohn’s disease patients with severe endoscopic colonic lesions had increased rates of penetrating complications and colectomy ⁸.

Biologics, and especially anti-TNFs – infliximab, adalimumab and certolizumab pegol have brought a major advance in the treatment of both luminal and fistulizing Crohn’s disease ⁹. They have demonstrated not only clinical efficacy, but also that mucosal healing was achievable and could be maintained in patients with active Crohn’s disease ^{3, 10-12}.

Therefore, mucosal healing has emerged as a new therapeutic goal and is now considered as an endpoint in clinical trials ^{11, 12}. It has been less studied with conventional immunosuppressants commonly used in Crohn’s disease for many years. Few studies have shown the ability of azathioprine to induce mucosal healing, ^{13, 14} but recently, complete mucosal healing at week 26 was achieved in 15.6% of the 109 patients assessable in the azathioprine arm of the SONIC trial ¹². Data with methotrexate are more scarce. According to two small retrospective studies – 14 and 8 recruited patients, respectively – mucosal healing

1
2
3 was obtained in 36-37.5% of patients responding to methotrexate^{15, 16}. Therefore, the aim of
4
5 the present study was to assess the rate of mucosal healing with methotrexate in Crohn's
6
7 disease, as compared to azathioprine and infliximab.
8
9
10
11
12
13
14
15
16
17
18
19
20
21
22
23
24
25
26
27
28
29
30
31
32
33
34
35
36
37
38
39
40
41
42
43
44
45
46
47
48
49
50
51
52
53
54
55
56
57
58
59
60

For Peer Review

Patients & Methods

Selection of patients and study schedule

This was a prospective single centre study conducted in the Gastroenterology department of the Haut-Leveque Hospital (south-western France) from October 2007 to May 2009.

Eligible Crohn’s disease patients were consecutively recruited when they met the following criteria: age 18 years or more, previous diagnosis of luminal Crohn’s disease established on usual criteria including identification of mucosal ulcerations with ileo-colonoscopy, clinical remission off steroids within the last three months with a single immunomodulator (methotrexate or azathioprine or infliximab) as maintenance treatment at stable doses, requiring a colonoscopy based on usual indication in Crohn’s disease (dysplasia/cancer screening according to the recommendations from the French endoscopic society, suspected stenosis) excluding assessment for mucosal healing. Subjects with ulcerative colitis, indeterminate colitis, active luminal Crohn’s disease (CDAI>150), isolated ano-perineal location or ileal disease not assessable with colonoscopy were excluded.

Inclusion date was defined as that of colonoscopy which was routinely performed by three experienced gastroenterologists (D.L., E.C., C.S.) not blinded to the medications taken by the patients. Data were collected at inclusion and the following characteristics were recorded: date of birth, gender, disease duration, age at diagnosis, disease location and behavior according to the Montreal classification ¹⁷, perianal disease, extraintestinal manifestation, smoking history, previous history of intestinal surgery, previous response to steroids, clinical (CDAI) and biological (CRP level in mg/L) disease activity at baseline, past treatment with immunosuppressants and biologics, type of immunomodulator (methotrexate, azathioprine, infliximab) given as maintenance and duration of this treatment, indication for colonoscopic examination. Endoscopic and clinical data were available in all patients.

Biopsy samples were taken in the most inflamed areas and for the screening of dysplasia. Samples were fixed in formalin and embedded in paraffin, and 3µm thick sections were stained with HES. All biopsy specimens were analyzed independently by one experienced pathologist (G.B.) blinded to the treatment. The goal of this examination was to assess microscopic activity of Crohn's disease according to the Scoring System for Crohn's disease constructed by Geboes and adapted from D'Haens *et al*¹⁸. The most inflammatory lesions observed within the most inflamed area at colonoscopy were retained for scoring.

During the follow-up period, from inclusion to December 2009, Crohn's disease clinical relapse, defined as worsening of symptoms coupled with endoscopic, radiographic, and/or biological evidence of inflammation, was recorded.

All patients received treatment according to clinical need. Drugs used were those normally employed in Crohn's disease, according to licensed or published doses and frequency (parenteral methotrexate: 15-25 mg/week; azathioprine: 2-3 mg/kg/d; infliximab: 5 mg/kg/8weeks). All patients received treatment and had colonoscopy only after full and informed consent.

Outcomes and objectives

Mucosal healing was defined as the total disappearance of all mucosal ulcerations in all segments^{11, 12}. Two indices of endoscopic activity, the Crohn's Disease Endoscopic Index of Severity (CDEIS)¹⁹ and the Simple Endoscopic Score for Crohn's Disease (SES-CD)²⁰, were calculated at inclusion. Considering the CDEIS, two cut-off values were retained: <6 as endoscopic remission and <4 as complete mucosal healing¹⁰. Microscopic Crohn's disease activity was assessed with the Scoring System for Crohn's disease adapted from D'Haens *et al*, ranging from 1 (no activity) to 13 (table 1)¹⁸.

The primary objective of the study was to establish the proportion of mucosal healing in Crohn's disease patients with sustained remission by monotherapy with methotrexate, as compared to azathioprine or infliximab.

Secondary objectives were: i) to compare CDEIS and SES-CD in Crohn's patients in remission receiving methotrexate to those treated with azathioprine or infliximab; ii) to identify factors associated with mucosal healing; iii) to compare Crohn's disease microscopic activity in patients in remission with methotrexate to those receiving azathioprine or infliximab; iv) to look for an association between mucosal healing at baseline and relapse rate during follow-up.

Statistics

Continuous variables are presented as medians and range; categorical variables are presented as percentages. Continuous data were analysed using Mann-Whitney's test. Categorical data were analysed using the Pearson's chi-squared test, or Fisher's exact test if any cell number was <5, for frequencies. Pearson's coefficient of correlation (κ) and their probabilities (p) evaluated the relationship between CDEIS, SES-CD and microscopic Crohn's disease activity.

Analysis of predictive factors of mucosal healing was performed. Univariate and multivariate analyses were performed to assess impact of clinical, disease, and treatment variables on mucosal healing. Continuous variable were dichotomised according to the median. Variables analysed were age at inclusion, gender, disease duration, active tobacco smoking, Crohn's disease location and behaviour, associated perineal disease, extra-intestinal manifestations, previous intestinal resection, current treatment type and duration, indication for colonoscopy, CRP level (mg/L). Difference between mucosal healing and non-healing groups was assessed by χ^2 or Fisher's exact tests when appropriate. A logistic regression model was created using significantly associated variables ($p < 0.10$), and the odds ratios (OR) for the variables that

1
2
3 remained significant ($p < 0.05$) in the model determined. Considering complete mucosal
4
5 healing at baseline (CDEIS <4), relapse-free survival rates in relation to observation time were
6
7 estimated using Kaplan-Meier life-table method.
8
9
10
11
12
13
14
15
16
17
18
19
20
21
22
23
24
25
26
27
28
29
30
31
32
33
34
35
36
37
38
39
40
41
42
43
44
45
46
47
48
49
50
51
52
53
54
55
56
57
58
59
60

Results

Study population

During the study period, 1 796 consecutive colonoscopies were performed in the Gastroenterology department of the Haut-Leveque Hospital, including 266 in patients with Crohn’s disease. Two-hundred-and-fifteen patients were excluded: 161 with active disease, 49 in remission not treated with a single immunomodulator at stable dose within the last three months, and 5 in whom colonoscopy aimed to assess mucosal healing. Therefore, 51 patients met the inclusion criteria (38 women; median age: 42 years): 18 receiving methotrexate, 18 azathioprine, and 15 infliximab. Their main characteristics are presented in Table 2. There was no difference between the methotrexate group and the two others except regarding median treatment duration that was shorter with methotrexate as compared to azathioprine (24 and 57 months, respectively, $p=0.014$).

Mucosal healing

The primary objective of the study – complete disappearance of mucosal ulcerations – was achieved in 2/18 (11%) patients treated with methotrexate, in 9/18 (50%) with azathioprine ($p=0.011$ vs. methotrexate) and in 9/15 (60%) with infliximab ($p=0.008$ vs. methotrexate) (Figure 1). Considering the CDEIS, patients receiving methotrexate had a higher median value than those from the two other groups (5.5, range [0.5-11.2] with methotrexate, 1.5, range [0-9.4] with azathioprine – $p=0.002$ vs. methotrexate – and 1.2, range [0-23.6] with infliximab – $p=0.03$ vs. methotrexate). Individual CDEIS values are presented in Figure 2A. According to the pre-specified CDEIS cut-off for endoscopic remission, rates of patients with $CDEIS<6$ were 50% with methotrexate, 89% with azathioprine ($p=0.011$ vs. methotrexate) and 80% with infliximab ($p=0.074$ vs. methotrexate). With the cut-off for complete mucosal healing ($CDEIS<4$), rates were 39% with methotrexate, 83% with azathioprine ($p=0,006$ vs. methotrexate) and 67% with infliximab ($p=0,112$ vs. methotrexate).

The median SES-CD value was higher in patients receiving methotrexate as compared to the two other groups (6, range [2-18] with methotrexate, 3, range [0-16] with azathioprine – $p=0.008$ vs. methotrexate – and 2, range [0-27] with infliximab – $p=0.032$ vs. methotrexate). Individual values are shown in Figure 2B. The two indices of endoscopic activity - CDEIS and SES-CD – were closely correlated ($\kappa=0.927$; $p<0,001$).

In univariate analysis, factors associated with mucosal healing were treatment at baseline and Crohn's disease location. In multivariate analysis, three factors were positively associated with mucosal healing: current treatment with azathioprine (OR=7.13, 95% confidence interval (CI): [1.11-45.68] vs. methotrexate), current treatment with infliximab (OR=19.02, 95%CI [2.49-145.52] vs. methotrexate), and pure ileal disease (OR=5.77, 95%CI [1.27-26.28] vs. ileo-colonic location; Table 3).

Histological response

Biopsy samples were available for 40 patients (12 methotrexate, 14 azathioprine, and 14 infliximab). Considering microscopic activity, no significant difference was observed between patients receiving methotrexate (median 2.5, range [1-12]) and those treated with azathioprine (3, range [0-11]; $p=0.622$) infliximab (3.5, range [0-12]; $p=0.583$). No correlation was found between microscopic inflammation and CDEIS (Pearson's coefficient: 0.154; $p=0.344$) or SES-CD.

Follow-up

During the follow-up period (median duration: 13.2 months, range [0-25.2]), 8 patients experienced Crohn's disease relapse with a median time of 4 months, range [0-23] (one patient without mucosal healing was lost to follow-up just after the inclusion and was considered to have relapsed at baseline). All but one had endoscopic ulcerations at entry. The last patient with mucosal healing at baseline experienced Crohn's disease worsening 23 months after inclusion. Relapse rates at 6, 12 and 24 months were 9.8%, 12.1% and 23.9%,

1
2
3
4
5
6
7
8
9
10
11
12
13
14
15
16
17
18
19
20
21
22
23
24
25
26
27
28
29
30
31
32
33
34
35
36
37
38
39
40
41
42
43
44
45
46
47
48
49
50
51
52
53
54
55
56
57
58
59
60

respectively. Considering complete mucosal healing at baseline according to CDEIS cut-off, patients with CDEIS<4 experienced fewer relapses during the follow up period than patients with CDEIS≥4 at entry (Figure 3).

For Peer Review

Discussion

Until recently, symptom improvement has been considered as the main therapeutic issue in Crohn's disease. With the advent of biologics, new objectives have been determined: mucosal healing, bowel damage, disability or surgical and hospitalisation rates²¹. Mucosal healing has become an endpoint in clinical trials and emerges as a desirable goal in current practice²². However, endoscopic response to conventional Crohn's disease treatments has been less studied than with anti-TNFs. When considering methotrexate, the efficacy of which has been proven in controlled trials^{23, 24}, little is known about its ability to heal inflammatory lesions^{15, 16}. In this prospective study conducted in Crohn's disease patients with sustained clinical remission, complete healing of endoscopic ulcerations was observed in 11% of methotrexate-treated patients. This rate was significantly lower compared to patients receiving monotherapy with azathioprine or infliximab: 50% and 60%, respectively.

Although mucosal healing is an important goal of treatment in Crohn's disease, no recognized definition exists. The disappearance of all mucosal ulcerations defined mucosal healing in controlled studies^{11, 12}, and should be very simple in practice. However, this binary outcome – healed-not healed – does not reflect the great variety of endoscopic signs of Crohn's disease activity, and two endoscopic quantitative scoring systems are available at this time. Firstly, the Crohn's disease endoscopic index of severity (CDEIS) has been prospectively established in order to detect changes in disease activity¹⁹. It has been validated as a reproducible index. Despite its complexity and the learning curve required, the CDEIS is considered as the gold standard for classifying severity of disease. Furthermore, two cut-offs defining endoscopic remission and complete mucosal healing have been proposed¹⁰. Secondly, the simple endoscopic score for Crohn's disease (SES-CD) correlates well with the CDEIS²⁰ and has been validated. No threshold defining remission has been established at this time.

Although the series reported here involved a modest number of patients, mucosal healing rates observed with azathioprine and infliximab are comparable to that previously published in patients in clinical remission with these drugs ^{3, 25}. Therefore, the small number of patients endoscopically healed with methotrexate in the same setting illustrates probably a lower mucosal efficacy of this drug. However, a more refractory Crohn's disease in patients receiving methotrexate cannot be excluded. Indeed, 78% previously received azathioprine which was discontinued because of failure or intolerance, and 83% infliximab. One can argue that this discrepancy can also be related to the treatment duration, which was shorter with methotrexate as compared to azathioprine. Nevertheless, duration of treatment was not associated with mucosal healing in the multivariate analysis. Furthermore, Crohn's disease inflammatory lesions seem to heal rapidly as suggested in a recent study with adalimumab showing similar endoscopic rates of response after 12 and 52 weeks of treatment. In the same study, shorter Crohn's disease duration was related to better endoscopic response ¹¹. This correlation was not confirmed in the current study, even if there was a trend for longer disease duration in patients treated with azathioprine and infliximab as compared to those receiving methotrexate.

Methotrexate is a folate anti-metabolite used at low doses in many inflammatory disorders. In Crohn's disease, it is usually proposed after azathioprine failure or intolerance as a second-line immunosuppressant ²⁶⁻²⁹. Indeed, methotrexate has been shown to have a steroid-sparing effect ²³ and this compound could provide prolonged remission ^{28, 30}. Although the duration of treatment is not defined, two main reasons can lead to discontinue the drug. Firstly, the long-term duration of treatment with methotrexate may expose patients to side effects related to high cumulative doses leading then to withdrawal ^{28, 30}. Secondly, an increasing proportion of patients become methotrexate-refractory with time ^{28, 30, 31}. This secondary loss of response to methotrexate could be related to partial efficacy of the drug, characterized by symptom relief

without complete mucosal healing, as suggested here. The route of administration probably cannot explain the low rate of complete endoscopic healing observed as all the included patients were treated parenterally (sub-cutaneous and/or intra-muscular). In the same way, the dosage used in the present study was the regimen proven to be effective as maintenance in Crohn's disease (15-25 mg/week) ²⁶. However, we cannot exclude that higher methotrexate doses may promote better endoscopic response.

Overall, the disappearance of all mucosal ulcerations is probably uncommon with methotrexate. However, it does not imply that methotrexate exerts no effect on gut mucosa. Considering the CDEIS, which is more quantitative and a less stringent criterion than the complete disappearance of all ulcerations, more than half of patients receiving methotrexate achieved Crohn's disease endoscopic remission. Moreover, whatever endoscopic tool used for mucosal healing assessment, the discrepancy observed between patients receiving methotrexate and those treated with azathioprine or infliximab was mostly due to the persistence of few ulcerations. Prospective studies are now required to determine if methotrexate is able to induce and maintain Crohn's disease endoscopic improvement.

Histology is an established procedure for the diagnosis of Crohn's disease. Nevertheless, the evolution of the microscopic intestinal features has been poorly investigated and there is a lack of data regarding histological response to the main medications used in Crohn's disease. Some changes have been observed, mainly on signs of mucosal injury and the presence of neutrophils ³², and in a small placebo-controlled study, significant histological improvement due to the disappearance of the inflammatory infiltrate was seen after a single infliximab infusion ¹⁸. Moreover, the correlation between clinical and endoscopic findings with histology is a matter of debate ³². In the present study which enrolled patients in clinical remission, endoscopic and histologic activities were not correlated. Furthermore, there is no validated and standardized microscopic scoring system for Crohn's disease. Targeting mucosal

1
2
3
4
5
6
7
8
9
10
11
12
13
14
15
16
17
18
19
20
21
22
23
24
25
26
27
28
29
30
31
32
33
34
35
36
37
38
39
40
41
42
43
44
45
46
47
48
49
50
51
52
53
54
55
56
57
58
59
60

inflammation to achieve histological healing could be a greater objective than mucosal healing in Crohn’s disease²² and should be explored in future prospective studies.

Mucosal healing is an important issue in Crohn’s disease patients and can probably predict the course of disease, as observed in the present study. Using quantitative measures such as CDEIS, methotrexate appears less effective than azathioprine or infliximab to heal the gut mucosa. However, further prospective studies have now to determine if this compound is able to induce a significant improvement of Crohn’s disease bowel lesions, not only on the mucosal side but also on the entire gut wall in this transmural disease.

Financial support: None.

Potential competing interests: David Laharie has acted as speaker for, and has received research support from Schering-Plough.

For Peer Review

References:

1. Solberg IC, Vatn MH, Hoie O, *et al.* Clinical course in Crohn's disease: results of a Norwegian population-based ten-year follow-up study. *Clin Gastroenterol Hepatol* 2007;5:1430-8.
2. Modigliani R, Mary JY, Simon JF, *et al.* Clinical, biological, and endoscopic picture of attacks of Crohn's disease. Evolution on prednisolone. Groupe d'Etude Therapeutique des Affections Inflammatoires Digestives. *Gastroenterology* 1990;98:811-8.
3. Rutgeerts P, Diamond RH, Bala M, *et al.* Scheduled maintenance treatment with infliximab is superior to episodic treatment for the healing of mucosal ulceration associated with Crohn's disease. *Gastrointest Endosc* 2006;63:433-42.
4. Froslic KF, Jahnsen J, Moum BA, *et al.* Mucosal healing in inflammatory bowel disease: results from a Norwegian population-based cohort. *Gastroenterology* 2007;133:412-22.
5. Schnitzler F, Fidder H, Ferrante M, *et al.* Mucosal healing predicts long-term outcome of maintenance therapy with infliximab in Crohn's disease. *Inflamm Bowel Dis* 2009;15:1295-301.
6. Baert F, Moortgat L, Van Assche G, *et al.* Mucosal healing predicts sustained clinical remission in patients with early-stage Crohn's disease. *Gastroenterology* 2010;138:463-8; quiz e10-1.
7. Louis E, Vernier-Massouille G, Grimaud JC, *et al.* Infliximab discontinuation in Crohn's disease patients in stable remission on combined therapy with immunosuppressors: interim analysis of a prospective cohort study. *Gut* 2008;57:A66.
8. Allez M, Lemann M, Bonnet J, *et al.* Long term outcome of patients with active Crohn's disease exhibiting extensive and deep ulcerations at colonoscopy. *Am J Gastroenterol* 2002;97:947-53.

- 1
2
3 9. Peyrin-Biroulet L, Deltenre P, de Suray N, *et al.* Efficacy and safety of tumor necrosis
4 factor antagonists in Crohn's disease: meta-analysis of placebo-controlled trials. Clin
5 Gastroenterol Hepatol 2008;6:644-53.
6
7
8
9
- 10 10. Hebuterne X, Colombel JF, Bouhnik Y, *et al.* Endoscopic improvement in patients
11 with active Crohn's disease treated with certolizumab pegol: first results of the MUSIC
12 clinical trial. Gut 2008;57 (Suppl. 2):A-15.
13
14
15
16
- 17 11. Rutgeerts P. Adalimumab induces and maintains mucosal healing in patients with
18 moderate to severe ileocolonic Crohn's disease. First results of the EXTEND trial.
19 Gastroenterology 2009;136 (suppl. 1):A-116.
20
21
22
23
- 24 12. Colombel JF, Sandborn WJ, Reinisch W, *et al.* Infliximab, azathioprine, or
25 combination therapy for Crohn's disease. N Engl J Med 2010;362:1383-95.
26
27
28
- 29 13. Sandborn WJ, Van OE, Zins BJ, *et al.* An intravenous loading dose of azathioprine
30 decreases the time to response in patients with Crohn's disease. Gastroenterology
31 1995;109:1808-17.
32
33
34
35
- 36 14. D'Haens G, Geboes K, Ponette E, *et al.* Healing of severe recurrent ileitis with
37 azathioprine therapy in patients with Crohn's disease. Gastroenterology 1997;112:1475-81.
38
39
40
- 41 15. Kozarek RA, Patterson DJ, Gelfand MD, *et al.* Methotrexate induces clinical and
42 histologic remission in patients with refractory inflammatory bowel disease. Ann Intern Med
43 1989;110:353-6.
44
45
46
47
- 48 16. Manosa M, Naves JE, Leal C, *et al.* Does methotrexate induce mucosal healing in
49 Crohn's disease? Inflamm Bowel Dis 2010;16:377-8.
50
51
52
- 53 17. Satsangi J, Silverberg MS, Vermeire S, *et al.* The Montreal classification of
54 inflammatory bowel disease: controversies, consensus, and implications. Gut. 2006;55:749-
55
56
57
58 53.
59
60

18. D'Haens G, Van Deventer S, Van Hogezaand R, *et al.* Endoscopic and histological healing with infliximab anti-tumor necrosis factor antibodies in Crohn's disease: A European multicenter trial. *Gastroenterology* 1999;116:1029-34.
19. Mary JY, Modigliani R. Development and validation of an endoscopic index of the severity for Crohn's disease: a prospective multicentre study. Groupe d'Etudes Therapeutiques des Affections Inflammatoires du Tube Digestif (GETAID). *Gut* 1989;30:983-9.
20. Daperno M, D'Haens G, Van Assche G, *et al.* Development and validation of a new, simplified endoscopic activity score for Crohn's disease: the SES-CD. *Gastrointest Endosc* 2004;60:505-12.
21. Rutgeerts P, Vermeire S, Van Assche G. Biological therapies for inflammatory bowel diseases. *Gastroenterology* 2009;136:1182-97.
22. Pineton de Chambrun G, Peyrin-Biroulet L, Lemann M, *et al.* Clinical implications of mucosal healing for the management of IBD. *Nat Rev Gastroenterol Hepatol* 2010;7:15-29.
23. Feagan BG, Rochon J, Fedorak RN, *et al.* Methotrexate for the treatment of Crohn's disease. The North American Crohn's Study Group Investigators. *N Engl J Med.* 1995;332:292-7.
24. Feagan BG, Fedorak RN, Irvine EJ, *et al.* A comparison of methotrexate with placebo for the maintenance of remission in Crohn's disease. North American Crohn's Study Group Investigators. *N Engl J Med.* 2000;342:1627-32.
25. Lemann M, Mary JY, Colombel JF, *et al.* A randomized, double-blind, controlled withdrawal trial in Crohn's disease patients in long-term remission on azathioprine. *Gastroenterology* 2005;128:1812-8.
26. Patel V, Macdonald JK, McDonald JW, *et al.* Methotrexate for maintenance of remission in Crohn's disease. *Cochrane Database Syst Rev* 2009:CD006884.

- 1
2
3 27. Dignass A, Van Assche G, Lindsay JO, *et al.* The second European evidence-based
4 consensus on the diagnosis and management of Crohn's disease: current management. J Crohn
5 Colitis 2010;4:28-62.
6
7
8
9
10 28. Hausmann J, Zabel K, Herrmann E, *et al.* Methotrexate for maintenance of remission
11 in chronic active Crohn's disease: long-term single-center experience and meta-analysis of
12 observational studies. Inflamm Bowel Dis 2010;16:1195-202.
13
14
15 29. Ng SC, Chan FK, Sung JJ. Review article: the role of non-biological drugs in
16 refractory inflammatory bowel disease. Aliment Pharmacol Ther 2010.
17
18
19
20
21 30. Lemann M, Zenzari T, Bouhnik Y, *et al.* Methotrexate in Crohn's disease: long-term
22 efficacy and toxicity. Am J Gastroenterol 2000;95:1730-4.
23
24
25 31. Roumeguere P, Bouchard D, Pigot F, *et al.* Combined approach with infliximab,
26 surgery, and methotrexate in severe fistulizing anoperineal Crohn's disease: Results from a
27 prospective study. Inflamm Bowel Dis 2010.
28
29
30
31
32 32. Geboes K, Dalle I. Influence of treatment on morphological features of mucosal
33 inflammation. Gut 2002;50 Suppl 3:III37-42.
34
35
36
37
38
39
40
41
42
43
44
45
46
47
48
49
50
51
52
53
54
55
56
57
58
59
60

1
2
3
4
5
6
7
8
9
10
11
12
13
14
15
16
17
18
19
20
21
22
23
24
25
26
27
28
29
30
31
32
33
34
35
36
37
38
39
40
41
42
43
44
45
46
47
48
49
50
51
52
53
54
55
56
57
58
59
60

Figure legends

Figure 1: Mucosal healing rates (%) in Crohn’s disease patients in sustained remission with methotrexate, azathioprine and infliximab monotherapy.

Figure 2: Endoscopic activity in Crohn’s disease patients in remission with maintenance monotherapy considering the Crohn’s Disease Endoscopic Index of Severity (CDEIS) ¹⁹ (A) and the Simple Endoscopic Score for Crohn’s Disease (SES-CD) ²⁰ (B). Thick points indicate values for individual patients, the wide horizontal line indicates median value.

Figure 3: Kaplan-Meier curves of survival without relapse according to complete mucosal healing ¹⁰ at baseline. Continuous line: CDEIS<4; discontinuous line: CDEIS≥4

Table 1 Microscopic Crohn's disease activity according to the Scoring System for Crohn's disease adapted from D'Haens *et al*¹⁸.

Histological variable	Grading
Epithelial damage	0 = normal; 1 = focal; 2 = extensive
Architectural changes	0 = normal; 1 = moderate; 2 = severe
Mononuclear cells in lamina propria	0 = normal; 1 = moderate increase; 2 = severe increase
Polymorphonuclear cells in lamina propria	0 = normal; 1 = moderate increase; 2 = severe increase
Neutrophils in epithelium	1 = surface epithelium; 1 = cryptitis; 2 = crypt abscess
Erosion or ulceration	0 = no; 1 = yes
Granuloma	0 = no; 1 = yes

Table 2 Main characteristics of the 51 patients included in the study according to the maintenance therapy (methotrexate, azathioprine, or infliximab).

	Methotrexate	Azathioprine	Infliximab
n	18	18	15
Median age, years [range]	40 [21-56]	48 [21-89]	46 [30-79]
Male gender, n (%)	3 (17)	6 (33)	4 (27)
Median disease duration, years [range]	9.1 [1.1-29.5]	12.9 [6.5-27.7]	10.8 [5.8-29.8]
Disease location, n (%)			
ileal	1 (5)	2 (11)	0
colonic	7 (39)	10 (56)	7 (47)
ileo-colonic	10 (56)	4 (33)	8 (53)
Perianal disease, n (%)	8 (44)	11 (73)	11 (61)
Current smoker, n (%)	7 (39)	3 (18)	7 (47)
Previous intestinal resection, n (%)	9 (50)	8 (44)	5 (33)
Previous treatments, n (%)			
AZA/6-MP	14 (78)	NA	11 (73)
Methotrexate	NA	0	7 (47)
IFX	15 (83)	11 (61)	NA
Median duration of current treatment, months [range]	24 [7-92]	57 [19-115]*	28 [12-90]
Median CRP level, mg/L [range]	0 [0-87]	0 [0-13]	0 [0-27]
Indication for colonoscopy, n (%)			
Screening for dysplasia	12 (67)	14 (78)	15 (100)
Suspected stenosis	6 (33)	4 (22)	0

*: p=0.014 as compared to the methotrexate group

Other differences between the methotrexate group and the others are not significant.

Table 3: Factors associated with mucosal healing in multivariate analysis (logistic regression)

	OR	95% CI	p
Infliximab <i>vs.</i> methotrexate	19.02	2.49-145.52	0.005
Azathioprine <i>vs.</i> methotrexate	7.13	1.11-45.68	0.038
Ileal location <i>vs.</i> ileocolonic	5.77	1.27-26.28	0.024

Figure 1

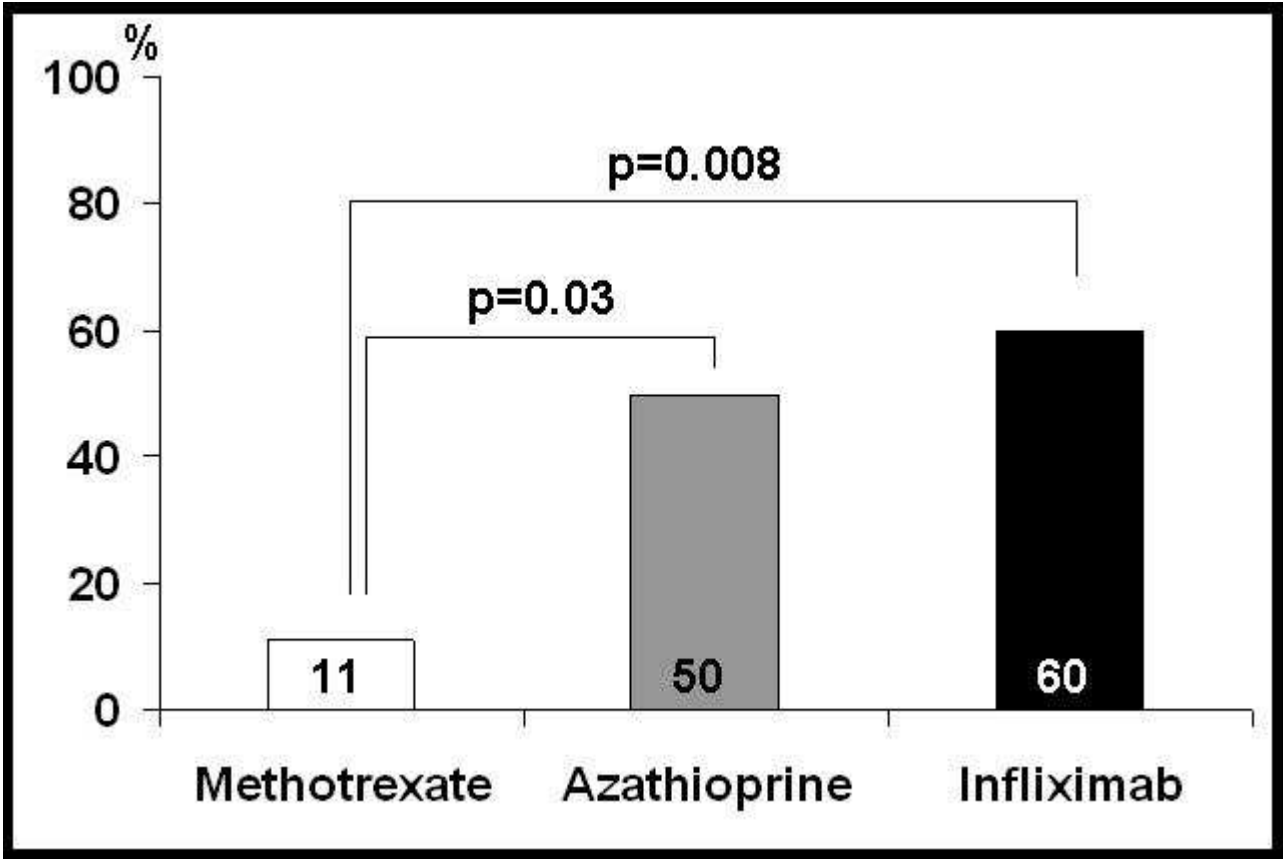


Figure 2A

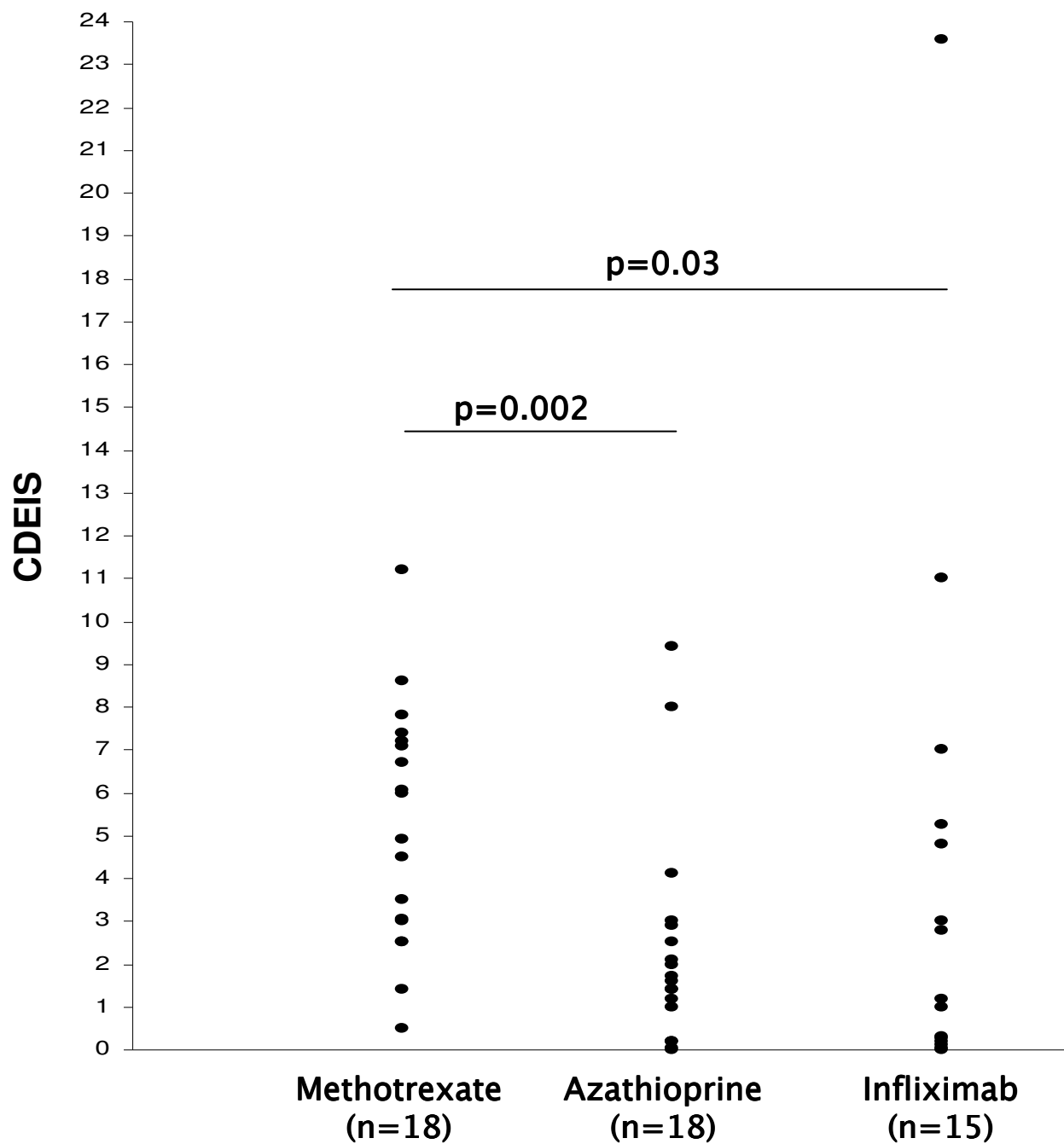


Figure 2B

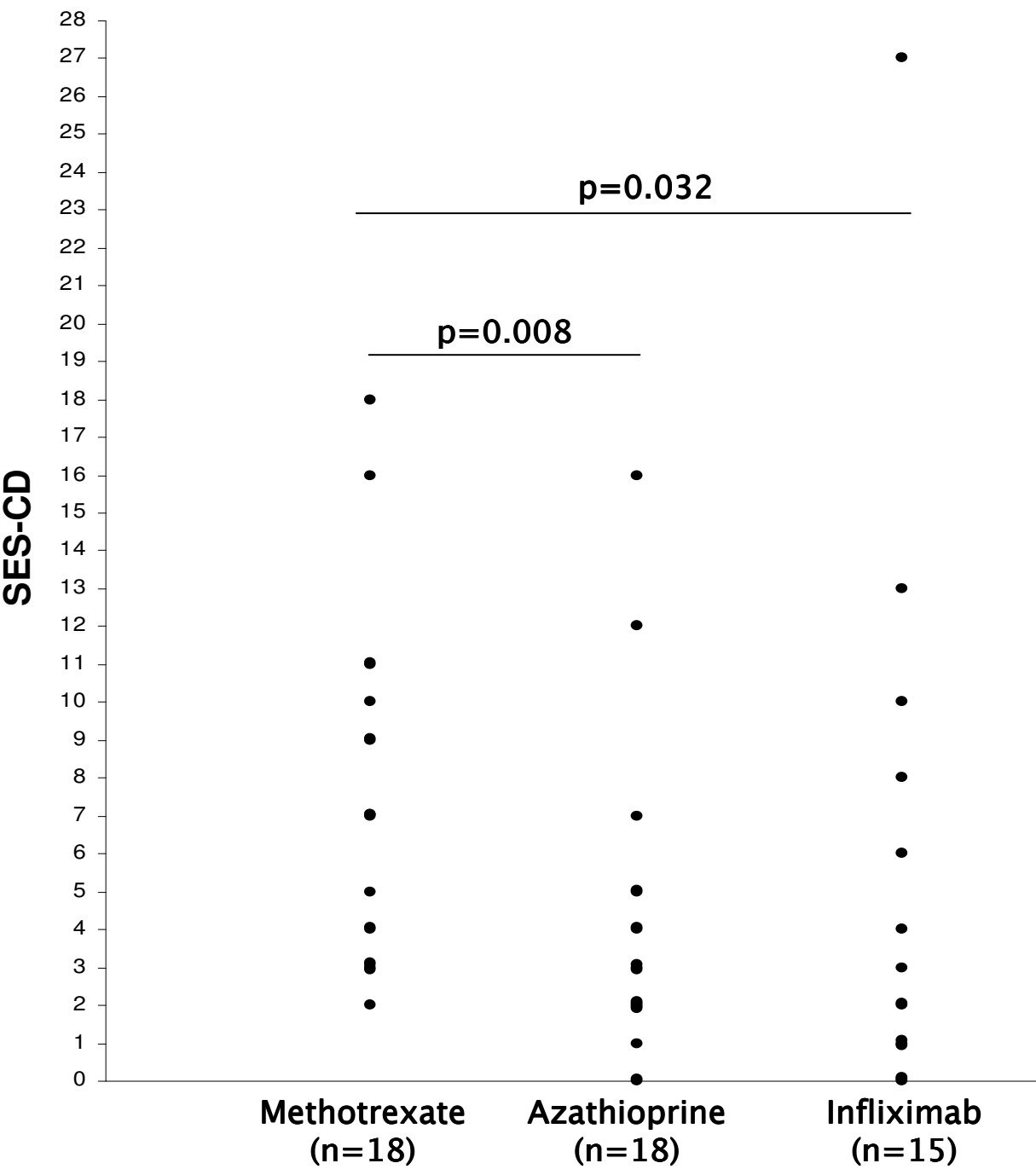


Figure 3

