



HAL
open science

Chan-Vese based method to segment mouse brain MRI images: application to cerebral malformation analysis in trisomy 21

Ahmad Almhdie, Patricia Lopes-Pereira, Sandra Môme, Caroline Colombier, Veronique Brault, Frédéric Szeremeta, Bich-Thuy Doan, Roger Lédée, Rachid Harba, Yann Hérault, et al.

► **To cite this version:**

Ahmad Almhdie, Patricia Lopes-Pereira, Sandra Môme, Caroline Colombier, Veronique Brault, et al.. Chan-Vese based method to segment mouse brain MRI images: application to cerebral malformation analysis in trisomy 21. Eusipco 2009, Aug 2009, Glasgow, United Kingdom. hal-00608092

HAL Id: hal-00608092

<https://hal.science/hal-00608092v1>

Submitted on 12 Jul 2011

HAL is a multi-disciplinary open access archive for the deposit and dissemination of scientific research documents, whether they are published or not. The documents may come from teaching and research institutions in France or abroad, or from public or private research centers.

L'archive ouverte pluridisciplinaire **HAL**, est destinée au dépôt et à la diffusion de documents scientifiques de niveau recherche, publiés ou non, émanant des établissements d'enseignement et de recherche français ou étrangers, des laboratoires publics ou privés.

Chan-Vese based method to segment mouse brain MRI images: application to cerebral malformation analysis in trisomy 21

Ahmad Almhdie^{1,*}, Patricia Lopes-Pereira², Sandra Mème³, Caroline Colombier²,
Véronique Brault², Frédéric Szeremeta³, Bich-Thuy Doan³, Roger Lédée¹,
Rachid Harba¹, Yann Héroult², Jean-Claude Belœil³, Christophe Léger¹

¹PRISME, Université d'Orléans, France, ²IEM, UMR 6218, CNRS, Orléans, France, ³CBM, UPR4301, CNRS, Orléans, France
*corresponding author, phone: + (33) 238 49 45 34, fax: + (33) 238 41 72 45, email: ahmad.almhdie@univ-orleans.fr

ABSTRACT

In this paper, a semi automatic active contour method based on Chan-Vese model is proposed for the segmentation of mouse brain MR images. First, a 2 1/2 D strategy is applied on the axial images to segment the 3D volume of interest. The method takes into account the special shape of the object to segment. Moreover, the user defines the limits where to search these contours and also provides an initial contour. This semi automatic method makes that human intervention is limited and the tedious manual handling is greatly reduced. Results have shown that the brain volumes estimated by the method are identical to expert manually estimated volumes. Last but not least, the new method was used in the analysis of the cerebral malformations linked to Trisomy 21: no significant difference of the brain volumes between Trisomy 21 mice and the control ones were found.

1. INTRODUCTION

This work is a part of a project granted by the French Region Centre which associates 3 laboratories of the city of Orléans, France. The project aims to a better understanding of the morphological malformations of the brain associated to Trisomy 21 or Down syndrome. Characterization of morphological malformations associated to trisomic mouse models for particular chromosome segments will help to link genes from these segments to specific dysmorphologies. It would also help to look after the consequences of this disease, and to improve the quality of life of the patients.

For this purpose, models of trisomic animals are usually of interest. Among various animals that can fit the study, mouse are often chosen since 80% of the genome is common with that of the Human. In addition, mice are easy to breed. For such studies, 3D images of the mouse brain must be analysed. One of the main strengths of MRI compared to other imaging techniques (optical, PET, CT, ultrasound,...) is the ability to obtain not only anatomical images in 3 dimensions but also functional information with the implementation of new methods of imaging (fMRI, diffusion, perfusion, imaging of chemical shift, imaging with contrast agents...). For this reason, MRI images will be used in our study.

3D mouse brain MRI images must be segmented in order to extract the brain itself. For the moment, most of biologists working in this domain perform a manual segmentation of these 3D data. For that reason, an automatic or semi automat-

ic method is needed. Consequently, human intervention will be limited and the tedious manual handling will be greatly reduced. Even if *a priori* information is taken into account, and even if the brain is surrounded by the cerebrospinal fluid, the automatic segmentation of 3D mouse brain MRI images is a difficult issue since the contrast between different objects in the brain is low. A semi automatic technique that could consider information given by the user could be more efficient and less complicated to develop. A good review of current medical image segmentation methods can be found in [1]. For the segmentation process itself, a Chan-Vese based approach of active contour [2], which is efficient in the case when image edges are not well defined, seems to be well adapted for our application.

In this work, we propose a semi automatic Chan-Vese active contour based method to segment mouse brain MRI images. The method includes some *a priori* information and takes into account user knowledge.

This paper is organized as follow. First, the material will be presented, i.e., the production of trisomic mouse models, and the acquisition of related 3D MRI brain images. Section 3 will describe the method. Next sections present the results and some perspectives. Concluding remarks are drawn in the final section.

2. MATERIAL

Trisomic mouse models: Different mouse models have been created to elucidate genetic pathways implicated in specific clinical aspect of the trisomy 21 pathology (Figure 1). In addition to the Tc1 model which corresponds to a mouse line carrying an additional quasi-complete copy of HSA21 [3], four other models are trisomies of counterparts regions of chromosome 21 carried by the mouse chromosome 16 (MMU16; MMU for Mus musculus): Ts1Yu, Ts65Dn, Ts1Cje, Ts1Rhr. Two other models, named Ts1Yah and Ts2Yah, have recently been created by the team of Yann Héroult at the IEM laboratory in Orleans. They are trisomic respectively for the part of the chromosome 21 counterpart region on MMU16 absent from the Ts65Dn model and for the chromosome 21 counterpart region in MMU17. Analyses of these different models have revealed alterations of the cerebral and cranial development. Skull and brain defects were mainly analyzed in the Tc1, Ts65Dn, Ts1Cje and Ts1Rhr models and are discussed in [4-6]. It was shown that

Ts65Dn mice have a reduced number of granule cells in the cerebellum and the hippocampus. When considering cerebellum, this reduction is accompanied by a decrease in the cerebellum size which is visible during postnatal development. No study has been made on the recently published Ts1Yu model [7]. The main conclusion from these studies was that the brain and skull defects observed in these models cannot be directly associated to one gene or to a chromosomal segment, but suggests that interactions between several genes throughout the chromosome 21 are responsible for the dysmorphologies seen in Down syndrome patients. Further studies are yet needed with new trisomic models for chromosomal segments that have not yet been studied such as in the Ts1Yah and Ts2Yah models in order to determine the importance of each trisomic region to the complete phenotype.

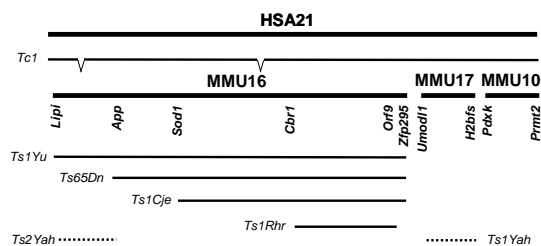


Figure 1 – Mouse models of the Trisomy 21.

Figure 1 gives a schematic representation of the mouse models available. Human chromosome 21 (HSA21 for Homo Sapiens) is shown on top with a bold line with the graph of the Tc1 mouse line. The corresponding homologous regions in the mouse region are indicated labelled as MMU16, MMU17 and MMU10 with genes located at the borders. Respective position of the mouse models, Ts1Yu, Ts65Dn, Ts1Cje and Ts1Rhr are indicated with a black line. New models, Ts1Yah and Ts2Yah are shown with a dashed line.

In order to further explore the role of each trisomic segment on brain patterning, we will analyse 3D reconstructions of MRI images of brains from Ts1Yah, Ts2Yah and control mice. 5 individuals of each group will be produced by taking adult animals of similar age, sex and genetic background. A contrast agent will be injected to the mice before cerebral MRI imaging, following the protocol already approved by the ethics committee (Decision CL2006-027 granted to Yann Héroult) for preliminary experiments which were conducted in order to define the best experimental conditions for the acquisition of images.

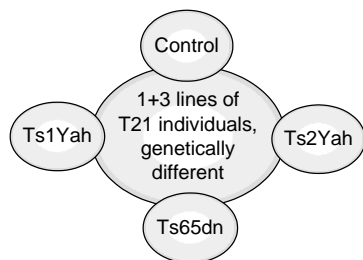


Figure 2 – Considered mouse brain models

Cerebral MRI imagery of the small animal: One of the main strengths of MRI compared to other imaging techniques (optical, PET, CT, ultrasound, etc...) is the ability to obtain not only anatomical images in 3 dimensions but also functional information with the implementation of new methods of imaging (fMRI, diffusion, perfusion, imaging of chemical shift, imaging with contrast agents etc. ...). However, one of the major limitations of MRI is its low sensitivity. To overcome this defect, it is possible today to use increasingly intense static magnetic fields. Nevertheless, the increase in the magnetic field increases the sensitivity to the effects of magnetic susceptibility and reduces the natural contrast between different tissues. Thus, one of the research objectives in MRI today is to propose new methodological, technological and instrumental developments to improve the contrast, sharpness, speed and spatial resolution at high field. So, the search for new contrast agents of contrast more adapted to the intense magnetic fields will allow the IRM to have a better specificity. For example, the Manganese ion Mn^{2+} has paramagnetic properties leading to an enhancement of the MRI signal [8-10]. In this work, the MR experiments were performed using Manganese Mn^{2+} as contrast agent within the framework of a cerebral application in order to carry out the quantitative and qualitative follow-up of the impact of the trisomy of certain regions of the chromosome in small animal models of the disease. Several experiments were conducted to obtain images with high spatial resolution ($118.2 \times 88.5 \times 118.2 \mu m^3/voxel$) with many details of the neuro-architecture, thanks to the power of the magnetic field and imaging gradient available on the used imaging system, first of its kind in France. Figure 3 shows a 3D image ($110 \times 341 \times 110$ voxels) as a result of one of these experiments.

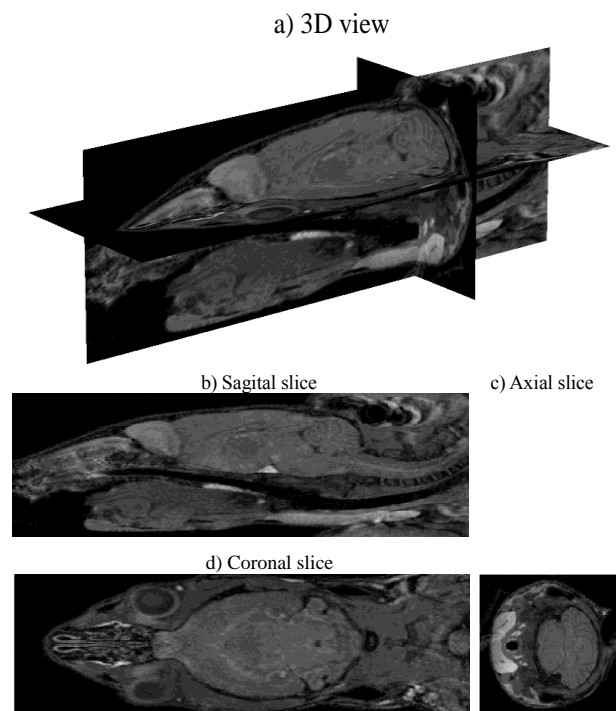


Figure 3 – An example of a resulting 3D image and its related slices

This MRI method is complementary to the technique of classical histology. It opens the possibility of obtaining simultaneous orthogonal or oblique cuts, the segmentation, the reconstruction, as well as volume estimations, in non-destructive and reproducible way.

MRI experiments were carried out on a spectrometer 9.4T/21 USR Biospec (Bruker, Wissembourg, France) using a stereotaxic setup. The mice were anaesthetized with isoflurane (1.5-2.5%) in an O₂/N₂O 1:1 mixture. Breath and temperature physiological parameters were monitored throughout the experiment. 3D FLASH experiments were recorded using, TR= 150 ms, $\alpha = 60^\circ$, duration 2h.

3. METHOD

Remember that we aim at developing a semi automatic segmentation for 3D mouse brain MR images. We will also take into account the *a priori* information relative to the specificity of the treated images, and will use some information given by the user. This strategy is explained in the following paragraphs.

Due to the elongated shape of the mouse brain, we have chosen a 2 ½ D contour detection based on axial slices. On axial slices, the brain mostly appears as a round shape that will be easier to detect (Figure 3c), compared to the other two sections (Figure 3b and 3d). First, the user determines the starting and ending point of the brain. The search of contours in the axial slices is limited in the region where the brain is present.

After that step, the contours of the brain in the initial axial slice are estimated using a Chan-Vese based approach of active contour segmentation [1]. Exhaustive tests, not reported here, have confirmed the superiority of the Chan-Vese approach compared to other methods for our application. Since Chan-Vese method requires an initial contour, an initial ellipse that best fits the desired organ is positioned by the user. These two tasks (determining the starting and the ending slices, and positioning the initial ellipse) are the only manual interventions of the user. By this way, human intervention is limited, which reduces the tedious manual handling.

Even if the brain is surrounded by the cerebrospinal fluid that makes this segmentation not too complex, some difficulties arise when using the Chan-Vese method. The contours given by the Chan-Vese method are not only the correct ones, but others are also detected. To overcome this difficulty we propose the following method. Since we know that the correct contour is a long one, a Mathematical Morphology method operation (a closing) is used on binarized level set images. As a result, small contours disappear. We also know that the right contour is close to the initial contour. Therefore, we only retain the contour which is the closest to the initial one. At this point, the processing of the initial slice is over.

Next slice is then considered. Using as initialization the contour found in the previous image, the contour of the next image is rapidly detected. This process is iterated until the limit given by the user is reached.

The precise strategy is detailed and illustrated in the following.

Initialisation: we shall follow the Chan-Vese model. Let u : be the original image of an axial slice to be segmented, and φ be its corresponding level set function, where: $\varphi > 0$ inside the contour, $\varphi < 0$ outside the contour, $\varphi = 0$ on the contour. Figure 4 shows a typical example of the level set function expressed in terms of a signed distance function to the original contour initiated by an ellipse that best fits the desired organ. This ellipse is given by the user.

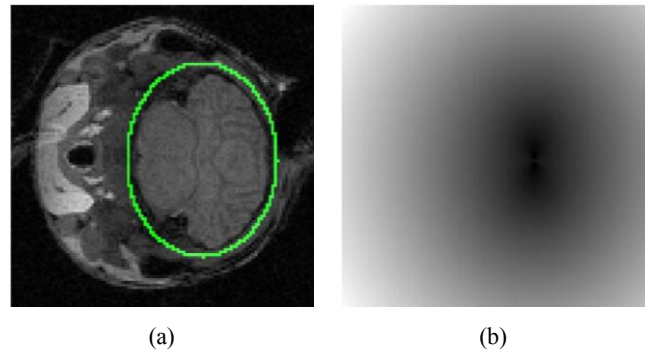


Figure 4 – an example of initial contour (a) and the corresponding level set image (b).

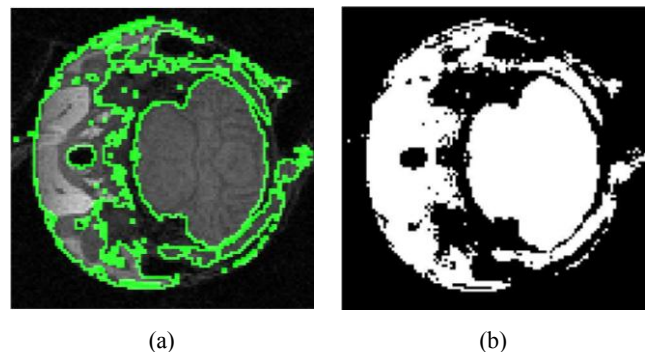


Figure 5 – Chan-Vese contours (a) and its binarized level set image (b).

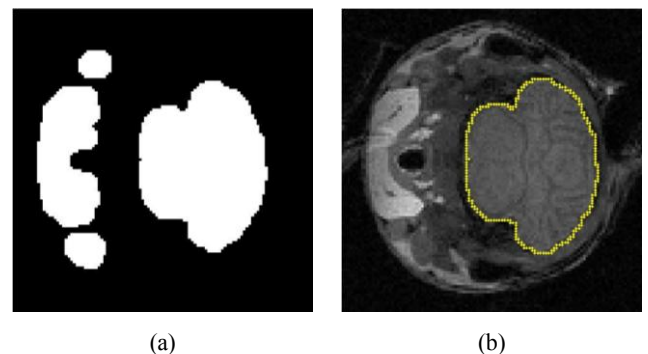


Figure 6 – Level set binarised image after closing (a) and final resulting contour (b).

Contour detection: the Chan-Vese method is used to detect the contour in the axial slice. This step will also produce a level set image. This level set image is binarized with a threshold equal to zero as illustrated in Figure 5.

Contour selection: since the segmentation is based on level set formulation, multiple contours could result. Hence, contour selection is preceded by firstly applying a morphological closing to the binarised level set image to separate attached contours. The structuring element is 5×5 pixels. As show in Figure 6, the closest contour to the initial ellipse is then chosen.

This process is iterated until the limit fixed by the user is reached. The user only defines the original ellipse and the range of search of the various contours.

An example is presented in Figure 7 for the 3 slices of Figure 3, whereas Figure 8 presents the volume of the detected brain structure.

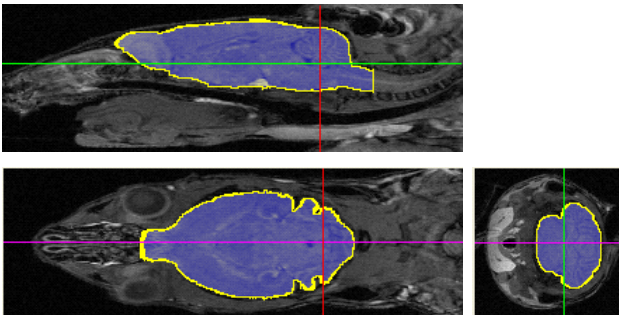


Figure 7 – three orthogonal sections, after final segmentation.

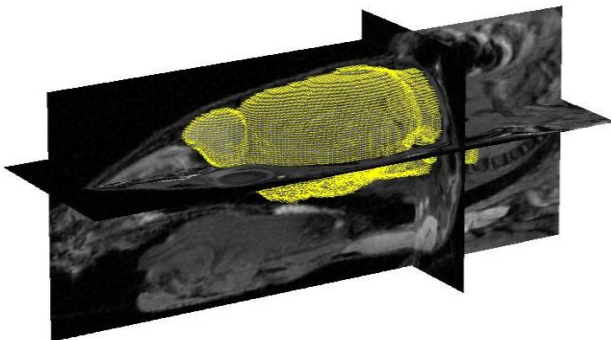


Figure 8 – 3D visualisation of the segmented brain.

4. RESULTS

When a user manually determines the brain volume, the processing time is of about 4 hours. Our semi automatic process reduces the time to about 15 minutes. This is a quite interesting time reduction. In the following, two additional results are given.

We first compare the estimated brain volume by our semi automatic method to manually estimated volumes measured by an expert using the OsiriX[®] software. In this study, 15 mice were considered: 5 controls, 5 TS2Yah and 5 TS2Yah

trisomic models (see section 2 for details). Results are shown in Table 1, Table 2 and Table 3, respectively.

Data Reference	Volume (mm ³)	
	Automatic	Manuel
13137	467.96	428.4
13577	463.17	452.1
13654	457.41	440.3
13580	439.20	460.1
13653	415.55	454.1

Table 1 – volume estimation of brains of 5 control mice

Data Reference	Volume (mm ³)	
	Automatic	Manuel
13136	446.49	457.6
13579	467.87	451.6
13578	452.60	447.9
13695	380.12	413.8
13582	415.63	447.8

Table 2 – volume estimation of brains of 5 trisomic TS2Yah mice

Data Reference	Volume (mm ³)	
	Automatic	Manuel
13130	437.74	417.7
13544	483.10	478.6
13549	475.71	456.6
13548	414.41	433.4
13644	454.52	460.0

Table 3 – volume estimation of brains of 5 trisomic TS1Yah mice

A Student t test shows that there is no statistical significant difference between the measured volumes by an expert and our semi-automatic measurement. This demonstrates that the proposed method is of high quality. Moreover, a Student t test shows that there is no statistical significant difference in brain volume between control mice and trisomic ones. Although this result might seem surprising in a first step, it is already known in the literature of this domain [5].

5. FUTURE WORK

It is known that differences between trisomic and control mice brain mainly occurs in the cerebellums and the hippocampus. The cerebellum is responsible of the equilibrium and of the walking process. The hippocampus rules the learning and memory procedure. It is known that there is a significant difference between a trisomic subject and a control one relatively to these various tasks. It will of great interest to have a good knowledge of the relations between the volumes of the cerebellums and the hippocampus and these functions.

However, the cerebellums and the hippocampus are difficult to segment due to their complicated shape. In addition, limits of these objects included in the brain are unclear. The high quality results of segmentation of the brain that we obtained could be used to perform such a task. A possible

strategy is described in the following for the segmentation of the cerebellum (it would be identical for the hippocampus). We start from a reference brain and a reference cerebellum of a given mouse which are manually segmented by an expert. On the mouse under consideration, we first could use a rigid registration process already developed in our institution (only translations, rotations and homothetic deformations are allowed) [11]. The reference brain is first registered with the brain segmented using the semi automatic process presented in this paper (first line of Figure 9). The measured rigid transformation between the current brain and reference brain is then applied on the reference cerebellum (second line of Figure 9). The resulting registered cerebellum is used for initializing the segmentation of the true cerebellum. Such a strategy is under active development.

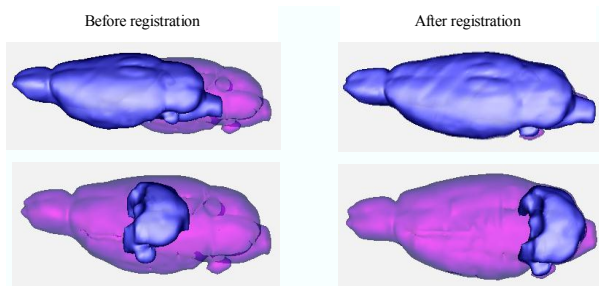


Figure 9 – Reference data are presented in blue color, whereas segmented brain is in purple. Top of the figure, the reference brain is registered with the brain under consideration. Bottom of figure, the rigid registration is applied to the reference cerebellum. This will be the initialisation to the segmentation process of this object.

6. CONCLUSION

In this work, we have proposed a semi automatic Chan-Vese active contour based method to segment mouse brain MRI images. This method associates the Chan-Vese approach to *a priori* information and also uses knowledge given by the user. Results first show that the brain volumes estimated by our method were identical to expert manually estimated volumes. Second, no significant difference of the brain volumes between Trisomy 21 mice and control ones were found.

We are currently investigating the use of a previously proposed registration method for the segmentation of the cerebellums and the hippocampus.

ACKNOWLEDGMENT

The authors thank the French Region Centre for their financial support that made this work possible.

REFERENCES

- [1] D. L. Pham, D. E. Angelini, T. Song, B. D. Mensh, and A. F. Laine, "Brain MRI Segmentation with Multiphase Minimal Partitioning: A Comparative Study," *International Journal of Biomedical Imaging* vol. 2007, pp. 10526, 15 pages, 2007.
- [2] T. F. Chan and L. A. Vese, "Active contours without edges," *IEEE Transactions on Image Processing*, vol. 10, pp. 266-277, 2001.
- [3] A. O'Doherty, S. Ruf, C. Mulligan, V. Hildreth, M. L. Errington, S. Cooke, A. Sesay, S. Modino, L. Vanes, D. Hernandez, J. M. Linehan, P. T. Sharpe, S. Brandner, T. V. P. Bliss, D. J. Henderson, D. Nizetic, V. L. J. Tybulewicz, and E. M. C. Fisher, "An Aneuploid Mouse Strain Carrying Human Chromosome 21 with Down Syndrome Phenotypes," *Science*, vol. 309, pp. 2033 - 2037, 2005.
- [4] K. Aldridge, R. Reeves, L. Olson, and J. Richtsmeier, "Differential effects of trisomy on brain shape and volume in related aneuploid mouse models," *Am. J. Med. Genet. A.*, vol. 143A, pp. 1060-1070, 2007.
- [5] L. Olson, J. Richtsmeier, J. Leszl, and R. Reeves, "A chromosome 21 region does not cause specific Down syndrome phenotypes," *Science*, vol. 306, pp. 687-90, 2004.
- [6] L. E. Olson, R. J. Roper, L. L. Baxter, E. J. Carlson, C. J. Epstein, and R. H. Reeves, "Down syndrome mouse models Ts65Dn, Ts1Cje, and Ms1Cje/Ts65Dn exhibit variable severity of cerebellar phenotypes," *Developmental Dynamics*, vol. 230, pp. 581-589, 2004.
- [7] Z. Li, T. Yu, M. Morishima, A. Pao, J. LaDuca, J. Conroy, N. Nowak, S. Matsui, I. Shiraishi, and Y. Yu, "Duplication of the entire 22.9 Mb human chromosome 21 syntenic region on mouse chromosome 16 causes cardiovascular and gastro-intestinal abnormalities," *Hum. Mol. Genet.*, vol. 16, pp. 359-66, 2007.
- [8] I. Aoki, T. J. Wu, A. C. Silva, R. M. Lynch, and A. Koretsky, "In vivo detection of neuroarchitecture in the rodent brain using manganese-enhanced MRI," *Neuroimage*, vol. 22, pp. 1046-59, 2004.
- [9] J. Lee, H. Silva, H. Merkle, and A. Koretsky, "Manganese-enhanced magnetic resonance imaging of mouse brain after systemic administration of MnCl₂: dose-dependent and temporal evolution of T1 contrast," *Magnetic Resonance in Medicine*, vol. 53, pp. 640-648, 2005.
- [10] J. D. Pinter, S. Eliez, J. E. Schmitt, G. T. Capone, and A. L. Reiss, "Neuroanatomy of Down's syndrome: a high-resolution MRI study," *American Journal of Psychiatry*, vol. 158, pp. 1659-1665, 2001.
- [11] A. Almhdie, C. Léger, M. Deriche, and R. Lédée, "3D Registration Using a New Implementation of the ICP Algorithm Based on A Comprehensive Lookup Matrix: Application to Medical Imaging," *Pattern Recognition Letters*, vol. 28, pp. 1383-1592, 2007.