HAL
open science

Paraneoplastic polymyositis associated with breast cancer: a therapeutic emergency

S. Croce, M. Guèye, A. C. E. Korganow, E. Chatelus, S. M. K. Guèye, P. Diemunsch, C. Mathelin

To cite this version:

S. Croce, M. Guèye, A. C. E. Korganow, E. Chatelus, S. M. K. Guèye, et al.. Paraneoplastic polymyositis associated with breast cancer: a therapeutic emergency. Breast Cancer Research and Treatment, 2011, 126 (3), pp.811-814. 10.1007/s10549-010-1328-7 . hal-00606286

HAL Id: hal-00606286

https://hal.science/hal-00606286v1

Submitted on 6 Jul 2011

HAL is a multi-disciplinary open access archive for the deposit and dissemination of scientific research documents, whether they are published or not. The documents may come from teaching and research institutions in France or abroad, or from public or private research centers.

L'archive ouverte pluridisciplinaire **HAL**, est destinée au dépôt et à la diffusion de documents scientifiques de niveau recherche, publiés ou non, émanant des établissements d'enseignement et de recherche français ou étrangers, des laboratoires publics ou privés.

BRIEF REPORT

Paraneoplastic polymyositis associated with breast cancer: a therapeutic emergency

S. Croce[1], M. Guèye[2], A.C.E. Korganow[3], E. Chatelus[4], S.M.K Guèye[5], P. Diemunsch[6], C. Mathelin[2]

1. Department of Pathology, Hautepierre Hospital, CHRU, avenue Molière, 67200 Strasbourg cedex, France

2. Pole of Obstetrics and Gynaecology, Senology Unit, Hautepierre Hospital, CHRU, avenue Molière, 67200 Strasbourg cedex, France

3. Department of Clinical Immunology and Internal Medicine, Civil Hospital, 1, place de l'Hôpital, BP 426, 67091 Strasbourg cedex, France

4. Department of Rheumatology, Hautepierre Hospital, CHRU, avenue Molière, 67200 Strasbourg cedex, France

5. Department of Gynecology and Obstetrics, Aristide Le Dantec Hospital, CHU, 1 avenue Pasteur, BP 3001, Dakar, *Senegal*

6. Department of Surgical Anesthesiology and Reanimation, Hautepierre Hospital, CHRU, avenue Molière, 67200 Strasbourg cedex, France

Corresponding author: Pr C. Mathelin

Tel. : +33 (0)3 88 12 78 34

Fax : +33 (0)3 88 12 84 82

E-mail address: carole.mathelin@chru-strasbourg.fr

Abstract

The association of polymyositis and cancer was first described in 1916, the most frequent cancers being mammary and gynecological for women, bronchopulmonary for men and digestive for both. This article reports a severe paraneoplastic polymyositis associated with breast cancer. We discuss its clinical, pathological and therapeutic particularities.

Keywords: breast cancer; paraneoplastic syndrome; polymyositis.

Introduction

Inflammatory polymyositis are a heterogeneous group of disorders affecting skeletal muscle via an inflammatory reaction. Paraneoplastic polymyositis (PP) may precede or occur simultaneously with the discovery of a tumor, and even persist after the treatment of the primary tumor. Moreover significant excesses of cancer are observed after polymyositis treatment and the excess cancer incidence declines steadily with increasing years since initial diagnosis of polymyositis [1, 2]. The central or peripheral nervous system can be affected, as well as the neuromuscular junction and the muscle itself. It was hypothesized that PP could result from an autoimmune attack of normal neuronal or muscular tissue, spurred by similar antigens expressed by tumor cells [3]. This article describes a case of severe PP associated with breast cancer which constituted a therapeutic emergency.

Case report

Mrs V.M., age 55, consulted in October 2009 for a gradual decrease in muscle strength predominating at the proximal segments of the limbs and accompanied by myalgia. Laboratory tests found rhabdomyolysis associated with an inflammatory syndrome. C Reactive Protein (CRP) was 90 mg/l (Normal less than 5), Creatine Phospho Kinase (CPK) was 8000 IU/l (Normal between 10 and 200), and Troponin Ic (cTnI) was 1.67 µg/l (Normal less than 0.04), indicating cardiac trouble. All laboratory results were compatible with a connective type of polymyositis or a scleroderma. The patient was admitted in the Department of Immunology for the diagnosis and appropriate management of her collagen disease. Her past medical history included pneumonia in 1999 and 2007 and an active smoking habitus (15 pack-years). She had felt a nodule in the upper-outer quadrant of her right breast, evolving for more than five years but was not motivated for consultation. The autoimmune results showed positive antinuclear antibodies (ANAs) at 1/128, strongly positive anti-Jo1 antibodies, and negative antineutrophil cytoplasmic antibodies (ANCAs). A steroid-based bolus of

methylprednisolone was instituted at a dose of 500 mg/day. During her hospital stay, a deterioration of her respiratory status required her transfer to the intensive care Unit. Hemodynamic stability was obtained on oxygen, furosemide, and catecholamines infusion. High-dose corticosteroids combined with rituximab were administered. The outcome was favorable and the patient was transferred to the continuing care service. The cardiologist's opinion concluded that progressive cardiac damage was linked to polymyositis as evidenced by elevated troponin levels. After improvement of vital parameters, the patient was admitted to the Senology Unit to treat her right breast mass. Physical examination confirmed her nodule in the upper-outer quadrant of the right breast, 5 cm long axis, indurated, and mobile with skin retraction opposite. The lymph nodes were cancer-free at physical exam. The mammography could not be performed because of unbearable standing position, whereas breast ultrasound showed a heterogeneous mass with irregular outline of 44 mm. The microbiopsy revealed infiltrating ductal carcinoma. The staging in search of distant metastases, including bone scan, brain and thoraco-abdomino-pelvic scan showed no secondary localization. The antigen CA 15.3 was at the upper limit of normal values at 34.4 IU/ml (Normal<30). A right mastectomy followed by axillary lymph nodes dissection (Berg levels I and II) was performed in November 2009. The resected mass was classified as an invasive ductal carcinoma (size 40 mm) grade II, according to the histopathological Elston and Ellis grading system [4], nuclear grade SBRM 4/5 with peritumoral vascular invasions.

The tumor was composed by two different cell populations (Fig 1): on one hand, glandular cells well differentiated with mild atypia and rare mitosis; on the other hand, cells organized in solid nests, with neuroendocrine-like features, mild atypia and frequent mitosis (10,9/ mm^2). The tumor highly expressed both estrogen (ER) and progesterone receptors (PR) (3+ and 2+ in 100% of the cells, respectively) whereas HER-2 protein was not overexpressed. The proliferative index evaluated with Ki-67 antibody was estimated at 60%. Subsequent immunohistochemical investigations with antibodies against TTF1, Chromogranin A,

Synaptophysin and CD56 ruled out the possibility of a metastatic event or a neuroendocrine primary lesion. The tumor was surrounded by an inflammatory lymphocytic wall polymorphous, B and T but CD20, CD3, CD4, CD8 were equally expressed. Three of the sixteen axillary lymph nodes appeared to be metastasized.

The additional treatment consisted of adjuvant chemotherapy (6 cycles of docetaxel and cyclophosphamide), followed, on the right side, by radiotherapy of the wall, the internal mammary chain and the supraclavicular area, and by hormone therapy with aromatase inhibitors. The outcome was uneventful from the surgical point of view and dramatically favorable on the muscular side with disappearance of the biological rhabdomyolysis one month after surgery, normalization of cardiovascular checkup and 5/5 restoration of muscle strength with effective resumption of walk and a score at 1 according to the « performance status of the World Health Organization ».

Discussion

Paraneoplastic syndromes are a group of symptoms that are not due to a direct effect of a tumor, infection, metabolic disorders, vascular diseases and coagulopathies, or to the secondary toxicity of a given treatment [5]. PP represent a rare complication of breast cancer which causes inflammation of muscles while dermatomyositis also implies skin lesions with the presence of a rash. Clinically, PP cause progressive muscle weakness predominating at the proximal part of the limbs. Respiratory distress related to respiratory muscles weakness associated with interstitial pneumonia, is a leading cause of death. Cardiac involvement leads to conduction disorders.

The association of polymyositis with cancer was first described in 1916 by Sterz [6]. PP occur in adults, mainly between the ages of 40 and 60. They precede the clinical manifestation of the tumor in 60% of cases [7]. The most frequently encountered tumors are lung and prostate cancers, gastrointestinal tumors in men and gynecological tumors in women [7, 8]. The

clinical expression of PP does not differ from that of polymyositis without cancer. The diagnosis of polymyositis rests on the elevated sedimentation rate and muscle enzymes with a myogenic aspect of the electromyographic tracing (too rich for effort, interferential, small polyphasic potentials, and shredded, normal nerve conduction velocity). Immunology is characterized by the presence of specific autoantibodies dominated by certain aminoacyl-tRNA synthetases (anti-synthetases), anti-Jo1 being the main one [8]. The presence of onconeural antibodies is not always found. In 2003, Roja-Marcos et al. [9] conducted a review of paraneoplastic neurological syndromes associated with breast and gynecological cancers in order to describe their clinical and immunologic characteristics and their relative frequency. In only half of the patients with breast cancer (25 of 92 patients in total) onconeural antibodies were present.

PP are therapeutic emergencies. Indeed, the functional prognosis depends on early treatment. However, the tumor is not always found at the time of diagnosis of PP, even after a thorough evaluation [1, 2]. The different immunological treatments are corticosteroids, intravenous immunoglobulin, cyclophosphamide, tacrolimus and rituximab [10]. In 2007, Minisini [7] reported a case of PP associated with a metastatic breast cancer improved after treatment with capecitabine.

Cancer treatment is frequently followed by an improvement of PP symptoms. The manifestations of polymyositis evolve synchronously with the tumor response to treatment [11]. The prognosis is usually unfavorable since the diagnosis is most often established at an advanced stage of the cancer. If no improvement of symptoms after the treatment of tumor is observed, causality is difficult to establish especially in case of negative onconeural antibodies. In these cases, a coincidence between the tumor and the neurological disorder cannot be excluded. Other possible paraneoplastic syndromes presentations include atypical paraneoplastic syndromes, absence of onconeural antibodies, and lack of improvement after removal of the tumor [9]. The outcome of the PP was favorable in our patient upon treatment

with steroids, immunotherapy and surgery. A driving force at 5/5 and a normalization of muscle enzymes were obtained.

Conclusion

Polymyositis in a woman always requires the search for cancer, especially breast cancer. Early symptomatic treatment of polymyositis associated with curative treatment of the tumor may improve dramatically the outcome of both the cancer and the paraneoplastic syndrome.

References

1. Chow WH, Gridley G, Mellemkjaer L, McLaughlin JK, Olsen JH, Fraumeni JF, Jr.: Cancer risk following polymyositis and dermatomyositis: a nationwide cohort study in Denmark. *Cancer Causes Control* 1995, 6(1):9-13.
2. Chen YJ, Wu CY, Huang YL, Wang CB, Shen JL, Chang YT: Cancer risks of dermatomyositis and polymyositis: a nationwide cohort study in Taiwan. *Arthritis Res Ther* 2010, 12(2):R70.
3. Toothaker TB, Rubin M: Paraneoplastic neurological syndromes: a review. *Neurologist* 2009, 15(1):21-33.
4. Elston CW, Ellis IO: Pathological prognostic factors in breast cancer. I. The value of histological grade in breast cancer: experience from a large study with long-term follow-up. *Histopathology* 1991, 19(5):403-410.
5. Dalmau J, Gultekin HS, Posner JB: Paraneoplastic neurologic syndromes: pathogenesis and physiopathology. *Brain Pathol* 1999, 9(2):275-284.
6. Sterz G: Polymyositis. *Berlin Klin Wochenschr* 1916, 53:489.
7. Minisini AM, Pauletto G, Bergonzi P, Fasola G: Paraneoplastic neurological syndromes and breast cancer. Regression of paraneoplastic neurological sensorimotor neuropathy in a patient with metastatic breast cancer treated with capecitabine: a case study and mini-review of the literature. *Breast Cancer Res Treat* 2007, 105(2):133-138.
8. Anderson NE, Cunningham JM, Posner JB: Autoimmune pathogenesis of paraneoplastic neurological syndromes. *Crit Rev Neurobiol* 1987, 3(3):245-299.
9. Rojas-Marcos I, Rousseau A, Keime-Guibert F, Rene R, Cartalat-Carel S, Delattre JY, Graus F: Spectrum of paraneoplastic neurologic disorders in women with breast and gynecologic cancer. *Medicine (Baltimore)* 2003, 82(3):216-223.
10. Keime-Guibert F, Graus F, Fleury A, Rene R, Honnorat J, Broet P, Delattre JY: Treatment of paraneoplastic neurological syndromes with antineuronal antibodies (Anti-Hu, anti-Yo) with a combination of immunoglobulins, cyclophosphamide, and methylprednisolone. *J Neurol Neurosurg Psychiatry* 2000, 68(4):479-482.
11. Verducci MA, Malkasian GD, Jr., Friedman SJ, Winkelmann RK: Gynecologic carcinoma associated with dermatomyositis-polymyositis. *Obstet Gynecol* 1984, 64(5):695-698.

Figure legend

A. Ductal invasive breast carcinoma exhibits both solid nests (arrow) and glandular architecture (star). Haematoxylin-eosin staining (HE) x 20.

B. High power magnification of the solid component. HE x 400.

C. High power magnification of the glandular and trabecular component. HE x 400.
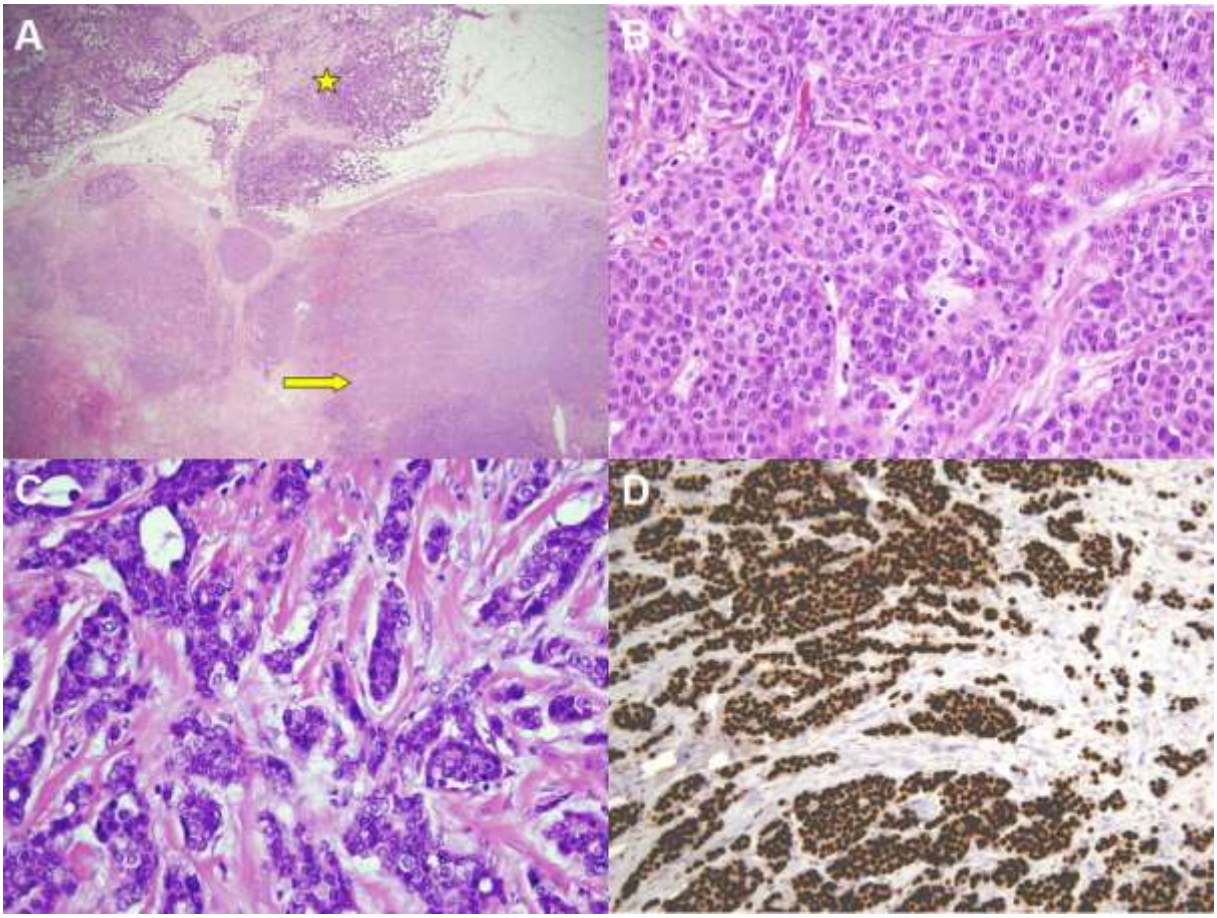
D. Immunohistochemical expression of oestrogen receptors (x 200).