



HAL
open science

Endobronchial fibrosarcoma presenting as recurrent left-sided pneumonia.

Atul Gupta, Rosemary Marsh, Simon Jordan, Simon Padley, Kareem Aboualfa, Ola Smith, Cyril Fisher, Andrew G Nicholson, Andrew Bush

► **To cite this version:**

Atul Gupta, Rosemary Marsh, Simon Jordan, Simon Padley, Kareem Aboualfa, et al.. Endobronchial fibrosarcoma presenting as recurrent left-sided pneumonia.. *Pediatric Pulmonology*, 2010, 10.1002/ppul.21407 . hal-00604880

HAL Id: hal-00604880

<https://hal.science/hal-00604880v1>

Submitted on 30 Jun 2011

HAL is a multi-disciplinary open access archive for the deposit and dissemination of scientific research documents, whether they are published or not. The documents may come from teaching and research institutions in France or abroad, or from public or private research centers.

L'archive ouverte pluridisciplinaire **HAL**, est destinée au dépôt et à la diffusion de documents scientifiques de niveau recherche, publiés ou non, émanant des établissements d'enseignement et de recherche français ou étrangers, des laboratoires publics ou privés.



Endobronchial fibrosarcoma presenting as recurrent left-sided pneumonia.

Journal:	<i>Pediatric Pulmonology</i>
Manuscript ID:	PPUL-10-0313.R1
Wiley - Manuscript type:	Case Report
Date Submitted by the Author:	28-Oct-2010
Complete List of Authors:	Gupta, Atul; Royal Brompton Hospital, Respiratory Paediatrics Marsh, Rosemary; Royal Brompton Hospital, Respiratory Paediatrics Jordan, Simon; Royal Brompton and Harefield NHS Foundation Trust, Department of Thoracic Surgery & Respiratory Medicine Padley, Simon; Royal Brompton and Harefield NHS Foundation Trust, Department of Radiology Aboualfa, Kareem; Royal Brompton and Harefield NHS Foundation Trust, Department of Histopathology Smith, Ola; Department of Paediatrics, William Harvey Hospital, Fisher, Cyril; Department of Histopathology, Royal Marsden Hospital NHS Trust Nicholson, Andrew; Royal Brompton and Harefield NHS Foundation Trust, Department of Histopathology Bush, Andrew; Royal Brompton Hospital, Respiratory Paediatrics
Keywords:	Endobronchial , fibrosarcoma , Polyp, Pneumonia, Tumor

SCHOLARONE™
Manuscripts

1
2
3 **Endobronchial fibrosarcoma presenting as recurrent left-sided pneumonia.**
4
5
6
7
8
9

10 **Authors** Gupta Atul¹, Marsh Rosemary¹, Jordan Simon², Padley Simon³, Aboualfa
11 Kareem⁴, Ola Smith⁵, Fisher Cyril⁶, Nicholson Andrew G⁴, Bush Andrew¹.
12
13
14
15

16 ¹ Department of Paediatric Respiratory Medicine, Royal Brompton and Harefield
17 NHS Foundation Trust
18
19

20
21
22 ² Department of Thoracic Surgery & Respiratory Medicine, Royal Brompton and
23 Harefield NHS Foundation Trust
24
25

26
27
28 ³ Department of Radiology, Royal Brompton and Harefield NHS Foundation Trust
29
30

31
32 ⁴ Department of Histopathology, Royal Brompton and Harefield NHS Foundation
33 Trust
34
35

36
37 ⁵ Department of Paediatrics, William Harvey Hospital, Ashford, Kent
38
39

40
41 ⁶ Department of Histopathology, Royal Marsden Hospital NHS Trust
42
43
44
45
46
47
48
49
50
51
52
53
54
55
56
57
58
59
60

Summary

We report a six year old girl with recurrent and non-resolving left-sided 'pneumonia' over a three year period who was diagnosed with an endobronchial low-grade fibrosarcoma. This highlights the importance of considering underlying localised airway obstruction in any case of clinically or radiologically atypical pneumonia in a child and therefore the need for careful follow-up of all but the most typical cases.

Introduction

Community-acquired pneumonia is relatively common in children, with an incidence of 10-40 cases per 1000 per year¹. It is usually due to viral or bacterial infection in an otherwise healthy child and resolves completely¹. Typically, such infections are clinically resolved before radiological resolution is complete². When infections have an atypical course (such as recurrent episodes, incomplete resolution or atypical radiological appearances) or atypical features (for example failure to thrive, positive family history, gastrointestinal symptoms) further investigations are warranted to exclude diseases like Cystic Fibrosis, immunodeficiency, Primary Ciliary Dyskinesia and aspiration. We describe an unusual case of recurrent pneumonia which highlights two important lessons.

Case

1
2
3 A fully immunised six year old girl was referred to Royal Brompton Hospital for
4 investigation of multiple episodes of a pneumonia-like illness over the previous three
5
6
7
8 years.
9

10
11 At three and a half years of age she had presented to the local hospital with a short
12 history of fever, cough and vomiting. Chest radiography showed left-sided
13 opacification. She was treated for community-acquired pneumonia with intravenous
14 antibiotics and was discharged home on oral antibiotics after clinical improvement.
15
16
17
18
19
20
21 Ten days later she was readmitted with respiratory distress and fever. Chest
22 radiograph showed persistent left sided opacification and was treated with 2 weeks of
23
24
25
26
27
28 broad spectrum intravenous antibiotics. Within three weeks of her recovery from this
29 episode, she was again admitted with respiratory exacerbation for intravenous
30
31
32
33
34
35
36
37
38
39
40
41
42
43
44
45
46
47
48
49
50
51
52
53
54
55
56
57
58
59
60

34
35
36
37
38
39
40
41
42
43
44
45
46
47
48
49
50
51
52
53
54
55
56
57
58
59
60

Follow up chest radiograph (two months after last episode of illness) showed some
but not complete resolution of left sided opacification. Further investigations were
done to exclude tuberculosis, Cystic Fibrosis and immune deficiency. Six months
later she was discharged from follow-up after clinical resolution of her illness.

Three years later, at six and a half years of age, she presented again with intermittent
dry cough for several weeks and short history of fever. She was treated with
intravenous and oral antibiotics. Chest radiograph showed extensive left lung
consolidation. After this episode she was referred to Royal Brompton Hospital for
further management.

Clinical assessment showed dramatically reduced breath sounds throughout the left
hemithorax with the apex beat displaced to the left axilla. There was a mild scoliosis

1
2
3 concave to the left. Spirometry revealed an FEV1 of 0.82L, 67% predicted, FVC
4
5 1.05L, 79% predicted. Chest radiograph (*figure 1*) showed a collapse of the left lung
6
7 with a soft tissue opacity protruding into the left main bronchus. Contrast enhanced
8
9 chest CT scan (*figure 2*) confirmed obstruction of the left main bronchus by a mass.
10
11 Three small soft tissue nodules measuring 2-3mm were also noted in the right lung.
12
13 Flexible bronchoscopy (*figure 3*) revealed an endobronchial polypoid mass,
14
15 completely occluding the left main bronchus. Following biopsy confirmation of
16
17 neoplasia, classified at that time as low-grade spindle cell neoplasm not otherwise
18
19 specified, the patient underwent left pneumonectomy. At thoracotomy, the tumour
20
21 was found to be arising from a broad base within the left main bronchus and so a
22
23 sleeve resection was not possible. A left pneumonectomy was therefore performed
24
25 with resection of a firm broad-based mass measuring 30x25x20mm obstructing the
26
27 left main bronchus and involving the bronchial wall. The proximal bronchial resection
28
29 margin was examined by frozen section microscopy during the operation, and showed
30
31 no evidence of disease.
32
33
34
35
36
37
38
39
40

41
42 Microscopy showed a submucosal proliferation of mildly pleomorphic spindle cells
43
44 arranged in sheets, storiform whorls and fascicles with scattered multinucleate giant
45
46 cells and some peripheral inflammatory cells (*figure 4*). There were occasional
47
48 mitoses present but no necrosis. Staining for CD34 was very focally positive,
49
50 although positivity for this antibody was not viewed as specific for a tumour type in
51
52 this context. The tumour was negative for SMA and ALK-1, arguing strongly against
53
54 an inflammatory myofibroblastic tumour. Staining for MNF116 and EMA was
55
56 negative, thus excluding carcinoma from the diagnosis. Neural and perineural tumours
57
58 were excluded based on the lack of S-100 and claudin-1 positivity. There was no
59
60

1
2
3 histiocytic component morphologically and this was corroborated by the lack of
4 CD68 positivity within the neoplastic cells. PCR did not detect the FUS-CREB3L2 or
5
6 ETV6-NTRK3 gene fusions, thus ruling out a low grade fibromyxoid sarcoma and
7
8 congenial fibrosarcoma. Overall, the features were regarded as those of a low-grade
9
10 fibrosarcoma.
11
12

13
14
15
16 Serial follow-up chest CT scans (over last 2 years) have not shown any change in the
17
18 number, size or appearances of the nodules in the right lung.
19
20

21 22 **Discussion** 23

24
25
26 Community-acquired pneumonia is a common in young children and usually resolves
27
28 completely with antibiotic treatment and supportive care¹. In most cases it is usually
29
30 not essential to investigate for an underlying cause. In adults chest radiography is
31
32 routinely repeated after convalescence from community acquired pneumonia to screen
33
34 for underlying neoplastic disease³. Current guidelines on management of community
35
36 acquired pneumonia in children state that, “follow up chest radiography should only
37
38 be performed after lobar collapse, an apparent round pneumonia, or for continuing
39
40 symptoms’¹. This recommendation is supported by prospective studies of which
41
42 demonstrate no need for routine follow-up chest radiography^{2,4-6}.
43
44
45
46
47

48
49 However, if there is a history suggesting progressive or persistent collapse or
50
51 consolidation it is important to consider the possibility, albeit rare, of a structural
52
53 abnormality including a neoplastic endobronchial lesion. Case series of endobronchial
54
55 neoplasms in children suggest that the majority of these present as persistent collapse
56
57 or consolidation⁷⁻¹⁰ and that delay in diagnosis can have implications for future
58
59 surgical management.
60

1
2
3 Primary lung tumours in children are rare. They have a tendency to present
4 endobronchially, in particular inflammatory myofibroblastic tumour, carcinoids,
5
6 salivary-gland tumours, hamartomas, papillomas and sarcomas. Inflammatory
7
8 myofibroblastic tumours are the most common primary pulmonary tumours in
9
10 children under the age of sixteen¹³. This entity was excluded in our patient based on
11
12 the lack of characteristic morphology, in particular an absence of inflammatory cells
13
14 within the tumour, and the absence of both SMA and ALK-1 staining. Guccion and
15
16 Rosen noted that the majority of endobronchial fibrosarcomas occurred in children,
17
18 whereas intrapulmonary fibrosarcomas presented mostly in adults and elderly
19
20 populations. They classified fibrosarcomas of the lung into endobronchial and
21
22 intrapulmonary types and this classification scheme was said to have prognostic and
23
24 clinical importance¹¹. In another series, metastases were more common with
25
26 pleuropulmonary blastoma and carcinoid being more frequently seen than
27
28 mesenchymal neoplasms¹².
29
30
31
32
33
34
35
36
37
38
39
40
41
42
43
44

45 Conclusion

46
47
48 This child had recurrent consolidation in the left lung with several relapses despite
49
50 aggressive antibiotic treatment. She also never had a completely normal chest x-ray
51
52 and perhaps this should have prompted earlier referral and investigation. We have
53
54 reported this case because it illustrates two important lessons: firstly, the importance
55
56 of following up all but the most typical cases of community acquired pneumonia to
57
58 ensure complete recovery (clinical and radiological). Secondly, although rare, primary
59
60

1
2
3
4
5
6
7
8
9
10
11
12
13
14
15
16
17
18
19
20
21
22
23
24
25
26
27
28
29
30
31
32
33
34
35
36
37
38
39
40
41
42
43
44
45
46
47
48
49
50
51
52
53
54
55
56
57
58
59
60

pulmonary tumours can occur in children and should be considered in the differential diagnoses of non-resolving radiological shadowing.

For Peer Review

1
2
3
4
5
6
7
8
9
10
11
12
13
14
15
16
17
18
19
20
21
22
23
24
25
26
27
28
29
30
31
32
33
34
35
36
37
38
39
40
41
42
43
44
45
46
47
48
49
50
51
52
53
54
55
56
57
58
59
60

Figure 1. Chest x ray showing a collapse of the left lung with a soft tissue opacity, protruding into the left main bronchus.

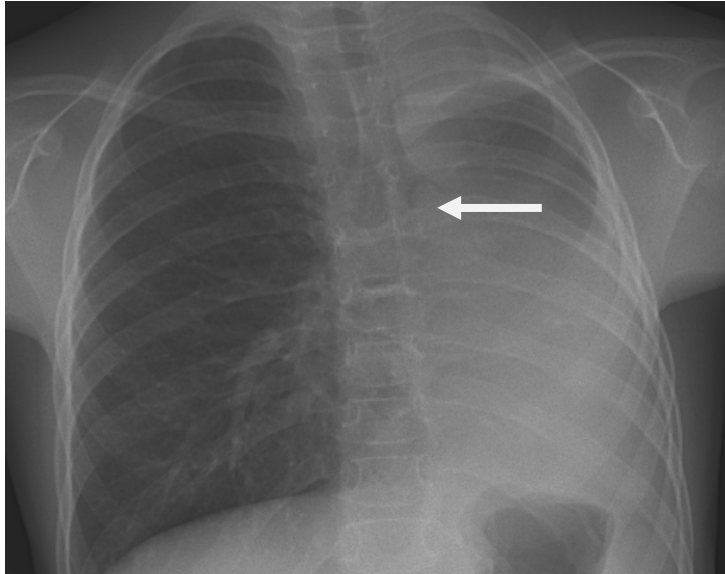
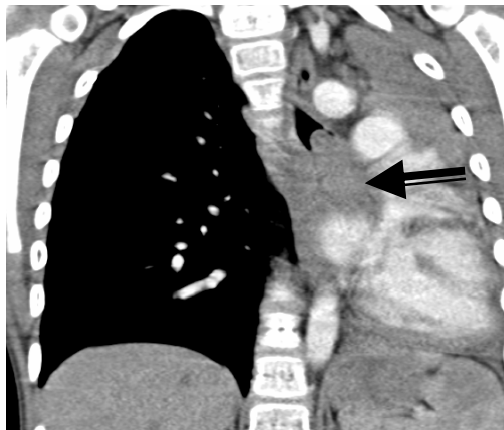


Figure 2. CT scan of chest confirmed a collapsed left lower lobe and a soft tissue mass in the left main bronchus extending into the left lung



1
2
3
4
5
6
7
8
9
10
11
12
13
14
15
16
17
18
19
20
21
22
23
24
25
26
27
28
29
30
31
32
33
34
35
36
37
38
39
40
41
42
43
44
45
46
47
48
49
50
51
52
53
54
55
56
57
58
59
60

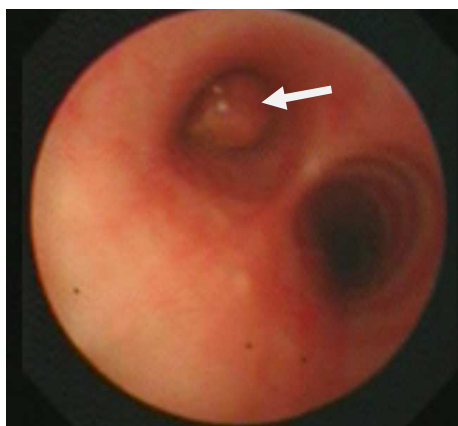


Figure 3. Flexible bronchoscopy showed a large endobronchial mass obstructing the left main bronchus

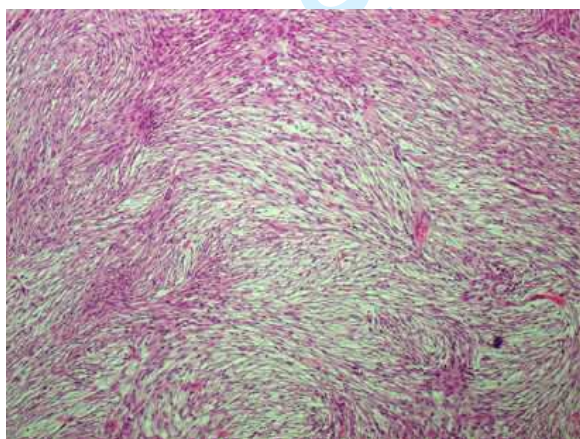


Figure 4. Microscopic image showing spindle cells arranged in storiform whorls and fascicles typical of a low-grade fibrosarcoma. (H&E x 100 magnification)

References

1. **British Thoracic Society Guidelines for the Management of Community Acquired Pneumonia in Childhood. Thorax 2002;57 Suppl 1:i1-24.**
2. **Virkki R, Juven T, Mertsola J, Ruuskanen O. Radiographic follow-up of pneumonia in children. Pediatr Pulmonol 2005;40(3):223-227.**
3. **Lim WS, Baudouin SV, George RC, Hill AT, Jamieson C, Le Jeune I, Macfarlane JT, Read RC, Roberts HJ, Levy ML, Wani M, Woodhead MA. BTS guidelines for the management of community acquired pneumonia in adults: update 2009. Thorax 2009;64 Suppl 3:iii1-55.**
4. **Heaton P, Arthur K. The utility of chest radiography in the follow-up of pneumonia. N Z Med J 1998;111(1072):315-317.**
5. **Gibson NA, Hollman AS, Paton JY. Value of radiological follow up of childhood pneumonia. BMJ 1993;307(6912):1117.**
6. **Suren P, Try K, Eriksson J, Khoshnewiszadeh B, Wathne KO. Radiographic follow-up of community-acquired pneumonia in children. Acta Paediatr 2008;97(1):46-50.**

- 1
2
3 7. Fauroux B, Aynie V, Larroquet M, Boccon-Gibod L, Ducou le Pointe H,
4 Tamalet A, Clement A. Carcinoid and mucoepidermoid bronchial
5 tumours in children. *Eur J Pediatr* 2005;164(12):748-752.
6
7
- 8
9
10
11 8. Al-Qahtani AR, Di Lorenzo M, Yazbeck S. Endobronchial tumors in
12 children: Institutional experience and literature review. *J Pediatr Surg*
13
14
15
16
17
18
19
20 9. Curtis JM, Lacey D, Smyth R, Carty H. Endobronchial tumours in
21 childhood. *Eur J Radiol* 1998;29(1):11-20.
22
23
24
25
26 10. Hullo E, Llerena C, Durand C, Piolat C, Plantaz D, Pin I. [Recurrent
27 pneumonia revealing a bronchial carcinoid tumor: report of two cases].
28
29
30
31
32
33
34
35
36
37
38
39
40
41
42
43 11. Guccion JG, Rosen SH. Bronchopulmonary leiomyosarcoma and
44 fibrosarcoma. A study of 32 cases and review of the literature. *Cancer*
45
46
47
48
49
50
51
52
53
54
55
56
57
58
59
60 12. Dishop MK, Kuruvilla S. Primary and metastatic lung tumors in the
pediatric population: a review and 25-year experience at a large
children's hospital. *Arch Pathol Lab Med* 2008;132(7):1079-1103.
13. Snyder CS, Dell'Aquila M, et al. Clonal changes in inflammatory
pseudotumor of the lung. *Cancer* 1995;76:1545-9.

1
2
3
4
5
6
7
8
9
10
11
12
13
14
15
16
17
18
19
20
21
22
23
24
25
26
27
28
29
30
31
32
33
34
35
36
37
38
39
40
41
42
43
44
45
46
47
48
49
50
51
52
53
54
55
56
57
58
59
60

For Peer Review

1
2
3
4
5
6
7
8
9
10
11
12
13
14
15
16
17
18
19
20
21
22
23
24
25
26
27
28
29
30
31
32
33
34
35
36
37
38
39
40
41
42
43
44
45
46
47
48
49
50
51
52
53
54
55
56
57
58
59
60

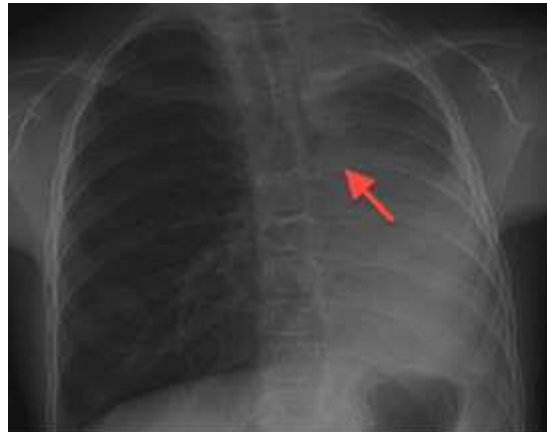

Figure 1. Chest x ray showing a collapse of the left lung with a soft tissue opacity, protruding into the left main bronchus.
96x75mm (72 x 72 DPI)

Peer Review

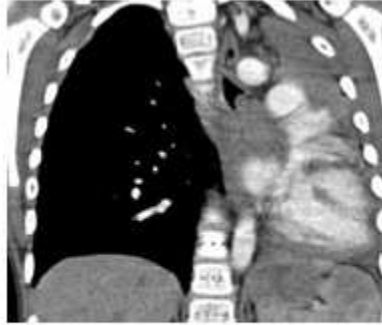


Figure 2. CT scan of chest confirmed a collapsed left lower lobe and a soft tissue mass in the left main bronchus extending into the left lung
112x84mm (72 x 72 DPI)

1
2
3
4
5
6
7
8
9
10
11
12
13
14
15
16
17
18
19
20
21
22
23
24
25
26
27
28
29
30
31
32
33
34
35
36
37
38
39
40
41
42
43
44
45
46
47
48
49
50
51
52
53
54
55
56
57
58
59
60

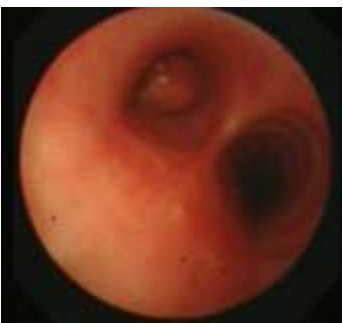

Figure 3. Flexible bronchoscopy showed a large endobronchial mass obstructing the left main bronchus
59x55mm (72 x 72 DPI)

Peer Review

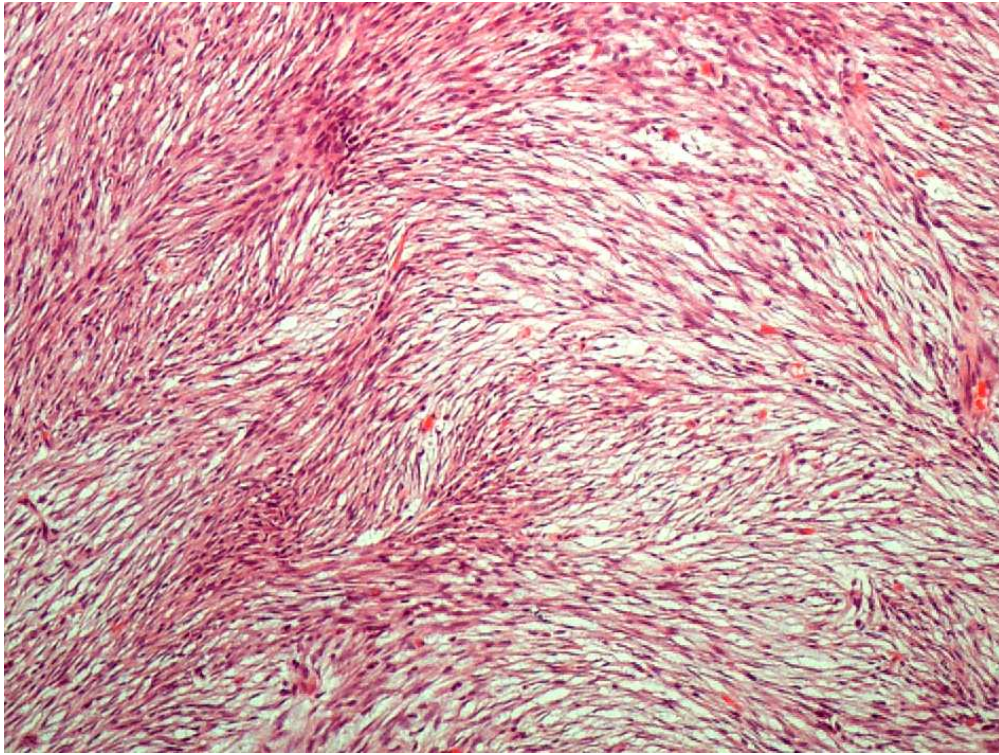


Figure 4. Microscopic image showing spindle cells arranged in storiform whorls and fascicles typical of a low-grade fibrosarcoma. (H&E x 100 magnification)
80x60mm (300 x 300 DPI)

1
2
3 **Endobronchial fibrosarcoma presenting as recurrent left-sided pneumonia.**
4
5
6
7

8 **Authors** Gupta Atul¹, Marsh Rosemary¹, Jordan Simon², Padley Simon³, Aboualfa
9 Kareem⁴, Ola Smith⁵, Fisher Cyril⁶, Nicholson Andrew G⁴, Bush Andrew¹.
10
11

12
13 ¹ Department of Paediatric Respiratory Medicine, Royal Brompton and Harefield
14 NHS Foundation Trust
15
16

17
18 ² Department of Thoracic Surgery & Respiratory Medicine, Royal Brompton and
19 Harefield NHS Foundation Trust
20
21

22
23 ³ Department of Radiology, Royal Brompton and Harefield NHS Foundation Trust
24
25

26
27 ⁴Department of Histopathology, Royal Brompton and Harefield NHS Foundation
28 Trust
29

30
31 ⁵Department of Paediatrics, William Harvey Hospital, Ashford, Kent
32
33

34
35 ⁶Department of Histopathology, Royal Marsden Hospital NHS Trust
36
37
38
39
40
41
42
43
44
45
46
47
48
49
50
51
52
53
54
55
56
57
58
59
60

Summary

We report a six year old girl with recurrent and non-resolving left-sided 'pneumonia' over a three year period who was diagnosed with an endobronchial low-grade fibrosarcoma. This highlights the importance of considering underlying localised airway obstruction in any case of clinically or radiologically atypical pneumonia in a child and therefore the need for careful follow-up of all but the most typical cases.

Introduction

Community-acquired pneumonia is relatively common in children, with an incidence of 10-40 cases per 1000 per year¹. It is usually due to viral or bacterial infection in an otherwise healthy child and resolves completely¹. Typically, such infections are clinically resolved before radiological resolution is complete². When infections have an atypical course (such as recurrent episodes, incomplete resolution or atypical radiological appearances) or atypical features (for example failure to thrive, positive family history, gastrointestinal symptoms) further investigations are warranted to exclude diseases like Cystic Fibrosis, immunodeficiency, Primary Ciliary Dyskinesia and aspiration. We describe an unusual case of recurrent pneumonia which highlights two important lessons.

Case

1
2 A fully immunised six year old girl was referred to Royal Brompton Hospital for
3 investigation of multiple episodes of a pneumonia-like illness over the previous three
4 years.
5
6
7

8
9 At three and a half years of age she had presented to the local hospital with a short
10 history of fever, cough and vomiting. Chest radiography showed left-sided
11 opacification. She was treated for community-acquired pneumonia with intravenous
12 antibiotics and was discharged home on oral antibiotics after clinical improvement.
13
14 Ten days later she was readmitted with respiratory distress and fever. Chest
15 radiograph showed persistent left sided opacification and was treated with 2 weeks of
16 broad spectrum intravenous antibiotics. Within three weeks of her recovery from this
17 episode, she was again admitted with respiratory exacerbation for intravenous
18 antibiotics.
19
20
21
22
23
24
25
26
27

28 Follow up chest radiograph (two months after last episode of illness) showed some
29 but not complete resolution of left sided opacification. Further investigations were
30 done to exclude tuberculosis, Cystic Fibrosis and immune deficiency. Six months
31 later she was discharged from follow-up after clinical resolution of her illness.
32
33
34
35
36
37

38 Three years later, at six and a half years of age, she presented again with intermittent
39 dry cough for several weeks and short history of fever. She was treated with
40 intravenous and oral antibiotics. Chest radiograph showed extensive left lung
41 consolidation. After this episode she was referred to Royal Brompton Hospital for
42 further management.
43
44
45
46
47
48

49 Clinical assessment showed dramatically reduced breath sounds throughout the left
50 hemithorax with the apex beat displaced to the left axilla. There was a mild scoliosis
51
52
53
54
55
56
57
58
59
60

1
2 concave to the left. Spirometry revealed an FEV1 of 0.82L, 67% predicted, FVC
3
4 1.05L, 79% predicted. Chest radiograph (*figure 1*) showed a collapse of the left lung
5
6 with a soft tissue opacity protruding into the left main bronchus. Contrast enhanced
7
8 chest CT scan (*figure 2*) confirmed obstruction of the left main bronchus by a mass.
9
10 Three small soft tissue nodules measuring 2-3mm were also noted in the right lung.
11
12 Flexible bronchoscopy (*figure 3*) revealed an endobronchial polypoid mass,
13
14 completely occluding the left main bronchus. Following biopsy confirmation of
15
16 neoplasia, classified at that time as low-grade spindle cell neoplasm not otherwise
17
18 specified, the patient underwent left pneumonectomy. At thoracotomy, the tumour
19
20 was found to be arising from a broad base within the left main bronchus and so a
21
22 sleeve resection was not possible. A left pneumonectomy was therefore performed
23
24 with resection of a firm broad-based mass measuring 30x25x20mm obstructing the
25
26 left main bronchus and involving the bronchial wall. The proximal bronchial resection
27
28 margin was examined by frozen section microscopy during the operation, and showed
29
30 no evidence of disease.
31
32

33
34 Microscopy showed a submucosal proliferation of mildly pleomorphic spindle cells
35
36 arranged in sheets, storiform whorls and fascicles with scattered multinucleate giant
37
38 cells and some peripheral inflammatory cells (*figure 4*). There were occasional
39
40 mitoses present but no necrosis. Staining for CD34 was very focally positive,
41
42 although positivity for this antibody was not viewed as specific for a tumour type in
43
44 this context. The tumour was negative for SMA and ALK-1, arguing strongly against
45
46 an inflammatory myofibroblastic tumour. Staining for MNF116 and EMA was
47
48 negative, thus excluding carcinoma from the diagnosis. Neural and perineural tumours
49
50 were excluded based on the lack of S-100 and claudin-1 positivity. There was no
51
52
53
54
55
56
57
58
59
60

1
2
3
4
5
6
7
8
9
10
11
12
13
14
15
16
17
18
19
20
21
22
23
24
25
26
27
28
29
30
31
32
33
34
35
36
37
38
39
40
41
42
43
44
45
46
47
48
49
50
51
52
53
54
55
56
57
58
59
60

histiocytic component morphologically and this was corroborated by the lack of CD68 positivity within the neoplastic cells. PCR did not detect the FUS-CREB3L2 or ETV6-NTRK3 gene fusions, thus ruling out a low grade fibromyxoid sarcoma and congenital fibrosarcoma. Overall, the features were regarded as those of a low-grade fibrosarcoma.

Serial follow-up chest CT scans (over last 2 years) have not shown any change in the number, size or appearances of the nodules in the right lung.

Discussion

Community-acquired pneumonia is a common in young children and usually resolves completely with antibiotic treatment and supportive care¹. In most cases it is usually not essential to investigate for an underlying cause. In adults chest radiography is routinely repeated after convalescence from community acquired pneumonia to screen for underlying neoplastic disease³. Current guidelines on management of community acquired pneumonia in children state that, “follow up chest radiography should only be performed after lobar collapse, an apparent round pneumonia, or for continuing symptoms¹. This recommendation is supported by prospective studies of which demonstrate no need for routine follow-up chest radiography^{2,4-6}.

However, if there is a history suggesting progressive or persistent collapse or consolidation it is important to consider the possibility, albeit rare, of a structural abnormality including a neoplastic endobronchial lesion. Case series of endobronchial neoplasms in children suggest that the majority of these present as persistent collapse or consolidation⁷⁻¹⁰ and that delay in diagnosis can have implications for future surgical management.

1
2 Primary lung tumours in children are rare. They have a tendency to present
3 endobronchially, in particular **inflammatory myofibroblastic tumour, carcinoids,**
4 **salivary-gland tumours, hamartomas, papillomas and sarcomas. Inflammatory**
5 **myofibroblastic tumours are the most common primary pulmonary tumours in**
6 **children under the age of sixteen¹³. This entity was excluded in our patient based on**
7 **the lack of characteristic morphology, in particular an absence of inflammatory cells**
8 **within the tumour, and the absence of both SMA and ALK-1 staining.** Guccion and
9
10 Rosen noted that the majority of endobronchial fibrosarcomas occurred in children,
11 whereas intrapulmonary fibrosarcomas presented mostly in adults and elderly
12 populations. They classified fibrosarcomas of the lung into endobronchial and
13 intrapulmonary types and this classification scheme was said to have prognostic and
14 clinical importance¹¹. In another series, metastases were more common with
15 pleuropulmonary blastoma and carcinoid being more frequently seen **than**
16 **mesenchymal neoplasms¹².**

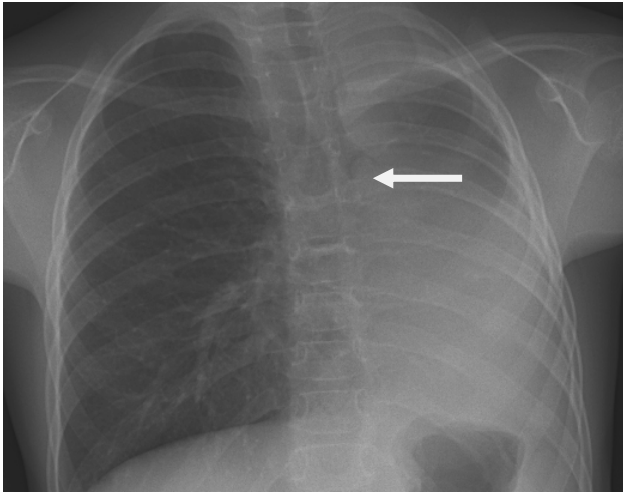
37 **Conclusion**

38
39
40 This child had recurrent consolidation in the left lung with several relapses despite
41 aggressive antibiotic treatment. She also never had a completely normal chest x-ray
42 and perhaps this should have prompted earlier referral and investigation. We have
43 reported this case because it illustrates two important lessons: firstly, the importance
44 of following up all but the most typical cases of community acquired pneumonia to
45 ensure complete recovery (clinical and radiological). Secondly, although rare, primary
46
47
48
49
50
51
52
53
54
55
56
57
58
59
60

1
2 pulmonary tumours can occur in children and should be considered in the differential
3
4 diagnoses of non-resolving radiological shadowing.
5
6
7
8
9
10
11
12
13
14
15
16
17
18
19
20
21
22
23
24
25
26
27
28
29
30
31
32
33
34
35
36
37
38
39
40
41
42
43
44
45
46
47
48
49
50
51
52
53
54
55
56
57
58
59
60

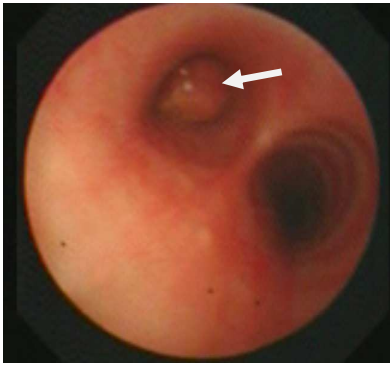
For Peer Review

1
2
3 **Figure 1.** Chest x ray showing a collapse of the left lung with a soft tissue opacity,
4 protruding into the left main bronchus.
5
6
7

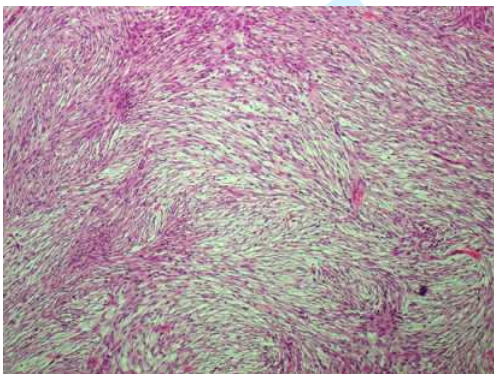


23
24
25
26 **Figure 2.** CT scan of chest confirmed a collapsed left lower lobe and a soft tissue
27 mass in the left main bronchus extending into the left lung
28
29
30
31
32
33
34
35
36
37
38
39
40
41
42
43
44
45
46
47
48
49
50
51
52
53
54
55
56
57
58
59
60





14
15 **Figure 3.** Flexible bronchoscopy showed a large endobronchial mass obstructing the
16 left main bronchus



32
33 **Figure 4.** Microscopic image showing spindle cells arranged in storiform whorls and
34 fascicles typical of a low-grade fibrosarcoma. (H&E x 100 magnification)

References

1. **British Thoracic Society Guidelines for the Management of Community Acquired Pneumonia in Childhood. Thorax 2002;57 Suppl 1:i1-24.**
2. **Virkki R, Juven T, Mertsola J, Ruuskanen O. Radiographic follow-up of pneumonia in children. Pediatr Pulmonol 2005;40(3):223-227.**
3. **Lim WS, Baudouin SV, George RC, Hill AT, Jamieson C, Le Jeune I, Macfarlane JT, Read RC, Roberts HJ, Levy ML, Wani M, Woodhead MA. BTS guidelines for the management of community acquired pneumonia in adults: update 2009. Thorax 2009;64 Suppl 3:iii1-55.**
4. **Heaton P, Arthur K. The utility of chest radiography in the follow-up of pneumonia. N Z Med J 1998;111(1072):315-317.**
5. **Gibson NA, Hollman AS, Paton JY. Value of radiological follow up of childhood pneumonia. BMJ 1993;307(6912):1117.**
6. **Suren P, Try K, Eriksson J, Khoshnewiszadeh B, Wathne KO. Radiographic follow-up of community-acquired pneumonia in children. Acta Paediatr 2008;97(1):46-50.**

Formatted: Space After: Auto

- 1
2
3 7. Fauroux B, Aynie V, Larroquet M, Boccon-Gibod L, Ducou le Pointe H,
4 Tamalet A, Clement A. Carcinoid and mucoepidermoid bronchial
5 tumours in children. *Eur J Pediatr* 2005;164(12):748-752.
6
7
- 8
9 8. Al-Qahtani AR, Di Lorenzo M, Yazbeck S. Endobronchial tumors in
10 children: Institutional experience and literature review. *J Pediatr Surg*
11 2003;38(5):733-736.
12
13
- 14
15 9. Curtis JM, Lacey D, Smyth R, Carty H. Endobronchial tumours in
16 childhood. *Eur J Radiol* 1998;29(1):11-20.
17
18
- 19
20 10. Hullo E, Llerena C, Durand C, Piolat C, Plantaz D, Pin I. [Recurrent
21 pneumonia revealing a bronchial carcinoid tumor: report of two cases].
22 *Arch Pediatr* 2007;14(8):1036-1040.
23
24
- 25
26 11. Guccion JG, Rosen SH. Bronchopulmonary leiomyosarcoma and
27 fibrosarcoma. A study of 32 cases and review of the literature. *Cancer*
28 1972;30(3):836-847.
29
30
- 31
32 12. Dishop MK, Kuruvilla S. Primary and metastatic lung tumors in the
33 pediatric population: a review and 25-year experience at a large
34 children's hospital. *Arch Pathol Lab Med* 2008;132(7):1079-1103.
35
36
- 37
38 13. Snyder CS, Dell'Aquila M, et al. Clonal changes in inflammatory
39 pseudotumor of the lung. *Cancer* 1995;76:1545-9.
40
41
42
43
44
45
46
47
48
49
50
51
52
53
54
55
56
57
58
59
60

1
2
3
4
5
6
7
8
9
10
11
12
13
14
15
16
17
18
19
20
21
22
23
24
25
26
27
28
29
30
31
32
33
34
35
36
37
38
39
40
41
42
43
44
45
46
47
48
49
50
51
52
53
54
55
56
57
58
59
60

For Peer Review