



HAL
open science

Atrophy of the Residual Alveolar Ridge Following Tooth Loss in a Historical Population

Karoline Maria Reich, Christian Domitian Huber, Wilburg Reingard Lippnig, Christian Ulm, Georg Watzek, Stefan Tangl

► **To cite this version:**

Karoline Maria Reich, Christian Domitian Huber, Wilburg Reingard Lippnig, Christian Ulm, Georg Watzek, et al.. Atrophy of the Residual Alveolar Ridge Following Tooth Loss in a Historical Population. *Oral Diseases*, 2010, 17 (1), pp.33. 10.1111/j.1601-0825.2010.01699.x . hal-00599901

HAL Id: hal-00599901

<https://hal.science/hal-00599901>

Submitted on 11 Jun 2011

HAL is a multi-disciplinary open access archive for the deposit and dissemination of scientific research documents, whether they are published or not. The documents may come from teaching and research institutions in France or abroad, or from public or private research centers.

L'archive ouverte pluridisciplinaire **HAL**, est destinée au dépôt et à la diffusion de documents scientifiques de niveau recherche, publiés ou non, émanant des établissements d'enseignement et de recherche français ou étrangers, des laboratoires publics ou privés.

ORAL DISEASES

Atrophy of the Residual Alveolar Ridge Following Tooth Loss in a Historical Population

Journal:	<i>Oral Diseases</i>
Manuscript ID:	ODI-10-09-OM-1432.R2
Manuscript Type:	Original Manuscript
Date Submitted by the Author:	12-Feb-2010
Complete List of Authors:	Reich, Karoline; Medical University of Vienna, Department of Oral Surgery; Autrian Cluster for Tissue Regeneration Huber, Christian; Medical University of Vienna, Department of Oral Surgery; Austrian Cluster for Tissue Regeneration Lippnig, Wilburg; Medical University of Vienna, Department of Oral Surgery Ulm, Christian; Medical University of Vienna, Department of Periodontology Watzek, Georg; Medical University of Vienna, Department of Oral Surgery; Austrian Cluster for Tissue Regeneration Tangl, Stefan; Medical University of Vienna, Department of Oral Surgery; Austrian Cluster for Tissue Regeneration
Keywords:	Pathology, Craniofacial, jaw atrophy, alveolar ridge resorption



1
2
3 **Atrophy of the Residual Alveolar Ridge Following Tooth Loss in an**
4 **Historical Population**
5
6
7
8

9 **Running title:** Natural course of jaw atrophy
10

11 **Keywords:**

12 jaw atrophy; alveolar ridge resorption; tooth loss; residual ridge; denture adverse effects; dental implants;
13 pathoaetiology
14
15
16
17

18 **Name(s) and address(es) of author(s):**

19 Karoline M. Reich^{1, 2}, Christian D. Huber^{1, 2}, Wilburg R. Lippnig¹, Christian Ulm³, Georg Watzek^{1, 2}, Stefan
20 Tangl^{1, 2}
21
22

23 ¹Department of Oral Surgery, Medical University of Vienna, Austria

24 ²Austrian Cluster for Tissue Regeneration, Vienna, Austria

25 ³Department of Periodontology, Medical University of Vienna, Austria
26
27

28 **Corresponding author:**

29 Stefan Tangl

30 Department of Oral Surgery, Medical University of Vienna, Austria

31 Währingerstraße 25a

32 1090 Vienna

33 Austria

34 Tel: +43-1-4277-67028; Fax: +43-1-4277-67019

35 stefan.tangl@meduniwien.ac.at
36
37
38

39 Date of submission:

40 29th October, 2009
41
42
43
44
45
46
47
48
49
50
51
52
53
54
55
56
57
58
59
60

Atrophy of the Residual Alveolar Ridge Following Tooth Loss in an Historical Population

Abstract

Objectives: To study the natural aetiopathology of jaw atrophy after tooth loss, unaltered by prosthetic procedures, an historical population without modern dental treatment was examined.

Methods: Based on the hypothesis that there are predictable changes in shape during jaw-atrophy, frequency and degree of atrophy as well as clinical aspects of bone quality and resorption were determined in the skeletal remains of 263 individuals. The potential association between age and frequency/severity of atrophy was analysed.

Results: Atrophy in at least one jaw segment was present in 45.2% of the analysed jaw specimens. The residual ridge underwent a series of changes in shape and height following the pattern of resorption described for modern populations. The severity of these alterations was associated with the age of the individual and the region within the jaw. Atrophy was frequently related to structural degradation of the covering cortical layer.

Conclusions: These findings prove that atrophy of the jaw evidently does occur, displaying similar patterns of resorption in a population without modern prosthetics, where the negative effect of ill-fitting dentures is excluded. The basic information about alterations of shape and the cortical layer covering the residual crest might help to provide a deeper insight into aetiopathological mechanisms of this common oral disease.

Introduction

As people grow progressively older in modern societies, health problems associated with advanced age increase dramatically. These include, among others, oral diseases that finally may lead to tooth loss and necessitate prosthetic treatment for the patient to obtain the ability to chew and eat as normally as possible.

Tooth loss may have a variety of causes such as periodontal disease, caries and trauma leading to pulpitis. Whatever the reason might be, the effect of tooth loss is always the same: The physiologic masticatory forces applied via the roots of teeth to the cancellous alveolar bone no longer persist (Devlin & Ferguson, 1991; Ulm et al., 1997). According to Wolff's Law (Wolff, 1892) and the Mechanostat Model (Frost, 2003) disuse and a loss of mechanical stimulation is followed by the reduction of bone mass. [This effect was originally demonstrated for limb bones. If these models also hold true for the alveolar process of the jaw and other regions of the skull remains to be investigated in more detail. Also the influence of other factors such as regionally different gene expression \(long bones vs. cranial vault\) resulting in site-specific osteoblast behavior, osteoclast activity and matrix composition has been discussed in this context recently \(Rawlinson et al., 2009\). However,](#) loss of teeth leads [invariably](#) to atrophy of the residual [alveolar ridge](#) being irreversible, chronic, progressive and cumulative (Atwood, 1971).

The rate of atrophy varies greatly between different individuals (Bras, 1990) and even within one and the same person at different times or in different regions within the jaw (Atwood, 1971; Atwood, 1973). However, atrophy is greatest during the first year after tooth loss; the reduction of the residual ridge is a lifelong process (Sennerby et al., 1988) but the rate of bone loss does decrease (Denissen et al., 1993).

Atrophy of the jaw bone can be slowed down, but unfortunately not eliminated, with the help of an appropriate treatment using prostheses balancing the loads to the underlying bone or preferably using implant-supported overdentures (Kordatzis et al., 2003) or endosseous implants (Jokstad et al., 2000a; Jokstad et al., 2000b; Bodic et al., 2005).

Yet, the influence of fixed or removable dentures is an issue of controversial discussion (Devlin & Ferguson, 1991; Carlsson, 2004). As complete dentures do not load the alveolus in the same way as the original teeth do, non-physiologic pressure is applied to the bone surface of the affected jaw, which might be a reason for increased resorption. This is particularly plausible for ill-fitting dentures that cause occlusal disharmonies and thus might enhance alveolar bone loss (Devlin & Ferguson, 1991). Hence the quality of the denture as a holistic system is crucial to prevent local overloading of the underlying bone (Xie et al., 1997a).

However, reduction of the height of the residual ridge is also observed in patients without denture treatment (Devlin & Ferguson, 1991). Consequently, atrophy of the alveolar bone is not attributable to prosthetic factors alone (Atwood, 1979).

Anatomic conditions of the jaws, systemic factors such as sex and age, hormonal balance, local inflammations and masticatory habits are supposed to act as co-factors in the development of residual ridge resorption after tooth loss (Atwood, 1971; Gruber et al., 1993; Kingsmill, 1999).

To gain information about the pathology of atrophy of the jawbone after tooth loss unaltered by the influence of prosthetic procedures, a population without modern dental treatment seems appropriate to serve as a model. For this reason, the skeletal remains of a central European population unearthed from a mediaeval cemetery of the 7th-8th century A.D. was used for this study. As dental treatment was not or only rarely practised in mediaeval populations (Watt et al., 1997; Vodanovic' et al., 2005), these skeletal remains are very useful for analysing the pure effect of oral diseases such as jaw atrophy on the residual ridge.

The purpose of this study is to characterise the patterns of jaw atrophy after tooth loss in an historical population without modern dentistry using an adapted classification system according to Atwood (Atwood, 1963) and Cawood and Howell (Cawood & Howell, 1988). The frequency and severity of atrophy as well as four clinical

1
2 aspects of bone quality and resorption are examined with respect to age within different segments of the jaw.
3 Understanding the natural history of this disease could help to improve our knowledge about atrophy of the jaw,
4 the final result of tooth loss, and is a prerequisite for the development of new treatment strategies. This study
5 also provides additional new information for the interpretation of living conditions and lifestyles of historical
6 populations (Alt, 1987; Vodanovic´ et al., 2005; Meller et al., 2009).
7
8

9 **Material and methods**

10 **Avarian skeletal remains**

11
12 A large mediaeval cemetery with skeletal remains of an Avarian population was unearthed during archaeological
13 excavations in the 11th district of Vienna, Austria. This Avarian cemetery of the 7th - 8th century A.D. consisted
14 of 705 graves. In total, the skeletal remains of 755 individuals were collected.

15
16 263 jaw specimens of this sample met the inclusion criteria of 1) completion of dental development, i.e. presence
17 of permanent dentition and 2) a sufficient state of preservation of the jaw allowing the evaluation of the features
18 described hereinafter.

19
20 Estimation of age at death and determination of sex was based on osteological and dental development criteria,
21 [according to the recommendations of Sarospatak (Ferembach et al., 1979)] and had previously been performed
22 by Großschmidt (1990). [Age at death was determined according to the degree of cranial suture synostosis,](#)
23 [surface characteristics of the symphysis of the pubic bone and of the auricular surface of the ilium and the degree](#)
24 [of tooth abrasion \(White & Folkens, 1999\). The degenerative processes evaluated in this study, were not used](#)
25 [to establish an age estimate and both factors are therefore independent of one another.](#)

26
27 According to these data, the study sample was divided into three age groups of *young* (21-40 years), *middle-aged*
28 (41-60 years) and *old* (61-80 years) individuals. Demographic data concerning age and sex distribution of the
29 analysed population are presented in **Table 1**.
30

31 **Methods**

32
33 Three investigators (WRL, ST, KMR), experienced in the analysis of degenerative alterations of the jaw,
34 discussed and interpreted the variation and expression of signs of atrophy in the sample. The application of the
35 classification systems employed in this study was standardized and calibrated until a consensus was reached.

36
37 The practical evaluations and classifications however, were performed solely by one investigator (WRL) to
38 avoid interobserver error. While undertaking these evaluations the investigator was blinded to age and sex of the
39 individuals. The following features were macroscopically diagnosed under bright light.

40 **1. Classification of atrophy stages**

41
42 Based on the classification system of Nakamoto (1968) six separate segments of the jaw were defined as
43 depicted in **Figure 1**. Each segment of the 263 jaw specimens was assigned to one of the 6 stages of atrophy
44 described by Atwood (1963) and Cawood and Howell (1988). (See **Figure 2**)

45
46 Stage 1 describes the physiological state of *preextraction* at which the tooth is still in the alveolar socket or the
47 tooth is lost post mortem. Stage 2 is assigned to tooth loss immediately before death. There are slight osseous
48 reactions of new bone formation within the alveolus. The alveolus is still in a good condition and the edges
49 might be sharpened.

50
51 In stage 3 the alveolus is completely refilled with newly formed bone. The shape of the original alveolus is no
52
53
54
55
56
57
58
59
60

1
2 longer identifiable and the top of the alveolar process finally becomes *well-rounded* due to first signs of
3 resorption. However, there is no notable reduction in height.

4 In stage 4 the shape of the alveolar crest alters into a thin and sharp *knife-edge*; the body of the jaw is still
5 adequate in height and width.

6 Stage 5: Further resorption leads to a *low well-rounded ridge* which is flat but already reduced in height and
7 width; the alveolar process is lost.

8 Stage 6: Continuing excessive atrophy of the residual crest results in a *depressed* bone level, where even the
9 basal bone shows signs of reduction.

12 **2. Exposed trabecular bone at the top of the residual ridge**

13 Atwood (1971) and Pietrokovski (1975) stated that in many individuals the cortical layer cannot close over the
14 former alveolus and adjacent areas sufficiently due to degenerative and resorptive alterations of the alveolar
15 crest. Accordingly, the residual crest exhibits trabecular bone, extending over the whole length of an edentulous
16 ridge. (See **Figure 3A**)

17 Stage I describes the situation after tooth loss in which the alveolus is totally closed and the crest completely
18 covered by cortical bone.

19 In stage II, the cortical layer of the alveolar crest is not closed, but discontinuous so that an area of exposed
20 trabecular bone with a width of up to 2mm is identifiable.

21 In stage III, the cortical layer of the crest is interrupted by even larger areas of exposed trabecular bone of more
22 than 2mm in width.

25 **3. Bony defects in the region of the former alveolus**

26 Due to poor or incomplete repair of the alveolus after tooth loss, bony defects such as trabecular spots and
27 macroscopic perforations (Solar et al., 1998) might be observed on the crest of the residual ridge (Nakamoto,
28 1968; Pietrokovski et al., 2007). (See **Figure 3B**)

29 As opposed to exposed trabecular bone, the occurrence of this feature is thought to be restricted to the area of the
30 former alveolus (Neufeld, 1958; Lammie, 1960). However, Nakamoto (1968) doubted this limited extension of
31 such defects since he could not detect a relation between the area of former alveolar sockets and the location of
32 defects. To scrutinise this discrepancy and to check whether a discrimination of exposed trabecular bone and
33 defects is expedient and useful, both features are separately assessed in this present study.

34 In stage I, no defects are present. Stage II characterises a residual alveolar crest with small defects. The cortical
35 layer encircles little trabecular inclusions of e.g. flame-like or channel-like shape.

36 In stage III, the observed irregularities at the cortical layer are increased in size.

39 **4. Concave depression of the alveolar crest**

40 In consequence of the loss of several adjacent teeth, the bone tissue in this edentulous space often breaks down.
41 The wound area in this edentulous part of the jaw is too large, so that bone is not able to regenerate up to the
42 height of the former alveolar crest resulting in a *depressed* level of the residual ridge. Towards the adjacent tooth
43 (or teeth, if existent) the bone level maintains the original height of the alveolar process. So-called concave
44 depressions can be observed at the distal end of the dentate arch (Pietrokovski, 1975) as well as in an edentulous
45 space between remaining teeth.

46 A segment is classified as stage I if there is *no concavity* observed.

47 Stage II describes an edentulous ridge portion with a *concave depression* looking like a recess in the residual
48 ridge.
49

5. Exposed mandibular canal

Excessive resorption of the mandibular residual ridge can lead to a reduction of the alveolar crest towards the mandibular canal (Ulm et al., 1989). In the final stage of resorption, the canal containing the mandibular nerve and blood vessels might even lie directly on the surface, solely covered with gingiva in the living individual. In this case, the canal is opened and its borders are well-defined.

In stage I, the mandibular canal is still completely covered with bone. In stage II, the mandibular canal is exposed.

Statistical Analysis

The frequency distribution of ante-mortem tooth loss and the degree of subsequent atrophy and its concomitant features were determined for all segments of the upper and the lower jaw. In case of absence or poor preservation of a segment within an otherwise well-preserved jaw, only segments that could be evaluated accurately were included.

In order to facilitate evaluation of potential trends between anterior and posterior segments, only the worse affected of both posterior segments was selected for analysis. This pooling of data was based on a high correlation of the analysed parameters between the right and the left posterior segments.

The main purpose of the study is to determine at which frequency the different stages of atrophy are present after tooth loss has occurred. Thus, segments without atrophy were specified as "non-affected" and excluded from further calculations. By this means, data about different stages of a certain feature are presented as a percentage of the affected jaw segments only and also as absolute values.

Descriptive analysis, two-sided Fisher's exact tests and cross tabulations were used to assess potential interrelationships between the occurrence and degree of the features.

Results

1. Frequency and severity of analysed features

1.1. Atrophy

Atrophy in at least one segment was present in 120 of the 263 analysed specimens.

The frequency of occurrence of jaw atrophy (including the stage of recent, intravital tooth loss) in this population is presented in **Figure 4** for the anterior and posterior segments of the mandible and the maxilla.

Three general trends concerning frequency and distribution of atrophy of the jaw are apparent:

- 1) Frequency and also severity of atrophy were lowest in the youngest age group (20-40 years) and increased significantly with advancing age. The occurrence of atrophy is highly correlated with age in all segments of the jaw ($p \leq 0.001$).
- 2) The mandible (Md) tended to be worse affected than the maxilla (Mx), independent of the position of the segment and the age group.
- 3) The posterior segments (post.) of both the mandible and the maxilla exhibited an increased frequency and also more severe stages of atrophy than the anterior segments (ant.) in all age groups.

Differences in the distribution of the 5 stages of atrophy, from *postextraction* state to a *depressed* level, in the

1
2 analysed segments of all age groups are shown in **Figure 5**. Percentages of atrophy stages were calculated from
3 affected segments only (atrophy stages 2 to 6), hereinafter referred to as 100%.

4
5 In the youngest age group (20-40yrs), atrophy was negligibly rare in the anterior segments. In the posterior
6 segments atrophy was slightly more frequent. In the older age groups (41-60yrs and 61-80yrs), a shift from the
7 lower to the higher, more severe atrophy stages was identified. Atrophy stage 4, representing a residual ridge
8 shaped like a *knife-edge*, was most frequent in anterior segments, particularly of the mandible. By contrast, in
9 posterior segments, atrophy stage 5, characterised by a reduced height of the ridge with a *well-rounded crest*, and
10 stage 6, a *depressed* ridge level, were most frequent. Particularly in posterior segments of the mandible, atrophy
11 showed two peaks, one at stage 2 (*postextraction*) and one at stage 5 (*low well-rounded*), whereas the stages in
12 between were very rare.

13
14 In brief, the *knife-edge* shape was the predominant stage of atrophy in anterior segments. Stage 5, the *low well-*
15 *rounded ridge*, and stage 6, the *depressed* ridge, played a less prominent role in anterior segments than in
16 posterior segments, where atrophy appeared to attain more severe stages more rapidly with increasing age.
17 Mandibular posterior segments of old individuals seemed to be the most affected of all.

18 Fisher's exact tests showed a statistically significant relationship between age group and atrophy stage in anterior
19 segments of the mandible (ant. Md: $p=0.049$) and posterior segments of the maxilla (post. Mx: $p=0.034$). In the
20 other segments no significant correlation was detected (post. Md: $p=0.095$; ant. Mx: $p=0.974$).
21
22

23 **1.2. Exposed trabecular bone at the top of the residual ridge**

24 This feature was more frequent in the mandible than in the maxilla. Posterior segments were more severely and
25 more often affected than anterior segments. Yet, frequency and extent of exposed trabecular bone increased only
26 up to the middle-aged group and decreased again in the oldest age group. (See **Table 2**)

27 Due to the low rate of atrophy in anterior segments of the youngest age group (20-40yrs), the feature of exposed
28 trabecular bone at the crest of the residual ridge was also very rare. In posterior segments, the rate of affection
29 was higher with stage III (area of exposed trabecular bone $\geq 2\text{mm}$ in width) being the predominant stage in young
30 individuals. In the middle-aged group (41-60yrs), the prevalence of a discontinuous cortical layer increased in all
31 segments, posterior segments again being worse affected by stage III. In old individuals (61-80yrs), the
32 frequency of stage III decreased compared to the middle-aged group. In contrast, stage I, characterised by a
33 closed cortical layer at the crest, became more frequent and even obtained its peak frequency in this age group.

34 A significant correlation between age group and the occurrence of different stages of exposed trabecular bone
35 was identified for the posterior segments of the mandible (post. Md: $p=0.011$) and the maxilla (post. Mx:
36 $p=0.010$), but not for anterior segments of either jaw (ant. Md: $p=0.375$; ant. Mx: $p=1.000$).
37
38

39 **1.3. Bony defects at the crest of the residual ridge**

40 Bony defects occurred with a higher frequency in the mandible than in the maxilla. Posterior segments were
41 more frequently affected than anterior segments. Similarly to atrophy, frequency increased with advanced age
42 and reached a plateau in the middle-aged (41-60yrs) and old group (61-80yrs). Indeed, also the frequency of
43 stage I (properly healed alveolus covered by a continuous cortical layer) was increased in old individuals. (See
44 **Table 2**)

45 In detail, bony defects in the region of the former alveolus were very rare in anterior segments of young adults
46 (20-40yrs), which is the result of low affection by atrophy. In posterior segments, the frequency of poorly healed
47 alveoli was higher, showing a pronounced occurrence of small defects (stage II) in the posterior segment of
48 mandible. The middle-aged group showed a notable increase of stage I in anterior segments and of stage III
49 (large trabecular spots at the crest) in posterior segments. In old individuals stage III was mainly identified in
50

posterior segments of the maxilla. In the other segments, the frequency of stage III decreased in favour of an increase of stage I, when compared to the middle-aged group.

Bony defects did not show a statistically significant correlation with age in any jaw segment (ant. Md: $p=0.699$, post. Md: $p=0.120$; ant. Mx: $p=0.312$, post. Mx: $p=0.218$).

1.4. Concave depression of the alveolar crest

With advanced age, the frequency of concave depressions increased. In the mandible, concave depressions occurred more frequently than in the maxilla. Posterior segments were affected with a higher frequency than anterior segments. (See Table 3)

In anterior segments of young adults (20-40yrs), concave depressions were almost non-existent. In the middle-aged group (41-60yrs), this feature occurred with a frequency of 14.3% in the anterior mandible and 22.2% in the anterior maxilla. In the oldest age group (61-8yrs), the anterior segments of the lower and the upper jaws were conversely affected with an increased frequency of 31.8% in mandibular segments and a decrease to 14.3% in maxillary segments.

In posterior segments, the frequency of concave depressions was increased compared to anterior segments in young and middle-aged individuals; the latter representing the most affected age group. Posterior segments of old individuals (61-8yrs) showed a decline in frequency.

This tendency was not pronounced enough to show a significant relationship between the occurrence of concave depressions and age in any segment (ant. Md: $p=0.544$, post. Md: $p=0.542$; ant. Mx: $p=0.300$, post. Mx: $p=0.431$).

1.5. Exposed mandibular canal

An exposed mandibular canal (stage II) was a very rare feature. With increasing age its frequency rose slightly. In the middle-aged group (41-60yrs) 3 (6.7%) and in old individuals 7 (16.7%) posterior segments were affected by such signs of excessive resorption.

2. Correlation of atrophy and concomitant features

2.1. Exposed trabecular bone & atrophy

In both the anterior and the posterior segments of the mandible, a statistically significant correlation between atrophy classes and the extent of exposed trabecular bone was identified (ant. Md: $p=0.004$; post. Md: $p<0.001$).

The size of exposed trabecular bone areas seemed to decrease with the progress of atrophy in the mandible. (See Table 4)

A continuous cortical layer covering the former alveolus without exposed trabecular bone at the surface (stage I) was the predominant feature in anterior mandibular segments classified as atrophy class 4 (*knife-edge* ridge). In posterior segments, this feature increased with the progress of atrophy and reached the highest frequency in *depressed* residual ridge (atrophy stage 6).

Exposed trabecular bone of up to 2mm in width (stage II) was most common in posterior segments classified as atrophy stage 5 and 6. Exposed trabecular bone of more than 2mm in widths (stage III) was most frequently observed in segments classified as atrophy stage 2 *postextraction*. At this atrophy stage, tooth loss did not date back very long; the alveolus already showed first signs of regeneration but the cortical layer had not closed completely over the trabecular area.

In the maxilla, there was no significant relationship between the dimensions of atrophy and exposed trabecular bone (ant. Mx: $p=0.310$; post. Mx: $p=0.655$).

2.2. Bony defects at the crest & atrophy

1
2 A statistically significant correlation between atrophy stages and the occurrence of bony defects at the crest of
3 the residual ridge was found in anterior segments of the maxilla (ant. Mx: $p=0.046$) and the posterior segments
4 of both jaws (post. Md: $p<0.001$, post. Mx: $p<0.001$).

5 No defects were most frequently found in *postextraction* segments (atrophy stage 2) with recent tooth loss where
6 the alveolus is not refilled with bone and thus has no covering cortical layer. In segments with first signs of
7 atrophy (*high well-rounded* ridge, stage 3), cortical layers lacking defects were non-existent.

8 In highly atrophic segments with a *low well-rounded* (stage 5) or a *depressed* ridge shape (stage 6), size of bony
9 defects was increased compared to earlier stages of atrophy. Thus, the occurrence of perforations of the cortical
10 layer with trabecular spots at the area of the former alveolus increased with the progress of atrophy. Also cortical
11 layers without defects increased slightly with higher atrophy stages.
12

13 14 **2.3. Concave depression & atrophy**

15 The presence of concave depressions of the crest of the residual ridge and the extent of atrophy were
16 significantly correlated in all segments of the jaw (ant. Md: $p=0.022$; post. Md: $p<0.001$; ant. Mx: $p=0.043$; post.
17 Mx: $p<0.001$).

18 19 20 **Discussion**

21 Atrophy of the jawbone following tooth loss is a very common oral disease particularly in elderly people.
22 Affected patients suffer not only from alterations of the anatomic structure of their jaw and loss of function but
23 also from changes of the facial shape and psychological problems (Atwood, 1971) such as a reduced quality of
24 life (Jokstad et al., 2000a; Jokstad et al., 2000b), feelings of shame, insecurity and decreased attractiveness
25 (Trulsson et al., 2002). Thus, the major tasks of prosthetic or implant-supported treatment are, on the one hand,
26 to restore the function including mastication (Şahin et al, 2002) and speech, and on the other hand, to preserve
27 the appearance and well-being of the patient (Jokstad et al., 2000a; Jokstad et al., 2000b; Sutton et al., 2004;
28 Heydecke et al., 2005; Pan et al., 2008; Fenlon & Sherriff, 2008).

29 Despite these undoubtedly positive results of prosthetic treatment, there are diverging opinions as to whether or
30 not there are severe side effects. Several studies have shown that in patients wearing dentures the reduction of
31 the residual ridge was worse than in patients without dentures (Thoma, 1959; Campbell, 1960; Carlsson et al.,
32 1969). As an explanatory concept, *pressure atrophy* is particularly plausible for ill-fitting dentures (Carlsson et al.,
33 1969; Xie et al., 1997a). By contrast, atrophy was also described in patients without prosthetic treatment
34 (Devlin & Ferguson, 1991; Thoma, 1959) supporting the concept of *disuse atrophy*.

35 Atwood (Atwood, 1971; Atwood, 1973) assumed that three major groups of co-factors seem to influence the
36 series of events from wound healing of the affected alveolus to resorption of the alveolar process. These are (1)
37 anatomic structure of the jaw, the (2) biology of the individual (age, sex, hormonal balance etc.) and (3)
38 mechanical factors such as force applied to the alveolar bone and the influence of prosthetic procedures.

39 Anatomy and biology of the patient are predetermined. Hence, one factor left to influence the inevitable progress
40 of atrophy is prosthetics. Clinicians can select from a wide variety of prosthetic and surgical treatment options
41 including traditional removable prosthesis, implant supported dentures, or a combination of both. However, the
42 outcome of the chosen therapy is hardly predictable (Carlsson et al., 1969). For that reason, and to find the best
43 individual solution for every patient, it is necessary to increase our knowledge about the preserving or
44 destructive effect of prosthetic procedures. Due to the complex pathoetiology of atrophy (Carlsson, 2004), the
45 true, unbiased influence of prosthetic treatment is difficult to isolate from the broad spectrum of co-factors.

46 Consequently, there is a growing demand for a purpose-made study design, somehow comparable to a knockout
47 experiment in mice. In a knockout study, the effect of a specific gene of unknown function is analysed by
48
49

1
2 deactivating the gene. Thus, differences from the normal condition can be examined and the probable function of
3 the gene can be inferred. In this present study, the influence of prosthetic treatment was “knocked out” by
4 analysing an historical population that did not practice any kind of modern dentistry. By this means the natural
5 course of disease could be studied excluding the mechanical factor of prosthetics.

6 Our results proved that atrophy of the jaw after tooth loss definitely does occur in a population without prosthetic
7 treatment, which is in strong agreement with the concept of a multifactorial disease (Atwood, 1971).
8 Furthermore, we could show that even without prosthetics the residual ridge underwent similar changes in height
9 and shape as described by Atwood (1963) and Cawood and Howell (1988). As expected, old individuals were
10 more frequently and worse affected than younger ones. This seems self-evident since tooth loss usually dates
11 back further in old people’s lives. Hence, atrophic processes had less time to proceed in individuals that died at
12 an earlier age. In addition, with increasing age the loss of several teeth accumulates - a situation that might
13 promote the development of advanced atrophy stages. The prevalence of *postextraction* segments increased in
14 middle-aged individuals, possibly indicating that this age group is very susceptible to tooth loss.

15 Notable differences in rate and degree of atrophy were observed between the mandible and the maxilla as well as
16 between anterior and posterior segments in all age groups, which might be the result of differences in anatomy.
17 Posterior segments showed a higher frequency and degree of atrophy than anterior segments, which is in
18 concordance with the fact that molars tend to be lost at an earlier age than anterior teeth. Hence, atrophy might
19 develop in the posterior part of the jaw first and progress further (Ulm et al., 2009). Interestingly, in maxillary
20 posterior segments the residual ridge seemed to skip atrophy stages 3 to 5 resulting rather directly in a *depressed*
21 bone level (stage 6) in both older age groups. Accordingly, stages 3 to 5 seem to be shorter processes, so that the
22 jaw does not remain long in these stages. By contrast, in the mandible the transition of stage 5 to stage 6
23 (*depressed*) took place with some time lag in the oldest group. This might indicate that in the initial phases of
24 atrophy mandible offers more resistance to vertical resorption, probably due to the greater thickness of its
25 cortical bone, than the maxilla. However, subsequently the mandible was more frequently and worse affected
26 than the maxilla.

27 Several studies on denture-wearing patients have attributed the higher atrophy rate in the lower jaw to the
28 smaller surface and the unfavourable shape of the mandibular ridge on which mechanical loads are applied to in
29 edentulous patients (Tallgren, 1972; Tallgren et al., 1980; Bodic et al., 2005). By contrast, the maxilla is thought
30 to resist loads of dentures more successfully, because of the larger supporting surface of the hard plate (Tallgren,
31 1972). In the present study, prosthetics cannot be held responsible for the higher degree of resorption of the
32 lower jaw. That leads us back again to other factors that might be involved. It seems plausible that forces through
33 chewing and swallowing are applied to the residual ridge also in non-denture wearers. Alterations in frequency,
34 intensity and direction of such forces might lead to an imbalance of the neuromuscular stability (Budtz-
35 Jørgensen, 1996; Kingsmill, 1999) and thus to an impaired activation of osteoblasts and osteoclasts, probably
36 resulting in a discrepancy of resorption (Atwood, 1962). [As recently shown by Rawlinson et al. \(2009\) also
37 differences in gene expression of developmentally and/or functionally distinct skeletal sites play a role in their
38 response to mechanical stimuli. The described differences in gene expression profiles between the skull vault
39 and limb bones were attributed to cell \(osteoblast\) populations of distinct embryonic lineages. This
40 developmental, “positional identity” of bone cells has been shown to determine cell activity and matrix
41 characteristics probably leading to differences in their susceptibility to osteoporosis and adaptation to mechanical
42 strain.](#)

43 In anterior segments of either jaw, a *knife-edge* shape of the residual ridge was predominant. This stage 4 is
44 particularly problematic for implantology since the width of the crest is insufficient for the insertion of
45 endosseous implants. Heights of 6mm and 10mm as well as widths of 6mm and 5mm are regarded as minimum
46 dimensions for successful implantation in the maxilla and the mandible, respectively (Neukam & Kloss, 2001).
47
48
49
50

1
2 Also *well-rounded* ridges with reduced height and ridges with a *depressed* bone level (stage 5 and 6), which are
3 predominant in posterior segments, do not meet the standard criteria for implantation and require pre-treatment -
4 complex surgical procedures, such as the removal of the thin bone structure (Nishimura & Atwood, 1994) or/and
5 alveolar ridge augmentation by bone graft techniques (Ulm et al., 1995; Coulthard et al., 2002; Bodic et al.,
6 2005). Even in the most recent systematic reviews on the subject (Esposito et al., 2006; Aghaloo & Moy, 2007;
7 Rocchietta et al., 2008), there are no indications which frequencies of cases that necessitate bone augmentation
8 procedures a surgeon has to expect. According to the results of the present study, implantologists might figure
9 that up to 75% of elderly patients require some kind of surgical pre-treatment (depending on the region of the
10 jaw). A comparison with modern populations is hardly possible since data on prevalence are very rare and
11 information about the sample is mostly lacking. Denissen et al. (1993) analysed a sample of 61 middle-aged
12 patients (40-65 years of age) treated with prostheses. 51.6% of these dried edentulous mandibles showed a *knife-*
13 *edge* shape (atrophy stage 4) compareable to a prevalence of 50% in ant. Md. segments of middle-aged
14 individuals of this present study. Al-Faleh (2009) found a similar prevalence of 46.5% in an inhomogeneous
15 sample of 30 17-67 year old patients. Pietrokovski et al. (2007) studied a sample of 123 human edentulous dried
16 skulls of unknown age, sex and treatment and described 38% of these maxillary and mandibular ridges to be
17 *knife-edged*.

18
19 Another aspect of clinical relevance is the bone quality of the cortical layer covering the crest of the residual
20 ridge. In fact, a large amount of continuous cortical bone provides good primary stability of the implant and
21 hence decreases the risk of implant failure (Rabel et al., 2007). Alterations in cortical layer, such as areas of
22 exposed trabecular bone and osseous defects, might have negative implications for the insertion of endosseous
23 implants (Pietrokovski et al., 2007). A closed cortical layer offers more resistance to the bur used than does a
24 crest with macroscopic openings and exposed trabeculae. Thus, there is a risk of overdosing the force at the
25 transition from the outer surface to the trabecular compartment when drilling a hole for the implant
26 (Pietrokovski, 1975).

27
28 According to our observations, the differentiation based on the localisation at the crest (Atwood, 1971;
29 Pietrokovski, 1975; Neufeld, 1958; Lammie, 1960) was not unequivocal, so that in many cases trabecular spots
30 were classified as both exposed trabecular bone and bony defects.

31
32 Yet, the results demonstrated that exposed trabecular bone and defects at the crest do occur in absence of
33 prosthetic treatment. Also, an exposed mandibular canal was detected in a few individuals as a result of
34 excessive atrophy. In the analysed population, the prevalence of an exposed mandibular canal was 6.7% for 41-
35 60 year-old individuals and 16.7% for individuals over 61 years of age. Xie et al. (1997b) reported an even
36 higher prevalence of 27% in a sample of 128 76-86 year old patients. The exact localisation of the mandibular
37 canal is essential to know for an implantologist when planning and inserting endosseous implants in the atrophic
38 mandible (Ulm et al., 1993; Lindh et al., 1995), since an injury would implicate neurosensory damage or even
39 loss of sensation (Ulm et al., 1993).

40
41 In this study, some limitations were encountered. Since only individuals with a sufficient state of preservation
42 were included, the sample might be biased to some extent (Meinl, 2009). Due to the lack of information about
43 the time point of tooth loss and hence of the duration being (partly) edentulous, no conclusions about the rate of
44 atrophy (i.e. the amount of bone being resorbed) per time unit could be drawn. The observed features within the
45 jawbone mirror only the conditions at time of death. The role of osteoporosis in the development and progression
46 of jaw atrophy is still controversially discussed (Hildebolt, 1997; Bollen et al., 2004; Felton, 2009; Yüzügüllü et
47 al., 2009). However, due to the large sample size of 263 jaw specimens it was economically not possible to study
48 systemic bone disorders such as osteopenia and osteoporosis by means of x-rays or DEXA. Several studies
49 reported that osteoporosis might promote ridge resorption (Bays & Weinstein, 1982; Kribbs et al., 1983; Hirai et
50 al., 1993) and tooth loss (Nicolopoulou-Karayianni et al., 2009) whilst others failed to demonstrate a correlation

1
2 (Klemetti et al. 1993a; Klemetti et al. 1993b; Bollen et al., 2004). Devlin & Horner (2007) state that age-related
3 bone loss of the jaw resulting in cortical porosity and a reduced BMD and BMC (Hildebolt, 1997) has to be
4 clearly distinguished from external alterations of the mandibular alveolar process due to tooth loss. Moreover, a
5 recent review of Slagter et al. (2008) reported no more than a minimal evidence for a relation between
6 osteoporosis and jaw atrophy. Future studies evaluating radiographic data of atrophic jaws would be of great
7 value to shed light onto this issue. So far, most published studies dealing with atrophy after tooth loss did not
8 meet modern scientific standards, mainly being written in a descriptive style, and lacking information on the
9 sample. Moreover, they had been limited to the assessment of single features of this complex oral disease. Here
10 we present a study analysing concomitant features described in literature and questioning/challenging the
11 consistency and applicability of the classification system. The strength of this current study lies in the analysis of
12 the natural history of atrophy in a large sample of a mediaeval population excluding the influence of prosthetic
13 treatment.

14
15 Results demonstrated that atrophy evidently did occur in the absence of prosthetics and followed the pattern of
16 resorption described for modern populations (Atwood, 1963; Cawood & Howell, 1988). Concomitant features,
17 i.e. exposed trabecular bone, osseous defects, concave depression and exposed mandibular nerve, were present
18 and often correlated with the occurrence of advanced atrophy stages. A differentiation of exposed trabecular
19 bone and bony defects at the crest of the ridge appears not to be useful since they were hardly distinguishable
20 and their developmental mechanisms might overlap to some extent. Yet, their presence might be of clinical
21 relevance for the planning and realisation of dental implants and prostheses.

22 Above all, our findings present basic information about the pathology of jaw atrophy and provide a deeper
23 insight into the structural characteristics of this common oral disease. Further research in this field is required to
24 study the effect and relative weights of other factors involved in this multifactorial process.
25
26
27
28
29
30
31
32
33
34
35
36
37
38
39
40
41
42
43
44
45
46
47
48
49
50
51
52
53
54
55
56
57
58
59
60

1
2
3 **Conclusions**
4

- 5 1. Atrophy of the jawbone following tooth loss is a multifactorial disease that is not attributable to prosthetics
6 alone, since its occurrence is observed in a population without modern prosthetic treatment.
7 2. The residual ridge undergoes a series of changes in shape and height following the pattern of resorption
8 described for modern populations. The severity of these alterations is associated with the age of the
9 individual and the region within the jaw.
10 3. Atrophy is frequently related to structural alterations of the covering cortical layer which all together might
11 have clinical relevance for planning and realisation of dental implants and prostheses.
12
13
14
15
16
17
18
19
20
21
22
23
24
25
26
27
28
29
30
31
32
33
34
35
36
37
38
39
40
41
42
43
44
45
46
47
48
49
50

Acknowledgements

The authors thank Martina Traindl-Prohazka of the Department of Anthropology, University of Vienna, for providing the skeletal remains, stored in the Department of Anthropology, University of Vienna, Austria. We express gratitude to Karl Großschmidt for providing his data on sex and age determination of the study sample. Thanks are also due to Robert Hütter of the Department of Oral Surgery, Medical University of Vienna, Austria for his technical support in taking photographs and creating figures.

Conflict of interest

None declared.

Authors Contributions

KMR was the primary author of the manuscript, was involved in the development of standardised and calibrated evaluation criteria, analysed and interpreted the results, reviewed literature and submitted the manuscript. CDH performed the statistical analyses and was involved in the interpretation of the results. WRL participated in study design, establishment of methods and performed practical evaluation and classification, being blinded to individuals' age and sex. CU and GW supervised the progress of the project, reviewed the manuscript critically and helped to finalise the manuscript. GW also provided funding for the study. ST designed and planned the study and monitored the progress of the project. He was also involved in the development of standardised and calibrated of evaluation criteria and in data interpretation and helped to prepare the paper.

All authors have contributed to, seen and approved the manuscript.

References

- 1
2
3
4
5 Aghaloo TL, Moy PK (2007). Which hard tissue augmentation techniques are the most successful in furnishing
6 bony support for implant placement? *International Journal of Oral and Maxillofacial Implants* **22** (Suppl): 49-
7 70.
- 8 Al-Faleh W (2009) A radiographic study on the prevalence of knife-edge residual alveolar ridge at proposed
9 dental implant sites. *Saudi Dental Journal* **21**:23-7.
- 10 Alt K (1987). Zahnerkrankungen sind schon tausende von Jahren alt. *Zahnärztliche Mitteilungen* **77**: 2274-87.
- 11 Atwood DA (1962). Some clinical factors related to rate of resorption of residual ridges. *The Journal of*
12 *Prosthetic Dentistry* **12**: 441-50.
- 13 Atwood DA (1963). Postextraction changes in the adult mandible as illustrated by microradiographs of
14 midsagittal sections and cephalometric roentgenograms. *The Journal of Prosthetic Dentistry* **13**: 810-24.
- 15 Atwood DA (1971). Reduction of Residual Rides: A Major Oral Disease Entity. *The Journal of Prosthetic*
16 *Dentistry* **26**: 266-79.
- 17 Atwood DA (1973). Reduction of residual ridges in the partially edentulous patient. *Dental Clinics of North*
18 *America* **17**: 747-54.
- 19 Atwood DA (1979). Bone Loss of Edentulous Alveolar Ridges. *Journal of Periodontology* **50**: 11-21.
- 20 Bays RA, Weinstein RS (1982) Systemic bone disease in patients with mandibular atrophy. *J Oral Maxillofac*
21 *Surg* **40**:270-2.
- 22 Bodic F, Hamel L, Lerouxel E, Baslé MF, Chappard D (2005). Bone Loss and Teeth - Review. *Joint Bone Spine.*
23 **72**: 215-21.
- 24 Bollen AM, Taguchi A, Hujuel PP, Hollender LG (2004) Number of teeth and residual alveolar ridge height in
25 subjects with a history of self-reported osteoporotic fractures. *Osteoporos Int* **15**:970-4.
- 26 Bras J (1990). Mandibular Atrophy and Metabolic Bone Loss. *International Dental Journal* **40**: 298-302.
- 27 Budtz-Jørgensen E (1996). Restoration of the partially edentulous mouth — a comparison of overdentures,
28 removable partial dentures, fixed partial dentures and implant treatment. *Journal of Dentistry* **24**: 237-44.
- 29 Campbell RL (1960). A comparative study of the resorption of the alveolar ridges in denture-wearers and non-
30 denture-wearers. *Journal of the American Dental Association* **60**: 143-53.
- 31 Carlsson GE, Ragnarson N, Astrand P (1969). Changes in height of the alveolar process in edentulous segments.
32 II. A longitudinal clinical and radiographic study over 5 years of full upper denture patients with residual lower
33 anteriors. *Swedish Dental Journal* **62**: 125-36.
- 34 Carlsson GE (2004). Responses of jawbone to pressure. *Gerodontology* **21**: 65-70.
- 35 Cawood JI, Howell RA (1988). A Classification of the Edentulous Jaws. *International Journal of Oral and*
36 *Maxillofacial Surgery* **17**: 232-6.
- 37 Coulthard P, Esposito M, Worthington HV, Jokstad A (2002). Interventions for replacing missing teeth:
38 preprosthetic surgery versus dental implants. *Cochrane Database of Systematic Reviews*; 4, Art. No.: CD003604.
39 DOI: 10.1002/14651858.CD003604.
- 40 Denissen HW, Kalk W, Veldhuis HA, van Waas MA (1993). Anatomic Considerations for Preventive
41 Implantation. *The International Journal of Oral and Maxillofacial Implants* **8**: 191-6.
- 42 Devlin H & Ferguson MW (1991). Alveolar Ridge Resorption and Mandibular Atrophy - A Review of the Role
43 of Local and Systemic Factors. *British Dental Journal* **170**: 101-4.
- 44 Devlin H, Horner K (2007) A study to assess the relative influence of age and edentulousness upon mandibular
45 bone mineral density in female subjects. *Oral Surg Oral Med Oral Pathol Oral Radiol Endod* **104**:117-21.
- 46 Esposito M, Grusovin MG, Coulthard P, Worthington HV (2006). The efficacy of various bone augmentation
47
48
49
50

- 1
2 procedures for dental implants: a Cochrane systematic review of randomized controlled clinical trials.
3 *International Journal of Oral and Maxillofacial Implants*. **2**: 696-710.
- 4 Felton DA (2009) Edentulism and comorbid factors. *J Prosthodont* **18**:88-96.
- 5 Fenlon MR, Sherriff M (2008). An investigation of factors influencing patients' satisfaction with new complete
6 dentures using structural equation modelling. *Journal of Dentistry* **36**: 427-34.
- 7 Ferembach D, Schwidetzky I, Stloukal M (1979). Empfehlungen für die Alters- und Geschlechtsdiagnose am
8 Skelett. *Homo* **30**: 1-32.
- 9 Frost HM (2003). Bone's Mechanostat: A 2003 Update. *Anatomic Record, Part A: Discoveries in Molecular,
10 Cellular and Evolutionary Biology* **275**: 1081-101.
- 11 Großschmidt K (1990). Paläopathologische Untersuchungen an den menschlichen Skeletten des
12 awarenzeitlichen Gräberfeldes Csokorgasse in Wien Simmering. PhD [dissertation]. University of Vienna.
- 13 Gruber H, Solar P, Ulm C (1993). Anatomie und atrophiebedingte Veränderungen der Kieferknochen. In:
14 Watzek G, ed. Enossale Implantationen in der oralen Chirurgie. Berlin: Quintessenz. p 29-62.
- 15 Heydecke G, Thomason JM, Lund JP, Feine JS (2005). The impact of conventional and implant supported
16 prostheses on social and sexual activities in edentulous adults: Results from a randomized trial 2 months after
17 treatment. *Journal of Dentistry* **33**: 649-57.
- 18 Hildebolt CF (1997) Osteoporosis and oral bone loss. *Dentomaxillofac Radiol* **26**:3-15.
- 19 Hirai T, Ishijima T, Hashikawa Y, et al. (1993) Osteoporosis and reduction of residual ridge in edentulous
20 patients. *J Prosthet Dent* **69**:49-56.
- 21
22
23 Jokstad A, Carr A, Esposito M, Coulthard P, Worthington HV (2002a). Interventions for replacing missing teeth:
24 partially absent dentition (Protocol). *Cochrane Database of Systematic Reviews*; 3. Art. No.: CD003814. DOI:
25 10.1002/14651858.CD003814.
- 26 Jokstad A, Carr A, Esposito M, Coulthard P, Worthington HV (2002b). Interventions for replacing missing teeth:
27 totally absent dentition (Protocol). *Cochrane Database of Systematic Reviews*; 2. Art. No.: CD003810. DOI:
28 10.1002/14651858.CD003810.
- 29 Kingsmill VJ (1999). Post-extraction remodeling of the adult mandible. *Critical Reviews in Oral Biology and
30 Medicine* **10**: 384-404.
- 31 Klemetti E, Vainio P, Lassila V, Alhava E (1993a) Trabecular bone mineral density in the mandible and alveolar
32 height in post-menopausal women. *Scand J Dent Res* **101**:166-70.
- 33 Klemetti E, Vainio P, Lassila V, et al. (1993b) Cortical bone mineral density in the mandible and osteoporosis
34 status in postmenopausal women. *Scand J Dent Res* **101**:219-23.
- 35
36 Kordatzis K, Wright PS, Meijer HJ (2003). Posterior Mandibular Residual Ridge Resorption in Patients with
37 Conventional Dentures and Implant Overdentures. *The International Journal of Oral and Maxillofacial Implants*
38 **18**: 447-52.
- 39 Kribbs PJ, Smith DE, Chesnut CH III (1983) Oral findings in osteoporosis. Part II: Relationship between
40 residual ridge and alveolar bone resorption and generalized skeletal osteopenia. *J Prosthet Dent* **50**:719-24.
- 41 Lammie GA (1960). The Reduction of the Edentulous Ridges. *The Journal of Prosthetic Dentistry* **10**: 605-11.
- 42 Lindh C, Petersson A, Klinge B (1995). Measurements of distances related to the mandibular canal in
43 radiographs. *Clinical Oral Implants Research* **6**: 96-103.
- 44 Meinel A, Rottensteiner GM, Huber CD, Tangl S, Watzek G, Watzek G (2009). Caries frequency and distribution
45 in an early medieval Avar population from Austria. *Oral Dis* [Epub ahead of print].
- 46 Meller C, Urzua I, Moncada G, von Ohle C (2009). Prevalence of oral pathologic findings in an ancient pre-
47 Columbian archeological site in the Atacama Desert. *Oral Dis* **15**: 287-294.
- 48 Nakamoto RY (1968). Bony Defects on the Crest of the Residual Alveolar Ridge. *The Journal of Prosthetic
49 Dentistry* **20**: 100-104.

- 1
2 *Dentistry* **19**: 111-8.
- 3 Neufeld JO (1958). Changes in the Trabecular Pattern of the Mandible Following the Loss of Teeth *The Journal*
4 *of Prosthetic Dentistry* **8**: 685-97.
- 5 Neukam FW, Kloss FR (2001). Compromised jawbone quantity and its influence on oral implant placement. In:
6 Zarb G, Lekholm U, Albrektsson T, Tenenbaum H, ed. *Aging, Osteoporosis and dental implants*. Chicago:
7 Quintessence. p85-97.
- 8 Nicopoulou-Karayianni K, Tzoutzoukos P, Mitsea A, Karayiannis A, Tsiklakis K, Jacobs R, Lindh C, van der
9 Stelt P, Allen P, Graham J, Horner K, Devlin H, Pavitt S, Yuan J (2009). Tooth loss and osteoporosis: the
10 OSTEODENT Study. *J Clin Periodontol* **36**:190-7.
- 11 Nishimura I, Atwood DA (1994). Knife-edge Residual Ridges: A Clinical Report. *The Journal of Prosthetic*
12 *Dentistry* **71**: 231-4.
- 13 Pan S, Awad M, Thomason JM, Dufresne E, Kobayashi T, Kimoto S, Wollin SD, Feine JS (2008). Sex
14 differences in denture satisfaction. *Journal of Dentistry* **36**: 301-8.
- 15 Pietrokovski J (1975). The Bony Residual Ridge in Man. *The Journal of Prosthetic Dentistry* **34**: 456-62.
- 16 Pietrokovski J, Starinsky R, Arensburg B, Kaffe I (2007). Morphologic Characteristics of Bony Edentulous
17 Jaws. *Journal of Prosthodontics* **16**: 141-7.
- 18 Rabel A, Köhler SG, Schmidt-Westhausen AM (2007). Clinical study on the Primary Stability of Two Dental
19 Implant Systems with Resonance Frequency Analysis. *Clinical Oral Investigations* **11**: 257-65.
- 20 [Rawlinson SC, McKay IJ, Ghuman M, Wellmann C, Ryan P, Prajaneh S, Zaman G, Hughes FJ, Kingsmill VJ](#)
21 [\(2009\). Adult rat bones maintain distinct regionalized expression of markers associated with their development.](#)
22 [PLoS One 4:e8358.](#)
- 23 Rocchietta I, Fontana F, Simion M (2008). Clinical outcomes of vertical bone augmentation to enable dental
24 implant placement: a systematic review. *Journal of Clinical Periodontology* **35**: 203-15.
- 25 Şahin S, Çehreli MC, Yalçın E (2002). The influence of functional forces on the biomechanics of implant-
26 supported prostheses – a review. *Journal of Dentistry* **30**: 271-82.
- 27 Sennerby L, Carlsson GE, Bergman B, Warfvinge J (1988). Mandibular Bone Resorption in Patients Treated
28 With Tissue-Integrated Prostheses and in Complete Denture-Wearers. *Acta Odontologica Scandinavica* **46**: 135-
29 40.
- 30 Slagter KW, Raghoobar GM, Vissink A (2008) Osteoporosis and edentulous jaws. *Int J Prosthodont* **21**:19-26.
- 31 Solar P, Aro G, Ulm C, Bernhart T (1998). Die Auswirkungen des Zahnverlustes auf die Anatomie der Maxilla.
32 *Schweizer Monatsschrift für Zahnmedizin* **108**: 871-5.
- 33 Sutton DN, Lewis BRK, Patel M, Cawood JI (2004). Changes in Facial Form Relative to Progressive Atrophy of
34 the Edentulous Jaws. *International Journal of Oral and Maxillofacial Surgery* **33**: 676-82.
- 35 Tallgren A (1972). The Continuing Reduction of the Residual Alveolar Ridges in Complete Denture Wearers: A
36 Mixed-Longitudinal Study Covering 25 years. *The Journal of Prosthetic Dentistry* **27**: 120-32.
- 37 Tallgren A, Lang BR, Walker GF, Ash MM Jr (1980). Roentgen Cephalometric Analysis of the Ridge
38 Resorption and Changes in Jaw and Occlusal Relationships in Immediate Complete Denture Wearers. *Journal of*
39 *Oral Rehabilitation* **7**: 77-94.
- 40 Thoma KH (1959). Progressive Atrophie des Unterkiefers und ihre Behandlung. *Deutsche Zahn-, Mund- und*
41 *Kieferheilkunde* **31**: 248-61.
- 42 Trulsson U, Engstrand P, Berggren U, Nannmark U, Branemark P-I (2002). Edentulousness and Oral
43 Rehabilitation: Experiences from the Patients' perspective. *European Journal of Oral Sciences* **110**: 417-24.
- 44 Ulm C, Pechmann U, Ertl L, Gruber H, Solar P, Matejka M (1989). Anatomische Untersuchungen an der
45 atrophien Mandibula. Teil 1. Die Lage des Canalis mandibulae im atrophien Unterkiefer. *Zeitschrift für*
46 *Stomatologie* **86**: 491-503.

- 1
2 Ulm CW, Solar P, Blahout R, Matejka M, Watzek G, Gruber H (1993). Location of the mandibular canal within
3 the atrophic mandible. *British Journal of Oral and Maxillofacial Surgery* **31**: 370-5.
4 Ulm CW, Solar P, Gsellmann B, Matejka M, Watzek G (1995). The Edentulous Maxillary Alveolar Process in
5 the Region of the Maxillary Sinus - A Study of Physical Dimensions. *International Journal of Oral and*
6 *Maxillofacial Surgery* **24**: 279-82.
7 Ulm CW., Kneissel M, Hahn M, Solar P, Matejka M, Donath K (1997). Characteristics of the Cancellous Bone
8 of Edentulous Mandibles. *Clinical Oral Implants Research* **8**: 125-30.
9 Ulm C, Tepper G, Blahout R, Rausch-Fan X, Hienz S, Matejka M (2009). Characteristic features of trabecular
10 bone in edentulous mandibles. *Clinical Oral Implants Research* **20**: 594-600.
11 Vodanovic´ M, Brikic´ H, Salus M, Demo Z (2005). The Frequency and Distribution of Caries in the Mediaeval
12 Population of Bijelo Brdo in Croatia (10th-11th Century). *Archives of Oral Biology* **50**: 669-80.
13 Watt ME, Lunt DA, Gilmour WH (1997). Caries Prevalence in the Permanent Dentition of a Mediaeval
14 Population from the South-West of Scotland. *Archives of Oral Biology* **42**: 601-20.
15 [White TD, Folkens PA \(1999\). Human Osteology. Oxford: Elsevier Ltd.](#)
16 Wolff J (1892). The Law of Bone Remodeling. (English translation of Wolff's Das Gesetz der Transformation
17 der Knochen by Maquet P. & Furlong R. in 1986) Berlin: Springer.
18 Xie Q, Närhi TO, Nevalainen JM, Wolf J, Ainamo A (1997a). Oral Status and Prosthetic Factors Related to
19 Residual Ridge Resorption in Elderly Subjects. *Acta Odontologica Scandinavica* **55**: 306-13.
20 Xie Q, Wolf J, Tilvis R, Ainamo A (1997b). Resorption of mandibular canal wall in the edentulous aged
21 population. *J Prosthet Dent* **77**:596-600.
22 Yüzügüllü B, Gulsahi A, Imirzalioglu P (2009) Radiomorphometric indices and their relation to alveolar bone
23 loss in completely edentulous Turkish patients: A retrospective study. *J Prosth Dent* **101**:160-5.
24
25
26
27
28
29
30
31
32
33
34
35
36
37
38
39
40
41
42
43
44
45
46
47
48
49
50
51
52
53
54
55
56
57
58
59
60

Tables

Table 1: Age and sex distribution of the analysed historical sample consisting of 263 individuals.

Age group	female		male		total (both sexes)	
	N	%	N	%	N	%
20-40 years	70	57.9%	69	48.6%	139	52.9%
41-60 years	22	18.2%	58	40.8%	80	30.4%
61-80 years	29	24.0%	15	10.6%	44	16.7%
all age groups	121	46.0%	142	54.0%	263	100%

Deleted: 69

Deleted: 5

Deleted: 3

Deleted: 2

Deleted: 120

Deleted: 5

Deleted: 8

Deleted: 2

Table 2: Frequency distribution of the features *exposed trabecular bone* and *bony defects* stages I to III in the jaw segments of young (20-40yrs), middle-aged (41-60yrs) and old individuals (61-80yrs).

Age group	Trab. bone	Mandible				Maxilla				Defects	Mandible				Maxilla			
		anterior		posterior		anterior		posterior			anterior		posterior		anterior		posterior	
		N	%	N	%	N	%	N	%		N	%	N	%	N	%	N	%
20-40 years	I	0	0%	5	26.3%	0	0%	4	28.6%	I	1	33.3%	3	15.8%	0	0%	7	50%
	II	1	50%	4	21.1%	1	50%	0	0%	II	2	66.7%	13	68.4%	1	100%	3	21.4%
	III	1	50%	10	52.6%	1	50%	10	71.4%	III	0	0%	3	15.8%	0	0%	4	28.6%
	Total	2	100%	19	100%	2	100%	14	100%	Total	3	100%	19	100%	1	100%	14	100%
41-60 years	I	3	21.4%	10	22.2%	2	22.2%	1	3.4%	I	7	50%	11	24.4%	6	66.7%	11	37.9%
	II	7	50%	8	17.8%	2	22.2%	1	3.4%	II	7	50%	17	37.8%	3	33.3%	4	13.8%
	III	4	28.6%	27	60%	5	55.6%	27	33.1%	III	0	0%	17	37.8%	0	0%	14	48.3%
	Total	14	100%	45	100%	9	100%	29	100%	Total	14	100%	45	100%	9	100%	29	100%
61-80 years	I	7	31.8%	23	54.8%	4	30.8%	6	25%	I	9	40.9%	15	35.7%	11	78.6%	4	17.4%
	II	13	59.1%	8	19%	3	23.1%	4	16.7%	II	10	45.5%	16	38.1%	3	21.4%	6	26.1%
	III	2	9.1%	11	26.2%	6	46.2%	14	58.3%	III	3	13.6%	11	26.2%	0	0%	13	56.5%
	Total	22	100.0%	42	100%	13	100%	24	100%	Total	22	100.0%	42	100%	14	100%	23	100%

Trabecular bone: Stage I=closed cortical layer, stage II=exposed trabecular bone \leq 2mm in width, stage III= exposed trabecular bone \geq 2mm in width.

Defects: Stage I=no defects, stage II=small defects, stage III= large defects.

Table 3: Frequency distribution of the features *concave depression* stages I and II in the jaw segments of young (20-40yrs), middle-aged (41-60yrs) and old individuals (61-80yrs).

Age group	Concavity	Mandible				Maxilla			
		anterior		posterior		anterior		posterior	
		N	%	N	%	N	%	N	%
20-40 yrs	I	2	100%	9	47.4%	0	0%	8	57.1%
	II	0	0%	10	52.6%	1	100%	6	42.9%
	Total	2	100%	19	100%	1	100%	14	100%
41-60 yrs	I	12	85.7%	15	33.3%	7	77.8%	11	37.9%
	II	2	14.3%	30	66.7%	2	22.2%	18	62.1%
	Total	14	100%	45	100%	9	100%	29	100%
61-80 yrs	I	15	68.2%	15	35.7%	12	85.7%	12	52.2%
	II	7	31.8%	27	64.3%	2	14.3%	11	47.8%
	Total	22	100.0%	42	100%	14	100%	23	100%

Stage I=no concave depression, stage II=concave depression existent.

Table 4: Cross tabulation demonstrating the interrelationship between atrophy stages and the occurrence of different degrees of exposed trabecular bone at the crest of the residual ridge.

		Mandible anterior						Mandible posterior						
		Atrophy stages						Atrophy stages						
		2	3	4	5	6	Total	2	3	4	5	6	Total	
trabecular bone	I	1	0	9	0	0	10	I	3	1	5	10	19	38
		10%	0%	90%	0%	0%	100%		7.9%	2.6%	13.2%	26.3%	50%	100%
	II	0	3	13	5	0	21	II	1	1	3	10	5	20
		0%	14.3%	61.9%	23.8%	0%	100%		5%	5%	15%	50%	25%	100%
	III	4	0	3	0	0	7	III	18	6	3	18	3	48
		57.1%	0%	42.9%	0%	0%	100%		37.5%	12.5%	6.3%	37.5%	6.3%	100%
Total		5	3	25	5	0	38	Total	22	8	11	38	27	106
%		13.2%	7.9%	65.8%	13.2%	0%	100%	%	20.8%	7.5%	10.4%	35.8%	25.5%	100%

		Maxilla anterior						Maxilla posterior						
		Atrophy stages						Atrophy stages						
		2	3	4	5	6	Total	2	3	4	5	6	Total	
trabecular bone	I	1	3	1	1	0	6	I	4	0	0	1	6	11
		16.7%	50.0%	16.7%	16.7%	0%	100%		36.4%	0%	0%	9.1%	54.5%	100%
	II	0	3	2	1	0	6	II	0	0	0	0	5	5
		0%	50.0%	33.3%	16.7%	0%	100%		0%	0%	0%	0%	100%	100%
	III	6	3	1	1	0	11	III	15	1	2	9	23	50
		54.5%	27.3%	9.1%	9.1%	0%	100%		30%	2%	4%	18%	46%	100%
Total		7	9	4	3	0	23	Total	19	1	2	10	34	66
%		30.4%	39.1%	17.4%	13%	0%	100%	%	28.8%	1.5%	3%	15.2%	51.5%	100%

Atrophy stages: 2=postextraction, 3=high well-rounded, 4=knife-edge, 5=low well-rounded, 6=depressed.
 Trabecular bone: Stage I=closed cortical layer, stage II=exposed trabecular bone ≤ 2mm in width, stage III= exposed trabecular bone ≥ 2mm in width.

Legends to Illustrations

Figure 1: Segments of the jaw according to the classification system of Nakamoto (1968). Mandible: SEG 1 (anterior), SEG 2 / SEG 3 (posterior, right/left). Red arrowheads indicate mental foramina, separating anterior from posterior segments; Maxilla: SEG 4 (anterior): between the two canines, SEG 5 / SEG 6 (posterior, right/left): between the 1st premolar and the tuberosity at the distal end of the alveolar arch. Red arrowheads indicate borderline between canines and 1st premolars.

Figure 2: Classification system of six atrophy stages in the maxilla (A) and the mandible (B) according to Atwood (1963) and Cawood and Howell (1988). Atrophy stage 1: *preextraction*, stage 2: *postextraction*, stage 3: *high well-rounded ridge*, stage 4: *knife-edge shaped ridge*, stage 5: *low well-rounded ridge*, stage 6: *depressed bone level*.

Figure 3: Photographs of two mandibular (right) posterior segments illustrating the differences between the features *exposed trabecular bone* and *bony defects*. (A) Area of exposed trabecular bone at the crest of the residual ridge (small black arrowheads). (B) Bony defects at the crest of the residual ridge (black arrowheads).

Figure 4: Prevalence of atrophy (stages 2 to 6) and of the non-affected state before tooth loss (stage 1) in anterior and posterior segments of the mandible and the maxilla. Jaw segments: le.=left, ri=right, ant.=anterior, post.=posterior, Md.=mandible, Mx.=maxilla.

Figure 5: Frequency distribution of the atrophy stages 2 to 6 (postextraction to depressed bone level) in the jaw segments of young (A), middle-aged (B) and old individuals (C). Due to the low frequency of atrophy in young individuals data were presented as absolute values instead of percents. By this means, the total increase of affected segments is evident. Atrophy stages: 2=*postextraction*, 3=*high well-rounded*, 4=*knife-edge*, 5=*low well-rounded*, 6=*depressed*. Jaw segments: ant.=anterior, post.=posterior, Md.=mandible, Mx.=maxilla.

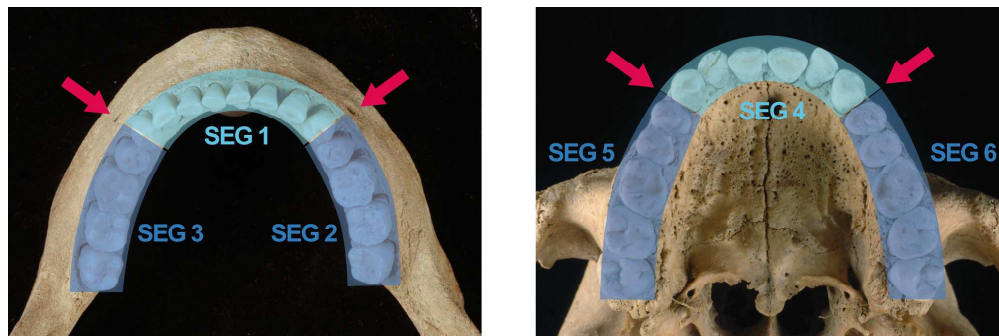


Figure 1: Segments of the jaw according to the classification system of Nakamoto (1968). Mandible: SEG 1 (anterior), SEG 2 / SEG 3 (posterior, right/left), red arrowheads indicate mental foramina, separating anterior from posterior segments; Maxilla: SEG 4 (anterior), SEG 5 / SEG 6 (posterior, right/left), red arrowheads indicate borderline between canines and 1st premolars.
175x58mm (600 x 600 DPI)

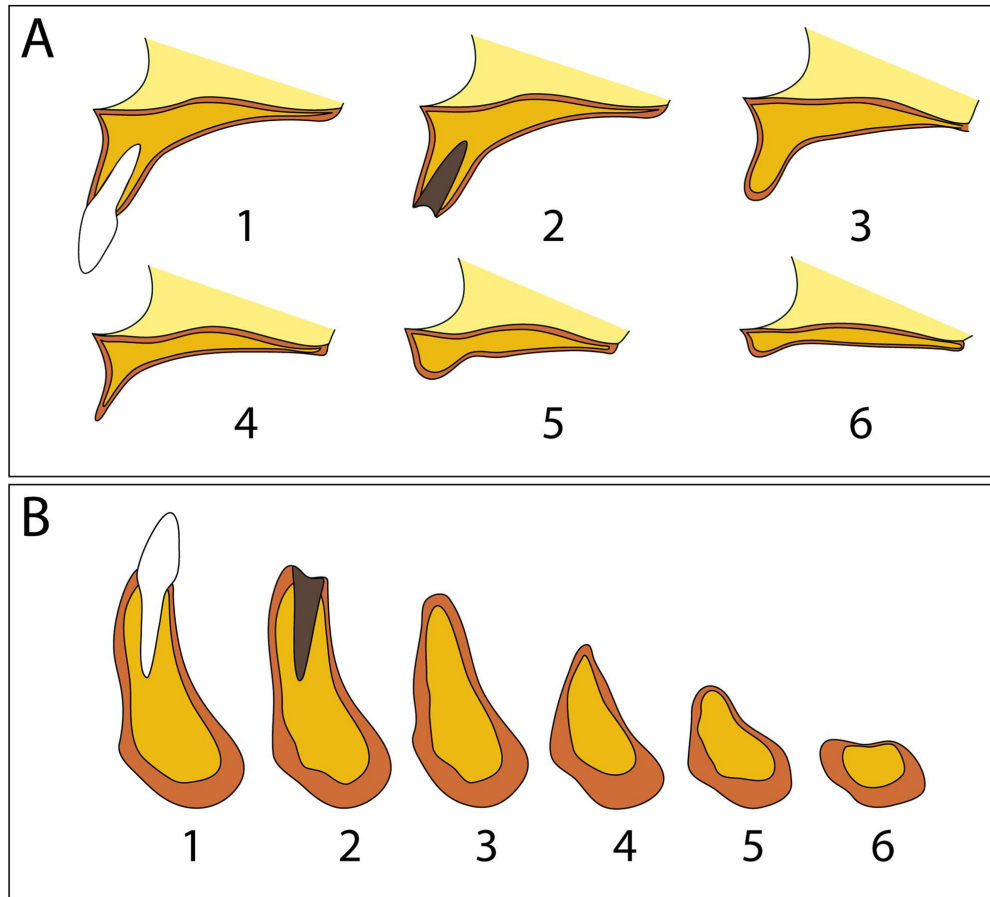


Figure 2: Classification system of six atrophy stages in the maxilla (A) and the mandible (B) according to Atwood (1963) and Cawood and Howell (1988). Atrophy stage 1: preextraction, stage 2: postextraction, stage 3: high well-rounded ridge, stage 4: knife-edge shaped ridge, stage 5: low well-rounded ridge, stage 6: depressed bone level.
85x76mm (600 x 600 DPI)

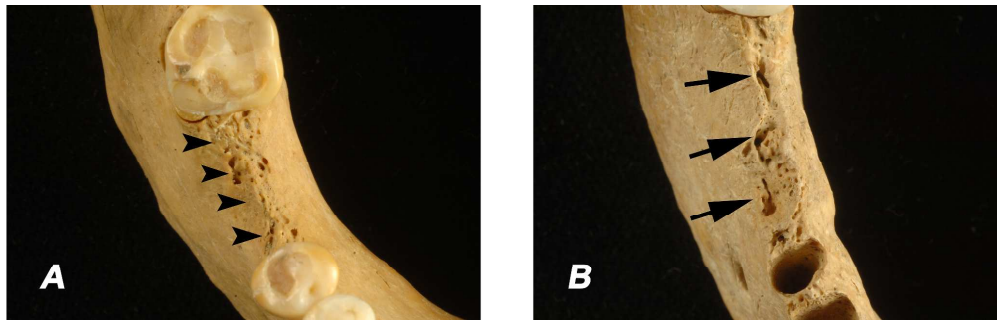


Figure 3: Photographs of two mandibular (right) posterior segments illustrating the differences between the features exposed trabecular bone and bony defects. (A) Area of exposed trabecular bone at the crest of the residual ridge (small black arrowheads). (B) Bony defects at the crest of the residual ridge (black arrowheads).
175x55mm (600 x 600 DPI)

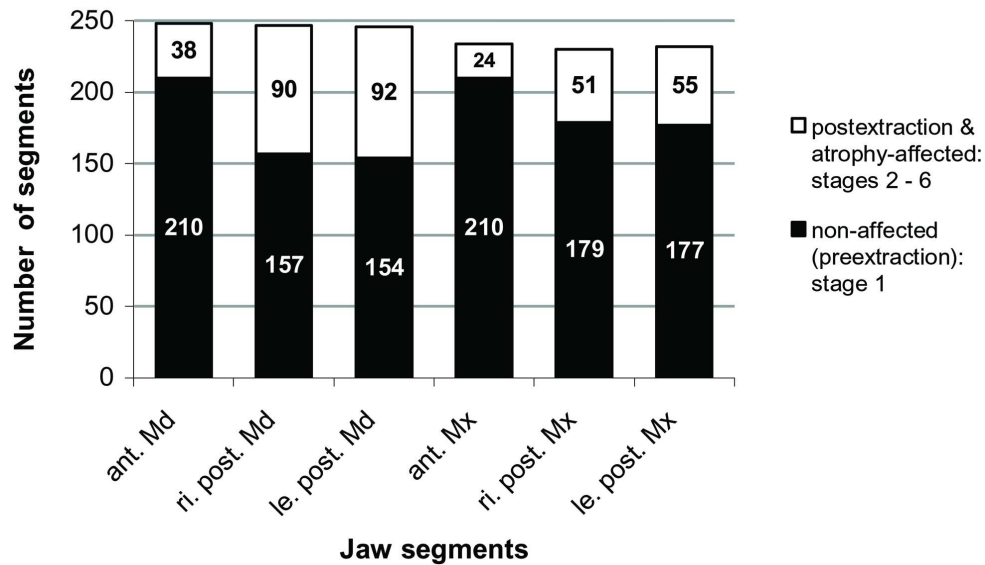


Figure 4: Prevalence of atrophy (stages 2 to 6) and of the non-affected state before tooth loss (stage 1) in anterior and posterior segments of the mandible and the maxilla. Jaw segments: le.=left, ri.=right, ant.=anterior, post.=posterior, Md.=mandible, Mx.=maxilla.
85x50mm (600 x 600 DPI)

1
2
3
4
5
6
7
8
9
10
11
12
13
14
15
16
17
18
19
20
21
22
23
24
25
26
27
28
29
30
31
32
33
34
35
36
37
38
39
40
41
42
43
44
45
46
47
48
49
50
51
52
53
54
55
56
57
58
59
60

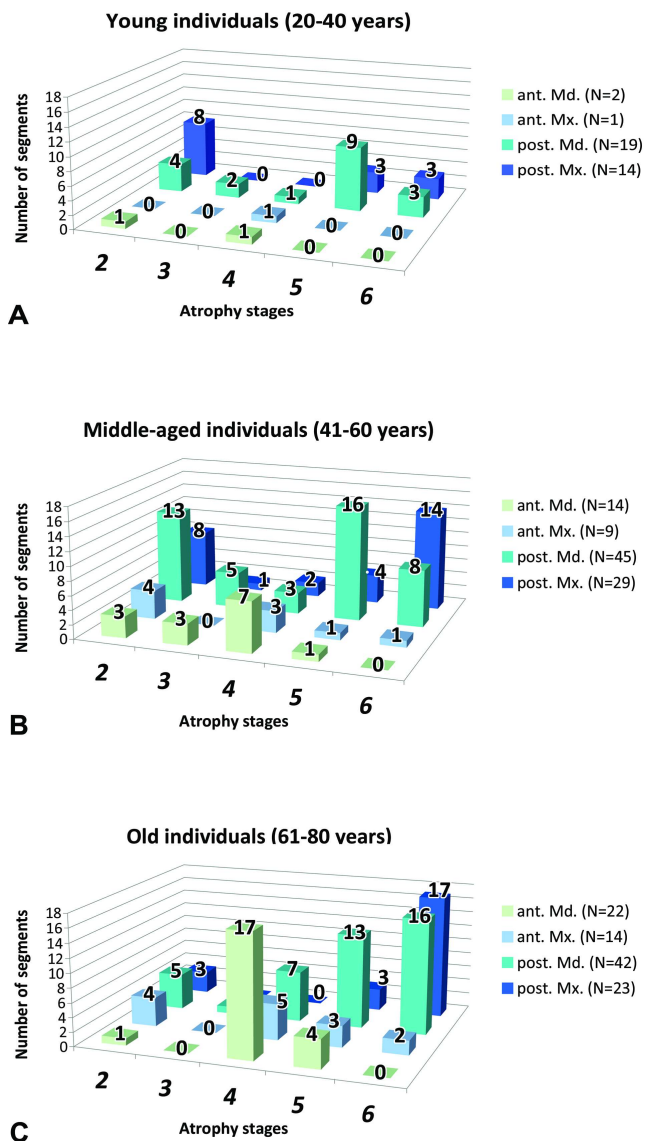


Figure 5: Frequency distribution of the atrophy stages 2 to 6 (postextraction to depressed bone level) in the jaw segments of young (A), middle-aged (B) and old individuals (C). Due to the low frequency of atrophy in young individuals data were presented as absolute values instead of percents. By this means, the total increase of affected segments is evident. Atrophy stages: 2=postextraction, 3=high well-rounded, 4=knife-edge, 5=low well-rounded, 6=depressed. Jaw segments: ant.=anterior, post.=posterior, Md.=mandible, Mx.=maxilla. 85x152mm (600 x 600 DPI)