



HAL
open science

Necrotizing fasciitis - early sonographic diagnosis.

Marek Wronski, Maciej Slodkowski, Włodzimierz Cebulski, Dominika Karkocha, Ireneusz Wojciech Krasnodebski

► **To cite this version:**

Marek Wronski, Maciej Slodkowski, Włodzimierz Cebulski, Dominika Karkocha, Ireneusz Wojciech Krasnodebski. Necrotizing fasciitis - early sonographic diagnosis.. *Journal of Clinical Ultrasound*, 2010, 39 (4), pp.236. 10.1002/jcu.20766 . hal-00599773

HAL Id: hal-00599773

<https://hal.science/hal-00599773>

Submitted on 11 Jun 2011

HAL is a multi-disciplinary open access archive for the deposit and dissemination of scientific research documents, whether they are published or not. The documents may come from teaching and research institutions in France or abroad, or from public or private research centers.

L'archive ouverte pluridisciplinaire **HAL**, est destinée au dépôt et à la diffusion de documents scientifiques de niveau recherche, publiés ou non, émanant des établissements d'enseignement et de recherche français ou étrangers, des laboratoires publics ou privés.



Necrotizing fasciitis – early sonographic diagnosis.

Journal:	<i>Journal of Clinical Ultrasound</i>
Manuscript ID:	JCU-10-057.R1
Wiley - Manuscript type:	Case Report
Keywords:	necrotizing fasciitis, soft tissue infection, ultrasonography, musculoskeletal

SCHOLARONE™
Manuscripts

Review

1
2
3
4
5
6
7
8
9
10
11
12
13
14
15
16
17
18
19
20
21
22
23
24
25
26
27
28
29
30
31
32
33
34
35
36
37
38
39
40
41
42
43
44
45
46
47
48
49
50
51
52
53
54
55
56
57
58
59
60

Title:

Necrotizing fasciitis – early sonographic diagnosis.

Running title:

Necrotizing fasciitis in US

For Peer Review

Abstract

Necrotizing fasciitis is a rare, but potentially fatal bacterial infection of the soft tissues.

Establishing the diagnosis at the early stages of the disease remains the greatest challenge.

[Delay in diagnosis, although still not uncommon, results in high morbidity and mortality.](#)

We report a case of necrotizing fasciitis involving the upper extremity. Sonography revealed

subcutaneous emphysema spreading along the deep fascia, swelling and increased

echogenicity of the overlying fatty tissue with interlacing fluid collections. [The patient](#)

[underwent early surgical exploration and debridement before the development of overt](#)

[necrosis. The patient responded well to early surgical debridement and parenteral antibiotics.](#)

Key words: necrotizing fasciitis, ultrasonography, soft tissue infection, [musculoskeletal](#)

Introduction

Necrotizing fasciitis (NF) is a life-threatening infection of the soft tissues. It is an uncommon and often rapidly progressive infection [of the deep soft structures. Necrotizing fasciitis](#) and may involve any part of the body, but the extremities and perineum are most frequently affected ¹. At its early stages, [NF necrotizing fasciitis](#) is difficult to differentiate from common skin infections such as cellulitis and a high index of clinical suspicion is required. Delay in establishing the correct diagnosis and surgical exploration results in high morbidity and mortality ². Clinical recognition of NF is difficult and imaging studies can prove helpful in suggesting early diagnosis. Computed tomography (CT) and magnetic resonance imaging (MRI) are most frequently used diagnostic tools in patients with suspected necrotizing fasciitis ^{3,4}. Ultrasonography has rarely been used in the recognition of [NF necrotizing fasciitis](#) ⁵⁻⁸.

We report a case of necrotizing fasciitis affecting the right upper extremity after a venipuncture that was diagnosed early based on sonographic findings.

Case report

62-year-old male was admitted to our surgical department because of a gastrointestinal bleeding. His medical history was significant for a recently diagnosed diabetes mellitus. On admission, he was in poor general condition with severe anemia and hypovolemia. Flexible endoscopy revealed a peptic ulcer located in the duodenum. The patient was treated medically with intravenous fluids and omeprazole. He received 4 units of packed red blood cells. A few days later, the patient complained of a small patchy discoloration on the right forearm approximately 5 cm above the venipuncture site. Within the next 24 hours, the skin induration and erythema progressed to involve the whole internal surface of the right forearm and arm and it became extremely painful. The patient was running fever. Crepitus was absent on palpation.

The sonographic examination was performed using a 8-12 MHz linear-array probe (Famio 8, Toshiba, Japan). Ultrasonography showed increased echogenicity of the subcutaneous fatty tissue with interlacing thin anechoic spaces corresponding to perifascial fluid resulting in the cobblestone appearance. There was a gas layer just above the deep fascia with posterior acoustic shadowing (Fig. 1). The subcutaneous emphysema extended a few centimeters beyond the margins of grossly changed skin, but the fatty tissue still appeared normal at that level (Fig. 2). Oblique scans of the upper extremity showed normal muscles without any detectable gas bubbles or fluid collections within the muscular compartments. The sonographic examination suggested the diagnosis of necrotizing fasciitis and therefore the patient underwent urgent surgical exploration. A generous longitudinal incision was made over the affected area. On inspection, the subcutaneous tissue was edematous with discharge of turbid fluid from the cut edges. The perifascial planes had a foamy appearance with crepitations due to gas bubbles. Only a few small necrotic patches were found within the skin and subcutaneous fat and the deep fascia still appeared normal. The tissues were debrided and

1
2
3
4 copiously irrigated. Gram stain of the excised necrotic tissues revealed multiple cocci.

5
6 [However, the cultures taken at the operation were negative, probably due to transportation](#)

7
8 [error.](#) The patient responded well to surgical debridement and parenteral antibiotics. The

9
10 infection was controlled and there was no need for further explorations. Subsequently, the

11
12 skin defects were covered by means of flap plasty.
13
14
15
16
17
18
19
20
21
22
23
24
25
26
27
28
29
30
31
32
33
34
35
36
37
38
39
40
41
42
43
44
45
46
47
48
49
50
51
52
53
54
55
56
57
58
59
60

For Peer Review

Discussion

Necrotizing fasciitis is a progressive and often rapidly spreading infection of the [deep](#) soft tissues. This type of infection was originally reported to affect the genital region and is now known as Fournier's gangrene ⁹. Subsequently, Meleney found [NF necrotizing fasciitis](#) to involve also other body regions ¹⁰. The term of "necrotizing fasciitis" was introduced by Wilson in 1952 ¹¹. Recently, the term of necrotizing soft-tissue infections was proposed to highlight the same treatment strategy in this group of infections ¹².

Necrotizing fasciitis is an infection that spreads along the superficial and deep fascial planes of the soft tissues. The skin and muscles are usually spared at the early stages of the disease. The speed with which the infection progresses depends on the virulence of the causative pathogen and the severity of immune suppression of the host. Necrotizing fasciitis is a synergistic bacterial infection usually due to a mixed flora. Most frequently cultured pathogens are streptococci. Clostridial infections, although commonly suspected, are rarely responsible ¹. [NF necrotizing fasciitis](#) often occurs in patients predisposed to infection because of the underlying chronic disease, especially diabetes mellitus that is a risk factor found in 21-64% of cases ¹. Patients present with severe pain that is often disproportionate to physical findings.

Initially necrotizing fasciitis has an insidious course and its clinical picture may be similar to cellulitis. A hallmark of [NF necrotizing fasciitis](#) is liquefying necrosis of the subcutaneous tissues, fascia, skin and also muscles in severe cases. Purpuric or necrotic areas in the skin indicative of [NF necrotizing fasciitis](#) appear late in the course of the disease and a high index of suspicion is required. The diagnosis of necrotizing fasciitis is a clinical one, but it is often delayed, because the infection begins and progresses in the deep layers of the subcutaneous tissues giving initially a false impression of a typical cellulitis. The provisional diagnosis

1
2
3 based solely on clinical findings is incorrect in 64% cases¹³. Early recognition is essential
4
5 because any delay in the surgical management results in worse prognosis^{2,14}.
6
7

8 Clinical recognition of [NF necrotizing fasciitis](#) is difficult and imaging studies can be helpful
9
10 in suggesting early diagnosis. Radiographic studies are usually used in doubtful cases without
11
12 obvious signs of [NF necrotizing fasciitis](#) such as overt skin necrosis or tissue crepitus.
13
14

15 Radiographic findings in [NF necrotizing fasciitis](#) are similar to those found in cellulitis.
16
17

18 Cellulitis begins and spreads in the superficial layers of the subcutaneous tissues. In contrast,
19
20 [NF necrotizing fasciitis](#) involves deeper structures and the inflammatory changes are more
21
22 severe¹⁵. The subcutaneous emphysema is a distinguishing sign of [NF necrotizing fasciitis](#),
23
24 but crepitus is not always present on palpation. Plain x-rays show subcutaneous emphysema
25
26 when there is a moderate to large amount of gas within the tissues. Although crepitus is found
27
28 on physical examination in 12-36% of patients with [NF necrotizing fasciitis](#), soft tissue gas is
29
30 seen on plain x-ray in 17-57% of patients¹. Tissue emphysema has been generally regarded a
31
32 late finding in necrotizing fasciitis. Our case illustrates, however, that in some cases tissue gas
33
34 might appear early in the course of the disease.
35
36
37

38
39 CT and MRI are frequently used diagnostic tools in patients with suspected necrotizing
40
41 fasciitis. The tomographic findings suggesting [NF necrotizing fasciitis](#) include asymmetric
42
43 fascial thickening, fluid collections along the deep fascia and soft tissue gas⁴. Although MRI
44
45 has a high resolution for soft tissues, its value is limited in necrotizing fasciitis, because the
46
47 patients are often too ill to undergo a timely study. MRI findings such as fluid collections
48
49 along the deep fascial sheath and thickening of the deep fascia with contrast enhancement
50
51 suggest necrotizing fasciitis³. Nevertheless, both CT and MRI have high sensitivity and low
52
53 specificity for [NF necrotizing fasciitis](#)^{3,4,16}.
54
55
56

57
58 The sonographic appearance of necrotizing fasciitis has rarely been reported in the literature⁶⁻
59
60 ^{8,17}. The ultrasound findings suggesting [NF necrotizing fasciitis](#) included thickening of the

1
2
3
4 deep fascia, diffuse thickening of the overlying fatty tissue and a fluid layer of at least 4 mm
5
6 in depth along the deep fascia. Yen et al ⁸ reported a sensitivity of 88,2% and specificity of
7
8 93,3% for ultrasonography in recognition of necrotizing fasciitis using the aforementioned
9
10 criteria. The diagnosis of [NF necrotizing fasciitis](#) is further aided by the detection of gas
11
12 within the soft tissues which is thought to be pathognomonic to necrotizing fasciitis.

13
14
15 The sonographic appearance of [NF necrotizing fasciitis](#) may be similar to cellulitis. In both
16
17 conditions, there is swelling and increased echogenicity of the subcutaneous tissue. In more
18
19 severe cases, the subcutaneous tissue has a so-called cobblestone appearance due to interlaced
20
21 anechoic spaces within the fatty tissue corresponding to fluid collections dissecting along the
22
23 perifascial planes. Nevertheless, fluid spaces tracking along the deep fascia strongly suggest
24
25 the diagnosis of necrotizing fasciitis and are usually not observed in cellulitis ⁶.

26
27
28 In necrotizing fasciitis, the inflammatory changes are usually more severe and located in
29
30 deeper layers than in cellulitis. In our patient, the sonographic diagnosis of necrotizing
31
32 fasciitis was based on the recognition of soft tissue gas and fluid collections dissecting along
33
34 the deep fascia. Soft tissue gas is indicative of necrotizing fasciitis and warrants an urgent
35
36 surgical exploration and debridement. In our patient, the debridement was performed before
37
38 the development of overt necrosis of the deep fascia. The infection was controlled early and
39
40 there was no need for any subsequent debridement procedures.

41
42
43 Our case highlights two essential features of necrotizing fasciitis. Firstly, the subcutaneous
44
45 emphysema may appear early in the course of the disease due to gas-forming bacteria.

46
47
48 Secondly, the inflammation spreads along the deep fascia and extends beyond the margins of
49
50 apparent skin infection.

51
52
53 In conclusion, ultrasonography is an attractive tool for early recognition of necrotizing
54
55 fasciitis, especially due to gas-forming bacteria. The subcutaneous emphysema and fluid
56
57 collections spreading along the deep fascia favor the diagnosis of necrotizing fasciitis. Liberal
58
59
60

1
2
3
4 use of ultrasound evaluation is strongly recommended in patients with atypical or rapidly
5
6 progressive cellulitis in order to detect necrotizing fasciitis at its early stages.
7
8
9
10
11
12
13
14
15
16
17
18
19
20
21
22
23
24
25
26
27
28
29
30
31
32
33
34
35
36
37
38
39
40
41
42
43
44
45
46
47
48
49
50
51
52
53
54
55
56
57
58
59
60

For Peer Review

References:

1. Cunningham JD, Silver L, Rudikoff D. Necrotizing fasciitis: a plea for early diagnosis and treatment. *Mt Sinai J Med* 2001;68(4-5):253.
2. McHenry CR, Piotrowski JJ, Petrinic D, et al. Determinants of mortality for necrotizing soft-tissue infections. *Ann Surg* 1995;221(5):558.
3. Schmid MR, Kossmann T, Duewell S. Differentiation of necrotizing fasciitis and cellulitis using MR imaging. *AJR Am J Roentgenol* 1998;170(3):615.
4. Wysoki MG, Santora TA, Shah RM, et al. Necrotizing fasciitis: CT characteristics. *Radiology* 1997;203(3):859.
5. Hosek WT, Laeger TC. Early diagnosis of necrotizing fasciitis with soft tissue ultrasound. *Acad Emerg Med* 2009;16(10):1033.
6. Tsai CC, Lai CS, Yu ML, et al. Early diagnosis of necrotizing fasciitis by utilization of ultrasonography. *Kaohsiung J Med Sci* 1996;12(4):235.
7. Chao HC, Kong MS, Lin TY. Diagnosis of necrotizing fasciitis in children. *J Ultrasound Med* 1999;18(4):277.
8. Yen ZS, Wang HP, Ma HM, et al. Ultrasonographic screening of clinically-suspected necrotizing fasciitis. *Acad Emerg Med* 2002;9(12):1448.
9. Fournier J. Gangrene foudroyante de la verge. *Semaine Medicale* 1883;3:345.
10. Meleney F. Hemolytic Streptococcus gangrene. *Arch Surg* 1924;9(2):317.
11. Wilson B. Necrotizing fasciitis. *Am Surg* 1952;18(4):416.
12. Anaya DA, Dellinger EP. Necrotizing soft-tissue infection: diagnosis and management. *Clin Infect Dis* 2007;44(5):705.
13. Hefny AF, Eid HO, Al-Hussona M, et al. Necrotizing fasciitis: a challenging diagnosis. *Eur J Emerg Med* 2007;14(1):50.

- 1
- 2
- 3
- 4 14. Majeski J, Majeski E. Necrotizing fasciitis: improved survival with early recognition
- 5
- 6 by tissue biopsy and aggressive surgical treatment. *South Med J* 1997;90(11):1065.
- 7
- 8
- 9 15. Fayad LM, Carrino JA, Fishman EK. Musculoskeletal infection: role of CT in the
- 10
- 11 emergency department. *Radiographics* 2007;27(6):1723.
- 12
- 13 16. Arslan A, Pierre-Jerome C, Borthne A. Necrotizing fasciitis: unreliable MRI findings
- 14
- 15 in the preoperative diagnosis. *Eur J Radiol* 2000;36(3):139.
- 16
- 17
- 18 17. Hanif MA, Bradley MJ. Sonographic findings of necrotizing fasciitis in the breast. *J*
- 19
- 20 *Clin Ultrasound* 2008;36(8):517.
- 21
- 22
- 23
- 24
- 25
- 26
- 27
- 28
- 29
- 30
- 31
- 32
- 33
- 34
- 35
- 36
- 37
- 38
- 39
- 40
- 41
- 42
- 43
- 44
- 45
- 46
- 47
- 48
- 49
- 50
- 51
- 52
- 53
- 54
- 55
- 56
- 57
- 58
- 59
- 60

1
2
3
4 Fig. 1 A transverse ultrasound scan of the forearm shows a hyperechoic layer above the deep
5
6 fascia with posterior acoustic shadowing that corresponds to soft tissue emphysema
7
8 (arrowheads). The overlying fatty tissue has increased echogenicity with interlacing anechoic
9
10 spaces (arrow) representing perifascial fluid spreading along the fascial planes (cobblestone
11
12 appearance). F – fatty tissue.
13
14
15
16
17
18
19

20 Fig. 2 A transverse sonographic image of the arm taken just above the proximal margin of the
21
22 skin induration and erythema demonstrates a hyperechoic foci (arrows) with posterior
23
24 acoustic shadowing above the deep fascia corresponding to gas bubbles. At that level of the
25
26 upper extremity the fatty tissue still appears normal. F – fatty tissue, M - muscles
27
28
29
30
31
32
33
34
35
36
37
38
39
40
41
42
43
44
45
46
47
48
49
50
51
52
53
54
55
56
57
58
59
60

1
2
3
4
5
6
7
8
9
10
11
12
13
14
15
16
17
18
19
20
21
22
23
24
25
26
27
28
29
30
31
32
33
34
35
36
37
38
39
40
41
42
43
44
45
46
47
48
49
50
51
52
53
54
55
56
57
58
59
60

Title:

Necrotizing fasciitis – early sonographic diagnosis.

Running title:

Necrotizing fasciitis in US

For Peer Review

Abstract

Necrotizing fasciitis is a rare, but potentially fatal bacterial infection of the soft tissues.

Establishing the diagnosis at the early stages of the disease remains the greatest challenge.

We report a case of necrotizing fasciitis involving the upper extremity. Sonography revealed subcutaneous emphysema spreading along the deep fascia, swelling and increased echogenicity of the overlying fatty tissue with interlacing fluid collections. The patient responded well to early surgical debridement and parenteral antibiotics.

Key words: necrotizing fasciitis, ultrasonography, soft tissue infection, musculoskeletal

Introduction

Necrotizing fasciitis is a life-threatening infection of the soft tissues. It is an uncommon and often rapidly progressive infection that may involve any part of the body, but the extremities and perineum are most frequently affected¹. At its early stages, necrotizing fasciitis is difficult to differentiate from common skin infections such as cellulitis and a high index of clinical suspicion is required. Delay in establishing the correct diagnosis and surgical exploration results in high morbidity and mortality². Clinical recognition of necrotizing fasciitis is difficult and imaging studies can prove helpful in suggesting early diagnosis. Computed tomography (CT) and magnetic resonance imaging (MRI) are most frequently used diagnostic tools in patients with suspected necrotizing fasciitis^{3,4}. Ultrasonography has rarely been used in the recognition of necrotizing fasciitis⁵⁻⁸.

We report a case of necrotizing fasciitis affecting the right upper extremity after a venipuncture that was diagnosed early based on sonographic findings.

Case report

62-year-old male was admitted to our surgical department because of a gastrointestinal bleeding. His medical history was significant for a recently diagnosed diabetes mellitus. On admission, he was in poor general condition with severe anemia and hypovolemia. Flexible endoscopy revealed a peptic ulcer located in the duodenum. The patient was treated medically with intravenous fluids and omeprazole. He received 4 units of packed red blood cells. A few days later, the patient complained of a small patchy discoloration on the right forearm approximately 5 cm above the venipuncture site. Within the next 24 hours, the skin induration and erythema progressed to involve the whole internal surface of the right forearm and arm and it became extremely painful. The patient was running fever. Crepitus was absent on palpation.

The sonographic examination was performed using a 8-12 MHz linear-array probe (Famio 8, Toshiba, Japan). Ultrasonography showed increased echogenicity of the subcutaneous fatty tissue with interlacing thin anechoic spaces corresponding to perifascial fluid resulting in the cobblestone appearance. There was a gas layer just above the deep fascia with posterior acoustic shadowing (Fig. 1). The subcutaneous emphysema extended a few centimeters beyond the margins of grossly changed skin, but the fatty tissue still appeared normal at that level (Fig. 2). Oblique scans of the upper extremity showed normal muscles without any detectable gas bubbles or fluid collections within the muscular compartments. The sonographic examination suggested the diagnosis of necrotizing fasciitis and therefore the patient underwent urgent surgical exploration. A generous longitudinal incision was made over the affected area. On inspection, the subcutaneous tissue was edematous with discharge of turbid fluid from the cut edges. The perifascial planes had a foamy appearance with crepitations due to gas bubbles. Only a few small necrotic patches were found within the skin and subcutaneous fat and the deep fascia still appeared normal. The tissues were debrided and

1
2
3
4 copiously irrigated. Gram stain of the excised necrotic tissues revealed multiple cocci. The
5
6 patient responded well to surgical debridement and parenteral antibiotics. The infection was
7
8 controlled and there was no need for further explorations. Subsequently, the skin defects were
9
10 covered by means of flap plasty.
11
12
13
14
15
16
17
18
19
20
21
22
23
24
25
26
27
28
29
30
31
32
33
34
35
36
37
38
39
40
41
42
43
44
45
46
47
48
49
50
51
52
53
54
55
56
57
58
59
60

For Peer Review

Discussion

Necrotizing fasciitis is a progressive and often rapidly spreading infection of the soft tissues.

This type of infection was originally reported to affect the genital region and is now known as Fournier's gangrene⁹. Subsequently, Meloney found necrotizing fasciitis to involve also other body regions¹⁰. The term of "necrotizing fasciitis" was introduced by Wilson in 1952¹¹.

Recently, the term of necrotizing soft-tissue infections was proposed to highlight the same treatment strategy in this group of infections¹².

Necrotizing fasciitis is an infection that spreads along the superficial and deep fascial planes of the soft tissues. The skin and muscles are usually spared at the early stages of the disease. The speed with which the infection progresses depends on the virulence of the causative pathogen and the severity of immune suppression of the host. Necrotizing fasciitis is a synergistic bacterial infection usually due to a mixed flora. Most frequently cultured pathogens are streptococci. Clostridial infections, although commonly suspected, are rarely responsible¹. Necrotizing fasciitis often occurs in patients predisposed to infection because of the underlying chronic disease, especially diabetes mellitus that is a risk factor found in 21-64% of cases¹. Patients present with severe pain that is often disproportionate to physical findings.

Initially necrotizing fasciitis has an insidious course and its clinical picture may be similar to cellulitis. A hallmark of necrotizing fasciitis is liquefying necrosis of the subcutaneous tissues, fascia, skin and also muscles in severe cases. Purpuric or necrotic areas in the skin indicative of necrotizing fasciitis appear late in the course of the disease and a high index of suspicion is required. The diagnosis of necrotizing fasciitis is a clinical one, but it is often delayed, because the infection begins and progresses in the deep layers of the subcutaneous tissues giving initially a false impression of a typical cellulitis. The provisional diagnosis

1
2
3 based solely on clinical findings is incorrect in 64% cases¹³. Early recognition is essential
4
5 because any delay in the surgical management results in worse prognosis^{2,14}.
6
7

8
9 Clinical recognition of necrotizing fasciitis is difficult and imaging studies can be helpful in
10
11 suggesting early diagnosis. Radiographic studies are usually used in doubtful cases without
12
13 obvious signs of necrotizing fasciitis such as overt skin necrosis or tissue crepitus.
14

15
16 Radiographic findings in necrotizing fasciitis are similar to those found in cellulitis. Cellulitis
17
18 begins and spreads in the superficial layers of the subcutaneous tissues. In contrast,
19
20 necrotizing fasciitis involves deeper structures and the inflammatory changes are more severe
21
22¹⁵. The subcutaneous emphysema is a distinguishing sign of necrotizing fasciitis, but crepitus
23
24 is not always present on palpation. Plain x-rays show subcutaneous emphysema when there is
25
26 a moderate to large amount of gas within the tissues. Although crepitus is found on physical
27
28 examination in 12-36% of patients with necrotizing fasciitis, soft tissue gas is seen on plain x-
29
30 ray in 17-57% of patients¹. Tissue emphysema has been generally regarded a late finding in
31
32 necrotizing fasciitis. Our case illustrates, however, that in some cases tissue gas might appear
33
34 early in the course of the disease.
35
36
37

38
39 CT and MRI are frequently used diagnostic tools in patients with suspected necrotizing
40
41 fasciitis. The tomographic findings suggesting necrotizing fasciitis include asymmetric fascial
42
43 thickening, fluid collections along the deep fascia and soft tissue gas⁴. Although MRI has a
44
45 high resolution for soft tissues, its value is limited in necrotizing fasciitis, because the patients
46
47 are often too ill to undergo a timely study. MRI findings such as fluid collections along the
48
49 deep fascial sheath and thickening of the deep fascia with contrast enhancement suggest
50
51 necrotizing fasciitis³. Nevertheless, both CT and MRI have high sensitivity and low specificity
52
53 for necrotizing fasciitis^{3,4,16}.
54
55
56

57
58 The sonographic appearance of necrotizing fasciitis has rarely been reported in the literature⁶⁻
59
60^{8,17}. The ultrasound findings suggesting necrotizing fasciitis included thickening of the deep

1
2
3
4 fascia, diffuse thickening of the overlying fatty tissue and a fluid layer of at least 4 mm in
5
6 depth along the deep fascia. Yen et al⁸ reported a sensitivity of 88,2% and specificity of
7
8 93,3% for ultrasonography in recognition of necrotizing fasciitis using the aforementioned
9
10 criteria. The diagnosis of necrotizing fasciitis is further aided by the detection of gas within
11
12 the soft tissues which is thought to be pathognomonic to necrotizing fasciitis.

13
14
15 The sonographic appearance of necrotizing fasciitis may be similar to cellulitis. In both
16
17 conditions, there is swelling and increased echogenicity of the subcutaneous tissue. In more
18
19 severe cases, the subcutaneous tissue has a so-called cobblestone appearance due to interlaced
20
21 anechoic spaces within the fatty tissue corresponding to fluid collections dissecting along the
22
23 perifascial planes. Nevertheless, fluid spaces tracking along the deep fascia strongly suggest
24
25 the diagnosis of necrotizing fasciitis and are usually not observed in cellulitis⁶.

26
27
28 In necrotizing fasciitis, the inflammatory changes are usually more severe and located in
29
30 deeper layers than in cellulitis. In our patient, the sonographic diagnosis of necrotizing
31
32 fasciitis was based on the recognition of soft tissue gas and fluid collections dissecting along
33
34 the deep fascia. Soft tissue gas is indicative of necrotizing fasciitis and warrants an urgent
35
36 surgical exploration and debridement. In our patient, the debridement was performed before
37
38 the development of overt necrosis of the deep fascia. The infection was controlled early and
39
40 there was no need for any subsequent debridement procedures.

41
42
43 Our case highlights two essential features of necrotizing fasciitis. Firstly, the subcutaneous
44
45 emphysema may appear early in the course of the disease due to gas-forming bacteria.

46
47
48 Secondly, the inflammation spreads along the deep fascia and extends beyond the margins of
49
50 apparent skin infection.

51
52
53 In conclusion, ultrasonography is an attractive tool for early recognition of necrotizing
54
55 fasciitis, especially due to gas-forming bacteria. The subcutaneous emphysema and fluid
56
57 collections spreading along the deep fascia favor the diagnosis of necrotizing fasciitis. Liberal
58
59
60

1
2
3
4 use of ultrasound evaluation is strongly recommended in patients with atypical or rapidly
5
6 progressive cellulitis in order to detect necrotizing fasciitis at its early stages.
7
8
9
10
11
12
13
14
15
16
17
18
19
20
21
22
23
24
25
26
27
28
29
30
31
32
33
34
35
36
37
38
39
40
41
42
43
44
45
46
47
48
49
50
51
52
53
54
55
56
57
58
59
60

For Peer Review

References:

1. Cunningham JD, Silver L, Rudikoff D. Necrotizing fasciitis: a plea for early diagnosis and treatment. *Mt Sinai J Med* 2001;68(4-5):253.
2. McHenry CR, Piotrowski JJ, Petrinic D, et al. Determinants of mortality for necrotizing soft-tissue infections. *Ann Surg* 1995;221(5):558.
3. Schmid MR, Kossmann T, Duewell S. Differentiation of necrotizing fasciitis and cellulitis using MR imaging. *AJR Am J Roentgenol* 1998;170(3):615.
4. Wysoki MG, Santora TA, Shah RM, et al. Necrotizing fasciitis: CT characteristics. *Radiology* 1997;203(3):859.
5. Hosek WT, Laeger TC. Early diagnosis of necrotizing fasciitis with soft tissue ultrasound. *Acad Emerg Med* 2009;16(10):1033.
6. Tsai CC, Lai CS, Yu ML, et al. Early diagnosis of necrotizing fasciitis by utilization of ultrasonography. *Kaohsiung J Med Sci* 1996;12(4):235.
7. Chao HC, Kong MS, Lin TY. Diagnosis of necrotizing fasciitis in children. *J Ultrasound Med* 1999;18(4):277.
8. Yen ZS, Wang HP, Ma HM, et al. Ultrasonographic screening of clinically-suspected necrotizing fasciitis. *Acad Emerg Med* 2002;9(12):1448.
9. Fournier J. Gangrene foudroyante de la verge. *Semaine Medicale* 1883;3:345.
10. Meleney F. Hemolytic Streptococcus gangrene. *Arch Surg* 1924;9(2):317.
11. Wilson B. Necrotizing fasciitis. *Am Surg* 1952;18(4):416.
12. Anaya DA, Dellinger EP. Necrotizing soft-tissue infection: diagnosis and management. *Clin Infect Dis* 2007;44(5):705.
13. Hefny AF, Eid HO, Al-Hussona M, et al. Necrotizing fasciitis: a challenging diagnosis. *Eur J Emerg Med* 2007;14(1):50.

- 1
- 2
- 3
- 4 14. Majeski J, Majeski E. Necrotizing fasciitis: improved survival with early recognition
- 5
- 6 by tissue biopsy and aggressive surgical treatment. *South Med J* 1997;90(11):1065.
- 7
- 8
- 9 15. Fayad LM, Carrino JA, Fishman EK. Musculoskeletal infection: role of CT in the
- 10
- 11 emergency department. *Radiographics* 2007;27(6):1723.
- 12
- 13 16. Arslan A, Pierre-Jerome C, Borthne A. Necrotizing fasciitis: unreliable MRI findings
- 14
- 15 in the preoperative diagnosis. *Eur J Radiol* 2000;36(3):139.
- 16
- 17
- 18 17. Hanif MA, Bradley MJ. Sonographic findings of necrotizing fasciitis in the breast. *J*
- 19
- 20 *Clin Ultrasound* 2008;36(8):517.
- 21
- 22
- 23
- 24
- 25
- 26
- 27
- 28
- 29
- 30
- 31
- 32
- 33
- 34
- 35
- 36
- 37
- 38
- 39
- 40
- 41
- 42
- 43
- 44
- 45
- 46
- 47
- 48
- 49
- 50
- 51
- 52
- 53
- 54
- 55
- 56
- 57
- 58
- 59
- 60

1
2
3
4 Fig. 1 A transverse ultrasound scan of the forearm shows a hyperechoic layer above the deep
5
6 fascia with posterior acoustic shadowing that corresponds to soft tissue emphysema
7
8 (arrowheads). The overlying fatty tissue has increased echogenicity with interlacing anechoic
9
10 spaces (arrow) representing perifascial fluid spreading along the fascial planes (cobblestone
11
12 appearance). F – fatty tissue.
13
14
15
16
17
18
19

20 Fig. 2 A transverse sonographic image of the arm taken just above the proximal margin of the
21
22 skin induration and erythema demonstrates a hyperechoic foci (arrows) with posterior
23
24 acoustic shadowing above the deep fascia corresponding to gas bubbles. At that level of the
25
26 upper extremity the fatty tissue still appears normal. F – fatty tissue, M - muscles
27
28
29
30
31
32
33
34
35
36
37
38
39
40
41
42
43
44
45
46
47
48
49
50
51
52
53
54
55
56
57
58
59
60

1
2
3
4
5
6
7
8
9
10
11
12
13
14
15
16
17
18
19
20
21
22
23
24
25
26
27
28
29
30
31
32
33
34
35
36
37
38
39
40
41
42
43
44
45
46
47
48
49
50
51
52
53
54
55
56
57
58
59
60

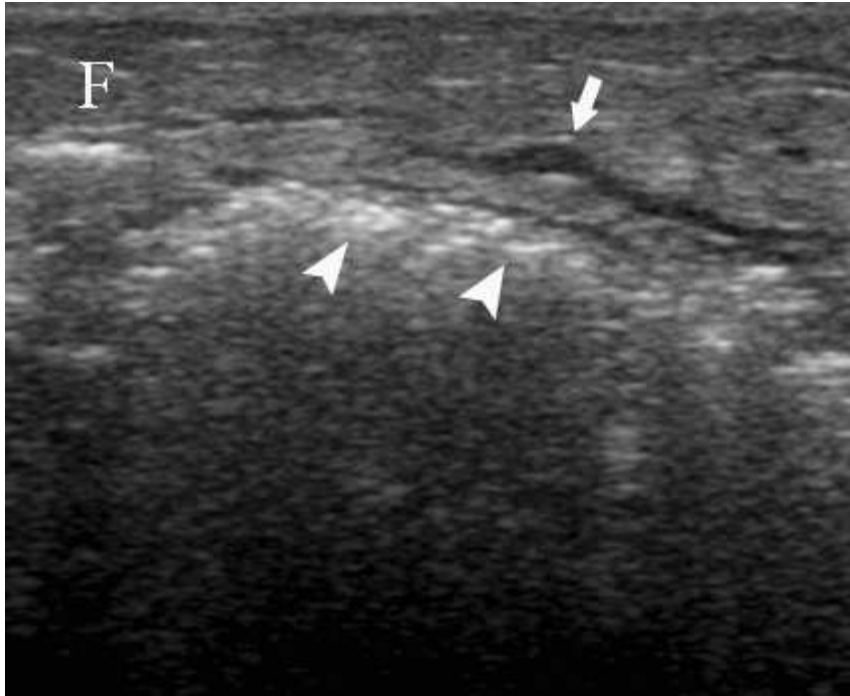


Fig. 1 A transverse ultrasound scan of the forearm shows a hyperechoic layer above the deep fascia with posterior acoustic shadowing that corresponds to soft tissue emphysema (arrowheads). The overlying fatty tissue has increased echogenicity with interlacing anechoic spaces (arrow) representing perifascial fluid spreading along the fascial planes (cobblestone appearance). F – fatty tissue.

35x29mm (300 x 300 DPI)

Review

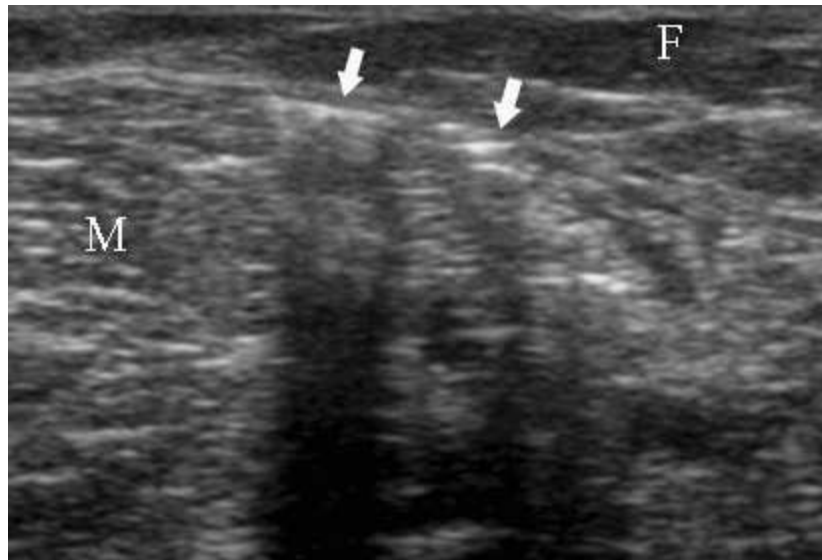


Fig. 2 A transverse sonographic image of the arm taken just above the proximal margin of the skin induration and erythema demonstrates a hyperechoic foci (arrows) with posterior acoustic shadowing above the deep fascia corresponding to gas bubbles. At that level of the upper extremity the fatty tissue still appears normal. F - fatty tissue, M - muscles.
34x23mm (300 x 300 DPI)