



**HAL**  
open science

## **Iodide mumps: Sonographic appearance**

Salvatore Greco, Riccardo Centenaro, Giuseppe Lavecchia, Francesco Rossi

► **To cite this version:**

Salvatore Greco, Riccardo Centenaro, Giuseppe Lavecchia, Francesco Rossi. Iodide mumps: Sonographic appearance. *Journal of Clinical Ultrasound*, 2010, 38 (8), pp.438. <10.1002/jcu.20701>. <hal-00599769>

**HAL Id: hal-00599769**

**<https://hal.science/hal-00599769v1>**

Submitted on 11 Jun 2011

**HAL** is a multi-disciplinary open access archive for the deposit and dissemination of scientific research documents, whether they are published or not. The documents may come from teaching and research institutions in France or abroad, or from public or private research centers.

L'archive ouverte pluridisciplinaire **HAL**, est destinée au dépôt et à la diffusion de documents scientifiques de niveau recherche, publiés ou non, émanant des établissements d'enseignement et de recherche français ou étrangers, des laboratoires publics ou privés.



HAL Authorization



### Iodide mumps: Sonographic appearance

Journal:	<i>Journal of Clinical Ultrasound</i>
Manuscript ID:	JCU-09-235.R1
Wiley - Manuscript type:	Case Report
Keywords:	ultrasound, submandibular glands, iodide mumps



Review

## Case report

### Iodide mumps: Sonographic appearance

#### Abstract

Swelling of the salivary glands occurring after injection of iodine based contrast agent is a rare late adverse reaction. Only few cases in the literature illustrate such ultrasound findings.

#### Case report

A 38-year-old man with recurrent pneumonia was referred for CT thoracic study. The patient had no past history of allergy. CT was performed after intravenous injection of 120 ml of the low osmolality contrast agent (120 ml Ultravist, Schering).

At the end of CT the patient had any symptom. After 18 hours of the CT scan, he presented with painful submandibular swelling. Physical examination revealed bilateral tender swelling of submandibular glands aching to light palpation and during the salivation. No evidence of laryngeal edema or bronchospasm was apparent. Routine laboratory test were unremarkable.

We performed high-resolution sonography of the submandibular space with 7-13 MHz linear probe of Aloka  $\alpha$ 10. The ultrasound findings were diffuse bilateral swelling of submandibular glands and internal low echoic thick septa that most likely represent prominent ducts (Figure 1). Power Doppler sonography used to examine tissue blood flow showed moderate increase of vascular flow, particularly in middle part of submandibular glands (Figure 2). Thyroid and parotid glands were normal.

Approximately 48 h after contrast agent administration, after short cycle of oral prednisone, sonography of the submandibular space showed well-capsulated glandular structure with uniform homogeneous parenchymal echopattern and no significant increase of vascular flow.

## Discussion

Swelling of the submandibular, sublingual, and parotid is an uncommon complication associated with intravascular administration of contrast agents. This reaction was called “iodide mumps” by Sussman and Miller [1] in 1956, although only few cases had been reported [2,3]. Iodide mumps is syndrome due to excessive intake or injection of iodine and iodine-containing compounds. This is known as iodism and includes inflammatory swelling of the salivary glands, coryza, skin erythema, facial nerve paralysis and other more severe systemic reactions [4].

To our knowledge, this is a rare case of description of sonographic appearance of iodide mumps: enlarged and hyperechoic parenchymal pattern with prominent ducts and hypervascularity of glands are expression of bilateral submandibular swelling.

The cause remains unclear but the reaction seems to be related to toxic accumulation of iodide in the ductal system of the salivary glands. Indeed we know that about 98% of injected iodide is eliminated by the kidneys and only 2% is excreted from other organs, such as salivary, sweat and lacrimal glands. Salivary gland swelling is caused in part by the ability of these glands to store high levels of inorganic iodide, with subsequent inflammatory phenomenon of the glands [5].

The onset of signs and symptoms varies from within a few minutes to up to 5 days after contrast agent administration. The prognosis of iodide mumps is relatively benign.

Current treatment for iodide mumps is supportive therapy and administration of anti-inflammatory agents [6]. For patients who do not respond use of hemodialysis to reduce blood levels of contrast agent and iodide may be necessary [2,7].

1  
2  
3 Although iodide mumps is a rare late adverse reaction to the intravascular administration of  
4  
5 iodine containing contrast material, ultrasound findings may be worthwhile to recognize this  
6  
7 entity.  
8  
9

- 10  
11  
12  
13  
14  
15 1. Sussman RM, Miller J. Iodide “mumps” after intravenous urography. *N Engl J Med*  
16  
17 1956;255:433-34  
18
- 19  
20 2. Berman HL, Delaney V. Iodide mumps due to low-osmolality contrast material. *AJR Am J*  
21  
22 *Roentgenol* 1992;159:1099-100  
23
- 24  
25 3. Park SJ, Hong HS, Lee HK et al. Ultrasound findings of iodide mumps. *Br J Radiol*  
26  
27 2005;78:164-65  
28
- 29  
30 4. Haynes RC Jr. Thyroid and antithyroid drugs. In: Gilman AG, Rall TW, Nies AS, Taylor P,  
31  
32 eds. *Goodman and Gillman’s the pharmacological basis of therapeutics*. New York:  
33  
34 Pergamon; 1990: 1361-83  
35
- 36  
37 5. Kohri K, Miyoshi S, Nagahara A et al. Bilateral parotid enlargement (“iodide mumps”)  
38  
39 following excretory urography. *Radiology* 1977;122:654  
40
- 41  
42 6. Waugh WH. Use of cortisone by mouth in prevention and therapy of severe iodism. *Arch*  
43  
44 *Intern Med* 1954;93:299-303  
45
- 46  
47 7. Lang JH, Lasser EC, Talner LB et al. Inorganic iodide in contrast media. *Invest Radiol*  
48  
49 1974;9:51-55  
50  
51  
52  
53  
54  
55  
56  
57  
58  
59  
60

1  
2  
3 Figure 1  
4

5 Axial sonogram shows diffuse bilateral swelling of submandibular glands and internal low  
6  
7  
8 echoic thick septa  
9

10  
11  
12 Figure 2  
13

14 Axial Power Doppler sonogram shows moderate increase of vascular flow, particularly in  
15  
16  
17 middle part of submandibular glands  
18  
19  
20  
21  
22  
23  
24  
25  
26  
27  
28  
29  
30  
31  
32  
33  
34  
35  
36  
37  
38  
39  
40  
41  
42  
43  
44  
45  
46  
47  
48  
49  
50  
51  
52  
53  
54  
55  
56  
57  
58  
59  
60

For Peer Review

## Case report

### [Ultrasonographic evaluation of iodide mumps]

#### Iodide mumps: Sonographic appearance

##### Abstract

Swelling of the salivary glands occurring after injection of iodine based contrast agent is a rare late adverse reaction. Only few cases in the literature illustrate such ultrasound findings.

##### Case report

A 38-year-old man with recurrent pneumonia was referred for CT thoracic study. The patient had no past history of allergy. CT was performed after intravenous injection of 120 ml of the low osmolality contrast agent (120 ml Ultravist, Schering).

At the end of CT the patient had any symptom. After 18 hours of the CT scan, he presented with painful submandibular swelling [complained of thin pain caused by salivation and progressive swelling of submandibolar area]. Physical examination revealed bilateral tender swelling of [his] submandibolar glands aching to light palpation and during the salivation. No evidence of laryngeal edema or bronchospasm was apparent. Routine laboratory test were unremarkable.

We performed [ultrasound of the neck] high-resolution sonography of the submandibular space with 7-13 MHz linear probe of Aloka  $\alpha$ 10. The ultrasound findings were diffuse bilateral swelling of submandibular glands and internal low echoic thick septa that most likely represent prominent ducts (Figure 1). [Colour] Power Doppler sonography [ultrasound] used to examine tissue blood flow showed

1  
2  
3 moderate increase of vascular flow, particularly in middle part of submandibular  
4 glands (Figure 2). Thyroid and parotid glands were normal.

5  
6  
7  
8 Approximately 48 h after contrast agent administration, after short cycle of oral  
9 prednisone, sonography of the submandibular space showed well-capsulated  
10 glandular structure with uniform homogeneous parenchymal echopattern and no  
11 significant increase of vascular flow [the swelling of his submandibular glands  
12 progressively decreased towards normal aspect].  
13  
14  
15  
16  
17  
18

## 19 20 21 22 **Discussion**

23 Swelling of the submandibular, sublingual, and parotid is an uncommon complication  
24 associated with intravascular administration of contrast agents. This reaction was  
25 called “iodide mumps” by Sussman and Miller [1] in 1956, although only few cases  
26 had been reported [2,3]. Iodide mumps is syndrome due to excessive intake or  
27 injection of iodine and iodine-containing compounds. This is known as iodism and  
28 includes inflammatory swelling of the salivary glands, coryza, skin erythema, facial  
29 nerve paralysis and other more severe systemic reactions [4].  
30  
31  
32  
33  
34  
35  
36  
37  
38  
39

40  
41 To our knowledge, this is a rare case of description of sonographic appearance of  
42 iodide mumps: enlarged and hyperechoic parenchymal pattern with prominent ducts  
43 and hypervascularity of glands are expression of bilateral submandibular swelling.  
44  
45  
46  
47

48 The cause remains unclear but the reaction seems to be related to toxic accumulation  
49 of iodide in the ductal system of the salivary glands. Indeed we know that about 98%  
50 of injected iodide is eliminated by the kidneys and only 2% is excreted from other  
51 organs, such as salivary, sweat and lacrimal glands. Salivary gland swelling is caused  
52 in part by the ability of these glands to store high levels of inorganic iodide, with  
53 subsequent inflammatory phenomenon of the glands [5].  
54  
55  
56  
57  
58  
59  
60

1  
2  
3 The onset of signs and symptoms varies from within a few minutes to up to 5 days  
4  
5 after contrast agent administration. The prognosis of iodide mumps is relatively  
6  
7 benign.  
8  
9

10 Current treatment for iodide mumps is supportive therapy and administration of anti-  
11  
12 inflammatory agents [6]. For patients who do not respond use of hemodialysis to  
13  
14 reduce blood levels of contrast agent and iodide may be necessary [2,7].  
15  
16

17 Although iodide mumps is a rare late adverse reaction to the intravascular  
18  
19 administration of iodine containing contrast material, ultrasound findings may be  
20  
21 worthwhile to recognize this entity.  
22  
23  
24  
25  
26  
27  
28

- 29 1. Sussman RM, Miller J. Iodide “mumps” after intravenous urography. *N Engl J*  
30  
31 *Med* 1956;255:433-34  
32  
33
- 34 2. Berman HL, Delaney V. Iodide mumps due to low-osmolality contrast material.  
35  
36 *AJR Am J Roentgenol* 1992;159:1099-100  
37  
38
- 39 3. Park SJ, Hong HS, Lee HK et al. Ultrasound findings of iodide mumps. *Br J Radiol*  
40  
41 [2005] 2005;78:164-65  
42  
43
- 44 4. Haynes RC Jr. Thyroid and antithyroid drugs. In: Gilman AG, Rall TW, Nies AS,  
45  
46 Taylor P, eds. *Goodman and Gillman’s the pharmacological basis of therapeutics*.  
47  
48 New York: Pergamon; 1990: 1361-83  
49  
50
- 51 5. Kohri K, Miyoshi S, Nagahara A et al. Bilateral parotid enlargement (“iodide  
52  
53 mumps”) following excretory urography. *Radiology* 1977;122:654  
54  
55
- 56 6. Waugh WH. Use of cortisone by mouth in prevention and therapy of severe  
57  
58 iodism. *Arch Intern Med* 1954;93:299-303  
59  
60
7. Lang JH, Lasser EC, Talner LB et al. Inorganic iodide in contrast media. *Invest*  
*Radiol* 1974;9:51-55

1  
2  
3  
4  
5  
6  
7  
8 **Figure 1**

9  
10 Axial sonogram shows diffuse bilateral swelling of submandibular glands and  
11  
12 internal low echoic thick septa  
13  
14

15  
16  
17 **Figure 2**

18  
19 Axial power Doppler sonogram shows moderate increase of vascular flow,  
20  
21 particularly in middle part of submandibular glands  
22  
23  
24  
25  
26  
27  
28  
29  
30  
31  
32  
33  
34  
35  
36  
37  
38  
39  
40  
41  
42  
43  
44  
45  
46  
47  
48  
49  
50  
51  
52  
53  
54  
55  
56  
57  
58  
59  
60

1  
2  
3  
4  
5  
6  
7  
8  
9  
10  
11  
12  
13  
14  
15  
16  
17  
18  
19  
20  
21  
22  
23  
24  
25  
26  
27  
28  
29  
30  
31  
32  
33  
34  
35  
36  
37  
38  
39  
40  
41  
42  
43  
44  
45  
46  
47  
48  
49  
50  
51  
52  
53  
54  
55  
56  
57  
58  
59  
60

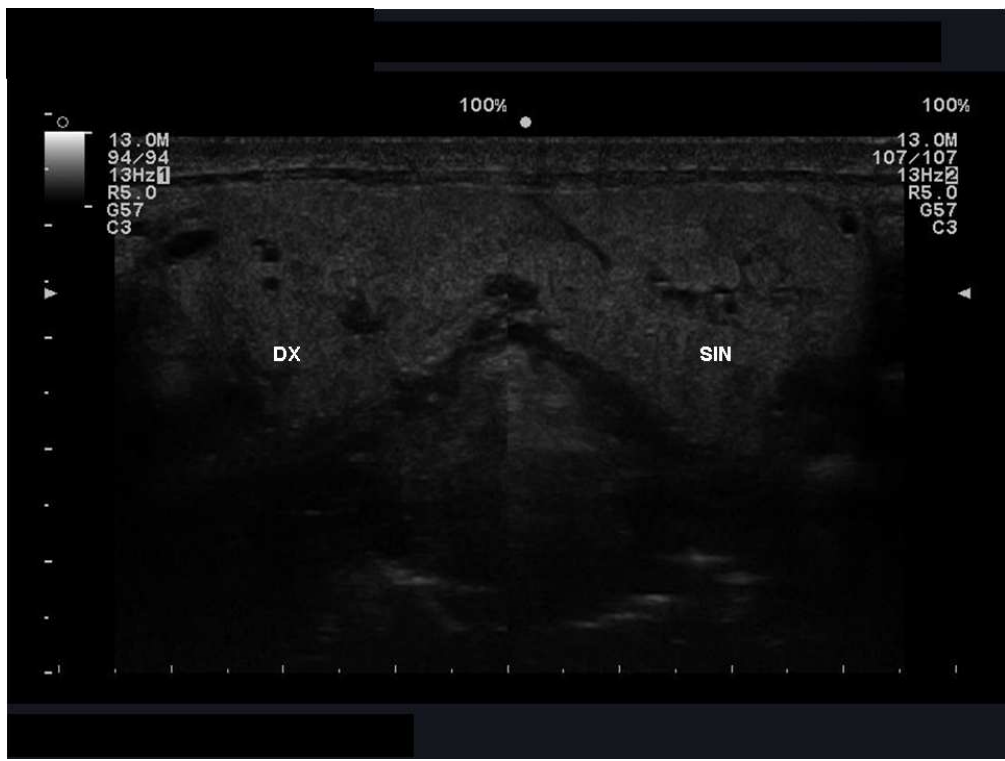

Figure 1

Axial sonogram shows diffuse bilateral swelling of submandibular glands and internal low echogenic thick septa

1  
2  
3  
4  
5  
6  
7  
8  
9  
10  
11  
12  
13  
14  
15  
16  
17  
18  
19  
20  
21  
22  
23  
24  
25  
26  
27  
28  
29  
30  
31  
32  
33  
34  
35  
36  
37  
38  
39  
40  
41  
42  
43  
44  
45  
46  
47  
48  
49  
50  
51  
52  
53  
54  
55  
56  
57  
58  
59  
60

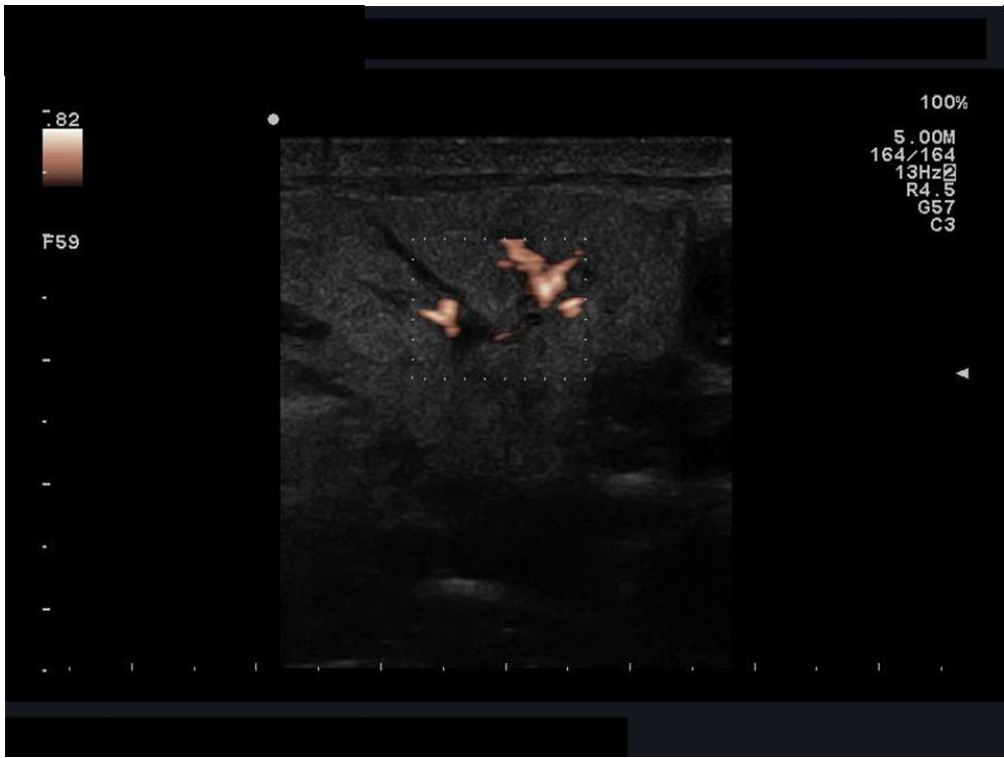


Figure 2

Axial Power Doppler sonogram shows moderate increase of vascular flow, particularly in middle part of submandibular glands

view