



HAL
open science

Review Article: Medical, surgical and radiological management of perianal Crohn's fistulas

Phil Tozer, David Burling, Arun Gupta, Robin K Phillips, Ailsa Hart

► To cite this version:

Phil Tozer, David Burling, Arun Gupta, Robin K Phillips, Ailsa Hart. Review Article: Medical, surgical and radiological management of perianal Crohn's fistulas. *Alimentary Pharmacology and Therapeutics*, 2010, 33 (1), pp.5. 10.1111/j.1365-2036.2010.04486.x . hal-00599506

HAL Id: hal-00599506

<https://hal.science/hal-00599506>

Submitted on 10 Jun 2011

HAL is a multi-disciplinary open access archive for the deposit and dissemination of scientific research documents, whether they are published or not. The documents may come from teaching and research institutions in France or abroad, or from public or private research centers.

L'archive ouverte pluridisciplinaire **HAL**, est destinée au dépôt et à la diffusion de documents scientifiques de niveau recherche, publiés ou non, émanant des établissements d'enseignement et de recherche français ou étrangers, des laboratoires publics ou privés.

**Review Article: Medical, surgical and radiological
management of perianal Crohn's fistulas**

Journal:	<i>Alimentary Pharmacology & Therapeutics</i>
Manuscript ID:	APT-0668-2010.R1
Wiley - Manuscript type:	Review Article
Date Submitted by the Author:	24-Sep-2010
Complete List of Authors:	Tozer, Phil; St Mark's Hospital, Surgery Burling, David; St Mark's Hospital, Intestinal Imaging Gupta, Arun; St Mark's Hospital, Intestinal Imaging Phillips, Robin; St Mark's Hospital, Surgery Hart, Ailsa; St Mark's Hospital, IBD Unit
Keywords:	Crohn's disease < Disease-based, Peri-anal disorders < Disease-based, Biologics (IBD) < Topics, Surgery < Topics, Radiology/imaging < Topics

Review Article: Medical, surgical and radiological management of perianal Crohn's fistulas

Philip J Tozer MBBS*†, David Burling MD*, Arun Gupta MD*, Robin KS Phillips MS*, Ailsa L Hart PhD*†.

*St Mark's Hospital, London, UK and Imperial College London, UK

†Antigen Presenting Research Group, Imperial College London, UK

Correspondence address:

Dr A Hart

Inflammatory Bowel Disease Unit

St Mark's Hospital

Watford Road

Harrow

Middlesex

HA1 3UJ

Tel. 02088695808 Fax. 02082354045 email. ailsa.hart@nwlh.nhs.uk

Acknowledgements: P Tozer would like to acknowledge the support of Core, for Crohn's and the St Mark's Foundation who have funded elements of his fistula work.

Abstract

Background

Crohn's anal fistulas are common and cause considerable morbidity. Their management is often difficult; medical and surgical treatments rarely lead to true healing with frequent recurrence and complications.

Aim

In this review, we examine medical treatments previously and currently used, surgical techniques and the important role of optimal imaging.

Methods

We conducted a literature search in the Pub Med database using Crohn's, Anal Fistula, Surgery, Imaging and Medical Treatment as search terms.

Results

Antibiotics and immunosuppressants have a role but slow initial response, side effects and relatively low remission rates of up to around a third with frequent recurrence limit their value. Long term infliximab produces clinical remission in 36-58% of patients with combined medical and surgical management achieving optimal outcomes. Traditional and newer surgical procedures often have a high rate of recurrence with a significant risk of temporary or, in up to 10% of cases, permanent stomas, incontinence and unhealed or slowly healing wounds in 30%.

Conclusions

Management of Crohn's anal fistulae remains challenging. Established principles are to drain infection, use setons as required, aggressively manage active proctitis, give antibiotics, immunosuppressants, and employ anti TNF α therapy

1
2
3
4
5
6
7
8
9
10
11
12
13
14
15
16
17
18
19
20
21
22
23
24
25
26
27
28
29
30
31
32
33
34
35
36
37
38
39
40
41
42
43
44
45
46
47
48
49
50
51
52
53
54
55
56
57
58
59
60

and they demand significant co-operation between gastroenterologists and surgeons.

Key words: perianal fistula, Crohn's disease, MRI, infliximab, surgery

For Peer Review

The scale of the problem

Perianal Crohn's disease is particularly distressing, it is difficult to treat and unfortunately occurs in around a third of all patients with Crohn's disease ¹, one study supplying a cumulative risk of anal fistula of 26% at 20 years ². **In a small proportion of patients with Crohn's disease, anal fistula is their initial manifestation.** One third of patients have recurring anal fistulas and two thirds of them have multiple fistulas ³. An early series of patients from **a tertiary referral centre** found low fistulas (superficial, low intersphincteric or low trans-sphincteric) represented 46 of 73 (63%), whereas 25 (35%) were high intersphincteric, high trans-sphincteric or suprasphincteric fistulas and the remaining 2 were extrasphincteric ⁴.

Fistula classification

Low intersphincteric fistulas, low transphincteric fistulas and those with a single track with no extensions or complicating abscesses are classified as 'simple'. Complex fistulas have extensions, high tracks (whether intersphincteric, transphincteric or suprasphincteric) involve the vagina or have an associated stricture or proctitis ⁵. The differentiation between simple and complex has prognostic relevance. Complexity, **historically at least**, worsens the prognosis, reduces the chance of healing and threatens continence ³. As yet no medical trials have randomized specifically based on complexity of fistula. Perhaps contrary to expectation, **a more recent** prospective cohort of patients with

1
2
3 perianal Crohn's disease treated with anti-TNF α antibodies showed no relation
4
5 between fistula complexity and the likelihood of healing with biologic agents ⁶.
6
7

8
9
10 The Montreal classification has recognised that perianal disease requires a
11
12 separate subclassification because it is distinct from and is not usually
13
14 associated with internal fistulating/penetrating disease ⁷. This classification
15
16 guides management and may have an aetiological basis.
17
18

19 20 21 22 23 24 25 ***Predisposing factors*** 26

27
28
29 Males, patients with distal disease, those who have a younger age of onset of
30
31 Crohn's disease, non Caucasians and Sephardic (as opposed to Ashkenazi)
32
33 Jews are all at higher risk of developing perianal Crohn's disease ⁸⁻¹¹.
34
35
36
37
38
39

40 41 42 ***Differential diagnoses*** 43

44
45 As previously discussed, a small group of patients with Crohn's disease present
46
47 with an anal fistula ³. In this situation the presentation of luminal and perianal
48
49 disease is often contemporaneous but sometimes the anal fistula presents
50
51 weeks, months or years before the evolution of luminal disease and in a few
52
53 cases the finding of non-caseating granulomas in specimens from anal fistula
54
55 surgery is the only evidence of Crohn's disease in a patient otherwise free from
56
57 symptoms throughout their life.
58
59
60

1
2
3
4
5
6 Isolated perianal Crohn's disease and Crohn's disease in evolution may then
7
8 prompt an incorrect diagnosis of cryptoglandular fistula in some cases. Other
9
10 causes of fistulae include as cancer, radiation, trauma and hidradenitis
11
12 suppurativa.
13
14

17 ***Hidradenitis Suppurativa***

20
21 Hidradenitis suppurativa (HS) is associated with perianal Crohn's disease, can
22
23 coexist with it and causes diagnostic difficulty in some patients. The clinical and
24
25 histological features of the two diseases can be similar and it is possible to
26
27 confuse HS with Crohn's perianal sepsis or with the cutaneous manifestations of
28
29 Crohn's. Early series highlighted the diagnostic difficulty^{12,13}; the presence of
30
31 granulomas in the submucosal layer of cutaneous biopsies led to a diagnosis of
32
33 Crohn's disease but the appearance of abscesses in the axillae suggested HS
34
35 and subsequent intestinal inflammation confirmed the dual diagnoses.
36
37 Epithelioid granulomas were subsequently shown also to exist in patients with
38
39 HS alone¹⁴. Further series reinforced the association between HS and perianal
40
41 Crohn's disease and the potential for missing one or other diagnosis as well as
42
43 describing the outcome for these patients in whom (in one series) 22 of 24 had a
44
45 stoma and 17 had undergone proctectomy^{15,16}. Further evidence of a link
46
47 between the diseases comes from two case reports in which concurrent luminal
48
49 Crohn's and HS responded to treatment with infliximab with improvement in all
50
51 sites of HS^{17,18}.
52
53
54
55
56
57
58
59
60

1
2
3
4
5
6 Clinical and radiological features may be valuable in distinguishing the two
7
8 diseases. The presence of abscesses at other sites including the groin and
9
10 axillae are clearly suggestive of HS, as are multiple sinus tracts and fistulae,
11
12 especially when they lack a clear focus on the anorectum. Severe disease at
13
14 onset rather than a gradual natural history is also suggestive of HS. Case
15
16 reports in the literature suggest that MRI may be valuable; skin thickening and
17
18 subcutaneous induration away from the perianal area, subcutaneous abscesses
19
20 remote from the rectum or anus, enlarged inguinal lymph nodes and no
21
22 communication with pelvic organs are consistent with HS rather than Crohn's
23
24 anal fistulae ¹⁹.

32 ***Implication of anal fistulas on Crohn's disease course***

33
34
35
36
37 Patients with Crohn's disease with perianal involvement are more likely to have a
38
39 severe disease course. Beaugerie and colleagues in 2006 reported that perianal
40
41 lesions at diagnosis were associated with a more disabling course in addition to
42
43 factors such as age below 40 years at onset or need for steroids for the first flare
44
45 of disease ²⁰. Lakatos and colleagues in 2009 reported that perianal disease (in
46
47 addition to other factors such as small bowel disease, smoking, prior steroid or
48
49 early azathioprine/biological therapy) is a predictor of disease behaviour change
50
51 (from inflammatory to stricturing or penetrating) over time in patients with Crohn's
52
53 disease ²¹.

1
2
3
4
5
6 In 2003, before many patients were treated with biologic agents, a group of 78
7
8 Crohn's patients with anal fistulas treated at St Mark's Hospital were assessed
9
10 and at long term follow up 76% of fistulas had healed, 16% were persistent and
11
12 7% had a seton in situ. Median time to healing was 44 months with a median of
13
14 3 (simple) or 6 (complex) treatments per patient ³.
15
16
17
18
19
20

21 ***Assessment of perianal Crohn's disease***

22
23
24
25 There are three ways to assess a patient with perianal Crohn's disease besides
26
27 history and physical examination:
28
29
30
31

- 32 1) endoscopy, for evaluating proximal luminal disease and in particular the state
33
34 of the rectum;
- 35
36 2) local imaging with MRI or anal endosonography;
- 37
38
39 3) examination under anaesthesia with surgical drainage of any abscesses and
40
41 seton placement as required.
42
43
44
45

46 These assessment methods are generally complementary and are often
47
48 undertaken in combination. Endoscopy will assist in diagnosis and map the
49
50 extent and severity of the known case. Additional small bowel imaging may be
51
52 used to fully map the disease.
53
54
55
56
57
58
59
60

1
2
3 Pelvic MRI has been shown to be the most accurate method for classification of
4 primary track and extensions ²², although anal ultrasound, particularly when
5 enhanced by hydrogen peroxide, can occasionally be useful for detecting the
6 internal opening where uncertainty exists. Anal ultrasound (in combination with
7 anorectal physiology tests) can also assess sphincter integrity and function to
8 inform an optimal surgical strategy. However, ultrasound will not reliably identify
9 ischioanal fossa or supralelevator sepsis due to rapidly declining resolution with
10 distance from the probe. Furthermore, there is considerable variation in operator
11 expertise and insertion of the ultrasound probe may be very uncomfortable in the
12 setting of active sepsis, or impossible with stenosis.
13
14
15
16
17
18
19
20
21
22
23
24
25
26
27
28

29 On the other hand, MRI can be performed without a radiologist needing to be
30 present at the time the test is done. Sequential images are easier to compare,
31 particularly when monitoring treatment. Interpretation is more intuitive and the
32 strategic view is better, which can be helpful intra-operatively. However, the test
33 is expensive and the internal opening is less well seen (its position is usually
34 inferred), and some patients feel claustrophobic in the confined space of the MRI
35 scanner.
36
37
38
39
40
41
42
43
44
45
46
47

48 As well as being diagnostic, examination under anaesthetic (EUA) by an
49 experienced surgeon allows infection to be drained and either definitive surgery
50 (lay open or other curative procedures) or placement of a temporary loose seton
51 for drainage while medical management is optimised. However, injudicious
52
53
54
55
56
57
58
59
60

1
2
3 probing may cause iatrogenic tracks, increasing the complexity of the fistula and
4
5 therefore the risk of recurrence or subsequent incontinence.
6
7
8

9
10 In 2001 Schwartz and colleagues reported 34 patients with perianal Crohn's
11 disease taking part in a prospective study comparing the accuracy of 3 methods,
12 EUS, early generation MRI and EUA. There was good agreement between all
13 three. EUS had 91% accuracy, MRI 87% accuracy and EUA 91% accuracy. A
14 combination of any 2 methods yielded an accuracy of 100% ²³. Two years
15 earlier, Orsoni and colleagues had detected more abscesses and fistulas in 22
16 Crohn's patients when using EUS compared to MRI ²⁴. However the quality of
17 MRI in this era was relatively poor.
18
19
20
21
22
23
24
25
26
27
28
29
30
31

32 A later blinded study at St Mark's hospital comparing clinical examination, EUS
33 and MRI was undertaken in 104 patients ²⁵. Classification of fistula, presence of
34 secondary tracts/abscesses and the site of internal openings were all most
35 accurately assessed at MRI. For example, tract accuracy was 90% with MRI,
36 81% with ultrasound and 61% with clinical examination. The question of which
37 modality is best for discriminating simple and complex fistulas was specifically
38 addressed using established Evidence Based Practice principals by Sahni and
39 colleagues in 2008 ²². They found that MRI is the superior technique with
40 sensitivity and specificity of 97% and 96% compared with 92% and 85% for anal
41 ultrasound and 75% and 64% for clinical examination. MRI remains the bed rock
42 of fistula imaging at St Mark's, partly for this reason, partly because the surgeons
43
44
45
46
47
48
49
50
51
52
53
54
55
56
57
58
59
60

1
2
3 and gastroenterologists are able to interpret them themselves to some degree in
4
5 theatre or in clinic, and partly because, as a more objective (less operator
6
7 dependent) examination, MRI also facilitates serial assessment and comparison
8
9 of images over different time points.
10
11

12 13 14 15 16 ***Treatment of perianal Crohn's disease*** 17

18
19
20 The established principles are to drain infection, use setons as required,
21
22 aggressively manage active proctitis, give antibiotics, immunosuppressants, and
23
24 employ anti TNF α therapy and they demand significant co-operation between
25
26 gastroenterologists and surgeons.
27
28

29
30
31
32 Few patients improve without any therapy (10% in the placebo arms of the early
33
34 trials)²⁶⁻²⁸. Also, improving, either spontaneously or with treatment, is not the
35
36 same as being cured. The majority of recent medical trials (particularly those
37
38 assessing the anti-TNF α agents) use clinical assessments of healing i.e. Fistula
39
40 Drainage Assessment, where response is defined as a reduction of 50% or more
41
42 from baseline in the number of draining fistulas observed at 2 or more
43
44 consecutive study visits \geq 4 weeks apart^{5,27,29}. A fistula is considered to be
45
46 closed when it no longer drains despite gentle finger compression at
47
48 examination. Remission is defined as the absence of any draining fistulas at two
49
50 consecutive visits. However, studies utilising MRI findings as a more rigorous
51
52 end-point of deep tissue healing, rather than simply closure of external openings,
53
54
55
56
57
58
59
60

1
2
3 demonstrate undrained sepsis in these patients who, in turn, are very likely to
4
5 recur or develop more complex sepsis ⁶.
6
7
8
9

10 11 ***Corticosteroids*** 12 13

14
15 There is no demonstrable role for corticosteroids in perianal Crohn's disease,
16
17 although corticosteroids are sometimes used to treat concomitant luminal
18
19 disease.
20
21
22
23

24 25 ***Metronidazole and ciprofloxacin*** 26 27

28
29 Both metronidazole and ciprofloxacin demonstrate slow and incomplete
30
31 response, early recurrence and unwanted side effects. In an uncontrolled series,
32
33 Bernstein and colleagues reported 21 patients with perianal Crohn's disease
34
35 treated with Metronidazole 20mg per kg daily ²⁹. All had less discomfort and 10
36
37 of 18 (56%) had complete clinical healing. Improvement typically occurred after
38
39 6 to 8 weeks. Brandt and colleagues followed up 17 of these patients and added
40
41 another 9 ³⁰. Three quarters relapsed on stopping metronidazole and side
42
43 effects including peripheral neuropathy and nausea limited long term use.
44
45 Jakobovtis and colleagues reported clinical healing in 33 to 50% of
46
47 metronidazole-treated patients ³¹.
48
49
50
51
52
53
54
55
56
57
58
59
60

1
2
3 Ciprofloxacin has been used in a small open series. Turunen and colleagues in
4
5 1989 reported 8 patients with perianal fistulating Crohn's disease resistant to
6 metronidazole; all improved but half had persistent drainage ³². Solomon and
7
8 colleagues reported 14 patients with perianal Crohn's disease treated with both
9 metronidazole and ciprofloxacin with approximately two thirds of patients
10 responding ³³. Metronidazole has been compared with ciprofloxacin or placebo
11
12 in a small randomized double-blind placebo-controlled pilot study reported in
13 2008 ³⁴. Twenty five patients with perianal Crohn's disease were randomised to
14 ciprofloxacin 500mg twice a day or metronidazole 500mg twice a day or placebo
15 twice a day and were treated for ten weeks. Clinical remission and response
16 rates were 30% and 40% with Ciprofloxacin, 0% and 14% with Metronidazole
17 and 12.5% and 12.5% with placebo, none of these differences being significant.
18
19 There were no differences seen in the scores of PDAI, CDAI, IBDQ, and patient
20 and physician global assessment at any time point during the study.
21
22
23
24
25
26
27
28
29
30
31
32
33
34
35
36
37

38 Overall, antibiotics remain a mainstay of treatment for perianal Crohn's disease
39 despite the lack of controlled trial evidence. If metronidazole is used, a dose of
40 750–1500 mg/day is suggested. Adverse events include metallic taste, glossitis,
41 nausea and neuropathy. It should be discontinued if any signs of neuropathy
42 occur, but generally therapy is continued for 3–4 months. If ciprofloxacin is used,
43 a dose of 500–1000 mg/day is adequate and again is usually required for 3-4
44 months. Adverse events include headache, diarrhoea, nausea and rash.
45
46
47
48
49
50
51
52
53
54
55
56
57
58
59
60

Immunomodulators

There are no controlled trials using the immunomodulators azathioprine and 6MP with fistula outcome assessed as primary end points. Efficacy is suggested by a meta-analysis of controlled trials in which fistulas were assessed as secondary end points. This meta analysis reports a clinical fistula response of 54% in the azathioprine/6MP group compared with 21% in the placebo group³⁵. There are two uncontrolled case series (one in children) that have been reported^{36,37}. The larger series by Korelitz and Present in 1985 included 18 patients with perianal fistulas. Six patients demonstrated complete fistula closure and 4 patients demonstrated clinical improvement of their fistulas.

The combination of azathioprine and antibiotics has also been assessed³⁸. Fifty two patients with predominantly simple Crohn's perianal fistulas were given metronidazole or ciprofloxacin for 8 weeks. Patients who received azathioprine as well had a better response at week 20 than those who had not suggesting combination treatment was better.

The slow initial response, side effects and relatively low remission and high recurrence rates with the drugs so far discussed have left the door open to newer treatments.

Infliximab

1
2
3 With the biological drugs, comes a change in treatment options for perianal
4 fistulating Crohn's disease. The potential not only to improve quality of life but
5 also to heal the fistula tracks has been realised and the time to clinical
6 improvement has changed from the order of several months to a few weeks.
7
8
9

10
11
12
13
14
15 The first placebo controlled trial using Infliximab was reported by Present and
16 colleagues in 1999²⁷. Ninety four patients were given three infusions of
17 Infliximab at 0, 2 and 6 weeks. Sixty eight percent of patients had a clinical
18 response and approximately 50% of patients closed all fistulas. The median time
19 to achieve response was 2 weeks.
20
21
22
23
24
25
26
27
28

29 In the maintenance trial of infliximab in patients with perianal fistulating Crohn's
30 disease ([A Crohn's Disease Clinical Trial Evaluating Infliximab in a New Long-
31 Term Treatment Regimen in Patients with Fistulizing Crohn's Disease, ACCENT
32 II](#)), 282 patients initially received 3 infusions of Infliximab at 0, 2 and 6 weeks and
33 responders at week 14 were randomized to receive placebo or maintenance
34 infliximab 8 weekly for 54 weeks³⁹. There was a significant difference in the
35 primary outcome measure, which was time to loss of response. Among patients
36 who had a response at the time of randomisation, those given infliximab
37 maintenance therapy had a significantly longer time to loss of response (greater
38 than 40 weeks) than those who received placebo maintenance (14 weeks) ($p <$
39 0.001). Forty six percent of patients in the infliximab maintenance group had a
40 fistula response at 54 weeks and 36% of patients had a complete response at 54
41
42
43
44
45
46
47
48
49
50
51
52
53
54
55
56
57
58
59
60

1
2
3 weeks. In the placebo maintenance group, 23% of patients still had a response at
4
5
6 week 54 and 19% had a complete response.
7
8
9

10 The impact of Infliximab maintenance in the ACCENT II patients on hospital
11 admissions and the need for surgery was examined by Lichtenstein in 2005 ⁴⁰.
12
13 The treatment maintenance group had a reduction of >50% in hospital
14 admissions compared with the placebo maintenance group and their length of
15 stay was also significantly reduced (2.5 to 0.5 days). The treatment group also
16 had an approximately 50% reduction in the mean number of all operations and
17 procedures, rising to >80% for major procedures. Not only does infliximab impact
18 on the number of hospitalisations and operations that a patient with perianal
19 Crohn's disease undergoes, but there is evidence that anti-TNF therapy
20 improves health related quality of life in patients with Crohn's perianal fistulas ⁴¹.
21
22
23
24
25
26
27
28
29
30
31
32
33
34
35
36
37
38
39
40
41
42
43
44
45
46
47
48
49
50
51
52

53 When infliximab is stopped, however, the risk of recurrence is high and it is
54 higher in perianal than luminal disease. Domenech and colleagues followed
55 patients with perianal Crohn's disease for 1 year after they had stopped a one
56 year course of infliximab (induction plus maintenance). They found 83% of
57 luminal CD patients were free of relapse compared to only 34% of perianal CD
58 patients ⁴².
59
60

More recently, a large open label case series from Hungary of 148 Crohn's anal
fistula patients reported a remission rate of 49% at 12 weeks follow up but longer

1
2
3 term follow up and confirmed healing on MRI were lacking ⁴³. An Italian
4
5 multicentre group reported an initial response to induction with infliximab in 76%
6
7
8 of 188 patients with perianal Crohn's disease and a 44% clinical remission rate
9
10 ⁴⁴. In a prospective study, 34 patients with perianal Crohn's fistulas were followed
11
12 up long term. At 6 months, 58% of the Infliximab treated patients were in clinical
13
14 remission, 37% were in clinical response and 5% had had no response ⁶.
15
16
17

18
19
20 The question of whether infliximab should be used with concomitant
21
22 immunomodulators such as thiopurines to achieve a better outcome is difficult to
23
24 answer in the setting of perianal Crohn's disease. It is interesting to note that the
25
26 majority in remission in the Hungarian study were on a concurrent
27
28 immunomodulator, most frequently Azathioprine. In the ACCENT II trial, about
29
30 one third of patients were on concomitant immunomodulators. A post-hoc
31
32 analysis of the ACCENT II data by Lichtenstein and colleagues published in 2009
33
34 identified that approximately one third of patients in both placebo and infliximab
35
36 arms were on concomitant immunomodulators at baseline and it appeared that
37
38 there was no major benefit of dual therapy ⁴⁵. However, in a recent study to
39
40 assess whether concomitant immunomodulators are useful in patients with
41
42 Crohn's disease, it was found that perianal complications were less frequently
43
44 observed at times when patients were on concomitant immunomodulators ⁴⁶. The
45
46 balance of risk and benefit of dual therapy needs to be considered in individual
47
48 cases. In the recent Study of Immunomodulator Naïve patients in Crohn's
49
50 disease (SONIC) trial which assessed efficacy of infliximab monotherapy,
51
52
53
54
55
56
57
58
59
60

1
2
3 azathioprine monotherapy and the two drugs combined in over 500 adults with
4 moderate to severe Crohn's disease who had not had previous
5 immunomodulator or biologic therapy, overall about 12% of patients had perianal
6 fistulas but no separate analysis was performed in this group to determine the
7 relative benefits of single or dual therapy ⁴⁷. However, across all Crohn's
8 patients dual therapy with infliximab and azathioprine was superior to either
9 therapy alone with regards to steroid free remission and mucosal healing at 26
10 weeks.
11
12
13
14
15
16
17
18
19
20
21
22
23

24 Presence of proctitis has been shown to be a predictor of poor response to anti-
25 TNF α ⁶. There are no other clear predictors of failure or success of anti-TNF α in
26 Crohn's perianal fistulas. However, it is interesting to note that perianal fistulas
27 heal more commonly than other fistulas, particularly internal fistulas, with this
28 treatment ⁴⁸.
29
30
31
32
33
34
35
36
37
38
39
40
41
42
43
44
45
46
47
48
49
50
51
52
53

Combined surgery and infliximab

54 The combination of infliximab and surgery has been examined in a number of small trials
55 in three ways; the application of surgery before radical infliximab treatment, the
56 application of infliximab before surgery or using maintenance infliximab with periodic
57 examination under anaesthetic with seton insertion as required.
58
59
60

The use of examination under anaesthetic, drainage of trapped sepsis and insertion of
setons prior to infliximab infusion improved outcome by increasing initial response rate

1
2
3 by almost a fifth, lowering recurrence rate by a third and increasing time to recurrence by
4
5 10 months ⁴⁹.
6
7

8
9
10 A series of 226 patients undergoing various surgical procedures for Crohn's anal fistulae
11 included 79 who received preoperative infliximab ⁵⁰. The groups in this study were not
12 randomised and are heterogeneous. For example the combined treatment group had a
13 higher proportion of transsphincteric (as opposed to intersphincteric) fistulae, a higher
14 proportion of seton insertions (as opposed to fistulotomies) and a higher proportion of
15 patients with proctitis. Both groups achieved healing similar rates of approximately
16 60% however there were signals in this report which suggest there is a benefit to
17 combined treatment. Time to healing was reduced from 12.1 to 6.5 months and two
18 subgroups, patients with transsphincteric fistulas or those treated with setons as their only
19 surgical intervention, healed more frequently if treated with infliximab too. Proctectomy
20 rates were similar in both groups (8-10%) and, interestingly, although proctitis was
21 reduced in the combination group, this did not correlate with healing.
22
23
24
25
26
27
28
29
30
31
32
33
34
35
36
37

38 A smaller series of 17 patients in which 7 underwent either fistulotomy (for low fistulae)
39 or advancement flap (for higher fistulae) alone and 10 had preoperative infliximab found
40 100% initial healing in both arms with 2 recurrences (29%) in the surgery alone group
41 and 1 (10%) in the infliximab group ⁵¹.
42
43
44
45
46
47

48 Several small uncontrolled case series report the successful use of combined seton
49 insertion and maintenance infliximab with remission rates of between 47% and 78% ⁵²⁻⁵⁴.
50
51
52
53
54
55
56
57
58
59
60

Local injection of infliximab

Two open label studies have used infliximab as a local instillation in situations where disease is limited to the anus or there are contraindications to systemic Infliximab. Poggioli and colleagues in 2005 reported the results of 3 to 12 infusions of infliximab (15 to 20mg) directly injected into the tissue surrounding both **internal and external** openings and into the wall of track ⁵⁵. Healing of fistulas was noted in 10 of 15 patients.

Asteria and colleagues in 2006 reported 6 of 11 patients treated with local Infliximab achieving a clinical response and 4 of the 11 remained healed at a median of 10 months follow up ⁵⁶.

Adalimumab

In the CHARM (Crohn's trial of the fully Human Antibody Adalimumab for Remission Maintenance) study, 113 patients with Crohn's fistulas were given adalimumab at week 0 (80mg), week 2 (40mg) and then maintenance with either weekly or fortnightly adalimumab or placebo ⁵⁷. Fistula response and fistula remission (cessation of drainage from all orifices) were secondary endpoints. At 26 weeks, 30% of patients treated with adalimumab had complete closure and this rose to 33% at 56 weeks compared with 13% in the placebo arm. In CLASSIC-1 (Clinical Assessment of Adalimumab Safety and Efficacy Studied as an Induction Therapy in Crohn's disease) adalimumab at 80/40 mg, 160/80 mg or

1
2
3 placebo was administered and short term effects were assessed. 32 of the 299
4
5 patients had draining perianal fistulae and no difference was found between
6
7 placebo and any of the ADA induction doses for fistula response or remission⁵⁸.
8
9

10 Other studies have considered adalimumab in patients who have already failed a
11
12 biologic drug. In GAIN (Gauging Adalimumab efficacy in Infliximab Non-
13
14 responders), Crohn's disease patients who had lost response or who were
15
16 intolerant to infliximab were treated with an induction regime of 160/80 mg
17
18 adalimumab or placebo⁵⁹. 45 of the 325 patients had perianal fistulae and no
19
20 difference was found between placebo and any of the ADA induction doses for
21
22 fistula response or remission. In an open label trial in which 22 patients with
23
24 perianal fistulae who had lost response or showed intolerance to infliximab were
25
26 treated with adalimumab 160/80 mg, remission was noted in 23% at 4 weeks⁶⁰.
27
28
29
30

31 The study of fistulating Crohn's disease, described above, in which 34 patients
32
33 with fistulating perianal disease (85% anal fistulas, 15% rectovaginal fistulas)
34
35 were followed up at St Mark's hospital, also evaluated the response to
36
37 adalimumab in patients who lost response to or were intolerant of infliximab⁶. At
38
39 6 months 14% of the adalimumab treated patients (who had failed Infliximab)
40
41 were in clinical remission, 43% in clinical response and 43% having had no
42
43 response. The data suggest that a second biological agent is effective in
44
45 patients who have failed one biological therapy already, but the effect is reduced.
46
47
48
49

50
51
52 The long term use of adalimumab is shown in the CHARM extension study which
53
54 followed patients for a further 2 years and demonstrated that 60% of
55
56
57
58
59
60

1
2
3
4
5
6
7
8
9
10
11
12
13
14
15
16
17
18
19
20
21
22
23
24
25
26
27
28
29
30
31
32
33
34
35
36
37
38
39
40
41
42
43
44
45
46
47
48
49
50
51
52
53
54
55
56
57
58
59
60

adalimumab-treated patients maintained fistula healing although the non-responder imputation efficacy at 2 years which includes those patients who started on Adalimumab but left the trials for any reason (including stopping the drug due to lack of efficacy, adverse events, protocol violations etc.) was 31%⁶¹.

Table 1. Randomised Controlled Trials (RCT) or meta-analyses of **established** medical treatments of Crohn's-related perianal fistulas

Drug	Study	Type of study	n	FU at end point	Fistula remission	
					Rx	Placebo
Metronidazole	Thia 2009 ³⁴	RCT	7	10 weeks	0%	12.5%
Ciprofloxacin	Thia 2009 ³⁴	RCT	10	10 weeks	30%	12.5%
Aza/6-MP	Pearson 1995 ³⁵	Metaanalysis	41	-	*54%	*21%
Tacrolimus	Sandborn 2003 ²⁸	RCT	42	10 weeks	10%	8%
Infliximab	Present 1999 ²⁷	RCT induction	94	14 weeks	55%	13%
Infliximab	Accent II ³⁹	RCT maintenance	282	54 weeks	36%	19%
Adalimumab	CHARM # ⁵⁷	RCT maintenance	113	56 weeks	33%	13%

* = remission and response included together

= In CHARM patient with luminal and perianal Crohn's disease were assessed

Other medical options

1
2
3 Other immunomodulators including Tacrolimus, Thalidomide, Methotrexate and
4
5 Ciclosporin have been considered. Alternative options include GMCSF,
6
7
8 absorptive carbon and hyperbaric oxygen.
9

10 11 12 13 14 ***Tacrolimus, Thalidomide, Methotrexate, Ciclosporin*** 15

16 17 18 19 **Tacrolimus** 20

21
22 Tacrolimus was assessed in a placebo-controlled trial in which it was given orally
23
24 for 10 weeks in 42 Crohn's anal fistula patients. There was significant clinical
25
26 improvement in the tacrolimus group (45%) compared with placebo (9%) but no
27
28 significant improvement in fistula remission rates was seen ⁶². Gonzalez Lama
29
30 and colleagues in 2005 showed that longer term therapy may be required to
31
32 achieve healing ⁶³. Topical tacrolimus has been used in a placebo controlled trial
33
34 in which 19 patients were stratified according to whether they had ulcerating or
35
36 fistulating disease ⁶⁴. There was a benefit in the ulcerating but not the fistulating
37
38 group. There was no systemic detection of tacrolimus and side effects were not
39
40 encountered. This lack of systemic absorption was also noted in a case series of
41
42 children with oral or perianal (6/8) Crohn's and in whom the topical preparation
43
44 was effective in improving fistulas after failure of numerous other therapies ⁶⁵.
45
46
47
48
49
50
51
52
53
54

55 **Thalidomide** 56 57 58 59 60

1
2
3 Thalidomide has been used in the context of perianal Crohn's disease.
4
5 Vasiliauskas and colleagues in 1999 reported an open series of 12 male patients
6
7 with Crohn's disease of whom six had fistulas and 5 out of 6 demonstrated
8
9 significant improvement ⁶⁶. Ehrenpreis and colleagues in 1999 reported an open
10
11 label study of 13 patients with fistulating Crohn's disease ⁶⁷. Six out of 13
12
13 achieved complete remission of their fistulas at 12 weeks. Plamondon and
14
15 colleagues in 2007 reported an open label study of 11 patients with fistulating
16
17 Crohn's disease treated with Thalidomide ⁶⁸. Nine out of the 11 responded to the
18
19 Thalidomide and 3 out of 9 had a complete response. The data suggest that
20
21 Thalidomide can heal fistulas in patients naïve or refractory to biological drugs.
22
23
24
25
26
27
28
29

30 **Methotrexate**

31
32
33
34 There is little evidence to support the use of methotrexate as monotherapy to
35
36 treat perianal Crohn's disease. There are no randomised data, only small case
37
38 series. In one case series, 56% of patients with Crohn's anal fistulas on
39
40 methotrexate showed a complete or partial response to therapy ⁶⁹. Schroder and
41
42 colleagues used infliximab induction as a bridge to methotrexate (20 mg/week) in
43
44 12 consecutive patients of whom four (33%) had complete closure and three
45
46 (25%) had partial response ⁷⁰.
47
48
49
50
51
52
53

54 **Ciclosporin**

55
56
57
58
59
60

1
2
3 There have been small case series using intravenous ciclosporin, usually at a
4 dose of 4mg/kg, to treat perianal Crohn's disease. Although about three quarters
5 of patients initially responded, the treatment was limited in that following oral
6 transition or discontinuance of ciclosporin, a majority of patients relapsed ⁷¹.
7
8
9
10
11
12
13
14
15

16 **GM-CSF**

17
18
19
20 Human granulocyte-macrophage colony-stimulating factor (GM-CSF) has been
21 examined in luminal Crohn's disease in a small number of studies, including a
22 double blind RCT where it was used as a steroid sparing agent in steroid
23 dependent Crohn's disease. The primary end point was steroid free remission
24 which was achieved in 18.6% of treatment patients vs. 4.9% of those taking
25 placebo (p = 0.03) ⁷². Evidence of improvement in perianal fistulas is limited and
26 a small case series of heterogeneous and complex patients published in 2010
27 failed to find any improvement in fistulas in Crohn's disease after GM-CSF
28 treatment ⁷³.
29
30
31
32
33
34
35
36
37
38
39
40
41
42
43
44

45 **Hyperbaric Oxygen Therapy (HBOT)**

46
47
48 The mechanism of action of HBOT is thought to be multifactorial including raising
49 the oxygen tension in damaged tissue, improving oxygen-burst mediated
50 phagocytosis, decreasing circulating LPS-stimulated pro-inflammatory cytokines
51 such as IL-1, IL-6 and TNF α levels and inhibiting neutrophil-associated
52
53
54
55
56
57
58
59
60

1
2
3 inflammation^{74,75}. Several studies during the 1980s and 1990s described cases
4
5 or small case series of patients with severe perianal Crohn's disease which
6
7 partially or completely responded to HBOT⁷⁶⁻⁷⁸.
8
9

10
11
12 In these trials, side effects of HBOT included tympanic membrane perforation
13
14 and blurred vision (which resolved after treatment finished). Patients spent
15
16 between 30 and 130 hours in the HBOT chamber in 1.5-2 hour sessions. It is
17
18 difficult to draw firm conclusions from these heterogeneous studies on efficacy or
19
20 side effects in the absence of randomized controlled data.
21
22
23

24 25 26 27 28 **Oral absorptive carbon**

29
30
31 Fukuda and colleagues reported a randomised controlled trial of oral absorptive
32
33 carbon in which 57 patients received either activated absorptive carbon or a non-
34
35 absorptive carbon molecule as placebo⁷⁹. The treatment group achieved 37%
36
37 improvement and 30% remission of anal fistulas after 8 weeks treatment
38
39 compared to 10% and 7%, in the placebo group. The authors suggested that the
40
41 mechanism of action might be a combination of firming of stool, absorption of
42
43 toxins or intestinal stimulation factors (such as serotonin and histamine) and
44
45 restoration of the normal luminal environment and flora.
46
47
48
49
50

51 52 53 54 ***Monitoring response to therapy***

1
2
3 The improved medical treatment for Crohn's perianal fistulas has prompted new
4
5 questions: how to monitor patients, how long to treat them with drugs which have
6
7 serious side effects and are expensive, and when or perhaps if to stop treatment.
8
9

10
11
12 Studies have shown that although clinical healing (in the form of a closed
13
14 external opening or cessation of drainage) has occurred in the short term,
15
16 imaging modalities including MRI indicate that the fistula track may remain for
17
18 some time with deep and true healing of the fistula lagging behind clinical
19
20 remission by months or with reactivation after cessation of treatment or during
21
22 maintenance treatment ^{6,80}. In those in whom healing does take place,
23
24 determining the moment of tissue healing using MRI and stopping treatment at
25
26 this point, rather than based on clinical remission, ought to mean a lower risk of
27
28 later recurrence.
29
30
31
32
33
34
35

36
37 Sequential MRI scanning may also select those patients who are non-responders
38
39 at an earlier stage, permitting an early change to another biological therapy or
40
41 the decision to stop altogether or continue on maintenance treatment. This early
42
43 diagnostic impact on decision making should improve treatment efficiency and
44
45 patient safety.
46
47
48
49

50
51 The prospective study of 34 patients with fistulating Crohn's disease at St Mark's
52
53 Hospital, discussed above, also evaluated the impact of MRI on clinical decision
54
55 making ⁶. Patients were treated with infliximab and if there was a lack or loss of
56
57
58
59
60

1
2
3 response or if the patient was intolerant to infliximab, they were treated with an
4
5 alternative agent (adalimumab or thalidomide). Patients were assessed clinically
6
7 and by MRI at 6, 12, 18 and 24 months, and yearly thereafter with a median
8
9 follow up of 83 weeks (range 52 to 131 weeks).
10
11

12
13
14
15 At 6 months, 58% of the Infliximab treated patients and 14% of adalimumab
16
17 treated patients were in clinical remission. They found that deep tissue healing
18
19 as assessed by MRI was slower to occur than clinical healing and the rate of
20
21 deep tissue healing varied between patients. The presence of proctitis, but
22
23 neither the complexity nor the duration of fistula, was associated with a lack of
24
25 response.
26
27
28
29
30
31
32
33
34
35
36
37
38
39
40
41
42
43
44
45
46
47
48
49
50
51
52
53
54
55
56
57
58
59
60

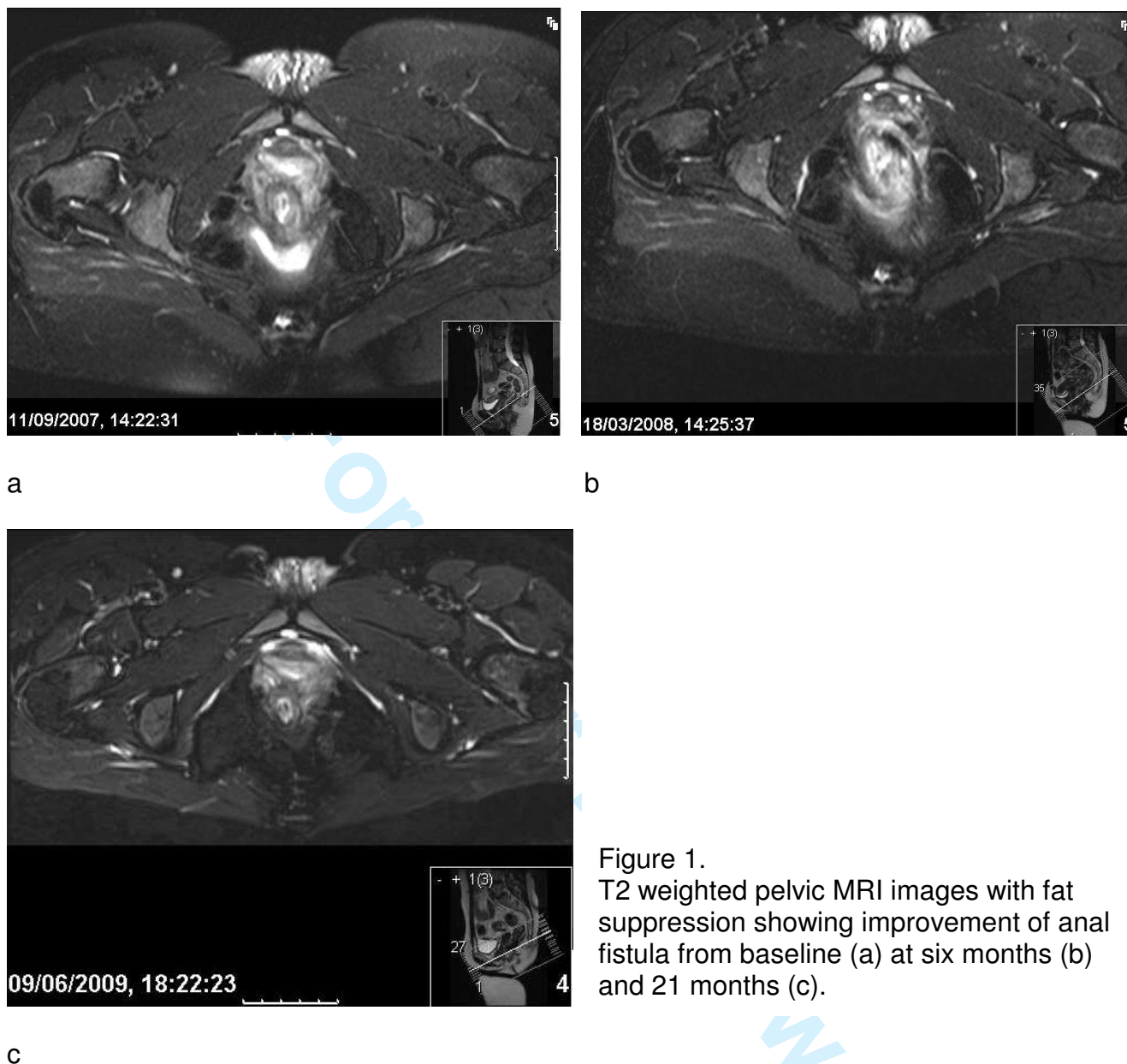


Figure 1.
T2 weighted pelvic MRI images with fat suppression showing improvement of anal fistula from baseline (a) at six months (b) and 21 months (c).

Imaging may also be useful in guiding surgical intervention during medical treatment and thereby improve outcome. A small study by Spradlin and colleagues (2008) showed that serial EUS during maintenance infliximab treatment, which was used to time seton removal and repeat abscess drainage and seton insertion, reduced fistula recurrence and treatment failure⁸¹.

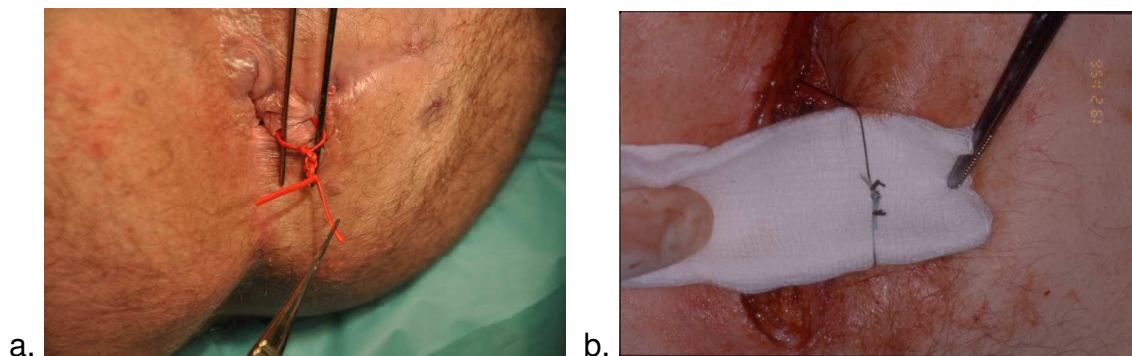
Surgery for perianal Crohn's disease

The surgeon's role in Crohn's perianal fistulae has changed and management is now performed in combination with the physician. Some fistulas can be definitively cured surgically, usually by lay open or advancement flap whilst other patients need palliation of their symptoms or even a proctectomy. Palliation usually comes in the form of drainage of any trapped infection and thereafter a long term, comfortable loose seton (figure 2b.).

Examination under anaesthetic, drainage of sepsis and insertion of comfortable setons now forms the first stage in the truly combined surgical-medical eradication of anal fistulas using infliximab as described above. If pre-treatment surgical drainage is inadequate, abscess formation during the infliximab course may be more likely and could cause the treatment to fail. In the ACCENT II trial of maintenance infliximab in patients with fistulating Crohn's disease, there was no signal that infliximab-treated patients were more likely to develop new perianal sepsis⁸². Twenty-one (15%) patients in the infliximab maintenance group had at least one newly developed fistula-related abscess compared with 27 (19%) in the placebo maintenance group (P = 0.526). The number of fistula-related abscesses diagnosed over time did not differ between groups.

Loose seton insertion seeks to palliate, reducing pain and discharge and in particular preventing recurrent abscess formation. In addition to the described

1
2
3 role with infliximab treatment, it remains a key tool in the surgeon's arsenal for
4
5 the long term management of Crohn's perianal fistulas, stubbornly resistant to all
6
7 attempts at eradication.
8
9



25
26
27
28
29
30
31
32
33
34
35

Figure 2. a. A bulky silastic seton and b. a low profile ethibond seton with just three throws and the 'whiskers' tied back with silk.

36 37 38 39 40 41 42 43 44 45 46 47 48 49 50 51 52 53 54

Lay open

55
56
57
58
59
60

Some Crohn's fistulas can be laid open and cured. As a general rule, surgeons are more cautious in Crohn's disease and will not lay open fistulas that in the idiopathic setting they would be happy to treat. Not only are there concerns regarding future fistula formation and problems with healing, but the increased bowel frequency and the tendency for this to worsen with disease activity or future resection makes incontinence a greater threat.

Advancement flaps

1
2
3 Advancement flaps can be used as a sphincter preserving technique for some
4
5 higher fistulas in Crohn's disease with a success rate of around 50%^{83,84}.
6
7
8 Patients are chosen who do not have active proctitis or extensive cavitating
9
10 ulceration in the anal canal. A defunctioning stoma is sometimes used in an
11
12 attempt to improve the chance of success, although there is little evidence
13
14 suggesting an improved success rate^{83,84}. An adjunctive Martius flap may be
15
16 helpful. An advancement flap is easier when there is perineal descent or internal
17
18 intussusception.
19
20
21
22
23

24
25 Two studies from the Cleveland Clinics of Florida and Ohio, published in 2002,
26
27 demonstrated a worse outcome for advancement flap surgery in Crohn's anal
28
29 and rectovaginal fistulas than those of cryptoglandular origin in more than 100
30
31 patients each^{83,84}. Mizrahi and colleagues showed an increased recurrence rate
32
33 after surgery from 33% in non-Crohn's fistulas to 57% in the Crohn's patients
34
35 which was similar to the findings of Sonoda and colleagues with 30% recurrence
36
37 rising to 50% in Crohn's disease. This latter study also demonstrated a lower
38
39 success rate in rectovaginal than anal fistulas and found that early surgery on a
40
41 well drained fistula complex increased the chance of success. Smoking has
42
43 been shown to increase the risk of failure in cryptoglandular fistulas although in
44
45 this as well as most studies of advancement flap surgery, patients with Crohn's
46
47 disease were excluded⁸⁵
48
49
50
51
52
53
54
55
56
57
58
59
60

Glues and plugs

Fistula infill materials, such as fibrin or collagen glues and collagen plugs, have not maintained the same initial enthusiasm and excellent results that their first published trials enjoyed. None-the-less they remain a low risk (albeit expensive) option in the management of idiopathic anal fistulas. Many of the trials of both glue (table b) and plugs (table c) have included small numbers of Crohn's patients, although independent analysis of efficacy in the Crohn's cohorts is often not possible due to these small numbers and the absence of MRI validation of healing.

Vitton and colleagues studied 14 Crohn's fistulas (superficial, inter- trans and suprasphincteric and anovaginal) and observed complete clinical healing in 8 of them at a median of 23 months follow up. The fistulas were described as refractory, although the complexity of the fistulas and extent of Crohn's disease is not described⁸⁶.

A recently published study of fibrin glue in Crohn's perianal fistulas, an open label, randomised controlled trial, demonstrated initial success (clinical remission at week 8) in 38% (13 of 34) of the fibrin glue group compared to 16% in the observation only group⁸⁷. Twenty of the 37 patients in the observation only group crossed over to fibrin glue treatment at week 8 and 9 of these patients went into remission at week 16. Unfortunately, of the 54 who underwent fibrin glue treatment at some point in the trial, only 11 (20%) were in remission at long

term follow up (median 37 months for initial fibrin glue group and 17 months for cross over group). No imaging was used to assess deep tissue healing in this study.

Table 2. Studies of fistula glue in anal fistula including Crohn's patients

Study	Year	FU (months)	Routine preop seton	Total n	Crohn's n	Overall success rate	Crohn's success rate
Abel+ ⁸⁸	1993	3-12	No	10	3	6/10 (60%)	1/3 (33%)
Venkatesh# ⁸⁹	1999	12	No	30	6	18/30 (60%)	0/6 (0%)
Cintron# ⁹⁰	2000	12	No	79	6	48/79 (61%)	2/6 (33%)
Lindsey ⁹¹	2002	17.1	No	19	2	12/19 (63%)	2/2 (100%)
Zmora ⁹²	2003	12.1	No	24	5	8/24 (33%)	2/5 (40%)
Sentovich ⁹³	2003	22	Yes	48	5	33/48 (69%)	4/5 (80%)
Loungnarath ⁹⁴	2004	26	No	39	13	12/39 (31%)	4/13 (31%)
Singer# ⁹⁵	2005	27	No	75	3	25-44%	0/3 (0%)
Vitton# ⁸⁶	2005	23.4	No	14	14	8/14 (57%)	8/14 (57%)
Chung\$ ⁹⁶	2010	3	No	(81)	2	23/79 (29%)	0/1 (0%)
de Parades# ⁹⁷	2010	11.7	Yes	30	11	15/30 (50%)	7/11 (63.6%)
Grimaud# ⁸⁷	2010	2	No	34	34	13/34 (38%)	13/34 (38%)

#Includes some rectovaginal fistulas

+The one success in the CD group had a rectovaginal fistula (RVF) which healed after 2 treatments

\$Idiopathic results from contemporary but separately published results by same authors

The anal fistula plug has been used in trials of Crohn's perianal disease with success rates between 25% and 100% (table c) including the two largest studies (of 14 and 20 patients) which were at opposite ends of this spectrum of success (26.6% and 80%). Failure occurred due to extrusion of the plug, abscess formation or ongoing discharge. Long term follow up or radiological proof of fistula healing in an adequately powered randomised control trial is required to establish efficacy of this expensive treatment.

Table 3. Studies of the fistula plug in anal fistula including Crohn's patients

Study	Year	FU (months)	Routine preop seton	Total n	Crohn's n	Success rate	Crohn's success rate
O'Connor* 98	2006	10	depends	20	20	16/20 (80%)	16/20 (80%)
van Koperen 99	2007	7	No	17	1	7/17 (41%)	1/1 (100%)
Ky 100	2008	6.5	No	44	14	24/44 (54.6%)	4/14 (26.6%)
Schwandner 101	2008	9	No	18	7	12/18 (61%)	6/7 (85.7%)
Christofordis 102	2008	6.5	No	47	3	20/47 (43%)	NR
Schwandner† 103	2009	9	No	9	9	7/9 (77%)	7/9 (77%)
Safar 104	2009	4	No	36	4	5/36 (13.9)	1/4 (25%)
Zubaidi 105	2009	12	No	22	2	19/22 (86%)	1/2 (50%)
Chung\$ 96	2010	3	No	50	4	27/46 (59%)	3/4 (75%)
Owen 106	2010	15		35	3	13/35 (37%)	1/3 (33%)

*The O'Connor study included one pouch patient, 2 anovaginal fistulas and 4 patients on concomitant infliximab. Single rather than multiple tracts were significantly associated with successful closure. Preoperative setons were used if the tract was too wide for the plug to sit snugly.

NR – not reported or cannot be concluded from the data presented

1
2
3 †In this study, 2 of the 10 patients enrolled were defunctioned and one was lost
4 to follow up.

5 \$Idiopathic results from contemporary but separately published results by same
6 authors
7
8
9

10 11 ***Modified infill materials*** 12

13
14
15 The waning published efficacy of glues and plugs over time has led to the
16 addition of agents designed to improve healing rates. Preclinical work at St
17 Mark's has demonstrated that the addition of autologous fibroblasts to a collagen
18 glue improved the histological appearance of the healed track compared to glue
19 alone and clinical studies are in progress ¹⁰⁷. A single case report of autologous
20 fibroblasts on a biologic scaffold (HYAFF) has been described in a Crohn's
21 patient with a transphincteric fistula ¹⁰⁸. The patient had a seton inserted and
22 three doses of intravenous infliximab administered before fistulectomy and then
23 insertion of the scaffold with autologous fibroblasts into the track until it was
24 completely filled. The patient was free of recurrence throughout a 20 month
25 follow up period, but MRI validation of healing was not performed.
26
27
28
29
30
31
32
33
34
35
36
37
38
39
40
41

42 In 2008 Garcia-Olmo and colleagues reported the administration of adipose
43 derived stem cells (ASCs) in fibrin glue vs. glue alone in a randomised controlled
44 trial of 49 patients (14 with Crohn's disease) and found a significant increase in
45 healing from 16% without ASCs to 71% with them ¹⁰⁹. ASCs are living adult stem
46 cells of mesenchymal origin which are extracted from subdermal adipose tissue
47 obtained through liposuction. The study's authors suggest that the ASCs may
48
49
50
51
52
53
54
55
56
57
58
59
60

1
2
3 have both an initial anti inflammatory effect and also aid tissue repair through
4
5 differentiation into epithelial cells.
6
7

8
9
10 This approach of adding constituents to correct specific aspects of the pathology
11
12 in persisting anal fistula tracts is extremely attractive and could in the future lead
13
14 to personally tailored treatments in both idiopathic and Crohn's related anal
15
16 fistulas incorporating aspects of immunology and microbiology specific to an
17
18 individual.
19
20
21
22
23

24 25 ***Defunctioning and proctectomy*** 26

27
28
29 Some patients have either failed medical therapy and undergone several
30
31 operations finding nothing that helps to alleviate their symptoms and gain the
32
33 quality of life they want, or are subdued by the systemic effects of their colorectal
34
35 disease to such an extent that a stoma becomes a realistic option. Proctectomy
36
37 (+/- colectomy depending on the extent of disease) in the patient with severe
38
39 rectal and/or perianal disease can leave patients with an improved quality of life
40
41 in spite of a recurrence (of luminal disease) rate of around 20% and a similar risk
42
43 of reoperation. The principle risks of this operation include damage to the pelvic
44
45 nerves and the delayed or unhealed perineal wound, which affects around 30%
46
47 of patients up to 6 months and 10% beyond that time. A small group of these will
48
49 require further surgical procedures to aid healing of the wound, including
50
51 curettage or (usually myocutaneous) flap reconstruction.
52
53
54
55
56
57
58
59
60

1
2
3
4
5
6 Defunctioning with an ileostomy provides temporary relief of symptoms but
7
8 disease often recurs and most of these stomas will never be reversed.
9
10 Yamamoto and colleagues reported their series of 31 patients who underwent
11
12 defunctioning alone in Crohn's disease for perianal or anovaginal disease ¹¹⁰.
13
14 Only 8 (26%) went into long standing remission and only 3 patients (10%) had
15
16 their stoma reversed. Hong and colleagues reported a series of 21 patients who
17
18 were defunctioned for perianal Crohn's disease and found the chance of having
19
20 continuity restored was not influenced by infliximab. At median follow up of 22
21
22 months (4-121), 4 patients (19%) had undergone stoma closure, 11 had had a
23
24 proctocolectomy, and 6 had both a stoma and their rectum in situ. The effect of
25
26 the procedure on severity of perianal disease was no effect in 4 (19%),
27
28 temporary improvement in 6 (29%), initial improvement with a sustained benefit
29
30 in 7 (33%), and healing in 4 (19%) ¹¹¹.
31
32
33
34
35
36
37
38

39 As a general rule, if a patient needs their large bowel Crohn's disease excised,
40
41 defunctioning alone will leave ongoing ill-health with little or no chance of reversal
42
43 in the longer term and should be avoided. **In a recent series of Crohn's anal**
44
45 **fistulae managed with a variety of medical and surgical interventions, around**
46
47 **10% ultimately underwent proctectomy (Gaertner 2007).**
48
49
50
51
52
53

Fistula-associated carcinoma in Crohn's disease

54
55
56
57
58
59
60

1
2
3 It is important to note that malignancies can arise in Crohn's related perianal
4 disease. Although it is uncommon, a recent literature review revealed 61 cases of
5 carcinomas arising in perineal fistulas in Crohn's disease. Sixty-one percent of
6 the patients were females and females were significantly younger than males at
7 the time of diagnosis of cancer, and had a shorter duration of fistulating perianal
8 disease prior to cancer transformation. Adenocarcinoma was the most common
9 histology followed by squamous cell carcinoma¹¹².
10
11
12
13
14
15
16
17
18
19
20
21
22
23

24 **An approach for managing anal fistulae in Crohn's disease**

25
26
27
28 Based on current best practice at St Mark's Hospital, we present an approach to
29 the management of the patient with anal fistulae in Crohn's disease and an
30 algorithm for the use of infliximab to heal their fistulae.
31
32
33
34
35
36
37

38 It should be remembered that the finding of anal fistulae in Crohn's disease
39 usually predicts a high risk of a severe and disabling disease course; luminal
40 disease should be managed aggressively and fistulae treated by the approach
41 described below.
42
43
44
45
46
47
48
49
50

51 ***Initial management***

52
53
54
55
56
57
58
59
60

1
2
3 A full assessment of both luminal and perianal disease should be made.
4
5 Perianal abscess should be clinically excluded. Luminal assessment will consist
6
7 of colonoscopy and small bowel imaging according to local expertise. Fistula
8
9 assessment should be by MRI in the first instance. Luminal assessment
10
11 provides information on the extent of disease. MRI of the pelvis will guide
12
13 surgical review and early examination under anaesthetic (EUA) and provide a
14
15 template for future comparison.
16
17
18
19

20
21
22 The initial treatment of anal fistulae in Crohn's disease is with antibiotics and
23
24 immunomodulators. If this treatment fails to produce remission, infliximab should
25
26 be considered. The therapy needs to be considered in the context of any luminal
27
28 disease elsewhere according to NICE guidelines.
29
30
31
32
33
34

35 ***Surgical assessment and infliximab induction (week zero)***

36
37
38
39

40 All patients should have a surgical review to assess the nature of the fistula[¶], the
41
42 patient's general health and any appropriate surgical approach. Most commonly,
43
44 EUA will be performed with adequate surgical drainage of the fistula complex,
45
46 with or without seton insertion, prior to treatment with biologic agents. However,
47
48 curative surgery should also be considered at this point although few patients are
49
50 suitable* and in the patient in poor general health and severely disabled by their
51
52 disease, ablative surgery may be most appropriate[§].
53
54
55
56
57
58
59
60

1
2
3 If surgical drainage and medical treatment is the optimal option, as in most
4 cases, infliximab should be commenced with a standard induction protocol of
5 5mg/kg at 0, 2 and 6 weeks. Setons should be removed around week 6 if there
6 is clinical evidence of improvement, to enable healing of the tract. If anal fistulae
7 and luminal disease are present, adalimumab can be considered as an
8 alternative.
9
10
11
12
13
14
15
16
17
18
19
20

21 ***Twelve week assessment***

22
23
24
25
26 At approximately 12 weeks, clinical assessment of response should be
27 performed. Primary non-responders can be identified as those who have
28 achieved no response to infliximab induction and they should be changed onto
29 an alternative biologic drug (adalimumab). If clinical response occurs then
30 maintenance treatment should commence with 5mg/kg doses every 8 weeks with
31 assessment of adverse events and response with each dose.
32
33
34
35
36
37
38
39
40
41
42

43 Any clinical improvement at 12 weeks, even if not meeting the criteria of clinical
44 response described above, should prompt maintenance treatment.
45
46
47
48
49
50

51 ***One year assessment***

1
2
3 At 1 year a full clinical and radiological (MRI pelvis) assessment of fistula
4 response should take place as well as assessment of luminal disease. Clinically,
5 the patient can either have remission (closure of all external openings), response
6 (closure of $\geq 50\%$ of external openings) or lack of response. Radiologically, the
7 patient can be healed, improved by comparison with baseline or have lost
8 response (either by returning to baseline appearance or, if an intercurrent scan
9 has occurred, by comparison with the last scan). The patient will thus fall into
10 one of the five categories outlined below:
11
12
13
14
15
16
17
18
19
20
21
22
23

24 1. If there is clinical remission and the fistula has radiologically fully healed, and
25 there is no other indication for continuing infliximab treatment such as luminal
26 disease, consider stopping infliximab but thiopurines should be maintained. A
27 further MRI scan should be performed in 6 months to confirm persistent
28 radiological healing or prompt reinstatement of infliximab if evidence of
29 recurrence is seen.
30
31
32
33
34
35
36
37
38
39
40

41 2. If there is clinical remission but only radiological improvement over baseline
42 and not full healing, maintenance infliximab should be continued and
43 reassessment performed 6 monthly for a year and annually thereafter.
44
45
46
47
48
49
50

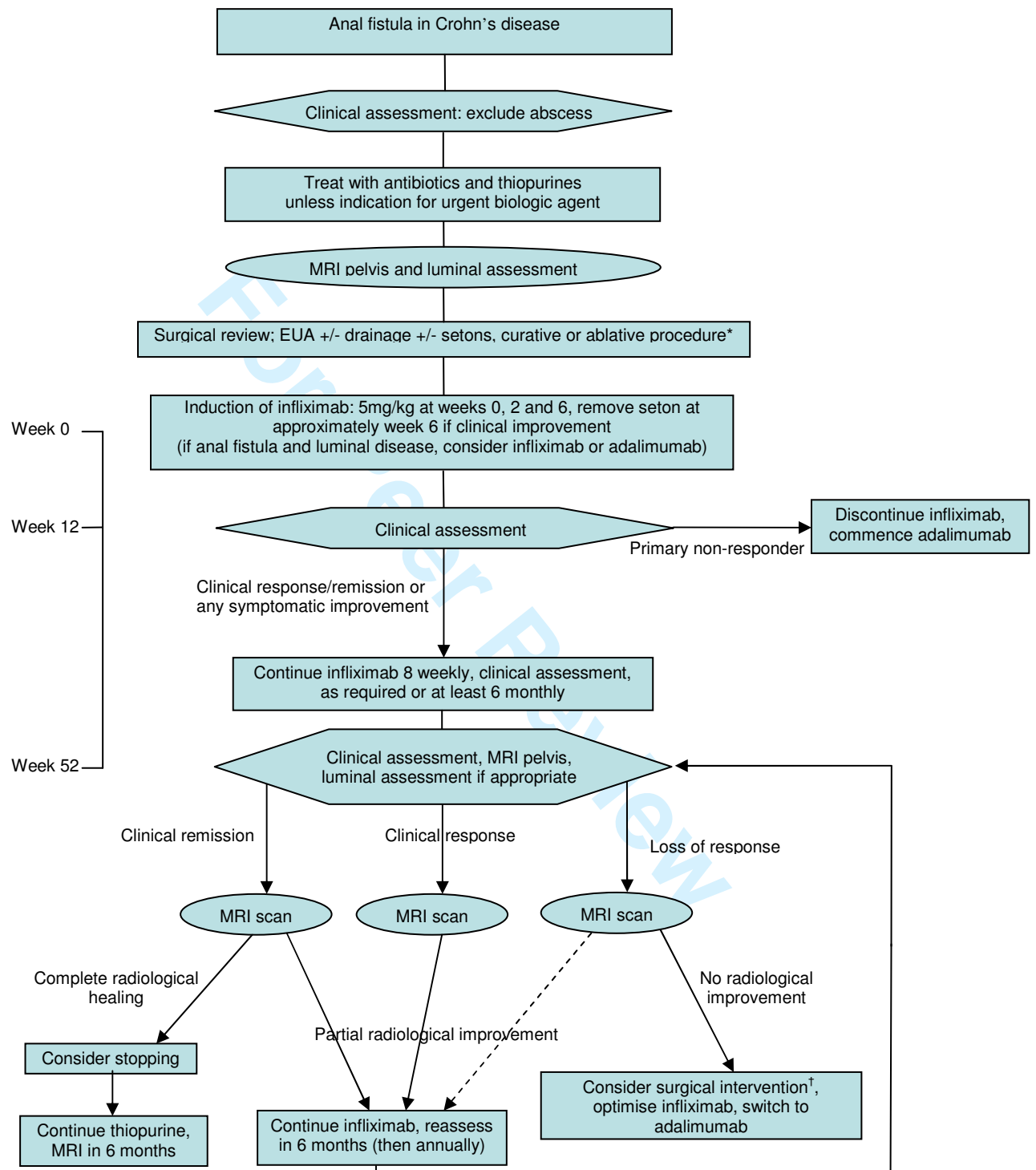
51 3. If clinical improvement and radiological improvement persist then the patient
52 should continue on maintenance infliximab.
53
54
55
56
57
58
59
60

1
2
3
4 4. If there is clinical loss of response but radiologically some improvement over
5
6 the baseline scan, infliximab treatment should be optimised (increase dose to
7
8 10mg/kg or decrease interval between doses) or consider switching to
9
10 adalimumab.
11

12
13
14
15 5. If the patient has clinically lost response and the fistula has radiologically
16
17 returned to the pre-treatment situation, the need for further surgical intervention
18
19 to drain trapped sepsis inhibiting response should be considered[†]. If there is no
20
21 trapped sepsis to drain then infliximab should be optimised (as described above)
22
23 or consider switching to adalimumab.
24
25
26
27
28

29
30
31
32
33
34
35
36
37
38
39
40
41
42
43
44
45
46
47
48
49
50
51
52
53
54
55
56
57
58
59
60
Fistula recurrence should be treated by restarting this algorithm from the
beginning

Algorithm for the management of anal fistulae in Crohn's disease



*** Curative surgery**

A few patients with moderate Crohn's disease may be candidates for curative surgery:

- advancement flap (good rectum, perineal descent/internal intussusception helpful, consider temporary stoma);
- coloanal pull through (rectal internal opening, good anus, good colon, loop ileostomy);
- Turnbull-Cutait[‡] (internal opening at dentate line, good anus, good colon, loop ileostomy);
- fistulotomy +/- delayed sphincter repair (consider temporary stoma).

Some patients with severe and debilitating disease may benefit from ablative surgery[§]

Temporary stoma

Temporary ileostomy/colostomy:

- will not of itself lead to fistula resolution
- may be an adjunct to surgical or medical therapy
- should not be used when proctectomy or proctocolectomy is needed

‡ Turnbull-Cutait procedure

Two stage coloanal.

- 1st stage leaves colon extruded anally for one week;
- 2nd stage trims the colon back to the anus.

† Surgery in loss of response

MRI may indicate undrained sepsis leading to lack or loss of response

- drainage of sepsis should be obtained and further setons inserted
- infliximab maintenance should then recommence
- further clinical assessment in 6 months

§ Ablative surgery

Perianal fistulae alone are unlikely to lead to very poor general health with restriction of work or social activities; colorectal disease is likely to be to blame. In this case:

- medical management should be optimised;
- if this fails, proctectomy or proctocolectomy (dependent on the extent of disease) should be considered;
- advice regarding the risk of delayed or poor perineal wound healing should be given.

¥ Incidental cryptoglandular fistulae

Rarely, a cryptoglandular fistula will occur in a patient with Crohn's disease:

- the anorectum will be entirely normal and unaffected by Crohn's disease;
- there will be very limited luminal disease;
- treatment should be surgical, as for other cryptoglandular fistulae, except with greater sphincter preservation because of the risk of diarrhoea in the future.

Summary

Anal fistulas are a common, unpleasant and treatment-resistant manifestation of Crohn's disease. Medical treatments with antibiotics and immunomodulators have been limited but the advent of biologic drugs has had a dramatic effect on the prognosis of these fistulas, offering the patient a realistic chance at response and indeed remission. However, loss of response and side effects are all too common. Local administration, combinations of drugs and new biologics all offer potential improvements.

Surgery likewise can have a high rate of recurrence for most procedures and the risks of stomas, impairment of continence, unhealed wounds and repeated operations are ever present.

The primary goal of treating Crohn's anal fistulas should be eradication without recurrence. This may sometimes be achieved by surgery in the form of laying open in low fistulas, or alternatives such as advancement flaps or fistula plugs

1
2
3 (although the evidence for these latter is scant and contradictory). Healing is
4
5 more likely to occur using biological treatments. Surgery and imaging remain
6
7 absolutely crucial to this mode of management with EUAs with drainage of
8
9 trapped sepsis and insertion of setons before and sometimes during treatment,
10
11 and high quality radiological monitoring of response so that appropriate decisions
12
13 on interventions such as surgery, cessation of medical treatment or dose or drug
14
15 change can be made.
16
17
18
19
20
21
22

23 ***Future focus***

24
25
26
27 At the moment, during medical treatment the timing of fistula healing is estimated
28
29 from observation of the external opening in many cases and the exact
30
31 appearance of a healed fistula on MRI is unclear, which puts patients at risk of
32
33 early cessation of treatment and resurgence of an unhealed fistula. Similarly,
34
35 patients who spend years on costly biologics (with significant side effects) but
36
37 never heal may be identifiable early in their treatment course on the basis of the
38
39 speed and extent of their initial response, for example, and could then be
40
41 protected from the potential risks of these drugs by early cessation. Such
42
43 prognostic correlations should be sought in order to maximize the benefits and
44
45 minimise risks of these treatments.
46
47
48
49
50
51
52

53 The search for a consistently effective treatment of perianal fistulas in Crohn's
54
55 disease is likely to combine medical and surgical elements and will need to
56
57
58
59
60

1
2
3 address the multiple aetiological factors that drive and maintain the process of
4
5 anal fistulation. A fuller understanding of these aetiological factors is crucial.
6
7
8
9

10 This may lead to treatments based on the “bioglue” model. A treatment
11
12 combining complete removal of all epithelialisation and granulation tissue
13
14 followed by instillation of an infill material (glue) loaded with factors to reduce
15
16 inflammation, tackle infection, correct cytokine abnormalities and promote
17
18 healing may represent the future of anal fistula treatment.
19
20
21
22
23

24 Acknowledgements: P Tozer would like to acknowledge the support of Core,
25
26 for Crohn’s and the St Mark’s Foundation who have funded elements of his fistula
27
28 work.
29
30
31
32
33

34 Statement of Interests: The preparation of this paper was funded in part by Core.
35
36
37
38
39
40
41
42
43
44
45
46
47
48
49
50
51
52
53
54
55
56
57
58
59
60

References

- 1
2
3
4
5
6
7
8
9
10
11
12
13
14
15
16
17
18
19
20
21
22
23
24
25
26
27
28
29
30
31
32
33
34
35
36
37
38
39
40
41
42
43
44
45
46
47
48
49
50
51
52
53
54
55
56
57
58
59
60
1. Ardizzone S, Porro GB. Perianal Crohn's disease: overview. *Dig.Liver Dis.* 2007; **39**: 957-958.

Ref Type: Journal

2. Schwartz DA, Loftus EV, Jr., Tremaine WJ, Panaccione R, Harmsen WS, Zinsmeister AR, Sandborn WJ. The natural history of fistulizing Crohn's disease in Olmsted County, Minnesota. *Gastroenterology* 2002; **122**: 875-880.

Ref Type: Journal

3. Bell SJ, Williams AB, Wiesel P, Wilkinson K, Cohen RC, Kamm MA. The clinical course of fistulating Crohn's disease. *Aliment.Pharmacol.Ther.* 2003; **17**: 1145-1151.

Ref Type: Journal

4. Marks CG, Ritchie JK, Lockhart-Mummery HE. Anal fistulas in Crohn's disease. *Br.J Surg.* 1981; **68**: 525-527.

Ref Type: Journal

5. Sandborn WJ, Fazio VW, Feagan BG, Hanauer SB. AGA technical review on perianal Crohn's disease. *Gastroenterology* 2003; **125**: 1508-1530.

Ref Type: Journal

6. Ng SC, Plamondon S, Gupta A, Burling D, Swatton A, Vaizey CJ, Kamm MA. Prospective evaluation of anti-tumor necrosis factor therapy guided by magnetic resonance imaging for Crohn's perineal fistulas. *Am.J Gastroenterol* 2009; **104**: 2973-2986.

Ref Type: Journal

7. Satsangi J, Silverberg MS, Vermeire S, Colombel JF. The Montreal classification of inflammatory bowel disease: controversies, consensus, and implications. *Gut* 2006; **55**: 749-753.

Ref Type: Journal

8. Cosnes J, Cattan S, Blain A, Beaugerie L, Carbonnel F, Parc R, Gendre JP. Long-term evolution of disease behavior of Crohn's disease. *Inflamm.Bowel.Dis.* 2002; **8**: 244-250.

Ref Type: Journal

9. Hellers G, Bergstrand O, Ewerth S, Holmstrom B. Occurrence and outcome after primary treatment of anal fistulae in Crohn's disease. *Gut* 1980; **21**: 525-527.

Ref Type: Journal

10. Karban A, Itay M, Davidovich O, Leshinsky-Silver E, Kimmel G, Fidler H, Shamir R, Waterman M, Eliakim R, Levine A. Risk factors for perianal Crohn's disease: the role of genotype, phenotype, and ethnicity. *Am.J.Gastroenterol.* 2007; **102**: 1702-1708.

1
2
3
4
5
6
7
8
9
10
11
12
13
14
15
16
17
18
19
20
21
22
23
24
25
26
27
28
29
30
31
32
33
34
35
36
37
38
39
40
41
42
43
44
45
46
47
48
49
50
51
52
53
54
55
56
57
58
59
60

Ref Type: Journal

11. Tang LY, Rawsthorne P, Bernstein CN. Are perineal and luminal fistulas associated in Crohn's disease? A population-based study. *Clin.Gastroenterol.Hepatol.* 2006; **4**: 1130-1134.

Ref Type: Journal

12. Burrows NP, Jones RR. Crohn's disease in association with hidradenitis suppurativa. *Br.J Dermatol.* 1992; **126**: 523.

Ref Type: Journal

13. Ostlere LS, Langtry JA, Mortimer PS, Staughton RC. Hidradenitis suppurativa in Crohn's disease. *Br.J Dermatol.* 1991; **125**: 384-386.

Ref Type: Journal

14. Roy MK, Appleton MA, Delicata RJ, Sharma AK, Williams GT, Carey PD. Probable association between hidradenitis suppurativa and Crohn's disease: significance of epithelioid granuloma. *Br.J Surg.* 1997; **84**: 375-376.

Ref Type: Journal

15. Attanoos RL, Appleton MA, Hughes LE, Ansell ID, Douglas-Jones AG, Williams GT. Granulomatous hidradenitis suppurativa and cutaneous Crohn's disease. *Histopathology* 1993; **23**: 111-115.

Ref Type: Journal

16. Church JM, Fazio VW, Lavery IC, Oakley JR, Milsom JW. The differential diagnosis and comorbidity of hidradenitis suppurativa and perianal Crohn's disease. *Int.J Colorectal Dis.* 1993; **8**: 117-119.

Ref Type: Journal

17. Rosi YL, Lowe L, Kang S. Treatment of hidradenitis suppurativa with infliximab in a patient with Crohn's disease. *J Dermatolog.Treat.* 2005; **16**: 58-61.

Ref Type: Journal

18. Roussomoustakaki M, Dimoulios P, Chatzicostas C, Kritikos HD, Romanos J, Panayiotides JG, Kouroumalis EA. Hidradenitis suppurativa associated with Crohn's disease and spondyloarthritis: response to anti-TNF therapy. *J Gastroenterol* 2003; **38**: 1000-1004.

Ref Type: Journal

19. Kelly AM, Cronin P. MRI features of hidradenitis suppurativa and review of the literature. *AJR Am.J Roentgenol.* 2005; **185**: 1201-1204.

Ref Type: Journal

20. Beaugerie L, Seksik P, Nion-Larmurier I, Gendre JP, Cosnes J. Predictors of Crohn's disease. *Gastroenterology* 2006; **130**: 650-656.

Ref Type: Journal

- 1
2
3 21. Lakatos PL, Czeglédi Z, Szamosi T, Banai J, David G, Zsigmond F, Pandur T,
4 Erdelyi Z, Gemela O, Papp J, Lakatos L. Perianal disease, small bowel disease,
5 smoking, prior steroid or early azathioprine/biological therapy are predictors of
6 disease behavior change in patients with Crohn's disease. *World J Gastroenterol*
7 2009; **15**: 3504-3510.

8
9 Ref Type: Journal

- 10
11 22. Sahni VA, Ahmad R, Burling D. Which method is best for imaging of perianal
12 fistula? *Abdom.Imaging* 2008; **33**: 26-30.

13
14 Ref Type: Journal

- 15
16 23. Schwartz DA, Wiersema MJ, Dudiak KM, Fletcher JG, Clain JE, Tremaine WJ,
17 Zinsmeister AR, Norton ID, Boardman LA, Devine RM, Wolff BG, Young-
18 Fadok TM, Diehl NN, Pemberton JH, Sandborn WJ. A comparison of endoscopic
19 ultrasound, magnetic resonance imaging, and exam under anesthesia for
20 evaluation of Crohn's perianal fistulas. *Gastroenterology* 2001; **121**: 1064-1072.

21
22 Ref Type: Journal

- 23
24 24. Orsoni P, Barthet M, Portier F, Panuel M, Desjeux A, Grimaud JC. Prospective
25 comparison of endosonography, magnetic resonance imaging and surgical
26 findings in anorectal fistula and abscess complicating Crohn's disease. *Br.J Surg.*
27 1999; **86**: 360-364.

28
29 Ref Type: Journal

- 30
31 25. Buchanan GN, Halligan S, Bartram CI, Williams AB, Tarroni D, Cohen CR.
32 Clinical examination, endosonography, and MR imaging in preoperative
33 assessment of fistula in ano: comparison with outcome-based reference standard.
34 *Radiology* 2004; **233**: 674-681.

35
36 Ref Type: Journal

- 37
38 26. Present DH, Korelitz BI, Wisch N, Glass JL, Sachar DB, Pasternack BS.
39 Treatment of Crohn's disease with 6-mercaptopurine. A long-term, randomized,
40 double-blind study. *N.Engl.J.Med.* 1980; **302**: 981-987.

41
42 Ref Type: Journal

- 43
44 27. Present DH, Rutgeerts P, Targan S, Hanauer SB, Mayer L, van Hogezaand RA,
45 Podolsky DK, Sands BE, Braakman T, DeWoody KL, Schaible TF, van Deventer
46 SJ. Infliximab for the treatment of fistulas in patients with Crohn's disease.
47 *N.Engl.J.Med.* 1999; **340**: 1398-1405.

48
49 Ref Type: Journal

- 50
51 28. Sandborn WJ, Present DH, Isaacs KL, Wolf DC, Greenberg E, Hanauer SB,
52 Feagan BG, Mayer L, Johnson T, Galanko J, Martin C, Sandler RS. Tacrolimus
53 for the treatment of fistulas in patients with Crohn's disease: a randomized,
54 placebo-controlled trial. *Gastroenterology* 2003; **125**: 380-388.

55
56 Ref Type: Journal

- 1
2
3 29. Bernstein LH, Frank MS, Brandt LJ, Boley SJ. Healing of perineal Crohn's
4 disease with metronidazole. *Gastroenterology* 1980; **79**: 599.
5
6 Ref Type: Journal
7
- 8 30. Brandt LJ, Bernstein LH, Boley SJ, Frank MS. Metronidazole therapy for perineal
9 Crohn's disease: a follow-up study. *Gastroenterology* 1982; **83**: 383-387.
10
11 Ref Type: Journal
12
- 13 31. Jakobovits J, Schuster MM. Metronidazole therapy for Crohn's disease and
14 associated fistulae. *Am.J Gastroenterol* 1984; **79**: 533-540.
15
16 Ref Type: Journal
17
- 18 32. Turunen U, Farkkila M, Seppala K. What is New and What is Established in
19 Inflammatory Bowel Diseases: *Proceedings of the Athens International Meeting*
20 *on Inflammatory Bowel Diseases* Athens, 19-23 April, 1989. Long-term
21 treatment of peri-anal or fistulous Crohn's disease with ciprofloxacin.
22 *Scandinavian Journal of Gastroenterology* 1989; **24**: 144.
23
24 Ref Type: Journal
25
- 26 33. Solomon M, McLeod R, O'Connor B, Steinhart A, Greenberg G, Cohen Z.
27 Combination ciprofloxacin and metronidazole in severe perineal Crohn's disease.
28 *Can J Gastroenterol* 1993; 571-573.
29
30 Ref Type: Journal
31
- 32 34. Thia KT, Mahadevan U, Feagan BG, Wong C, Cockeram A, Bitton A, Bernstein
33 CN, Sandborn WJ. Ciprofloxacin or metronidazole for the treatment of perianal
34 fistulas in patients with Crohn's disease: a randomized, double-blind, placebo-
35 controlled pilot study. *Inflamm.Bowel.Dis.* 2009; **15**: 17-24.
36
37 Ref Type: Journal
38
- 39 35. Pearson DC, May GR, Fick GH, Sutherland LR. Azathioprine and 6-
40 mercaptopurine in Crohn disease. A meta-analysis. *Ann.Intern.Med.* 1995; **123**:
41 132-142.
42
43 Ref Type: Journal
44
- 45 36. Korelitz BI, Present DH. Favorable effect of 6-mercaptopurine on fistulae of
46 Crohn's disease. *Dig.Dis.Sci.* 1985; **30**: 58-64.
47
48 Ref Type: Journal
49
- 50 37. Jeshion WC, Larsen KL, Jawad AF, Piccoli DA, Verma R, Maller ES, Baldassano
51 RN. Azathioprine and 6-mercaptopurine for the treatment of perianal Crohn's
52 disease in children. *J Clin.Gastroenterol* 2000; **30**: 294-298.
53
54 Ref Type: Journal
55
- 56 38. Dejaco C, Harrer M, Waldhoer T, Miehsler W, Vogelsang H, Reinisch W.
57 Antibiotics and azathioprine for the treatment of perianal fistulas in Crohn's
58 disease. *Aliment.Pharmacol.Ther.* 2003; **18**: 1113-1120.
59
60 Ref Type: Journal

- 1
2
3 39. Sands BE, Anderson FH, Bernstein CN, Chey WY, Feagan BG, Fedorak RN,
4 Kamm MA, Korzenik JR, Lashner BA, Onken JE, Rachmilewitz D, Rutgeerts P,
5 Wild G, Wolf DC, Marsters PA, Travers SB, Blank MA, van Deventer SJ.
6 Infliximab maintenance therapy for fistulizing Crohn's disease. *N.Engl.J.Med.*
7 2004; **350**: 876-885.

8
9 Ref Type: Journal

- 10
11 40. Lichtenstein GR, Yan S, Bala M, Blank M, Sands BE. Infliximab maintenance
12 treatment reduces hospitalizations, surgeries, and procedures in fistulizing Crohn's
13 disease. *Gastroenterology* 2005; **128**: 862-869.

14
15 Ref Type: Journal

- 16
17 41. Ng SC, Plamondon S, Gupta A, Burling D, Kamm MA. Prospective assessment
18 of the effect on quality of life of anti-tumour necrosis factor therapy for perineal
19 Crohn's fistulas. *Aliment.Pharmacol.Ther.* 2009; **30**: 757-766.

20
21 Ref Type: Journal

- 22
23 42. Domenech E, Hinojosa J, Nos P, Garcia-Planella E, Cabre E, Bernal I, Gassull
24 MA. Clinical evolution of luminal and perianal Crohn's disease after inducing
25 remission with infliximab: how long should patients be treated?
26 *Aliment.Pharmacol.Ther.* 2005; **22**: 1107-1113.

27
28 Ref Type: Journal

- 29
30 43. Miheller P, Lakatos PL, Horvath G, Molnar T, Szamosi T, Czeglédi Z, Salamon
31 A, Czimmer J, Rumi G, Palatka K, Papp M, Jakab Z, Szabo A, Gelley A, Lakatos
32 L, Barta Z, Balazs C, Racz I, Zeher M, Dobronte Z, Altorjay I, Hunyady B,
33 Simon L, Papp J, Banai J, Nagy F, Lonovics J, Ujszaszy L, Muzes G, Herszenyi
34 L, Tulassay Z. Efficacy and safety of infliximab induction therapy in Crohn's
35 Disease in Central Europe--a Hungarian nationwide observational study.
36 *BMC.Gastroenterol* 2009; **9**: 66.

37
38 Ref Type: Journal

- 39
40 44. Orlando A, Colombo E, Kohn A, Biancone L, Rizzello F, Viscido A, Sostegni R,
41 Benazzato L, Castiglione F, Papi C, Meucci G, Riegler G, Mocciaro F, Cassinotti
42 A, Cosentino R, Geremia A, Morselli C, Angelucci E, Lavagna A, Rispo A, Bossa
43 F, Scimeca D, Cottone M. Infliximab in the treatment of Crohn's disease:
44 predictors of response in an Italian multicentric open study. *Dig.Liver Dis.* 2005;
45 **37**: 577-583.

46
47 Ref Type: Journal

- 48
49 45. Lichtenstein GR, Diamond RH, Wagner CL, Fasanmade AA, Olson AD, Marano
50 CW, Johanns J, Lang Y, Sandborn WJ. Clinical trial: benefits and risks of
51 immunomodulators and maintenance infliximab for IBD-subgroup analyses
52 across four randomized trials. *Aliment.Pharmacol.Ther.* 2009; **30**: 210-226.

53
54 Ref Type: Journal

- 1
2
3 46. Sokol H, Seksik P, Carrat F, Nion-Larmurier I, Vienne A, Beaugerie L, Cosnes J.
4 Usefulness of co-treatment with immunomodulators in patients with inflammatory
5 bowel disease treated with scheduled infliximab maintenance therapy. *Gut* 2010.
6

7 Ref Type: Journal

- 8
9 47. Colombel JF, Sandborn WJ, Reinisch W, Mantzaris GJ, Kornbluth A,
10 Rachmilewitz D, Lichtiger S, D'Haens G, Diamond RH, Broussard DL, Tang KL,
11 Van der Woude CJ, Rutgeerts P. Infliximab, azathioprine, or combination therapy
12 for Crohn's disease. *N.Engl.J Med* 2010; **362**: 1383-1395.
13

14 Ref Type: Journal

- 15
16 48. Parsi MA, Lashner BA, Achkar JP, Connor JT, Brzezinski A. Type of fistula
17 determines response to infliximab in patients with fistulous Crohn's disease. *Am.J*
18 *Gastroenterol* 2004; **99**: 445-449.
19

20 Ref Type: Journal

- 21
22 49. Regueiro M, Mardini H. Treatment of perianal fistulizing Crohn's disease with
23 infliximab alone or as an adjunct to exam under anesthesia with seton placement.
24 *Inflamm.Bowel.Dis.* 2003; **9**: 98-103.
25

26 Ref Type: Journal

- 27
28 50. Gaertner WB, Decanini A, Mellgren A, Lowry AC, Goldberg SM, Madoff RD,
29 Spencer MP. Does infliximab infusion impact results of operative treatment for
30 Crohn's perianal fistulas? *Dis.Colon Rectum* 2007; **50**: 1754-1760.
31

32 Ref Type: Journal

- 33
34 51. van der Hagen SJ, Baeten CG, Soeters PB, Russel MG, Beets-Tan RG, van
35 Gemert WG. Anti-TNF-alpha (infliximab) used as induction treatment in case of
36 active proctitis in a multistep strategy followed by definitive surgery of complex
37 anal fistulas in Crohn's disease: a preliminary report. *Dis.Colon Rectum* 2005; **48**:
38 758-767.
39

40 Ref Type: Journal

- 41
42 52. Talbot C, Sagar PM, Johnston MJ, Finan PJ, Burke D. Infliximab in the surgical
43 management of complex fistulating anal Crohn's disease. *Colorectal Dis.* 2005; **7**:
44 164-168.
45

46 Ref Type: Journal

- 47
48 53. Guidi L, Ratto C, Semeraro S, Roberto I, De V, I, Papa A, Marzo M, Parello A,
49 Foglietto G, Doglietto GB, Gasbarrini GB, Fedeli G. Combined therapy with
50 infliximab and seton drainage for perianal fistulizing Crohn's disease with anal
51 endosonographic monitoring: a single-centre experience. *Tech.Coloproctol.* 2008;
52 **12**: 111-117.
53

54 Ref Type: Journal

- 55
56 54. Topstad DR, Panaccione R, Heine JA, Johnson DR, MacLean AR, Buie WD.
57 Combined seton placement, infliximab infusion, and maintenance
58
59
60

1
2
3 immunosuppressives improve healing rate in fistulizing anorectal Crohn's disease:
4 a single center experience. *Dis.Colon Rectum* 2003; **46**: 577-583.

5
6 Ref Type: Journal

7
8 55. Poggioli G, Laureti S, Pierangeli F, Rizzello F, Ugolini F, Gionchetti P, Campieri
9 M. Local injection of Infliximab for the treatment of perianal Crohn's disease.
10 *Dis.Colon Rectum* 2005; **48**: 768-774.

11
12 Ref Type: Journal

13
14 56. Asteria CR, Ficari F, Bagnoli S, Milla M, Tonelli F. Treatment of perianal fistulas
15 in Crohn's disease by local injection of antibody to TNF-alpha accounts for a
16 favourable clinical response in selected cases: a pilot study.
17 *Scand.J.Gastroenterol.* 2006; **41**: 1064-1072.

18
19 Ref Type: Journal

20
21 57. Colombel JF, Sandborn WJ, Rutgeerts P, Enns R, Hanauer SB, Panaccione R,
22 Schreiber S, Byczkowski D, Li J, Kent JD, Pollack PF. Adalimumab for
23 maintenance of clinical response and remission in patients with Crohn's disease:
24 the CHARM trial. *Gastroenterology* 2007; **132**: 52-65.

25
26 Ref Type: Journal

27
28 58. Hanauer SB, Sandborn WJ, Rutgeerts P, Fedorak RN, Lukas M, MacIntosh D,
29 Panaccione R, Wolf D, Pollack P. Human anti-tumor necrosis factor monoclonal
30 antibody (adalimumab) in Crohn's disease: the CLASSIC-I trial.
31 *Gastroenterology* 2006; **130**: 323-333.

32
33 Ref Type: Journal

34
35 59. Sandborn WJ, Rutgeerts P, Enns R, Hanauer SB, Colombel JF, Panaccione R,
36 D'Haens G, Li J, Rosenfeld MR, Kent JD, Pollack PF. Adalimumab induction
37 therapy for Crohn disease previously treated with infliximab: a randomized trial.
38 *Ann.Intern.Med* 2007; **146**: 829-838.

39
40 Ref Type: Journal

41
42 60. Hinojosa J, Gomollon F, Garcia S, Bastida G, Cabriada JL, Saro C, Ceballos D,
43 Penate M, Gassull MA. Efficacy and safety of short-term adalimumab treatment
44 in patients with active Crohn's disease who lost response or showed intolerance to
45 infliximab: a prospective, open-label, multicentre trial. *Aliment.Pharmacol.Ther.*
46 2007; **25**: 409-418.

47
48 Ref Type: Journal

49
50 61. Colombel JF, Schwartz DA, Sandborn WJ, Kamm MA, D'Haens G, Rutgeerts P,
51 Enns R, Panaccione R, Schreiber S, Li J, Kent JD, Lomax KG, Pollack PF.
52 Adalimumab for the treatment of fistulas in patients with Crohn's disease. *Gut*
53 2009; **58**: 940-948.

54
55 Ref Type: Journal

56
57 62. Sandborn WJ, Present DH, Isaacs KL, Wolf DC, Greenberg E, Hanauer SB,
58 Feagan BG, Mayer L, Johnson T, Galanko J, Martin C, Sandler RS. Tacrolimus
59
60

1
2
3 for the treatment of fistulas in patients with Crohn's disease: a randomized,
4 placebo-controlled trial. *Gastroenterology* 2003; **125**: 380-388.

5
6 Ref Type: Journal

7
8 63. Gonzalez-Lama Y, Abreu L, Vera MI, Pastrana M, Tabernero S, Revilla J, Duran
9 JG, Escartin P. Long-term oral tacrolimus therapy in refractory to infliximab
10 fistulizing Crohn's disease: a pilot study. *Inflamm.Bowel.Dis.* 2005; **11**: 8-15.

11
12 Ref Type: Journal

13
14 64. Hart AL, Plamondon S, Kamm MA. Topical tacrolimus in the treatment of
15 perianal Crohn's disease: exploratory randomized controlled trial.
16 *Inflamm.Bowel.Dis.* 2007; **13**: 245-253.

17
18 Ref Type: Journal

19
20 65. Casson DH, Eltumi M, Tomlin S, Walker-Smith JA, Murch SH. Topical
21 tacrolimus may be effective in the treatment of oral and perineal Crohn's disease.
22 *Gut* 2000; **47**: 436-440.

23
24 Ref Type: Journal

25
26 66. Vasiliauskas EA, Kam LY, Abreu-Martin MT, Hassard PV, Papadakis KA, Yang
27 H, Zeldis JB, Targan SR. An open-label pilot study of low-dose thalidomide in
28 chronically active, steroid-dependent Crohn's disease. *Gastroenterology* 1999;
29 **117**: 1278-1287.

30
31 Ref Type: Journal

32
33 67. Ehrenpreis ED, Kane SV, Cohen LB, Cohen RD, Hanauer SB. Thalidomide
34 therapy for patients with refractory Crohn's disease: an open-label trial.
35 *Gastroenterology* 1999; **117**: 1271-1277.

36
37 Ref Type: Journal

38
39 68. Plamondon S, Ng SC, Kamm MA. Thalidomide in luminal and fistulizing Crohn's
40 disease resistant to standard therapies. *Aliment.Pharmacol.Ther.* 2007; **25**: 557-
41 567.

42
43 Ref Type: Journal

44
45 69. Mahadevan U, Marion JF, Present DH. Fistula response to methotrexate in
46 Crohn's disease: a case series. *Aliment.Pharmacol.Ther.* 2003; **18**: 1003-1008.

47
48 Ref Type: Journal

49
50 70. Schroder O, Blumenstein I, Schulte-Bockholt A, Stein J. Combining infliximab
51 and methotrexate in fistulizing Crohn's disease resistant or intolerant to
52 azathioprine. *Aliment.Pharmacol.Ther.* 2004; **19**: 295-301.

53
54 Ref Type: Journal

55
56 71. Griggs L, Schwartz DA. Medical options for treating perianal Crohn's disease.
57 *Dig.Liver Dis.* 2007; **39**: 979-987.

58
59 Ref Type: Journal

- 1
2
3 72. Valentine JF, Fedorak RN, Feagan B, Fredlund P, Schmitt R, Ni P, Humphries TJ.
4 Steroid-sparing properties of sargramostim in patients with corticosteroid-
5 dependent Crohn's disease: a randomised, double-blind, placebo-controlled, phase
6 2 study. *Gut* 2009; **58**: 1354-1362.

7
8 Ref Type: Journal
9

- 10 73. Magno P, Jimenez CE, Ortiz Z, Torres EA. Recombinant human granulocyte-
11 macrophage colony stimulating factor (sargramostim) as an alternative therapy for
12 fistulizing Crohn's disease. *P.R.Health Sci.J* 2010; **29**: 60-65.

13
14 Ref Type: Journal
15

- 16 74. Noyer CM, Brandt LJ. Hyperbaric oxygen therapy for perineal Crohn's disease.
17 *Am.J Gastroenterol* 1999; **94**: 318-321.

18
19 Ref Type: Journal
20

- 21 75. Weisz G, Lavy A, Adir Y, Melamed Y, Rubin D, Eidelman S, Pollack S.
22 Modification of in vivo and in vitro TNF-alpha, IL-1, and IL-6 secretion by
23 circulating monocytes during hyperbaric oxygen treatment in patients with
24 perianal Crohn's disease. *J Clin.Immunol* 1997; **17**: 154-159.

25
26 Ref Type: Journal
27

- 28 76. Colombel JF, Mathieu D, Bouault JM, Lesage X, Zavadil P, Quandalle P, Cortot
29 A. Hyperbaric oxygenation in severe perineal Crohn's disease. *Dis.Colon Rectum*
30 1995; **38**: 609-614.

31
32 Ref Type: Journal
33

- 34 77. Lavy A, Weisz G, Adir Y, Ramon Y, Melamed Y, Eidelman S. Hyperbaric
35 oxygen for perianal Crohn's disease. *J Clin.Gastroenterol* 1994; **19**: 202-205.

36
37 Ref Type: Journal
38

- 39 78. Nelson EW, Jr., Bright DE, Villar LF. Closure of refractory perineal Crohn's
40 lesion. Integration of hyperbaric oxygen into case management. *Dig.Dis.Sci.*
41 1990; **35**: 1561-1565.

42
43 Ref Type: Journal
44

- 45 79. Fukuda Y, Takazoe M, Sugita A, Kosaka T, Kinjo F, Otani Y, Fujii H, Koganei
46 K, Makiyama K, Nakamura T, Suda T, Yamamoto S, Ashida T, Majima A,
47 Morita N, Murakami K, Oshitani N, Takahama K, Tochiara M, Tsujikawa T,
48 Watanabe M. Oral spherical adsorptive carbon for the treatment of intractable
49 anal fistulas in Crohn's disease: a multicenter, randomized, double-blind, placebo-
50 controlled trial. *Am.J Gastroenterol* 2008; **103**: 1721-1729.

51
52 Ref Type: Journal
53

- 54 80. Van AG, Vanbeckevoort D, Bielen D, Coremans G, Aerden I, Noman M,
55 D'Hoore A, Penninckx F, Marchal G, Cornillie F, Rutgeerts P. Magnetic
56 resonance imaging of the effects of infliximab on perianal fistulizing Crohn's
57 disease. *Am.J.Gastroenterol.* 2003; **98**: 332-339.

58
59 Ref Type: Journal
60

- 1
2
3
4
5
6
7
8
9
81. Spradlin NM, Wise PE, Herline AJ, Muldoon RL, Rosen M, Schwartz DA. A randomized prospective trial of endoscopic ultrasound to guide combination medical and surgical treatment for Crohn's perianal fistulas. *Am.J Gastroenterol* 2008; **103**: 2527-2535.

Ref Type: Journal

- 10
11
12
13
14
15
16
82. Sands BE, Blank MA, Diamond RH, Barrett JP, van Deventer SJ. Maintenance infliximab does not result in increased abscess development in fistulizing Crohn's disease: results from the ACCENT II study. *Aliment.Pharmacol.Ther.* 2006; **23**: 1127-1136.

Ref Type: Journal

- 17
18
19
20
21
22
83. Mizrahi N, Wexner SD, Zmora O, Da SG, Efron J, Weiss EG, Vernava AM, III, Noguerras JJ. Endorectal advancement flap: are there predictors of failure? *Dis.Colon Rectum* 2002; **45**: 1616-1621.

Ref Type: Journal

- 23
24
25
26
27
28
84. Sonoda T, Hull T, Piedmonte MR, Fazio VW. Outcomes of primary repair of anorectal and rectovaginal fistulas using the endorectal advancement flap. *Dis.Colon Rectum* 2002; **45**: 1622-1628.

Ref Type: Journal

- 29
30
31
32
33
85. Zimmerman DD, Delemarre JB, Gosselink MP, Hop WC, Briel JW, Schouten WR. Smoking affects the outcome of transanal mucosal advancement flap repair of trans-sphincteric fistulas. *Br.J Surg.* 2003; **90**: 351-354.

Ref Type: Journal

- 34
35
36
37
38
39
86. Vitton V, Gasmi M, Barthet M, Desjeux A, Orsoni P, Grimaud JC. Long-term healing of Crohn's anal fistulas with fibrin glue injection. *Aliment.Pharmacol.Ther.* 2005; **21**: 1453-1457.

Ref Type: Journal

- 40
41
42
43
44
45
46
47
87. Grimaud JC, Munoz-Bongrand N, Siproudhis L, Abramowitz L, Senejoux A, Vitton V, Gambiez L, Flourie B, Hebuterne X, Louis E, Coffin B, De P, V, Savoye G, Soule JC, Bouhnik Y, Colombel JF, Contou JF, Francois Y, Mary JY, Lemann M. Fibrin glue is effective healing perianal fistulas in patients with Crohn's disease. *Gastroenterology* 2010; **138**: 2275-81, 2281.

Ref Type: Journal

- 48
49
50
51
52
53
88. Abel ME, Chiu YS, Russell TR, Volpe PA. Autologous fibrin glue in the treatment of rectovaginal and complex fistulas. *Dis.Colon Rectum* 1993; **36**: 447-449.

Ref Type: Journal

- 54
55
56
57
58
59
60
89. Venkatesh KS, Ramanujam P. Fibrin glue application in the treatment of recurrent anorectal fistulas. *Dis.Colon Rectum* 1999; **42**: 1136-1139.

Ref Type: Journal

- 1
2
3 90. Cintron JR, Park JJ, Orsay CP, Pearl RK, Nelson RL, Sone JH, Song R, Abcarian
4 H. Repair of fistulas-in-ano using fibrin adhesive: long-term follow-up. *Dis.Colon*
5 *Rectum* 2000; **43**: 944-949.

6
7 Ref Type: Journal

- 8
9 91. Lindsey I, Smilgin-Humphreys MM, Cunningham C, Mortensen NJ, George BD.
10 A randomized, controlled trial of fibrin glue vs. conventional treatment for anal
11 fistula. *Dis.Colon Rectum* 2002; **45**: 1608-1615.

12
13 Ref Type: Journal

- 14
15 92. Zmora O, Mizrahi N, Rotholtz N, Pikarsky AJ, Weiss EG, Nogueras JJ, Wexner
16 SD. Fibrin glue sealing in the treatment of perineal fistulas. *Dis.Colon Rectum*
17 2003; **46**: 584-589.

18
19 Ref Type: Journal

- 20
21 93. Sentovich SM. Fibrin glue for anal fistulas: long-term results. *Dis.Colon Rectum*
22 2003; **46**: 498-502.

23
24 Ref Type: Journal

- 25
26 94. Loungnarath R, Dietz DW, Mutch MG, Birnbaum EH, Kodner IJ, Fleshman JW.
27 Fibrin glue treatment of complex anal fistulas has low success rate. *Dis.Colon*
28 *Rectum* 2004; **47**: 432-436.

29
30 Ref Type: Journal

- 31
32 95. Singer M, Cintron J, Nelson R, Orsay C, Bastawrous A, Pearl R, Sone J, Abcarian
33 H. Treatment of fistulas-in-ano with fibrin sealant in combination with intra-
34 adhesive antibiotics and/or surgical closure of the internal fistula opening.
35 *Dis.Colon Rectum* 2005; **48**: 799-808.

36
37 Ref Type: Journal

- 38
39 96. Chung W, Ko D, Sun C, Raval MJ, Brown CJ, Phang PT. Outcomes of anal
40 fistula surgery in patients with inflammatory bowel disease. *Am.J Surg.* 2010;
41 **199**: 609-613.

42
43 Ref Type: Journal

- 44
45 97. De P, V, Far HS, Etienney I, Zeitoun JD, Atienza P, Bauer P. Seton drainage and
46 fibrin glue injection for complex anal fistulas. *Colorectal Dis.* 2010; **12**: 459-463.

47
48 Ref Type: Journal

- 49
50 98. O'Connor L, Champagne BJ, Ferguson MA, Orangio GR, Schertzer ME,
51 Armstrong DN. Efficacy of anal fistula plug in closure of Crohn's anorectal
52 fistulas. *Dis.Colon Rectum* 2006; **49**: 1569-1573.

53
54 Ref Type: Journal

- 55
56 99. van Koperen PJ, D'Hoore A, Wolthuis AM, Bemelman WA, Slors JF. Anal fistula
57 plug for closure of difficult anorectal fistula: a prospective study. *Dis.Colon*
58 *Rectum* 2007; **50**: 2168-2172.

59
60 Ref Type: Journal

- 1
2
3
4
5
6
7
8
9
10
11
12
13
14
15
16
17
18
19
20
21
22
23
24
25
26
27
28
29
30
31
32
33
34
35
36
37
38
39
40
41
42
43
44
45
46
47
48
49
50
51
52
53
54
55
56
57
58
59
60
100. Ky AJ, Sylla P, Steinhagen R, Steinhagen E, Khaitov S, Ly EK. Collagen fistula plug for the treatment of anal fistulas. *Dis.Colon Rectum* 2008; **51**: 838-843.
Ref Type: Journal
101. Schwandner O, Stadler F, Dietl O, Wirsching RP, Fuerst A. Initial experience on efficacy in closure of cryptoglandular and Crohn's transsphincteric fistulas by the use of the anal fistula plug. *Int.J Colorectal Dis.* 2008; **23**: 319-324.
Ref Type: Journal
102. Christoforidis D, Etzioni DA, Goldberg SM, Madoff RD, Mellgren A. Treatment of complex anal fistulas with the collagen fistula plug. *Dis.Colon Rectum* 2008; **51**: 1482-1487.
Ref Type: Journal
103. Schwandner O, Fuerst A. Preliminary results on efficacy in closure of transsphincteric and rectovaginal fistulas associated with Crohn's disease using new biomaterials. *Surg.Innov.* 2009; **16**: 162-168.
Ref Type: Journal
104. Safar B, Jobanputra S, Sands D, Weiss EG, Nogueras JJ, Wexner SD. Anal fistula plug: initial experience and outcomes. *Dis.Colon Rectum* 2009; **52**: 248-252.
Ref Type: Journal
105. Zubaidi A, Al-Obeed O. Anal fistula plug in high fistula-in-ano: an early Saudi experience. *Dis.Colon Rectum* 2009; **52**: 1584-1588.
Ref Type: Journal
106. Owen G, Keshava A, Stewart P, Patterson J, Chapuis P, Bokey E, Rickard M. Plugs unplugged. Anal fistula plug: the Concord experience. *ANZ.J Surg.* 2010; **80**: 341-343.
Ref Type: Journal
107. Himpson RC, Cohen CR, Sibbons P, Phillips RK. An experimentally successful new sphincter-conserving treatment for anal fistula. *Dis.Colon Rectum* 2009; **52**: 602-608.
Ref Type: Journal
108. Ascanelli S, de TD, Gregorio C, Azzena G, Occhionorelli S. Autologous fibroblasts transplant after infliximab administration: a new approach in Crohn's perianal fistulas? Brief clinical report. *Int.J.Colorectal Dis.* 2007; **22**: 1135-1136.
Ref Type: Journal
109. Garcia-Olmo D, Garcia-Arranz M, Herreros D. Expanded adipose-derived stem cells for the treatment of complex perianal fistula including Crohn's disease. *Expert.Opin.Biol.Ther.* 2008; **8**: 1417-1423.
Ref Type: Journal

- 1
2
3 110. Yamamoto T, Allan RN, Keighley MR. Effect of fecal diversion alone on perianal
4 Crohn's disease. *World J.Surg.* 2000; **24**: 1258-1262.

5
6 Ref Type: Journal

- 7
8 111. Hong MK, Lynch AC, Bell S, Woods RJ, Keck JO, Johnston MJ, Heriot AG.
9 Faecal Diversion in the Management of Perianal Crohn's Disease. *Colorectal Dis.*
10 2009.

11 Ref Type: Journal

- 12
13 112. Thomas M, Bienkowski R, Vandermeer TJ, Trostle D, Cagir B. Malignant
14 transformation in perianal fistulas of Crohn's disease: a systematic review of
15 literature. *J Gastrointest.Surg.* 2010; **14**: 66-73.

16
17 Ref Type: Journal
18
19
20
21
22
23
24
25
26
27
28
29
30
31
32
33
34
35
36
37
38
39
40
41
42
43
44
45
46
47
48
49
50
51
52
53
54
55
56
57
58
59
60

For Peer Review

Tables for CPD Mx review

Table 1. Randomised Controlled Trials (RCT) or meta-analyses of **established** medical treatments of Crohn's-related perianal fistulas

Drug	Study	Type of study	n	FU at end point	Fistula remission	
					Rx	Placebo
Metronidazole	Thia 2009 (93)	RCT	7	10 weeks	0%	12.5%
Ciprofloxacin	Thia 2009 (93)	RCT	10	10 weeks	30%	12.5%
Aza/6-MP	Pearson 1995 (64)	Metaanalysis	41	-	*54%	*21%
Tacrolimus	Sandborn 2003 (75)	RCT	42	10 weeks	10%	8%
Infliximab	Present 1999 (68)	RCT induction	94	14 weeks	55%	13%
Infliximab	Accent II (78)	RCT maintenance	282	54 weeks	36%	19%
Adalimumab	CHARM # (20)	RCT maintenance	113	56 weeks	33%	13%

* = remission and response included together

= In CHARM patient with luminal and perianal Crohn's disease were assessed

Table 2. Studies of fistula glue in anal fistula including Crohn's patients

Study	Year	FU (months)	Routine preop seton	Total n	Crohn's n	Overall success rate	Crohn's success rate
Abel+ (1)	1993	3-12	No	10	3	6/10 (60%)	1/3 (33%)
Venkatesh# (100)	1999	12	No	30	6	18/30 (60%)	0/6 (0%)
Cintron# (16)	2000	12	No	79	6	48/79 (61%)	2/6 (33%)
Lindsey (47)	2002	17.1	No	19	2	12/19 (63%)	2/2 (100%)
Zmora (105)	2003	12.1	No	24	5	8/24 (33%)	2/5 (40%)
Sentovich (86)	2003	22	Yes	48	5	33/48 (69%)	4/5 (80%)
Loungnarath (48)	2004	26	No	39	13	12/39 (31%)	4/13 (31%)
Singer# (87)	2005	27	No	75	3	25-44%	0/3 (0%)
Vitton# (101)	2005	23.4	No	14	14	8/14 (57%)	8/14 (57%)
Chung\$ (14)	2010	3	No	(81)	2	23/79 (29%)	0/1 (0%)
de Parades# (23)	2010	11.7	Yes	30	11	15/30 (50%)	7/11 (63.6%)
Grimaud# (31)	2010	2	No	34	34	13/34 (38%)	13/34 (38%)

#Includes some rectovaginal fistulas

+The one success in the CD group had a RECTOVAGINAL FISTULA (RVF) which healed after 2 treatments

\$Idiopathic results from contemporary but separately published results by same authors

Table 3. Studies of the fistula plug in anal fistula including Crohn's patients

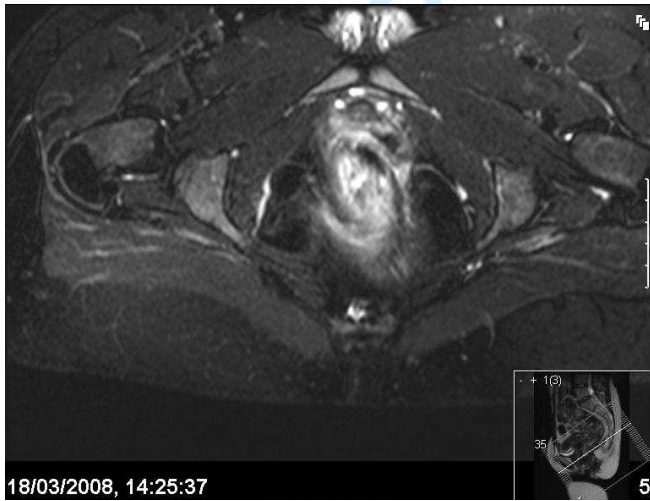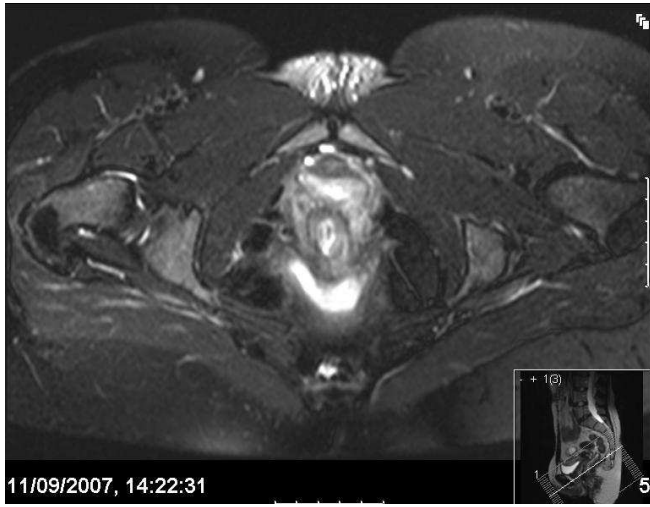Study	Year	FU (months)	Routine preop seton	Total n	Crohn's n	Success rate	Crohn's success rate
O'Connor* (58)	2006	10	depend s	20	20	16/20 (80%)	16/20 (80%)
van Koperen (97)	2007	7	No	17	1	7/17 (41%)	1/1 (100%)
Ky (42)	2008	6.5	No	44	14	24/44 (54.6%)	4/14 (26.6%)
Schwandner (83)	2008	9	No	18	7	12/18 (61%)	6/7 (85.7%)
Christofordis (13)	2008	6.5	No	47	3	20/47 (43%)	NR
Schwandner † (82)	2009	9	No	9	9	7/9 (77%)	7/9 (77%)
Safar (72)	2009	4	No	36	4	5/36 (13.9)	1/4 (25%)
Zubaidi (106)	2009	12	No	22	2	19/22 (86%)	1/2 (50%)
Chung\$ (14)	2010	3	No	50	4	27/46 (59%)	3/4 (75%)
Owen (62)	2010	15		35	3	13/35 (37%)	1/3 (33%)

*The O'Connor study included one pouch patient, 2 anovaginal fistulas and 4 patients on concomitant infliximab. Single rather than multiple tracts were significantly associated with successful closure. Preoperative setons were used if the tract was too wide for the plug to sit snugly.

NR – not reported or cannot be concluded from the data presented

1
2
3
4
5
6
7
8
9
10
11
12
13
14
15
16
17
18
19
20
21
22
23
24
25
26
27
28
29
30
31
32
33
34
35
36
37
38
39
40
41
42
43
44
45
46
47
48
49
50
51
52
53
54
55
56
57
58
59
60

Figures for CPD Mx review



b

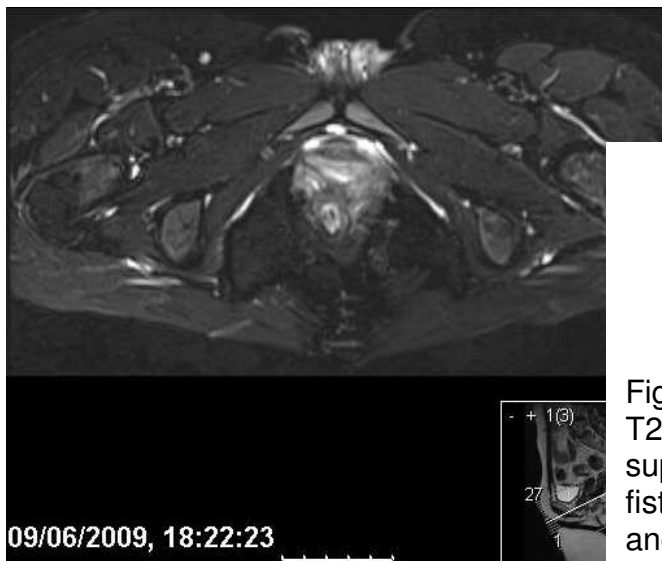
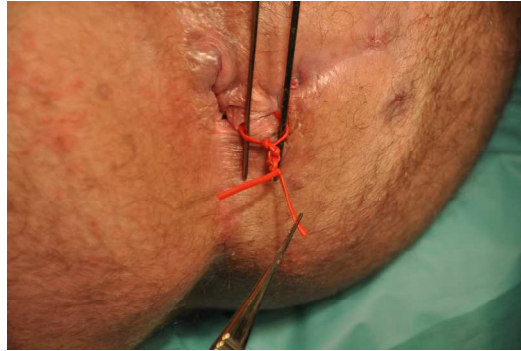


Figure 1. T2 weighted pelvic MRI images with fat suppression showing improvement of anal fistula from baseline (a) at six months (b) and 21 months (c).



a.

b.

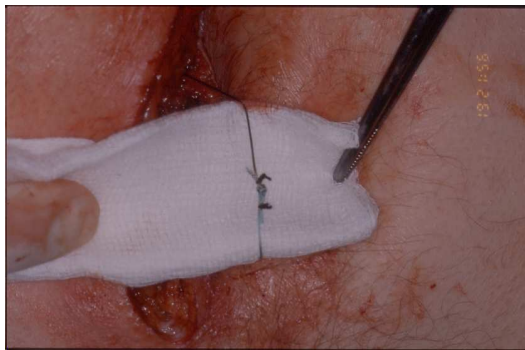


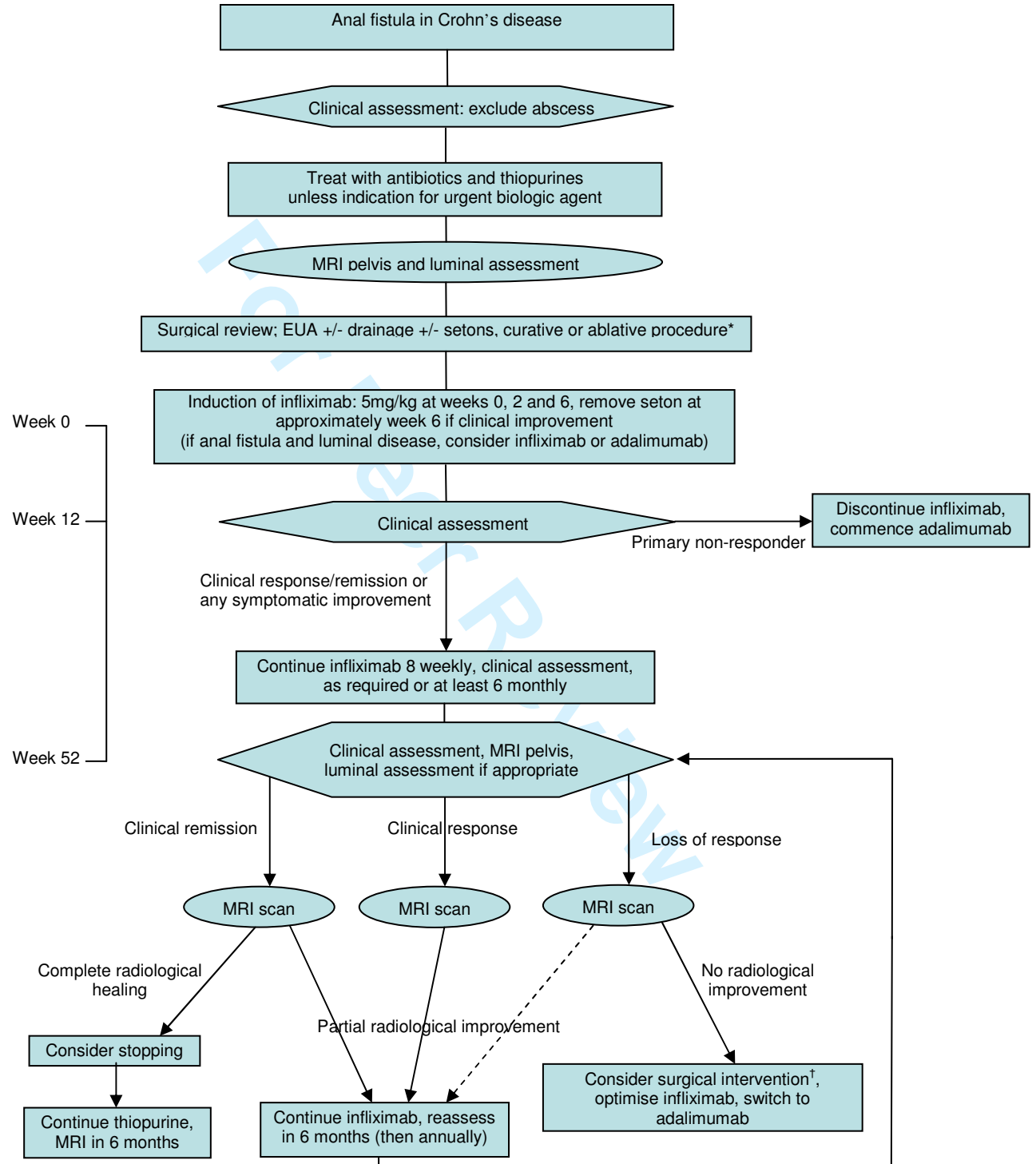
Figure 2. a. A bulky silastic seton and b. a low profile ethibond seton with just three throws and the 'whiskers' tied back with silk.

Review

1
2
3
4
5
6
7
8
9
10
11
12
13
14
15
16
17
18
19
20
21
22
23
24
25
26
27
28
29
30
31
32
33
34
35
36
37
38
39
40
41
42
43
44
45
46
47
48
49
50
51
52
53
54
55
56
57
58
59
60

Figure 3

Algorithm for the management of anal fistulae in Crohn's disease



1
2
3
4
5
6
7
8
9
10
11
12
13
14
15
16
17
18
19
20
21
22
23
24
25
26
27
28
29
30
31
32
33
34
35
36
37
38
39
40
41
42
43
44
45
46
47
48
49
50
51
52
53
54
55
56
57
58
59
60

*** Curative surgery**

A few patients with moderate Crohn's disease may be candidates for curative surgery:

- advancement flap (good rectum, perineal descent/internal intussusception helpful, consider temporary stoma);
- coloanal pull through (rectal internal opening, good anus, good colon, loop ileostomy);
- Turnbull-Cutait[‡] (internal opening at dentate line, good anus, good colon, loop ileostomy);
- fistulotomy +/- delayed sphincter repair (consider temporary stoma).

Some patients with severe and debilitating disease may benefit from ablative surgery[§]

Temporary stoma

Temporary ileostomy/colostomy:

- will not of itself lead to fistula resolution
- may be an adjunct to surgical or medical therapy
- should not be used when proctectomy or proctocolectomy is needed

‡ Turnbull-Cutait procedure

Two stage coloanal.

- 1st stage leaves colon extruded anally for one week;
- 2nd stage trims the colon back to the anus.

† Surgery in loss of response

MRI may indicate undrained sepsis leading to lack or loss of response

- drainage of sepsis should be obtained and further setons inserted
- infliximab maintenance should then recommence
- further clinical assessment in 6 months

§ Ablative surgery

Perianal fistulae alone are unlikely to lead to very poor general health with restriction of work or social activities; colorectal disease is likely to be to blame. In this case:

- medical management should be optimised;
- if this fails, proctectomy or proctocolectomy (dependent on the extent of disease) should be considered;
- advice regarding the risk of delayed or poor perineal wound healing should be given.

1
2
3
4
5
6
7
8
9
10
11
12
13
14
15
16
17
18
19
20
21
22
23
24
25
26
27
28
29
30
31
32
33
34
35
36
37
38
39
40
41
42
43
44
45
46
47
48
49
50
51
52
53
54
55
56
57
58
59
60

¥ Incidental cryptoglandular fistulae

Rarely, a cryptoglandular fistula will occur in a patient with Crohn's disease:

- the anorectum will be entirely normal and unaffected by Crohn's disease;
- there will be very limited luminal disease;
- treatment should be surgical, as for other cryptoglandular fistulae, except with greater sphincter preservation because of the risk of diarrhoea in the future.

For Peer Review

1
2
3
4
5
6
7
8
9
10
11
12
13
14
15
16
17
18
19
20
21
22
23
24
25
26
27
28
29
30
31
32
33
34
35
36
37
38
39
40
41
42
43
44
45
46
47
48
49
50
51
52
53
54
55
56
57
58
59
60