



HAL
open science

INFLAMMATORY MANIFESTATIONS AT COLONOSCOPY IN PATIENTS WITH COLONIC DIVERTICULAR DISEASE

Antonio Tursi, Walter Elisei, Gianmarco Giorgetti, Fabio Aiello, Giovanni
Brandimarte

► **To cite this version:**

Antonio Tursi, Walter Elisei, Gianmarco Giorgetti, Fabio Aiello, Giovanni Brandimarte. INFLAMMATORY MANIFESTATIONS AT COLONOSCOPY IN PATIENTS WITH COLONIC DIVERTICULAR DISEASE. *Alimentary Pharmacology and Therapeutics*, 2010, 33 (3), pp.358. 10.1111/j.1365-2036.2010.04530.x . hal-00599496

HAL Id: hal-00599496

<https://hal.science/hal-00599496>

Submitted on 10 Jun 2011

HAL is a multi-disciplinary open access archive for the deposit and dissemination of scientific research documents, whether they are published or not. The documents may come from teaching and research institutions in France or abroad, or from public or private research centers.

L'archive ouverte pluridisciplinaire **HAL**, est destinée au dépôt et à la diffusion de documents scientifiques de niveau recherche, publiés ou non, émanant des établissements d'enseignement et de recherche français ou étrangers, des laboratoires publics ou privés.

**INFLAMMATORY MANIFESTATIONS AT COLONOSCOPY IN
PATIENTS WITH COLONIC DIVERTICULAR DISEASE**

| | |
|-------------------------------|-------------------------------------------------------------------------------------------------------------------------------------------------------------------------------------------------------------------------------------------------------------------------------------------------------------------------------------------------------------------------------------------------------------------------------------------|
| Journal: | <i>Alimentary Pharmacology & Therapeutics</i> |
| Manuscript ID: | APT-0622-2010.R5 |
| Wiley - Manuscript type: | Original Scientific Paper |
| Date Submitted by the Author: | 12-Nov-2010 |
| Complete List of Authors: | Tursi, Antonio; GI Endoscopy, Andria, Italy ELISEI, Walter; "Cristo Re" Hospital, Department of Internal Medicine, Division of Gastroenterology GIORGETTI, GianMarco; "S. Eugenio" Hospital, Clinical Nutrition Unit AIELLO, Fabio; University of Palermo, Department of Quantitative Methods for Human Sciences Brandimarte, Giovanni; "Cristo Re" Hospital,, Department of Internal Medicine, Division of Gastroenterology, |
| Keywords: | Diverticular disease < Disease-based, Ulcerative colitis < Disease-based, Large intestine < Organ-based, Colonoscopy < Topics, General practice < Topics |
| | |

Original Paper to *Alimentary Pharmacology & Therapeutics*

**INFLAMMATORY MANIFESTATIONS AT COLONOSCOPY IN PATIENTS
WITH COLONIC DIVERTICULAR DISEASE**

(revised manuscript APT-0622-2010 R4)

Running head: *Inflammation in diverticular disease*

**Antonio TURSI, MD[°], Walter ELISEI, MD^{*}, Gian Marco GIORGETTI, MD[^], Fabio
AIELLO, PhD[#], Giovanni BRANDIMARTE, MD[§].**

[°] Servizio di Gastroenterologia Territoriale, ASL BAT, Andria (BAT)

^{*} U.O.C. di Gastroenterologia, ASL Roma H, Albano Laziale (Roma)

[^] U.O.D. di Endoscopia Digestiva e Nutrizionale, Ospedale "S. Eugenio", Roma

[#] Dipartimento di Scienze Matematiche e Statistiche, Università di Palermo, Palermo

[§] U.O.S. di Gastroenterologia, Ospedale "Cristo Re", Roma

Address for correspondence:

Dr. Antonio Tursi, MD

Servizio di Gastroenterologia Territoriale

DSS n°4, ASL BAT

Via Torino, 49

70031 Andria, Italy

Telephone: +39-0883-551094

Fax: +39-0883-1978225

e-mail: antotursi@tiscali.it

SUMMARY

Background: Ulcerative colitis with diverticulosis (UCD), segmental colitis associated with diverticulosis (SCAD), and acute uncomplicated diverticulitis (AUD) may affect the same colonic regions, but the real incidence of these entities in clinical practice is unknown.

Aim: The aim of our study was to assess the incidence and the endoscopic findings of UCD, SCAD, and AUD.

Methods: From January 2004 to June 2009, 8525 consecutive colonoscopies were performed. Diagnosis of the diseases was based on specific endoscopic and histological (UCD and SCAD), and on endoscopic and radiological (AUD) patterns.

Results: UCD was diagnosed in 25 patients (0.3%), SCAD was diagnosed in 129 patients (1.5%), and AUD was diagnosed in 130 patients (1.5%). In UCD the inflammation in colonic area harbouring diverticula always affects the overall colonic mucosa in all cases, involving also diverticular orifices. The endoscopic characteristic of SCAD is that inflammation is mainly detected within the inter-diverticular mucosa without involvement of the diverticular orifices. In AUD the inflammation affects primarily diverticular orifice and peri-diverticular mucosa.

Conclusions: **In clinical practice, the incidence of mucosal inflammation in the presence of colonic diverticular disease is low and endoscopy is the mainstay of differential diagnosis.**

Key words: diverticulosis, acute uncomplicated diverticulitis, endoscopy, segmental colitis associated with diverticulosis, ulcerative colitis.

INTRODUCTION

Ulcerative colitis (UC), segmental colitis associated with diverticulosis (SCAD), and acute uncomplicated diverticulitis (AUD) are characterized by inflammation of the colonic mucosa that may affect the same colonic regions. In particular, left-sided colon is primarily affected in UC (1), and sigmoid and descending colon are primarily involved in SCAD and AUD (2,3).

UC may be sometimes associated with diverticulosis, although the prevalence of diverticulosis in patients with UC seems to be lower than in general population (4,5).

The incidence of SCAD and, in particular, AUD is now increasing (2,3). The endoscopic findings of these diseases may be similar. The distinction between these three diseases may be extremely difficult, even when the results of endoscopy, surgery, and histological evaluation are available. In years past, distinguishing between UC and SCAD was not a problem, because the incidence of SCAD was low and most of patients were erroneously considered as suffering from UC with diverticulosis (UCD) (6). New endoscopic and histological patterns were proposed for SCAD, with particular attention to the differential diagnosis with inflammatory bowel disease (IBD) (2,6). At the same time, distinguishing between SCAD and AUD may be difficult, since it is still unclear whether SCAD is a complication of diverticular disease or, actually, a clinical autonomous entity (7).

Endoscopy may be useful to differentiate these three entities. The endoscopic findings in UC have been well described (8), as well as new endoscopic criteria in diagnosing SCAD have been recently described (2). However, there have been no attempts to endoscopic classification of AUD.

Moreover, it may be sometimes difficult to differentiate between SCAD and UCD.

We conducted a prospective study to evaluate the incidence of these three entities in clinical practice according to endoscopic classification of these three diseases.

PATIENTS AND METHODS

Study Population

From January 2004 to June 2009, a prospective study was performed involving four primary Endoscopic Centres in central-south Italy (Servizio di Gastroenterologia Territoriale, ASL BAT, Andria (BAT); U.O.C. di Gastroenterologia, ASL Roma H, Albano Laziale (Roma); U.O.D. di Endoscopia Digestiva e Nutrizionale, Ospedale “S. Eugenio”, Roma; U.O.D. di Gastroenterologia, Ospedale “Cristo Re”, Roma).

During the study period 8525 consecutive colonoscopies were performed: 2238 colonoscopies were performed in inpatients, 6287 were performed in outpatients. Colonoscopy was performed due to intestinal symptoms (abdominal pain, diarrhoea, constipation, rectal bleeding) in 6041 patients, whilst it was performed as screening in 1484 patients. Exclusion criteria were: Crohn’s disease, large bowel resection, and a previous endoscopic or radiological diagnosis of colon cancer. Moreover, other forms of chronic colitis (e.g. lymphocytic, collagenous or ischemic), as well as complicated diverticulitis, were excluded by final assessment.

The study was approved by the Institutional review Board, and informed consent was obtained from all patients.

Diagnostic criteria

Diagnostic criteria for, UCD, SCAD, and AUD are summarized in table 1.

Diagnosis of UCD was made according to endoscopic and histological criteria: macroscopic and microscopic inflammation involving the colonic mucosa coming from the rectum to the proximal segments with presence of diverticula in the sigmoid and descending colon (Figure 1). Endoscopic severity was graded according to the “Mayo Subscore for endoscopy” (9):

0: normal mucosal appearance;

1: Erythema, mild mucosal friability, reduction of vascular pattern;

2: Absence of vascular pattern, severe erythema, mucosal friability, erosions;

3. Spontaneous bleeding, ulcerations.

The criteria for SCAD included endoscopic lesions within the sigmoid-descending colon harbouring diverticula, combined with endoscopic and histological rectal and proximal colon sparing (10). The endoscopic classification of SCAD was based on a recent score formulated prospectively by the authors (2). This score isn't based on the progressive severity of the disease, but it is based on the character of the endoscopic damage:

- “Crescentic fold disease”. The colonic mucosa shows some swollen red patches ranging from 0.5 to 1.5 cm in diameter, without hemorrhage or ulceration, confined to the crescentic mucosal fold. Diverticular orifices are always spared.
- “Mild-to moderate ulcerative colitis-like” pattern (Figure 2). This endoscopic pattern includes diffuse loss of vascular pattern, mucosal edema and hyperemia and diffuse erosions. Also in these cases diverticular orifices are always spared.
- “Crohn's disease colitis-like” pattern. This endoscopic pattern shows scattered aphthous ulcers, which may be found within a normal colonic mucosa. Diverticular orifices are always spared.
- “Severe ulcerative colitis-like” pattern. This endoscopic pattern shows diffuse loss of vascular pattern, diffuse hyperemia, and easy bleeding at contact with colonoscope. Edema in the mucosa with ulcerations was marked, sometimes with reduction of the lumen. The diverticular orifices are not always easy to recognize, but they may be visible and spared by inflammation at maximal air inflation. Sometimes, inflammation also involves diverticular orifices. In these cases, differential diagnosis with UCD is based on SCAD rectal sparing.

The endoscopic characteristic of SCAD is that inflammation is mainly detected within the inter-diverticular mucosa without involvement of the diverticular orifices.

Diagnosis of AUD was made according to endoscopic and radiological criteria: macroscopic and microscopic inflammation involving the colon harbouring diverticula, and affecting bowel wall without complications, assessed by Computerized Tomography (CT) scan (12). In particular,

1
2
3 complicated diverticulitis was defined as stage Ib-III or the presence of fistula or obstruction on CT
4
5 according to a modified Hinchey classification (13).
6

7
8 After exclusion of complicated acute diverticulitis on CT scan, patients underwent colonoscopy. As
9
10 there is no endoscopic classification of severity of AUD, endoscopic severity was arbitrarily graded
11
12 as follows:
13

- 14 • Mild (figure 3): diverticular inflammation localized within and around diverticula;
- 15
- 16 • Moderate: diverticular inflammation that affects both peri- and inter-diverticular mucosa;
- 17
- 18 • Severe: inflammation that affects the overall colonic segment harbouring diverticula.
19
20
21
22
23
24

25 *Procedures*

26
27 All patients underwent the same standard bowel preparation for colonoscopy prescribed in our
28
29 centres consisting in an oral polyethylene glycol solution (Selg-Esse, Promefarm, Milano - Italy) to
30
31 be taken during the evening. The following morning pancolonoscopy (clean colon colonoscopy)
32
33 was performed. Using standard biopsy forceps, six biptic samples of colonic mucosa were
34
35 collected in the colonic tract affected by lesions for histological assessment. Moreover, six biptic
36
37 samples of the colonic mucosa were obtained from every other colonic region (ascending,
38
39 transverse colon, and rectum) in order to confirm the histological diagnosis of SCAD.
40
41
42
43
44
45

46 *Statistical assessment*

47
48 Descriptive analysis was performed and continuous data were expressed as the mean (range) and
49
50 categorical data as numbers (percentage).
51
52
53
54
55
56
57
58
59
60

RESULTS

UC was diagnosed in 242 patients (2.8%), and diverticulosis was found in 1104 patients (12.9%). Among them, SCAD was diagnosed in 129 patients (11.4%, 1.5% of the overall studied population), UCD was diagnosed in 25 patients (2.3%, 0.30% of the overall studied population), and AUD was diagnosed in 130 patients (11.8%, 1.5% of the overall studied population). The results are summarized in Table 2.

UCD

According to the above mentioned criteria, UCD was diagnosed in 25 patients (15 Males, 10 Females, mean age 63.68 years, range 63-82 years). The most frequent form of disease diagnosed was procto-sigmoiditis in 13 patients (52.0%), followed by left-sided colitis in 7 subjects (28.0%), and pancolitis in 5 (20.0%). Diverticula were localized in sigmoid region in 14 cases (56.0%) and in sigmoid-descending colon in 11 (44.0%), respectively.

In this disease, the inflammation in colonic area harbouring diverticula always affects the overall colonic mucosa in all cases, involving also diverticular orifices (see figure 2). Rectal bleeding was the most recorded isolated symptom (11 patients, 44%), followed by diarrhea (4 patients, 16%), and by abdominal pain (2 patients, 8%). Eight patients (32%) experienced more than one symptom.

SCAD

According to the above mentioned criteria, SCAD was diagnosed in 129 patients (77 Males, 52 Females, mean age 63.68 years, range 43-87 years). The endoscopic lesions affected primarily inter-diverticular mucosa in 121 patients (93.8%). Only in the severe form of the disease ("Severe ulcerative colitis-like" pattern SCAD) the inflammation involved the overall colonic mucosa in 8 subjects (6.2%). Chronic diarrhea was the most recorded isolated symptom (58 patients, 44.96%),

1
2
3 followed by recurrent abdominal pain (15 patients, 11.63%), and by recurrent rectal bleeding (19
4 patients, 14.73%%). Thirty-seven patients (28,68%) experienced more than one symptom.
5
6
7
8
9

10 11 12 *AUD*

13
14 According to the above mentioned criteria, AUD was diagnosed in 130 patients (81 Males, 49
15 Females, mean age 64.71 years, range 40-85 years). Eighty-three patients (63.8%) referred a
16 previous history of diverticulosis or diverticular disease, whilst diverticular disease was diagnosed
17 for the first time in 47 patients (36.2%). In the 66 inpatients (50.8% of the overall population
18 affected by AUD), we performed an “early colonoscopy” (within 7 days since admission, and after
19 a 7 days course of antibiotic therapy) in patients affected by AUD (11) in order to exclude other
20 diseases (in particular colorectal cancer or IBD) and in order to confirm the AUD diagnosis as soon
21 as possible, whilst in the 64 outpatients (49.2% of the overall population affected by AUD)
22 colonoscopic examination was the first diagnostic tool in diagnosing AUD. No complication was
23 recorded after colonoscopy, and it was able to confirm the radiological diagnosis in all patients
24 undergoing to the intervention. In AUD the inflammation affects primarily diverticular orifice and
25 peri-diverticular mucosa. Actually, we found inflammation restricted to mucosa surrounding
26 diverticular orifices in 64 (49.2%) patients (see figure 3). When the inflammation increases, it
27 begins to involve also inter-diverticular mucosa, as we found in 12 out of 42 patients (28.8%) and in
28 13 out of 21 (61.9%) with moderate and severe form of AUD, respectively. Abdominal pain was the
29 most recorded isolated symptom (79 patients, 60.76%), followed by diarrhea (15 patients, 11.54%),
30 constipation (11 patients, 8.47%) and by rectal bleeding (9 patients, 6.92%). Sixteen patients
31 (12.31%) experienced more than one symptom.
32
33
34
35
36
37
38
39
40
41
42
43
44
45
46
47
48
49
50
51
52
53
54
55
56
57
58
59
60

DISCUSSION

Current literature data showed that incidence of diverticulosis is increasing (14). Most of these patients are suffering from diverticular disease (DD), but often the endoscopists are face up to make a correct differential diagnosis between DD and other diseases in which diverticulosis can be found. This is particularly true in patients affected by UCD and SCAD.

This study showed that the incidence of diverticulosis in UC is low in clinical practice. Two recent studies reported that prevalence of diverticulosis in UC ranges from 2% to 8.2%, affecting in particular patients older than 50 years (4,5). This study found a similar incidence (2.5%), with a mean age of 63.68 years. The first consideration about this study is that incidence of UCD, SCAD, and AUD is low in clinical practice. This results may be related to the overall number of colonoscopies performed in the observed period (8,525 colonoscopies performed in 4 centres during a 4.5 year period). This would appear a quite low endoscopic volume, suggesting that a referral bias is possible. However, we think that this may be also a strength of this study, because it describes what is the real incidence of these diseases in clinical practice.

An interesting finding arising from this study is that SCAD and AUD showed surprising similar incidence. The literature incidence of SCAD ranges from 0.3% and 3.8% (15,16). Two recent prospective studies confirmed that the incidence of SCAD ranged from 0.3% (9) to 1.5% (2). In particular, this last prospective study found that about 12% of patients with diverticulosis is affected by SCAD (2). Our prospective study found a SCAD incidence of 1.4% (11.4% of the population harbouring diverticula) similar to the highest values reported in literature. Although the incidence of this disease is low, considering these results, an endoscopic diagnosis of SCAD may be expected to occur once every 300-400 colonoscopies. This study confirms a low incidence of the disease but an increasing occurrence of new cases may be registered given the high number of colonoscopies currently carried out at our endoscopic centres.

The incidence of AUD is increasing. A recent nationwide inpatient sample survey, performed in United States, found that the incidence of patients admitted with acute diverticulitis raised from

1
2
3 120.500 in 1998 to 151.900 in 2005 (26% increase) (3). Another recent study from United Kingdom
4
5 found that annual admissions for DD (including both symptomatic DD and acute diverticulitis)
6
7 increased from 71 to 263. There was a significant trend of decreasing mean age from 71.2 years in
8
9 1995 to 68.1 years in 2004, and admissions younger than 50 years raised from 8% in 1995 to 42%
10
11 in 2003 (17), with poor outcome in the elderly (18). We found a low AUD incidence of 1.5%
12
13 (11.8% of the population harbouring diverticula). As this study only assessed AUD, it is probably
14
15 that the real incidence of acute diverticulitis is higher than recorded. Actually, we should consider
16
17 that complicated diverticulitis is managed surgically, the acute complicated diverticulitis incidence
18
19 is increasing particularly in younger people (3), and in most of patients with CT findings compatible
20
21 with diverticulitis do not undergo colonoscopy. Performing colonoscopy in acute diverticulitis is
22
23 still controversial, because acute inflammation of the diverticula may be at risk of perforation or
24
25 bleeding (19,20). But recent literature data found that early colonoscopy (within 3 and 11 days after
26
27 the admission) is as safe and effective as late colonoscopy (within 6 and 19 weeks following
28
29 admission), without any complication in both approaches. We performed colonoscopy within 7 days
30
31 after exclusion of complicated diverticulitis [which is considered the only parameter avoiding early
32
33 colonoscopy (11)], and after a course of antibiotic therapy, and we did not record any complication.
34
35 Somebody may argue that computerized tomography colonography (CTC) may have a better
36
37 diagnostic potential for imaging of diverticular disease-specific findings, when compared with
38
39 colonoscopy. Moreover, CTC is less uncomfortable and may be preferred by a majority of patients
40
41 (21). However, we cannot forget that diverticular disease often shows circular muscle hypertrophy,
42
43 that leads to a thickened colonic wall. This condition needs a correct differential diagnosis, since
44
45 colorectal adenocarcinoma or new diagnosis of IBD (namely SCAD or UCD) can be established
46
47 (22). On these bases, colonoscopy is advisable in that patients to make a correct diagnosis. The
48
49 safety of colonoscopy is an important issue in that patients. Our opinion is that an adequate course
50
51 of antibiotic therapy before colonoscopy is a good option to reduce the risk of perforation. We
52
53 performed early colonoscopy after a 7-day course of antibiotic therapy, after careful clinical
54
55
56
57
58
59
60

1
2
3 evaluation and after exclusion of free perforation by abdominal CT. None perforation was recorded
4
5 during or after colonoscopy. So, our opinion is that gentle colonoscopy with minimal air
6
7 insufflation can be carried out safely in that patients. If a diagnosis of diverticulitis is confirmed, the
8
9 procedure may terminate, because the risk of perforation cannot be completely avoided (23).

10
11 Since the incidence of these three diseases is quite low in clinical practice, what is the role of
12
13 colonoscopy in managing these three diseases in clinical practice?
14

15
16 First of all, our study found that endoscopy is mainstay to discriminate these three clinical entities.
17
18 In fact, colonoscopy found inflammation localized in different fashions. In UCD, inflammation
19
20 affects the overall mucosa of the region harbouring diverticula, also involving colonic mucosa
21
22 surrounding diverticular orifices. In SCAD, inflammation affects primarily inter-diverticular
23
24 mucosa, and only in severe cases we can see the overall involvement of the colonic mucosa
25
26 harbouring diverticula. In these last cases, the correct differential diagnosis between SCAD and
27
28 UCD is based on endoscopic and histological rectal assessment, which shows sparing by
29
30 inflammation, and which, by definition, characterized SCAD instead of UC. On the contrary, in
31
32 AUD the inflammation affects primarily the colonic mucosa surrounding diverticula, and only in
33
34 more severe forms of the disease we can see the overall involvement of the colonic mucosa
35
36 surrounding diverticula. In these last cases, differential diagnosis between SCAD and AUD is based
37
38 on three criteria:
39
40
41
42
43
44

- 45
46 1. CT scan finding of thickening of the colonic wall, sometimes associated with fat stranding,
47
48 in AUD instead of SCAD (24);
49
- 50
51 2. Endoscopic findings in AUD are characterized by aspecific signs, such as diffuse mucosal
52
53 edema and fragility, and sometimes bleeding coming from diverticula (11,25), whilst SCAD
54
55 is characterised by diffuse erosions and, sometimes, by ulcers (2);
56
57
- 58
59 3. Histological findings of SCAD are characterized by IBD-like pictures in most of cases (2,9),
60
whilst AUD mainly shows an active, unstructured inflammatory infiltrate (26,27).

1
2
3 But more important to the clinician is assistance regarding the appropriate clinical circumstances
4 and timing of endoscopy. This is particularly true in managing the disease. Knowing the prevalence
5 and the natural history of each disease, endoscopic appearance may be a key point to program
6 adequate clinical and endoscopic surveillance. For example, the treatment of UCD is similar to that
7 of a standard UC that may evolve to a more severe form of the disease (28). SCAD has usually a
8 more benign course (29,30), but some cases of severe disease may require immunosuppressors or
9 surgery. Also AUD may be managed with conservative therapy (31), but it often recurs with
10 complication (32). In light of these information, it is probably that less aggressive forms of SCAD
11 (types A and C) required less aggressive clinical and endoscopic follow-up, whilst UCD or more
12 aggressive forms of SCAD (types B and D) required more aggressive clinical and endoscopic
13 follow-up. An opening question remains the role of endoscopy in the follow-up of AUD, since there
14 are no data about the role of colonoscopy in long-lasting management of this disease.
15
16
17
18
19
20
21
22
23
24
25
26
27
28
29
30

31 In conclusion, this study showed that incidence of UCD, SCAD, and AUD is low in clinical
32 practice. Although endoscopy is the mainstay of diagnosis, further studies are needed to solve the
33 questions opening by this study.
34
35
36
37
38
39
40

41 **Statement of Interests**

42 Authors declare no conflict of interest. Moreover, No founding was received for this study.
43
44
45
46
47
48
49
50
51
52
53
54
55
56
57
58
59
60

REFERENCES

- 1) Shanahan F, Bernstein CN. The evolving epidemiology of inflammatory bowel disease. *Curr Opin Gastroenterol* 2009;25:301-5.
- 2) Tursi A, Elisei W, Brandimarte G *et al.* The endoscopic spectrum of segmental colitis associated with diverticulosis. *Colorectal Dis* 2010;12:464-70.
- 3) Etzioni DA, Mack TM, Beart RW Jr *et al.* Diverticulitis in the United States: 1998-2005: changing patterns of disease and treatment. *Ann Surg* 2009;249:210-7.
- 4) Rispo A, Pasquale L, Cozzolino A *et al.* Lower prevalence of diverticulosis in patients with ulcerative colitis. *Dis Colon Rectum* 2007;50:1164-8.
- 5) Lahat A, Avidan B, Bar-Meir S *et al.* Long-standing colonic inflammation is associated with a low prevalence of diverticuli in inflammatory bowel disease patients. *Inflamm Bowel Dis* 2007;13:733-6.
- 6) Hadithi M, Cazemier M, Meijer GA *et al.* Retrospective analysis of old-age colitis in the Dutch inflammatory bowel disease population. *World J Gastroenterol* 2008;14:3183-7.
- 7) Tursi A, Inchingolo CD, Nenna R *et al.* Pattern of mucosal tumour necrosis factor-alpha expression in segmental colitis associated with diverticula suggests a truly autonomous clinical entity. *Inflamm Bowel Dis* 2008;14:1315-7.
- 8) Daperno M, Sostegni R, Lavagna A *et al.* The role of endoscopy in inflammatory bowel disease. *Eur Rev Med Pharmacol Sci* 2004;8:209-14.
- 9) Schroeder KW, Tremaine WJ, Ilstrup DM. Coated oral 5-aminosalicylic acid therapy for mildly to moderately active ulcerative colitis. A randomized study. *N Engl J Med* 1987;317:1625-9.
- 10) Lamps LW, Knapple WL. Diverticular disease-associated segmental colitis. *Clin Gastroenterol Hepatol* 2007;5: 27-31.

- 1
2
3 11) Lahat A, Yanai H, Menachem Y *et al.* The feasibility and risk of early colonoscopy in acute
4
5
6
7
8
9 12) Tursi A, Brandimarte G, Giorgetti GM *et al.* The clinical picture of uncomplicated versus
10
11
12
13 13) Kaiser AM, Jiang JK, Lake JP *et al.* The management of complicated diverticulitis and the
14
15
16
17 14) Koutroubakis IE, Antoniou P, Tzardi M *et al.* The spectrum of segmental colitis associated
18
19
20
21
22 15) Delvaux M. Diverticular disease of the colon in Europe: epidemiology, impact on citizen
23
24
25
26
27 16) Imperiali G, Meucci G, Alvisi C *et al.* Segmental colitis associated with diverticula: a
28
29
30
31
32
33 17) Jeyarajah S, Papagrigoriadis S. Diverticular disease increases and affects younger ages: an
34
35
36
37
38 18) Jeyarajah S, Faiz O, Bottle A *et al.* Diverticular disease hospital admissions are increasing,
39
40
41
42
43
44
45
46 19) Szojda MM, Cuesta MA, Mulder CM, Felt-Bersma RJF. Review article: management of
47
48
49
50
51 20) Jacobs DO. Clinical practice. Diverticulitis. *N Engl J Med* 2007;357:2057-66
52
53 21) Hjern F, Jonas E, Holmström B *et al.* CT colonography versus colonoscopy in the follow-up
54
55
56
57
58
59
60

- 1
2
3 22) Wolff JH, Rubin A, Potter JD *et al.* Clinical significance of colonoscopic findings associated
4
5 with colonic thickening on computed tomography: is colonoscopy warranted when
6
7 thickening is detected? *J Clin Gastroenterol* 2008;42:472-5
8
9
- 10 23) Hale WB; NDSG. Colonoscopy in the diagnosis and management of diverticular disease. *J*
11
12 *Clin Gastroenterol* 2008;42:1142-4
13
14
- 15 24) Pereira J.M, Sirlin CB, Pinto PS *et al.* Disproportionate Fat Stranding: A Helpful CT Sign in
16
17 Patients with Acute Abdominal Pain. *RadioGraphics* 2004;24: 703-15.
18
19
- 20 25) Ghorai S, Ulbright TM, Rex DK. Endoscopic findings of diverticular inflammation in
21
22 colonoscopy patients without clinical acute diverticulitis: prevalence and endoscopic
23
24 spectrum. *Am J Gastroenterol* 2003;98:802-6.
25
26
- 27 26) Tursi A, Brandimarte G, Elisei W *et al.* Assessment and grading of mucosal inflammation in
28
29 colonic diverticular disease. *J Clin Gastroenterol* 2008;42:699-703.
30
31
- 32 27) West AB. The pathology of diverticulitis. *J Clin Gastroenterol* 2008;42:1137-8.
33
- 34 28) Bresci G, Parisi G, Bertoni M *et al.* Long-term maintenance treatment in ulcerative colitis: a
35
36 10-year follow-up. *Dig Liver Dis* 2002;34:419-23.
37
38
- 39 29) Freeman HJ. Natural history and long-term clinical behavior of segmental colitis associated
40
41 with diverticulosis (SCAD syndrome). *Dig Dis Sci* 2008;53:2452-7.
42
43
- 44 30) Imperiali G, Terpin MM, Meucci G *et al.* Segmental colitis associated with diverticula: a 7-
45
46 year follow-up study. *Endoscopy* 2006;38:610-2.
47
48
- 49 31) Tursi A, Papagrigoriadis S. Review article: the current and evolving treatment of colonic
50
51 diverticular disease. *Aliment Pharmacol Ther* 2009;30:532-46.
52
53
- 54 32) Frileux P, Dubrez J, Burdy G *et al.* Sigmoid diverticulitis. Longitudinal analysis of 222
55
56 patients with a minimal follow-up of 5 years. *Colorectal Dis* 2010;12:674-80.
57
58
59
60

1
2
3
4
5
6
7
8
9
10
11
12
13
14
15
16
17
18
19
20
21
22
23
24
25
26
27
28
29
30
31
32
33
34
35
36
37
38
39
40
41
42
43
44
45
46
47
48
49
50
51
52
53
54
55
56
57
58
59
60**Table 1. Diagnostic criteria of ulcerative colitis with diverticulosis (UCD), segmental colitis associated with diverticulosis (SCAD), and acute uncomplicated diverticulitis (AUD)**

| | Diagnostic criteria |
|------|----------------------------------------------------------------------------------------------------------------------------------------------------------------------------------------------------------------------------------------------------------------------------------------------------------------------------|
| UCD | <ol style="list-style-type: none">1. Macroscopic and microscopic inflammation involving the colonic mucosa coming from the rectum to the proximal segments.2. Presence of diverticula in the sigmoid and descending colon, with macroscopic and microscopic inflammation of the diverticular ostia. |
| SCAD | <ol style="list-style-type: none">1. Macroscopic and microscopic inflammation of the sigmoid-descending colon mucosa without involvement of the diverticular ostia.2. Normal aspect of the rectum and proximal colon. |
| AUD | <ol style="list-style-type: none">1. Macroscopic and microscopic inflammation of the colon harbouring diverticula.2. Stage 0-Ia according to modified Hinchey classification. |

Table 2. Endoscopic spectrum of ulcerative colitis with diverticulosis (UCD), segmental colitis associated with diverticulosis (SCAD), and acute uncomplicated diverticulitis (AUD)

| Endoscopic spectrum | UCD (25 pts.) | | | SCAD (129 pts) | | | | AUD (130 pts.) | | |
|-------------------------------------------|------------------|-----------------------|--------------------|-------------------|----------------|----------------|---------------|-------------------|-----------------------|---------------------|
| | Mild (8 pts.) | Moderate (10 pts.) | Severe (7 pts.) | A (72 pts.) | B (36 pts.) | C (13 pts.) | D (8 pts.) | Mild (67 pts) | Moderate (42 pts.) | Severe (21 pts.) |
| Diffuse inflammation | 7(87.5) | 9 (90.0) | 7 (100) | - | - | - | 8 (100) | 1 (1.5) | 1(2.4) | 7 (33.3) |
| Inflammation of inter-diverticular mucosa | 1 (12.5) | 1 (10.0) | - | 71 (98.6) | 34 (94.4) | 11 (84.6) | - | 2 (3.0) | 12 (28.6) | 13(61.9) |
| Inflammation of peri-diverticular mucosa | - | - | - | 1 (1.4) | 2 (5.6) | 2 (15.4) | - | 64 (95.5) | 29 (69.0) | 1 (4.8) |

Data are given as number (percentage) of patients (pts.)

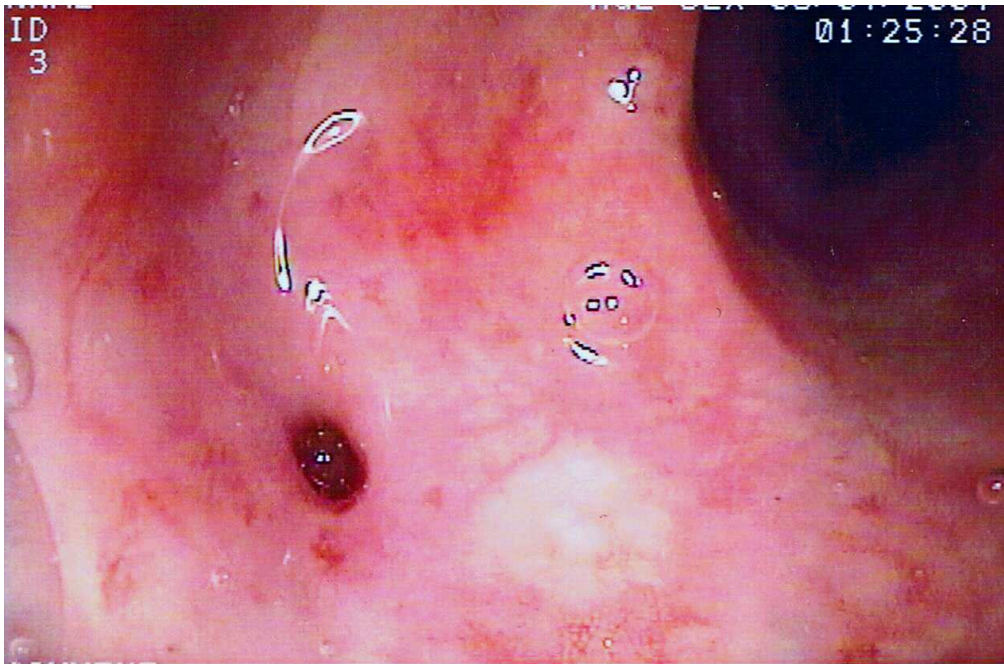
1
2
3
4
5
6
7
8
9
10 **FIGURE LEGEND**
11

12
13
14
15 **Figure 1.** Ulcerative Colitis with diverticulosis. We can see a diffuse inflammation (diffuse loss of
16 vascular pattern, diffuse hyperemia, and erosions). The diverticular orifices are always involved by
17 inflammation (lower **left** corner). In these cases, the differential diagnosis with pattern D of
18 segmental colitis associated with diverticulosis (severe disease) is based on the diffuse
19 inflammation in UC with diverticulosis, always involving rectum.
20
21
22
23
24
25
26
27
28

29 **Figure 2.** "Crescentic fold disease" segmental colitis associated with diverticulosis (pattern A).
30
31 **Loss of vascular pattern, mucosal edema, hyperemia, and red spots confined to the top of the**
32 **colonic folds, with sparing of the diverticula are showed.**
33
34
35
36
37

38 **Figure 3.** **Mild acute, uncomplicated diverticulitis: we can see diverticular inflammation**
39 **localized around diverticular orifice. Sparing of other diverticula, and sparing of the**
40 **interdiverticular mucosa is showed.**
41
42
43
44
45
46
47
48
49
50
51
52
53
54
55
56
57
58
59
60

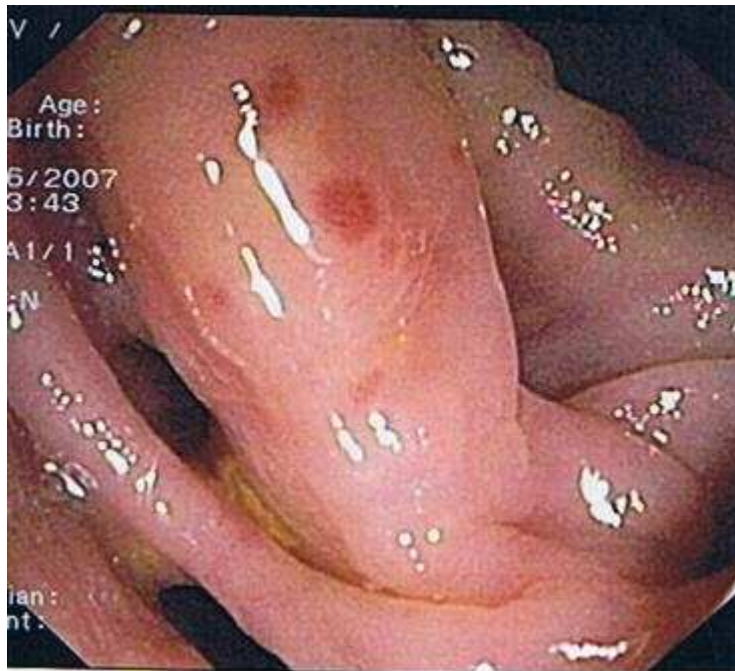
1
2
3
4
5
6
7
8
9
10
11
12
13
14
15
16
17
18
19
20
21
22
23
24
25
26
27
28
29
30
31
32
33
34
35
36
37
38
39
40
41
42
43
44
45
46
47
48
49
50
51
52
53
54
55
56
57
58
59
60



106x70mm (300 x 300 DPI)

Review

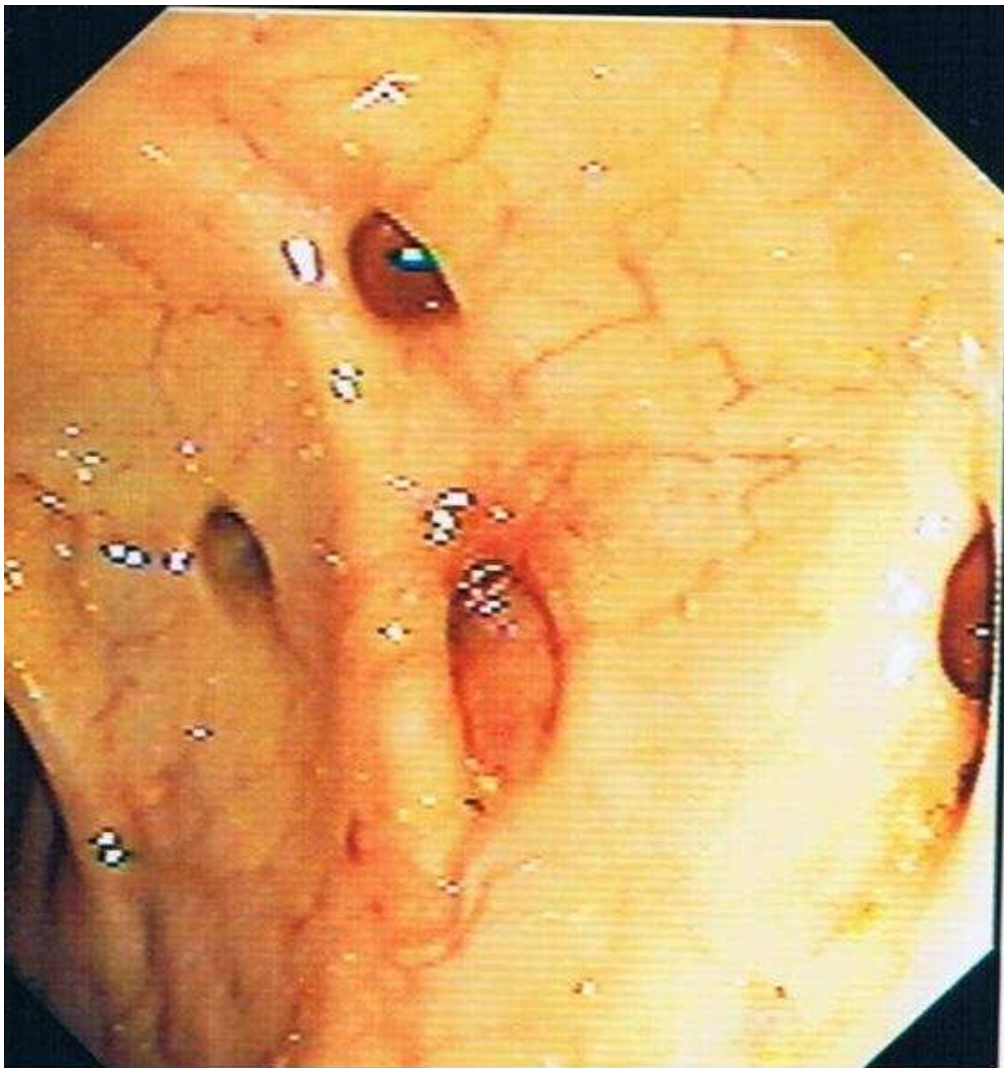
1
2
3
4
5
6
7
8
9
10
11
12
13
14
15
16
17
18
19
20
21
22
23
24
25
26
27
28
29
30
31
32
33
34
35
36
37
38
39
40
41
42
43
44
45
46
47
48
49
50
51
52
53
54
55
56
57
58
59
60



93x85mm (100 x 100 DPI)

Review

1
2
3
4
5
6
7
8
9
10
11
12
13
14
15
16
17
18
19
20
21
22
23
24
25
26
27
28
29
30
31
32
33
34
35
36
37
38
39
40
41
42
43
44
45
46
47
48
49
50
51
52
53
54
55
56
57
58
59
60



46x50mm (300 x 300 DPI)