

**Stem cell therapies for inflammatory bowel disease -
efficacy and safety**

Journal:	<i>Alimentary Pharmacology & Therapeutics</i>
Manuscript ID:	APT-0505-2010.R1
Wiley - Manuscript type:	Review Article
Date Submitted by the Author:	28-Jul-2010
Complete List of Authors:	Garcia-Bosch, Orlando; Hospital Clínic, Gastroenterology Ricart, Elena; Hospital Clínic, Gastroenterology Panes, Julian; Hospital Clinic, Vailarroel 170, Gastroenterology Dept.
Keywords:	Crohn's disease < Disease-based, Inflammatory bowel disease < Disease-based, Ulcerative colitis < Disease-based, Immunology < Topics

1
2
3
4
5
6
7
8
9
10
11
12 **Review article: Stem cell therapies for inflammatory bowel disease - efficacy and safety.**

13
14 Orlando García-Bosch, Elena Ricart, Julián Panés

15
16
17 Department of Gastroenterology, Hospital Clínic de Barcelona, Barcelona, Spain

18
19
20
21
22
23
24 **Address for correspondence:**

25 Julián Panés, M.D.
26 Department of Gastroenterology
27 Hospital Clínic of Barcelona
28 Villarroel 170
29 08036 Barcelona
30 Spain
31 Tel: +34 932275418
32 Fax: + 34 932279387
33 e-mail: jpanes@clinic.ub.es

34
35
36
37
38
39
40
41 **Running Title:** Stem cell therapy for inflammatory bowel disease

42
43
44
45
46 **Acknowledgements:** This work was supported in part by grant SAF2009/07272 from Ministerio
47 de Ciencia e Innovación, Spain, to JP, and grant TRA-097 from Ministerio de Sanidad y Política
48 Social, Spain, to JP.
49

50
51
52
53
54
55
56 **Keywords:** Inflammatory bowel diseases, Crohn disease, ulcerative colitis, stem cells,
57 hematopoietic stem cell transplantation, mesenchymal stem cells
58
59
60

Summary

Background: Drugs available for the treatment of inflammatory bowel disease fail to induce and maintain remission in a significant number of patients.

Aim: To assess the value of stem cell therapies for treatment of inflammatory bowel disease based on published studies.

Methods: Publications were identified through a MEDLINE search using the Medical Subject Heading terms: inflammatory bowel diseases, or Corhn disease, or ulcerative colitis, and stem cell, or stromal cell or transplant.

Results: Hematopoietic stem cell therapy as a primary treatment for inflammatory bowel disease was originally supported by animal experiments, and by remissions in patients undergoing transplant for hematological disorders. Later, transplantation specifically performed for patients with refractory Crohn's disease showed long lasting clinical remission and healing of inflammatory intestinal lesions. Use of autologous non-myeloablative regimens, and concentration of the procedures in centers with large experience, are key in reducing treatment-related mortality. Initial trials of mesenchymal stem cell therapy with local injection in Crohn's perianal fistulas had positive results.

Conclusions: Autologous hematopoietic stem cell transplant changes the natural course of Crohn's disease, and may be a therapeutic option in patients with refractory disease if surgery is not feasible due to disease location or extension.

1
2
3
4
5
6 Standard medical therapy for inflammatory bowel diseases (IBD) is directed against the
7 inflammatory and immune processes that are known to play an important role in the disease
8 process. Medical therapy is of variable success in ameliorating cardinal symptoms of the
9 disease (diarrhea, abdominal pain), in treating extraintestinal manifestations (fatigue,
10 anorexia, fever, weight loss, arthralgias, and skin, eye, liver, and kidney manifestations), and in
11 preventing complications (stricture, fistula, abscess). Currently, therapy is most often
12 implemented in a stepwise fashion, progressing through aminosalicylates (sulfasalazine,
13 mesalazine), antibiotics (metronidazole, ciprofloxacin), corticosteroids, immunosuppressive
14 medications including thioguanine compounds (6-mercaptopurine, azathioprine),
15 methotrexate, and cyclosporine, and finally anti-TNF drugs. This common approach is
16 predicated on the addition of more potent medications to agents that are believed to be safer
17 but that may also be less effective. Despite an optimized use of this treatment paradigm the
18 need for intestinal resection in Crohn's disease has remained stable (1). Primary and secondary
19 failure to respond to approved therapies, and in some cases inability to provide a surgical
20 solution to a particular patient due to extension and/or location of lesions, represents unmet
21 needs in the treatment of IBD.
22
23
24
25
26
27
28
29
30
31
32

33
34 Two streams of research, experimental and clinical, are the origin of the increasing utilization
35 of stem cell therapies for severe immune-mediated diseases (IMIDs) including IBD. The
36 considerable excitement surrounding the stem cell field was initially based on the unique
37 biological properties of these cells and their capacity to self-renew and regenerate tissue and
38 organ systems; later, the immunomodulatory ability of stem cell therapy has become also
39 apparent. The definition of stem cell conventionally indicates the hematopoietic ones, with
40 reference to the myeloid and lymphoid lineages. However, a distinct lineage is now known to
41 consist of mesenchymal stromal cells. Similar to hematopoietic stem cells (HSC), mesenchymal
42 stem (stromal) cells (MSC) are rare in the bone marrow, representing 1 in 10,000 nucleated
43 cells (2). The ontogenic relationship between HSCs and MSCs remains unclear.
44
45
46
47
48
49
50
51
52
53
54

55 **Hematopoietic Stem cells**

56
57 Stem cells are undifferentiated cells that have the capability of both self-renewal and
58 differentiation into mature specialized cells through replication. Two types of stem cells have
59 been recognized, embryonic stem cells and adult stem cells. Human embryonic stem cells are
60

1
2
3 isolated from a 50- to 150-cell, 4- to 5-day-old blastocyst. Embryonic stem cells can generate
4 every specialized cell in the human body and, while capable of indefinite ex vivo proliferation,
5 in vivo exist only during embryogenesis. Adult stem cells exist in all types of tissues throughout
6 the body and function as a reservoir to replace damaged or aging cells. Under physiologic
7 conditions, adult stem cells are mostly restricted in their differentiation to cell lineages of the
8 organ system in which they are located.
9

10
11
12
13
14 Embryonic stem cells have a great versatility and were envisioned as a promising option for
15 cell therapy, but compared with adult stem cells are currently difficult to control due to their
16 tendency to form tumors containing all types of tissue (teratomas). In contrast, adult stem cells
17 do not have this tendency, and follow traditional lineage-specific differentiation patterns,
18 fulfilling their physiologic homologous function of replacing normal turnover, aging, or
19 damaged tissues. Due to the inability to efficiently and safely harvest or expand stem cells from
20 most adult organs (eg, liver, gastrointestinal tract, heart, brain), the majority of human stem
21 cell trials have focused on clinical applications for HSCs, MSCs, or both, which can be easily
22 obtained in clinically sufficient numbers from peripheral blood, bone marrow, or umbilical cord
23 blood and placenta. Human hematopoietic progenitor cells are identified by glycoproteins
24 CD34⁺, CD133⁺, or both. Most human marrow or blood CD34⁺ or CD133⁺ cells are committed
25 progenitors, and only a minority are lifelong repopulating stem cells. A CD34⁻ or CD133⁻
26 enriched HSC product will reconstitute lifelong hematopoiesis and may be easily purified from
27 the marrow or peripheral blood (3).
28
29
30
31
32
33
34
35
36
37
38
39
40
41
42

43 Mesenchymal Stem Cells

44
45
46 When cells from a bone marrow aspirate are cultured in plastic flasks, hematopoietic cells and
47 HSCs do not adhere to the plastic and are removed with change of media. The remaining
48 plastic-adherent cells were originally termed colony-forming unit fibroblasts because they
49 formed fibroblast-like colonies ex vivo. Subsequently, these adherent cells have been termed
50 MSCs, an abbreviation for both mesenchymal stromal cells and mesenchymal stem cells. The
51 former refers to the ability of MSCs to contribute to the structural matrix of bone marrow and
52 to support hematopoiesis; the latter describes the ability of MSCs to differentiate under
53 various ex vivo culture conditions into different mesenchymal-derived cells (4). MSCs may be
54 isolated from bone marrow, skeletal muscle, adipose tissue, synovial membranes and other
55 connective tissues of human adults as well as cord blood and placenta.
56
57
58
59
60

1
2
3 MSCs have no unique phenotypic marker. The minimal criteria by the International Society of
4 Cellular Therapy to define MSCs are (1) plastic-adherent in culture; (2) expression of CD105,
5 CD73, and CD90; 3) lack of expression of hematopoietic markers such as CD45, CD34, CD14,
6 CD11b, CD19, CD79a, and HLA-DR; and 4) able to differentiate into osteoblasts, adipocytes,
7 and chondrocytes (3). The ratio of MSCs to marrow mononuclear cells is estimated to be only
8 10 – 100 MSCs per million marrow cells (5). Despite relatively low numbers, a 2-mL aspirate of
9 bone marrow can be expanded 500-fold *ex vivo* to 12 billion to 35 billion MSCs within 3 weeks
10 (5).
11
12
13
14
15
16

17
18 Depending upon the environment, MSCs give rise to many cell lineages including epithelial
19 cells, astrocytes, osteoblasts, chondrocytes, adipocytes, and muscle, promoting regeneration of
20 damaged tissue *in vivo* (4). *In vitro*, MSCs have vast proliferative potential, can clonally
21 regenerate and can give rise to differentiated progeny. They also exhibit antiproliferative and
22 anti-inflammatory properties *in vitro* and *in vivo*, making them candidates for treatment of
23 IMIDs (6). Regardless of whether or not MSCs are true stem cells, clinical benefit from MSCs
24 may not require sustained engraftment of large numbers of cells or differentiation into specific
25 tissues. It is possible that a therapeutic benefit can be obtained by local paracrine production
26 of growth factors and by the provision of temporary antiproliferative and immunomodulatory
27 properties (7).
28
29
30
31
32
33
34
35

36 Until recently, it was assumed that MSCs enjoyed ‘immune privilege’ in allogeneic settings,
37 neither exerting nor being subject to immunological reaction. However, recent data suggest
38 that in an immunocompetent host, allogeneic MSCs will be eliminated. *In-vitro* studies indicate
39 that MSCs possess immunosuppressive properties. Rodent, baboon and human MSCs suppress
40 T and B-cell lymphocyte proliferation in mixed lymphocyte cultures (MLCs) or induced by
41 mitogens and antibodies in a dose-dependent manner. The suppression is MHC independent,
42 and in human cell cultures the magnitude of suppression is not reduced when the MSCs are
43 separated from the lymphocytes in transwells, indicating that cell–cell contact is not required.
44
45
46
47
48
49

50
51 The mechanism(s) underlying the immunosuppressive effect of MSCs remains to be fully
52 clarified with sometimes conflicting data, probably reflecting variable definitions and
53 experimental conditions. MSCs exert important immunomodulatory functions both *in vitro* and
54 in experimental *in vivo* models. Bone marrow-derived MSCs can suppress cytotoxic and IFN-
55 γ T-cell proliferation in a cell contact-dependent mechanism through engagement of the
56 inhibitory molecule PD-1. Also, MSCs have been shown to trigger generation of Treg, as well as
57 to directly induce antigen-dependent Treg proliferation (4). On the other hand, MSCs can
58
59
60

1
2
3 modulate the innate immune response which is known to play a key role in the pathogenesis
4 of CD. In particular, MSCs inhibit dendritic cell differentiation and maturation, act on resting
5 NK cells and decrease the respiratory burst and apoptosis of neutrophils. Interestingly, MSCs
6 obtained from adipose tissue (AMSCs) have been shown to exert immunosuppressive effects *in*
7 *vitro* and inhibit peripheral blood mononuclear cell proliferation and IFN- γ production while
8 increasing IL-10 secretion (8).
9

10
11
12 Data demonstrating the fate of transplanted MSCs *in vivo* are scarce. In rats, radiolabeling
13 experiments following intra-arterial and intravenous infusion of MSCs show localization mainly
14 in the lungs and secondarily in the liver and other organs. Estimated levels of engraftment in
15 these tissues ranged from 0.1 to 2.7% and were similar in the autologous and allogeneic
16 settings (9). MSCs homing to tumors is of concern. Human MSCs have been shown to localize
17 to a murine xenogenic breast cancer via monocyte chemoattractant protein-1 (MCP-1) (10) in a
18 severe combined immunodeficiency (SCID) mouse model. Although this suggests that MSCs
19 may provide a potential therapeutic delivery system for cancer therapy, it may pose long-term
20 safety issues in autoimmune disease treatment.
21
22
23
24
25
26
27
28
29
30
31
32

33 **Lessons from hematopoietic stem cell studies as a treatment for IMIDs**

34
35
36 The concept and practice of HSC transplant (HSCT) as a primary treatment for IMIDs began in
37 the late 1990s, and was originally supported by decades of animal experiments and by
38 unanticipated remissions of inflammatory diseases observed in patients undergoing HSCT for
39 hematological disorders or cancer. In 1995 an international committee was established that
40 developed guidelines on entry criteria and transplant protocols for severe autoimmune
41 diseases (11). Furthermore, a database was created to collect clinical data that would enable
42 monitoring of feasibility, toxicity, and efficacy of the different treatment protocols. Analysis of
43 the pooled data has yielded relevant information on trends with regard to mortality, type of
44 protocols used, and diseases targeted.
45
46
47
48
49
50
51

52
53 HSCT includes conditioning (high dose chemotherapy, anti-lymphocyte antibodies and/or total
54 body irradiation) followed by infusion of HSC. The HSC are usually mobilized from bone
55 marrow to peripheral blood and harvested by apheresis. In some protocols of autologous
56 transplantation for autoimmune diseases, the graft is depleted of T cells (e.g. selection of CD34
57 cells) to reduce the likelihood of reinfusing presumed disease-causing T cells (12). Allogeneic
58 HSCT should theoretically be associated with a higher probability of cure than autologous
59
60

1
2
3 HSCT, as the genetic background of immune cells would be changed, and there is a graft-vs-
4 host reaction that removes the presumed disease-causing T cells that could survive
5 conditioning (13). However, due to graft-vs-host disease, allogeneic transplantation is
6 associated with higher transplant-related morbidity and mortality. For this reason, more
7 autologous transplants have been performed for IMIDs. The rationale of autologous HSCT for
8 autoimmune diseases is to immune reset, ie, to generate new self-tolerant lymphocytes after
9 chemotherapy-induced elimination of self- or auto-reactive lymphocytes (ie, lymphoablation).
10 Allogeneic HSCT is based on the rationale of both immune reset (similar to autologous HSCT)
11 and of correcting the genetic predisposition to disease by reinfusing non-disease-prone HSCs
12 from a normal donor.
13
14
15
16
17
18
19
20

21 Over the last two decades, HSCT has become increasingly safe due to reduced conditioning
22 procedures, use of peripheral blood stem cells, and improvement in supportive measures and
23 patient selection. This has led to the application of HSCT to treat IMIDs refractory to available
24 therapies. Treatment-related mortality for autologous HSCT of autoimmune diseases in the
25 European Group for Blood and Marrow Transplantation registry is approximately 7% (11), and
26 some trials have reported rates of up to 23% (14). Although mortality is reduced with greater
27 experience and more careful patient selection, has justifiably dampened enthusiasm for the
28 field. Autologous HSCT for IMIDs may be performed with either myeloablative or
29 nonmyeloablative regimens (15). Myeloablative regimens use cancer-specific treatments that
30 destroy the entire marrow compartment, including marrow stem cells, resulting in irreversible
31 and lethal marrow failure if HSCs are not reinfused. Nonmyeloablative regimens are designed
32 specifically for autoimmune diseases, ie, for lymphoablation without irreversible destruction of
33 marrow stem cells. Following a nonmyeloablative regimen, hematopoietic recovery will occur
34 without infusion of HSCs; however, autologous HSCs provide support and shorten the duration
35 of chemotherapy-induced marrow suppression (15).
36
37
38
39
40
41
42
43
44
45
46
47

48 The essential argument in favor of nonmyeloablative regimens is that treatment-related
49 mortality needs to be very low for nonmalignant diseases, and nonmyeloablative regimens
50 appear safer than myeloablative regimens (14). A second consideration in favor of
51 nonmyeloablative regimens is that independent of using a myeloablative or nonmyeloablative
52 regimens disease relapse may occur; autologous HSCT for autoimmune diseases should not be
53 viewed as a cure but rather as changing the natural history of disease. A third point in favor of
54 nonmyeloablative regimens is that IMIDs may undergo long-lasting spontaneous remissions
55 despite an initial aggressive course, and no clinical reliable predictor has been identified for
56 any of the IMIDs. It is debatable whether a subset of patients who may remit without HSCT
57
58
59
60

1
2
3 should be exposed to myeloablative regimens, especially those including total body irradiation,
4 which cause a relatively high incidence of a more lethal disease, ie, myelodysplastic syndrome
5 and leukemia (15).
6
7

8
9 Both early and late toxicity are a consequence of the regimen used for transplantation and of
10 the increase in transplant-related mortality that occurs with increased intensity of the
11 transplant regimen. Treatment-related mortality is less than 1% for nonmyeloablative, less
12 than 2% for low-intensity myeloablative, and 13% for high-intensity myeloablative regimens
13 (16). A number of reports combined data from patients treated with different conditioning
14 regimens or from those with different diseases complicating interpretation, because toxicity is
15 both regimen- and disease-specific. Although transplant regimen intensity may correlate with
16 remission duration it is unclear if, at some point in dose intensity, a response plateau occurs
17 independent of any further increase in regimen intensity. In that regard, it has been observed
18 that in patients with systemic sclerosis, autologous HSCT results in remarkable reversal of skin
19 tightness, improved joint flexibility and quality of life, and reversal of pulmonary alveolitis
20 (17,18). Two studies of nonmyeloablative regimens demonstrated 0% (0/10) and 4% (1/26)
21 rates of treatment-related mortality (17,18), respectively, while a study using a myeloablative
22 approach including total body irradiation reported a rate of 23% (8/34) (14). Importantly, both
23 myeloablative (14) and nonmyeloablative (18) approaches reported identical 64% 5-year event-
24 free survival.
25
26
27
28
29
30
31
32
33
34
35
36
37

38 Independent of whether myeloablative or nonmyeloablative regimens are used, another
39 complication, late secondary autoimmune disorders, may arise from some agents used in the
40 conditioning regimen. The initial standard nonmyeloablative regimen of cyclophosphamide and
41 rabbit antithymocyte globulin (rATG) was well tolerated. A second-generation
42 nonmyeloablative regimen used cyclophosphamide and a broader- and longer-acting agent,
43 alemtuzumab, instead of rATG. Potential life-threatening secondary autoimmune cytopenias,
44 including idiopathic thrombocytopenic purpura, autoimmune neutropenia, and autoimmune
45 hemolytic anemia, occurred late (2 to 18 months) after transplantation in patients receiving
46 regimens containing alemtuzumab (19). A third-generation nonmyeloablative regimen, termed
47 "rituximab sandwich", entails 1 dose of rituximab given before and after cyclophosphamide
48 and rATG. To date, this regimen has been well tolerated.
49
50
51
52
53
54
55
56
57

58 Another factor with a notable influence on mortality is the experience of the center in the use
59 of HSCT for treatment of a particular IMID, since the transplant procedure may be associated
60 with disease-specific complications that benefit from specific prevention and/or treatment. In

1
2
3 a single experienced center, nonmyeloablative autologous HSCT for patients with systemic
4 lupus erythematosus, when performed as salvage therapy for treatment-refractory disease,
5 resulted in marked serologic, clinical, and organ improvement, with 2% (1/50) treatment-
6 related mortality and 50% probability of maintaining remission for 5 years (20). In comparison,
7 a multicenter analysis of HSCT for systemic lupus erythematosus that included both
8 myeloablative and nonmyeloablative regimens from 23 different centers reported a similar
9 55% 5-year disease-free survival, but treatment-related mortality was 13% (7/53) (21).

10
11
12
13
14
15
16 Timing of HSCT relative to disease duration and/or complications may be another key factor
17 affecting treatment outcome. For multiple sclerosis, original HSCT studies were performed
18 predominantly in patients with secondary progressive and, to a lesser extent, primary
19 progressive disease. In this subset of patients, intense myeloablative regimens generally failed
20 to improve neurologic disability or to convincingly halt or change the rate of progressive
21 neurologic disability (16). Despite lack of clinical benefit in patients with progressive multiple
22 sclerosis, magnetic resonance imaging evidence of inflammation was abrogated, while loss of
23 brain volume continued for 2 years before subsiding (22). In retrospect, the predominant
24 pathophysiology in primary and secondary progressive multiple sclerosis is axonal
25 degeneration, which would not be expected to improve after autologous HSCT, a method that
26 allows delivery of intense immune suppression. Learning from these studies, a trial of
27 autologous HSCT for relapsing-remitting multiple sclerosis, which is an immune-mediated
28 inflammatory disease, was performed with a safer nonmyeloablative regimen. There was no
29 treatment-related mortality, no disease progression, and two-thirds of patients had significant
30 improvement in neurologic function (23). The relevance of timing of cell therapy may not only
31 depend on the appearance of irreversible damage, but also to the differential characteristics of
32 immune activation in early and late disease, which has been shown also in CD (24).

33
34
35
36
37
38
39
40
41
42
43
44
45
46 The lessons learned from multiple sclerosis—ie, treat early while the disease is inflammatory
47 and use nonmyeloablative regimens with low risk of treatment-related mortality—were
48 applied to patients with type 1 diabetes by using a nonmyeloablative regimen and selecting
49 patients within 6 weeks of diagnosis before complete loss of insulin-producing islet cells.
50 Autologous nonmyeloablative HSCT resulted in insulin-free remission of type 1 diabetes in 20
51 of 23 patients, and 12 patients maintained this status for a mean of 31 months (range 14-52
52 months). There was no mortality (25).

53
54
55
56
57
58
59 Recently, allogeneic HSCT using a sibling's HSCs has also been reported for treatment of several
60 IMIDs (26,27), including CD (see below). Because it changes genetic predisposition to disease,

1
2
3 allogeneic HSCT is considered more likely to cure autoimmune diseases compared with
4 autologous HSCT. Graft-vs-host disease (GvHD), an often more lethal immune-mediated
5 disease, is not an acceptable risk following allogeneic HSCT for autoimmune disorders rather
6 than for malignancies and should be minimized by depletion of lymphocytes from the donor
7 graft. Although yet unproven, some animal and limited human data (26-28) suggest that an
8 allogeneic graft-vs-autoimmunity effect may occur without GvHD via use of a lymphocyte-
9 depleted graft.
10
11
12
13
14
15
16
17
18
19

20 Hematopoietic Stem Cell Transplant for Inflammatory Bowel Disease

21
22
23 The possibility that HSCT might be an effective treatment for IBD arose initially from reports of
24 improvements in IBD patients who had HSCT for other reasons, followed by case reports and
25 case series of transplantation specifically performed for Crohn's disease (CD) patients. Tables 1
26 and 2 summarize the publications on direct and indirect evidence of efficacy.
27
28
29

30 Effect of HTSC performed for cancer on IBD

31
32
33 In 1993 the first report was published on a 41 year old female with CD who underwent
34 autologous HSCT for non-Hodgkin's lymphoma (29). The patient remained symptom free
35 during the 6 month reported period of follow-up. Since then, a total of 25 patients have been
36 reported who underwent HSCT for cancer (Table 1).
37
38
39

40
41 A series from Seattle (30) was reported on 1996 of six patients with CD who underwent
42 allogeneic HSCT for leukemia. Five of these patients had active CD at the time of transplant. All
43 patients received cyclophosphamide and total body irradiation as conditioning therapy. Two
44 patients had sclerosing cholangitis. One patient died of sepsis at 3 months post-transplant. The
45 remaining five patients were in clinical remission more than one year post transplant despite
46 discontinuation of immunosuppression. Four of these five patients had sustained remission of
47 CD at 54 to 183 months post-transplant. One patient had a relapse of CD 18 months after
48 transplantation. Interestingly, the relapsed patient had mixed donor-host hematopoietic
49 chimerism, whereas the four patients who achieved sustained remission were assumed to be
50 complete chimeras as they had GvHD in the first two years after HSCT.
51
52
53
54
55
56
57

58
59 Another series from Germany (31) reported in 2003 of 7 patients with CD and 4 with UC who
60 underwent allogeneic HSCT for hematological malignancy. Six of the 11 patients had active

1
2
3 disease at the time of transplantation. All patients received cyclophosphamide as part of
4 different conditioning regimens, and all patients except for two received also total body
5 irradiation. Ten patients went into remission following HSCT with a median follow-up time of
6 34 months. In the one patient with recurrent IBD symptoms after transplant endoscopy and
7 radiological examinations did not demonstrate any IBD related lesion. There was one
8 transplant-related mortality reported at ten months, from an opportunistic infection. The
9 usefulness of this study for the determination of whether allogeneic HCT may cure CD is
10 limited by the fact that at the last follow up only two patients were off of immunosuppressive
11 drugs.
12

13
14
15
16
17
18
19
20 Between 1996 and 2007 7 additional single case reports of patients suffering IBD who
21 underwent HSCT for treatment of cancer were published. One patient with CD underwent
22 allogeneic HSCT and had a sustained remission 8 years after transplant (32). Five patients with
23 CD received an autologous HSCT, in 4 the disease remained in remission during follow-up
24 lasting from 2 to 8 years, and one patient had a clinical relapse at 8 years (33-37). Finally one
25 patient with UC underwent autologous HSCT and had a relapse of the IBD 20 months after
26 transplant (38).
27

28
29
30
31
32
33 Overall, 22 out of 25 patients have achieved clinical remission over a median follow up of 20
34 months. Only two of these patients are on any ongoing medication for IBD suggesting that
35 HSCT may result in long lasting remission without any need for medications. There have been
36 two transplant-related deaths among the 25 cases, both related to infectious complications,
37 and other 2 cases died of unrelated causes: one myocardial infarction and one suicide.
38
39
40

41
42
43 Although these studies were not designed to investigate the effect of HSCT on the course of
44 IBD, they support the notion that elimination of self- or auto-reactive lymphocytes (ie,
45 lymphoablation) and generation of new self-tolerant lymphocytes after chemotherapy
46 (immune reset) affords long lasting remissions in patients with IBD. The central role of the
47 immune system in the pathogenesis of CD is further supported by another observation coming
48 also from the HSCT field. A healthy patient undergoing allogeneic HSCT developed severe CD
49 soon after transplant (39) Investigations showed that the transplanted stem cell had a
50 pathogenetic mutation of the NOD2-gene, compatible with the notion that the CD developed
51 when the normal immune response was disrupted by an anomalous handling of bacterial
52 products by the transplanted immune cells. This body of evidence suggested that long term
53 remissions may be achieved by HSCT in CD and form the basis to prospective studies.
54
55
56
57
58
59
60

HSCT as a primary treatment for CD

In IBD, HSCT is currently being tested for the treatment of CD, given that ulcerative colitis has a relatively simple therapeutic option for refractory cases with surgery.

The first documentation of the efficacy of autologous HSCT for treatment of CD came from the Chicago group in 2003 (40). The response to this therapy in the first four patients was excellent; all patients achieved clinical remission with no significant untoward event from the transplantation. These initial cases are also integrated in the final report of the phase I study (41) including 12 patients with active moderate-severe CD (CDAI 250-358) refractory to conventional therapies including anti-TNF treatment. The majority of these patients had a history of surgery. Mobilization was with cyclophosphamide 2 g/m² and G-CSF 10 µg/kg/day, and conditioning with cyclophosphamide 200 mg/kg and equine ATG 90 mg/kg. The peripheral blood stem cells were CD34+ enriched. Follow-up was at 6 and 12 mo post HSCT and then yearly, and included at each visit small bowel radiography and colonoscopy. There was an early and sustained clinical remission (CDAI ≤ 150) in 11 of 12 patients after a median follow-up of 18.5 months. Radiographic and colonoscopy findings improved more gradually over months to years. One patient experienced CD relapse at 15 months post-transplant. All patients tolerated the HSCT well and there were no transplant-related deaths. One patient died of accidental cause at 37 months post HSCT; there was no evidence of active CD at this time.

A second phase I-II study from Milan was published in 2008 (42). The study includes 4 patients of similar characteristics, all had failed immunosuppressant treatment and anti-TNF therapy and 2 of them had undergone multiple surgical resections. All patients had active disease (CDAI 258-404) at the time of transplantation. Mobilization was with cyclophosphamide 1.5 g/m² and G-CSF 10 µg/kg/day, and conditioning with cyclophosphamide 200 mg/kg and rabbit ATG 7.5 mg/kg. No cell immunoselection was carried out in this study. Three months after transplant all patients had achieved clinical remission, and complete endoscopic remission was achieved in 2/3 patients. Three of the 4 patients had sustained remission after a median follow-up of 16.5 months. No mortality was observed in the two series of patients.

In the first study coming from the group in Chicago (41), the authors observed improvement of the CD in most patients following the HSC mobilization that was attributed to the immunomodulatory effects of the drugs used in this phase. By contrast in the study from Milan (42) the authors reported a deterioration of the clinical condition of the patients during mobilization. Observations of two additional case reports published so far using HSCT as a primary treatment for CD also suggest that sustained clinical remission with HCT is likely not

1
2
3 due just to cyclophosphamide and G-CSF. Scime et al (43) reported a case of a 55 year old male
4 who showed no improvement in colonic lesions one month after mobilization therapy, but
5 achieved significant endoscopic and histological improvement after autologous HSCT. Five
6 months after HCT the patient remains in clinical remission. Kreisel et al (44) describe a 36 year
7 old male who continued to have persistent histological changes and recurrent CD nine months
8 after mobilization therapy with cyclophosphamide and G-CSF (before HCT). Ten months after
9 HSCT the CD was improved, in clinical remission with minimal histological changes. The
10 mechanisms underlying the beneficial effect of HSCT in Crohn's disease remain unclear.
11 Initially a beneficial effect is likely to result from eradication of autoreactive T cells and
12 memory cells because of the direct lymphoablative effects of drugs used in the conditioning
13 regimen; this process is non-specific and recruitment of inflammatory cells will be restricted
14 for at least 2-3 months until their ablated bone marrow source reconstitutes with cells derived
15 from the graft. Later, there may be an effect of altered immune reconstitution. To gain an
16 insight on this question, the European Bone Marrow Transplantation (EBMT) Group along with
17 the European Crohn's and Colitis Organization (ECCO) are currently conducting a randomized
18 trial on autologous HSCT (ASTIC trial; www.nottingham.ac.uk/icr/astic/) to evaluate the
19 potential clinical benefit of hematopoietic stem cell mobilization followed by high dose
20 immuneablation and HSCT compared to hematopoietic stem cell mobilization only followed by
21 best clinical practice in patients with refractory CD.
22
23
24
25
26
27
28
29
30
31
32
33
34
35
36

37 In 1995, the international committee established for development of guidelines on entry
38 criteria and transplant protocols for IMiDs recommended that autologous HSCT should be
39 preferred to allogeneic due to lower risk of severe toxicity (11). Although at that time a genetic
40 predisposition to CD had been established based on familial aggregation studies, not a single
41 susceptibility gene had been identified. Now more than 50 disease susceptibility genotypes are
42 known highlighting the complex heritability of this polygenic disease in the majority of cases.
43 However, a recent study based on genetic-linkage analysis and candidate-gene sequencing on
44 samples from two unrelated consanguineous families with children who were affected by
45 early-onset inflammatory bowel disease, identified three distinct homozygous mutations in
46 genes IL10RA and IL10RB that perfectly segregated with disease phenotype (45). A member of
47 the family with the IL10RB mutation suffered a very severe CD since the 3rd month of life with
48 proctitis and perianal abscesses, which required multiple surgical interventions and finally
49 colostomy; multiple enterocutaneous fistulas originating from the small intestine required
50 bowel resections and ileostomy; and recurrent episodes of intestinal obstruction. At 9 years of
51 age he underwent allogeneic HSCT using as a donor an HLA-matched sibling unaffected not
52
53
54
55
56
57
58
59
60

1
2
3 carrying the mutation. Inflammatory anal fistulas resolved shortly after transplantation. The
4 patient has remained in continuous remission from ileocolitis, he gained weight and had no
5 further episodes of intestinal pseudo-obstruction during the follow-up period of two years
6 after HSCT. This is a stepping-stone study showing a curative approach to severe CD by means
7 of allogeneic HSCT, which was justified based on the monogenic cause of the disease in this
8 case.
9
10
11
12

13 14 15 16 17 18 **Mesenchymal Stem Cells for treatment of IMIDs**

19
20 The past 5 years have seen major interest in the use of MSCs in the treatment of autoimmune
21 and inflammatory disorders. Human trials of MSCs for numerous immune-mediated diseases
22 are being discussed and have been initiated in patients with GvHD. Since MSCs can be easily
23 obtained and culture-expanded, bone marrow– or adipose tissue–derived MSCs from third
24 parties or from the original marrow donor have been infused to modulate refractory GvHD. In
25 nonrandomized trials, 94% of patients with acute GvHD responded to intravenous infusion of
26 MSCs (46).
27
28
29
30
31
32
33
34
35
36
37

38 Animal models of tissue protection

39 It may be impossible, to separate the anti-inflammatory, immunomodulatory and tissue
40 protective ‘trophic’ effects of MSCs. An immunosuppressive effect of MSCs in vivo was first
41 suggested in a baboon model, in which infusion of ex-vivo expanded donor or third-party MSCs
42 delayed the time to rejection of histo-incompatible skin grafts (47). MSCs also downregulate
43 bleomycin-induced lung inflammation and fibrosis in murine models (48) if given early (but not
44 late) after the induction. A similar effects were seen in a murine hepatic fibrosis model using a
45 MSC line (49), and in a rat kidney model of ischemia–reperfusion injury in which syngeneic
46 MSCs but not fibroblasts were used (50). The notion that early treatment is necessary to
47 provide significant clinical and pathological amelioration is also supported by observations in
48 an experimental autoimmune encephalomyelitis (EAE) murine model (51). The responses are
49 dependent on time of MSCs treatment (the earlier the better), and are reversed with IL-2
50 treatment, indicating that anergy rather than apoptosis had occurred.
51
52
53
54
55
56
57
58
59
60

1
2
3 Other experimental observations suggest that stem cell combinations may afford higher
4 benefit that purified single cells lines. In a murine model of streptozocin-induced diabetes
5 mellitus clinical improvement was documented following transplantation with a combination
6 of bone marrow-derived cells and syngeneic and allogeneic MSCs following sublethal
7 irradiation, but neither cell product alone was effective (52). The proposed mechanism was
8 regeneration of recipient-derived islet cells and immunosuppression of autoreactive T cells.
9

10
11
12
13
14 In experimental models of IBD adipose-derived MSCs ameliorate clinical and microscopic signs
15 of colitis, reduce systemic and mucosal pro-inflammatory cytokine production, increase IL-10
16 secretion and induce Tregs in mesenteric lymph nodes of colitic mice (53). MSCs emerge,
17 therefore, as potent direct modulators of the innate immune system that preferentially target
18 inflamed tissues and modulate T cell responses. MSCs from adipose tissue, in contrast to bone
19 marrow MSCs, present the additional benefit of being more easily accessible and expanded *in*
20 *vitro*. The potential anti-inflammatory actions of MSCs are summarized in figure 1.
21
22
23
24
25
26
27
28
29

30 MCS for treatment of human IMIDs

31
32 Successful pre-clinical studies using MSCs in models of autoimmunity, inflammation and tissue
33 damage have paved the way for clinical trials. In humans, ex-vivo expanded allogeneic MSCs
34 have been infused in several phase I studies (54-56). No adverse events during or after MSCs
35 infusion have been observed and no ectopic tissue formation has been noted. After infusion,
36 MSCs remain in the circulation for no more than an hour. Although durable stromal cell
37 chimerism has been difficult to establish, low levels of engrafted MSCs have been detected in
38 several tissues. It is possible that sufficient therapeutic benefit is obtained by local paracrine
39 production of growth factors and the provision of temporary immunosuppression by MSCs
40 infusion. Infusion of haploidentical MSCs to a patient with steroid-resistant severe acute GvHD
41 of the gut and liver promptly improved liver abnormalities and intestinal function (57). Upon
42 discontinuation of cyclosporine, the patient's acute GvHD recurred but was still responsive to a
43 second MSC infusion. Lymphocytes from the patient, when investigated on multiple occasions
44 after MSCs infusion, continued to proliferate against lymphocytes derived from the
45 haploidentical MSCs donor in coculture experiments. This suggests an immunosuppressive
46 effect of MSCs *in vivo*, rather than a development of tolerance. The EBMT is currently
47 sponsoring clinical trials of MSCs for the prevention and treatment of acute GvHD through the
48 Developmental Committee and interim results of the treatment trial have recently been
49
50
51
52
53
54
55
56
57
58
59
60

1
2
3 published. Thirty out of 55 steroid-resistant acute GvHD patients had a complete response
4 with no immediate toxicity. Median dose of allogeneic MSC was 1.4×10^6 /kg body weight up to
5 five times. Four patients had a recurrence or de-novo malignancy. Patients who achieved a
6 complete response had a reduced transplant-related mortality at 12 months (37 versus 72%)
7 and higher overall 2-year survival (52 versus 16%) (56).
8
9

10
11
12 Autologous bone marrow-derived MSCs have been shown to be potently antiproliferative to
13 stimulated T cells from normal individuals and from patients with IMIDs (rheumatoid arthritis,
14 systemic sclerosis, Sjögrens syndrome and systemic lupus erythematosus). In patients with
15 systemic sclerosis, the MSCs were normal with respect to proliferation, clonogenicity and
16 differentiation to bone and fat (58). Encouraging results from an initial phase I clinical trial
17 using locally administered ASCs to treat complex perianal fistula (59), have been confirmed in a
18 phase II multicenter randomized trial including patients with complex perianal fistulas
19 (cryptoglandular origin, n = 35; associated with Crohn's disease, n = 14), observing fistula
20 closure in 17 (71 %) of 24 patients who received ASCs in addition to fibrin glue compared with
21 4 (16 %) of 25 patients who received fibrin glue alone, with similar fistula healing in Crohn's
22 and non-Crohn's subgroups (60). The results of two trials of intravenous MSCs have been
23 reported in abstract form. An open label phase II trial using allogeneic bone marrow-derived
24 adult MSCs for the treatment of refractory luminal CD showed a clinical response defined as a
25 reduction in CDAI of at least 100 points in 3 of 9 treated patients (61). Results of another
26 completed phase I trial of intravenous autologous bone marrow derived MSCs that included 9
27 patients, confirmed that the treatment is feasible and safe, but without apparent benefit for
28 patients with severe refractory luminal disease (62).
29
30
31
32
33
34
35
36
37
38
39
40
41
42

43 There are several ongoing phase I/II clinical trials of MSCs treatment in autoimmune disease,
44 including Crohn's disease, multiple sclerosis, systemic lupus erythematosus, and type 1
45 diabetes mellitus, with other proposals under consideration for the treatment of other IMIDs
46 such as vasculitis. For these studies, it is important to set clear therapeutic targets and attempt
47 to identify uniform cell products. It is especially important to define the source and type of
48 MSC (autologous or allogeneic), to standardize cell expansion conditions and to adopt uniform
49 trial protocols. In addition, an international interdisciplinary registry of MSC-treated patients
50 has been launched to allow uniform collection of long-term safety data.
51
52
53
54
55
56
57

58 **Conclusions**

59
60

1
2
3 The use of adult HSCs is rapidly expanding beyond the traditional applications for malignancy.
4
5 In IMIDs, chemotherapy to ablate the disease-causing immune system is followed by infusion
6
7 of unmanipulated or purified CD34⁺ HSCs to reconstitute immunopoiesis or hematopoiesis. A
8
9 large experience exists on the use of HSCT as treatment for MS, systemic sclerosis and lupus.
10
11 Important lessons from these studies indicate that non-myeloablative regimens should be
12
13 preferred to myeloablative ones, that patients should receive this cell therapy before
14
15 irreversible damage occurs, while there is still a considerable component of reversible
16
17 inflammatory lesions, and that morbidity and mortality are minimized in experienced centers.

18
19 A growing body of evidence shows that CD is also a highly responsive disease to this form of
20
21 therapy. Time has now come for the scientific evaluation of the transplant-based procedures
22
23 against acceptably best non-transplant treatments, and also for the comparison of various
24
25 forms of stem cell therapies in randomized controlled trials. A robust rationale coming from
26
27 experimental studies also sets the base for testing MSCs, in human IBD, but initial phase I and
28
29 II studies have produced mixed results.

30
31 Notwithstanding the fascinating perspective of immune re-education and regulation, it is
32
33 unrealistic to believe that cell-based therapies can eradicate the immune disease, but data
34
35 available so far indicate that at least HSCT is able to change the natural course of Crohn's
36
37 disease.
38
39
40
41
42
43
44
45
46
47
48
49
50
51
52
53
54
55
56
57
58
59
60

References

1. Peyrin-Biroulet L, Loftus EV, Jr., Colombel JF, Sandborn WJ. The natural history of adult Crohn's disease in population-based cohorts. *Am.J.Gastroenterol.* 2010; **105**: 289-297.
2. Chamberlain G, Fox J, Ashton B, Middleton J. Concise review: mesenchymal stem cells: their phenotype, differentiation capacity, immunological features, and potential for homing. *Stem Cells.* 2007; **25**: 2739-2749.
3. Dominici M, Le BK, Mueller I, et.al. Minimal criteria for defining multipotent mesenchymal stromal cells. The International Society for Cellular Therapy position statement. *Cytotherapy.* 2006; **8**: 315-317.
4. Uccelli A, Moretta L, Pistoia V. Mesenchymal stem cells in health and disease. *Nat.Rev.Immunol.* 2008; **8**: 726-736.
5. Pittenger MF, Mackay AM, Beck SC, et.al. Multilineage potential of adult human mesenchymal stem cells. *Science.* 1999; **284**: 143-147.
6. Dazzi F, van Laar JM, Cope A, Tyndall A. Cell therapy for autoimmune diseases. *Arthritis Res.Ther.* 2007; **9**: 206.
7. Panes J, Salas A. Mechanisms underlying the beneficial effects of stem cell therapies for inflammatory bowel diseases. *Gut.* 2009; **58**: 898-900.
8. Gonzalez-Rey E, Gonzalez MA, Rico L, Buscher D, Delgado M. Human adult stem cells derived from adipose tissue protect against experimental colitis and sepsis. *Gut.* 2009; **58**: 929-939.
9. Devine SM, Cobbs C, Jennings M, Bartholomew A, Hoffman R. Mesenchymal stem cells distribute to a wide range of tissues following systemic infusion into nonhuman primates. *Blood.* 2003; **101**: 2999-3001.
10. Dwyer RM, Potter-Beirne SM, Harrington KA, et.al. Monocyte chemotactic protein-1 secreted by primary breast tumors stimulates migration of mesenchymal stem cells. *Clin.Cancer Res.* 2007; **13**: 5020-5027.
11. Gratwohl A, Passweg J, Bocelli-Tyndall C, et.al. Autologous hematopoietic stem cell transplantation for autoimmune diseases. *Bone Marrow Transplant.* 2005; **35**: 869-879.
12. Kapoor S, Wilson AG, Sharrack B, et.al. Haemopoietic stem cell transplantation--an evolving treatment for severe autoimmune and inflammatory diseases in rheumatology, neurology and gastroenterology. *Hematology.* 2007; **12**: 179-191.
13. Marmont AM. Immunoablation followed or not by hematopoietic stem cells as an intense therapy for severe autoimmune diseases. New perspectives, new problems. *Haematologica.* 2001; **86**: 337-345.
14. Nash RA, McSweeney PA, Crofford LJ, et.al. High-dose immunosuppressive therapy and autologous hematopoietic cell transplantation for severe systemic sclerosis: long-term follow-up of the US multicenter pilot study. *Blood.* 2007; **110**: 1388-1396.

- 1
2
3 15. Burt RK, Marmont A, Oyama Y, et.al. Randomized controlled trials of autologous
4 hematopoietic stem cell transplantation for autoimmune diseases: the evolution from
5 myeloablative to lymphoablative transplant regimens. *Arthritis Rheum.* 2006; **54**: 3750-
6 3760.
7
- 8
9 16. Farge D, Labopin M, Tyndall A, et.al. Autologous hematopoietic stem cell transplantation
10 (HSCT) for autoimmune diseases: an observational study on 12 years of experience from
11 the European Group for Blood and Marrow Transplantation (EBMT) Working Party on
12 Autoimmune Diseases. *Haematologica.* 2009; doi:10.3324/haematol.2009.013458.
13
- 14 17. Oyama Y, Barr WG, Statkute L, et.al. Autologous non-myeloablative hematopoietic stem
15 cell transplantation in patients with systemic sclerosis. *Bone Marrow Transplant.* 2007;
16 **40**: 549-555.
17
- 18 18. Vonk MC, Marjanovic Z, van den Hoogen FH, et.al. Long-term follow-up results after
19 autologous haematopoietic stem cell transplantation for severe systemic sclerosis.
20 *Ann.Rheum.Dis.* 2008; **67**: 98-104.
21
- 22 19. Loh Y, Oyama Y, Statkute L, et.al. Development of a secondary autoimmune disorder
23 after hematopoietic stem cell transplantation for autoimmune diseases: role of
24 conditioning regimen used. *Blood.* 2007; **109**: 2643-548.
25
- 26 20. Burt RK, Traynor A, Statkute L, et.al. Nonmyeloablative hematopoietic stem cell
27 transplantation for systemic lupus erythematosus. *JAMA.* 2006; **295**: 527-535.
28
- 29 21. Jayne D, Passweg J, Marmont A, et.al. Autologous stem cell transplantation for systemic
30 lupus erythematosus. *Lupus.* 2004; **13**: 168-176.
31
- 32 22. Rocca MA, Mondria T, Valsasina P, et.al. A three-year study of brain atrophy after
33 autologous hematopoietic stem cell transplantation in rapidly evolving secondary
34 progressive multiple sclerosis. *AJNR Am.J.Neuroradiol.* 2007; **28**: 1659-1661.
35
- 36 23. Burt RK, Loh Y, Cohen B, et.al. Autologous non-myeloablative haemopoietic stem cell
37 transplantation in relapsing-remitting multiple sclerosis: a phase I/II study. *Lancet*
38 *Neurol.* 2009; **8**: 244-253.
39
- 40 24. Veny M, Esteller M, Ricart E, et.al. Late Crohn's disease patients present an increase in
41 peripheral Th17 cells and cytokine production compared with early patients.
42 *Aliment.Pharmacol.Ther.* 2009.
43
- 44 25. Couri CE, Oliveira MC, Stracieri AB, et.al. C-peptide levels and insulin independence
45 following autologous nonmyeloablative hematopoietic stem cell transplantation in newly
46 diagnosed type 1 diabetes mellitus. *JAMA.* 2009; **301**: 1573-1579.
47
- 48 26. Burt RK, Oyama Y, Verda L, et.al. Induction of remission of severe and refractory
49 rheumatoid arthritis by allogeneic mixed chimerism. *Arthritis Rheum.* 2004; **50**: 2466-
50 2470.
51
- 52 27. Nash RA, McSweeney PA, Nelson JL, et.al. Allogeneic marrow transplantation in patients
53 with severe systemic sclerosis: resolution of dermal fibrosis. *Arthritis Rheum.* 2006; **54**:
54 1982-1986.
55
56
57
58
59
60

- 1
 - 2
 - 3
 - 4
 - 5
 - 6
 - 7
 - 8
 - 9
 - 10
 - 11
 - 12
 - 13
 - 14
 - 15
 - 16
 - 17
 - 18
 - 19
 - 20
 - 21
 - 22
 - 23
 - 24
 - 25
 - 26
 - 27
 - 28
 - 29
 - 30
 - 31
 - 32
 - 33
 - 34
 - 35
 - 36
 - 37
 - 38
 - 39
 - 40
 - 41
 - 42
 - 43
 - 44
 - 45
 - 46
 - 47
 - 48
 - 49
 - 50
 - 51
 - 52
 - 53
 - 54
 - 55
 - 56
 - 57
 - 58
 - 59
 - 60
28. Verda L, Kim DA, Ikehara S, et.al. Hematopoietic mixed chimerism derived from allogeneic embryonic stem cells prevents autoimmune diabetes mellitus in NOD mice. *Stem Cells*. 2008; **26**: 381-386.
29. Drakos PE, Nagler A, Or R. Case of Crohn's disease in bone marrow transplantation. *Am.J.Hematol*. 1993; **43**: 157-158.
30. Lopez-Cubero SO, Sullivan KM, McDonald GB. Course of Crohn's disease after allogeneic marrow transplantation. *Gastroenterology*. 1998; **114**: 433-440.
31. Ditschkowski M, Einsele H, Schwerdtfeger R, et.al. Improvement of inflammatory bowel disease after allogeneic stem-cell transplantation. *Transplantation*. 2003; **75**: 1745-1747.
32. Talbot DC, Montes A, Teh WL, Nandi A, Powles RL. Remission of Crohn's disease following allogeneic bone marrow transplant for acute leukaemia. *Hosp.Med*. 1998; **59**: 580-581.
33. Castro J, Bentch H, Smith L, et.al. Prolonged clinical remission in patients with inflammatory bowel disease (IBD) after high dose chemotherapy (HDC) and autologous blood stem cell transplantation. *Blood* 1996; **88 (Supplement)**: 133A.
34. Kashyap A, Forman SJ. Autologous bone marrow transplantation for non-Hodgkin's lymphoma resulting in long-term remission of coincidental Crohn's disease. *Br.J.Haematol*. 1998; **103**: 651-652.
35. Musso M, Porretto F, Crescimanno A, et.al. Crohn's disease complicated by relapsed extranodal Hodgkin's lymphoma: prolonged complete remission after unmanipulated PBPC autotransplant. *Bone Marrow Transplant*. 2000; **26**: 921-923.
36. Soderholm JD, Malm C, Juliusson G, Sjodahl R. Long-term endoscopic remission of crohn disease after autologous stem cell transplantation for acute myeloid leukaemia. *Scand.J.Gastroenterol*. 2002; **37**: 613-616.
37. Anumakonda V, Hayee B, Chung-Faye G. Remission and relapse of Crohn's disease following autologous haematopoietic stem cell transplantation for non-Hodgkin's lymphoma. *Gut*. 2007; **56**: 1325.
38. Marti JL, Mayordomo JI, Isla MD, et.al. PBSC autotransplant for inflammatory bowel disease (IBD): a case of ulcerative colitis. *Bone Marrow Transplant*. 2001; **28**: 109-110.
39. Sonwalkar SA, James RM, Ahmad T, et.al. Fulminant Crohn's colitis after allogeneic stem cell transplantation. *Gut*. 2003; **52**: 1518-1521.
40. Craig RM, Traynor A, Oyama Y, Burt RK. Hematopoietic stem cell transplantation for severe Crohn's disease. *Bone Marrow Transplant*. 2003; **32 Suppl 1**: S57-S59.
41. Oyama Y, Craig RM, Traynor AE, et.al. Autologous hematopoietic stem cell transplantation in patients with refractory Crohn's disease. *Gastroenterology*. 2005; **128**: 552-563.
42. Cassinotti A, Annaloro C, Ardizzone S, et.al. Autologous haematopoietic stem cell transplantation without CD34+ cell selection in refractory Crohn's disease. *Gut*. 2008; **57**: 211-217.

- 1
 - 2
 - 3
 - 4
 - 5
 - 6
 - 7
 - 8
 - 9
 - 10
 - 11
 - 12
 - 13
 - 14
 - 15
 - 16
 - 17
 - 18
 - 19
 - 20
 - 21
 - 22
 - 23
 - 24
 - 25
 - 26
 - 27
 - 28
 - 29
 - 30
 - 31
 - 32
 - 33
 - 34
 - 35
 - 36
 - 37
 - 38
 - 39
 - 40
 - 41
 - 42
 - 43
 - 44
 - 45
 - 46
 - 47
 - 48
 - 49
 - 50
 - 51
 - 52
 - 53
 - 54
 - 55
 - 56
 - 57
 - 58
 - 59
 - 60
43. Scime R, Cavallaro AM, Tringali S, et.al. Complete clinical remission after high-dose immune suppression and autologous hematopoietic stem cell transplantation in severe Crohn's disease refractory to immunosuppressive and immunomodulator therapy. *Inflamm.Bowel.Dis.* 2004; **10**: 892-894.
44. Kreisel W, Potthoff K, Bertz H, et.al. Complete remission of Crohn's disease after high-dose cyclophosphamide and autologous stem cell transplantation. *Bone Marrow Transplant.* 2003; **32**: 337-340.
45. Glocker EO, Kotlarz D, Boztug K, et.al. Inflammatory bowel disease and mutations affecting the interleukin-10 receptor. *N.Engl.J.Med.* 2009; **361**: 2033-2045.
46. Fang B, Song YP, Liao LM, Han Q, Zhao RC. Treatment of severe therapy-resistant acute graft-versus-host disease with human adipose tissue-derived mesenchymal stem cells. *Bone Marrow Transplant.* 2006; **38**: 389-390.
47. Bartholomew A, Sturgeon C, Siatskas M, et.al. Mesenchymal stem cells suppress lymphocyte proliferation in vitro and prolong skin graft survival in vivo. *Exp.Hematol.* 2002; **30**: 42-48.
48. Ortiz LA, Gambelli F, McBride C, et.al. Mesenchymal stem cell engraftment in lung is enhanced in response to bleomycin exposure and ameliorates its fibrotic effects. *Proc.Natl.Acad.Sci.U.S.A.* 2003; **100**: 8407-8411.
49. Fang B, Shi M, Liao L, et.al. Systemic infusion of FLK1(+) mesenchymal stem cells ameliorate carbon tetrachloride-induced liver fibrosis in mice. *Transplantation.* 2004; **78**: 83-88.
50. Togel F, Weiss K, Yang Y, et.al. Vasculotropic, paracrine actions of infused mesenchymal stem cells are important to the recovery from acute kidney injury. *Am.J.Physiol Renal Physiol.* 2007; **292**: F1626-F1635.
51. Zappia E, Casazza S, Pedemonte E, et.al. Mesenchymal stem cells ameliorate experimental autoimmune encephalomyelitis inducing T-cell anergy. *Blood.* 2005; **106**: 1755-1761.
52. Urban VS, Kiss J, Kovacs J, et.al. Mesenchymal stem cells cooperate with bone marrow cells in therapy of diabetes. *Stem Cells.* 2008; **26**: 244-253.
53. Gonzalez MA, Gonzalez-Rey E, Rico L, Buscher D, Delgado M. Adipose-derived mesenchymal stem cells alleviate experimental colitis by inhibiting inflammatory and autoimmune responses. *Gastroenterology.* 2009; **136**: 978-989.
54. Koc ON, Day J, Nieder M, et.al. Allogeneic mesenchymal stem cell infusion for treatment of metachromatic leukodystrophy (MLD) and Hurler syndrome (MPS-IH). *Bone Marrow Transplant.* 2002; **30**: 215-222.
55. Horwitz EM, Gordon PL, Koo WK, et.al. Isolated allogeneic bone marrow-derived mesenchymal cells engraft and stimulate growth in children with osteogenesis imperfecta: Implications for cell therapy of bone. *Proc.Natl.Acad.Sci.U.S.A.* 2002; **99**: 8932-8937.

- 1
 - 2
 - 3
 - 4
 - 5
 - 6
 - 7
 - 8
 - 9
 - 10
 - 11
 - 12
 - 13
 - 14
 - 15
 - 16
 - 17
 - 18
 - 19
 - 20
 - 21
 - 22
 - 23
 - 24
 - 25
 - 26
 - 27
 - 28
 - 29
 - 30
 - 31
 - 32
 - 33
 - 34
 - 35
 - 36
 - 37
 - 38
 - 39
 - 40
 - 41
 - 42
 - 43
 - 44
 - 45
 - 46
 - 47
 - 48
 - 49
 - 50
 - 51
 - 52
 - 53
 - 54
 - 55
 - 56
 - 57
 - 58
 - 59
 - 60
56. Le Blanc K, Frassoni F, Ball L, et.al. Mesenchymal stem cells for treatment of steroid-resistant, severe, acute graft-versus-host disease: a phase II study. *Lancet*. 2008; **371**: 1579-1586.
57. Le Blanc K, Rasmusson I, Sundberg B, et.al. Treatment of severe acute graft-versus-host disease with third party haploidentical mesenchymal stem cells. *Lancet*. 2004; **363**: 1439-1441.
58. Larghero J, Farge D, Braccini A, et.al. Phenotypical and functional characteristics of in vitro expanded bone marrow mesenchymal stem cells from patients with systemic sclerosis. *Ann.Rheum.Dis*. 2008; **67**: 443-449.
59. Garcia-Olmo D, Garcia-Arranz M, Herreros D, et.al. A phase I clinical trial of the treatment of Crohn's fistula by adipose mesenchymal stem cell transplantation. *Dis.Colon Rectum*. 2005; **48**: 1416-1423.
60. Garcia-Olmo D, Herreros D, Pascual I, et.al. Expanded adipose-derived stem cells for the treatment of complex perianal fistula: a phase II clinical trial. *Dis.Colon Rectum*. 2009; **52**: 79-86.
61. Onken JE, Gallup D, Hanson J, et.al. Successful outpatient treatment of refractory Crohn's disease using adult mesenchymal stem cells. *ACG 2006 Final Program Book* 2006; 121.
62. Duijvestein M, Wildenberg ME, Vos ACW, et.al. Phase I results of intravenous autologous bone marrow derived mesenchymal stromal cell treatment in refractory Crohn's disease. *Journal of Crohn's and Colitis* 2010; **4**: S6.

Figure Legends

Figure 1. Mechanisms of action of mesenchymal stem cells (MSC) in inflammatory bowel disease. In active Crohn's disease (right part of the figure), destruction of the epithelium or decreased antimicrobial defense by epithelial cells leads to an increased exposure to commensal bacteria that activate innate immune cells of the lamina propria. Activated mature antigen presenting cells (APC) acquire the ability to drive T cell differentiation and activation into effector cells (IFN- γ producing Th1 or IL-17-producing Th17, depending on the nature of the response). An inflammatory infiltrate with a Th1 and Th17 phenotype accumulates in the lamina propria. Increased proinflammatory cytokine production by APC and macrophages induces up-regulation of adhesion molecules in both lymphatic and blood vessels that irrigate the intestinal mucosa and produce chemotactic factors, favoring recruitment of leukocytes and therefore further amplifying the inflammatory response

Transplanted MSCs migrate to inflamed tissues where they promote epithelial regeneration and tissue healing, and exert immuno-regulatory functions (left part of the figure). MSC inhibit APC maturation, T cell proliferation and IFN- γ production. Transplanted adipose-derived MSC also decrease production of pro-inflammatory cytokines such as IL-6, TNF- α , and IL-12 by lamina propria mononuclear cells. Furthermore MSCs can produce both IL-10 and TGF- β , which inhibit Th1 differentiation while promoting Treg differentiation, and restoring tolerance.

Modified from (7).

Table 1. Myeloablative HTSC for treatment of cancer in patients with IBD

Year	Study	Primary condition	Type HSCT	IBD	IBD complications	IBD duration (years)	age	Sex F/M	Cell selection	Conditioning	Mortality	SAEs	Outcome
1993	Drakos PE (29)	NHL	autologous	1 CD	Fistula Surgery	22	41	1/0	No	BCNU 300 mg/m ² , Etoposide 600 mg/m ² , CTX 60 mg/m ² , ara-C 600 mg/m ² , melphalan 120 mg/m ²	0	0	Remission 6 mo
1996	Castro J (33)	Breast cancer	autologous	1 CD	NA	11	N/A	1/0	N/A	CTX 5.525 g/m ² , cisplatin 165 mg/m ² , BCNU 0.6 g/m ²	0	NA	Remission > 2 yrs
1998	Kashyap A, (34)	NHL	autologous	1 CD	Perianal disease Obstruction Surgery	8	21	0/1	No	TBI 200cGt x 6, VP-16 60mg/kg, CTX 100 mg/kg,	0	0	Remission 7 ys
1998	Talbot DC (32)	Leukemia	allogeneic	1CD	Surgery	7	35	0/1	No	CTX 200 mg/kg Busulfan16 mg/kg	0	GvHD	Remission 8 yrs
1998	Lopez-Cubero SO, (30)	Leukemia	allogeneic	6 CD	Fistulae 2 Obstruction 1 EIM 3 Surgery 2 PSC 2	3- 29 (median 11)	27- 46	0/6	No	CTX 120 mg/kg TBI 12-13.5 Gy	1 sepsis 97 days 1 MI 4.5 yr 1 suicide 5.8 yr	Acute GHVD 6 Chronic GvHD 4	Remission 4-15 yrs in 4, relapse 1.5 yr in 1
2000	Musso M (35)	HL	autologous	1 CD	Surgery	10	30	0/1	No	idarubicin melphalan	0	0	Remission 3 years

2001	Marti JL (38)	Breast cancer	autologous	1 UC	None	7	57	1/0	No	CTX carboplatin thiotepa	0	0	Relapse at 20 months
2002	Soderholm JD, (36)	Leukemia	autologous	1 CD	Obstruction, Fistula, Surgery	3	57	1/0	No	CTX 60 mg/kg x 2 TBI 6x 2Gy	0	Sepsis Klebsiella	Clinical & endoscopic Remission 5 years
2003	Ditschkowski M (31)	MDS 1 / leukemia 10	allogeneic	4 UC 7 CD	Fistulae 3 Obstruction 2 EIM 2 Surgery 4	Median 10 yrs	27 – 55 Median 41	6/5	CD34 enriched in 4 cases	Myeloablative various; TBI in 7	1 pulmonary fungal infection	Acute GHVD 8 Pulmonary fungal infection 1	Remission in 10, (median follow up 34 months)
2007	Anumakonda V (37)	NHL	autologous	1 CD	NA	16	32	1/0	NA	CHOP	0	NA	Remission, relapse after 8 yrs.

CD: Crohn's disease; F/M: Female/male; GvHD: Graft-versus-host disease; HL: Hodgkin's lymphoma; HSCT: Hematopoietic stem cell transplantation; IBD: Inflammatory bowel disease, MDS: Myelodysplastic syndrome; NA: Information not available; NHL: Non-Hodgkin's lymphoma; SAE: Severe adverse event; UC: ulcerative colitis

Table 2. HTSC as primary treatment for Crohn's disease

Year	Study	Type HSCT	n	IBD complications	CD duration (years)	age	Sex F/M	Mobilization	Cell selection	Conditioning	Previous Tmts	Maintenance	SAEs	Outcome
2003	Kreisel W (44)	autologous	1	Fistula Abscess Surgery	14	36	0/1	CTX 2 g/m ² /day x 2 G-CSF 480 ug/day	Yes	CTX 200 mg	Antibiotics steroids azathioprine anti-TNF	No treatment 9 mo, Prednisone + MTX at mo 9	0	Clinical remission, Mild endoscopic lesions at 9 mo.
2004	Scimè R (43)	Autologous	1	EIM	2.5	55	0/1	CTX 2 g/m ² G-CSF 10 ug/kg/day	Yes	CTX 200 mg equine ATG 90 mg	azathioprine anti-TNF MTX	No tmt	0	Clinical remission, mild endoscopy lesions 5 mo
2005	Oyama Y (41)	Autologous	12	Fistula 6 Obstruction 3 Perianal 4 Surgery 9	10 (1.5–20)	27 (15–38)	6/6	CTX 2 g/m ² G-CSF 10 ug/kg/day	Yes	CTX 200 mg equine ATG 90 mg	Thiopurine 12 MTX 6 Anti-TNF 12	1 Pred + MTX 11 no	1 Surgery stenosis mo 5	11 Remission mo 12 1 recurrence mo 18
2008	Cassinotti A (42)	Autologous	4	Obstruction 1 Surgery 3 EIM 3 Perianal 3	NA	31 (26–45)	1/3	CTX 1.5 g/m ² G-CSF 10 ug/kg/day	No	CTX 200 mg rabbit ATG 7.5 mg/kg	Thiopurine 4 MTX 4 Anti-TNF 4	Antibiotic 2	0	Remission at 3 mo. 1 relapse mo4 Endoscopic

1
2
3
4
5
6
7
8
9
10
11
12
13
14
15
16
17
18
19
20
21
22
23
24
25
26
27
28
29
30
31
32
33
34
35
36
37
38
39
40
41
42
43
44
45
46
47

				GI bleeding 1										remission mo 12 2/2
2009	Glocker EO (45)	Allogeneic	1	Fistula Obstruction Surgery Perianal EIM	9	9	0/1	-	-	alemtuzumab 1 mg/kg fludarabine 180 mg/m2 treosulfan 42 mg/m2 thiotepa 10 mg/kg	MTX thalidomide anti-TNF	NA	0	Remission 2 yrs

CD: Crohn's disease; F/M: Female/male; HSCT: Hematopoietic stem cell transplantation; MTX: Methotrexate; NA: Information not available; SAE: Severe adverse event.

Peer Review

Financial Support

This work was supported in part by grant SAF2009/07272 from Ministerio de Ciencia e Innovación, Spain, to JP, and grant TRA-097 from Ministerio de Sanidad y Política Social, Spain to JP.

Competing Interests

None of the authors has competing interests related with the information provided in the manuscript.

For Peer Review

1
2
3
4
5
6
7
8
9
10
11
12
13
14
15
16
17
18
19
20
21
22
23
24
25
26
27
28
29
30
31
32
33
34
35
36
37
38
39
40
41
42
43
44
45
46
47
48
49
50
51
52
53
54
55
56
57
58
59
60

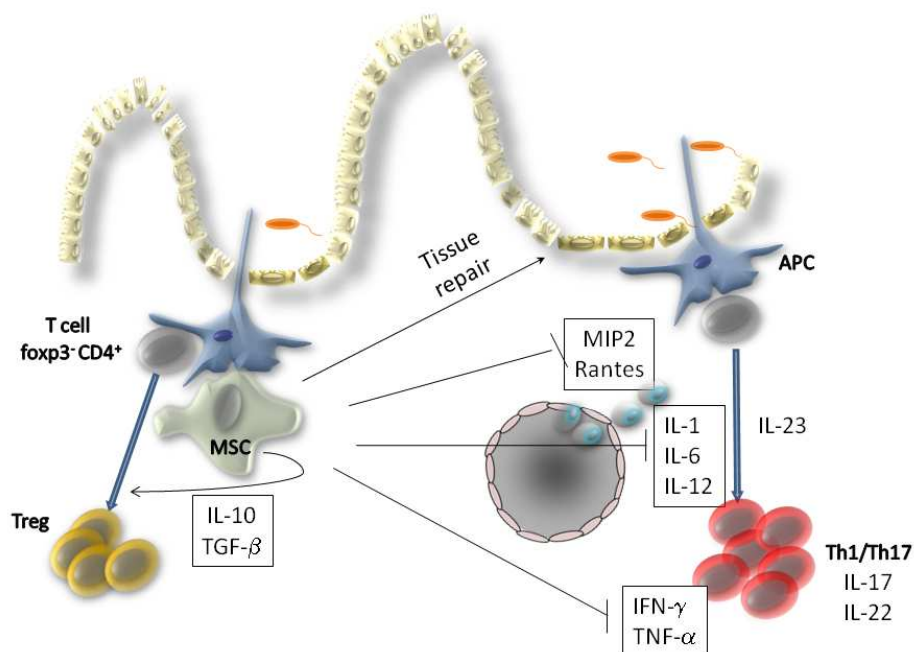


Figure 1. Mechanisms of action of mesenchymal stem cells (MSC) in inflammatory bowel disease.

In active Crohn's disease (right part of the figure), destruction of the epithelium or decreased antimicrobial defense by epithelial cells leads to an increased exposure to commensal bacteria that activate innate immune cells of the lamina propria. Activated mature antigen presenting cells (APC) acquire the ability to drive T cell differentiation and activation into effector cells (IFN- γ producing Th1 or IL-17-producing Th17, depending on the nature of the response). An inflammatory infiltrate with a Th1 and Th17 phenotype accumulates in the lamina propria. Increased proinflammatory cytokine production by APC and macrophages induces up-regulation of adhesion molecules in both lymphatic and blood vessels that irrigate the intestinal mucosa and produce chemotactic factors, favoring recruitment of leukocytes and therefore further amplifying the inflammatory response. Transplanted MSCs migrate to inflamed tissues where they promote epithelial regeneration and tissue healing, and exert immuno-regulatory functions (left part of the figure). MSC inhibit APC maturation, T cell proliferation and IFN- γ production. Transplanted adipose-derived MSC also decrease production of pro-inflammatory cytokines such as IL-6, TNF- α , and IL-12 by lamina propria mononuclear cells. Furthermore MSCs can produce both IL-10 and TGF- β , which inhibit Th1 differentiation while promoting Treg differentiation, and restoring tolerance. Modified from (7).

254x190mm (96 x 96 DPI)