



HAL
open science

Musculo-contractural Ehlers-Danlos syndrome (former EDS type VIB) and adducted thumb clubfoot syndrome (ATCS) represent a single clinical entity caused by mutations in the dermatan-4-sulfotransferase 1 encoding CHST14 gene.

Fransiska Malfait, Delfien Syx, Philip Vlummens, Sofie Symoens, Sheela Nampoothiri, Trinh Hermanns-Lê, Lut van Laer, Anne Depaepe

► **To cite this version:**

Fransiska Malfait, Delfien Syx, Philip Vlummens, Sofie Symoens, Sheela Nampoothiri, et al.. Musculo-contractural Ehlers-Danlos syndrome (former EDS type VIB) and adducted thumb clubfoot syndrome (ATCS) represent a single clinical entity caused by mutations in the dermatan-4-sulfotransferase 1 encoding CHST14 gene.. Human Mutation, 2010, 31 (11), pp.1233. 10.1002/humu.21355 . hal-00599478

HAL Id: hal-00599478

<https://hal.science/hal-00599478v1>

Submitted on 10 Jun 2011

HAL is a multi-disciplinary open access archive for the deposit and dissemination of scientific research documents, whether they are published or not. The documents may come from teaching and research institutions in France or abroad, or from public or private research centers.

L'archive ouverte pluridisciplinaire **HAL**, est destinée au dépôt et à la diffusion de documents scientifiques de niveau recherche, publiés ou non, émanant des établissements d'enseignement et de recherche français ou étrangers, des laboratoires publics ou privés.



Musculo-contractural Ehlers-Danlos syndrome (former EDS type VIB) and adducted thumb clubfoot syndrome (ATCS) represent a single clinical entity caused by mutations in the dermatan-4-sulfotransferase 1 encoding *CHST14* gene.

Journal:	<i>Human Mutation</i>
Manuscript ID:	humu-2010-0306.R1
Wiley - Manuscript type:	Rapid Communication
Date Submitted by the Author:	09-Aug-2010
Complete List of Authors:	Malfait, Fransiska; Ghent University Hospital, Center for Medical Genetics Syx, Delfien; Ghent University Hospital, Center for Medical Genetics Vlummens, Philip; Ghent University Hospital, Center for Medical Genetics Symoens, Sofie; Ghent University Hospital, Center for Medical Genetics Nampoothiri, Sheela; Cochin, Amrita Institute of Medical Sciences and Research Center Hermanns-Lê, Trinh; University Hospital of Sart-Tilman, Department of Dermatopathology Van Laer, Lut; Ghent University Hospital, Center for Medical Genetics DePaepe, Anne; Ghent University Hospital, Center for Medical Genetics
Key Words:	Ehlers-Danlos syndrome, collagen, CHST14, dermatan-4-sulfotransferase 1, adducted thumb clubfoot syndrome

SCHOLARONE™
Manuscripts

1
2
3 **Musculo-contractural Ehlers-Danlos syndrome (former EDS type VIB) and adducted**
4 **thumb clubfoot syndrome (ATCS) represent a single clinical entity caused by mutations in**
5 **the dermatan-4-sulfotransferase 1 encoding *CHST14* gene.**
6
7
8
9

10 Fransiska Malfait¹, Delfien Syx¹, Philip Vlummens¹, Sofie Symoens¹, Sheela Nampoothiri²,
11 Trinh Hermanns-Lê³, Lut Van Laer¹ and Anne De Paepe¹
12
13
14
15

16 ¹: Center for Medical Genetics, Gent University Hospital, De Pintelaan 185, B-9000 Ghent,
17 Belgium
18
19

20 ²: Amrita Institute of Medical Sciences and Research Center, Cochin, Kerala, India
21

22 ³: Department of Dermatopathology, University Hospital of Sart-Tilman, Liège, Belgium
23
24
25

26 **Corresponding author:**
27

28 Fransiska Malfait
29

30 Center for Medical Genetics
31

32 Ghent University Hospital, 0K5
33

34 De Pintelaan 185
35

36 B-9000 Ghent
37

38 Belgium
39

40 Tel: 0032-9-332.36.03
41

42 Fax: 0032-9-332.49.70
43

44 E-mail: Fransiska.Malfait@UGent.be
45

Formatted: English (U.K.)

Abstract

We present clinical and molecular findings of three patients with an EDS VIB phenotype from two consanguineous families. The clinical findings of EDS kyphoscoliotic type (EDS type VI A&B) comprise kyphoscoliosis, muscular hypotonia, hyperextensible, thin and bruisable skin, atrophic scarring, joint hypermobility and variable ocular involvement. Distinct craniofacial abnormalities, joint contractures, wrinkled palms, and normal urinary pyridinoline ratios distinguish EDS VIB from EDS VIA. A genome-wide SNP scan and sequence analyses identified a homozygous frameshift mutation ([NM_130468.2:c.145delG](#), [NP_569735.1:p.Val49*](#)) in *CHST14*, encoding dermatan-4-sulfotransferase 1 (D4ST-1), in two Turkish siblings. Subsequent sequence analysis of *CHST14* identified a homozygous 20-bp duplication ([NM_130468.2:c.981_1000dup](#), [NP_569735.1:p.Glu334Glyfs*107](#)) in an Indian patient. Loss-of-function mutations in *CHST14* were recently reported in adducted thumb-clubfoot syndrome (ATCS). Patients with ATCS present similar craniofacial and musculoskeletal features as [the EDS VIB patients reported here](#), but lack the severe skin manifestations. By identifying an identical mutation in patients with EDS VIB and ATCS, we show that both conditions form a phenotypic continuum. Our findings confirm that the EDS-variant associated with *CHST14* mutations (Miyake, et al., 2010) [forms a clinical spectrum](#), [which we propose to coin as “musculo-contractural EDS”](#) and [which](#) results from a defect in dermatan sulfate biosynthesis, [perturbing](#) collagen assembly.

Deleted: Turkish

Deleted: and Indian

Deleted: gastro-intestinal and genitourinary manifestations,

Formatted: English (U.S.)

Deleted: c.145delG, p.V49X

Deleted: c.981_1000dup, pGlu334GlyfsX107

Deleted: the

Deleted:

Deleted: new

Deleted: , recently

Deleted: which

Deleted: s

Keywords: Ehlers-Danlos syndrome type VI, collagen, *CHST14*, dermatan-4-sulfotransferase 1, adducted thumb clubfoot syndrome

Introduction

The Ehlers-Danlos syndrome (EDS) comprises a heterogeneous group of connective tissue diseases of which the major clinical features are skin hyperextensibility, joint hypermobility and generalized connective tissue fragility. (Steinmann et al., 2002) The current classification recognizes six subtypes which differ in clinical symptoms, inheritance pattern and the nature of the underlying biochemical and molecular defect(s). In several of these subtypes mutations have been identified in genes encoding the polypeptide (α)-chains of fibrillar collagen type I (arthrochalasia type), collagen type III (vascular type) and collagen type V (classic type), or in genes encoding enzymes involved in the posttranslational modification of type I collagen (kyphoscoliotic and dermatosparaxis type). (Beighton et al., 1998) Recently, several new EDS-variants have been characterized, which include the progeroid form of EDS (*β GALT7*, OMIM 604327) (Quentin et al., 1990); a Tenascin-X deficient form of EDS (*TNXB*, OMIM 600985) (Schalkwijk et al., 2001); a cardiac-valvular EDS-form (*COL1A2*, OMIM 120160) (Schwarze et al., 2004; Malfait et al., 2006); and an EDS-like spondylocheiroidysplastic form (*SLC39A13*, OMIM 608735). (Giunta et al., 2008)

EDS kyphoscoliotic type or EDS type VI is an autosomal recessive (AR) disorder which is characterized by early-onset progressive kyphoscoliosis, severe neonatal muscle hypotonia with delayed gross motor development, generalized joint hyperlaxity, marfanoid habitus, osteopenia, and a fragile, hyperextensible and bruisable skin with widened atrophic scars. In some patients, scleral fragility with risk for rupture of the globe, and life-threatening rupture of medium-sized arteries have occasionally been reported. (Yeowell and Steinmann, 2000) One form of EDS kyphoscoliotic type, EDS type VIA, is caused by deficient activity of the enzyme procollagen-lysine, 2-oxoglutarate 5-dioxygenase 1 (PLOD1 or lysyl hydroxylase-1 (LH-1)) (Pinnell et al.,

Deleted: (Steinmann, et al., 2002)

Field Code Changed

Deleted: s

Field Code Changed

Deleted: (Beighton, et al., 1998)

Formatted: Font: Not Italic

Deleted: (Quentin, et al., 1990)

Field Code Changed

Field Code Changed

Deleted: (Schalkwijk, et al., 2001)

Field Code Changed

Deleted: (Malfait, et al., 2006; Schwarze, et al., 2004)

Formatted: Font: Times New Roman, 12 pt, Not Bold

Field Code Changed

Deleted: (Giunta, et al., 2008)

Field Code Changed

Field Code Changed

Formatted: English (U.K.)

1
2
3
4
5
6
7
8
9
10
11
12
13
14
15
16
17
18
19
20
21
22
23
24
25
26
27
28
29
30
31
32
33
34
35
36
37
38
39
40
41
42
43
44
45
46
47
48
49
50
51
52
53
54
55
56
57
58
59
60

[1972](#), This enzyme hydroxylates lysyl residues in Xaa-Lys-Gly- triplets of the helical region of collagens and collagen-like sequences of non-collagenous proteins (Kivirikko and Pihlajaniemi, 1998). The resulting hydroxylysyl residues are essential for the formation of stable intermolecular crosslinks that provide tensile strength and mechanical stability to the collagen fibrils, and they serve as attachment sites for carbohydrate units. These carbohydrate units have been shown to influence the lateral packing of collagen molecules into fibrils. The diagnosis of EDS type VIA can be confirmed by the demonstration of an increased ratio of lysylpyridinoline (LP) to hydroxylysylpyridinoline (HP) crosslinks in the urine, [\(Steinmann et al., 1995\)](#), a reduction of > 75% of LH-1 enzyme activity in skin (Yeowell and Walker, 2000), and mutation analysis of the *PLOD1* gene ([OMIM 153454](#)).

Deleted: (Pinnell, et al., 1972)

Field Code Changed

Deleted: (Steinmann, et al., 1995)

Field Code Changed

Field Code Changed

A subset of EDS type VI patients have been reported with normal LH-1 activity and normal urinary LP/HP ratios. They are usually referred to as “EDS type VIB” and the underlying molecular defect is hitherto unknown ([Steinmann et al., 1975](#); [Ogur et al., 1994](#); [Steinmann et al., 2002](#); [Walker et al., 2004](#); [Kosho et al., 2005](#); [Kosho et al., 2010](#)). A small proportion of these present with predominant corneal fragility and fit into the Brittle Cornea Syndrome (BCS), for which *ZNF469* was recently identified as the causal gene. ([Al-Hussain et al., 2004](#); [Abu et al., 2008](#)).

Field Code Changed

Deleted: (Kosho, et al., 2010; Kosho, et al., 2005; Ogur, et al., 1994; Steinmann, et al., 1975; Steinmann, et al., 2002; Walker, et al., 2004)

Field Code Changed

Deleted: (Abu, et al., 2008; Al-Hussain, et al., 2004)

Here we report the clinical, biochemical and ultrastructural features of three patients with EDS type VIB from two consanguineous families and provide evidence that this phenotype is caused by mutations in *CHST14* ([OMIM 608429](#)), encoding dermatan-4-sulfotransferase 1.

Material and Methods

Subjects

1
2 The patients and parents participated in this study following informed consent. This study has
3
4 been approved by the Ethics Committee of the Ghent University Hospital, Ghent, Belgium. In all
5
6 patients, a skin biopsy was taken for ultrastructural and/or biochemical studies. Blood samples
7
8 were collected from the patients, their parents, and from unaffected siblings.
9

10 11 **Biochemical analysis**

12 A dermal fibroblast culture of patient 1 and 2 was established from a skin biopsy, and grown
13
14 under standard conditions. At confluence the cells were labeled with ¹⁴C proline as described
15
16 previously (Nuytinck et al., 1996) and collagen proteins were separated on SDS-polyacrylamide
17
18 gels. The gels were processed for fluorography, dried and exposed to an X-ray film.
19
20

Field Code Changed

Deleted: (Nuytinck, et al., 1996)

21 Urinary lysylpyridinoline and hydroxyllysylpyridinoline excretion was evaluated with HPLC in
22
23 all patients as described previously. (Steinmann et al., 1995)
24
25

Deleted: (Steinmann, et al., 1995)

Field Code Changed

26 27 **Ultrastructural analyses**

28 For ultrastructural studies, a skin biopsy from the upper arms of patient 2 was fixed with 4%
29
30 glutaraldehyde in phosphate buffer at pH 4.7 and prepared for transmission microscopy.
31
32

33 34 **Homozygosity mapping**

35 Genomic DNA was isolated from venous blood using the Puregene® DNA purification kit
36
37 (Gentra Systems, Minneapolis, MN, USA) according to the manufacturer's instructions.
38
39 Genotyping was performed for individuals II.1-3 of family 1 using the Mapping 250K Nsp array
40
41 from Affymetrix containing 262264 SNPs (analysis performed by DNA Vision, Gosselies,
42
43 Belgium). Genomic regions harbouring 25 consecutive homozygous SNPs (approximately 250
44
45
46
47

1
2 kb) or more were marked. To overcome SNP miscalls, regions spanning maximum 50 kb
3
4 between two marked regions were considered homozygous. Eventually, regions that contained at
5
6 least 100 consecutive homozygous SNPs were assigned as a candidate region if they were
7
8 homozygous for the same allele in both affected patients and had a different genotype in the non-
9
10 affected individual.

11 12 13 **Mutation screening**

14
15 PCR amplification was performed with 50ng genomic DNA. Reaction conditions,
16
17 oligonucleotide primer pairs and thermal cycling conditions are listed in [Suppl. Table S1](#). PCR
18
19 products were bidirectionally sequenced using the BigDye® Terminator Cycle Sequencing kit
20
21 protocol (Applied Biosystems, Foster City, CA, USA), followed by separation on the ABI
22
23 3730XL Genetic Analyzer (Applied Biosystems).
24
25
26
27

Deleted: Supplementary

28 Results

29 30 **Clinical findings**

31
32 The clinical findings are summarized in [Suppl. Table S2](#) and illustrated in Fig 1.
33

Deleted: ementary

34 Family 1 (patient 1 & 2)

35
36 Patient 1 was born by normal vaginal delivery at 42 weeks of gestation as the second child to
37
38 first-cousin Turkish parents. Birth weight was 3100g (-0.67 SD) and birth length 51cm (mean).
39
40 Occipitofrontal circumference (OFC) was not recorded. She presented a large fontanel, flexion-
41
42 adduction contractures of the thumb, which disappeared during the first year of life,
43
44 camptodactyly of the 3rd, 4th and 5th finger and clubfeet, which were surgically corrected at age
45
46 2,5 yrs. She had a slender build with low muscle and fat mass leading to severe decubitus
47
48
49
50
51
52
53
54
55
56
57
58
59
60

1
2 wounds on the buttocks during school age. Motor development was delayed, and she was not
3
4 able to walk before age 4 yrs. During childhood she developed a kyphoscoliosis, which
5
6 worsened rapidly at time of puberty and required surgery at age of 14 yrs. Her tissues were noted
7
8 to be very thin and fragile upon surgical procedures. Skin fragility, delayed wound healing, easy
9
10 bruising and bleeding from the gums were prominent. An umbilical hernia was corrected at age 5
11
12 yrs. Hiatal hernia with gastro-esophageal reflux and frequent bouts of abdominal cramping pain
13
14 were reported. Abdominal ultrasonography revealed nephrolithiasis at a very young age. Early-
15
16 onset high myopia and glaucoma required several surgical treatments, but evolved to phtysis in
17
18 the right eye and were complicated by retinal detachment in the left eye.

19
20 Examination at age 22 yrs revealed a height of 155cm (-2.0 SD) with an armspan of 149 cm and
21
22 OFC of 55 cm (mean). She presented a slender build with low muscle mass and marked
23
24 muscular hypotonia, a corrected kyphoscoliosis and a narrow, flattened anterior thorax with no
25
26 breast development. She had no light perception, and presented mild bilateral hearing loss.

27
28 Craniofacial abnormalities included brachycephaly, asymmetric face with deep-set eyes,
29
30 downslanting palpebral fissures, low-set and posteriorly rotated ears, malar hypoplasia, a short
31
32 nose with hypoplastic columella, small mouth with thin upper lip, dental crowding, high and
33
34 narrow palate and a protruding jaw with pointed chin. Her skin was very thin, transparent and
35
36 hyperextensible, showed several cigarette paperscars and felt doughy and soft upon palpation
37
38 with a very puffy aspect on lower limbs and feet. She had tapering fingers, severe wrinkling of
39
40 the palms, flexion contractures of fingers (Fig 1D) and toes, and dislocation of the radio-ulnar
41
42 joints. Joint hyperlaxity was limited to the metacarpophalangeal joints. She presented talipes

43
44 | valgus and planus. Echocardiography at age 21 yrs, was normal, with an aortic root of 17 mm.

Deleted: 2

Deleted: and 28 yrs

1
2 Patient 2, the younger sister of patient 1, was born at 42 weeks of gestation after a normal
3 pregnancy and vaginal delivery. At birth, her fontanel was large and she had clubfeet which were
4 corrected at 12 months. Muscular hypotonia caused delayed gross motor development and
5 inability to walk independently before age 2 yrs. During childhood, she suffered a spontaneous
6 rupture of the abdominal muscles and diastasis recti, repetitive painful dislocations of the
7 patellae, requiring surgical fixation, and repeated dislocations of temporomandibular, shoulder
8 and ankle joints. At the age of 14 yrs she developed a rapidly progressive lumbar scoliosis. Skin
9 fragility, delayed wound healing, easy bruising and formation of widened atrophic scars were
10 comparable to her sister's, She suffered from early onset nephrolithiasis and abdominal
11 ultrasonography disclosed hydronephrosis due to renal ptosis and ureteral stenosis for which an
12 ureteral stent was placed. The laparoscopic procedure was complicated by severe hemorrhage
13 due to excessive tissue fragility. Early-onset high myopia and glaucoma were complicated by
14 retinal detachment of the left eye. Clinical examination at the age of 14 yrs showed a similar,
15 though milder phenotype as her older sister, with low muscle mass, muscular hypotonia and a
16 narrow, flat thorax. She was 168 cm tall (0.68 SD) with an armspan of 157 cm and an OFC of 58
17 cm (> 2.0 SD). Facial appearance was characterized by brachycephaly, malar hypoplasia, bushy
18 eyebrows and synophrys, downslanting palpebral fissures, blue sclerae, microcornea, thin
19 upperlip and a high, narrow palate (Fig1A). Her skin had the same doughy, hyperextensible and
20 thin aspect as her sister's, with atrophic cigarette paperscars on both knees (Fig 1 J&K) and
21 marked generalized hirsutism. She had tapering fingers, clinodactyly, small joint hypermobility,
22 wrinkled palms (Fig 1E) and dislocation of the radio-ulnar joints (Fig 1I). Her feet were small
23 and broad with short toes, and markedly soft and puffy subcutaneous tissues (Fig 1G). Follow-up
24 examination at age 21 yrs (Fig 1B) revealed moderate thoracolumbar scoliosis with high
25
26
27
28
29
30
31
32
33
34
35
36
37
38
39
40
41
42
43
44
45
46
47
48
49
50
51
52
53
54
55
56
57
58
59
60

Deleted: '

Deleted: E

1
2 vertebral bodies on X-rays, absence of breast development and a mild hearing impairment.

3
4 Echocardiography at the age of 14 yrs was normal with an aortic root of 18 mm.

Deleted: and 21

5
6 Family 2 (patient 3)

7
8 Patient 3 is a 12-year old girl and first child of a consanguineous couple of Indian origin. She
9
10 was born at term after an uneventful pregnancy and delivery with a birth weight of 2800 g (-1.88
11
12 SD). Birth length and OFC were not recorded. She presented clubfeet at birth, which were
13
14 corrected at the age of 18 months. Her fingers and toes were tapering with flexion contractures
15
16 of all fingers (Fig 1F) and toes (Fig 1H) and flexion-adduction contractures of the thumbs (Fig
17
18 1F). She had prominent wrinkles on the palms, but absence of deep palmar creases. At the age of
19
20 5 months she developed a kyphoscoliosis which worsened progressively during childhood. Gross
21
22 motor development was delayed, she had a slender build with low muscle mass and a history of
23
24 dislocation of the left elbow and tendon injury of the right knee following a fall. Her skin was
25
26 soft and hyperextensible, especially over elbows and neck. Wound healing was delayed with
27
28 large gaping wounds and severe atrophic cigarette paperscars (Fig 1L), which needed multiple
29
30 surgical suturing over knees. She presented easy bruisability and chronic ulcers. Her facial
31
32 appearance was characterized by blue sclerae, microcornea, prominent bulging eyes, myopia and
33
34 low-set ears (Fig 1C). At the age of 8 yrs she had a subacute duodenal obstruction due to
35
36 malrotation, which was treated surgically.

37
38
39
40 **Morphological and ultrastructural studies**

41
42 The majority of the collagen bundles were small-sized. Some bundles were composed of variable
43
44 diameter collagen fibrils separated by irregular interfibrillar spaces. Flower-like collagen fibrils
45
46 were present. Granulo-filamentous material was found throughout the dermis, within the

1 collagen bundles and in the interstitial area, which in addition contained large stellate globules of
2
3 hyaluronic acid (not shown). The elastic fibers presented normal ultrastructural features in
4
5 papillary and reticular dermis (not shown). Fibroblasts exhibited an elongated and/or dilated
6
7 endoplasmic reticulum (ER) (Fig 2).
8
9

Deleted: (Fig 2A)

Deleted: B

10 11 **Biochemical studies**

12 SDS-PAGE analysis of procollagens and pepsin-digested collagens from the medium and the cell
13
14 layer fraction showed a normal electrophoretic pattern for type I, III and V (pro)collagen proteins
15
16 (data not shown).
17
18

19 In all three patients, normal LP/HP ratios were observed, excluding the diagnosis of EDS type
20
21 VIA.
22
23

24 25 **Molecular studies**

26 After excluding the presence of disease-causing mutations in the *PLOD1* gene by means of direct
27
28 sequencing at gDNA level, homozygosity mapping for individuals II.1-3 from family 1 identified
29
30 four candidate regions which were homozygous among the two affected patients, but not in the
31
32 non-affected sib and which contained in total 217 known or predicted genes, excluding
33
34 pseudogenes (NCBI MapViewer, Build 36.3) (detailed description of the regions in Table 1).
35
36

37 Within the disease interval no genes previously associated with EDS were found. Sixteen
38
39 positional and functional candidate genes, including *TGFBR3*, *RSPO3*, *ZNF596*, *SRP14*,
40
41 *CHST14*, *DNAJC17*, *PPP1R14D*, *SPINT1*, *VPS18*, *VPS39*, *SNAP23*, *LRRC57*, *PDIA3*, *MFAP1*,
42
43 *GALK2* and *AP4E1* were selected for sequencing using the Sanger method, and this resulted in
44
45 the identification of a homozygous deletion of a single nucleotide in the *CHST14* gene in the two
46
47

Formatted: Font: Not Italic

1
2 affected patients of family 1 ([NM_130468.2:c.145delG, NP_569735.1:p.Val49*](#)) (Fig 3A).

Deleted: c.145delG, p.V49X

Formatted: English (U.S.)

3
4 Subsequent sequencing analysis of *CHST14* identified a homozygous 20-bp duplication in

5
6 patient 3 ([NM_130468.2:c.981_1000dup, NP_569735.1:p.Glu334Glyfs*107](#)) (Fig 3B). The

Deleted: c.981_1000dup,
pGlu334GlyfsX107

Formatted: English (U.S.)

7
8 mutations were found in homozygous state only in the affected patients, and were present in the

9
10 heterozygous state in their parents. The unaffected sister from family 1 has two wild-type alleles.

11
12 The mutations were not detected in 109 control individuals (218 alleles). Nucleotide numbering

13
14 reflects cDNA numbering with +1 corresponding to the A of the ATG translation initiation

15
16 codon in the reference sequence (GenBank reference sequence [NM_130468.3](#)), according to the

Deleted: 8

17
18 journal guidelines. The initiation codon is codon 1.

Discussion

We report homozygous frameshift mutations in *CHST14*, encoding dermatan-4-sulfotransferase 1 (D4ST-1), in two unrelated inbred families from Turkish and Indian origin respectively, presenting a form of EDS, which, up till now, has been, referred to as EDS VIB. The clinical phenotype in these patients is characterized by distinct craniofacial, musculoskeletal, cutaneous and ophthalmological abnormalities (Suppl. Table S2). Our patients closely resemble the Pakistani siblings reported by Steinmann and co-workers (Steinmann et al., 1975), with a phenotype of EDS kyphoscoliotic type (EDS VI) but normal LH-1 activity, a condition subsequently referred to as EDS VIB. (Steinmann et al., 2002) Loss-of-function mutations in *CHST14* were recently shown to cause a rare autosomal recessive condition called “adducted thumb clubfoot syndrome” (ATCS). (Dundar et al., 2009) The EDS patients reported here show many features of ATCS including the craniofacial abnormalities, congenital contractures of thumbs and fingers, clubfeet, joint hyperlaxity, wasted build, thin skin and easy bruising. However, they differ from ATCS in the severity of the cutaneous manifestations, especially in the presence of atrophic scars, and also in the more severe kyphoscoliosis and ocular involvement (Suppl. Table S2). With the identification of a homozygous NM_130468.2:c.145delG (NP_569735.1:p.Val49*) mutation in patient 1 and 2 of this study, which is identical to the mutation reported earlier in two ATCS-sibs (Dundar et al., 2009), we provide evidence that ATCS and EDS VIB form a continuum within the same clinical spectrum. Furthermore our findings show that the new EDS-variant, recently reported by Kosho et al (Kosho et al., 2010), and also shown to be associated with loss-of-function mutations in *CHST14* (Miyake et al., 2010), is situated within the EDS VIB-ATCS spectrum.

Formatted: Justified

Deleted: is

Deleted: ementary

Field Code Changed

Deleted: (Steinmann, et al., 1975)

Deleted: (Steinmann, et al., 2002)

Field Code Changed

Formatted: English (U.S.)

Field Code Changed

Deleted: (Dundar, et al., 2009)

Deleted: Supplementary

Formatted: English (U.S.)

Formatted: English (U.S.)

Formatted: English (U.S.)

Deleted: c.145delG (p.V49X)

Field Code Changed

Deleted: (Dundar, et al., 2009)

Deleted:

Field Code Changed

Deleted: (Kosho, et al., 2010)

Field Code Changed

Deleted: (Miyake, et al., 2010)

Hitherto reported *CHST14* mutations comprise six missense mutations, one frameshift mutation and one nonsense mutation ([Dundar et al., 2009](#)). We expand the range of mutations in *CHST14* with a novel homozygous 20-bp duplication in the Indian patient (patient 3).

Deleted: (Dundar, et al., 2009; Miyake, et al., 2010)

Field Code Changed

The *CHST14*- related EDS VIB phenotype is distinguished from EDS VIA by the presence of distinct craniofacial abnormalities, contractures of fingers and toes, tapering fingers, severe wrinkling of the palms, and gastro-intestinal and genito-urinary manifestations ([Suppl. Table S2](#)). On the other hand, arterial rupture and rupture of the eye globe, sometimes observed in EDS VIA, have not been observed in patients with *CHST14* mutations so far. In order to clearly distinguish the *CHST14*-related phenotype and its associated risks from the kyphoscoliotic type of EDS, we propose to coin the *CHST14*-related condition “musculo-contractural Ehlers-Danlos syndrome”.

Deleted: Supplementary

Formatted: Font: Italic

Formatted: Font: Italic

Musculo-contractural EDS shows phenotypic resemblance to the spondylocheirodysplastic form of EDS (SCD-EDS) ([Suppl. Table S2](#)), caused by mutations in the *SLC39A13*, encoding a membrane-bound zinc transporter and in which moderately increased urinary LP/HP ratios

Deleted: EDS VIB

Deleted: Supplementary

(intermediate values between EDS VIA & VIB) have been reported ([Giunta et al., 2008](#)).

Field Code Changed

Deleted: (Giunta, et al., 2008)

CHST14 encodes the enzyme D4ST-1, which is involved in the biosynthesis of the glycosaminoglycan (GAG) dermatan sulfate (DS), where it catalyzes 4-O-sulfation of N-acetyl-galactosamine (GalNAc) ([Penc et al., 1998](#)). GAGs, such as DS and chondroitin sulfate (CS) are long unbranched polymers, whose synthesis starts with the formation of a tetrasaccharide linker region that attaches the GAG chains to a serine residue within the conserved attachment sites of core proteins ([Suppl. Fig S1](#)). CS/DS chains are composed of alternating glucuronic acid (GlcA) and GalNAc disaccharide units. (Trowbridge and Gallo, 2002). In DS, GlcA is epimerized to iduronic acid (IdoA) ([Maccarana et al., 2006; Pacheco et al., 2009](#)). Subsequent addition of

Field Code Changed

Deleted: (Penc, et al., 1998)

Deleted: ementary

Field Code Changed

Field Code Changed

Deleted: (Maccarana, et al., 2006; Pacheco, et al., 2009)

1 sulfate to the C-4 hydroxyl group of GalNAC prevents further epimerization of the adjacent
2
3
4 GlcA or IdoA. (Malmstrom, 1984) GalNac can be sulfated in the 4-O-position by the three major
5
6 sulfotransferases C4ST-1 and -2 (chondroitin-4-sulfotransferase 1 & 2) and D4ST-1, which have
7
8 different substrate specificities. (Evers et al., 2001; Hiraoka et al., 2001; Mikami et al., 2003)

Field Code Changed

Deleted: (Evers, et al., 2001; Hiraoka, et al., 2001; Mikami, et al., 2003)

Field Code Changed

9
10 The epimerisation and sulfation reactions are not random, but reflect a tightly controlled system
11
12 which produces structural variability into the CS/DS chain, thereby determining functional
13
14 interactions with potential protein partners. (Trowbridge and Gallo, 2002). Both Dundar et al and
15
16 Miyake et al showed that the *CHST14* mutations result in loss of D4ST-1 activity. Although
17
18 patients' fibroblasts are able to epimerize GlcA-GalNac to IdoA-GalNac, they cannot add
19
20 sulfate to the C-4 hydroxyl group of IdoA-GalNac, thereby allowing back-epimerisation from
21
22 IdoA to GlcA to form CS. (Dundar et al., 2009; Miyake et al., 2010) This suggests that D4ST-1
23
24 is the key enzyme for 4-O-sulfation of DS in skin, which cannot be compensated for by the
25
26 chondroitin 4-O-sulfotransferases.

Field Code Changed

Field Code Changed

Deleted: (Dundar, et al., 2009; Miyake, et al., 2010)

27
28 DS is covalently attached via an O-xylose linkage to serine residues of core proteins to form DS
29
30 proteoglycans (DSPG), such as thrombomodulin, versican, and the small leucine-rich
31
32 proteoglycans (SLRP) decorin and biglycan. These DSPG have widespread tissue distribution in
33
34 blood vessel walls, cornea, skin, tendon, cartilage, bone and undifferentiated mesenchymal
35
36 tissue. (Trowbridge and Gallo, 2002) They are involved in organization of the extracellular
37
38 matrix, wound repair, anti-coagulant processes, cell adhesion, migration and proliferation.

Field Code Changed

39
40 Miyake et al showed that DS of decorin is completely lost and replaced by CS in the patients'
41
42 fibroblasts. (Miyake et al., 2010) Decorin is essential in maintaining skin integrity and collagen
43
44 structure. The protein core of decorin binds to collagen fibrils, and its single DS chain binds to
45
46 Tenascin-X, another extracellular matrix (ECM) protein which co-localizes with collagen fibrils.

Field Code Changed

Deleted: (Miyake, et al., 2010)

1
2 Patients deficient in tenascin-X and mice deficient in decorin both have increased skin fragility
3
4 and altered skin collagen fibril architecture ([Danielson et al., 1997](#); [Schalkwijk et al., 2001](#)),

Deleted: (Danielson, et al., 1997;
Schalkwijk, et al., 2001)

Field Code Changed

5
6 Miyake et al argue that loss of the decorin hybrid CS/DS chain and replacement by CS decreases
7
8 the flexibility of the GAG chain. This hybrid CS/DS regulates the space between collagen fibrils,
9
10 and its replacement by CS results in disturbed collagen bundle organisation, as observed on
11
12 ultrastructural examination of the skin from D4ST-1 deficient patients ([Miyake et al., 2010](#)), and
13
14 this study).

Deleted: (Miyake, et al., 2010)

Field Code Changed

15
16 DSPG bind to a diverse range of extracellular matrix proteins either through their core protein or
17
18 through their GAG chains. Besides structural molecules such as collagens and tenascin-X, these
19
20 include growth factors, cytokines, chemokines and protease inhibitors, including proteins
21
22 involved in the coagulation cascade (Trowbridge and Gallo, 2002). The broad array of
23
24 physiological events in which DS and DSPG play a role, and the essential role of D4ST-1 in the
25
26 biosynthesis of these DS, indicate that altered interaction of these proteoglycans, and disturbed
27
28 ECM homeostasis underly the pathogenesis of both [musculo-contractural EDS](#) and ATCS, and
29
30 explains the observed multisystemic clinical manifestations which result from disturbances in
31
32 diverse physiological processes, including development, extracellular matrix maintenance and
33
34 wound repair.

Field Code Changed

Deleted: EDS VIB

35 36 37 Acknowledgments:

38 We wish to thank the patients and their parents for participating in this work.

39
40
41 FM, DS and PV are fellows of the Fund for Scientific Research (FWO), Flanders, Belgium. This
42
43 work was supported by a Methusalem Grant 08/01M01108 from the Ghent University to ADP
44
45 and Grant G.0171.05 from the Fund for Scientific Research (FWO), Flanders, Belgium to ADP.
46
47

1
2
3
4
5
6
7
8
9
10
11
12
13
14
15
16
17
18
19
20
21
22
23
24
25
26
27
28
29
30
31
32
33
34
35
36
37
38
39
40
41
42
43
44
45
46
47
48
49
50
51
52
53
54
55
56
57
58
59
60

For Peer Review

References

Abu A, Frydman M, Marek D, Pras E, Nir U, Reznik-Wolf H, Pras E. 2008. Deleterious mutations in the Zinc-Finger 469 gene cause brittle cornea syndrome. *Am J Hum Genet* 82(5):1217-22.

Formatted: Line spacing: Double

Field Code Changed

Formatted: English (U.K.)

Formatted: German (Germany)

Al-Hussain H, Zeisberger SM, Huber PR, Giunta C, Steinmann B. 2004. Brittle cornea syndrome and its delineation from the kyphoscoliotic type of Ehlers-Danlos syndrome (EDS VI): report on 23 patients and review of the literature. *Am J Med Genet A* 124A(1):28-34.

Formatted: English (U.K.)

Beighton P, De Paepe A, Steinmann B, Tsipouras P, Wenstrup RJ. 1998. Ehlers-Danlos syndromes: revised nosology, Villefranche, 1997. Ehlers-Danlos National Foundation (USA) and Ehlers-Danlos Support Group (UK). *Am J Med Genet* 77(1):31-7.

Danielson KG, Baribault H, Holmes DF, Graham H, Kadler KE, Iozzo RV. 1997. Targeted disruption of decorin leads to abnormal collagen fibril morphology and skin fragility. *J Cell Biol* 136(3):729-43.

Dundar M, Muller T, Zhang Q, Pan J, Steinmann B, Vodopiutz J, Gruber R, Sonoda T, Krabichler B, Utermann G, Baenziger JU, Zhang L, Janecke AR. 2009. Loss of dermatan-4-sulfotransferase 1 function results in adducted thumb-clubfoot syndrome. *American Journal of Human Genetics* 85(6):873-82.

Evers MR, Xia G, Kang HG, Schachner M, Baenziger JU. 2001. Molecular cloning and characterization of a dermatan-specific N-acetylgalactosamine 4-O-sulfotransferase. *Journal of Biological Chemistry* 276(39):36344-53.

Giunta C, Elcioglu NH, Albrecht B, Eich G, Chambaz C, Janecke AR, Yeowell H, Weis M, Eyre DR, Kraenzlin M, Steinmann B. 2008. Spondylocheiro dysplastic form of the Ehlers-

1
2
3
4
5
6
7
8
9
10
11
12
13
14
15
16
17
18
19
20
21
22
23
24
25
26
27
28
29
30
31
32
33
34
35
36
37
38
39
40
41
42
43
44
45
46
47
48
49
50
51
52
53
54
55
56
57
58
59
60

Danlos syndrome--an autosomal-recessive entity caused by mutations in the zinc transporter gene SLC39A13. Am J Hum Genet 82(6):1290-305.

Hiraoka N, Misra A, Belot F, Hindsgaul O, Fukuda M. 2001. Molecular cloning and expression of two distinct human N-acetylgalactosamine 4-O-sulfotransferases that transfer sulfate to GalNAc beta 1-->4GlcNAc beta 1-->R in both N- and O-glycans. Glycobiology 11(6):495-504.

Kivirikko KI, Pihlajaniemi T. 1998. Collagen hydroxylases and the protein disulfide isomerase subunit of prolyl 4-hydroxylases. Adv Enzymol Relat Areas Mol Biol 72:325-98.

Kosho T, Miyake N, Hatamochi A, Takahashi J, Kato H, Miyahara T, Igawa Y, Yasui H, Ishida T, Ono K, Kosuda T, Inoue A, Kohyama M, Hattori T, Ohashi H, Nishimura G, Kawamura R, Wakui K, Fukushima Y, Matsumoto N. 2010. A new Ehlers-Danlos syndrome with craniofacial characteristics, multiple congenital contractures, progressive joint and skin laxity, and multisystem fragility-related manifestations. Am J Med Genet A 152A(6):1333-46.

Kosho T, Takahashi J, Ohashi H, Nishimura G, Kato H, Fukushima Y. 2005. Ehlers-Danlos syndrome type VIB with characteristic facies, decreased curvatures of the spinal column, and joint contractures in two unrelated girls. Am J Med Genet A 138A(3):282-7.

Maccarana M, Olander B, Malmstrom J, Tiedemann K, Aebersold R, Lindahl U, Li JP, Malmstrom A. 2006. Biosynthesis of dermatan sulfate: chondroitin-glucuronate C5-epimerase is identical to SART2. Journal of Biological Chemistry 281(17):11560-8.

Malfait F, Symoens S, Coucke P, Nunes L, De Almeida S, De Paepe A. 2006. Total absence of the alpha2(I) chain of collagen type I causes a rare form of Ehlers-Danlos syndrome with hypermobility and propensity to cardiac valvular problems. J Med Genet 43(7):e36.

Formatted: Font: Times New Roman, 12 pt

Formatted: English (U.K.)

- 1
2
3
4
5
6
7
8
9
10
11
12
13
14
15
16
17
18
19
20
21
22
23
24
25
26
27
28
29
30
31
32
33
34
35
36
37
38
39
40
41
42
43
44
45
46
47
48
49
50
51
52
53
54
55
56
57
58
59
60
- Malmstrom A. 1984. Biosynthesis of dermatan sulfate. II. Substrate specificity of the C-5 uronosyl epimerase. Journal of Biological Chemistry 259(1):161-5.
- Mikami T, Mizumoto S, Kago N, Kitagawa H, Sugahara K. 2003. Specificities of three distinct human chondroitin/dermatan N-acetylgalactosamine 4-O-sulfotransferases demonstrated using partially desulfated dermatan sulfate as an acceptor: implication of differential roles in dermatan sulfate biosynthesis. Journal of Biological Chemistry 278(38):36115-27.
- Miyake N, Kosho T, Mizumoto S, Furuichi T, Hatamochi A, Nagashima Y, Arai E, Takahashi K, Kawamura R, Wakui K, Takahashi J, Kato H, Yasui H, Ishida T, Ohashi H, Nishimura G, Shiina M, Saito H, Tsurusaki Y, Doi H, Fukushima Y, Ikegawa S, Yamada S, Sugahara K, Matsumoto N. 2010. Loss-of-function mutations of CHST14 in a new type of Ehlers-Danlos syndrome. Human Mutation.
- Nuytinck L, Dalgleish R, Spotila L, Renard JP, Van Regemorter N, De Paepe A. 1996. Substitution of glycine-661 by serine in the alpha1(I) and alpha2(I) chains of type I collagen results in different clinical and biochemical phenotypes. Hum Genet 97(3):324-9.
- Ogur G, Baykan N, De Paepe A, Steinmann B, Quatacker J, Kuseyri F, Yuksel-Apak M. 1994. Clinical, ultrastructural and biochemical studies in two sibs with Ehlers-Danlos syndrome type VI-B-like features. Clinical Genetics 46(6):417-22.
- Pacheco B, Malmstrom A, Maccarana M. 2009. Two dermatan sulfate epimerases form iduronic acid domains in dermatan sulfate. Journal of Biological Chemistry 284(15):9788-95.
- Penc SF, Pomahac B, Winkler T, Dorschner RA, Eriksson E, Herndon M, Gallo RL. 1998. Dermatan sulfate released after injury is a potent promoter of fibroblast growth factor-2 function. Journal of Biological Chemistry 273(43):28116-21.

1
2
3
4
5
6
7
8
9
10
11
12
13
14
15
16
17
18
19
20
21
22
23
24
25
26
27
28
29
30
31
32
33
34
35
36
37
38
39
40
41
42
43
44
45
46
47
48
49
50
51
52
53
54
55
56
57
58
59
60

Pinnell SR, Krane SM, Kenzora JE, Glimcher MJ. 1972. A heritable disorder of connective tissue. Hydroxylysine-deficient collagen disease. New England Journal of Medicine 286(19):1013-20.

Quentin E, Gladen A, Roden L, Kresse H. 1990. A genetic defect in the biosynthesis of dermatan sulfate proteoglycan: galactosyltransferase I deficiency in fibroblasts from a patient with a progeroid syndrome. Proc Natl Acad Sci U S A 87(4):1342-6.

Schalkwijk J, Zweers MC, Steijlen PM, Dean WB, Taylor G, van Vlijmen IM, van Haren B, Miller WL, Bristow J. 2001. A recessive form of the Ehlers-Danlos syndrome caused by tenascin-X deficiency. N Engl J Med 345(16):1167-75.

Schwarze U, Hata R, McKusick VA, Shinkai H, Hoyme HE, Pyeritz RE, Byers PH. 2004. Rare autosomal recessive cardiac valvular form of Ehlers-Danlos syndrome results from mutations in the COL1A2 gene that activate the nonsense-mediated RNA decay pathway. Am J Hum Genet 74(5):917-30.

Formatted: German (Germany)

Formatted: English (U.K.)

Steinmann B, Eyre DR, Shao P. 1995. Urinary pyridinoline cross-links in Ehlers-Danlos syndrome type VI. Am J Hum Genet 57(6):1505-8.

Formatted: German (Germany)

Formatted: English (U.K.)

Steinmann B, Gitzelmann R, Vogel A, Grant ME, Harwood R, Sear CH. 1975. Ehlers-Danlos syndrome in two siblings with deficient lysyl hydroxylase activity in cultured skin fibroblasts but only mild hydroxylysine deficit in skin. Helv Paediatr Acta 30(3):255-74.

Steinmann B, Royce P, Superti-Furga A. 2002. The Ehlers-Danlos Syndrome. In: Royce P, Steinmann B, editors. Connective Tissue and its Heritable Disorders. New York: Wiley-Liss, Inc. p 431-523.

Trowbridge JM, Gallo RL. 2002. Dermatan sulfate: new functions from an old glycosaminoglycan. Glycobiology 12(9):117R-25R.

Walker LC, Overstreet MA, Willing MC, Marini JC, Cabral WA, Pals G, Bristow J,

Atsawasuwan P, Yamauchi M, Yeowell HN. 2004. Heterogeneous basis of the type VIB form of Ehlers-Danlos syndrome (EDS VIB) that is unrelated to decreased collagen lysyl hydroxylation. *Am J Med Genet A* 131(2):155-62.

Yeowell H, Steinmann B. 2000. Ehlers-Danlos syndrome, kyphoscoliotic form. Seattle: University of Washington, Seattle.

Yeowell HN, Walker LC. 2000. Mutations in the lysyl hydroxylase 1 gene that result in enzyme deficiency and the clinical phenotype of Ehlers-Danlos syndrome type VI. *Mol Genet Metab* 71(1-2):212-24.

Formatted: German (Germany)

Formatted: Font: Times New Roman, 12 pt, German (Germany)

Formatted: Indent: Left: 0 pt, Hanging: 36 pt

Formatted: German (Germany)

Deleted: Table Legend¶
Table 1: Candidate regions for family 1 following homozygosity mapping.¶

Figure Legends

Figure 1: Clinical characteristics.

A-C: Clinical pictures of patient 2 at age 14 yrs (A) and age 21 yrs (B), showing craniofacial dysmorphism with flattened profile, malar hypoplasia, bushy eyebrows and synophrys, downslanting palpebral fissures, blue sclerae, microcornea, long philtrum with thin upperlip, and protruding jaw with pointed chin. Clinical picture of patient 3 at age 12 yrs (C).

D-I: Hands and feet with characteristic features. Patient 1 at age 22 yrs (D), patient 2 at age 14 (I) and age 21 yrs (E, G) and patient 3 at age 12 yrs (F, H): tapering fingers with flexion contractures and excessive wrinkling of the palms (D-F), foot deformities with short broad feet

1
2 and toes in patient 2 (G) and long tapering toes with contractures, pseudotumor and cigarette
3 paper scarring in patient 3 (H); dislocation of radio-ulnar joint in patient 2 (I).

4
5
6 J-L: Thin and hyperextensible skin (J) and cigarette paperscars in patient 2 (K) and 3 (L).
7
8
9

10 *Figure 2: electron microscopic findings in skin of patient 2.*

11 Fibroblasts show dilatation of endoplasmic reticulum.
12
13
14
15

Deleted: Collagen fibrils are of variable diameters and irregularly spaced (A), with presence of small flower-like deformities (arrows) and irregular interfibrillar spaces enriched in granulo-filamentous deposits (asterisk).

Deleted: ed

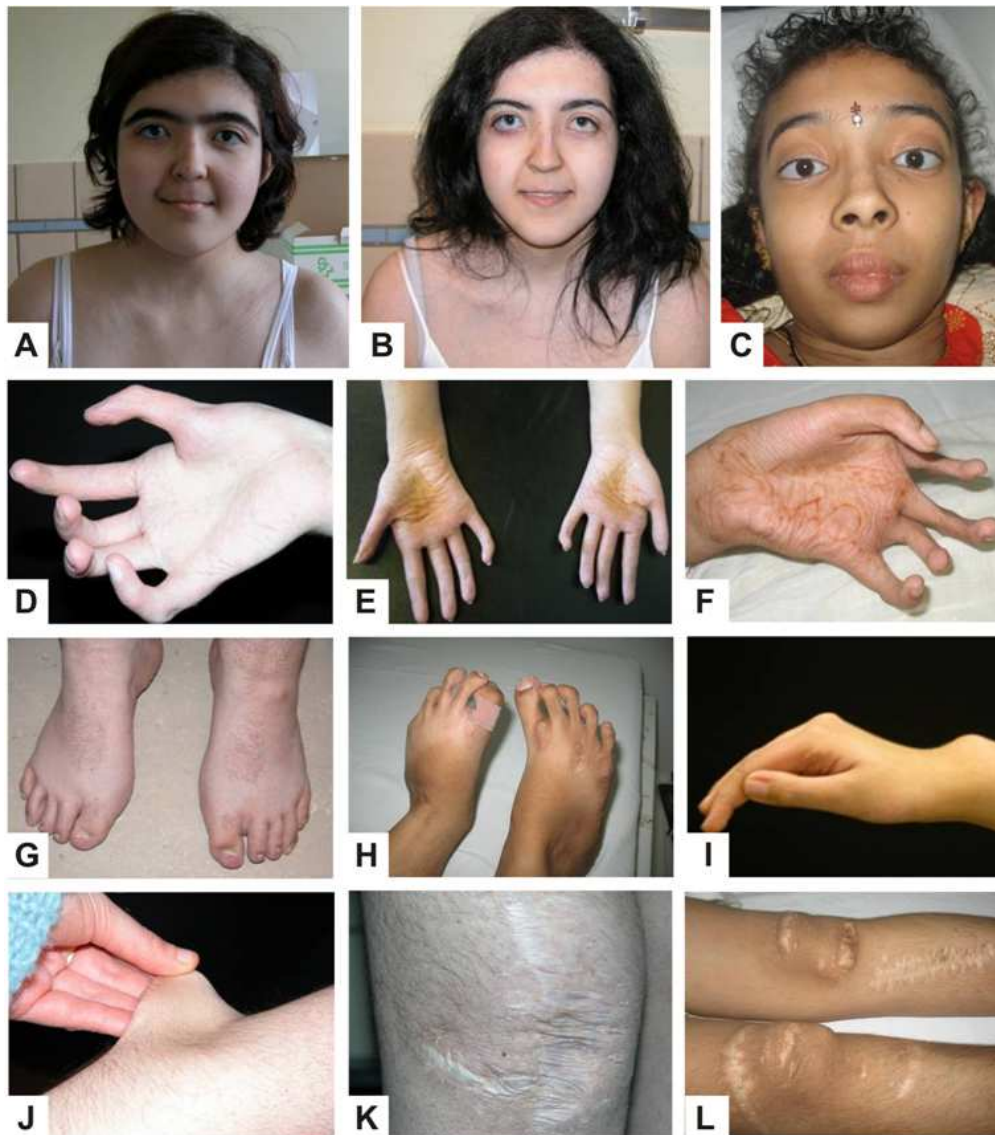Deleted: (B)

16 *Figure 3: CHST14 mutations in the patients.*

17
18 A: Pedigree of family 1. Sequence analysis reveals a homozygous G deletion at cDNA position
19 145 of the *CHST14* gene in both affected siblings. The deleted nucleotides are *boxed* in the WT
20 sequence (upper panel), while the *arrow* indicates the position of the deleted nucleotide in the
21 mutant sequence (lower panel).
22
23
24
25

26 B: Pedigree of family 2. Sequence analysis reveals a homozygous 20-bp duplication at cDNA
27 position c.981-1000 of the *CHST14* gene in the affected patient. The duplicated nucleotides are
28 *boxed* in upper and lower panel.
29
30
31
32
33
34
35
36
37
38
39
40
41
42
43
44
45
46
47
48
49
50
51
52
53
54
55
56
57
58
59
60

Formatted: Font: Italic



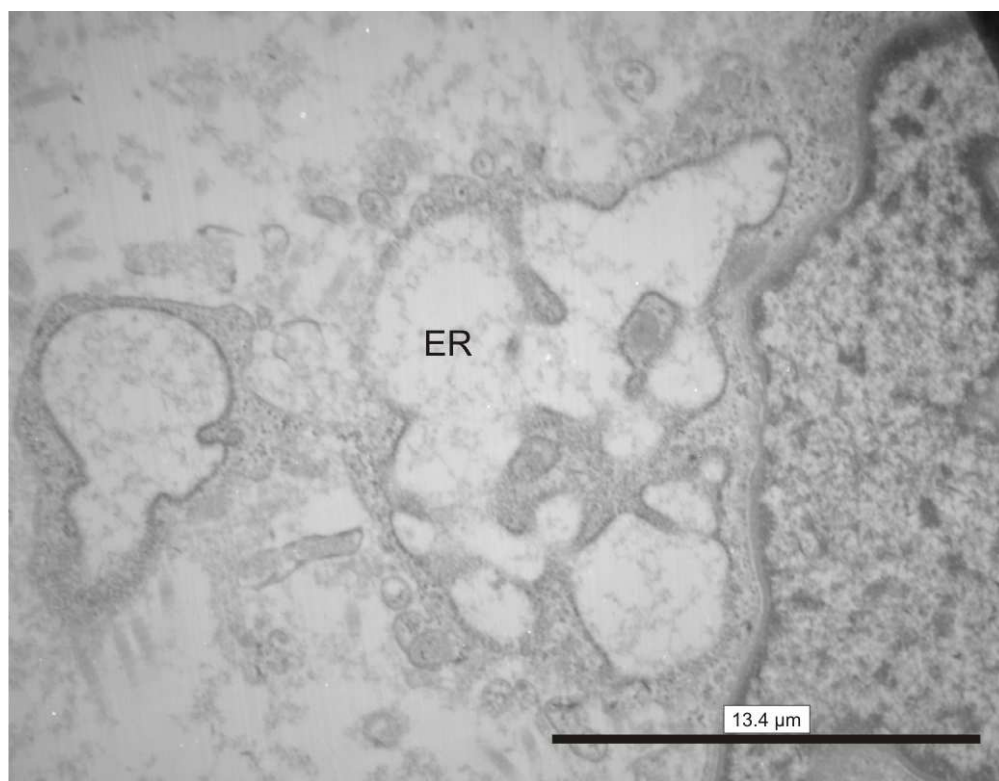
Clinical characteristics.

A-C: Clinical pictures of patient 2 at age 14 yrs (A) and age 21 yrs (B), showing craniofacial dysmorphism with flattened profile, malar hypoplasia, bushy eyebrows and synophrys, downslanting palpebral fissures, blue sclerae, microcornea, long philtrum with thin upperlip, and protruding jaw with pointed chin. Clinical picture of patient 3 at age 12 yrs (C).

D-I: Hands and feet with characteristic features. Patient 1 at age 22 yrs (D), patient 2 at age 14 (I) and age 21 yrs (E, G) and patient 3 at age 12 yrs (F, H): tapering fingers with flexion contractures and excessive wrinkling of the palms (D-F), foot deformities with short broad feet and toes in patient 2 (G) and long tapering toes with contractures, pseudotumor and cigarette paper scarring in patient 3 (H); dislocation of radio-ulnar joint in patient 2 (I).

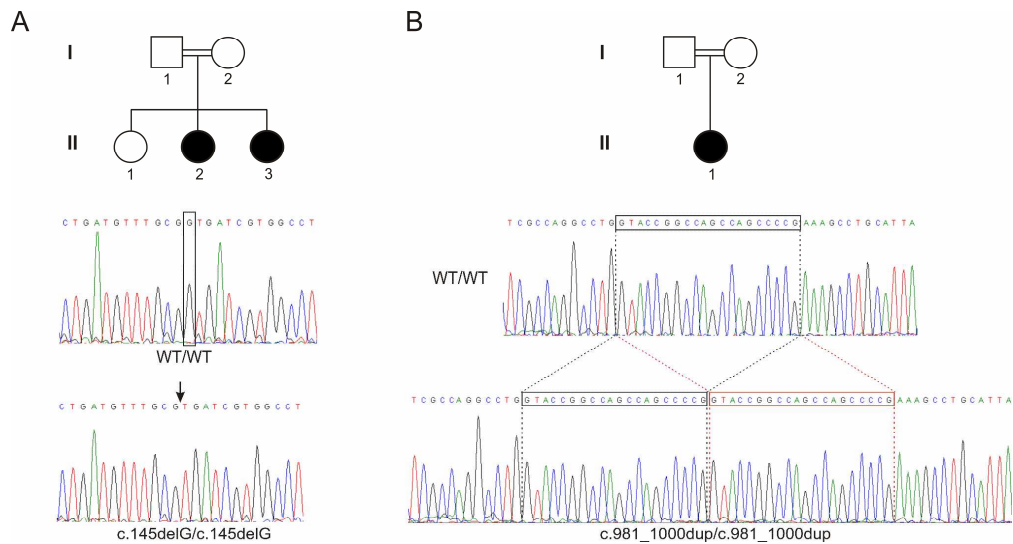
J-L: Thin and hyperextensible skin (J) and cigarette paperscars in patient 2 (K) and 3 (L).

32x36mm (600 x 600 DPI)



34 electron microscopic findings in skin of patient 2. Fibroblasts show dilatation of endoplasmic
35 reticulum.
36 43x34mm (600 x 600 DPI)

view



CHST14 mutations in the patients.

A: Pedigree of family 1. Sequence analysis reveals a homozygous G deletion at cDNA position 145 of the *CHST14* gene in both affected siblings. The deleted nucleotides are boxed in the WT sequence (upper panel), while the arrow indicates the position of the deleted nucleotide in the mutant sequence (lower panel).

B: Pedigree of family 2. Sequence analysis reveals a homozygous 20-bp duplication at cDNA position c.981-1000 of the *CHST14* gene in the affected patient. The duplicated nucleotides are boxed in upper and lower panel.

257x136mm (600 x 600 DPI)

Table Legend

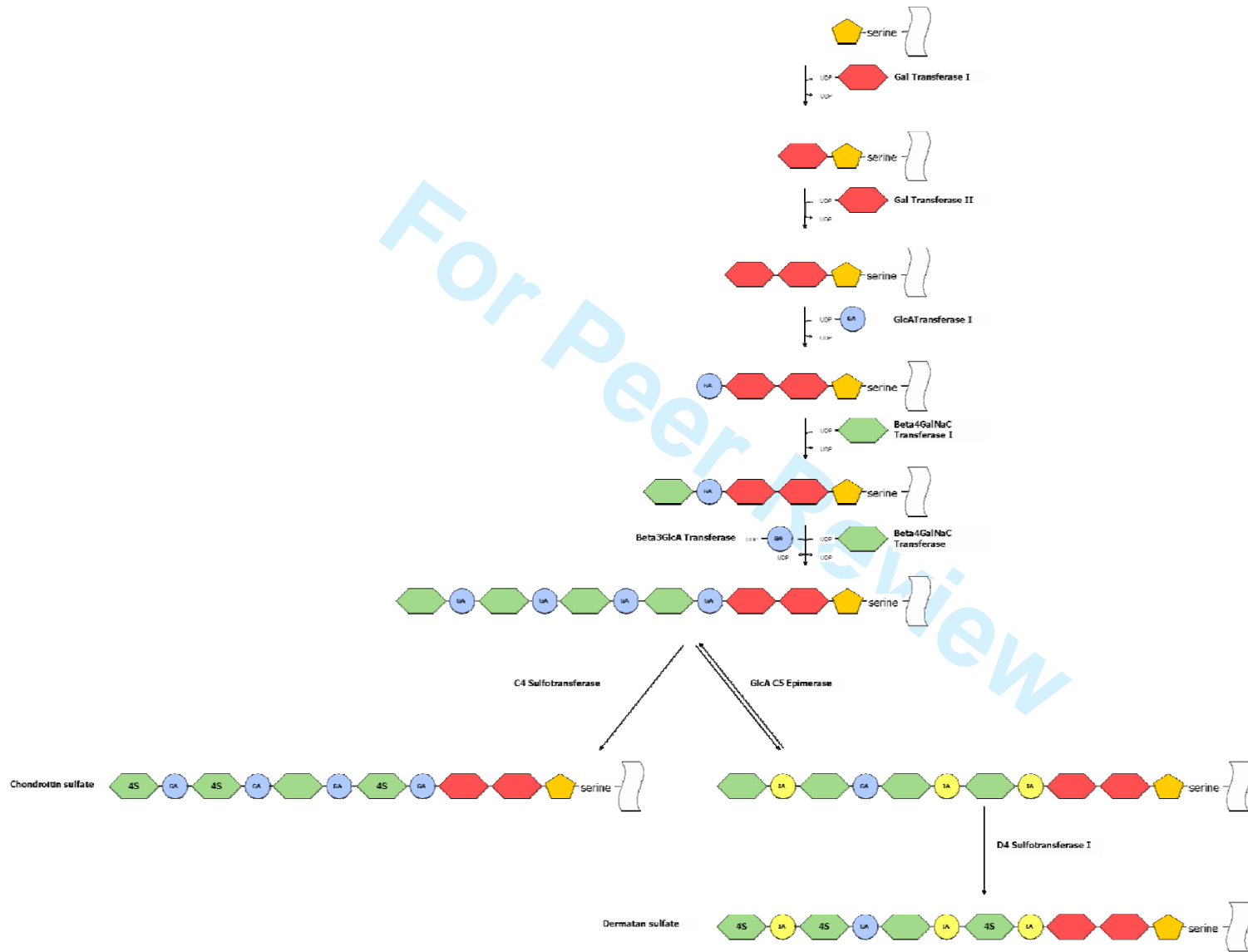
Table 1: Candidate regions for family 1 following homozygosity mapping.

Chr	SNP delineation	#Mb	# genes	# microRNAs
1	rs284180-rs1325433	0.65	10	0
6	rs2875742-rs4371861	2.31	16	1
8	rs10488368-rs1822243	3.01	18	1
15	rs2412456-rs7176579	11.17	173	3
Total		17.14 Mb	217	5

1
2
3
4
5 *Suppl. Figure S1: Biosynthesis of Chondroitin and Dermatan Sulfate.*
6

7 Synthesis of CS and DS starts with the formation of a tetrasaccharide linker region that attaches the GAG chains to a serine residue within the
8 conserved attachment sites of core proteins. The activity of Beta4 GalNac Transferase I, that transfers the first GalNac residue onto the
9 tetrasaccharide linker, starts a growing CS/DS chain, composed of alternating GlcA and GalNac disaccharide units. (Trowbridge and Gallo,
10 2002). In DS, GlcA is epimerised to IdoA, followed by sulfate addition to C-4 hydroxylgroup of the adjacent GalNac residue by D4ST-1,
11 thereby generating DS from CS. Loss of D4ST-1 activity will result in loss of this 4-O-sulfation lock, and will allow back epimerisation of IdoA
12 to GlcA, replacing DS by CS.
13
14
15
16
17
18
19
20
21
22
23
24
25
26
27
28
29
30
31
32
33
34
35
36
37
38
39
40
41
42
43
44
45
46
47
48
49

1
2
3
4
5
6
7
8
9
10
11
12
13
14
15
16
17
18
19
20
21
22
23
24
25
26
27
28
29
30
31
32
33
34
35
36
37
38
39
40
41
42
43
44
45
46
47
48
49



Suppl. Table S1:

CHST14 sequencing oligonucleotide primer pairs. Fragments 1 to 4 amplify the coding region whereas fragments 5 and 6 amplify the 3'UTR of the gene.

Amplicon	F primer sequence	R primer sequence	PCR mix	Annealing temperature
Fr1	GCCTGTGTCACTGCGAG	CCGCTCGATCATGAGCA	A	TD62-50
Fr2	CTGCCGTCCATGCTGAT	CTGCGGTGGTCCATCTT	A	TD62-50
Fr3	GAAGCGGGTGATGAAGGT	TCCAGCACCTGATTTGCAT	B	AT60
Fr4	CTTGTGCCGTGCACTATG	CTGTCCTCTGAGTCACTGT	B	TD62-50
Fr5	GGATCCTGGATGGCAGAG	TGGCAGGTGTAGGAAATTTGA	B	TD62-50
Fr6	CAGGACTAGAGTGAGCAATC	ACATCGAGGAGATCTGCTG	B	TD62-50

For mix A, PCR amplification was performed with 50ng genomic DNA, 0.6 μ M of each primer (oligonucleotide primer pairs (Invitrogen, Carlsbad, CA, USA) are listed in Supplementary Table 1), 0.12 mM dNTP mix (Invitrogen), and 1 unit of KAPA2G Robust HotStart DNA polymerase in 1 x KAPA2G Robust HotStart GC Buffer (Kapa Biosystems, Woburn, MA, USA).

For mix B, PCR amplification was performed with 50ng genomic DNA, 0.6 μ M of each primer (oligonucleotide primer pairs (Invitrogen) are listed in Supplementary Table 1), 1 mM MgCl₂, 0.12 mM dNTP mix (Invitrogen), and 0.5 units of KAPATaq HotStart DNA polymerase in 1 x KAPATaq HotStart Buffer (Kapa Biosystems, Woburn, MA, USA).

1
2
3
4
5 For TD62-50 thermal cycling conditions consisted of an initial denaturation step of 94°C for 4 minutes, 12 cycles of 94°C for 20s, 62°C for 15s,
6 and 72°C for 60s with a decrease in annealing temperature of 1°C each cycle, followed by 24 cycles of 94°C for 40s, 50°C for 40s, and 72°C for
7 30s, and a final extension at 72°C for 10 minutes.
8
9

10 For AT60 thermal cycling conditions consisted of an initial denaturation step of 94°C for 4 minutes, 32 cycles of 94°C for 20s, 60°C for 20s, and
11 72°C for 40s followed by a final extension at 72°C for 10 minutes.
12
13
14
15
16
17
18
19
20
21
22
23
24
25
26
27
28
29
30
31
32
33
34
35
36
37
38
39
40
41
42
43
44
45
46
47
48
49

1
2
3
4
5
6
7
8
9
10
11
12
13
14
15
16
17
18
19
20
21
22
23
24
25
26
27
28
29
30
31
32
33
34
35
36
37
38
39
40
41
42
43
44
45
46
47
48
49

Suppl. Table 2:

Summary of the clinical findings in the currently reported patients, and comparison with patients reported by Steinmann et al (Steinmann, et al., 1975; Steinmann, et al., 2002), Kosho et al (Kosho, et al., 2010), patients with typical EDS VIA, patients with ATCS (Dundar, et al., 2009) and patients with spondylocheiroadysplastic (SCD) EDS (Giunta, et al., 2008).

Abbreviations: AR: autosomal recessive; n.r.: not reported

Symbols: +: present; -: absent; †: deceased

	P1	P2	P3	(Steinmann, et al., 1975)	(Kosho, et al., 2010)	ATCS	EDS VIA	SCD-EDS
Inheritance pattern	AR	AR	AR	AR	AR	AR	AR	AR
CRANIOFACIAL								
Large fontanel	+	+	n.r.	n.r.	+ (5/5)	+ (7/7)	-	-
Brachycephaly	+	+	-	-	-	+ (7/7)	-	-
Flat face	+	+	-	-	+	+ (6/7)	-	-
low-set ears	+	+	+	-	+ (5/5)	+	-	-
Downslanting palpebral fissures	+	+	-	+	+ (6/6)	+ (7/7)	-	+ (3/6)
Telecanthus/hypertelorism	-	-	-	+	+ (6/6)	+ (7/7)	-	+ (1/6)
Short nose, hypoplastic columella	+	+	-	+ (1/2)	+ (6/6)	n.r.	-	-
Long philtrum, thin upper lip	+	+	-	-	+ (5/5)	+ (1/7)	-	-

Small mouth	+	+	-	+	+ (4/4)	-	-	-
High palate	+	+	+	+(1/2)	+ (6/6)	+ (3/7)	+	-
Dental crowding	+	+	-	-	-	-	-	-
Protruding jaw, pointed chin	+	+	-	-	+ (5/5)	-	-	-
CUTANEOUS								
Skin fragility/atrophic scars	+	+	+	+	+ (5/6)	-	+	+ (5/6)
Hyperextensibility	+	+	+	+	+ (6/6)	-	+	+ (6/6)
Thin, transparent	+	+	+	n.r.	+ (6/6)	+	+	+ (6/6)
Doughy, velvety	+	+	+	+	n.r.	n.r.	+	+ (4/6)
Easy bruising	+	+	+	+	+ (6/6)	+	+	+ (4/6)
Palmar wrinkling	+	+	+	+(1/2)	+ (6/6)	n.r.	-	+ (6/6)
Hyperalgesia to pressure	-	-	n.r.	+	+ (5/6)	-	-	n.r.
MUSCULOSKELETAL								
Kyphoscoliosis	+	+	+	+	+ (6/6)	+ (1/7)	+	-
Joint hyperlaxity	+	+	+	+	+ (6/6)	+ (5/7)	+	+ (4/6)
Dislocations	-	+	+	+(1/2) (hip)	+ (4/6)	+ (1/7)	+	+ (3/6)
Tapered fingers	+	+	+	+(1/2)	+ (6/6)	+ (7/7)	-	+ (6/6)
Joint contractures	+	+	+	-	+	+ (7/7)	-	+ (5/6)
Adducted thumbs	+	-	+	-	+ (5/6)	+ (7/7)	-	-
Clubfeet	+	+	+	+	+ (6/6)	+ (7/7)	+	+ (1/6)
Pectus deformity	+ flat	+ flat	-	+ flat	+ (6/6)	+ (2/7)	+	-
Muscle hypotonia	+	+	+	+	+	+ (mild 4/7)	+	-
CARDIOVASCULAR								

1
2
3
4
5
6
7
8
9
10
11
12
13
14
15
16
17
18
19
20
21
22
23
24
25
26
27
28
29
30
31
32
33
34
35
36
37
38
39
40
41
42
43
44
45
46
47
48
49

Valve abnormalities	-	-	-	-	+ (3/5)	+ (2/7)	-	-
OPTALMOLOGICAL								
Microcornea	-	+	-	+	+ (1/6)	-	+	+ (3/3)
Blue sclerae	-	+	+	+ (1/2)	+ (4/6)	+ (4/7)	+	+ (6/6)
Myopia	blind	+ (-14.5 diopters at 14 yrs)	+	+	+	-	+	+ (2/6)
Scleral/corneal fragility	-	-	-	-	-	-	+	-
Glaucoma	+	+	-	-	+ (3/6)	↑ IO pressure 2/7	+	-
Retinal detachment	+	+	-	-	+ (1/6)	-	+	-
OTHER								
Hearing impairment	+	+	-	-	+ (4/6)	+	-	-
Intestinal	Abdominal cramping	Abdominal cramping	malrotation with duodenal obstruction	-	Constipation (5/6) Diverticula perforation (1/6)	Absence of gastrocolic omentum, spontaneous volvulus of small intestine (1/7)	-	-
Genito-urinary	nephrolithiasis	Nephrolithiasis- renal ptosis with ureteral obstruction	-	Nephrolithiasis and hydronephrosis (1/2)	Nephrolithiasis (1/6) Urinary retention Cryptorchidism (1/2M)	Hydronephrosis (2/7) Nephrolithiasis (1/7) Horseshoekidney (1/7) Crytorchidism (4/4 M)	-	-
Other	-	Rupture abdominal	-	‡ (1/2)	Diastasis recti (1/6)	Cleft lip/ palate (2/7)	-	Platyspondyly Metaphyseal

1
2
3
4
5
6
7
8
9
10
11
12
13
14
15
16
17
18
19
20
21
22
23
24
25
26
27
28
29
30
31
32
33
34
35
36
37
38
39
40
41
42
43
44
45
46
47
48
49

		muscles diastasis recti				Diastasis recti (1/7) Contractures elbows/knees (1/7) Coarctatio aortae (1/7) ‡ (5/11)		broadening Thenar hypotrophy
--	--	----------------------------	--	--	--	---	--	------------------------------------

Or Peer Review