



**HAL**  
open science

## The use of CT derived solid modelling of the pelvis in planning cancer resections

J. Bruns, C.R. Habermann, W. Rütther, D. Delling

► **To cite this version:**

J. Bruns, C.R. Habermann, W. Rütther, D. Delling. The use of CT derived solid modelling of the pelvis in planning cancer resections. *EJSO - European Journal of Surgical Oncology*, 2010, 36 (6), pp.594. 10.1016/j.ejso.2009.11.005 . hal-00599231

**HAL Id: hal-00599231**

**<https://hal.science/hal-00599231>**

Submitted on 9 Jun 2011

**HAL** is a multi-disciplinary open access archive for the deposit and dissemination of scientific research documents, whether they are published or not. The documents may come from teaching and research institutions in France or abroad, or from public or private research centers.

L'archive ouverte pluridisciplinaire **HAL**, est destinée au dépôt et à la diffusion de documents scientifiques de niveau recherche, publiés ou non, émanant des établissements d'enseignement et de recherche français ou étrangers, des laboratoires publics ou privés.

# Accepted Manuscript

Title: The use of CT derived solid modelling of the pelvis in planning cancer resections

Authors: J. Bruns, C.R. Habermann, W. R  ther, D. Delling

PII: S0748-7983(09)00513-7

DOI: [10.1016/j.ejso.2009.11.005](https://doi.org/10.1016/j.ejso.2009.11.005)

Reference: YEJSO 2916

To appear in: *European Journal of Surgical Oncology*


Received Date: 9 April 2009

Revised Date: 6 November 2009

Accepted Date: 9 November 2009

Please cite this article as: Bruns J, Habermann CR, R  ther W, Delling D. The use of CT derived solid modelling of the pelvis in planning cancer resections, *European Journal of Surgical Oncology* (2009), doi: 10.1016/j.ejso.2009.11.005

This is a PDF file of an unedited manuscript that has been accepted for publication. As a service to our customers we are providing this early version of the manuscript. The manuscript will undergo copyediting, typesetting, and review of the resulting proof before it is published in its final form. Please note that during the production process errors may be discovered which could affect the content, and all legal disclaimers that apply to the journal pertain.



**The use of CT derived solid modelling of the pelvis in planning cancer resections.**

J. Bruns<sup>\*</sup>, C.R. Habermann<sup>#</sup>, W. Rüter<sup>§</sup>, D. Delling<sup>¶</sup>

<sup>\*</sup> Dept. of Orthop. Surgery, Diaconial Hospital Hamburg, Germany

<sup>#</sup> Dept. of Diagnostic & Interventional Radiology, University Hospital of Hamburg, Germany

<sup>§</sup> Dept. of Orthop. Surgery, University of Hamburg

<sup>¶</sup> Institute of pathology, neuropathology and molecular pathology, Hannover, Germany

**Acknowledgment:** We thank Mrs. Dawson for the translation and correction into English language.

**Abstract:**Clinical problem:

Resection of malignant tumors of the pelvis is demanding. To avoid disabling hemipelvectomies, years ago internal hemipelvectomy combined with partial pelvic replacements had become a surgical procedure. To achieve adequate reconstructions custom-made replacements were recommended. In early stages of the surgical procedure using megaprotheses, individual pelvic models were manufactured.

Aim of the study:

Since little is known about the accuracy of such models we analysed the charts of 24 patients (25 models) for whom an individual model of the osseous pelvis had been manufactured.

Results:

Two patients refused surgery. In 23 patients partial resection of the bony pelvis was performed followed by a partial pelvic replacement (13 x), hip transposition procedure (5 x), ilio-sacral resection (4 x), or revision surgery.

In all patients who received a partial pelvic replacement, the fit of the replacement was optimal. No major unplanned resection was necessary.

The same was observed in patients who received a hip transposition procedure or an ilio-sacral resection.

Oncologically, in most of the patients we achieved wide resection margins (14 x). In 5 patients the margins were marginal (4x) or intralesional (1 x).

In two cases the aim was a palliative resection because of a metastatic disease (1x) or benign entity (1 x).

Conclusion:

Pelvic models are helpful tools to planning the manufacture of partial pelvic replacements and ensuring optimal osseous resection of the involved bone. Further attempts have to be made to evaluate the aim of navigational techniques regarding the accuracy of the osseous and soft tissue resection.

**Introduction:**

Owing to the complex anatomical situation, operative procedures involving the osseous pelvis as well as the sacrum present a great challenge to the orthopaedic surgeon(1-4). This applies in particular to oncological operations in which a false preparation of the soft parts of the pelvis and an incorrect osteotomy can have far-reaching consequences regarding the oncological quality of resection and thus the long-term survival of the patients (1-3, 5-7).

Historically regarded, oncological operations of the osseous pelvis are a relatively new procedure. To our knowledge, the first internal hemipelvectomy (IHP) combined with a partial pelvic replacement was performed in Germany in 1978/79 (8,9). First attempts to excise such tumors were reported by Enneking 1966 (10) and Steel 1978(11).

Compared to the present, the planning tools and imaging techniques used at that time seem archaic: magnetic resonance tomography (MRI) did not exist and computer tomography (CT) was a rather new technique. In the meantime, both diagnostic procedures have greatly improved and it has long since been possible to define the exact extent of a tumor and, in particular, its relation to functionally important structures such as the nerves and the blood vessels as well as to the intestinal organs.

Owing to new diagnostic procedures and the option of improving the manufacture of custom-made partial pelvic replacements (PPR) using

individual pelvic models, the performance of three-dimensional pelvic operations has also greatly improved.

The aim of this paper is to report on results gained from the preoperative planning and performance of pelvic resections followed by a PPR implementing the above-mentioned pelvic models.

## **Materials and Methods**

### **Aim of the study**

We analysed the charts of those patients for whom a pelvic model was manufactured either for planning a PPR or a hip transposition procedure (HTP) or for another pelvic resection. The intraoperative fit of the PPR was approved in the operation report, e.g. if an additional resection to achieve an optimal fit was necessary, and in the postoperative X-ray. The oncological quality was assessed on the re-sected tissue by the pathologist.

### **Manufacture of the pelvic models**

The data necessary for the construction of the models were acquired with CT.

Using these data the individual pelvic model was then constructed by the manufacturer (W. Link, Hamburg, Germany; ESKA Implants, Luebeck, Germany, or Implantcast, Buxtehude, Germany).

In principle, two different technological methods were employed:

The model was cut out of a block of polyurethane or was constructed from a liquid polymer which had been hardened layer by layer under an ultraviolet lamp.

#### Preoperative planning of the resection

The resection was preoperatively planned by means of CT and MRI images. The bony line of resection was defined on the pelvic model using the osseous anatomical landmarks such as the anterior superior or inferior spine, the posterior superior or inferior spine, or the pubic symphysis. The definite line of resection was then defined by measuring the distance from the above-mentioned anatomical landmarks.

Depending on the anatomical extent of the tumor according to the classification of Enneking & Dunham 1978 (12), in most of the cases a PI or PII resection with a horizontal osteotomy in the iliac bone was performed for the cranial osteotomies. In a few cases a vertical resection of the os ilium according to a P I or PI/IV was necessary.

The osteotomies performed in other parts of the bony pelvis such as the superior or inferior ramus of the os pubis or os ischium did not need to be accurate in the millimeter dimension because these areas of the bony pelvis were not needed for implantation of any part of the PPR.



## Results

### Patients data

During the period 1995 to 2004, 25 pelvic models were constructed preoperatively for the planning of operations in 24 patients. The operations were performed in the Department of Orthopaedic Surgery in the University Hospital Hamburg by one surgeon (J.B.). Three patients refused surgery. Thus, in 21 patients surgical resection of parts of the bony pelvis was performed followed by either a partial pelvic replacement (13 x PPR), hip transposition (5 x HTP), ilio-sacral resection (3 x ISR), ilio-sacral revision and PPR exchange surgery (1 x).

In all patient who received a PPR the fit of the replacement was optimal, in none of them a major unplanned resection was necessary (Fig.1). The same was observed in all patients who received a HTP transposition or an ISR or the revision surgery.

### Oncological data

Oncologically, in most of the patients we achieved wide resection margins (14x). In only 5 patients the margins were marginal (4x) or intralesional (1x). In two cases the aim was a palliative resection because of a metastatic disease or benign entity (1x).

In one of the patients, a second pelvic model had to be constructed following an ilio-sacral resection and reconstruction using a fibula graft

and spine instrumentation system, this being necessitated by a fracture of the primary fibular implant in order to facilitate better three-dimensional orientation.

Almost all operations had been performed for oncological reasons and had aimed at achieving a “wide resection”. Epidemiological data and the diagnoses are presented in Table 1. In one patient, the indication for a PPR was not related to a tumor but to material breakage ten years after an initial PPR owing to a solitary metastasis. The implantation of a new PPR was carried out.

The oncological resection areas and the achieved margins of resection are listed in Table 2. Table 3 lists the intraoperative procedures: Out of 25 patients, 3 refused surgery, in the remaining 23 patients surgery was performed.

#### Accuracy of the pelvic models

In all patients who received a PPR after an IHP (13 x), an optimal fit of the pelvic implant into the remaining bone was achieved. This means, no major unplanned additional bony resection was necessary. Even in the patients in whom the exchange of the PPR was performed, the fit was optimal.

In the patients in whom a hip transposition procedure (HTP) (5 x) was performed, the fit of the transposed proximal femur to the remaining part of

the pelvis was not a problem since this procedure does not need the accuracy that a PPR requires.

The benefit of the pelvic model in the two patients with an ilio-sacral resection (3 x ISR) was that it enabled better understanding of the line of resection, particularly in the ilio-sacral region. For the reconstruction using fibular grafts and spinal instrumentation systems, there was no need for an optimal fit as with a PPR.

However, in one case with breakage of the instrumentation and the implanted fibular grafts, a newly-produced pelvic model allowed more insight into the ilio-sacral area even after tumor resection.

#### Quality of resection

Oncologically, in most of the patients, an adequate resection, i.e. a resection with at least wide margins (14 x), was performed: e.g. in all patients who had an IHP followed by a PPR. In two of the patients in whom a HTP was carried out after an IHP, the resection was marginal and, in one of those with an ilio-sacral resection, the tumor had already spread into the spinal canal so that only an intralesional resection could be achieved (Table 2). In 3 cases the resection was palliative because of the metastatic character of the disease.

## Discussion

### History of pelvic surgery and partial pelvic replacement

When one considers the present level of technology for the planning and performance of complex surgeries of the bony pelvis, it would seem particularly heroic under what conditions the first of these IHP's followed by a PPR were carried out (8-11,13,14).

Without an MRI or pelvic model, it was only possible to roughly plan an individual PPR based on X-rays and CT-scans. Although the use of pelvic models had already been reported by Tonner & Engelbrecht (14), in the first cases with a PPR and IHP, a fit to the bony line of resection was achieved in stages since the modular technology did not exist. The optimal fit of a custom-made prosthesis could be accomplished since, intraoperatively, the PPR was adapted step-by-step to the extent of the bony resection and corrected by the orthopaedic workshop (9). At that time, a correct fit of the prosthesis was not the main problem because fixation of the PPR was achieved with horizontal screws which secured the fixation arms of the PPR to the remaining part of the os ileum.

Thus, the oncological quality of a resection, whether radical or wide versus marginal or even intralesional, was rather compromised (1,6,15,16).

In 1997 Abudu et al. (1) reported a series of 35 patients who received a prosthesis. In the first 17 patients the operative procedure was performed in two steps, in the remaining 18, a one-step-procedure was carried out. In the

two-step-procedure the resected specimen and a cast made of the cut iliac surface were used as templates to manufacture the custom-made pelvic prosthesis which was implanted six weeks later. In the one-step procedure, the custom-made prosthesis was manufactured on the basis of radiographs and 3-dimensional reconstructions.

The procedure was rapidly improved by means of a pelvic model (14,17, 18) but CT-technology was still in its early days. In 1999 Handels et al. (19) reported on virtual three-dimensional models for the computer-assisted planning and simulation of hip operations for oncological purposes.

The current technology used in producing an individual 3-D pelvic model bases on CT-data from the bony pelvis. The line of resection can be determined on such a model as described above. Thus, an individual PPR with an acceptable accuracy needed for a good fit to the remaining part of the pelvic bone can be produced.

Although the use of individual pelvic models had already been mentioned by Burri and other authors et al. (8,14), to our knowledge, Guarino et al. in 2007 (20) were the first to mention the particular advantages of such rapidly prototyped models in pediatric spinal and pelvic operations, e.g. the improvement of preoperative planning, intraoperative orientation and navigation and the reduction of operating time. But, the authors did not give exact data regarding the accuracy and oncological results.

Thus, to our knowledge, our paper is the first to report on surgical and oncological results regarding such pelvic models. We believe that the results described here are very promising despite the generally high complication rate of pelvic tumor resections (1,3,6,15,16).

Also, our oncological data are acceptable and are in the range of those reported previously (1,3,6,15,16) or even better.

Current status of pelvic reconstruction

Meanwhile, the technology of reconstruction has changed towards a modular PPR allowing a better intraoperative adaptation to improve the position of the socket and thus improve the off-set for an optimal function of the hip replacement. The construction of an individual pelvic model using available CT data is the standard method used today in the planning of oncological pelvic operations (3).

Completion of the model takes only a few days and the achieved accuracy of the fit is optimal.

Despite this modern technology, the surgeon still has the intraoperative problem of finding the anatomical landmarks that mark the starting-point of the resection on the model. Until now, identification and marking of the landmarks and marking of the resection line has been done with Kirschner wires.

### Aspects for the future

It is to be expected that the intraoperative navigation technology, which has already been comprehensively employed in conventional total hip replacements (21), in some trauma cases (22) and in a few tumor cases (23,24), will bring about an improvement of tumor-resection procedures in the pelvis.

Some first experiences regarding the osseous part of resection have already been published (23,24). However, the navigation technology for determination of the oncologically correct line of resection of the soft-tissue part of the tumor is still not advanced enough but is currently being improved (25). Despite the new planning technology, this type of pelvic intervention is still extremely complicated (1-3,6,16) and demands a high level of concentration, stamina and perseverance from the operating team. So, it is recommended that such surgeries should only be performed in specialised oncologiccal centres (1-3).

It is possible that the combined employment of pelvic models and navigation technology will help to reduce the length of the operation and thereby the high quotient of infections.

### **Conflict of interest**

The authors state that they have no conflict of interest.

## References:

1. Abudu A, Grimer RJ., Cannon SR., Carter SR., Sneath RS. Reconstruction of the hemipelvis after the excision of malignant tumours. *J Bone Joint Surg (B)* 1997;79-B:773-779.
2. Grimer RJ, Carter SR, Tillman RM, Spooner D, Mangham DC, Kabukcuoglu Y. Osteosarcoma of the pelvis. *J Bone Joint Surg (B)* 1999;81-B:796-802.
3. Tunn PU, Fehlberg S, Andreou D, Kettelhack C. Stellenwert der Becken-endoprothetik in der operativen Therapie von Tumoren des knöchernen Beckens. *Z Orthop Unfall* 2007;145:753-759.
4. Hoffmann C, Gosheger G, Gebert C, Jürgens H, Winkelmann, W. Functional Results and Quality of Life after Treatment of Pelvic Sarcomas Involving The Acetabulum. *J Bone Joint Surg (A)* 2006;88-A:575-582.
5. Matsuo T, Sugita T, Sato K, Hotta T, Tsuchiya H, Shimose S, Kubo T, Ochi M. Clinical outcome of 54 pelvic osteosarcomas registerd by Japanese musculoskeletal oncology group. *Oncology* 2005;68:375-381.
6. Ozaki T, Hillmann A, Lindner N, Blasius S, Winkelmann W. Chondrosarcoma of the pelvis. *Clin Orthop* 1997;337:226-2239.
7. Ozaki TH, Hoffman C, Hillmann, A, Gosheger G, Lindner N, Winkelmann W. Implantation of Hemipelvic Prosthesis After Resection of Sarcoma. *Clin Orthop* 2002;396:197-205.
8. Burri C, Claes L, Gerngroß H, Mathys R jun. Total "Internal" Hemipelvectomy. *Arch Orthop Trauma Surg* 1979;94:219-226.
9. Dahmen G, Heise U. Alloplastischer Beckenteilersatz mit Hüftgelenk und proximalem Femur. *Z. Orthop* 1985;123:265-272.
10. Enneking WF. Local resection of malignant lesions of the hip and pelvis. *J Bone Joint Surg (A)* 1966;48-A:991-1007.
11. Steel HH. Partial or complete resection of the hemipelvis. An alternative to hindquarter amputation for periacetabular chondrosarcoma of the pelvis. *J Bone Joint Surg (A)* 1978;60-A:719-730.
12. Enneking WF, Dunham WK. Resection and reconstruction for primary neoplasms involving the innominate bone. *J Bone Joint Surg (A)* 1978;60-A:731-746.
13. Burri C, Schulte J. Beckentumoren. *Langenbecks Arch Chir* 1980;352:465-469.
14. Tonner HD, Engelbrecht H. A new method for the preparation of special alloplastic implants for partial replacement of the pelvis. *Fortschr Med* 1979;26:781-783.
15. Capanna R, van Hoorn JR, Guernelli N, Briccoli A, Ruggieri P, Biagini R, Bettelli G, Campanacci M. Complications of pelvic resections. *Arch Orthop Trauma Surg* 1987;106:71-77.
16. Bruns J, Luessenhop SL, Dahmen G sen. Internal hemipelvectomy and endoprosthetic pelvic replacement: long-term follow-up results. *Arch Orthop Trauma Surg* 1997;116:27-31.
17. Gerngross H, Burri C, Claes L, Eckardt V. Possibilities of geometric X-ray examination of the pelvis for partial pelvis replacement. *Z. Orthop* 1980;118:331-336.
18. Gradinger R, Rechl H, Ascherl R, Plötz W, Hipp E. Endoprothetischer Teilersatz des Beckens bei malignen Tumoren. *Orthopäde* 1993;22:167-173.
19. Handels H, Ehrhardt J, Plötz W, Pöpl SJ. Computer-assisted planning and simulation of hip operations using virtual three-dimensional models. *Stud Health Technol Inform* 1999;68:686-689.
20. Guarino J, Tennyson S, McCain G, Bond L, Shea K, King H. Rapid prototyping technology for surgeries of the pediatric spine and pelvis: benefits analysis. *J Pediatr Orthop* 2007;27:955-960.



21. Kalteis T, Handel M, Bächli H, Perlick L, Tingart M, Grifka J. Imageless navigation for insertion of the acetabular component in total hip arthroplasty: is it as accurate as CT-based navigation? *J Bone Joint Surg (B)* 2006;88-B:163-167.
22. Oszwald M, Citak M, Kendoff D, Kowal J, Amstutz C, Kirchoff T, Nolte LP, Krettek C. Accuracy of navigated surgery of the pelvis after surface matching with an a-mode ultrasound probe. *J Orthop Res* 2008;26:860-864.
23. Hüfner T, Geerling J, Gänsslen A, Kendoff D, Citak C, Grützner P, Krettek C. Rechnergestütztes Operieren bei Beckenverletzungen. *Chirurg* 2004;75:961-966.
24. Wong KC, Kumta SM, Chiu KH, Antonio GE, Unwin P, Leung KS. Precision tumour resection and reconstruction using image-guided computer navigation. *J Bone Joint Surg (B)* 2007;89-B:943-947.
25. Chopra SS, Hünerbein M, Eulenstein S, Lange T, Schlag PM, Beller S. Development and validation of a three dimensional ultrasound based navigation system for tumor resection. *Europ J Surg Oncol* 2008;34:456-461.

Legends of the figures:

Fig.1a: MRI of the pelvis exhibiting the exact extend of the tumor

Fig.1b: Pelvic model before planned resection

Fig.1c: Pelvic model after after planned resection

Fig.1d: Postop. X-ray

ACCEPTED MANUSCRIPT

Table 1

**Indication for manufacturing the pelvic models:****24 patients with pelvic tumors 25 pelvic models**

- 13 male, 11 female; Age: 57.4 yrs (25-69)
- 8 x Chondrosarcoma
- 5 x Ewing-Sarcoma-Group
- 4 x Osteosarcoma
- 1 x Angiosarcoma
- 2 x malignant fibrous histiocyoma (MFH)
- 1 x malignant peripheral nerve-sheath-tumor (MPNST)
- 1 x radiogenes sarcoma
- 1 x benign nerve-sheath-tumor
- 1 x breakage PPR (implanted 10 yrs before)

## Table 2

### **23 surgeries**

- **21x tumor surgeries,**
- **1x PPR-exchange**
- **1x revision surgery**

### **Area of resection (Enneking):**

- **10x I-II**
- **8x II\***
- **4x II-III**

### **Quality of resection (Enneking):**

- **14 x wide**
- **4 x marginal**
- **1 x intralesional (Angiosarkom, sacral spine)**
- **1 x palliativ (radiogenic sarcoma)**
- **1 x benign tumor**

**\*: exchange of a 10 yrs previously implanted PPR**

Table 3

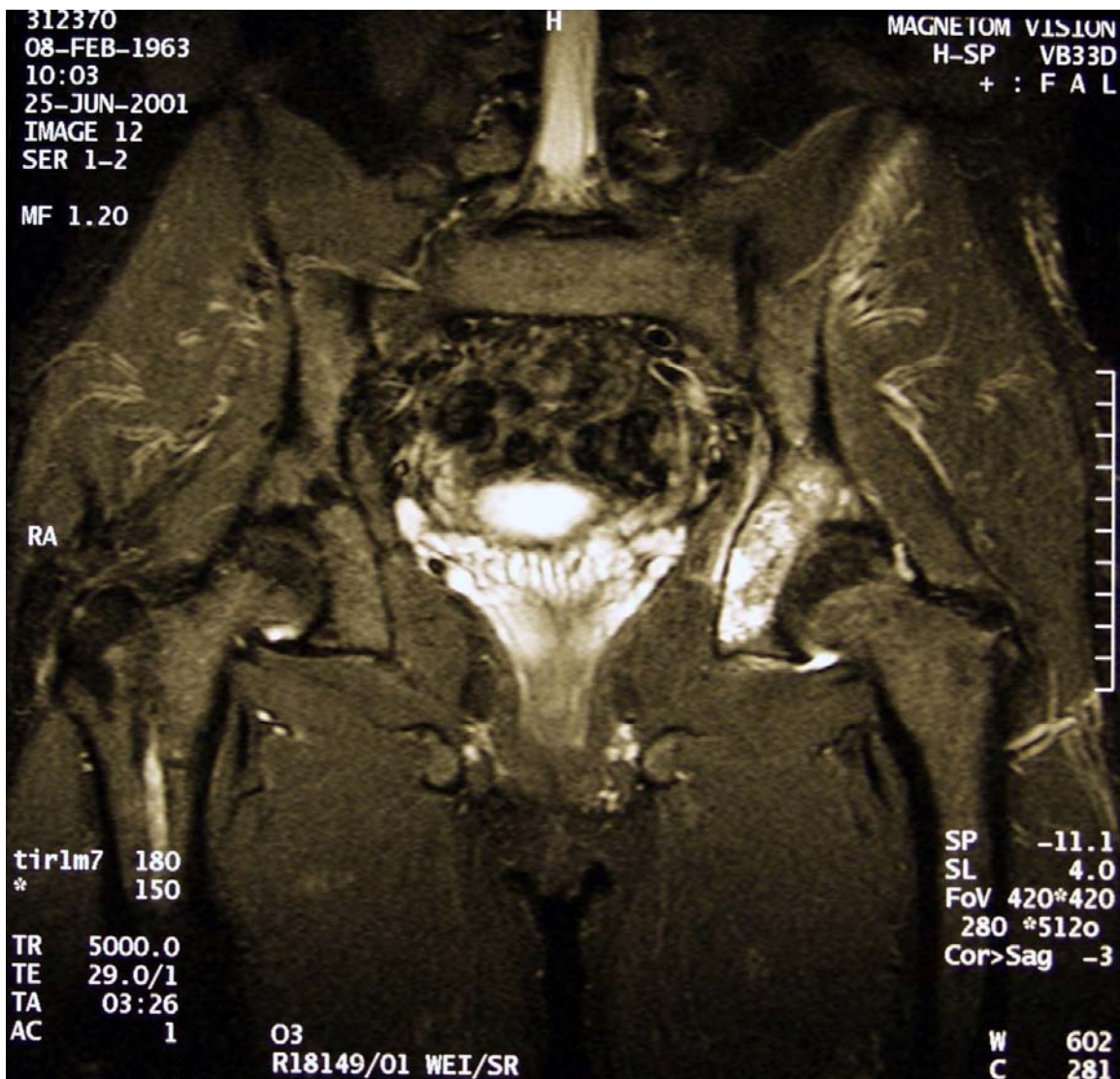
**18 patients with IHP + PPR or HTP (1 Surgeon)**

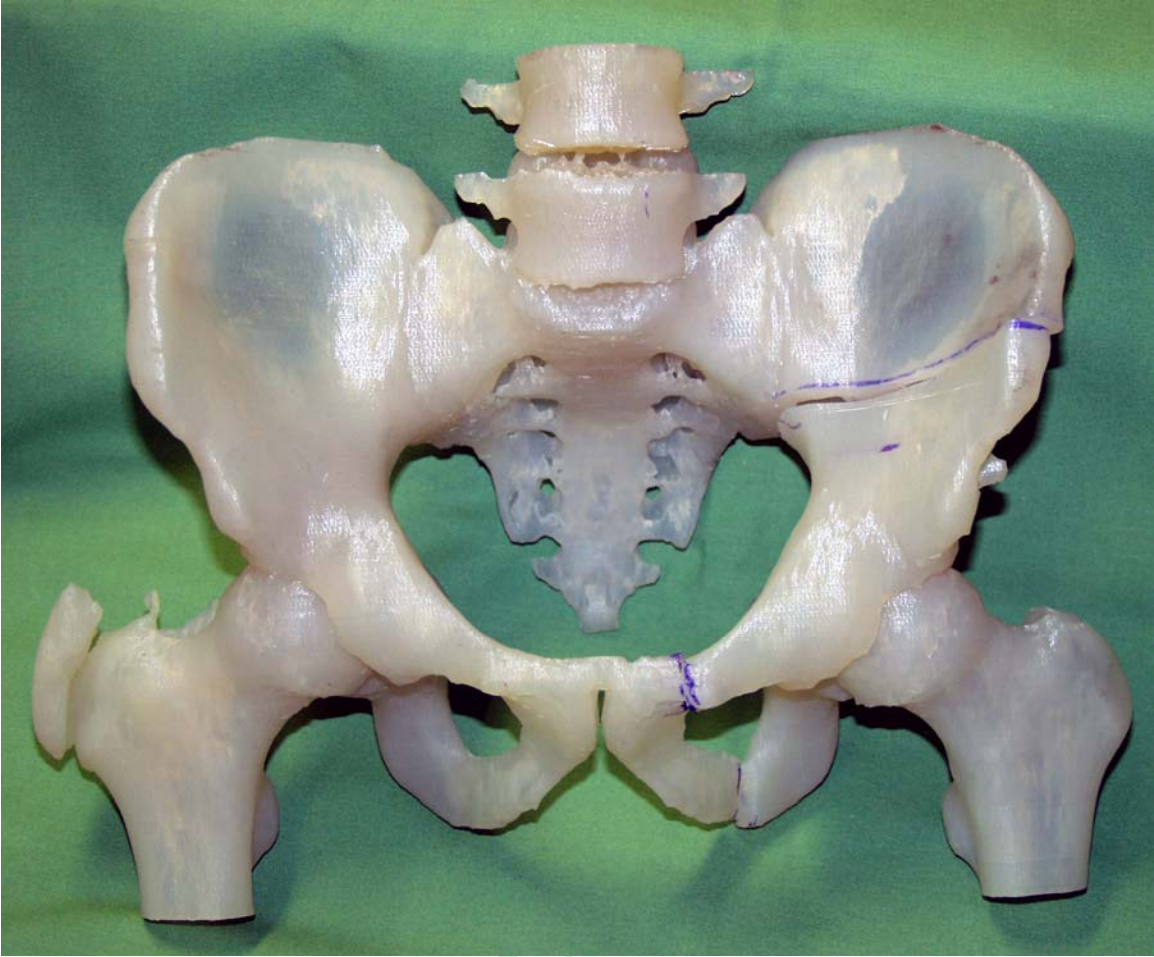
- 13 x IHP + PPR: all optimal fit
- 5 x IHP + HTP: all optimal fit
- 3 x Ilio-sacral resection: wide (1) / intralesional res.  
(1)
- 1 x PPR exchange (no resection necessary):  
optimal fit

-----

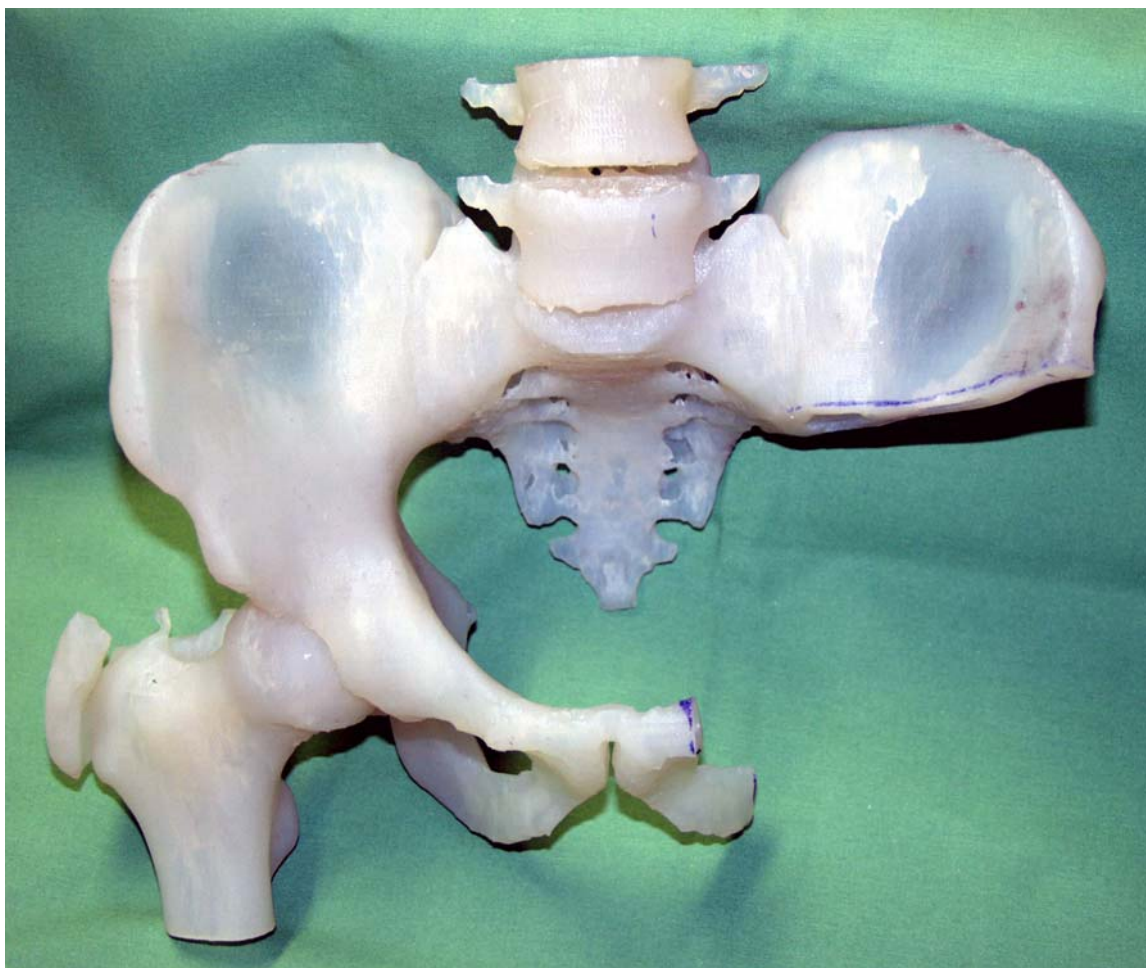
**3 pats.: Refusal of surgery**

- 1 pat. (MFH) Tumor progress during manufacturing
- 2 Pat. no surgery:
  - 1 psychiatr. Disease,
  - 1 refusal of surgery due to the bad prognosis





ACCEPTED



ACCEPTED



