



HAL
open science

Lymphogranuloma venereum proctocolitis: a silent endemic disease in men who have sex with men in industrialised countries

R. Martin-Iguacel, J. M. Llibre, H. Nielsen, E. Heras, L. Matas, R. Lugo, B. Clotet, G. Sirera

► **To cite this version:**

R. Martin-Iguacel, J. M. Llibre, H. Nielsen, E. Heras, L. Matas, et al.. Lymphogranuloma venereum proctocolitis: a silent endemic disease in men who have sex with men in industrialised countries. *European Journal of Clinical Microbiology and Infectious Diseases*, 2010, 29 (8), pp.917-925. <10.1007/s10096-010-0959-2>. <hal-00596612>

HAL Id: hal-00596612

<https://hal.science/hal-00596612v1>

Submitted on 28 May 2011

HAL is a multi-disciplinary open access archive for the deposit and dissemination of scientific research documents, whether they are published or not. The documents may come from teaching and research institutions in France or abroad, or from public or private research centers.

L'archive ouverte pluridisciplinaire **HAL**, est destinée au dépôt et à la diffusion de documents scientifiques de niveau recherche, publiés ou non, émanant des établissements d'enseignement et de recherche français ou étrangers, des laboratoires publics ou privés.



HAL Authorization

Lymphogranuloma venereum proctocolitis: a silent endemic disease in men who have sex with men in industrialised countries

R. Martin-Iguacel · J. M. Llibre · H. Nielsen · E. Heras ·
L. Matas · R. Lugo · B. Clotet · G. Sirera

Received: 17 January 2010 / Accepted: 6 May 2010 / Published online: 28 May 2010
© Springer-Verlag 2010

Abstract Lymphogranuloma venereum (LGV) is a sexually transmitted disease (STD) caused by serovars L1–L3 of *Chlamydia trachomatis*. Rare in the western world prior to 2003, different outbreaks or clusters of LGV have been reported in Europe, North America and Australia among men who have sex with men (MSM) over the past few years. The majority were HIV infected MSM with high-risk sexual behaviour and a high rate of concomitant STD, including hepatitis C. Most of them presented with a proctitis syndrome and only a few with the classical bubonic form. A previously non-described serovar, L2b, has been identified as the main causative agent of the epidemic. A delay in diagnosis has been the rule because of the misleading symptomatology of LGV proctitis, the unfamiliarity of the disease to physicians, and the lack of a routine diagnostic test for LGV serovars. It is crucial to

increase the awareness of the disease among physicians for prompt diagnosis and treatment, to avoid complications, and to stop ongoing transmission. It has additional public health implications since LGV may facilitate the transmission and acquisition of HIV and other STD.

Introduction

Lymphogranuloma venereum (LGV) is a systemic sexually transmitted disease (STD) caused by serovars L1, L2 and L3 of the obligate intracellular bacterium *Chlamydia trachomatis*. *C. trachomatis* is classified into 15 serovars based on immunogenic epitope analysis of the major outer membrane protein. Serovars A, B, Ba and C are associated with ocular trachoma and strains D–K with genital tract disease and with inclusion conjunctivitis, and represent the most frequent STD in industrialised countries. Only serovars L1, L2 and L3 cause LGV, probably due to their tropism for the lymphatic system, in contrast to serovars A–K, which affect mucocutaneous tissue. The L2 serovar can be further classified into L2, L', L2a and L2b, and the recently described L2c–L2g according to amino acid differences [1, 2].

Endemic in Africa, the Caribbean and many parts of Asia, prior to 2003 LGV was considered rare in industrialised countries and the sporadic cases seen were deemed to be imported from endemic areas. In 2003 a cluster of LGV with a new strain, L2b, was detected in Rotterdam, the Netherlands, among men who have sex with men (MSM) presenting mainly as proctitis [3]. Since then many countries all across Europe, North America and Australia have reported clusters of cases in sexual networks of MSM with a total of over 1,600 cases of proctitis reported so far [1, 2, 4–19].

R. Martin-Iguacel (✉) · H. Nielsen
Department of Infectious Diseases,
Aalborg Hospital, Aarhus University Hospital,
Hobrovej 18, P. O. Box 365, DK9100 Aalborg, Denmark
e-mail: raquel@bisaurin.org

R. Martin-Iguacel · J. M. Llibre · E. Heras · B. Clotet · G. Sirera
Lluita contra la SIDA Foundation,
University Hospital Germans Trias I Pujol,
Barcelona, Spain

L. Matas
Microbiology, University Hospital Germans Trias I Pujol,
Barcelona, Spain

R. Lugo
CEEISCAT, University Hospital Germans Trias I Pujol,
Barcelona, Spain

B. Clotet
Irsi-Caixa Foundation,
Barcelona, Spain

The majority of patients were HIV-infected with high rates of promiscuity and high-risk sexual behaviour, often involving international sexual networks, which correlates with the high rate of concomitant STD observed.

The atypical clinical presentation, the unawareness of physicians and patients with regard to the disease, and the lack of a routine diagnostic test for LGV serovars of *C. trachomatis* have conditioned a delay in the diagnosis and even misdiagnosis.

The untreated disease is associated with significant sequelae with chronic inflammation of the lymphatic vessels, progressive lymphoedema and sclerosing fibrosis leading to fistula formation and strictures and disfiguring conditions such as genital elephantiasis and esthiomene [20].

The current resurgence of LGV represents furthermore a significant public health problem as the ulcerative nature of LGV may facilitate both transmission and acquisition of HIV infection and other STD as well as other blood-borne diseases like hepatitis C [21].

It is therefore critical to increase the awareness of the re-emergence of this disease among health care professionals in industrialised countries for prompt diagnosis and appropriate treatment. It is important to highlight that specific diagnostic tests not routinely used are required to allow the diagnosis of LGV infections.

This review addresses the characteristics of the present recurrence of LGV proctocolitis in MSM in high-income, non-tropical settings.

Materials and methods

This review used a systematic search in the literature using PubMed. The incorporating criteria were “*Chlamydia trachomatis*”, “*Lymphogranuloma venereum*”, “*homosexual male*”, “*men who have sex with men*” and “*proctitis*”. The search was restricted to the period 1990–2009 and only those series reporting more than 5 patients were included in the present review. A total of 25 studies were identified.

Epidemiology

Lymphogranuloma venereum was endemic in Europe and the US in the pre-antibiotic era, but thereafter only sporadic cases were seen in the western world, and all were considered to be imported [22, 23]. However, in the 1980s some clusters of LGV in MSM presenting as proctitis were reported in industrialised, non-tropical areas [24, 25]. The estimates of incidence are difficult to ascertain, as LGV was not a mandatory reportable disease in most countries. It is still currently endemic in parts of Africa, South East Asia, South America and the Caribbean.

In February 2003 the first case of LGV proctitis in Europe was detected in a recently infected HIV-positive bisexual white man who presented with a painful perianal ulcer, bilateral inguinal lymphadenitis and general malaise in Rotterdam, the Netherlands (NL) [26]. Subsequently, a cluster of 13 MSM with LGV serovar L2 was detected through contact tracing [3], most of whom were HIV-positive. They presented with a median duration of 3 months of unspecific intestinal symptoms and 46% had another concomitant STD [1–10]. Several outbreaks in MSM have so far been reported in Western Europe, Australia and the USA, clustering in large cities [2, 4–15, 27–32].

A total of 232 cases of LGV proctitis had been recorded in the NL by March 2007 [15]. Previously, the NL had an incidence of LGV of fewer than 5 cases per year. In the UK a total of 492 cases had been recorded by April 2007, in France 244 cases by December 2005, in Germany 78 by November 2005 and in Sweden 20 cases by December 2007, of which 15 were detected in 2007 [4, 7, 16, 33]. In Canada there were 88 cases by September 2007 [28]. The first case of LGV in Barcelona was reported in an MSM in 2005 and as of April 2009 a total of 42 confirmed cases had been reported in Catalonia, an autonomous community in the north-east corner of the Iberian Peninsula with a population of around 7 million (Fig. 1).

In all these countries LGV proctitis has been described nearly exclusively in MSM most of whom were HIV-infected, but typically not immunosuppressed, and some had seroconverted to HIV at around the time of the LGV diagnosis [3, 6, 33]. The epidemic might be expanding beyond the initial core group of high-risk MSM [1, 34], even though the detection of LGV in the general population has not been confirmed in other studies [9, 35, 36]. The majority reported high-risk sexual behaviour including unprotected anal intercourse, fisting, sharing sex toys, often connected to the sex party scene and involving international sexual networks [3]. In a cross-sectional study the use of enemas was found to be associated with a higher risk of LGV proctitis, probably because such a procedure leads to mucosal damage before receptive anal intercourse favouring the transmission of the disease [37].

Contact tracing was difficult as most cases reported multiple, mainly anonymous sexual contacts.

The HIV-1 infection has been identified as the strongest risk factor for anorectal LGV [3, 38]. MSM have not been confirmed to be a reservoir of LGV and the high rate of HIV co-infection probably reflects the confounding effect of HIV as a surrogate marker of high-risk behaviour; nevertheless, a potential effect of HIV infection increasing the susceptibility to infection or facilitating the expression of the disease cannot be ruled out [2, 39–41].

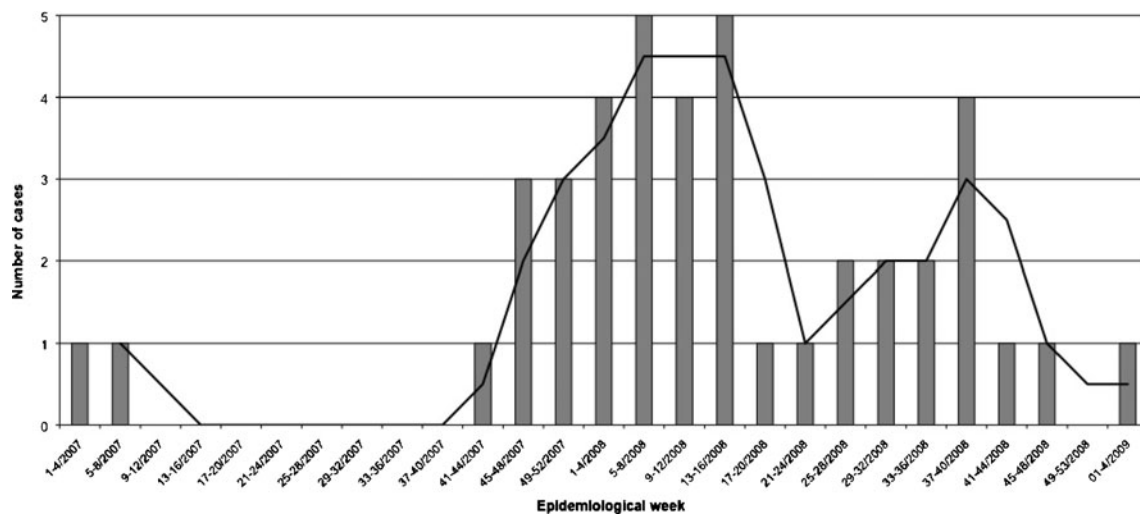


Fig. 1 Distribution of confirmed cases of lymphogranuloma venereum (LGV) by date of consultation, Catalonia (Spain), January 2007 to April 2009 (Source: CEEISCAT)

Since the introduction of highly active anti-retroviral therapy an increase in unprotected sexual practices has been observed worldwide among both HIV-positive and -negative MSM, which could have contributed to facilitating the spread of LGV in this core group. During the 1980s the Bahamas registered a sequential epidemic of crack cocaine use, genital ulcer-inguinal adenopathy disease (including bubonic LGV) and HIV infection in heterosexuals related to unsafe sexual behaviours [42].

It seems unlikely that LGV constitutes an opportunistic infection involving immunosuppressed HIV-infected patients, and studies have failed to detect a significant asymptomatic reservoir in the general population [9, 35, 36].

On the other hand, the ulcerative nature of LGV could enhance transmission and acquisition of HIV and other STD, as well as other blood-borne diseases like hepatitis C as indicated by the high co-prevalence of STD observed in these patients. Although hepatitis C is not usually considered a STD it has been consistently reported to be sexually transmitted among MSM, especially with high-risk sexual practices that lead to mucosal damage [21].

Almost all patients presented with long-lasting gastrointestinal symptoms and were initially misdiagnosed, which increased the risk of transmission. In some series there was a significant group with no or few symptoms, which could suggest that the number of cases reported might underestimate the real disease occurrence [37, 38].

A previously non-described L2b *Chlamydia* variant has been identified as the main causative agent [11, 27, 30, 43, 44]. Nevertheless, this variant seems to have been circulating in the NL since 2000 (no earlier samples were available) and has also been detected retrospectively in rectal samples from symptomatic MSM collected from 1979 to 1985 in San Francisco (LGV represented 13% of

the collected samples and 67.3% of the *C. trachomatis*-positive samples) [45]. This fact could support the hypothesis proposed by some authors of the existence of an ongoing unrecognised endemic disease among MSM for at least 20 years rather than a new outbreak [45, 46]. However, other countries have not confirmed the retrospective detection of undiagnosed cases in stored samples [8, 39, 47].

The existence of an unrecognised endemic disease could also be supported by the fact that before 2003 no systematic surveillance of LGV was available and that the diagnostic tests necessary to find LGV serovars of *C. trachomatis* were not routinely available, and anal swabs positive for *Chlamydia* were recorded as *Chlamydia* proctitis with no additional testing for LGV being performed. On the other hand, there are some characteristics suggesting an ongoing outbreak like a sudden increase in the number of cases potentially linked and the presence of geographical clustering. The increase in high-risk sexual practices, such as serosorting, among HIV-positive MSM after the introduction of highly active anti-retroviral therapy (HAART) could have contributed to the spread of the disease in the last years in this specific group, as observed for other STD such as syphilis and gonorrhoea [48]. A selection bias (testing only HIV-infected patients and HIV-infected persons being more aware) cannot be excluded [9]. Further investigations are needed to shed light on this issue.

Clinical syndrome

Lymphogranuloma venereum is caused by *Chlamydia trachomatis* serovars L1–L3. Serovars B and D–K are responsible for the syndromes of non-gonococcal urethritis

and cervicitis and can also cause a mild inflammation of the rectal mucosa. It is an invasive disease and has tropism for the lymphatic system, causing severe inflammation, often with systemic implication in contrast to serovars A–K, which are associated with mild or asymptomatic systemic implications. LGV can be transmitted through vaginal, anal or oral sexual contact. The clinical characteristics depend on the site of inoculation.

The classical description of LGV consists of a primary lesion at the site of inoculation after an incubation period of 3–30 days involving a small, painless genital papula, which may ulcerate, heal spontaneously and leaving no scarring. This lesion frequently passes unnoticed. The initial infection can also be intraurethral, producing an asymptomatic urethritis, cervical, producing cervicitis, or in the rectum, producing proctitis. It was well known that LGV serovars were associated with more severe forms of proctitis, especially seen in the collective of MSM [24, 25], but this is probably more common than previously presumed.

This primary stage is followed after days to weeks by a secondary stage characterised by lymphatic involvement of those lymph nodes that drain the area of the primary lesion. In the classical form tender unilateral or bilateral inguinal and/or femoral (“groove” sign) adenopathies appear. When the primary infection occurs in the rectum the deep iliac lymph nodes are affected, but remain unnoticed. This can also be observed in women due to the drainage of the cervical or upper vaginal area to the perirectal lymph nodes. The lymph nodes become inflamed and painful and may coalesce to form a “bubo” or abscesses that may rupture spontaneously with the development of fistulas or sinus tracts. This stage may be associated with systemic features such as malaise, fever and headaches.

If untreated, a proportion of patients will progress to a chronic granulomatous inflammatory process (tertiary stage) with lymphatic obstruction leading to fistula formation and strictures and disfiguring conditions such as genital elephantiasis and esthiomene (Greek, “eating away”) which refers to hypertrophic enlargement with ulceration of the external genitalia.

In the present outbreak of LGV among MSM the majority of patients were HIV-positive with preserved CD4 cell counts. The role of the CD4 cell count in modulating the clinical picture of LGV proctocolitis, as occurs with almost all opportunistic infections associated with HIV, is yet to be elucidated [37]. In a retrospective study no differences in the clinical picture of proctitis investigated by proctoscopy were noted among HIV-positive patients who did or did not receive HAART [38]. However, more than the use of HAART, it would be interesting to examine the clinical presentation stratified by the CD4 count.

The immune restoration inflammatory syndrome (IRIS) seen with many opportunistic infections after the initiation of HAART seems unlikely to modulate the clinical presentation of LGV proctocolitis, since most patients had been on anti-retroviral therapy (ART) for several years before the LGV diagnosis and no signs of IRIS were registered [37, 38].

High rates of co-infection with other STD and hepatitis C have been observed [3, 6, 21]. Tables 1 and 2 summarise the main clinical characteristics of different series reported so far, where wide variations in clinical symptoms can be observed. They presented typically with a rectal syndrome (>90%) with moderate to severe ulcerative proctitis or proctocolitis with mucopurulent discharge, rectal pain, bloody rectal discharge, constipation and tenesmus. Systemic symptoms like fever and malaise and weight loss were relatively common. Paradoxically, simultaneous penile lesions and/or inguinofemoral lymphadenopathy have been reported rarely [49]. Despite the fact that most patients had reported unprotected insertive and receptive anal sexual intercourse, only few cases of urethritis due to LGV serovars have been reported in the present outbreak [35, 50]. The reason why the bubonic form or the urethral infection is not more commonly reported remains unclear. Some reports have suggested transmission through sex toys, but further research will be required to reveal the exact mode of transmission.

Some patients were pauci-symptomatic or asymptomatic, up to 40% in the Dutch series, but other studies have failed to demonstrate a significant reservoir of asymptomatic or urethral infection in MSM or in the general population [2, 39, 40, 50, 51]. On the other hand, the absence of the classical clinical features of LGV have also conditioned a delay in the diagnosis and treatment in the current outbreak as evidenced by the large number of cases diagnosed retrospectively, allowing ongoing transmission [5, 8, 11, 43, 46].

The endoscopic findings included mucopurulent exudate with a hyperaemic and friable mucosa, easily bleeding, with multiple ulcers and erosions being replaced by granulomatous tissue and tumorous inflammatory masses. However, in some reports up to 40% of men with LGV proctitis showed no anoscopic abnormalities [37, 38]. Even these endoscopic findings are unspecific and the disease can be misdiagnosed. The pathology shows typically only non-specific inflammatory features with an intense chronic inflammatory process. It is crucial to remember that the histology is non-specific and can be easily misinterpreted, even by trained pathologists [3].

Clinical proctitis is a common problem in MSM and clinicians should suspect LGV in MSM who present with colorectal gastrointestinal symptoms. Diagnosis may be hampered because rectal LGV may clinically and histologically mimic other conditions such as inflammatory bowel

Table 1 Main characteristics of lymphogranuloma venereum cases in men who have sex with men (MSM) reported between 1990 and 2009

Country	Period of study	Cases (number)	Median age (year)	HIV (%)	STD ^g (%)	Hep C (%)	HAART (%)	Proctitis ^h (%)	Asymp ^j (%)	Proc ^l (%)
The Netherlands [38]	2002–2003	87	37.6	60	21		54			47
The Netherlands [43]	2002–2003	45	35.8	69						
The Netherlands [3]	2004	13	39	85	46	8	36	92.3		100
France [11]	2002–2005	244	39	85 ^e				Most patients		
UK [5]	2004	24	40	90	42	21		94.7		
The Netherlands [14]	2004–2005	114	40	67	Frequent	10		91	18	
Belgium [10]	2004–2005	13		92				100		
Switzerland [8]	1999–2005	10		70				100		
The Netherlands [37]	2004–2006	32	39.6	78	19	13			40 ^k	60
UK [6]	2004–2006	327	38	76	39	19	45	96	13	
UK [7]	2004–2007	492	40	74	48	14		90–77 ^l	5–18 ^l	
The Netherlands [15]	2006–2007	57	45	77	Frequent			Most patients		
Spain ^a	2007–2009	42	39.4	91	50			Most patients		
Australia [29]	2005–2008	11	47	82				81.8		
Canada [28]	2001–2007	88	37.5	78	Frequent	6				
Sweden [16]	2007	15	38	73	40		33	80	6.6	
Germany [4]	2004–2005	78	39	96 ^f				75		
Italy [13]	2006–2007	13		62	38		46	77		
France [12]	2002–2004	22	39.2	57				100		
Austria [2] ^b	2005–2006	15	41.3	85	53		13	86.7		
France [33]	2003–2004	38 ^c	40	57	64			100		
Canada [27]	2004–2005	22 ^d	38	73		25		78		
Portugal [1]	2007	8	36	25	38			12.5	75	

^a Data from CEEISCAT in Catalonia (Jordi Casabona, personal communication)

^b Mean CD4 count 469 (±180.4) cells/mL. No specification of CD4 count was available in the other studies

^c Complete surveillance data were available for 14 of the 38 patients

^d Surveillance data were available for 19 of the 22 cases, though not complete for all cases

^e HIV status was available for 96 patients, of which 82 were known to be HIV-positive

^f HIV status was available for 52 patients, of which 50 were known to be HIV-positive

^g Concomitant sexually transmitted disease (STD)

^h Proctitis syndrome includes, unless otherwise stated, variable degrees of loose, bloody stools associated with the passage of mucus, cramping abdominal pain, rectal tenesmus and low-grade fever. Periods of constipation are also common

^l Proctitis syndrome was present in 90% of the individuals in the period of 2004–2005 and in 77% in 2006–2007; asymptomatic patients accounted for 5% in 2004–2005 and 18% in 2006–2007

^j Asymptomatic patients

^k 40% were pauci-symptomatic

^l Signs of proctitis observed in proctoscopy/sigmoidoscopy

disease, colorectal cancer and lymphoma [24], which is why they should be included in the differential diagnosis along with other ulcerative rectal STD such as syphilis and herpetic or cytomegalovirus proctitis. The case of lymphoma is

particularly relevant, because the tissue infiltration by lymphocytes and the immunohistochemical markers for the Epstein–Barr virus can be extremely confusing for the pathologist [52].

Table 2 Main characteristics of reported lymphogranuloma venereum cases in MSM between 1990 and 2009 (continued)

Country	Rectal pain (%)	Anal discharge (%)	Constipation (%)	Blood loss (%)	Tenesmus (%)	Systemic ^a (%)	Inguinal nodes (%)	Anogenital ulcer (%)
The Netherlands [38]	2	2					24	9
The Netherlands [43]		33.3					13.3	6.6
The Netherlands [3]		77	77	61	15	15	0	
France [11]								
UK [5]						36.8	10.5	
The Netherlands [14]	74	85		65		41	24	
Belgium [10]								
Switzerland [8]							0	
The Netherlands [37]		44					13	
UK [6]	64	72	23	53	25	29	8	4
UK [7]						15–24 ^b		
The Netherlands [15]	66	78		89		25		
Spain								
Australia [29]							9	
Canada [28]								
Sweden [16]							13	13
Germany [4]							13	
Italy [13]							23	
France [12]								
Austria [2]							13.3	
France [33]						21		57
Canada [27]	21	21	7			28	43	21
Portugal [1]								

^a Systemic symptoms (weight loss, malaise, fever)

^b Systemic symptoms was registered in 15% in 2004–2005 and in 24% in 2006–2007

Diagnosis

First of all, it is of paramount importance to bear in mind that *LGV* proctocolitis will not be diagnosed if specific tests are not ordered, as routine smears and cultures performed in urethral or rectal samples do not identify this pathogen.

Correct diagnosis is essential as a prolonged treatment of 3 weeks is recommended for LGV infection, in contrast to infection with other *Chlamydia* serovars, where only 1 week (or a single azithromycin dose) is required.

Lymphogranuloma venereum was classically diagnosed by the Frei intradermal skin test, based on the delayed hypersensitivity reactions to chlamydial antigens, but this is no longer in use because of its low sensitivity and specificity. Direct identification of *C. trachomatis* from clinical specimens is the current standard. Before 2003 we did not have a routine test for diagnosing LGV since the tests that were available did not distinguish between the LGV and non-LGV serovars.

Initially, the laboratory diagnosis of LGV was based in either culture (which was rarely available in routine practice,

because it was slow and less sensitive), or nucleic acid amplification testing (NAAT) followed by genotyping of positive samples with PCR-based restriction fragment length polymorphism (RFLP) analysis and/or sequencing of the *omp1* gene encoding the major outer membrane protein. All this required a sophisticated laboratory setting and was time consuming. Since 2005, several fast molecular biological diagnostic tests that have a higher sensitivity have been widely available. In 2005, the first RT-PCR technique was developed to detect LGV serovars in a *C. trachomatis* PCR-positive sample using the polymorphic membrane protein H gene (*pmp* gene) as a PCR target because of its unique gap in LGV strains, making it highly specific [53]. This technique can detect the LGV serovars, but it cannot distinguish between them. A multiplex RT-PCR specific to serovar L2, and a quadriplex RT-PCR that simultaneously detects LGV and non-LGV serovars and mixed infections have been developed more recently [54, 55].

Chlamydia nucleic acids can be detected in urethral, endocervical, vaginal, pharyngeal or rectal swab specimens

and urine samples. However, the use of rectal swabs for nucleic acid testing is not cleared by the US Food and Drug Administration and in consequence is not recommended by the CDC yet [38], although initial data support its validity [56].

Serology has been replaced by direct detection tests. However, it could still be useful in selected cases. A high titre of antibody (with microimmunofluorescence or with complement fixation) in a symptomatic patient is strongly suggestive of LGV, but cannot distinguish between current or previous infection. Comparative studies between different serological tests are lacking, and there is no consensus regarding their interpretation.

Investigation of proctitis, with or without inguinal lymphadenopathy and genital ulcer, especially in the MSM group, should make the physician suspect LGV. Clinicians should not count on patient complaints and/or proctoscopic findings alone to identify LGV proctitis. Serovar typing is recommended in MSM with a PCR-positive anal swab for *Chlamydia* infection. If routine LGV serovar typing is not available or until definitive diagnosis, syndromic LGV management is proposed by some authors using clinical predictors of LGV proctitis in MSM with anorectal *Chlamydia* with either proctitis detected by proctoscopic examination, > 10 WBC detected on Gram stain smears from anal mucosa or presence of HIV infection [38].

Management

According to the current European and US STD guidelines the recommended treatment for LGV is doxycycline (100 mg orally twice a day for 21 days or as long as anorectal symptoms persist). An alternative regimen is erythromycin (500 mg orally four times daily for 21 days). However, this recommendation is not supported by randomised evidence in clinical trials, but by empirical data. Azithromycin (1.0 g orally once weekly for 3 weeks) has also been suggested as an alternative, but clinical data are lacking, as well as data regarding the new fluoroquinolones [57–60].

Patients should be followed up until symptoms have disappeared, and clinically reviewed at 3–6 weeks.

In uncomplicated chlamydial infections with non-LGV strains a single oral dose of 1 g azithromycin is enough or a shorter (1-week) course of doxycycline. In HIV-infected patients the recommended treatment is the same, even though randomised studies are lacking [58]. A delay in resolution may be observed in immunosuppressed persons, and prolonged therapy may be necessary. Sexual partners who have had unprotected contact with the patient within the previous 60 days of onset of clinical symptoms should

be screened or empirically treated with an LGV regimen [58, 60]. Aspiration of bubos may be necessary as well as surgical management of anorectal fistulas and strictures in advanced cases.

Patients should receive risk education counselling and be routinely screened for other STD, especially including HIV and hepatitis B and C.

Lymphogranuloma venereum should be a mandatory reportable disease in all countries, and contact tracing is of major importance to prevent further spread within the community.

Clinical implications

Clinicians should suspect LGV proctocolitis, especially in MSM presenting with colorectal symptoms like rectal pain, mucopurulent or bloody discharge, cramping abdominal pain, constipation, tenesmus leading to specific molecular biological diagnostic testing based on RT-PCR of a rectal swab with serovar typing. Systemic symptoms like fever, malaise and weight loss are relatively common. Simultaneous penile lesions and/or inguino-femoral lymphadenopathy are observed rarely in the present outbreak.

Early diagnosis and management are pivotal and furthermore have important public health implications, since the ulcerative character of the disease may facilitate transmission and acquisition of HIV and other STD, including hepatitis C. Screening for HIV, other STD and hepatitis C is mandatory since many of the described cases had concomitant infections. Contact tracing should be performed but it may be difficult given the anonymous nature of many sexual contacts in this core group.

Future challenges

There are still some pivotal questions to be answered concerning LGV proctitis. Diagnostic testing for *C. trachomatis* with LGV typing of *C. trachomatis*-positive samples in symptomatic men or contacts of men with LGV is currently recommended. The role of systematic screening for rectal LGV in stopping the transmission of LGV in HIV-infected MSM needs to be defined. Also, the usefulness of a shorter treatment with tetracyclines, macrolides or quinolones would be of great interest and may also have public health implications in reducing transmission. Moreover, there is a strong need for simpler and more affordable diagnostic methods, particularly those quick on-the-spot results, to help physicians with earlier diagnosis. It would be of great interest to perform prevalence studies among both HIV-positive and HIV-negative MSM.

Last but not least, there is an urgent need to implement regular and coordinated national and international surveillance programs in many countries in order to monitor the disease occurrence, to better identify patterns of disease and possible risk factors and to implement health service needs. This implementation would be of utmost urgency.

References

- Gomes J, Nunes A, Florindo C, Ferreira M, Santo I, Azevedo J, Borrego M (2009) Lymphogranuloma venereum in Portugal: unusual events and new variants during 2007. *Sex Transm Dis* 36(2):88–91
- Sary G, Meyer T, Bangert C, Kohrgruber N, Gmeinhardt B, Kirnbauer R, Jantschitsch C, Rieger A, Sary A, Geusau A (2008) New Chlamydia trachomatis L2 strains identified in a recent outbreak of lymphogranuloma venereum in Vienna, Austria. *Sex Transm Dis* 35(4):377–382
- Nieuwenhuis RF, Ossewaarde JM, Götz HM, Dees J, Thio HB, Thomeer MG, den Hollander JC, Neumann MH, van der Meijden WI (2004) Resurgence of lymphogranuloma venereum in Western Europe: an outbreak of Chlamydia trachomatis serovar I2 proctitis in The Netherlands among men who have sex with men. *Clin Infect Dis* 39(7):996–1003
- Bremer V, Meyer T, Marcus U, Hamouda O (2006) Lymphogranuloma venereum emerging in men who have sex with men in Germany. *Euro Surveill* 11(9):152–154
- Macdonald N, Ison C, Martin I, Alexander S, Lowndes C, Simms I, Ward H (2005) Initial results of enhanced surveillance for lymphogranuloma venereum (LGV) in England. *Euro Surveill* 10(1):E050127.050125
- Ward H, Martin I, Macdonald N, Alexander S, Simms I, Fenton K, French P, Dean G, Ison C (2007) Lymphogranuloma venereum in the United Kingdom. *Clin Infect Dis* 44(1):26–32
- Jebbari H, Alexander S, Ward H, Evans B, Solomou M, Thornton A, Dean G, White J, French P, Ison C, Group ULI (2007) Update on lymphogranuloma venereum in the United Kingdom. *Sex Transm Infect* 83(4):324–326
- Gebhardt M, Goldenberger D (2005) Lymphogranuloma venereum (LGV) serotype L2 in Switzerland, 2003–2005. *Euro Surveill* 10(12):E051222.051224
- Goldenberger D, Dutly F, Gebhardt M (2006) Analysis of 721 Chlamydia trachomatis-positive urogenital specimens from men and women using lymphogranuloma venereum L2-specific real-time PCR assay. *Euro Surveill* 11(10):E061018.061014
- Vandenbruaene M, Ostyn B, Crucitti T, De Schrijver K, Sasse A, Sergeant M, Van Dyck E, Van Esbroeck M, Moerman F (2005) Lymphogranuloma venereum outbreak in men who have sex with men (MSM) in Belgium, January 2004 to July 2005. *Euro Surveill* 10(9):E050929.050923
- Herida M, de Barbeyrac B, Sednaoui P, Scieux C, Lemarchand N, Kreplak G, Clerc M, Timsit J, Goulet V, Desenclos JC, Semaille C (2006) Rectal lymphogranuloma venereum surveillance in France 2004–2005. *Euro Surveill* 11(9):155–156
- Halioua B, Bohbot JM, Monfort L, Nassar N, de Barbeyrac B, Monsonego J, Sednaoui P (2006) Ano-rectal lymphogranuloma venereum: 22 cases reported in a sexually transmitted infections center in Paris. *Eur J Dermatol* 16(2):177–180
- Cusini M, Boneschi V, Arancio L, Ramoni S, Venegoni L, Gaiani F, De Vries H (2008) Lymphogranuloma venereum: the Italian experience. *Sex Transm Infect* 85(3):171–172
- Van de Laar MJ, Koedijk FD, Gotz HM, de Vries HJ (2006) A slow epidemic of LGV in the Netherlands in 2004 and 2005. *Euro Surveill* 11(9):150–152
- Koedijk FD, de Boer IM, de Vries HJ, Thiesbrummel HF, van der Sande MA (2007) An ongoing outbreak of lymphogranuloma venereum in the Netherlands, 2006–2007. *Euro Surveill* 12(4):E070419.070412
- Velicko I, Cullberg M, Bratt G, Mamlöv G, Johnsson A, Hansson HB, Herrmann B, Blaxhult A (2009) Lymphogranuloma venereum-increased spread in Sweden. A rare Chlamydia subtype which become more and more common among men who have sex with men. *Lakartidningen* 106(1–2):28–31
- Savage EJ, van de Laar MJ, Galloway A, van der Sande M, Hamouda O, Sasse A, Hoffmann S, Diez M, Borrego MJ, Lowndes CM, Ison C, European Surveillance of Sexually Transmitted Infections n (2009) Lymphogranuloma venereum in Europe, 2003–2008. *Euro Surveill* 14(48)pii: 19428
- Castro R, Baptista T, Vale A, Nunes H, Prieto E, Mansinho K, da Luz Martins Pereira F (2008) Anorectal lymphogranuloma venereum: the first two confirmed cases in Portugal. *Euro Surveill* 13(50)pii: 19060
- Berglund T, Bratt G, Herrmann B, Karlsson A, Löfdahl M, Payne L (2005) Two cases of lymphogranuloma venereum (LGV) in homosexual men in Stockholm. *Euro Surveill* 10(3):E050303.050303
- Mabey D, Peeling RW (2002) Lymphogranuloma venereum. *Sex Transm Infect* 78(2):90–92
- Götz HM, van Doornum G, Niesters HG, den Hollander JG, Thio HB, de Zwart O (2005) A cluster of acute hepatitis C virus infection among men who have sex with men—results from contact tracing and public health implications. *AIDS* 19(9):969–974
- Koch RA, McDonald RS, Marshall MS (1949) Public health aspects of lymphogranuloma venereum. *Calif Med* 71(3):178–186
- Geiger JC, Mathewson C (1940) Venereal lymphogranuloma: public health aspects. *Calif West Med* 52(1):25–27
- Quinn TC, Stamm WE, Goodell SE, Mkrтчichian E, Benedetti J, Corey L, Schuffler MD, Holmes KK (1983) The polymicrobial origin of intestinal infections in homosexual men. *N Engl J Med* 309(10):576–582
- Levine JS, Smith PD, Brugge WR (1980) Chronic proctitis in male homosexuals due to lymphogranuloma venereum. *Gastroenterology* 79(3):563–565
- Nieuwenhuis RF, Ossewaarde JM, van der Meijden WI, Neumann HA (2003) Unusual presentation of early lymphogranuloma venereum in an HIV-1 infected patient: effective treatment with 1 g azithromycin. *Sex Transm Infect* 79(6):453–455
- Kropp RY, Wong T; Canadian LGV Working Group (2005) Emergence of lymphogranuloma venereum in Canada. *CMAJ* 172(13):1674–1676
- (2009) Lymphogranuloma venereum (LGV) Epi Update—STI Epi Updates—Public Health Agency of Canada. Available online <http://www.phac-aspc.gc.ca/publicat/epiu-aeipi/std-mts/lgv-eng.php>
- Lee D, Fairley C, Owen L, Horvath L, Chen M (2009) Lymphogranuloma venereum becomes an established infection among men who have sex with men in Melbourne. *Aust N Z J Public Health* 33(1):94
- Stark D, Van Hal S, Hillman R, Harkness J, Marriott D (2007) Lymphogranuloma venereum in Australia: anorectal Chlamydia trachomatis serovar L2b in men who have sex with men. *J Clin Microbiol* 45(3):1029–1031
- Ahdoot A, Kotler DP, Suh JS, Kutler C, Flamholz R (2006) Lymphogranuloma venereum in human immunodeficiency virus-infected individuals in New York City. *J Clin Gastroenterol* 40(5):385–390
- Vall Mayans M, Caballero E, Garcia de Olalla P, Armengol P, Codina MG, Barberà MJ, Sanz B, Andreu A, Caylà JA (2008)

- Outbreak of lymphogranuloma venereum among men who have sex with men in Barcelona 2007/08—an opportunity to debate sexual health at the EuroGames 2008. *Euro Surveill* 13(25):pii: 18908
33. Herida M, Sednaoui P, Couturier E, Neau D, Clerc M, Scieux C, Kreplak G, Goulet V, Hamers FF, de Barbeyrac B (2005) Rectal lymphogranuloma venereum, France. *Emerging Infect Dis* 11(3):505–506
 34. De Munain J, Ezpeleta G, Imaz M, Del Mar CM, Esteban V, Santamaría J, Cisterna R (2008) Two lymphogranuloma venereum cases in a heterosexual couple in Bilbao (Spain). *Sex Transm Dis* 35(11):918–919
 35. Herida M, Kreplack G, Cardon B, Desenclos JC, de Barbeyrac B (2006) First case of urethritis due to *Chlamydia trachomatis* genovar L2b. *Clin Infect Dis* 43(2):268–269
 36. Geisler W, Morrison S, Bachmann L (2008) Absence of lymphogranuloma venereum strains among rectal *Chlamydia trachomatis* outer membrane protein A genotypes infecting women and men who have sex with men in Birmingham, Alabama. *Sex Transm Dis* 35(10):856–858
 37. De Vries HJ, Van Der Bij A, Fennema HS, Smit C, De Wolf F, Prins M, Coutinho RA, Morrè SA (2008) Lymphogranuloma venereum proctitis in men who have sex with men is associated with anal enema use and high-risk behavior. *Sex Transm Dis* 35(2):203–208
 38. Van der Bij AK, Spaargaren J, Morrè SA, Fennema HS, Mindel A, Coutinho RA, de Vries HJ (2006) Diagnostic and clinical implications of anorectal lymphogranuloma venereum in men who have sex with men: a retrospective case-control study. *Clin Infect Dis* 42(2):186–194
 39. Klint M, Löfdahl M, Ek C, Airell A, Berglund T, Herrmann B (2006) Lymphogranuloma venereum prevalence in Sweden among men who have sex with men and characterization of *Chlamydia trachomatis* ompA genotypes. *J Clin Microbiol* 44(11):4066–4071
 40. Timmouth J, Gilmour M, Kovacs C, Kropp R, Mitterni L, Rachlis A, Richards S, Salit I, Sikri R, Valencia G, Wesson T, Wong T, Wood H (2008) Is there a reservoir of sub-clinical lymphogranuloma venereum and non-LGV *Chlamydia trachomatis* infection in men who have sex with men? *Int J STD AIDS* 19(12):805–809
 41. Alexander S, Thornton A, Dean G et al (2007) What is the prevalence of lymphogranuloma venereum in the United Kingdom among men who have sex with men, and is there an asymptomatic reservoir of infection? Seventeenth International Society for Sexually Transmitted Diseases Research (ISSTD). Washington, Seattle
 42. Bauwens JE, Orlander H, Gomez MP, Lampe M, Morse S, Stamm WE, Cone R, Ashley R, Swenson P, Holmes KK (2002) Epidemic lymphogranuloma venereum during epidemics of crack cocaine use and HIV infection in the Bahamas. *Sex Transm Dis* 29(5):253–259
 43. Spaargaren J, Fennema HS, Morrè SA, de Vries HJ, Coutinho RA (2005) New lymphogranuloma venereum *Chlamydia trachomatis* variant, Amsterdam. *Emerging Infect Dis* 11(7):1090–1092
 44. Meyer T, Arndt R, von Krosigk A, Plettenberg A (2005) Repeated detection of lymphogranuloma venereum caused by *Chlamydia trachomatis* L2 in homosexual men in Hamburg. *Sex Transm Infect* 81(1):91–92
 45. Schachter J, Moncada J (2005) Lymphogranuloma venereum: how to turn an endemic disease into an outbreak of a new disease? Start looking. *Sex Transm Dis* 32(6):331–332
 46. Spaargaren J, Schachter J, Moncada J, de Vries HJ, Fennema HS, Peña AS, Coutinho RA, Morrè SA (2005) Slow epidemic of lymphogranuloma venereum L2b strain. *Emerging Infect Dis* 11(11):1787–1788
 47. Lister NA, Tabrizi SN, Fairley C, Smith A, Janssen PH, Garland S (2004) Variability of the *Chlamydia trachomatis* omp1 gene detected in samples from men tested in male-only saunas in Melbourne, Australia. *J Clin Microbiol* 42(6):2596–2601
 48. Fenton KA, Imrie J (2005) Increasing rates of sexually transmitted diseases in homosexual men in Western Europe and the United States: why? *Infect Dis Clin North Am* 19(2):311–331
 49. Sethi G, Allason-Jones E, Richens J, Annan NT, Hawkins D, Ekbote A, Alexander S, White J (2008) Lymphogranuloma venereum presenting as genital ulceration and inguinal syndrome in men who have sex with men in London, United Kingdom. *Sex Transm Infect* 85(3):165–170
 50. Ward H, Alexander S, Carder C, Dean G, French P, Ivens D, Ling C, Paul J, Tong W, White J, Ison CA (2009) The prevalence of lymphogranuloma venereum infection in men who have sex with men: results of a multicentre case finding study. *Sex Transm Infect* 85(3):173–175
 51. Annan NT, Sullivan AK, Nori A, Naydenova P, Alexander S, McKenna A, Azadian B, Mandalia S, Rossi M, Ward H, Nwokolo N (2009) Rectal chlamydia—a reservoir of undiagnosed infection in men who have sex with men. *Sex Transm Infect* 85(3):176–179
 52. Van Hal SJ, Hillman R, Stark DJ, Harkness JL, Marriott D (2007) Lymphogranuloma venereum: an emerging anorectal disease in Australia. *Med J Aust* 187(5):309–310
 53. Morrè SA, Ouburg S, van Agtmael MA, de Vries HJ (2008) Lymphogranuloma venereum diagnostics: from culture to real-time quadruplex polymerase chain reaction. *Sex Transm Infect* 84(4):252–253
 54. Chen C, Chi K, Alexander S, Ison C, Ballard R (2008) A real-time quadruplex PCR assay for the diagnosis of rectal lymphogranuloma venereum and non-lymphogranuloma venereum *Chlamydia trachomatis* infections. *Sex Transm Infect* 84(4):273–276
 55. Chen CY, Chi KH, Alexander S, Martin IM, Liu H, Ison CA, Ballard RC (2007) The molecular diagnosis of lymphogranuloma venereum: evaluation of a real-time multiplex polymerase chain reaction test using rectal and urethral specimens. *Sex Transm Dis* 34(7):451–455
 56. Alexander S, Martin I, Ison C (2007) Confirming the *Chlamydia trachomatis* status of referred rectal specimens. *Sex Transm Infect* 83(4):327–329
 57. Mcmillan A, van Voorst Vader PC, de Vries HJ, IUaSTIWH O (2007) The 2007 European Guideline (International Union against Sexually Transmitted Infections/World Health Organization) on the management of proctitis, proctocolitis and enteritis caused by sexually transmissible pathogens. *Int J STD AIDS* 18(8):514–520
 58. Mclean C, Stoner B, Workowski KA (2007) Treatment of lymphogranuloma venereum. *Clin Infect Dis* 44 [Suppl 3]:S147–S152
 59. De Vries HJ, Smelov V, Middelburg JG, Pleijster J, Speksnijder AG, Morrè SA (2009) Delayed microbial cure of lymphogranuloma venereum proctitis with doxycycline treatment. *Clin Infect Dis* 48(5):e53–e56
 60. Centers for Disease Control and Prevention; Workowski KA, Berman SM (2006) Sexually transmitted diseases treatment guidelines, 2006. *MMWR Recomm Rep* 55(RR-11):1–94