



HAL
open science

Validation of a Fornix Depth Measurer - A Putative Tool for the Assessment of Progressive Cicatrising Conjunctivitis

Geraint P. Williams, Valerie P.J. Saw, Tariq Saeed, Simon T. Evans, Paul Cottrell, S. John Curnow, Peter Nightingale, Saaeha Rauz

► **To cite this version:**

Geraint P. Williams, Valerie P.J. Saw, Tariq Saeed, Simon T. Evans, Paul Cottrell, et al.. Validation of a Fornix Depth Measurer - A Putative Tool for the Assessment of Progressive Cicatrising Conjunctivitis. *British Journal of Ophthalmology*, 2010, 95 (6), pp.842. 10.1136/bjo.2010.188011 . hal-00595939

HAL Id: hal-00595939

<https://hal.science/hal-00595939>

Submitted on 26 May 2011

HAL is a multi-disciplinary open access archive for the deposit and dissemination of scientific research documents, whether they are published or not. The documents may come from teaching and research institutions in France or abroad, or from public or private research centers.

L'archive ouverte pluridisciplinaire **HAL**, est destinée au dépôt et à la diffusion de documents scientifiques de niveau recherche, publiés ou non, émanant des établissements d'enseignement et de recherche français ou étrangers, des laboratoires publics ou privés.

Validation of a Fornix Depth Measurer - A Putative Tool for the Assessment of Progressive Cicatrising Conjunctivitis

Geraint P.Williams¹, Valerie P.J. Saw², Tariq Saeed¹, Simon T. Evans³, Paul Cottrell, S. John Curnow¹, Peter Nightingale⁴ and Saaeha Rauz¹.

¹Academic Unit of Ophthalmology, School of Immunity and Infection, University of Birmingham, Birmingham, United Kingdom

²Corneal and External Diseases Service, Moorfields Eye Hospital, London, United Kingdom

³Diamond Centre of Wales, Talbot Green, United Kingdom

⁴Wellcome Trust Clinical Research Facility, Queen Elizabeth Hospital, Birmingham, United Kingdom

Short title: Validation of a Fornix Depth Measurer

Key words: Conjunctiva, Inflammation, Diagnostic Tests/Investigations, Treatment Medical

Word Count: 2435

Disclosure Statement: The authors have no proprietary interest in the products described in this article and have nothing to disclose.

Presented in part at the Association for Research in Vision and Ophthalmology meeting, Fort Lauderdale, Florida, May 2009 (E-abstract number 50; 1538).

Address for correspondence: Saaeha Rauz PhD FRCOphth (Miss)
Academic Unit of Ophthalmology
School of Immunity and Infection
University of Birmingham
Birmingham and Midland Eye Centre
Dudley Road
Birmingham B18 7QU
United Kingdom
Tel 44-(0)121-507-6849
Fax 44-(0)121-507-6853
E-mail: s.rauz@bham.ac.uk

1 **Abstract**

2

3 **Background/aims:** Documentation of conjunctival forniceal foreshortening in cases of
4 progressive cicatrising conjunctivitis (PCC) is important in ascertaining disease stage and
5 progression. Lower fornix shortening is frequently documented subjectively or semi-objectively
6 whereas upper forniceal obliteration is seldom quantified. Although tools such as fornix depth
7 measurers (FDMs) have been described, their designs limit upper fornix measurement. The
8 purpose of this study was to custom-design a FDM to evaluate the upper fornix, and to assess
9 variability in gauging fornix depth.

10 **Methods:** A polymethylmethacrylate FDM was constructed using industry-standard jewellery
11 computer software and machinery. Two observers undertook a prospective independent
12 evaluation of central lower fornix depth in a heterogeneous cohort of patients with clinically
13 normal and abnormal conjunctival fornices both subjectively, and by using the FDM (in mm).
14 Upper central fornix depth was also measured. Agreement was assessed using Bland-Altman
15 plots.

16 **Results:** Fifty one eyes were evaluated. There was 100% intra-observer agreement to within
17 1mm for each observer for lower fornix measurement. The mean difference in fornix depth
18 loss using the FDM between observer 1 and 2 was 1.19% with 95% confidence of agreement
19 ($\pm 2SD$) of -15 to +20%. 86%(44/51) of measurements taken by the two observers agreed to
20 within 10% of total lower fornix depth (i.e. $\pm 1mm$) versus only 63%(32/51) of the subjective
21 measurements. Mean upper fornix difference was 0.57mm with 95% agreement between -2
22 and + 3mm.

23 **Conclusions:** Our custom-designed FDM is well tolerated by patients and demonstrates low
24 intra- and inter-observer variability. This enables repeatable and reproducible measurements
25 of upper and lower fornix depths, facilitating improved rates of detection and better monitoring
26 of progression of conjunctival scarring.

27

1 Introduction

2

3 Sequential documentation of forniceal foreshortening in cases of progressive cicatrising
4 conjunctivitis (PCC) such as ocular mucous membrane pemphigoid (OcMMP), is important in
5 assessing stage and progression of disease.[1-3] The Foster staging relies upon subjective
6 evaluation of subepithelial fibrosis and extent of symblepharon formation[3] whilst the system
7 described by Mondino and Brown describes grading of percentage shrinkage of the lower
8 fornix[4] . A modification encompassing both systems, was described by Tauber et al, who
9 proposed that counting the number and percentage horizontal obliteration of the lower fornix
10 by symblephara, could potentially improve detection of disease progression.[1]

11

12 We have previously shown that lower fornix shortening is frequently documented either
13 subjectively or semi-objectively by utilising a slit-light beam; whereas the degree of upper
14 forniceal obliteration is seldom quantified.[5] Furthermore, we have shown that at initial visit to
15 tertiary referral centres, Foster's staging of disease is undertaken in 100% of patients' lower
16 fornix, but only 78% of patients had quantification of forniceal shrinkage. This is likely to be
17 related to the difficulty in assessing lower fornix depth accurately without the aid of a made-for
18 purpose tool.[6]

19

20 Measurement of the fornices utilising devices such as the fornix depth measurer (FDM), have
21 been previously described, but their design restricts accurate upper fornix measurements.[7,8]
22 Specifically, the depth and curvature of the upper fornix dictates the requirement that the ideal
23 FDM is sufficiently long and curved to enable comfortable and accurate assessment of the
24 upper fornix. We previously employed a FDM based upon that designed by Schwab[7] in
25 routine clinical practice but its design was suboptimal (**Figure 1**). In 2004, a modification of the
26 Schwab FDM was designed at Moorfields Eye Hospital ((MEH), for the purpose of a clinical
27 trial[9] and is currently being used in an epidemiological study. In 2007, we wished to re-
28 design and evaluate a bespoke comfortable prototype that could provide an accurate tool for
29 improving forniceal sac documentation in the outpatient clinic setting, with potential for wider

1 scale commercial manufacture. In this study we describe this custom-designed FDM
2 constructed specifically to facilitate evaluation of the depth of the upper conjunctival fornix, and
3 we assess intra- and inter-observer variability in gauging the extent of the upper and lower
4 fornices by validating the FDM and comparing it to subjective assessment of fornix shrinkage.
5

1 **Materials and Methods**

2

3 **Design of a Bespoke Fornix Depth Measurer (FDM)**

4 A polymethylmethacrylate (PMMA) FDM was designed using industry-standard jewellery
5 computer software (CAD v5, 3Design, Brussieu, France 2007). The virtual model was then
6 exported as an .STL file into a program to set the cutting parameters for the milling machine
7 (Modela Player v4, Roland DG, Shizuoka, Japan 2002) (**Figure 2a**). The virtual model was
8 cut with a machine to a precision of 2 μ m/step, and increments expressed at 2mm intervals at
9 both ends of the FDM: the main “body” and the “handle”. This design feature enables
10 measurement of the fornix in the context of multiple symblephara which could potentially
11 hinder the smooth passage of the FDM to the limits of the conjunctival sac. The FDM
12 measured 25mm x 5mm and was moulded to a biconcave shape to ensure ease of insertion
13 and comfort (**Figure 1c and 2b**).

14

15 **Patients**

16 An evaluation of the bespoke FDM was undertaken through a prospective, masked,
17 independent assessment of central lower fornix depth by two observers (GPW, TS), following
18 the Tenets of the Declaration of Helsinki. This was undertaken as a service evaluation at the
19 Birmingham and Midland Eye Centre (BMEC). The validation of the FDM was conducted on a
20 heterogeneous group of patients comprising of clinically normal and abnormal conjunctival
21 fornices presenting to BMEC. This heterogeneity enabled a wide range of fornix depths to be
22 tested with the bespoke FDM.

23

24 The cohort consisted of 51 eyes of 26 patients with a median age of 64 years (range 42-100
25 years) of whom 65% (17/26) of patients (33/51 eyes) had an identifiable cause of cicatrising
26 conjunctivitis (OcMMP, 10; dry eyes, 5 (including 3 with Sjögren’s syndrome); Stevens-
27 Johnson Syndrome (SJS), 2) and 35% (18/51) had no evidence of conjunctival scarring (Age-
28 Related Macular Degeneration (ARMD), 4; Uveitis, 3; Peripheral Ulcerative Sclero-keratitis, 2).

1 Following instillation of one drop of 0.4% Oxybuprocaine hydrochloride, patients were asked to
 2 look in the opposite direction to the placement of the FDM (upper fornix, down-gaze; lower
 3 fornix, up-gaze) in order to protect the cornea, ensure consistency in readings and circumvent
 4 variability in the eyelid position in primary gaze. The central conjunctival fornix was measured
 5 to the eyelid margin, defined as the posterior lip of the meibomian gland orifice (**Figure 1c**). All
 6 FDM readings were in triplicate with the first measurement taken used for inter-observer
 7 comparison. A semi-objective estimation of lower fornix conjunctival shrinkage was also
 8 performed by gauging the central lower fornix depth, measured from the inferior fornix to the
 9 eyelid margin with the aid of a vertical 1mm wide slit-lamp beam with illumination and
 10 observation axes in a coaxial position (NB a subjective assessment of the upper fornix is
 11 impossible). The FDM was sterilised by soaking the device in 0.05% Sodium
 12 dichloroisocyanurate solution for 5 minutes between patients (as per the BMEC infection
 13 control policy for reusable tonometer heads). Patients were also asked about their tolerance to
 14 the FDM.

15

16 **Calculations and Statistical Analyses**

17 The percentage loss of lower fornix for both methods of measurement (subjective and
 18 objective) was calculated using the equation:

19

$$20 \{[\text{Fornix Depth (FD) age} - \text{FDM measurement}] / \text{FD age}\} \times 100 = \% \text{ loss of fornix}$$

21

22 A correction factor for age was implemented as the lower forniceal depth is known to
 23 progressively shorten with age.[7] The “FD age” values were derived from published age-
 24 specific lower fornix depths in normal eyes detailed in **Table 1**.^[7] For example, for a patient
 25 aged 80 years with a lower fornix measured at 6mm, the calculated percentage shrinkage is
 26 as follows:

$$27 \{[10.2-6]/10.2 \times 100\}=41.2\%$$

28

1 It is important to note that it was not possible to calculate percentage loss of the upper fornix
2 because the normal range of age-specific upper forniceal depths is currently unknown.

3 Intra- and inter-observer agreement was assessed using Bland-Altman plots of differences in
4 measurements versus mean measurements using excel for Macintosh (Microsoft Office
5 2008).[10,11] The mean difference in observations and the 95% limits of agreement (the mean
6 difference ± 2 standard deviations)[10] were calculated using SPSS v 16.0 for Macintosh
7 (SPSS, Chicago, Illinois 2007). A continuity correction was applied to the 95% limits of
8 agreement, to take account of the fact that Bland and Altman plots assume that the variables
9 measured are continuous.

10

11 A 10% threshold or 'tolerance' was chosen as an allowance for intra-observer variation.
12 Agreement was also evaluated by determining the percentage of observations which agreed
13 to within the 10% 'allowance' for both observers.

14

15

1 Results

2

3 Lower Fornix Assessment

4

5 *Intra-observer variation*

6 Triplicate measurements of FDM readings of the same anatomical position by each observer
7 (central lower fornix) demonstrated exact agreement of 86% (42/49) and 89% (41/46) of
8 measurements within observer 1 and observer 2 respectively. When allowing for 1mm
9 'tolerance' (approximating to 10% of the normal lower fornix, see **Table 1**), 100% of intra-
10 observer observations fell within 1mm for both observers.

11

12 *Inter-observer variation*

13 Inter-observer variation between the subjective and objective measurements of the central
14 lower fornix by the two observers was also assessed. Assessment of the lower fornix
15 shrinkage was expressed as a percentage for both subjective and objective estimations, the
16 latter using the age correction factor described in the methods[7].

17

18 The mean difference in calculated percentage fornix depth using measurements obtained from
19 the FDM by observer 1 and 2 was 1.19% and with a continuity correction, the 95% limits of
20 agreement ($\pm 2SD$) were narrower for inter-observer objective (FDM) measurements versus
21 those obtained subjectively (-15 and + 20%) (**Figure 3**). The inter-observer agreement within
22 the 10% allowance (i.e. approx. ± 1 mm) of total lower fornix depth was 86% (44/51) (**Figure 4**).

23

24 By contrast, the inter-observer mean difference in subjective estimation of percentage fornix
25 depth was -1.86% and with a continuity correction, the 95% limits of agreements (± 2 Standard
26 Deviations, SD) were between -30 and +25% (**Figure 3**). Only 63% (32/51) of the subjective
27 measurements taken by the two observers agreed to within a 10% allowance of total lower
28 fornix depth (**Figure 4**).

1

2 These data highlight that the FDM afforded greater consistency in fornix depth measurement
3 by each observer (intra-observer variation), and between observers (inter-observer variation).

4

5 **Upper Fornix Assessment**

6

7 ***Intra-observer variation***

8 Triplicate measurements (to assess intra-observer variation) of FDM readings of the same
9 anatomical position of the central upper fornix by each observer demonstrated minimal
10 variation (i.e. identical objective measurements) in 88% (45/51) and 70% (33/47) of
11 measurements by observer 1 and observer 2 respectively. There are no data regarding normal
12 upper fornix depth in the published literature, mitigating calculations for age-based corrections
13 and percentage fornix depth foreshortening and tolerance threshold.

14

15 ***Inter-observer variation***

16 Inter-observer variation of the upper fornix showed a mean difference in fornix depth
17 measurement using the FDM for observer 1 and 2 of 0.57mm with 95% agreement ($\pm 2SD$) of
18 -2 and + 3mm (**Figure 5**). The absence of normal upper fornix values precludes evaluation of
19 the 10% allowance, however 84.3% (43/51) of upper fornix measurements were within 1SD of
20 the mean difference of 0.57mm (+2 to -1mm of the mean with a continuity correction).

21

22 **Patient comfort and tolerance**

23

24 The FDM was well tolerated by patients with only a few patients (3) experiencing mild
25 discomfort with upper fornix measurement, despite repeated measurements. None of these
26 patients reported prolonged discomfort or pain.

27

1 Discussion

2

3 PCC comprises a group of disorders characterised by progressive scar formation in response
4 to conjunctival inflammation affecting the stromal layers of the conjunctiva.[12] These include
5 ocular immunobullous diseases such as OcMMP, SJS and Toxic Epidermal Necrolysis (TEN),
6 Lichen planus, Linear IgA disease, Paraneoplastic Pemphigus and Epidermolysis Bullosa.
7 Other causes include Graft-Versus Host Disease, Sjögren's syndrome, Acne Rosacea and
8 those associated with topical therapy where progression is reported to be more insidious with
9 less destructive clinical sequelae.

10

11 Due to the sight-threatening consequences of OcMMP, the ocular phenotype of MMP is
12 regarded as "high risk"[13] particularly as disease progression is more aggressive in younger
13 patients[14] and 50% of patients continue to have progression of cicatrising disease in the
14 apparent absence of inflammation.[15]

15

16 Determining progression in PCC is a challenging aspect of patient management. When
17 considering OcMMP for example, the most common of the acquired immunobullous diseases
18 that cause PCC[12,16], progression may occur at any stage of disease [2,17] that can be
19 aggressive early in the disease course[14], but importantly, is frequently independent of
20 clinically identifiable inflammation.[15] Determining disease progression in the cicatrising
21 conjunctivitides therefore relies upon accurate documentation of disease, in particular
22 conjunctival shrinkage of the fornices. Although the Mondino staging system is considered to
23 be more sensitive than Foster's staging system[15] and is integrated in the proposed system
24 described by Tauber and Foster[1], Mondino fornix depth measurement is reported to be
25 undertaken in only 78% of new patients in tertiary referral centres compared with 100%
26 documentation of the Foster's system.

27

1 Vigilant assessment, quantification and documentation of forniceal foreshortening is
2 mandatory for enabling accurate patient follow-up currently not achieved by subjective or
3 semi-objective assessments of the fornix. These approaches are limited by inconsistency,
4 poor reproducibility and reliability, but are overcome by the development and implementation
5 of fornix depth measuring devices for the assessment and progression of diseases that cause
6 conjunctival scarring[7,8,18]. Our aim was to architect an FDM based upon the original
7 Schwab et al concept, but with additional upper fornix depth capability[7]. Specifically, our
8 custom-made FDM was found to be comfortable and accurate. Designed and made using
9 industry-standard computer software and machinery, this FDM prototype was modelled
10 mathematically taking into account the curvature of the globe necessary for comfortable
11 measurement of the upper fornix. We tested our bespoke FDM on patients with a range of
12 fornix depths in the presence or absence of conjunctival fibrosis. Our findings demonstrated
13 low intra- and inter-observer variability enabling repeatable and reproducible measurements of
14 both upper and lower fornix depths, highlighting its potential in facilitating both accurate and
15 robust clinical documentation of disease stage. This FDM prototype is currently being
16 optimised with further modifications to improve comfort and fit.

17

18 Crucially, the conjunctival cicatrising process is not confined to the lower fornix and sight
19 threatening sequelae secondary to subtarsal fibrosis, upper lid entropion or lash trauma
20 commonly ensue. These clinico-pathological processes are not taken into consideration by
21 ocular staging systems which calculate percentage obliteration of the lower fornix[1,2],
22 although are reflected in the staging system described by Foster where fornix shortening or
23 symblephara of any degree throughout the conjunctival surface are thought to be important.[3]
24 The decreased sensitivity in relying solely upon this system, or those that include direct
25 measurement of the lower fornix alone, increase the risk of type 2 errors (false negatives) in
26 determining disease progression, which are considerably rescinded by the use of fornix depth
27 measuring devices for the upper fornix.

28

1 The larger depth of the upper fornix and difficulty of access explains the omission of detailed
2 upper fornix pathology in currently recognised scoring systems.[1,2] Perhaps not surprisingly
3 therefore, there appears to be little data in the ophthalmic literature regarding the anthropology
4 and normal depth of the upper fornix. Kawakita and colleagues have recently discussed the
5 use of a non-curved 150x2 mm FDM in Japanese patients with Stevens Johnson Syndrome
6 and healthy volunteers.[8] They found that the mean supero-temporal and supero-nasal upper
7 fornix depths were 14.1mm±2.5mm in normal individuals. Our findings demonstrate a median
8 central upper fornix depth of 16mm in a Caucasoid group of patients, even in the presence of
9 recognised cases of cicatrising conjunctivitis. The variation of the central upper fornix depth
10 amongst healthy populations utilising anthropological ethnography together with differences
11 with age, remains unresolved. This has recently been highlighted in the context of other
12 diseases affecting the size of the upper fornix such as the giant fornix syndrome described by
13 Rose.[19] These pieces of data illustrate the need for population-based studies of the normal
14 age-based upper fornix depths to facilitate percentage shrinkage calculations in conjunctival
15 scarring diseases; and these are is currently being undertaken at BMEC and MEH.

16

17 In summary, our custom-designed FDM is well tolerated by patients with only three patients
18 experiencing short-lived mild discomfort during assessment of the upper fornix. This FDM
19 demonstrates low intra- and inter-observer variability enabling repeatable and reproducible
20 measurements of lower fornix depths. We believe that the custom design of an FDM using
21 industry-standard jewellery software and machinery, curved to fit for the globe provides an
22 accurate and comfortable means of assessing lower fornix depth. Furthermore, it offers
23 potential to measure upper fornix depth, currently not routinely employed in clinical practice,
24 thereby improving both the detection and monitoring of progressive conjunctival fibrosis in
25 these devastating group of disorders.

26

1 **Acknowledgements**

2

3 Geraint Williams is a Wellcome Trust Clinical Research Fellow (London, UK). The Academic
4 Unit of Ophthalmology is supported by the Birmingham Eye Foundation (Registered (UK)
5 Charity 257549). We would like to thank Mr. John Dart for reviewing the manuscript. We
6 would also like to thank the Medical Illustration department at City Hospital, Birmingham, UK
7 for their help in preparing of images.

8

9

10 The Corresponding Author has the right to grant on behalf of all authors and does grant on
11 behalf of all authors, an exclusive licence (or non-exclusive for government employees) on a
12 worldwide basis to the BMJ Publishing Group Ltd and its Licensees to permit this article (if
13 accepted) to be published in British Journal of Ophthalmology and any other BMJPG
14 products to exploit all subsidiary rights, as set out in our licence
15 (<http://group.bmj.com/products/journals/instructions-for-authors/licence-forms>).

16

17

1 **References**

2

- 3 1. Tauber J, Jabbur N, Foster CS. Improved detection of disease progression in ocular
4 cicatricial pemphigoid. *Cornea* 1992;11:446-51.
- 5 2. Mondino BJ, Brown SI. Ocular cicatricial pemphigoid. *Ophthalmology* 1981;88:95-100.
- 6 3. Foster CS. Cicatricial pemphigoid. *Trans Am Ophthalmol Soc* 1986;84:527-663.
- 7 4. Mondino BJ, Brown SI. Immunosuppressive therapy in ocular cicatricial pemphigoid. *Am*
8 *J Ophthalmol* 1983;96:453-9.
- 9 5. Williams GP, Radford C, Saw V, et al. Presentation and Disease Progression in
10 Established Ocular Mucous Membrane Pemphigoid [abstract]. *Invest Ophthalmol Vis Sci*
11 2008;49 (e-abstract 803):
- 12 6. Radford CF, Williams GP, Saw VP, et al. Presentation, Management and Disease
13 Progression in Early Ocular Mucous Membrane Pemphigoid [abstract]. *Invest*
14 *Ophthalmol Vis Sci* 2008;49 (e-abstract 802).
- 15 7. Schwab IR, Linberg JV, Gioia VM, et al. Foreshortening of the inferior conjunctival fornix
16 associated with chronic glaucoma medications. *Ophthalmology* 1992;99:197-202.
- 17 8. Kawakita T, Kawashima M, Murat D, et al. Measurement of fornix depth and area: a
18 novel method of determining the severity of fornix shortening. *Eye* 2009;**23**(5):1115-9.
- 19 9. Saw VPJ, Dart JKG, Bunce C *et al.* Pulsed Intravenous Methylprednisolone For Mucous
20 Membrane Pemphigoid (MMP): A Pilot Randomised Clinical Trial [abstract]. *World*
21 *Cornea Congress VI*. 2010 (poster 384).
- 22 <http://wccvi.abstractsnet.com/acover.wcs?entryid=000319>

1
2
3
4
5
6
7
8
9
10
11
12
13
14
15
16
17
18
19
20
21
22
23
24
25
26
27

10. Bland JM, Altman DG. Statistical methods for assessing agreement between two methods of clinical measurement. *Lancet* 1986;1:307-10.
11. Bunce C. Correlation, agreement, and Bland-Altman analysis: statistical analysis of method comparison studies. *Am J Ophthalmol* 2009;148:4-6.
12. Bernauer W, Elder MJ, Dart JK. Introduction to Cicatrising Conjunctivitis. In: Bernauer W, Dart, J.K.G. and Elder, M.J., ed. *Cicatrising Conjunctivitis*. Basel, Switzerland: Karger, 1997: 1-10.
13. Chan LS, Ahmed AR, Anhalt GJ, et al. The first international consensus on mucous membrane pemphigoid: definition, diagnostic criteria, pathogenic factors, medical treatment, and prognostic indicators. *Arch Dermatol* 2002;138:370-9.
14. Rauz S, Maddison PG, Dart JK. Evaluation of mucous membrane pemphigoid with ocular involvement in young patients. *Ophthalmology* 2005;112:1268-74.
15. Saw VP, Dart JK, Rauz S, et al. Immunosuppressive therapy for ocular mucous membrane pemphigoid strategies and outcomes. *Ophthalmology* 2008;115:253-61 e1.
16. Wojnarowska FT, Briggaman RA. *Management of blistering diseases: Chapman and Hall Medical*;1990.
17. Elder MJ, Bernauer W, Leonard J, et al. Progression of disease in ocular cicatricial pemphigoid. *Br J Ophthalmol* 1996;80:292-6.
18. Barabino S, Rolando M, Bentivoglio G, et al. Role of amniotic membrane transplantation for conjunctival reconstruction in ocular-cicatricial pemphigoid. *Ophthalmology* 2003;110:474-80.
19. Rose GE. The Giant Fornix Syndrome: Author reply. *Ophthalmology* 2005;112:1173.

1 **Figures Legends**

2

3 **Figure 1:** Colour photographs illustrating the evolution of the FDM. The original adaptation of
4 an FDM described by Schwab et al [7] (produced by our local prosthetics department) is
5 shown in Panel A. An FDM constructed at Moorfields Eye Hospital (MEH) is an elongated
6 polymethylmethacrylate modification of the Schwab FDM using a hand-made plaster cast
7 (designed by VS, Scott Hau and David Carpenter - ocular prosthetist at Moorfields Eye
8 Hospital), specifically to facilitate upper fornix depth measurement for use in a clinical trial is
9 shown in Panel B. For comparison, Panel C illustrates the computer-designed bespoke FDM
10 prototype. This is an elongated, biconcave design with engraved markings to a precision of
11 $2\mu\text{m}/\text{step}$, and increments expressed at 2 mm intervals on both the main body of the FDM and
12 the narrower 'handle'. The markings on the handle facilitate upper fornix measurement and the
13 ability to measure the fornix in the presence of symblephara (panel D). The accuracy and
14 reproducibility of the computer generated design and jewellery precision engraving, provides
15 potential for commercial manufacture.

16

1 **Figure 2:** A PMMA FDM was constructed using industry-standard jewellery software and
2 machinery. A screenshot of the 3design prototype is shown in the top panel (panel A). The
3 final prototype is illustrated in the left panel (panel B). Increments are expressed at 2mm
4 intervals to a precision of 2 μ m/step and the FDM was heat moulded to a biconcave shape for
5 comfort. The FDM was applied following instillation of one drop of 0.4% Oxybuprocaine
6 hydrochloride (panel C). Patients were asked to look in the opposite direction to the placement
7 of the FDM and the central conjunctival fornix was measured to the eyelid margin, defined as
8 the posterior lip of the meibomian gland orifice.
9

1 **Figure 3:** Bland-Altman plots showing inter observer variation in lower fornix assessment (left
2 panels; A objective and C subjective). Some data points are identical and therefore overlay
3 each other on the figures. The % difference in assessment between observer 1 and 2 is
4 plotted against the mean % loss of fornix for each eye. If there was a completely normal fornix
5 this is represented as 0% loss of fornix on the x axis. Note the increase in the 95% limits of
6 agreement ($\pm 2SD$) for subjective assessment (arrowed), demonstrated also by the histograms
7 (right panels, B and D).
8

1 **Figure 4:** The histograms demonstrate the difference in objective and subjective lower fornix
2 assessment between observer 1 and 2. The number of individuals which agree to within a
3 10% 'allowance' are boxed and are higher for objective measurements A 86% (44/51),
4 compared to subjective measurement, B, 63% (32/51).

5

1 **Figure 5:** The Bland-Altman plot (left upper panel, A) shows inter observer variation in upper
2 fornix assessment. As there are no defined limits for the upper fornix, the calculations are in
3 mm. The mm difference in assessment between observer 1 and 2 is plotted against mean mm
4 measurement for each patient. The 95% limits of agreement are vertically arrowed and
5 represented also by the histogram (right upper panel B). The lower histogram (panel C)
6 demonstrates the difference in upper fornix assessment between observer 1 and 2; the 10%
7 allowance cannot be calculated in the absence of normal upper fornix values but 71% (36/51)
8 of measurements were within 1mm and 92% (47/51) of observations were within 2mm of each
9 other.
10

1 **Table 1:** Age specific normal values for the conjunctival lower fornix.

2

Age	Mean Depth of normal lower fornix in mm ('100%')	10% of normal lower fornix in mm
40-49	11.9	1.19
50-59	11.3	1.13
60-69	11.0	1.10
70-79	10.6	1.06
80+	10.2	1.02

3

4

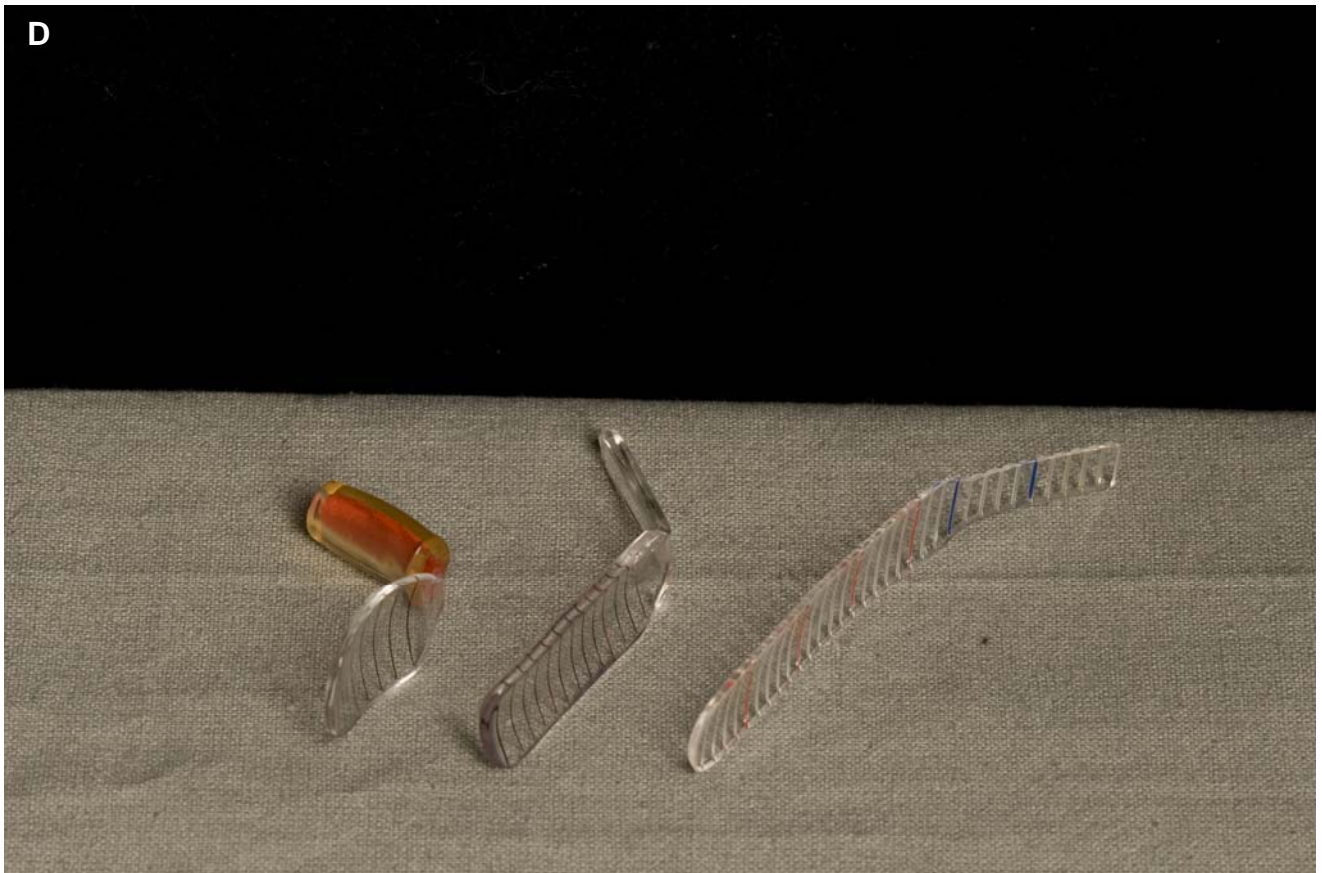
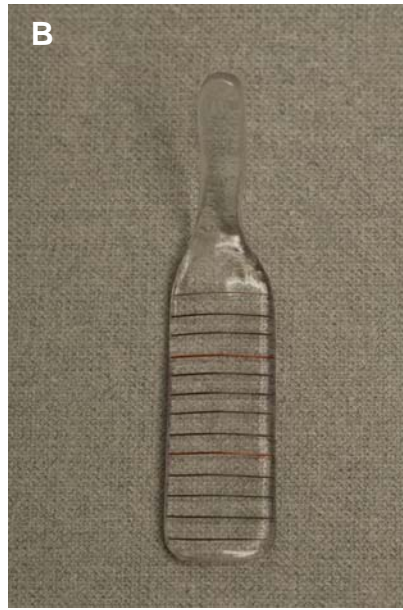
Adapted from Schwab *et al* Ophthalmology 1992.

5

6

7

8



Figure

1

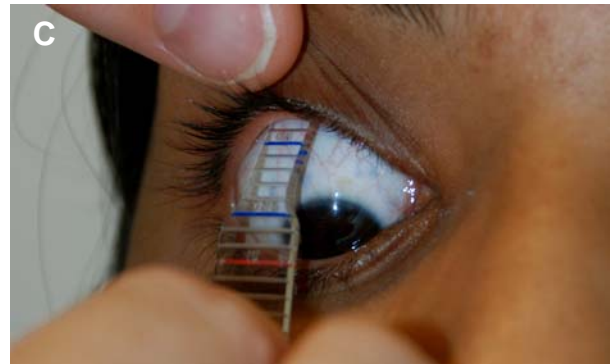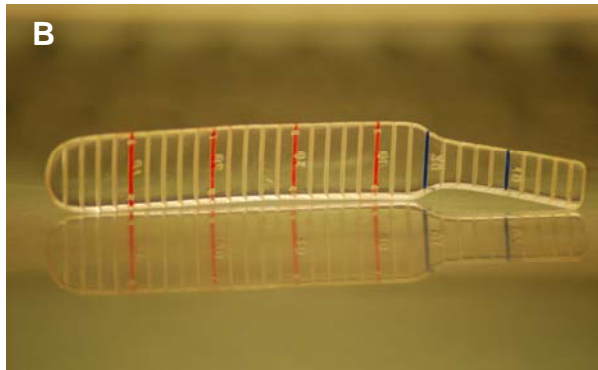
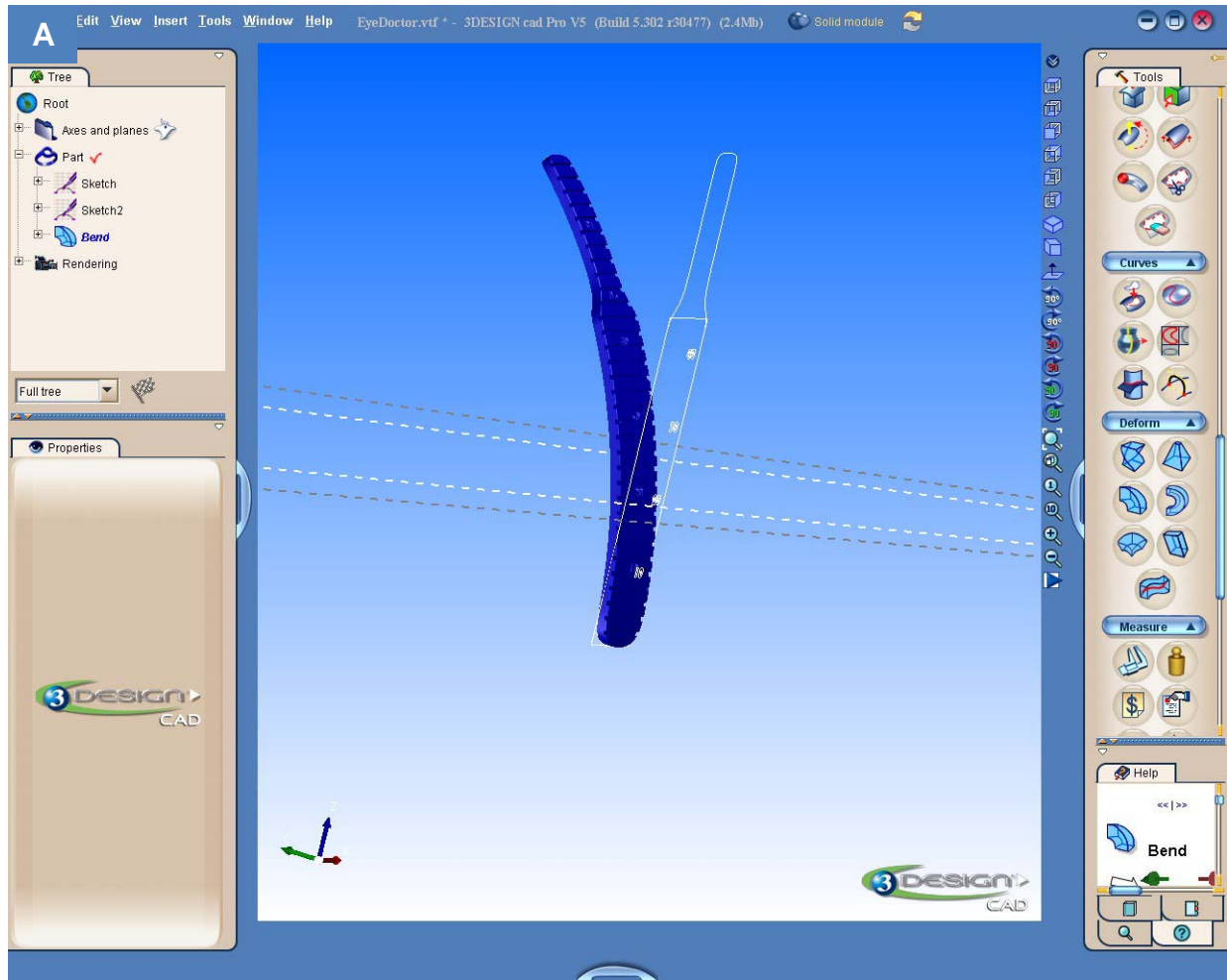
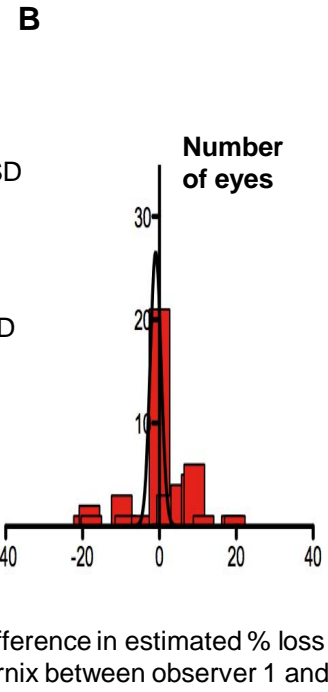
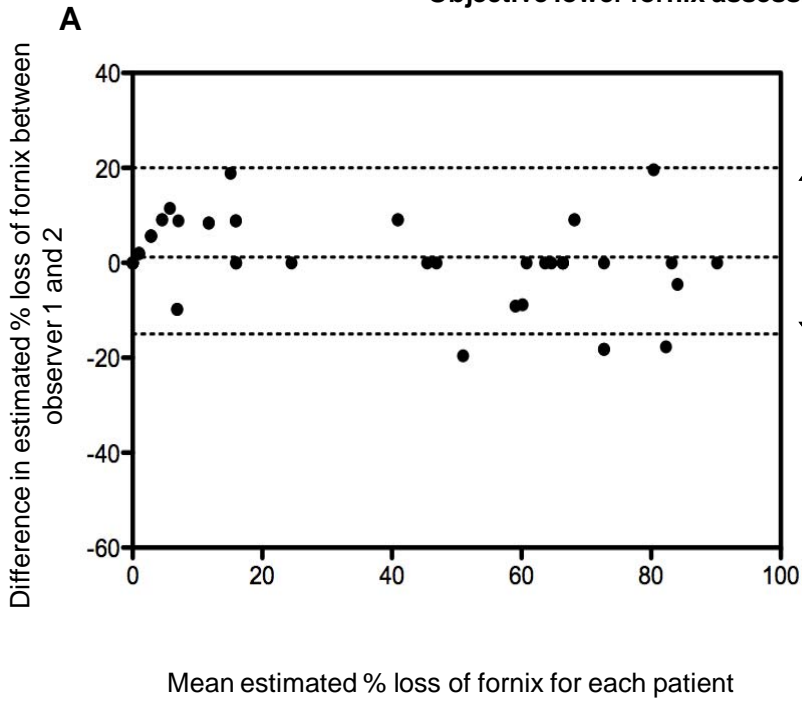


Figure 2

Objective lower fornix assessment



Subjective lower fornix assessment

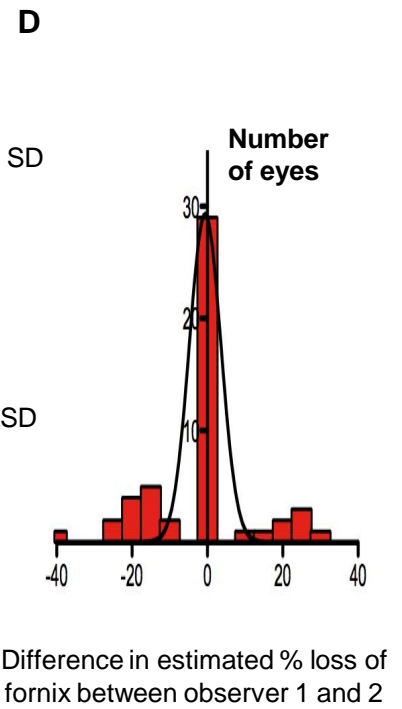
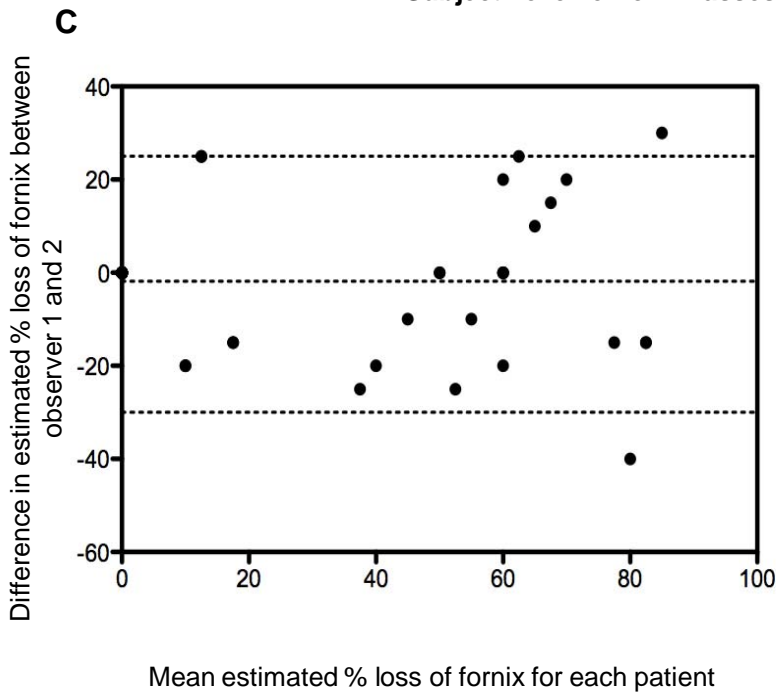
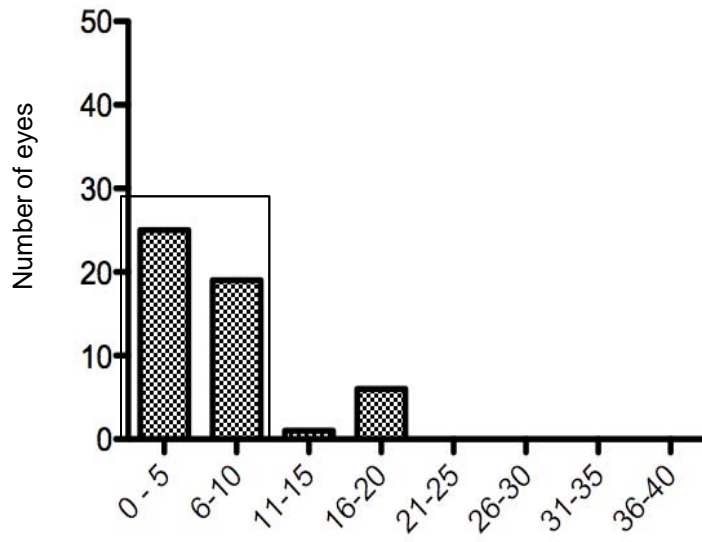


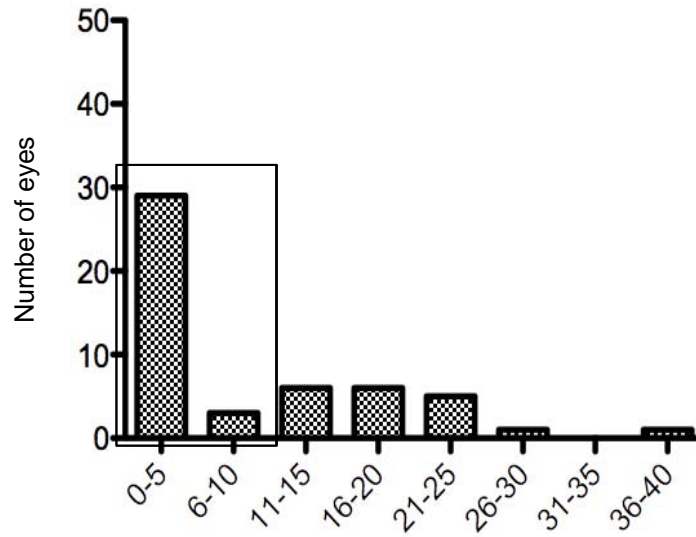
Figure 3

A Objective lower fornix assessment



Difference in assessment (%) between observer 1 and 2

B Subjective lower fornix assessment



Difference in assessment (%) between observer 1 and 2

Figure 4

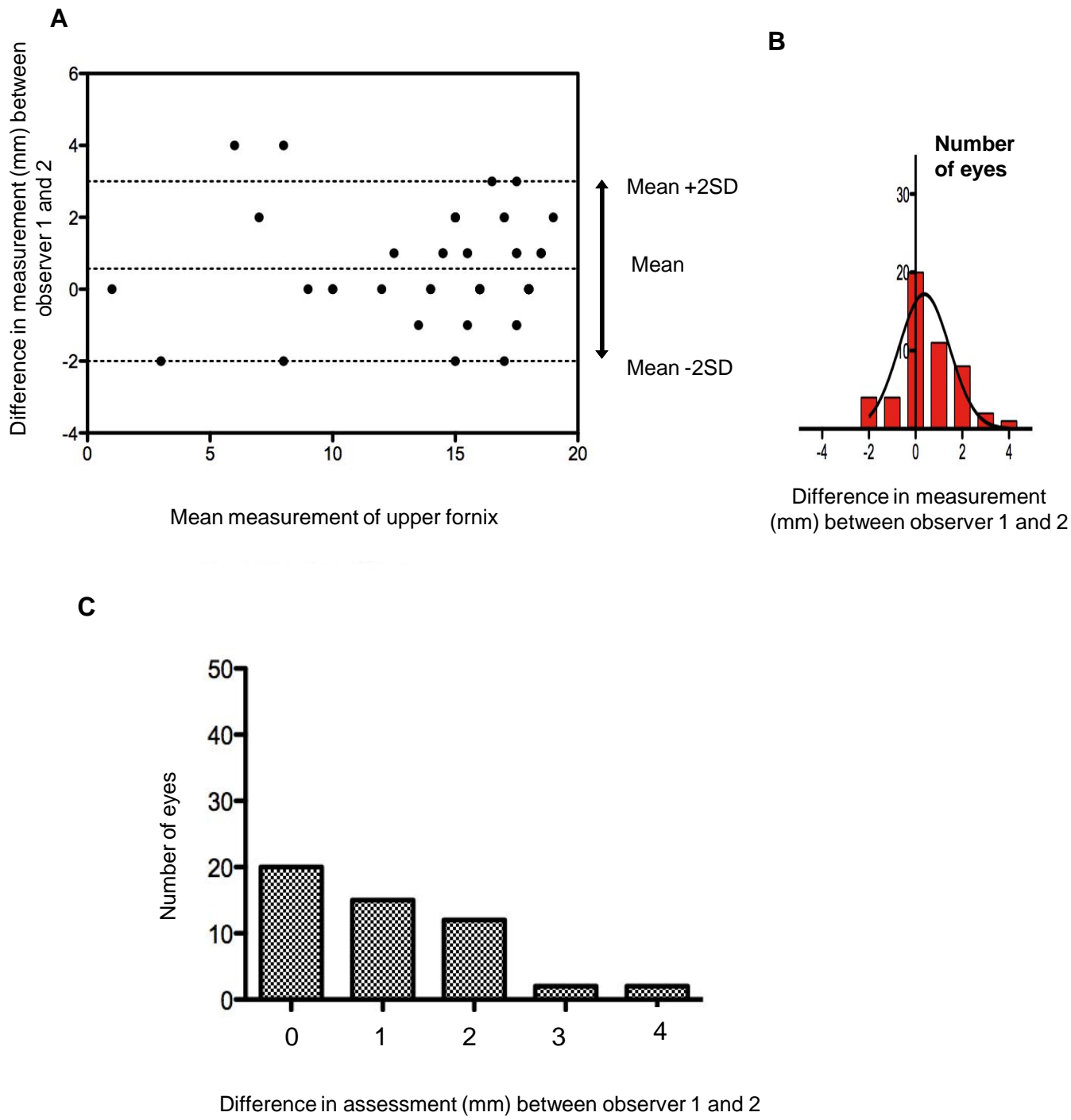


Figure 5