



HAL
open science

Radiofrequency ablation is a feasible therapeutic option in the multi modality management of bone and soft tissue sarcoma

R.L. Jones, J. Mccall, A. Adam, D. O'Donnell, S. Ashley, O. Al-Muderis, K
Thway, C. Fisher, I.R. Judson

► **To cite this version:**

R.L. Jones, J. Mccall, A. Adam, D. O'Donnell, S. Ashley, et al.. Radiofrequency ablation is a feasible therapeutic option in the multi modality management of bone and soft tissue sarcoma. *EJSO - European Journal of Surgical Oncology*, 2010, 36 (5), pp.477. 10.1016/j.ejso.2009.12.005 . hal-00594805

HAL Id: hal-00594805

<https://hal.science/hal-00594805>

Submitted on 21 May 2011


HAL is a multi-disciplinary open access archive for the deposit and dissemination of scientific research documents, whether they are published or not. The documents may come from teaching and research institutions in France or abroad, or from public or private research centers.

L'archive ouverte pluridisciplinaire **HAL**, est destinée au dépôt et à la diffusion de documents scientifiques de niveau recherche, publiés ou non, émanant des établissements d'enseignement et de recherche français ou étrangers, des laboratoires publics ou privés.

Accepted Manuscript

Title: Radiofrequency ablation is a feasible therapeutic option in the multi modality management of bone and soft tissue sarcoma

Authors: R.L. Jones, J. McCall, A. Adam, D. O'Donnell, S. Ashley, O. Al-Muderis, K Thway, C. Fisher, I.R. Judson



PII: S0748-7983(09)00569-1

DOI: [10.1016/j.ejso.2009.12.005](https://doi.org/10.1016/j.ejso.2009.12.005)

Reference: YEJSO 2928

To appear in: *European Journal of Surgical Oncology*

Received Date: 15 September 2009

Revised Date: 15 December 2009

Accepted Date: 21 December 2009

Please cite this article as: Jones RL, McCall J, Adam A, O'Donnell D, Ashley S, Al-Muderis O, Thway K, Fisher C, Judson IR. Radiofrequency ablation is a feasible therapeutic option in the multi modality management of bone and soft tissue sarcoma, *European Journal of Surgical Oncology* (2009), doi: [10.1016/j.ejso.2009.12.005](https://doi.org/10.1016/j.ejso.2009.12.005)

This is a PDF file of an unedited manuscript that has been accepted for publication. As a service to our customers we are providing this early version of the manuscript. The manuscript will undergo copyediting, typesetting, and review of the resulting proof before it is published in its final form. Please note that during the production process errors may be discovered which could affect the content, and all legal disclaimers that apply to the journal pertain.

Radiofrequency ablation is a feasible therapeutic option in the multi modality management of bone and soft tissue sarcoma

R.L. Jones¹

J McCall^{1,2}

A Adam³

D O'Donnell³

S Ashley¹

O Al-Muderis¹

K Thway¹

C Fisher¹

I.R. Judson¹

¹Sarcoma Unit, Royal Marsden Hospital, Fulham Road, London. SW3 6JJ

²Department of Radiology, Chelsea and Westminster Hospital, Fulham Road, SW10 9NH

³Department of Radiology, St. Thomas' Hospital, Lambeth Palace Road, SE1 7EH

Corresponding author: Dr Robin L Jones

Sarcoma Unit

Royal Marsden Hospital

Fulham Road, London, UK

SW3 6JJ

Telephone: 020 7808 2200

Fax: 020 7808 2113

Email: robin.jones@icr.ac.uk

Abstract

The role of radiofrequency ablation (RFA) in metastatic sarcoma is not well defined. The aim of this study was to evaluate the efficacy and safety of RFA in a series of sarcoma patients. A retrospective search of a prospectively maintained database identified 13 gastrointestinal stromal tumour (GIST) patients and 12 with other histological subtypes treated with RFA. All the GIST patients received RFA for metastatic disease in the liver: 12 of these responded to the first RFA procedure and one achieved stable disease. Two GIST patients received RFA on two occasions to separate lesions within the liver and both responded to the second RFA procedure. Of the other subtypes: 7 underwent RFA to liver lesions, 5 of these responded to RFA, one progressed and 1 was not assessable for response at the time of analysis. All 5 patients with lung metastases achieved a response following their first RFA procedure. RFA was effective and well tolerated in this series of sarcoma patients. RFA may have a role in patients with GIST who have progression in a single metastasis but stable disease elsewhere. Further larger studies are required to better define the role of this technique in this patient population.

Keywords: Radio frequency ablation, sarcoma, response, progression, toxicity.

Introduction

Soft tissue sarcomas are rare cancers arising from mesodermal tissues.¹ Surgical resection is the mainstay of management for localized disease, but despite adequate excision approximately half of patients will develop metastatic disease.¹ Sarcomas comprise over 50 different histological subtypes, each with different biological characteristics, prognosis and response to therapy. The number of effective treatment strategies available to treat metastatic disease is limited.¹

Radiofrequency ablation (RFA) has emerged as an effective local therapy in the treatment of hepatocellular carcinoma and liver metastases secondary to colorectal cancer as well as other malignancies.² This technique produces coagulative necrosis via an alternating high-frequency electric current in the radiofrequency range. This results in the movement of ions within the targeted lesion, and consequently frictional heat is created by the ions following the alternating current.² Local intra lesional temperatures approach or exceed 100°C. RFA can achieve improved objective responses in a small number of treatment sessions, and the technique is usually regarded as most effective against small lesions (<3.5cm). Minor side effects include pain and discomfort. Other potential disadvantages include severe adverse events (including pain, cutaneous burns and fever) and death (reported as approximately 0.5%).²

To our knowledge there is little published data on the use of RFA specifically in the management of patients with sarcoma.³⁻⁸ The aim of this study was to evaluate the efficacy of RFA to both lung and liver metastases in a series of sarcoma patients. A further aim was to document the complication rate associated with this technique in these patients.

Materials and methods

Prior to commencing the study approval was obtained from the Royal Marsden Hospital Audit Committee. A retrospective search of a prospectively maintained database was made to identify sarcoma patients treated with RFA between October 2003 and April 2009. Patients who received their systemic therapy and were treated with RFA whilst receiving systemic therapy at the Royal Marsden were included in the analysis. Patients who had received RFA at other institutions and were referred to the Royal Marsden for further therapy or for a second opinion were excluded from the analysis. Patient demographics, histological subtype, treatment and survival data were obtained from the database. The time from diagnosis to ablation was also obtained from the database as well as systemic and other local therapies administered. Toxicity was retrospectively ascertained from the Royal Marsden electronic patient record. The number and size of lesions ablated was reviewed and the time to progression at ablated sites.

As per Royal Marsden Sarcoma Unit protocol, the histological diagnosis was confirmed by a sarcoma pathologist on referral (KT, CF).

RFA

RFA was performed by two experienced interventional radiologists (JM, AA). A baseline CT was performed prior to the procedure. Response was assessed by CT scan approximately 3 months post procedure unless otherwise indicated. The date of progression at the ablated site and systemic progression were recorded. Complications

were documented following the procedure on the Royal Marsden electronic patient record system.

Selection of GIST (gastro intestinal stromal tumour) patients for hepatic RFA was based on the appearance of progression at one site on the background of otherwise stable metastatic disease.

Selection of other sarcoma patients for RFA was based on the uncertainty of obtaining systemic disease control and the need for treating specific hepatic or pulmonary lesions, in order to obtain local control without subjecting a patient to surgery.

Statistical analysis

Follow-up data was available up to 20th April 2009.

The GIST patients represented a homogenous group and therefore they were analysed separately from the patients with other sarcomas. Survival was determined by the Kaplan-Meier method and measured from the date of RFA until death from any cause and censored at last follow-up. Time to progression at the RFA site was measured from the start of RFA until a documented progression at the treated site. RFA episodes without progression were omitted from the analysis of progression. Differences between GIST and other histological subgroups were assessed by the logrank test.

Results

A total of 38 patients were identified of whom 13 had undergone RFA prior to referral to the Royal Marsden Hospital. Therefore, twenty-five patients treated with RFA were

analysed (17 males and 8 females). The median age of these patients was 54 years (range 33-75) and the median follow-up was 21 months (range 2-60).

GIST patients

Thirteen GIST patients with liver metastases were treated with RFA. The median age of these patients was 59 years (range 37-75): there were 12 males and 1 female. Eleven patients had surgical resection of the primary tumour at diagnosis and two presented with metastatic disease. Of these 13, one underwent a liver resection prior to hepatic RFA. The GIST patients received a median of 2 lines of systemic therapy (range 1–6). At the time of analysis 2 of these patients had died and 11 were still alive with a median follow-up of 26 months.

Response and toxicity in GIST patients

Of the 13 GIST patients treated with RFA, 12 achieved a response at the RFA site and one stable disease following the first RFA procedure. One patient had two liver lesions ablated during the same procedure, all the others underwent RFA to one lesion. The site and number of liver lesions ablated at first RFA, along with the response and complications are illustrated in Table 1.

Two patients received RFA on two occasions to separate lesions within the liver and both responded to the second RFA procedure.

All of these patients were treated with systemic therapy, 12 GIST patients underwent RFA whilst receiving first-line systemic therapy in the form of imatinib. The other patient underwent RFA whilst receiving re-challenge with imatinib 400 mg per day.

Two patients developed infections post procedure (one at the RFA site) and one developed atrial fibrillation with a rapid ventricular response. All three patients were treated with appropriate medical therapy and made a prompt recovery. One of the patients treated with two separate RFA procedures developed sepsis post second RFA.

Time to progression and overall survival in GIST patients

The median time to progression from date of ablation to progression at RFA site was 28 months, see Figure 1.

The median time to progression at other sites from date of RFA was 26 months (95%CI, 1-51). At the time of analysis, 7 patients were on first-line imatinib and a further 6 patients continued on first-line therapy for a median of 11 months (range 3-28) following RFA.

The 2-year overall survival from start of RFA was 77% (95%CI 35-94%), see Figure 2. Median survival for this group of patients has not been reached.

Other sarcomas

Twelve patients with other sarcomas (i.e. not GIST) were treated with RFA, 7 to the liver and 5 to the lung. The median age of these patients was 50 years (range 33-71), there were 5 males and 7 females. The most common histological subtype was leiomyosarcoma (n=5) followed by chondrosarcoma (n=2) and fibrosarcoma (n=2). Eleven of these patients underwent surgical resection of the primary tumour and one received radical radiotherapy to a primary malignant fibrous histiocytoma in the left popliteal fossa. Two patients underwent one further surgical resection for recurrent or

metastatic disease, one patient underwent two such procedures and 5 patients had a total of 3 separate operations for recurrent or metastatic disease. Two of these patients had not received systemic therapy at the time of analysis. Of the 12 sarcoma patients, five received one line of systemic therapy, two received 2 lines and three received 3 lines of therapy. At the time of analysis, 6 patients had died and 6 were alive.

Response and toxicity in other sarcoma patients

Of the 7 patients with liver metastases, 5 of these patients responded to RFA and one patient displayed progression at the RFA site on the post procedure scan. One patient was not assessable for response at the time of analysis (Table 2). Two of these patients displayed progression elsewhere on the 3 month post procedure CT scan.

One patient received 3 separate RFA treatments and responded on all 3 occasions. One patient received 4 separate RFA procedures and another 12 separate procedures. No toxicity was recorded following these multiple procedures.

All patients with lung metastases achieved a response following their first RFA procedure, and 2 displayed progression at other sites between 3–5 months post procedure.

Two of the patients with lung metastases were treated twice with RFA to separate lesions within the lung, one of whom displayed progression at the ablated site post procedure.

One patient underwent 1 thoracotomy and 3 underwent 2 separate thoracotomies prior to RFA. In addition, 3 patients underwent one thoracotomy, each, following RFA.

One patient developed a small pneumothorax post first RFA procedure, which did not require any medical intervention. Another patient had a pneumothorax following the

second RFA of a lung metastasis and this again did not require the insertion of a chest drain.

Time to progression and overall survival in other sarcoma patients

The median follow-up was 11 (range 2-54) months.

The median time to progression at RFA site (following first ablation) for patients with the other soft tissue tumours was 9 months (95%CI, 8-10 months), see Figure 1.

The median time to progression at other sites from date of RFA was 8 months (95%CI, 4-11).

The 2 year overall survival from RFA in this cohort 40% (95%CI, 10-70%), and the median overall survival from RFA was 19 months (95%CI, 12-26 months), see Figure 2.

GIST patients had significantly longer time to progression at RFA site (median time to progression 28 months, 95% CI undefined) compared to the combined group of patients with other sarcomas (9 months, 95% CI, 8-10 months). No significant difference in time to progression at other sites following RFA was observed between the GIST and the non-GIST group ($p=0.2$). However, GIST patients had significantly longer overall survival from RFA compared to the other group ($p=0.01$).

Discussion

Our study of a small series of sarcoma patients treated with RFA to the liver and lung indicates that this treatment modality may have a role in these conditions. Patients with GIST who have stable systemic disease on a tyrosine kinase inhibitor but have

progression at one metastatic site (presumably due to a resistant clone) seem particularly suitable for RFA. Consequently, RFA can delay a change in systemic therapy by achieving local control at the site of solitary disease progression in such patients.

In other sarcomas the role of RFA is less clear, but it could be of value in a subgroup of patients deemed potentially resectable but not operable due to concurrent medical conditions. Of the 11 non-GIST patients assessable for response one progressed at the RFA on the post procedure scan. A further 4 achieved disease control at ablated sites but displayed progression elsewhere 3-5 months post procedure. This technique could potentially be offered to sarcoma patients who are symptomatic due to a solitary localized area of disease.

Our small exploratory study was retrospective and therefore any results must be interpreted with caution. We observed that GIST patients had significantly longer time to progression at ablation site compared to patients with other sarcomas. Furthermore, GIST patients had significantly longer overall survival from RFA compared to the group of other sarcoma subtypes. This is possibly explained by the heterogeneous nature of the non-GIST group who had received multi modality therapy consisting of surgery, chemotherapy and radiotherapy for metastatic disease. Additionally, this group consisted of patients who had received RFA for lung and liver metastases.

RFA was well tolerated in our series of patients treated by experienced interventional radiologists. All toxicities were easily manageable. Of the 20 patients who underwent RFA to the liver, two developed infections and one atrial fibrillation. Both patients who developed infections were treated appropriately with no long-term complications. Of the 5 patients treated with RFA for lung metastases, the presence of a small post-procedural

pneumothorax was observed in two patients and neither required insertion of a chest drain.

RFA studies including sarcoma patients

A number of other retrospective studies have included sarcoma patients treated with RFA to the liver³⁻⁵ and lung,⁶⁻⁹ but few have specifically analysed the value of this technique in sarcoma.

A study by Pawlik et al examined the role of hepatic resection and/ or RFA in a cohort of 66 sarcoma patients with metastatic disease in the liver.³ RFA alone was performed in 13 patients (19.7%) who had metastases in unresectable locations and in combination with surgery in 18 patients (27.3%). In their retrospective study, these authors found that patients treated with RFA alone or in combination had significantly worse disease-free survival (7.4 months) compared to those treated with surgical resection alone (18.6 months). However, they found no significant difference in overall survival between the cohort treated with RFA and surgical resection alone.

A retrospective study by Berber and colleagues assessed the value of laparoscopic RFA in 53 patients with non colorectal or hepatocellular cancers.¹⁰ Eighteen sarcoma patients were included in this study with liver only metastatic disease. The median survival of sarcoma patients following hepatic RFA in the study by Berber *et al* was 25 months. Most of these patients had GIST all though the exact breakdown by histological subtype was not published.

Other ablative techniques

A number of other image-guided catheter-based therapies are available for the treatment of hepatic metastases, which include transcatheter arterial chemoembolisation (TACE), transcatheter arterial embolisation (TAE) and TAE with drug eluting beads.² Hepatic artery embolisation/ chemoembolisation were originally developed as therapy for unresectable hepatocellular carcinoma.¹¹ The liver receives dual blood supply from the portal vein and hepatic artery, whereas hepatocellular carcinomas are supplied only by the hepatic artery. Consequently, embolisation of the hepatic artery produces selective ischaemic necrosis of the tumour while sparing the surrounding normal liver parenchyma. Furthermore, the effect of a relatively small dose of a conventional chemotherapeutic agent, administered to the region, followed by embolisation may increase the efficacy of chemotherapy. Mavligit and colleagues reported, in 1995, on the use of hepatic chemoembolisation in a series of 14 patients with hepatic metastases secondary to gastrointestinal leiomyosarcoma (which would now be classified as gastrointestinal stromal tumours).¹² Ten (70%) of these patients experienced a major regression (>50%), which were maintained for a median of 12 months, following an average of two hepatic chemoembolisation procedures. Shima et al treated 4 GIST patients with liver metastases with hepatic artery chemoembolisation.¹³ Three of these patients died of disease 17, 23 and 28 months following chemoembolisation and one was still alive 7 months after the procedure. There have also been reports of arterial chemoembolisation in localized osteosarcoma¹⁴ and hepatic angiosarcoma.^{15,16}

Percutaneous ethanol injection involves introducing single or multiple fine needles into the metastatic lesion and injecting ethanol (90-100%), thus causing cell death mainly by

dehydration.¹⁷ A randomized trial of 232 patients with small hepatocellular carcinomas demonstrated those treated with radiofrequency ablation to have significantly longer survival compared to those treated with percutaneous ethanol injection.¹⁸ In addition, there are a number of alternative percutaneous thermal ablation techniques to treat patients with primary liver tumours and/ or metastases. Laser-induced thermotherapy uses optical fibres to deliver high energy laser radiation to the target region.¹⁹ Microwave coagulation therapy involves the introduction of a thin microwave antenna directly into the tumour.²⁰ With the use of a microwave generator an electromagnetic wave is emitted through the exposed, non-insulated part of the antenna. This agitates water molecules in the surrounding tissue, which produces friction and heat and subsequently cell death by coagulative necrosis. In another technique, cryotherapy, the lesion is frozen by the introduction of liquid nitrogen or argon.¹⁷

Conclusion

Our study has shown that RFA is feasible, tolerable and effective in the multimodality management of patients with metastatic sarcoma if the goal of therapy is local disease control. This technique has shown particular promise in GIST, and further prospective evaluation is required to confirm our preliminary findings. RFA is also a feasible therapeutic option in patients with other sarcoma subtypes with localised disease, in whom local disease control can be achieved without surgery. However, the exact role of RFA in such conditions remains to be defined, as systemic disease control often proves difficult, and further assessment in a larger cohort of patients is warranted.

References

1. Clark MA, Fisher C, Judson I, Thomas JM. Soft-tissue sarcomas in adults. *N Engl J Med.* 2005;353(7):701-11.
2. Liapi E, Geschwind JF. Transcatheter and ablative therapeutic approaches for solid malignancies. *J Clin Oncol.* 2007;25(8):978-86.
3. Pawlik TM, Vauthey JN, Abdalla EK, Pollock RE, Ellis LM, Curley SA. Results of a single-center experience with resection and ablation for sarcoma metastatic to the liver. *Arch Surg.* 2006;141(6):537-43; discussion 543-4.
4. Amersi FF, McElrath-Garza A, Ahmad A, Zogakis T, Allegra DP, Krasne R, et al. Long-term survival after radiofrequency ablation of complex unresectable liver tumors. *Arch Surg.* 2006;141(6):581-7; discussion 587-8.
5. Hildebrand P, Kleemann M, Roblick UJ, Mirow L, Birth M, Leibecke T, Bruch HP. Radiofrequency-ablation of unresectable primary and secondary liver tumors: results in 88 patients. *Langenbecks Arch Surg.* 2006;391(2):118-23.
6. Yasui K, Kanazawa S, Sano Y, Fujiwara T, Kagawa S, Mimura H, et al. Thoracic tumors treated with CT-guided radiofrequency ablation: initial experience. *Radiology.* 2004;231(3):850-7.
7. Suh RD, Wallace AB, Sheehan RE, Heinze SB, Goldin JG. Unresectable pulmonary malignancies: CT-guided percutaneous radiofrequency ablation—preliminary results. *Radiology.* 2003;229(3):821-9.
8. Strauss S, Gillams A., Seddon, B., Jordan, S., Ladas, G., Lees, W., Whelan, J. Radiofrequency Ablation (RFA) of pulmonary metastases is safe and feasible in patients with relapsed bone and soft tissue sarcoma. British Sarcoma Group Meeting Glasgow, 2009.
9. Nakamura T, Matsumine A, Yamakado K, Matsubara T, Takaki H, Nakatsuka A, et al. Lung radiofrequency ablation in patients with pulmonary metastases from musculoskeletal sarcomas: an initial experience (R#2). *Cancer* 2009;115(16):3774-81.
10. Berber E, Ari E, Herceg N, Siperstein A. Laparoscopic radiofrequency thermal ablation for unusual hepatic tumors: operative indications and outcomes. *Surg Endosc* 2005;19(12):1613-7.
11. Yamada R, Sato M, Kawabata M, Nakatsuka H, Nakamura K, Takashima S. Hepatic artery embolization in 120 patients with unresectable hepatoma. *Radiology* 1983;148(2):397-401.
12. Mavligit GM, Zukwiski AA, Ellis LM, Chuang VP, Wallace S. Gastrointestinal leiomyosarcoma metastatic to the liver. Durable tumor regression by hepatic chemoembolization infusion with cisplatin and vinblastine. *Cancer.* 1995;75(8):2083-8.
13. Shima Y, Horimi T, Ishikawa T, Ichikawa J, Okabayashi T, Nishioka Y, Hamada M, Shibuya Y, Ishii T, Ito M. Aggressive surgery for liver metastases from gastrointestinal stromal tumors. *J Hepatobiliary Pancreat Surg.* 2003;10(1):77-80.
14. Chu JP, Chen W, Li JP, Zhuang WQ, Huang YH, Huang ZM, et al. Clinicopathologic features and results of transcatheter arterial chemoembolization for osteosarcoma. *Cardiovasc Intervent Radiol.* 2007;30(2):201-6.

15. Stambo GW, Guiney MJ. Hepatic angiosarcoma presenting as an acute intraabdominal hemorrhage treated with transarterial chemoembolization. *Sarcoma*. 2007;2007:90169.
16. Park YS, Kim JH, Kim KW, Lee IS, Yoon HK, Ko GY, et al. Primary hepatic angiosarcoma: imaging findings and palliative treatment with transcatheter arterial chemoembolization or embolization. *Clin Radiol*. 2009;64(8):779-85.
17. Evans J. Ablative and catheter-delivered therapies for colorectal liver metastases (CRLM). *Eur J Surg Oncol*. 2007;33 Suppl 2:S64-75.
18. Shiina S, Teratani T, Obi S, Sato S, Tateishi R, Fujishima T, et al. A randomized controlled trial of radiofrequency ablation with ethanol injection for small hepatocellular carcinoma. *Gastroenterology*. 2005;129(1):122-30.
19. Vogl TJ, Straub R, Eichler K, Woitaschek D, Mack MG. Malignant liver tumors treated with MR imaging-guided laser-induced thermotherapy: experience with complications in 899 patients (2,520 lesions). *Radiology*. 2002;225(2):367-77.
20. Seki T, Wakabayashi M, Nakagawa T, Itho T, Shiro T, Kunieda K, et al. Ultrasonically guided percutaneous microwave coagulation therapy for small hepatocellular carcinoma. *Cancer*. 1994;74(3):817-25.

Table 1. Response, complications, size and number of liver metastases treated with RFA in GIST patients.

Patient number	Site	Number of lesions ablated	Size (mm)	Response	Complication
1	Posterior right lobe	One	<10	Response	Sepsis
2	Segment 2	One	25	Response	None
3	Segment 7 + 5	Two	25 + 6	Response	None
4	Segment 6	One	40	Response	None
5	Segment 5/8	One	35	Response	None
6	Segment 6	One	42	Response	Atrial fibrillation
7	Left lobe	One	32	Response	None
8	Segment 8	One	39	Response	None
9	Segment 4a	One	11	Response	None
10	Segment 4a	One	21	Response	None
11	Segment 7/8	One	30	Response	Infection RFA cavity
12	Segment 5	One	20	Response	None
13	Segment 8	One	15	Response	None

Table 2. Location, number, size, response and complications in other sarcoma patients treated with radio frequency ablation.

Patient Number	Histology	Site ablated	Number of lesions ablated	Size of lesions ablated (mm)	Response	Complications
14	LMS	Liver – posterior right lobe	1		Response	None
15	LMS	Liver			PD	None
16	LMS	Liver – segment 4a	1	20	Response	None
17	Fibrosarcoma	Liver – right lobe	1	30	Response	None
18	SFT	Liver	5		Response	None
19	Synovial sarcoma	Liver – segments 4a + 8	2	25	Response	None
20	LMS	Liver – segment 4a	1	23	Not assessable for response	None

					at the time of analysis	
21	LMS	Lung - right lower lobe	2	20 + 9	Response	None
22	Fibrosarcoma	Lung - right upper lobe	2	18 + 11	Response	None
23	CS	Lung - right upper lobe				Small left pneumothorax
24	CS	Lung - bilateral	3	23, 12 and <5	Response	None
25	Malignant fibrous histiocyoma	Lung - left mid zone	1	14	Response	None

Abbreviations: PD – progressive disease. LMS – leiomyosarcoma. SFT – solitary fibrous tumour. CS- chondrosarcoma.

Figure 1. Time to progression at first radiofrequency ablation site for gastrointestinal stromal tumours and other histological subtypes.

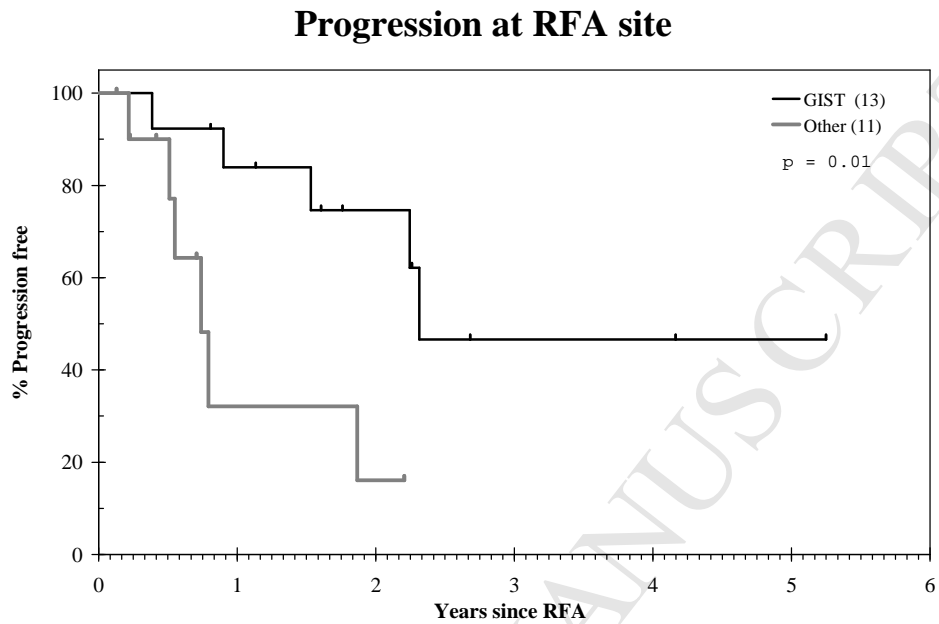


Figure 2. Overall survival from RFA for gastrointestinal stromal tumours and other histological subtypes.

