HAL
open science

Immunohistochemical detection of arginine methylated proteins (MeRP) in archival tissues

Marzia Vezzalini, John M Aletta, Stefania Beghelli, Eisabetta Moratti, Marco Della Peruta, Andrea Mafficini, Wilfrido D. Mojica, Aldo Mombello, Aldo Scarpa, Claudio Sorio

To cite this version:

Marzia Vezzalini, John M Aletta, Stefania Beghelli, Eisabetta Moratti, Marco Della Peruta, et al.. Immunohistochemical detection of arginine methylated proteins (MeRP) in archival tissues. Histopathology, 2010, 57 (5), pp.725. 10.1111/j.1365-2559.2010.03684.x . hal-00593449

HAL Id: hal-00593449

https://hal.science/hal-00593449

Submitted on 16 May 2011

HAL is a multi-disciplinary open access archive for the deposit and dissemination of scientific research documents, whether they are published or not. The documents may come from teaching and research institutions in France or abroad, or from public or private research centers.

L'archive ouverte pluridisciplinaire **HAL**, est destinée au dépôt et à la diffusion de documents scientifiques de niveau recherche, publiés ou non, émanant des établissements d'enseignement et de recherche français ou étrangers, des laboratoires publics ou privés.

Histopathology

Immunohistochemical detection of arginine methylated proteins (MeRP) in archival tissues

Journal:	*Histopathology*
Manuscript ID:	HISTOP-12-09-0672
Manuscript Type:	Original Article
Date Submitted by the Author:	03-Dec-2009
Complete List of Authors:	Vezzalini, Marzia; University of Verona, Department of Pathology Aletta, John; CH3 BioSystems LLC, New York State Center of Excellence in Bioinformatics & Life Sciences Beghelli, Stefania; University of Verona, Department of Pathology Moratti, Eisabetta; University of Verona, Department of Pathology Della Peruta, MArco; University of Verona, Department of Pathology Mafficini, Andrea; University of Verona, Department of Pathology Mojica, Wilfrido; University at Buffalo, Department of Pathology Mombello, Aldo; University of Verona, Department of Pathology Scarpa, Aldo; University of Verona, Department of Pathology Sorio, Claudio; University of Verona, Department of Pathology
Keywords:	Methylarginine, cancer, PRMT, immunohistochemistry, normal tissue

scholarONE™
Manuscript Central

Immunohistochemical detection of arginine methylated proteins (MeRP) in archival tissues

Marzia Vezzalini[1], John M. Aletta[2], Stefania Beghelli[3], Elisabetta Moratti[1], Marco Della Peruta[1], Andrea Mafficini[3], Wilfrido D. Mojica[4], Aldo Mombello[1], Aldo Scarpa[1,3] and Claudio Sorio[1,3*]

[1]Department of Pathology, University di Verona, Verona, Italy

[2]CH3 BioSystems LLC, New York State Center of Excellence in Bioinformatics & Life Sciences, Buffalo, New York 14203, USA

[3]ARC-NET Center for Applied Research on Cancer, Hospital Concern and University School of Medicine, Verona, Italy

[4] Department of Pathology, University at Buffalo, New York 14203, USA

Running title: In situ analysis of Methylarginine

Keywords: Methylarginine, PRMT, immunohistochemistry, cancer, normal tissue

*Corresponding author for page proofs, correspondence and requests for reprints

Dr. Claudio Sorio, Department of Pathology, University of Verona, Strada Le Grazie 8, 37134 Verona, Italy Tel: +39-045-8027688, Fax: +39-045-8027127, e-mail: claudio.sorio@univr.it

For Peer Review

Support: This study was supported by Associazione Italiana Ricerca sul Cancro (AIRC) Veneto Region Grant, Milan, Italy; Fondazione Cariparo, Padova, Italy; Ricerca Sanitaria Finalizzata Regione Veneto; Ministero della Salute - project RF-EMR-2006-361866; European Community FP6 "MolDiagPaca".

Disclosure: JMA is a co-founder and the Principal Scientist of CH3 BioSystems LLC. He is named as inventor on USPTO 6699673, "Protein Methylarginine-Specific Antibodies" and on the provisional patent application "Methylarginine Detection in Cells and Tissues".

For Peer Review

ABSTRACT (195 words)

Aims: i) To determine if methylarginine-specific antibodies can be employed for standard immunohistochemical analysis of paraffin-embedded tissues, ii) analyze methylarginine expression in normal and neoplastic tissues, and iii) correlate methylarginine expression with that of PRMT1, the predominant cellular arginine methyltransferase.

Methods and Results: Immunohistochemical staining of normal and cancer tissues utilizing three commercial polyclonal antibodies: anti-mRG raised against a methylarginine peptide, anti-RG, a control antiserum raised against a corresponding arginine peptide without any methylated residues, and anti-PRMT1.

Nuclear and/or cytoplasmic methylarginine expression was detected in all keratinized and non-keratinized epithelia. A preliminary survey of a series of thyroid, pancreatic, colon and gastric cancers identified a different pattern of methylarginine expression in comparison with normal tissue. A correlation between methylarginine staining and PRMT1 expression was found in all normal and cancer tissues analyzed.

Conclusion: This study reports for the first time that methylarginine-specific antibodies are capable of recognizing MeRP in paraffin-embedded tissues. Methylarginine proteins are widely expressed and show differences in subcellular localization in various organs and neoplastic conditions. The efficient detection of methylproteins by standard immunohistochemistry demonstrated in this study provides a new tool to investigate the role of MeRP in biological processes including carcinogenesis.

For Peer Review

INTRODUCTION

Proteins containing methylarginine residues have been implicated in a wide variety of human diseases, but the detection of methylarginine proteins (MeRP) in normal and pathological tissue specimens has not been reported.

The post-translational methylation of arginine has been described for proteins that exert an important role in transcriptional regulation[1-3]. The modification of arginine side chain guanidino groups is quantitatively one of the most extensive post-translational modifications of proteins in mammalian cells[4, 5]. The protein arginine methyltransferase (PRMT) family of enzymes is responsible for the methyl-transfer reaction using S-adenosyl-L-methionine as the methyl donor. These enzymes catalyze the formation of mono-methylarginine and asymmetric or symmetric di-methylarginine in mammalian cells. Six genes with PRMT catalytic subunits are known to date (PRMT1, 3, 4, 5, 6, and 8) and three other genes encode sequence-related proteins with possible methyltransferase activities (PRMT2, 7, and 9)[6, 7]. The number of distinct modified proteins is also diverse[8]. Further diversity of the methylation reactions occurring in living cells is added by alternative splicing mechanisms[9]. Individual members of the PRMT family differ in abundance, activity, substrate specificity and intracellular localization indicating non-redundant roles *in vivo*. The predominant member of the PRMT family, PRMT1, is an essential enzyme responsible for approximately 85% of all arginine methylation reactions in human and mouse cells[10-12]. PRMT1 generally recognizes arginines within a glycine-arginine-rich (GAR) region, a motif present in many RNA- and DNA-binding proteins.

For Peer Review

Based on the rapid expansion of biomedical research implicating methylarginine proteins in gene expression and other fundamental biological functions, the study of protein arginine methylation holds great promise for extending our understanding of human developmental and pathological processes[13, 14]. Antibodies have been developed that specifically recognize a canonical methylarginine peptide sequence and the major arginine methyltransferase in eukaryotic cells, PRMT1[15, 16]; however a method for rapid screening of the process in biological tissues is lacking. Although western blotting is a sensitive and quantitative assay that has been used to assess methylation status, it is not suited for high-throughput analysis.

Here we report that methylarginine proteins may be detected by immunohistochemistry on archival tissues using available commercial antibodies and describe for the first time the distribution of MeRPs in normal tissue. We also provide evidence of altered expression/redistribution of MeRP in neoplastic tissues.

For Peer Review

MATERIALS AND METHODS

Tissues

Formalin-fixed paraffin-embedded human normal and cancer tissues were retrieved from the archives of the Department of Pathology of the University of Verona.

Antibodies

The IgG-purified rabbit antibodies used in this work have been described[15, 16]. They were polyclonal rabbit anti-mRG, anti-RG (CH3 BioSystems LLC, Buffalo, NY) and anti-PRMT1 IgG purified by Protein A Sepharose chromatography[17] (a generous gift from Dr. Harvey Herschman, UCLA).

Western blotting

Human normal tissues were frozen in liquid nitrogen vapors and stored at –80°C. Fifteen to 30 20µm cryostat sections were lysed in buffer containing 50 mM Tris pH 7.4, 1% Triton X-100, 150 mM NaCl, 200 µM $NaVO_4$, 1 mM EDTA, 1 mM DTT, 1 mM NaF, 1x final concentration Complete EDTA-free Protease Inhibitor Cocktail Tablets (Roche, Mannheim, Germany) and processed for westen blotting as described[16].

Immunohistochemistry

Four-µm thick formalin fixed-paraffin-embedded sections were placed on polylysinated slides. Antigen retrieval was performed in 10mM citrate buffer, pH 6.0 heated in microwave at 360 W for 20 min. All subsequent incubations were performed at room temperature: endogenous peroxidase and non-specific sites were blocked by incubation

For Peer Review

with 3% H_2O_2 and 10% goat serum in PBS/0.05% Tween-20 for 15 min. Sections were then incubated with anti-mRG (8 µg/ml), anti-PRMT1 (12 µg/ml) or anti-mRG (8 µg/ml), for two hours, washed three times with PBST (PBS/0.2% Tween-20), and incubated for 40 min with the appropriate secondary antibodies: EnVision+ System- HRP Labelled Polymer Anti-Rabbit (DakoEnVision+®, Peroxidase) After 3 washes with PBST, diaminobenzidine (DAB DakoCytomation Liquid DAB+ Substrate Chromogen System) was used as peroxidase substrate for 10 min.

For Peer Review

RESULTS

Western blot analysis and immunohistochemistry related to methylarginine proteins were performed by utilizing anti-mRG, anti-RG and anti-PRMT1 antisera.

mRG expression in normal human tissues analyzed by western blotting

Western blot analysis of seven normal tissues showed a wide diversity of immunoreactive methylarginine proteins of molecular masses from 30 to 250 kD detected by anti-mRG (**Figure 1**, upper panel). Although the pattern of reactive protein bands was generally similar, there were perceptible qualitative and quantitative differences among the different tissues with regard to specific protein bands. The control antibody, anti-RG, raised against the non-methylated form of the peptide used to generate anti-mRG, gave a dramatically different staining with recognition of a predominant 70 kDa protein in most tissues (Figure 1, lower panel).

These results confirmed the previously demonstrated specificity of anti-mRG[16] and indicate the existence of tissue specific variations in the methylarginine expression pattern. The distinctive differences between the anti-mRG and anti-RG western blot staining were also observed by the immunohistochemistry results presented below.

mRG and PRMT1 immunohistochemical expression in normal tissues

Specific nuclear and cytoplasmic mRG immunoreactivity was detected in epithelial and endocrine cells of various organs (**Table 1**).

For Peer Review

mRG and PRMT1 in epithelia

mRG was expressed in all the epithelia of the gastrointestinal tract, and most cells of the genito-urinary system. mRG expression was also found in breast, ducts of parotid and sweat glands, acini and ducts of pancreas, bronchioli and pneumocytes Inconsistent staining was detected in fibroblasts of the connective tissues. PRMT1 expression was generally coincident with that of mRG in the different epithelia. The exception was PRMT1 signal in liver, which was only cytoplasmic with no nuclear staining and fainter than that of mRG (**Figures 2a and 2b**).

mRG and PRMT1 in hematopoietic and lymphoid tissues

Bone marrow myeloid precursors expressed mRG at variable levels while erythroid precursors as well as megakaryocytes were negative (not shown). There was robust immunostaining associated with lymphoid germinal centers (Figure 2b). In thymus, thymocytes only stained with anti-mRG antibody and PRMT1 was undetectable while macrophagesstained strongly with both antibodies **(Figure 3).** Macrophagic elements in spleen and lymphoid follicles of the tonsil and appendix expressed high levels of both mRG and PRMT1. By contrast, lung alveolar macrophages expressed high levels of mRG but lacked PRMT1 expression (**Figure 3**).

mRG and PRMT1 in endocrine tissues

There was high mRG expression in the whole adrenal gland (Cortex shown in figure 2b), thyroid **(Figure 4)** and islets of Langerhans (**Figure 5**) and as well as other

For Peer Review

endocrine tissues. The signal intensity from methylarginine in each of these tissues was highest in nuclei.

mRG and PRMT1 in selected tumors

Looking for possible altered mRG expression associated with neoplasia we stained samples of epithelial (colon, gastric and breast) and endocrine (thyroid and pancreas) tumors. The comparison among various cancer histotypes summarized in **Table 2** revealed that most breast cancers show a high level of mRG and only a minority of cases (4.6%) shows a low level of staining; thyroid papillary cancers were always immunopositive; the overall the overall reactivity of colon, gastric and pancreatic neoplasms was about 80% positive. Various patterns of staining were detected: cytosolic, golgi-like, both nuclear and cytosolic and low/undetectable staining (**Figure- 6**). These patterns appear different from what has been observed in the corresponding normal tissues indicating an underlying heterogeneity of tumor type based on the site and intensity of methylarginine expression. We next wondered if PRMT1 expression could explain these patterns as we observed a correspondence between mRG staining and PRMT1 expression in normal tissues. We performed this analysis in pancreatic endocrine tumors (PET) where we found that the staining for mRG corresponds to the staining with anti-PRMT1 antibody in 9 of 10 cases (7 positive and 2 negative cases for both antigens) This result suggested that PRMT1 activity was responsible for the majority of the mRG signal detected. The close association between the mRG and PRMT1 staining patterns implies that reduced protein arginine methylation represent a likely molecular explanation for the differential staining in the patient specimens.

For Peer Review

DISCUSSION

We reported the application of immunohistochemistry to detect arginine methylated proteins (MeRP) in archival paraffin-embedded tissues, which provides rapid, semi-quantitative, subcellular cytological and histological data on the methylarginine status in physiologic and pathologic conditions.

Protein arginine methylation is involved in fundamental cellular functions including gene regulation, DNA repair, intracellular protein targeting and signal transduction [1, 13]. The possibility to analyze its variation in healthy and diseased tissues is of great interest and will also help in suggesting the mechanisms by which methylation modifications of proteins exert control of diverse cell functions. The intensity of mRG expression is indeed quantitatively and qualitatively variable in normal tissues, as demonstrated by western blot data and comparison of immunohistochemical staining across different tissues.

Specificity of antibodies. The antibodies used for mRG detection and control staining reactions have been validated previously by ELISA, western blot and immunoprecipitation[16]. Application of either reagent to the paraffin embedded specimens of control, normal tissue at the same immunoglobulin concentration yields dramatically different outcomes. Negligible to no staining is typical when using the control antibody. Staining alternate serial sections with anti-PRMT1, which recognizes the principal enzyme responsible for the generation of asymmetric dimethylarginine in eukaryotic cells, provides further independent and complementary assessment of antibody

For Peer Review

specificity. Using this approach we demonstrate, for example, that syncytial trophoblasts are devoid of mRG signal and do not express PRMT1. In contrast, the decidual cells are strongly positive for both antigens. The correlation of staining intensity for methylarginine and PRMT1 was demonstrated for nearly all of the other tissues analyzed and supports the conclusion that the anti-mRG antibody specifically detects asymmetric dimethyl-arginine substrates in the same cellular compartment as PRMT1. Few exceptions to this rule were observed. Namely in thymocytes and alveolar macrophages, there was strong mRG staining, but no expression of PRMT1. In different nearby cells PRMT1 was, however, present, thus excluding the occurrence of artifacts. In such cases we suspect that enzymes other than PRMT1 catalyze the addition of mRG to cell proteins, suggesting the activation of specific signalling pathways in these cell types. *Sensitivity of antibodies.* The sensitivity of the mRG detection illustrated in the data images in this report was quite favorable as suggested by a low tissue background and a resultant high signal to noise in all tissues examined. Further evidence of excellent sensitivity can be inferred by a recent study on the functional domains of the *S. pombe* Rmt3 arginine methyltransferase. Using anti-mRG to assess the ability of Rmt3 variants to methylate ribosomal protein S2 (Rps2), the authors found a relative quantitative correlation between anti-mRG staining of native Rps2 methylated by the Rmt3 variants and in vitro radioactive methylation of Rps2 by the same series of recombinant Rmt3 variants [18].

Observations on normal tissues. MeRP detectable with anti-RG antibody were widely but not ubiquitously distributed. For example, high expression was detected in germinal centers while the surrounding lymphocytes are negative. This indicates that B

For Peer Review

cell differentiation/proliferation was associated with the increase of mRG levels. This situation is reminiscent of the role of arginine methylation in the epigenetic transcription events associated with myeloid cell differentiation[19]. The differences in subcellular distribution, along with likely differences of methylation reactions in different normal tissues, will need to be addressed by future studies in order to understand better the possible physiopathological relevance of these findings. An initial step toward this direction was the comparative analysis among normal and neoplastic cells derived from the same tissues presented here and discussed in the following section.

Observations on neoplasia: The distribution of mRG expression in carcinoma was of particular interest given recent observations regarding the involvement of PRMTs in genome stability[20], DNA repair[21] and oncogenesis[22]. The discovery that mRG of p53 is required for the regulation of its activity[3, 23] further highlights the potential importance of the signaling pathways regulated by this post-translational modification in tumors. The potential use of mRG immunohistochemistry for the study of alterations in protein arginine methylation in primary tumors was suggested by the differential staining observed between normal and neoplastic tissues. Moreover and at variance with the matched normal tissue, cancer showed heterogeneous mRG staining characteristics, both quantitative and qualitative, including perinuclear golgi-like staining or different nuclear-to-cytosol ratio, hyper- or hypo-expression (**Figures 4 to 6**). Several possible molecular alterations that may occur as a consequence of tumorigenesis could give rise to the heterogeneity of tumor staining. Hypo- or, perhaps, hyper-methylation of constitutive protein substrates may lead to aberrant targeting of the methylprotein[24]. Variant alternatively spliced forms of PRMT1[9] may also influence the staining characteristics of

For Peer Review

mRG and, lastly, differential effects of putative protein arginine demethylases[25] may play some role in mRG staining.

Considered together, our results imply that mRG levels are differentially regulated in different tumor types and might thus play various roles in in neoplastic transformation, according to the pathways specific for individual tumor histotypes. This speculation is supported by the observation that gastrointestinal tract and pancreatic endocrine tumors share a similar level of mRG down-regulation (between 20 to 30%) at variance with breast (4.6%) and thyroid papillary cancers (0%).

Finally, it is important to recognize the limitations of the method that we describe. Since the immunogen used was a repetitive methylation motif common to the majority of methylarginine proteins, a large number of reactive methylarginine proteins could be expected to react with the antibody. We have not formally determined whether the antibody recognizes only asymmetric dimethylarginine or mono-methylarginine and symmetric dimethylarginine as well. We also could not exclude the remote possibility that the antibody will react with free asymmetric dimethylarginine that is not part of a protein amide bonded backbone. The issues of methyl-type specificity will be addressed by future biochemical studies.

In conclusion, this study demonstrated that anti-methylarginine and anti-PRMT1 antibodies can specifically detect the respective antigens in paraffin embedded tissues and can reveal alteration in the expression/processing of mRG. The procedure can be utilized for the study of archival material and the screening of large collections of normal and diseased tissues and, thus, contribute to a greater understanding of the pathophysiological role of arginine methylation.

For Peer Review

REFERENCES

1. Lee YH, Stallcup MR. Minireview: protein arginine methylation of nonhistone proteins in transcriptional regulation. *Mol Endocrinol* 2009;23;425-433.

2. Litt M, Qiu Y, Huang S. Histone arginine methylations: their roles in chromatin dynamics and transcriptional regulation. *Biosci Rep* 2009;29;131-141.

3. Chen Y, Zhou X, Liu N *et al.* Arginine methylation of hnRNP K enhances p53 transcriptional activity. *FEBS Lett* 2008;582;1761-1765.

4. Paik WK, Kim S. *Natural occurrence of various methylated amino acid derivatives.* . New York: John Wiley & Sons, 1980;8-25.

5. Najbauer J, Johnson BA, Young AL, Aswad DW. Peptides with sequences similar to glycine, arginine-rich motifs in proteins interacting with RNA are efficiently recognized by methyltransferase(s) modifying arginine in numerous proteins. *J Biol Chem* 1993;268;10501-10509.

6. Bedford MT. Arginine methylation at a glance. *J Cell Sci* 2007;120;4243-4246.

7. Fisk JC, Sayegh J, Zurita-Lopez C *et al.* A type III protein arginine methyltransferase from the protozoan parasite Trypanosoma brucei. *J Biol Chem* 2009;284;11590-11600.

8. Pahlich S, Zakaryan RP, Gehring H. Protein arginine methylation: Cellular functions and methods of analysis. *Biochim Biophys Acta* 2006;1764;1890-1903.

9. Goulet I, Gauvin G, Boisvenue S, Cote J. Alternative splicing yields protein arginine methyltransferase 1 isoforms with distinct activity, substrate specificity, and subcellular localization. *J Biol Chem* 2007;282;33009-33021.

For Peer Review

10. Pawlak MR, Scherer CA, Chen J, Roshon MJ, Ruley HE. Arginine N-methyltransferase 1 is required for early postimplantation mouse development, but cells deficient in the enzyme are viable. *Mol Cell Biol* 2000;20;4859-4869.

11. Pawlak MR, Banik-Maiti S, Pietenpol JA, Ruley HE. Protein arginine methyltransferase I: substrate specificity and role in hnRNP assembly. *J Cell Biochem* 2002;87;394-407.

12. Tang J, Kao PN, Herschman HR. Protein-arginine methyltransferase I, the predominant protein-arginine methyltransferase in cells, interacts with and is regulated by interleukin enhancer-binding factor 3. *J Biol Chem* 2000;275;19866-19876.

13. Bedford MT, Clarke SG. Protein arginine methylation in mammals: who, what, and why. *Mol Cell* 2009;33;1-13.

14. Aletta JM, Hu JC. Protein arginine methylation in health and disease. *Biotechnol Annu Rev* 2008;14;203-224.

15. Tang J, Gary JD, Clarke S, Herschman HR. PRMT 3, a type I protein arginine N-methyltransferase that differs from PRMT1 in its oligomerization, subcellular localization, substrate specificity, and regulation. *J Biol Chem* 1998;273;16935-16945.

16. Duan P, Xu Y, Birkaya B *et al.* Generation of polyclonal antiserum for the detection of methylarginine proteins. *J Immunol Methods* 2007;320;132-142.

17. Birkaya B, Aletta JM. NGF promotes copper accumulation required for optimum neurite outgrowth and protein methylation. *J Neurobiol* 2005;63;49-61.

18. Perreault A, Gascon S, D'Amours A, Aletta JM, Bachand F. A methyltransferase-independent function for Rmt3 in ribosomal subunit homeostasis. *J Biol Chem* 2009;284;15026-15037.

For Peer Review

19. Balint BL, Szanto A, Madi A *et al.* Arginine methylation provides epigenetic transcription memory for retinoid-induced differentiation in myeloid cells. *Mol Cell Biol* 2005;25;5648-5663.

20. Yu MC, Lamming DW, Eskin JA, Sinclair DA, Silver PA. The role of protein arginine methylation in the formation of silent chromatin. *Genes Dev* 2006;20;3249-3254.

21. Lake AN, Bedford MT. Protein methylation and DNA repair. *Mutat Res* 2007;618;91-101.

22. Cheung N, Chan LC, Thompson A, Cleary ML, So CW. Protein arginine-methyltransferase-dependent oncogenesis. *Nat Cell Biol* 2007;9;1208-1215.

23. Jansson M, Durant ST, Cho EC *et al.* Arginine methylation regulates the p53 response. *Nat Cell Biol* 2008;10;1431-1439.

24. Nichols RC, Wang XW, Tang J *et al.* The RGG domain in hnRNP A2 affects subcellular localization. *Exp Cell Res* 2000;256;522-532.

25. Chang B, Chen Y, Zhao Y, Bruick RK. JMJD6 is a histone arginine demethylase. *Science* 2007;318;444-447.

For Peer Review

FIGURE LEGENDS

Figure 1: Methyl-arginine expression in normal tissues by western blotting. Normal human tissues stained with anti-mRG (upper panel) and control anti-RG (lower panel) antibodies. Ponceau stain corresponding to the region of the blot between 50kDa and 70kDa (middle panel) demonstrates comparable protein loads. Molecular weight markers are shown on left. Multiple bands are present in most tissues; note the relatively lower signal present in spleen and the presence of a major band in the 50kDa range in pancreas. Control (anti-RG) antibody binds to a predominant band in the 70 kDa range weaker than that with the anti-mRG antibody; note the absence of the immunoreactive anti-RG band in spleen and the smear of weak anti-RG reactive bands between 30 to 70 kDa in pancreas.

Comment [MC1]: Speculation about proteolysis has little to no value in this context.

Figure 2a and b: Methylarginine and PRMT1 expression in normal tissues. The tissues stained are indicated on the left. Note the correspondence between the cells that stain positive for mRG and PRMT1. Objective: 20x (appendix, salivary gland), 40x all the other tissues.

Figure 3: Methylarginine and PRMT1 expression in macrophages. Spleen stained with anti-mRG antibody (A) and the control anti-RG antibody (B), 40x obj. Macrophages of the white pulp (white arrows in A) are stained by anti-mRG (A); note the presence of some tingible body macrophages of the white pulp (black arrow in B) characterized by brown pigment visible without a specific stain. On the right side are shown the myeloid

For Peer Review

cells present in the indicated tissues (A.M.: alveolar macrophage); the arrow in the lung indicates type 1 pneumocytes serving as internal positive control (63x obj); note the lack of PRMT1 staining in alveolar macrophages in comparison with macrophages in the other tissues where both antigens are expressed.

Figure 4: Methylarginine and PRMT1 expression in normal and neoplastic thyroid. Normal thyroid stained with anti mRG (A) and anti-PRMT1 (C), showing nuclear and cytosolic staining for both antigens. Thyroid papillary carcinoma (white arrow) and adjacent non-neoplastic thyroid (black arrow) stained with anti-mRG antibody show a predominant nuclear localization of mRG antigens in the latter, whereas the tumor exhibits mainly a cytosolic staining (B). Control anti-RG staining is shown in D. 20 x obj.

Figure 5: Methylarginine and PRMT1 expression in normal pancreas and in endocrine tumors. Upper panel: normal human pancreas stained with anti-RG (A) and anti-mRG antibody (B and C). The white arrow indicates a ductule in B and a Langerhans's islet in C. Anti-PRMT1 staining is shown in the inset of C (40x obj.). Lower panel, three different pancreatic endocrine tumors showing a predominant cytosolic staining (D), mixed cytosolic and nuclear staining (E), or no staining (F). 20x obj (63x obj in the insets).

Figure 6: Distinctive patterns and levels of methylarginine protein are detected in colon, gastric and breast cancers. Tumor samples stained with anti-mRG antibody. Example of a colon cancer showing cytoplasmic mRG expression (upper panel) and of a

For Peer Review

colon cancer with perinuclear/Golgi-like signal (lower panel). Examples of gastric and breast cancers with high mRG cytoplasmic expression are shown in the upper panel, and cases with a faint signal in the lower panels. The inset (63x objective) shown in the lower right image (breast cancer) displays a mitosis where mRG signal is clearly higher than that of the surrounding cells. (20x obj.)

For Peer Review

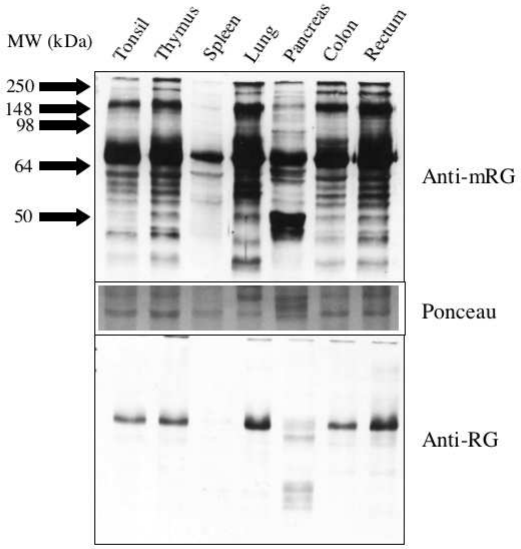
MW (kDa)
Tonsil
Thymus
Spleen
Lung
Pancreas
Colon
Rectum
250
148
98
64
50
Anti-mRG
Ponceau
Anti-RG

Review

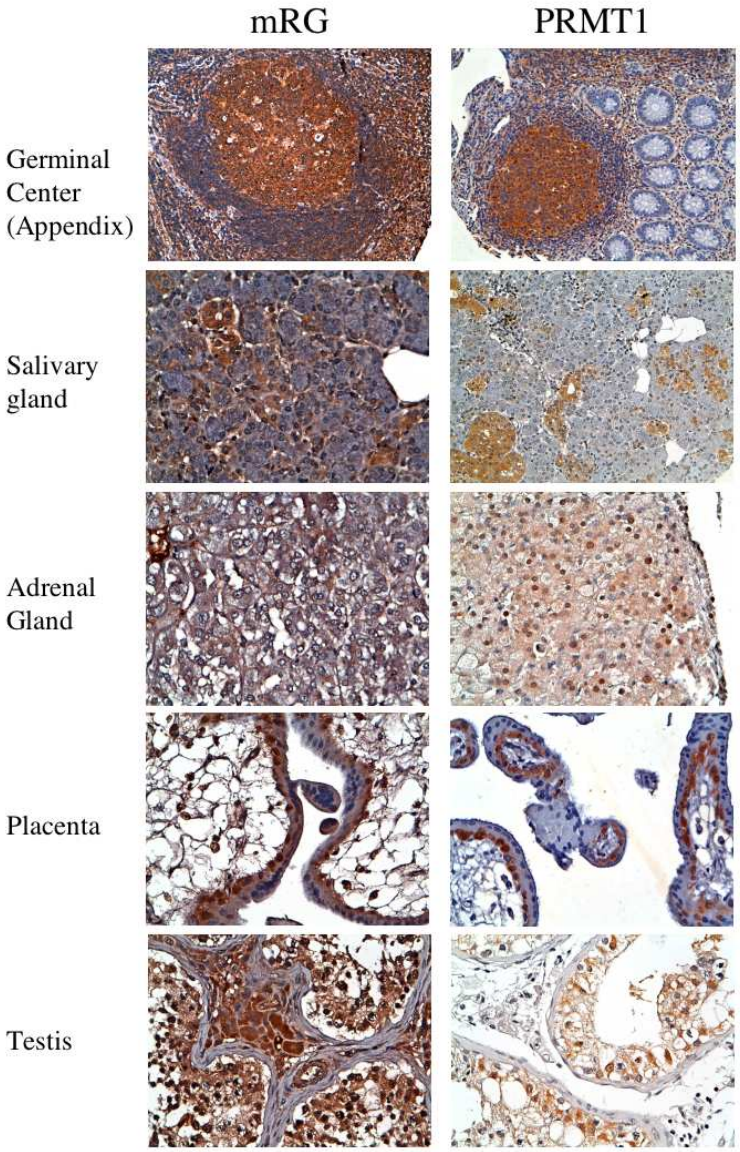
mRG
PRMT1
Germinal Center (Appendix)
Salivary gland
Adrenal Gland
Placenta
Testis

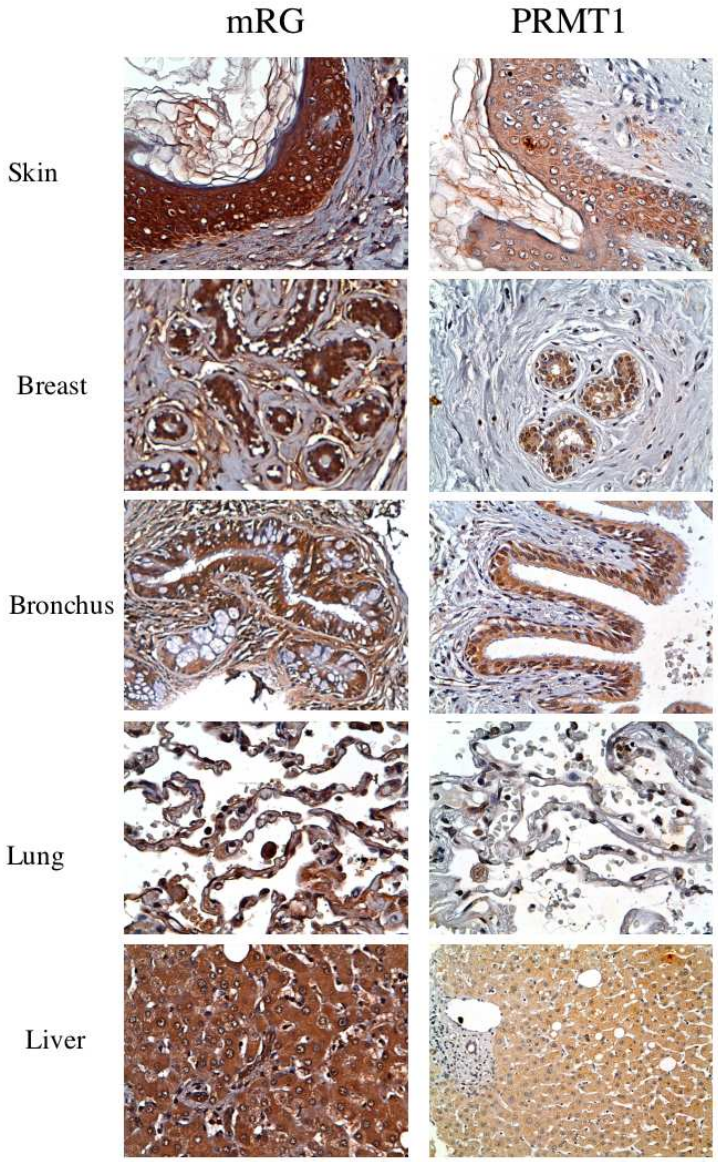
mRG
PRMT1
Skin
Breast
Bronchus
Lung
Liver

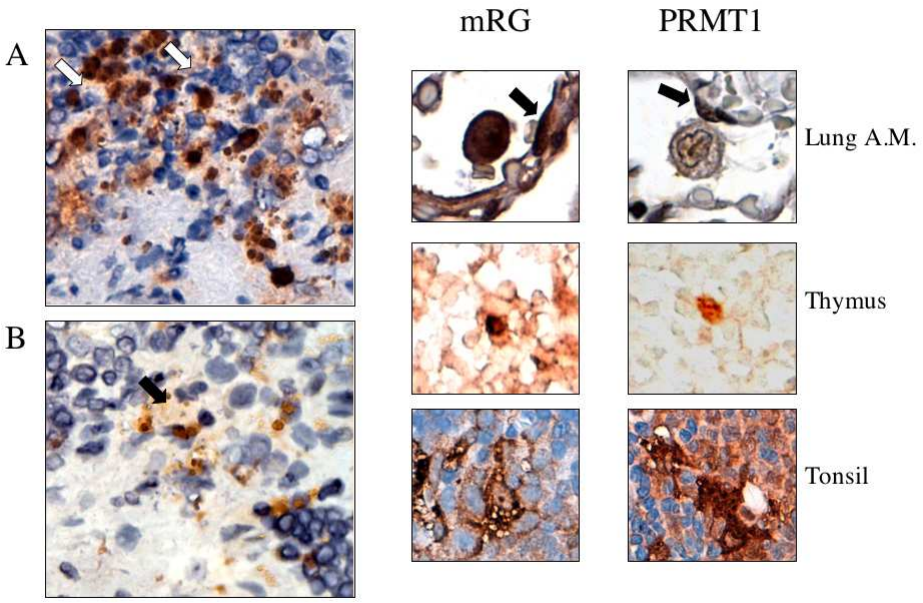

Review

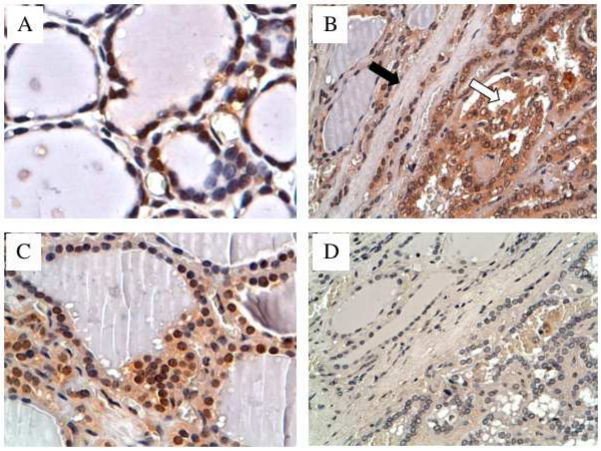

Review

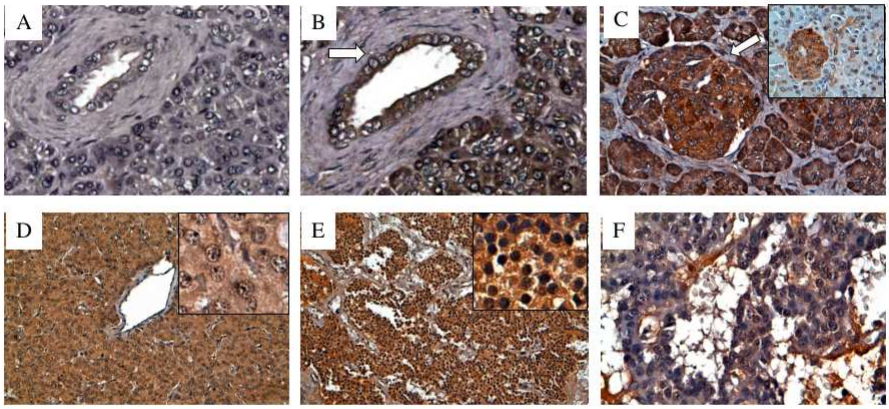

Review

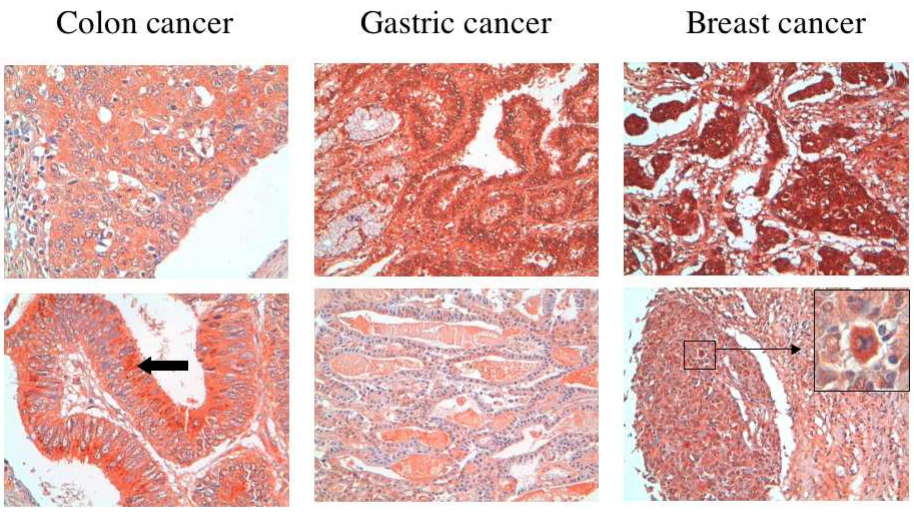

Review

Table 1: Immunohistochemical expression of mRG and PRMT1 in various tissues and cell types

Tissue	Cell type	mRG	PRMT1
Skin	Squamous epithelium	+	+
	Sweat glands	nd	nd
Parotid	Duct epithelia	+	+
	Acini	-	-
Stomach	Foveolar epithelium	+	+
	Gastric glands	+	+
Duodenum	Surface epithelium	+	+
	Brunner glands	+	+
Small bowel	Surface epithelium	+	+
Appendix	Epithelium	-	-
Large bowel	Surface epithelium	+	+
Liver	Ductules	+	+/-
	Hepatocytes	+	+/-
Gall bladder	Epithelium	+	+
	Acini	+	+
Pancreas	Ducts	+	+
	Ductules	+	+
	Islets of Langerhans	+	+
Thyroid	Thyrocytes	+	+
	Parafollicular cells	+	+
	Colloid	-	-
Parathyroid	Cells	+	+
Adrenal	Cortex	++	+*
	Medulla	+/-	+/-
Bronchus	Epithelium	+	+
	Mucinous glands	-	nd
	Serous glands	+	nd
Lung	Pneumocytes type I	+	+
	Pneumocytes type II	+	+
	Alvolar macrophages	+	-
Kidney	Tubules +	+	+
	Glomeruli -	-	-
Ureter	Epithelium	+	+**
	Smooth muscle	+/-	+/-
Testis	Germ cells	+	+
	Leydig	++	-
Prostate	Epithelial cells	+	nd
	Stromal cells	+/-	nd
Spermatic ducts	Epithelium	+	+
	smooth muscle	-	-
Ovary	Stroma	+	nd
Fallopian tube	Serous epithelium	+	nd

For Peer Review

Uterus	Epithelium	+	+
	Stroma	+/-	+/-
Placenta	Cytotrophoblast	+	+
	Syncytiotrophoblast	-	-
	Endothelium	+	+
Breast	Duct epithelia	+	+
	Lobular epithelia	+	+
	Endometrium	+	+
Bone marrow	Megakaryocytes	-	nd
	Myeloid cells	+	nd
	Erythroid precursors	-	nd
	Macrophages/DC	+	nd
Thymus	Lymphoid cells	+	nd
	Epithelial cells	+	nd
Lymphoid follicle	Germinal Center	+	+
	Mantle	-	-
	Mantle Zone	+	+
	FDC	+	+

Legend: +, positive; ++, strong positive; +/-, faint positivity; nd, not done; *, only nuclei; **, only cytoplasm, FDC: follicular dendritic cells

For Peer Review

Table 2: Expression of mRG in various neoplasms

Cancer type	Cases	positive	negative	% negative
Thyroid papillary	8	8	0	0
Breast	64	60	4	4.6
Colon	19	15	4	22
Gastric	32	25	7	21
Pancreatic ductal	25	17	8	32
Pancreatic endocrine	10	8	2	20

For Peer Review