



HAL
open science

Endobronchial Ultrasound-guided Transbronchial Needle Aspiration

Andrew Rl Medford

► **To cite this version:**

Andrew Rl Medford. Endobronchial Ultrasound-guided Transbronchial Needle Aspiration. International Journal of Clinical Practice, 2010, 64 (13), pp.1773. 10.1111/j.1742-1241.2010.02454.x . hal-00592308

HAL Id: hal-00592308

<https://hal.science/hal-00592308>

Submitted on 12 May 2011

HAL is a multi-disciplinary open access archive for the deposit and dissemination of scientific research documents, whether they are published or not. The documents may come from teaching and research institutions in France or abroad, or from public or private research centers.

L'archive ouverte pluridisciplinaire **HAL**, est destinée au dépôt et à la diffusion de documents scientifiques de niveau recherche, publiés ou non, émanant des établissements d'enseignement et de recherche français ou étrangers, des laboratoires publics ou privés.



Endobronchial Ultrasound-guided Transbronchial Needle Aspiration

Journal:	<i>International Journal of Clinical Practice</i>
Manuscript ID:	IJCP-03-10-0198.R1
Wiley - Manuscript type:	Non-Systematic Review
Date Submitted by the Author:	22-Apr-2010
Complete List of Authors:	Medford, Andrew; North Bristol Lung Centre, Respiratory Medicine
Specialty area:	



1
2
3
4 **Title Page**
5
6
7

8 **Title:** Endobronchial Ultrasound-guided Transbronchial Needle Aspiration
9

10
11 **Authors:** Medford ARL
12

13
14 **Affiliation:** North Bristol Lung Centre, Southmead Hospital, Westbury-on-Trym, Bristol BS10 5NB,
15
16 UK.
17

18
19
20 **Correspondence:** Dr Andrew RL Medford (Consultant Chest Physician),
21
22 North Bristol Lung Centre, Southmead Hospital, Westbury-on-Trym,
23
24 Bristol BS10 5NB, United Kingdom.
25

26
27 **Tel:** 01173236242
28

29 **Fax:** 01179595863
30

31 **Email:** andrewmedford@hotmail.com
32
33

34
35 **Word count:** 3560
36

37
38 **Keywords:** endobronchial ultrasound - transbronchial needle aspiration – mediastinoscopy - lung
39
40 cancer - diagnosis – staging
41
42

43
44 **Disclosures:** None to declare.
45
46
47
48
49
50
51
52
53
54
55
56
57
58
59
60

Review criteria

Information on “endobronchial ultrasound-guided transbronchial needle aspiration” (EBUS-TBNA), “endobronchial ultrasound” (EBUS), “EBUS-TBNA” or “EBUS” was gathered via a search for relevant primary and review literature in the PubMed database using the search terms “endobronchial ultrasound-guided transbronchial needle aspiration”, “endobronchial ultrasound”, “EBUS-TBNA” or “EBUS”, and a wide variety of key areas of interest (e.g. “management”, “staging”, “diagnosis”). This was then supplemented by references found within relevant selected papers and by the clinical experience of the author.

Message for the clinic

EBUS-TBNA is a new technology in bronchoscopy indicated for staging NSCLC and diagnosis of mediastinal lymphadenopathy including benign disease especially sarcoidosis and tuberculosis. It is a minimally invasive staging tool **used** as the first sampling procedure in suspected NSCLC with solitary hilar nodes, discrete N2 or N3 disease or bulky mediastinal disease. Mediastinoscopy is still recommended for clarification of EBUS-TBNA negative nodes when the pre-test probability of lung cancer is high although this may change in time. **Cost issues may limit the development of EBUS-TBNA in all centres. Conventional TBNA should still be performed and has a useful role in avoiding a proportion of mediastinoscopies.**

Introduction

Linear probe endobronchial ultrasound-guided transbronchial needle aspiration (EBUS-TBNA) offers a minimally invasive mediastinal lung cancer staging and diagnostic tool. Current surgical staging is more invasive (with rare but serious complications) and expensive (requiring general anaesthesia, operating theatre staff and a thoracic surgeon). EBUS-TBNA performs comparably to mediastinoscopy in many respects and is superior to conventional transbronchial needle aspiration (TBNA). EBUS-TBNA also has an important diagnostic role for inaccessible lung cancer and benign disease. There are important cost considerations and technical differences from flexible bronchoscopy. After a brief historic rationale, this paper reviews the indications for EBUS-TBNA, gives an overview of practical, training and financial issues; reviews the evidence comparing the mediastinal staging tools; and briefly discusses potential future applications.

Brief developmental history and rationale

Quick diagnosis and accurate lung cancer staging are essential. Mediastinal lymph node metastases determine outcome and this has influenced staging algorithms[1]. Non-invasive (radiological) staging investigations have their limitations. Contrast-enhanced computed tomography (CT) of the chest and upper abdomen and positron emission tomography (PET) yield false negative and positive results, so tissue sampling is needed[2]. CT is limited by benign causes of adenopathy, interobserver variability[3], the need for an interface between adjacent soft tissues[4], and mucus plugs or secretions which may mimic solid structures.

1
2
3
4 Radiological staging guides further diagnostic decisions on how best to obtain diagnostic tissue
5 and staging as well as assessing suitability for radical treatment. Flexible bronchoscopy is less
6 helpful for lung cancers presenting outwith the airway. Conventional TBNA can sample the
7 mediastinal nodes but without direct vision relying on correlation with CT. Real-time sampling is
8 a logical development.
9

10
11
12
13
14
15
16 Transthoracic ultrasound is limited by air reflecting the ultrasound wave. Endoluminal ultrasound
17 circumvents this. Oesophageal endoscopic ultrasound-guided fine needle aspiration (EUS-FNA)
18 was developed in the 1980s for assessing gastrointestinal malignancies but also in lung cancer
19 to sample accessible para-oesophageal lymph nodes[5]. EBUS-TBNA was developed in the next
20 decade to allow access to some stations remove air interference[6, 7]. Smaller radial ultrasound
21 probes allowed ventilation and a linear probe was later developed[8, 9].
22
23
24
25
26
27
28
29

30 Surgical mediastinal node staging by cervical mediastinoscopy (stations 1-4 and 7, see Figure
31 1), and/or anterior mediastinotomy (stations 5-6) cannot access stations 8-9 (accessible via
32 EUS-FNA or thoracoscopically) or stations 10-11 (accessible via EBUS-TBNA). EBUS-TBNA
33 samples the same stations as mediastinoscopy but also stations 10-11. EUS-FNA can sample
34 stations 4L, 5-9 as well as the left adrenal and left lobe of liver.
35
36
37
38
39
40
41

42 Indications for EBUS-TBNA

43
44

45 The main indications for EBUS-TBNA are as follows:
46
47

- 48 1. Staging the mediastinum in suspected non-small cell lung cancer (NSCLC).
 - 49 2. Diagnosis of lung cancer when there is no endoluminal tumour but mediastinal adenopathy.
 - 50 3. Diagnosis of unexplained mediastinal lymphadenopathy.
 - 51 4. Tissue banking samples for research studies.
- 52
53
54
55
56
57
58
59
60

Contraindications

EBUS-TBNA is well tolerated with identical contraindications to flexible bronchoscopy[10].

Patients need to be able to lie flat as intubation is via the oral route.

Practical issues

EBUS-TBNA images structures within and adjacent to the airway wall, including lymph nodes, blood vessels, the heart and tumour masses (see Figure 2) and allows real-time sampling. A separate flexible bronchoscopy is often done to examine the distal tracheobronchial tree due to the larger external diameter and inferior endoscopic image of the endobronchial ultrasound (EBUS) bronchoscope.

Equipment

The bronchoscope tip is stiffer, more fragile, larger and bulkier (external diameter 6.9mm versus 5-6mm for conventional scopes, see Figure 3A)[11]. Oral intubation of the supine patient from behind is required. Sedation varies from intravenous conscious sedation to general anaesthesia with a laryngeal mask[12]. Monitoring, topical anaesthesia and oxygenation are as for standard bronchoscopy.

Ultrasound

The ultrasound probe can be enveloped by an inflatable balloon sheath on the tip on the scope (see Figure 3A). The inflated balloon improves ultrasound image quality by better contact between probe and airway wall but is seldom needed. The linear probe is the focus of this review and used in EBUS-TBNA (see Figures 3A and B).

1
2
3
4 The probe frequency is 7.5 megahertz (MHz) giving a depth penetration of 9cm. There are two
5
6 images: an endoscopic image at an obliquely angled view of 30 degrees forward (see Figure 3B)
7
8 and an ultrasound image at an angled forward view of 90 degrees parallel to the EBUS
9
10 bronchoscope shaft. Colour flow and power Doppler features allow differentiation of vascular
11
12 structures (see Figure 3C).
13

14
15
16 The radial probe is used for other applications including assessment of airway tumour infiltration
17
18 to guide endobronchial therapy and peripheral pulmonary nodule sampling. Sampling is done
19
20 sequentially and not in real-time. Radial probes give a 360 degree view (see Figure 4) and the
21
22 frequencies are higher (range 20-30 MHz) giving greater resolution of less than 1mm but
23
24 reduced depth penetration of 5cm [13, 14]. The probes can either fit into a 2.8mm working
25
26 channel or even a 2mm working channel.
27
28

29 30 **EBUS-TBNA technique**

31
32
33 A trained assistant is advisable. For NSCLC staging, the higher stage nodes are sampled first to
34
35 prevent upstaging by contamination. The EBUS needle is usually a 22-gauge needle housed in a
36
37 sheath as for conventional TBNA (see Figures 3A and B). The technique for performing the EBUS-
38
39 TBNA when in the node is similar but slightly different to conventional TBNA. The internal stylet
40
41 needs to be withdrawn and jiggled on entry to the node to get rid of debris that may occlude the
42
43 needle lumen. The distance to the node (target) centre is variably set and derived from the EBUS
44
45 ultrasound image (0.5 to 4cm typically). The stylet is reintroduced after sampling to expel the
46
47 tissue core (the sample size is bigger and longer than for conventional TBNA). Air then saline is
48
49 injected to expel sample remnants after removing the stylet. It is important to clean the EBUS
50
51 needle and stylet to remove debris. Two passes per station are sufficient if visible tissue cores
52
53 are obtained[15].
54
55
56
57
58
59
60

Safety

EBUS-TBNA is well tolerated and as safe as conventional bronchoscopy[16, 17]. Pneumomediastinum, pneumothorax and haemomediastinum can occur very rarely but a post-procedure chest radiograph is not usually needed[18, 19]. Major vessel puncture is less likely due to real-time sampling but is not a problem as previously described with aortic haematoma post conventional TBNA[18]. Some EBUS-TBNA centres intentionally traverse the pulmonary artery for left hilar mass sampling[20]. Infectious complications have rarely been reported and bacteraemia is usually asymptomatic and clinically insignificant[21, 22].

Sample processing

Many centres use formalin pots (and saline pots for mycobacterial culture) and liquid cytology bottles for samples or smear part of the sample onto glass slides and fix in alcohol. Data from conventional TBNA studies suggest the smear technique is superior resulting in less cellular distortion which may be important in granulomatous disease[23-25]. Phua et al. demonstrated the importance of smear method and histology gauge needle (before using EBUS) in optimising conventional TBNA yield[26]. Rapid on-site evaluation for cytopathology (ROSE) improves the yield of TBNA by confirming an adequate sample, but is not routinely available in many centres[27, 28].

Pros and cons of EBUS-TBNA compared to other mediastinal staging techniques

These are summarised in Table 1.

Advantages over conventional TBNA

EBUS-TBNA is superior to conventional TBNA in diagnostic yield at all accessible stations except station 7: stations 2-4,10-11 (see Table 2). The node is directly visualised and sampled in real-time reducing the chances of major vessel puncture and a larger tissue core is obtained. Image capture is possible for audit purposes.

Advantages over mediastinoscopy

EBUS-TBNA accesses the hilar nodal stations which may be diagnostic for sarcoidosis and tuberculosis. EBUS-TBNA is a relatively quick, safe, minimally invasive and a day case procedure under conscious sedation performable by pulmonologists. Mediastinoscopy leaves adhesions[29], a neck scar, has a 1.4-2.3% risk of important complications and can be rarely fatal) [30, 31]. Mediastinoscopy also requires a thoracic surgeon, general anaesthesia, often overnight admission, and takes longer (2 hours 24 minutes in one tertiary UK centre[32] versus 30 minutes for EBUS-TBNA typically[33]).

Disadvantages

The EBUS-TBNA needle is typically 22 gauge yielding a tissue core but of smaller size than at mediastinoscopy. This may limit the utility of EBUS-TBNA in lymphoma or when the intranodal metastases are very small. Contamination of the EBUS-TBNA with bronchial epithelial cells can occur affecting the utility of some tumour markers such as cytokeratin 19[34]. The negative predictive value of EBUS-TBNA is lower than for mediastinoscopy (see Table 2) so patients with a high pre-test probability of lung cancer with a negative EBUS-TBNA currently need a mediastinoscopy. EBUS-TBNA is more expensive than conventional TBNA, takes longer and requires extra training. Delays in EBUS-TBNA specific tariffs evolution may lead to loss in tariff-based revenue.

Training and competency

All bronchoscopists should be trained in conventional TBNA as it is relatively cheap, universally available to all bronchoscopists (unlike EBUS-TBNA), easy to learn and requires no extra equipment. The learning curve for conventional TBNA is short amongst experienced bronchoscopists[35] and it is as well tolerated as conventional bronchoscopy[36]. Conventional TBNA can avoid mediastinoscopy in 35% of cases[37, 38]. It can avoid a significant number of mediastinoscopies and save £560 per patient even when developed as a new service and for diagnosis alone in a real world cohort[39].

1
2
3
4 National bodies differ on training recommendations but only refer to radial probe EBUS-TBNA.
5
6 The European Respiratory Society/American Thoracic Society recommends 40 supervised
7
8 procedures and 25 per year to maintain skills[40]. The American College of Chest Physicians
9
10 recommend a minimum of 50 supervised procedures and then 5-10 procedures per year to
11
12 maintain skills[41]. Experience suggests the linear probe requires at least 40-50 procedures
13
14 (assuming already a fully trained conventional bronchoscopists) supervised by an experienced
15
16 EBUS-TBNA bronchoscopist, although this is not evidence based[16]. Reasonable performance
17
18 can be achieved quickly in newly established EBUS-TBNA services and experience suggests
19
20 results improve beyond 50 cases[33, 42-44]. Interpreting, obtaining and maintaining the EBUS
21
22 ultrasound image, and acclimatising to the altered angle of view, handling, weight and fragility
23
24 of the EBUS bronchoscope are the key challenges. Previous conventional TBNA and ultrasound
25
26 (especially supraclavicular node ultrasound[45]) experience is helpful. Gastroenterologists,
27
28 interventional radiologists or surgeons who are experienced in EUS-FNA may be an additional
29
30 source of support.
31
32
33
34

35 EUS-FNA is currently predominantly performed by gastroenterologists, interventional radiologists
36
37 and surgeons but a number of pulmonologists are also doing this procedure sometimes in
38
39 conjunction with an EUS-FNA operator or may perform a more limited oesophageal EUS-FNA via
40
41 the same EBUS scope[46, 47].
42
43
44
45
46
47
48
49
50
51
52
53
54
55
56
57
58
59
60

Cost issues

Cost implications are an essential consideration in health care systems due to resource rationing. The EBUS bronchoscope and ultrasound processor are the major capital costs. The disposable EBUS-TBNA needles are a significant running cost compared to conventional TBNA needles (approximately £150-175 versus £40 respectively). A UK centre cost analysis estimated a £104465 total capital cost for an EBUS-TBNA system over a 5 year period[48]. **In contrast, conventional TBNA can save £560 per patient even in a newly established service[39].**

Staff costs are higher because EBUS-TBNA requires a trained assistant, it takes longer than a standard flexible bronchoscopy, an additional flexible bronchoscopy is needed for endobronchial sampling (in 32.5% of unselected cases of suspected lung cancer[43]), a combined EUS-FNA is performed or limited EUS-FNA with the same EBUS scope[46, 47] and ROSE may be used if available. Repair costs are much higher than for a conventional flexible bronchoscope.

Prevalence of disease is important. A recent European cost analysis concluded EUS-FNA would be cheaper (£11115 per patient) than combined EBUS-TBNA/EUS-FNA (£11205 per patient) in low prevalence (<33%) cohorts whereas combined EBUS-TBNA/EUS-FNA would be more cheaper in higher prevalence cohorts[49]. Both strategies were cheaper than mediastinoscopy by staging and diagnosing lung cancer in one visit and avoiding mediastinoscopy and also increasing thoracic surgical capacity.

For tariff-based health care systems it is crucial that EBUS-TBNA tariffs recognise this innovation. In the UK until recent times, there was no specific EBUS-TBNA tariff so that EBUS-TBNA received a standard flexible bronchoscopy tariff despite the increased cost, complexity and time of the procedure[50, 51]. Coding errors remain commonplace and also contribute to revenue loss[43, 52, 53].

1
2
3
4 Conventional TBNA performs well especially for large central (>25mm) nodes, although the
5 sample size is less. For patients with bulky (>25mm) central nodal disease, conventional TBNA
6 is a reasonable alternative to EBUS-TBNA and much cheaper (less expensive equipment and
7 quicker). EBUS-TBNA is better than conventional TBNA at more distal and all smaller nodes. The
8 cost saving potential for EBUS-TBNA is therefore far greater and can offset the higher cost.
9 Where EBUS-TBNA is not available, conventional TBNA should be used first line for central bulky
10 mediastinal disease.
11
12
13
14
15
16
17
18
19

20 The importance of mediastinal staging

21
22
23
24 Mediastinal metastatic lymph node involvement in NSCLC correlates with extra-thoracic
25 metastases and influences resectability, management and prognosis[54]. Radiological
26 mediastinal staging with CT and PET has limited sensitivity and specificity so tissue is
27 required[2]. Active mediastinal nodes on PET and/or greater than 1cm on CT short axis are
28 sampled via mediastinoscopy, EBUS-TBNA (with/without EUS-FNA)[33, 55, 56] or conventional
29 TBNA. [The relative performance of the mediastinal staging techniques is now considered.](#)
30
31
32
33
34
35
36
37

38 EBUS-TBNA versus CT and PET

39
40
41 [Studies comparing EBUS-TBNA with radiological staging are summarised in Table 3. Two studies](#)
42 [have compared EBUS-TBNA to non-invasive staging \(CT and PET\) in pre-operative staging in](#)
43 [patients with a radiologically “normal” mediastinum\[57, 58\]. EBUS-TBNA was superior to CT and](#)
44 [PET in diagnostic performance in both studies \(see Table 3\) \[57, 58\]. Notably, PET performance](#)
45 [will have been reduced as nodal diameters were down to 5mm.](#)
46
47
48
49
50
51
52
53
54
55
56
57
58
59
60

1
2
3
4 Hwangbo et al. further demonstrated the diagnostic superiority (see Table 3) of EBUS-TBNA over
5 PET/CT in a prospective study of 117 patients with nodes of 5-20mm[59]. EBUS-TBNA was
6 especially superior with adenocarcinoma (probably related to the higher rate of mediastinal
7 metastases[60] and lower PET SUV[61]) but not with squamous cell carcinoma. Szlubowski et al.
8 demonstrated the diagnostic superiority of combined EBUS-TBNA with EUS-FNA (EBUS-
9 TBNA/EUS-FNA) over either technique alone for sub-centimetre nodes on CT[62].
10
11
12
13
14
15
16
17

18 EBUS-TBNA may therefore have a role in pre-operative staging in stage 1 disease and is superior
19 to radiological staging but may be better still with combined EUS-FNA.
20
21
22
23

24 EBUS-TBNA versus conventional TBNA

25
26

27 EBUS-TBNA is superior to conventional TBNA. Conventional TBNA had a 76% sensitivity in a
28 recent systematic review (EBUS-TBNA was not compared)[63]. EBUS-TBNA achieved a 95%
29 sensitivity in a prospective study of 108 patients with suspected NSCLC, with a 90% negative
30 predictive value and avoided 50 more invasive sampling procedures[64]. In a comparative trial,
31 radial probe EBUS-TBNA was superior to conventional TBNA at stations other than station 7
32 (84% versus 58% positive) for 200 patients with suspected NSCLC[16]. This reflects the
33 technical ease of sampling station 7 by conventional TBNA compared to other stations although
34 sensitivities favoured EBUS-TBNA (86% versus 74%).
35
36
37
38
39
40
41
42
43
44

45 EBUS-TBNA versus mediastinoscopy

46
47

48 EBUS-TBNA performs comparably to mediastinoscopy based on systematic reviews and meta-
49 analyses (see Table 2) [63, 65-69]. Performance varies with selection criteria; when nodes are
50 selected on radiological criteria, sensitivity is higher (94% versus 76%)[66]. The lower sensitivity
51 for mediastinoscopy relates to lower disease prevalence in these studies. The negative predictive
52 value of mediastinoscopy is higher than EBUS-TBNA.
53
54
55
56
57
58
59
60

1
2
3
4 There are few comparative studies with contrasting results, summarised in Table 4, although the
5 second study is still in abstract form and final data are awaited[70, 71]. In the second study,
6 (with a lower prevalence) results favoured mediastinoscopy and 3 patients were upstaged by
7 mediastinoscopy indicating EBUS-TBNA may not completely replace it[71]. A randomised multi-
8 centre controlled trial of EBUS-TBNA and EUS-FNA versus mediastinoscopy (ASTER trial) reports
9 in 2012[72].

10
11 Other non-comparative studies (also summarised in Table 4) have only surgically staged EBUS-
12 TBNA negative cases. Szlubowski et al. performed extensive surgical mediastinal
13 lymphadenectomy on all negative EBUS-TBNA results in a large prospective cohort study[73].
14 False negative results were due to micrometastases. Rintoul et al. achieved a similar sensitivity
15 (see Table 4) in a large prospective study of patients with PET positive nodes, but the negative
16 predictive value was lower indicating the need for surgical evaluation of EBUS-TBNA negative
17 nodes where the pre-test probability is high[74].

18
19 The American College of Chest Physicians[65] advocate EBUS-TBNA instead of mediastinoscopy
20 to stage discrete N2 or N3 disease or bulky mediastinal disease. Mediastinoscopy is
21 recommended for radical treatment staging including single station N2 disease given the better
22 prognosis[75]. For hilar node staging, EBUS-TBNA is indicated and supported by a multi-centre
23 study of 213 patients with CT or PET positive hilar nodes (91% sensitivity for EBUS-TBNA)[76].

24
25 The optimal staging technique for restaging is unclear. Mediastinoscopy results in adhesions and
26 re-mediastinoscopy performs less well[77]. A recent prospective study suggests EBUS-TBNA may
27 be a reasonable alternative[78]. 68% sensitivity and 78% negative predictive value were
28 achieved with false negatives only in very small nodes with small deposits (5mm or less).
29
30
31
32
33
34
35
36
37
38
39
40
41
42
43
44
45
46
47
48
49
50
51
52
53
54
55
56
57
58
59
60

Diagnosis of unexplained mediastinal lymphadenopathy

EBUS-TBNA is increasingly used for diagnosis of unexplained malignant (non-lung cancers[79]) or benign mediastinal lymphadenopathy. Because many lung tumours present outside the airway, it is commonly the sole diagnostic method in lung cancer patients (22% in a typical real world cohort of patients[43]). It can also reduce the need for other diagnostic procedures such as CT-guided biopsy of the primary lung mass without loss in yield[80] and also deliver the final diagnosis in 45% following a negative bronchoscopy and CT-guided biopsy[81]. Clinical followup and close collaboration with cytologists can improve the performance of EBUS-TBNA[82].

EBUS-TBNA is also used to diagnose benign disease especially sarcoidosis although studies are limited in this area (summarised in Table 5). Studies (varying from case series to cohort studies to randomised controlled studies) have shown sensitivities varying between 71% up to 93% depending on patient selection criteria (see Table 5)[83-89]. A recent small case series in a newly established EBUS-TBNA service achieved a 78% sensitivity [83]. Nakajima et al. confirmed EBUS-TBNA was superior to other bronchoscopic techniques [84]. Following a negative flexible bronchoscopy, Tournoy et al. achieved a 71% sensitivity for EBUS-TBNA in a selected cohort[85]. Garwood et al used real life selection criteria without a CT scan for all stages of disease, achieving an 85% sensitivity[86]. A higher sensitivity of 87.5% was obtained by Wong et al. in patients with CT evidence of larger nodes and stage 1-2 disease [87]. A similar sensitivity was obtained by Oki et al using similar selection criteria[88]. Tremblay et al confirmed the superiority of EBUS-TBNA to 19-gauge conventional TBNA in a randomised controlled trial[89]. Limited oesophageal EUS-FNA with an EBUS scope has been reported to have a high yield for tuberculosis in a recent case series[47].

1
2
3
4
5
6
7
8
9
10
11
12
13
14
15
16
17
18
19
20
21
22
23
24
25
26
27
28
29
30
31
32
33
34
35
36
37
38
39
40
41
42
43
44
45
46
47
48
49
50
51
52
53
54
55
56
57
58
59
60

EBUS-TBNA also has a role in diagnosis of lymphoma in selected centres with available flow cytometry. Mediastinal lymphoma was diagnosed by EBUS-TBNA with 91% sensitivity and 93% predictive value in a retrospective study of 25 patients with a lymphoma prevalence of 44%[90].

The tissue core volume and real-time sampling in EBUS-TBNA are crucial factors for diagnosis of lymphoma, benign disease, and mutation testing for growth factors which may have prognostic importance[91-93]. A recent study of 75 patients showed 1.15mm mini-forceps biopsies were superior to both 22-gauge and 19-gauge TBNA needle biopsies for subcarinal nodes especially for sarcoidosis (88% versus 36%) and lymphoma (81% versus 35%)[94].

Predictors of malignancy

Sonographic appearances histological characteristics of biopsies can be helpful in predicting malignancy at EBUS-TBNA. A short axis diameter of greater than 2cm was highly predictive of malignancy (>90% probability) and a spherical shape with a short to long axis ratio of 1 (55% probability) in a recent Spanish study of 161 patients with 51% disease prevalence[95]. A recent prospective study of 50 patients reported granulomatous reactions in 4.3% of nodes without any metastases[96]. A granulomatous node in the setting of NSCLC may have useful negative predictive value.

Other applications

EBUS has other potential applications and its indications are likely to increase in the future as its potential is realised. Linear probe EBUS allows real time imaging of the central pulmonary vessels. Aumiller et al. identified central pulmonary emboli (all previously diagnosed by prior CT pulmonary angiography) with linear probe EBUS in an unblinded prospective pilot study[97]. Rice et al. staged malignant mesothelioma with EBUS-TBNA more effectively than with mediastinoscopy for suitability for radical surgery, although EUS-FNA will be needed for infradiaphragmatic nodes[98]. Soja et al. measured airway wall thickness by radial probe EBUS and correlated this with asthma severity[99]. Radial probe EBUS has also been used to place fiducial markers for stereotactic radiosurgery for early stage NSCLC[100].

Summary

EBUS-TBNA is an advance in techniques for the respiratory physician and is indicated for staging NSCLC, diagnosing unexplained mediastinal lymphadenopathy including benign disease especially sarcoidosis and tuberculosis. It is a minimally invasive option for staging NSCLC with solitary hilar nodes, discrete N2 or N3 disease or bulky mediastinal disease. Currently, mediastinoscopy is still advisable for EBUS-TBNA negative nodes when the pre-test probability of lung cancer is high although this may not be needed in time. For radical treatment, mediastinoscopy is advisable for staging but this may be replaced in the future by EBUS-TBNA for CT and PET negative sub-centimetre nodes. EBUS-TBNA may also have a role in primary staging where re-staging (with mediastinoscopy) is likely to be needed or as an alternative re-staging tool itself.

1
2
3
4 EBUS-TBNA requires training with a definite learning curve even for even experienced
5
6 conventional bronchoscopists. When setting up a service, capital and running costs need careful
7
8 thought with the main cost benefit being avoidance of unnecessary mediastinoscopies. In the
9
10 future, a combined EBUS-TBNA/EUS-FNA service giving access to all the nodal stations may be
11
12 feasible with sufficient expertise and patient throughput on site. **In the mean time, conventional**
13
14 **TBNA should be performed by all bronchoscopists as it is far cheaper, well tolerated, easier to**
15
16 **learn and set up and avoids mediastinoscopies in 25-35% of patients.**
17
18
19

20 Acknowledgements

21
22
23
24 None to declare.
25
26
27
28
29
30
31
32
33
34
35
36
37
38
39
40
41
42
43
44
45
46
47
48
49
50
51
52
53
54
55
56
57
58
59
60

References

- [1] Mountain CF, Dresler CM. Regional lymph node classification for lung cancer staging. *Chest* 1997;111(6):1718-23.
- [2] Silvestri GA, Gould MK, Margolis ML, et al. Noninvasive staging of non-small cell lung cancer: ACCP evidenced-based clinical practice guidelines (2nd edition). *Chest* 2007;132(3 Suppl):178S-201S.
- [3] Guyatt GH, Lefcoe M, Walter S, et al. Interobserver variation in the computed tomographic evaluation of mediastinal lymph node size in patients with potentially resectable lung cancer. *Chest* 1995;107(1):116-9.
- [4] McCollough CH, Morin RL. The technical design and performance of ultrafast computed tomography. *Radiol Clin N Amer* 1994;32(3):521-36.
- [5] Annema JT, Versteegh MI, Veselic M, et al. Endoscopic ultrasound-guided fine-needle aspiration in the diagnosis and staging of lung cancer and its impact on surgical staging. *J Clin Oncol* 2005;23(33):8357-61.
- [6] Silvestri GA, Hoffman BJ, Bhutani MS, et al. Endoscopic ultrasound with fine-needle aspiration in the diagnosis and staging of lung cancer. *Ann Thor Surg* 1996;61(5):1441-5.
- [7] Hurter T, Hanrath P. Endobronchial sonography: feasibility and preliminary results. *Thorax* 1992;47(7):565-7.
- [8] Becker HD. EBUS: a new dimension in bronchoscopy. Of sounds and images—a paradigm of innovation. *Respiration* 2006;73(5):583-6.
- [9] Herth FJ, Eberhardt R. Actual role of endobronchial ultrasound (EBUS). *European Radiology* 2007;17(7):1806-12.
- [10] British Thoracic Society guidelines on diagnostic flexible bronchoscopy. *Thorax* 2001;56 Suppl 1:i1-21.
- [11] Sheski FD, Mathur PN. Endobronchial ultrasound. *Chest* 2008;133(1):264-70.
- [12] Douadi Y, Bentayeb H, Malinowski S, et al. Anaesthesia for bronchial echoendoscopy: experience with the laryngeal mask. *Rev Mal Respir* 2010;27(1):37-41.
- [13] Kurimoto N, Murayama M, Yoshioka S, et al. Assessment of usefulness of endobronchial ultrasonography in determination of depth of tracheobronchial tumor invasion. *Chest* 1999;115(6):1500-6.
- [14] Baba M, Sekine Y, Suzuki M, et al. Correlation between endobronchial ultrasonography (EBUS) images and histologic findings in normal and tumor-invaded bronchial wall. *Lung Cancer* 2002;35(1):65-71.
- [15] Lee HS, Lee GK, Lee HS, et al. Real-time endobronchial ultrasound-guided transbronchial needle aspiration in mediastinal staging of non-small cell lung cancer: how many aspirations per target lymph node station? *Chest* 2008;134(2):368-74.
- [16] Herth F, Becker HD, Ernst A. Conventional vs endobronchial ultrasound-guided transbronchial needle aspiration: a randomized trial. *Chest* 2004;125(1):322-5.
- [17] Herth FJ, Eberhardt R, Vilman P, et al. Real-time endobronchial ultrasound guided transbronchial needle aspiration for sampling mediastinal lymph nodes. *Thorax* 2006;61(9):795-8.
- [18] Agli LL, Trisolini R, Burzi M, Patelli M. Mediastinal hematoma following transbronchial needle aspiration. *Chest* 2002;122(3):1106-7.
- [19] Kucera RF, Wolfe GK, Perry ME. Hemomediastinum after transbronchial needle aspiration. *Chest* 1986;90(3):466.
- [20] Vincent B, Huggins JT, Doelken P, Silvestri G. Successful real-time endobronchial ultrasound-guided transbronchial needle aspiration of a hilar lung mass obtained by traversing the pulmonary artery. *J Thorac Oncol* 2006;1(4):362-4.

- 1
2
3
4 [21] Haas AR. Infectious complications from full extension endobronchial ultrasound
5 transbronchial needle aspiration. *Eur Respir J* 2009;33(4):935-8.
6 [22] Steinfurt DP, Johnson DF, Irving LB. Incidence of bacteraemia following endobronchial
7 ultrasound-guided transbronchial needle aspiration. *Eur Respir J* 2009; doi:
8 09031936.00151809v1.
9 [23] Trisolini R, Agli LL, Cancellieri A, et al. The value of flexible transbronchial needle
10 aspiration in the diagnosis of stage I sarcoidosis. *Chest* 2003;124(6):2126-30.
11 [24] Bilaceroglu S, Chhajed P. Transbronchial needle aspiration: a diagnostic tool in routine
12 bronchoscopy. *J Assoc Phys Ind* 2005;53:797-802.
13 [25] Bilaceroglu S, Cagiotariotaciota U, Gunel O, et al. Comparison of rigid and flexible
14 transbronchial needle aspiration in the staging of bronchogenic carcinoma. *Respiration*
15 1998;65(6):441-9.
16 [26] Phua GC, Rhee KJ, Koh M, et al. A strategy to improve the yield of transbronchial needle
17 aspiration. *Surg Endosc* 2010; doi: 10.1007/s00464-010-0906-4.
18 [27] Klapman JB, Logrono R, Dye CE, Waxman I. Clinical impact of on-site cytopathology
19 interpretation on endoscopic ultrasound-guided fine needle aspiration. *Amer J Gastroenterol*
20 2003;98(6):1289-94.
21 [28] Herbert A, Santis G. EBUS-TBNA: an opportunity for clinicians, cytopathologists and
22 patients to gain from multidisciplinary collaboration. *Cytopathology* 2010;21(1):3-5.
23 [29] Van Schil P, van der Schoot J, Poniewierski J, et al. Remediastinoscopy after neoadjuvant
24 therapy for non-small cell lung cancer. *Lung Cancer* 2002;37(3):281-5.
25 [30] Reich JM, Brouns MC, O'Connor EA, Edwards MJ. Mediastinoscopy in patients with
26 presumptive stage I sarcoidosis: a risk/benefit, cost/benefit analysis. *Chest* 1998;113(1):147-
27 53.
28 [31] Cybulsky IJ, Bennett WF. Mediastinoscopy as a routine outpatient procedure. *Ann Thorac*
29 *Surg* 1994;58(1):176-8.
30 [32] Medford ARL, Agrawal S, Free CM, Bennett JA. Mediastinal staging procedures in lung
31 cancer: EBUS, TBNA and mediastinoscopy. *Curr Opin Pulm Med* 2009; 15(4):334-42.
32 [33] Rintoul RC, Skwarski KM, Murchison JT, et al. Endobronchial and endoscopic ultrasound-
33 guided real-time fine-needle aspiration for mediastinal staging. *Eur Respir J* 2005;25(3):416-21.
34 [34] Dango S, Cucuruz B, Mayer O, et al. Detection of disseminated tumour cells in
35 mediastinoscopic lymph node biopsies and endobronchial ultrasonography-guided
36 transbronchial needle aspiration in patients with suspected lung cancer. *Lung Cancer* 2009;
37 doi:10.1016/j.lungcan.2009.08.003.
38 [35] Hermens FH, Limonard GJ, Termeer R, et al. Learning curve of conventional
39 transbronchial needle aspiration in pulmonologists experienced in bronchoscopy. *Respiration*
40 2008;75(2):189-92.
41 [36] Bernasconi M, Chhajed PN, Muller P, Borer H. Patients' Satisfaction with Flexible
42 Bronchoscopy in a Hospital-Based Community Practice. *Respiration* 2009;78(4):440-445.
43 [37] Patel NM, Pohlman A, Husain A, et al. Conventional transbronchial needle aspiration
44 decreases the rate of surgical sampling of intrathoracic lymphadenopathy. *Chest*
45 2007;131(3):773-8.
46 [38] Kunst PW, Lee P, Paul MA, et al. Restaging of mediastinal nodes with transbronchial
47 needle aspiration after induction chemoradiation for locally advanced non-small cell lung
48 cancer. *J Thorac Oncol* 2007;2(10):912-5.
49 [39] Medford AR, Agrawal S, Free CM, Bennett JA. A prospective study of conventional
50 transbronchial needle aspiration: performance and cost utility. *Respiration* 2009; doi:
51 10.1159/000277931.
52
53
54
55
56
57
58
59
60

- 1
2
3
4 [40] Bolliger CT, Mathur PN, Beamis JF, et al. ERS/ATS statement on interventional
5 pulmonology. European Respiratory Society/American Thoracic Society. *Eur Respir J*
6 2002;19(2):356-73.
7 [41] Ernst A, Silvestri GA, Johnstone D. Interventional pulmonary procedures: Guidelines from
8 the American College of Chest Physicians. *Chest* 2003;123(5):1693-717.
9 [42] Steinfors DP, Hew MJ, Irving LB. Bronchoscopic evaluation of the mediastinum using
10 endobronchial ultrasound - A description of the first 216 cases performed at an Australian
11 tertiary hospital. *Int Med J* 2009; doi: 10.1111/j.1445-5994.2009.02142.x.
12 [43] Medford AR, Agrawal S, Free CM, Bennett JA. A performance and theoretical cost
13 analysis of endobronchial ultrasound-guided transbronchial needle aspiration in a UK tertiary
14 respiratory centre. *QJM* 2009;102(12):859-64.
15 [44] Omark Petersen H, Eckardt J, Hakami A, et al. The value of mediastinal staging with
16 endobronchial ultrasound-guided transbronchial needle aspiration in patients with lung cancer.
17 *Eur J Cardiothorac Surg* 2009;36(3):465-8.
18 [45] Kumaran M, Benamore RE, Vaidhyanath R, et al. Ultrasound guided cytological
19 aspiration of supraclavicular lymph nodes in patients with suspected lung cancer. *Thorax*
20 2005;60(3):229-33.
21 [46] Herth F, Krasnik M, Kahn N, et al. Combined Endoesophageal-Endobronchial Ultrasound-
22 Guided, Fine-Needle Aspiration of Mediastinal Lymph Nodes through a Single Bronchoscope in
23 150 Patients with Suspected Lung Cancer. *Chest* 2010; doi:10.1378/chest.09-2149.
24 [47] Medford AR, Agrawal S. Single bronchoscope combined endoesophageal-endobronchial
25 ultrasound-guided fine-needle aspiration for tuberculous mediastinal nodes. *Chest* 2010; (in
26 press).
27 [48] Callister ME, Gill A, Allott W, Plant PK. Endobronchial ultrasound guided transbronchial
28 needle aspiration of mediastinal lymph nodes for lung cancer staging: a projected cost analysis.
29 *Thorax* 2008;63(4):384.
30 [49] Harewood GC, Pascual J, Raimondo M, et al. Economic analysis of combined endoscopic
31 and endobronchial ultrasound in the evaluation of patients with suspected non-small cell lung
32 cancer. *Lung Cancer* 2010;67(3):366-71.
33 [50] Medford AR. Endobronchial ultrasound-transbronchial needle aspiration and lung cancer
34 *J R Coll Physicians Edinb* 2009;39(1):91.
35 [51] Manaker S, Ernst A, Marcus L. Affording endobronchial ultrasound. *Chest*
36 2008;133(4):842-3.
37 [52] Medford AR, Agrawal S, Free CM, Bennett JA. Retrospective analysis of Healthcare
38 Resource Group coding allocation for local anaesthetic video-assisted 'medical' thoracoscopy in
39 a UK tertiary respiratory centre. *QJM* 2009;102(5):329-33.
40 [53] Audit Commission. PbR Data Assurance Framework 2007/08: Findings from the first
41 year of the national clinical coding audit programme. [http://www.audit-](http://www.audit-commission.gov.uk/Products/NATIONAL-REPORT/CD8608E5-A7D9-4a5a-B0F3-C161B76DE630/PbRreport.pdf)
42 [commission.gov.uk/Products/NATIONAL-REPORT/CD8608E5-A7D9-4a5a-B0F3-](http://www.audit-commission.gov.uk/Products/NATIONAL-REPORT/CD8608E5-A7D9-4a5a-B0F3-C161B76DE630/PbRreport.pdf)
43 [C161B76DE630/PbRreport.pdf](http://www.audit-commission.gov.uk/Products/NATIONAL-REPORT/CD8608E5-A7D9-4a5a-B0F3-C161B76DE630/PbRreport.pdf).
44 [54] Dillemans B, Deneffe G, Verschakelen J, Decramer M. Value of computed tomography
45 and mediastinoscopy in preoperative evaluation of mediastinal nodes in non-small cell lung
46 cancer. A study of 569 patients. *Eur J Cardiothorac Surg* 1994;8(1):37-42.
47 [55] Wallace MB, Pascual JM, Raimondo M, et al. Minimally invasive endoscopic staging of
48 suspected lung cancer. *JAMA* 2008;299(5):540-6.
49 [56] Vilmann P, Krasnik M, Larsen SS, et al. Transesophageal endoscopic ultrasound-guided
50 fine-needle aspiration (EUS-FNA) and endobronchial ultrasound-guided transbronchial needle
51 aspiration (EBUS-TBNA) biopsy: a combined approach in the evaluation of mediastinal lesions.
52 *Endoscopy* 2005;37(9):833-9.
53
54
55
56
57
58
59
60

- 1
2
3
4 [57] Herth FJ, Eberhardt R, Krasnik M, Ernst A. Endobronchial ultrasound-guided
5 transbronchial needle aspiration of lymph nodes in the radiologically and positron emission
6 tomography-normal mediastinum in patients with lung cancer. *Chest* 2008;133(4):887-91.
- 7 [58] Yasufuku K, Nakajima T, Motoori K, et al. Comparison of endobronchial ultrasound,
8 positron emission tomography, and CT for lymph node staging of lung cancer. *Chest*
9 2006;130(3):710-8.
- 10 [59] Hwangbo B, Kim SK, Lee HS, et al. Application of endobronchial ultrasound-guided
11 transbronchial needle aspiration following integrated PET/CT in mediastinal staging of
12 potentially operable non-small cell lung cancer. *Chest* 2009;135(5):1280-7.
- 13 [60] Fibla JJ, Molins L, Simon C, et al. The yield of mediastinoscopy with respect to lymph
14 node size, cell type, and the location of the primary tumor. *J Thorac Oncol* 2006;1(5):430-3.
- 15 [61] Vesselle H, Salskov A, Turcotte E, et al. Relationship between non-small cell lung cancer
16 FDG uptake at PET, tumor histology, and Ki-67 proliferation index. *J Thorac Oncol*
17 2008;3(9):971-8.
- 18 [62] Szlubowski A, Zielinski M, Soja J, et al. A combined approach of endobronchial and
19 endoscopic ultrasound-guided needle aspiration in the radiologically normal mediastinum in
20 non-small-cell lung cancer staging - a prospective trial. *Eur J Cardiothorac Surg* 2009;
21 doi:10.1016/j.ejcts.2009.11.015.
- 22 [63] Toloza EM, Harpole L, Detterbeck F, McCrory DC. Invasive staging of non-small cell lung
23 cancer: a review of the current evidence. *Chest* 2003;123(1 Suppl):157S-66S.
- 24 [64] Yasufuku K, Chiyo M, Koh E, et al. Endobronchial ultrasound guided transbronchial
25 needle aspiration for staging of lung cancer. *Lung Cancer* 2005;50(3):347-54.
- 26 [65] Detterbeck FC, Jantz MA, Wallace M, et al. Invasive mediastinal staging of lung cancer:
27 ACCP evidence-based clinical practice guidelines (2nd edition). *Chest* 2007;132(3 Suppl):202S-
28 20S.
- 29 [66] Gu P, Zhao YZ, Jiang LY, et al. Endobronchial ultrasound-guided transbronchial needle
30 aspiration for staging of lung cancer: A systematic review and meta-analysis. *Eur J Cancer* 2009;
31 45(8):1389-96.
- 32 [67] Adams K, Shah P, Edmonds L, Lim E. Endobronchial ultrasound and transbronchial
33 needle aspiration biopsy for mediastinal staging in patients with lung cancer: systematic review
34 and meta-analysis. *Thorax* 2009;64(9):757-62.
- 35 [68] Varela-Lema L, Fernandez-Villar A, Ruano-Ravina A. Effectiveness and safety of
36 endobronchial ultrasound-transbronchial needle aspiration: a systematic review. *Eur Respir J*
37 2009;33(5):1156-64.
- 38 [69] Gomez M, Silvestri GA. Endobronchial ultrasound for the diagnosis and staging of lung
39 cancer. *Proc Am Thor Soc* 2009;6(2):180-6.
- 40 [70] Ernst A, Anantham D, Eberhardt R, et al. Diagnosis of mediastinal adenopathy-real-time
41 endobronchial ultrasound guided needle aspiration versus mediastinoscopy. *J Thorac Oncol*
42 2008;3(6):577-82.
- 43 [71] Yasufuku K, Quadri M, dePerrot M, et al. A prospective controlled trial of endobronchial
44 ultrasound guided transbronchial needle aspiration compared to mediastinoscopy for
45 mediastinal lymph node staging of lung cancer. Western Thoracic Surgical Association 33rd
46 Annual Meeting (abstract). Canada 2007.
- 47 [72] <http://www.ncchta.org/project/1603.asp>. Assessment of Surgical sTaging versus
48 Endobronchial and endoscopic ultrasound in lung cancer: a Randomised controlled trial (ASTER)
49 2007.
- 50 [73] Szlubowski A, Kuzdzal J, Kolodziej M, et al. Endobronchial ultrasound-guided needle
51 aspiration in the non-small cell lung cancer staging. *Eur J Cardiothorac Surg*. 2009;35(2):332-5.
- 52
53
54
55
56
57
58
59
60

- 1
2
3
4 [74] Rintoul RC, Tournoy KG, El Daly H, et al. EBUS-TBNA for the clarification of PET positive
5 intra-thoracic lymph nodes-an international multi-centre experience. *J Thorac Oncol*
6 2009;4(1):44-8.
7
8 [75] Goldstraw P, Crowley J, Chansky K, et al. The IASLC Lung Cancer Staging Project:
9 proposals for the revision of the TNM stage groupings in the forthcoming (seventh) edition of the
10 TNM Classification of malignant tumours. *J Thorac Oncol* 2007;2(8):706-14.
11 [76] Ernst A, Eberhardt R, Krasnik M, Herth FJ. Efficacy of endobronchial ultrasound-guided
12 transbronchial needle aspiration of hilar lymph nodes for diagnosing and staging cancer. *J*
13 *Thorac Oncol* 2009;4(8):947-50.
14 [77] Van Schil P, De Waele M, Hendriks J, Lauwers P. Remediastinoscopy. *J Thorac Oncol*
15 2007;2(4):365-6.
16 [78] Szlubowski A, Herth FJ, Soja J, et al. Endobronchial ultrasound-guided needle aspiration
17 in non-small-cell lung cancer restaging verified by the transcervical bilateral extended
18 mediastinal lymphadenectomy - a prospective study. *Eur J Cardiothorac Surg* 2009;
19 doi:10.1016/j.ejcts.2009.11.014.
20 [79] Chow A, Oki M, Saka H, et al. Metastatic mediastinal lymph node from an unidentified
21 primary papillary thyroid carcinoma diagnosed by endobronchial ultrasound-guided
22 transbronchial needle aspiration. *Int Med* 2009;48(15):1293-6.
23 [80] Fielding D, Windsor M. Endobronchial ultrasound convex-probe transbronchial needle
24 aspiration as the first diagnostic test in patients with pulmonary masses and associated hilar or
25 mediastinal nodes. *Int Med J* 2009;39(7):435-40.
26 [81] Eckardt J, Petersen HO, Hakami-Kermani A, et al. Endobronchial ultrasound-guided
27 transbronchial needle aspiration of undiagnosed intrathoracic lesions. *Interact Cardiovasc Thor*
28 *Surg* 2009;9(2):232-5.
29 [82] Feller-Kopman D, Yung RC, Burroughs F, Li QK. Cytology of endobronchial ultrasound-
30 guided transbronchial needle aspiration: a retrospective study with histology correlation. *Cancer*
31 *Cytopath* 2009;117(6):482-90.
32 [83] Medford AR, Agrawal S, Bennett JA. Sarcoidosis: Technique to enable diagnosis. *BMJ*
33 2009;339:766-7.
34 [84] Nakajima T, Yasufuku K, Kurosu K, et al. The role of EBUS-TBNA for the diagnosis of
35 sarcoidosis - comparisons with other bronchoscopic diagnostic modalities. *Respir Med* 2009;
36 103(12):1796-800.
37 [85] Tournoy KG, Bolly A, Aerts JG, et al. The value of endoscopic ultrasound after
38 bronchoscopy to diagnose thoracic sarcoidosis. *Eur Respir J* 2010; doi:
39 09031936.00111509v1.
40 [86] Garwood S, Judson MA, Silvestri G, et al. Endobronchial ultrasound for the diagnosis of
41 pulmonary sarcoidosis. *Chest* 2007;132(4):1298-304.
42 [87] Wong M, Yasufuku K, Nakajima T, et al. Endobronchial ultrasound: new insight for the
43 diagnosis of sarcoidosis. *Eur Respir J* 2007;29(6):1182-6.
44 [88] Oki M, Saka H, Kitagawa C, et al. Real-time endobronchial ultrasound-guided
45 transbronchial needle aspiration is useful for diagnosing sarcoidosis. *Respirology*
46 2007;12(6):863-8.
47 [89] Tremblay A, Stather DR, Maceachern P, et al. A Randomized Controlled Trial of Standard
48 vs Endobronchial Ultrasonography-Guided Transbronchial Needle Aspiration in Patients With
49 Suspected Sarcoidosis. *Chest* 2009;136(2):340-6.
50 [90] Kennedy MP, Jimenez CA, Bruzzi JF, et al. Endobronchial ultrasound-guided
51 transbronchial needle aspiration in the diagnosis of lymphoma. *Thorax* 2008;63(4):360-5.
52 [91] Nakajima T, Yasufuku K, Suzuki M, et al. Assessment of epidermal growth factor
53 receptor mutation by endobronchial ultrasound-guided transbronchial needle aspiration. *Chest*
54 2007;132(2):597-602.
55
56
57
58
59
60

- 1
2
3
4 [92] Garcia-Olive I, Monso E, Andreo F, et al. Endobronchial ultrasound-guided transbronchial
5 needle aspiration for identifying EGFR mutations. *Eur Respir J* 2010;35(2):391-5.
6 [93] Nishimura H, Nakajima T, Itakura M, et al. Successful treatment of lung cancer with
7 gefitinib and EGFR mutation status determination using EBUS-TBNA samples in an extremely old
8 patient. *Int Med* 2009;48(21):1905-7.
9 [94] Herth FJ, Morgan RK, Eberhardt R, Ernst A. Endobronchial ultrasound-guided miniforceps
10 biopsy in the biopsy of subcarinal masses in patients with low likelihood of non-small cell lung
11 cancer. *Ann Thorac Surg* 2008;85(6):1874-8.
12 [95] Garcia-Olive I, Monso E, Andreo F, et al. Sensitivity of linear endobronchial
13 ultrasonography and guided transbronchial needle aspiration for the identification of nodal
14 metastasis in lung cancer staging. *Ultrasound Med Biol* 2009;35(8):1271-7.
15 [96] Steinfort DP, Irving LB. Sarcoidal reactions in regional lymph nodes of patients with non-
16 small cell lung cancer: Incidence and implications for minimally invasive staging with
17 endobronchial ultrasound. *Lung Cancer* 2009;66(3):305-8.
18 [97] Aumiller J, Herth FJ, Krasnik M, Eberhardt R. Endobronchial ultrasound for detecting
19 central pulmonary emboli: a pilot study. *Respiration* 2009;77(3):298-302.
20 [98] Rice DC, Steliga MA, Stewart J, et al. Endoscopic ultrasound-guided fine needle
21 aspiration for staging of malignant pleural mesothelioma. *Ann Thorac Surg* 2009;88(3):862-8.
22 [99] Soja J, Grzanka P, Sladek K, et al. The Use of Endobronchial Ultrasonography in
23 Assessment of the Bronchial Wall Remodeling in Asthma Patients. *Chest* 2009;136(3):797-804.
24 [100] Harley DP, Krinsky WS, Sarkar S, et al. Fiducial marker placement using endobronchial
25 ultrasound and navigational bronchoscopy for stereotactic radiosurgery: an alternative strategy.
26 *Ann Thorac Surg* 2010;89(2):368-73.
27
28
29
30
31
32
33
34
35
36
37
38
39
40
41
42
43
44
45
46
47
48
49
50
51
52
53
54
55
56
57
58
59
60

1
2
3
4 **Figure legends**
5
6
7

8 **Figure 1: Regional lymph node map. Reproduced with permission from: Mountain CF, Dresler**
9 **CM. Regional lymph node classification for lung cancer staging. Chest 1997; 111: 1718-23.**
10

11
12
13 **Figure 2: Typical linear probe EBUS-TBNA image (prior to sampling) of lymph node with adjacent**
14 **aorta (illustrated in power Doppler mode below).**
15
16

17
18
19 **Figure 3: Figure A and B: (Linear probe) EBUS-TBNA has the ultrasound probe at the distal end of**
20 **the EBUS bronchoscope. The direct view is 30° to the horizontal. The biopsy needle is placed**
21 **through the working channel, extending from the bronchoscope end at 20° to the direct view.**
22
23

24 **Figure C: The ultrasound image (needle in a node) is a 50° slice, in parallel to the long axis of**
25 **the EBUS bronchoscope (power Doppler flow image shown in bottom half). Reproduced with**
26 **permission from: Sheski FD, Mathur PN. Endobronchial ultrasound. Chest 2008; 133(1): 264-70.**
27
28 **AO: aorta, LN: lymph node.**
29
30
31
32

33
34
35 **Figure 4: Left: Radial probe EBUS-TBNA. Radial probe is placed in the EBUS bronchoscope**
36 **working channel but must be removed prior to sampling. Right: the radial probe ultrasound**
37 **image is 360 degrees to the long axis of the EBUS bronchoscope. Reproduced with permission**
38 **from: Sheski FD, Mathur PN. Endobronchial ultrasound. Chest 2008; 133(1): 264-70. LN#3:**
39 **lymph node.**
40
41
42
43
44
45
46
47
48
49
50
51
52
53
54
55
56
57
58
59
60

Table 1

Advantages over conventional TBNA	Advantages over mediastinoscopy	Disadvantages
Direct vision (additional ultrasound features) of node and vessels	Minimally invasive (can also do with flexible bronchoscopy and EUS-FNA in one visit) and less adhesions (restaging?)	Lower negative predictive value to mediastinoscopy (currently)
Higher sensitivity	Higher turnover: day case, no general anesthesia	Less core tissue than mediastinoscopy and bronchial epithelial cell contamination possible
Wider accessibility (stations 1-3,10-11, see Figure 1)	Wider accessibility (stations 5,6 and 8,9 if EUS-FNA too, see Figure 1)	Training and learning curve
Real-time sampling: safer	Cheaper: not in theatre, out patient, no anesthetist	High initial capital costs and running cost of needle
Larger tissue size: needle more robust	Quicker procedure time than mediastinoscopy	Two operators: time and staff factors
Image capture	Greater availability: performed by pulmonologists and thoracic surgeons	Vulnerable to tariff-based revenue systems: innovative technique

Advantages and disadvantages of EBUS-TBNA compared to other staging techniques

Table 2

Technique	Sensitivity	Negative predictive value	Prevalence (range)
Cervical mediastinoscopy	78-81%	91%	39% (15-71)
Conventional TBNA	76-78%	71-72%	75% (30-100)
EBUS-TBNA	88-93%	76%	68% (17-98)
EUS-FNA	84-88%	77-81%	61% (33-85)

Relative performance of surgical and minimally invasive mediastinal staging techniques based on data from systematic reviews and meta-analyses[63,65-69].

Table 3

Study	No	Technique	Sensitivity (%)	Specificity (%)	NPV (%)	Prevalence (%)	Node size (mm)
Herth et al[57]	97	EBUS-TBNA*	89	100	98.9	8.2	<10 (mean 7.9)
Yasufuku et al[58]	102	EBUS-TBNA	92.3	100	97.4	23.6	5-22 (mean 8.7)
		CT	76.9	55.3	87.5		
		PET	80.0	70.1	91.5		
Hwangbo et al[59]	117	EBUS-TBNA	90.0	100	96.7	26	5-20
		PET/CT	70.0	59.8	85.2		
Szlubowski et al [62]	120	EBUS-TBNA/ EUS-FNA	68	98	91	22	<10

Studies evaluating EBUS-TBNA in either the “normal” radiological (according to PET and CT) mediastinum or comparing to CT and PET staging. *Compared to normal PET and CT.

Table 4

Study	No	Technique	Sensitivity (%)	Specificity (%)	NPV (%)	Prevalence (%)	Node size (mm)
Comparative studies							
Ernst et al[70]	66	EBUS-TBNA	87	100	78	89	>10
		MEDI	68	100	59		
Yasufuku et al [71]*	33	EBUS-TBNA	77	100	86	39	2-23 (mean 6.7)
		MEDI	85	100	90		
Non-comparative studies							
Szlubowski et al[73]	206	EBUS-TBNA	89	100	83.5	61	5-23 (mean 13.8)
Rintoul et al[74]	109	EBUS-TBNA	91	100	60	71	n/a

Comparative and non-comparative studies evaluating EBUS-TBNA and mediastinoscopy (MEDI). *Denotes in abstract form (preliminary results to date).

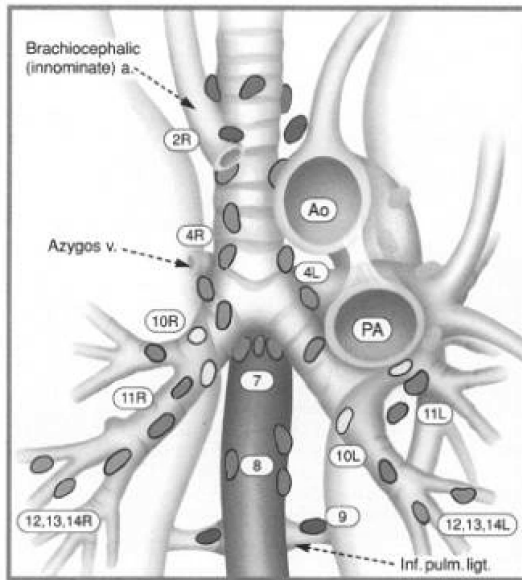
Table 5

Study	No	Criteria	Technique	Sensitivity (%)	Node size (mm)
Medford et al[83]	9*	Stage 1	EBUS-TBNA	78	20-40
Nakajima et al[84]	31	Stage 1	EBUS-TBNA	90.3	>10
Tournoy et al[85]	80	Initial negative FB	EBUS-TBNA	71	n/a
Garwood et al[86]	48	All stages	EBUS-TBNA	85	4-40 (mean 16)
Wong et al[87]	65	Stage 1-2	EBUS-TBNA	87.5	7-37 (mean 20.5)
Oki et al[88]	15	Stage 1-2	EBUS-TBNA	93	>10
Tremblay et al[89]	50	Stage 1	EBUS-TBNA	83.3	>10
			TBNA	60.9	

Studies evaluating EBUS-TBNA for the diagnosis of sarcoidosis. *Denotes case series only.

FB = flexible bronchoscopy.

1
2
3
4
5
6
7
8
9
10
11
12
13
14
15
16
17
18
19
20
21
22
23
24
25
26
27
28
29
30
31
32
33
34
35
36
37
38
39
40
41
42
43
44
45
46
47
48
49
50
51
52
53
54
55
56
57
58
59
60



Superior Mediastinal Nodes

- 1 Highest Mediastinal
- 2 Upper Paratracheal
- 3 Pre-vascular and Retrotrachea
- 4 Lower Paratracheal (including Azygos Nodes)

N₂ = single digit, ipsilateral
N₃ = single digit, contralateral or supraclavicular

Aortic Nodes

- 5 Subaortic (A-P window)
- 6 Para-aortic (ascending aorta or phrenic)

Inferior Mediastinal Nodes

- 7 Subcarinal
- 8 Paraesophageal (below carina)
- 9 Pulmonary Ligament

N₁ Nodes

- 10 Hilar
- 11 Interlobar
- 12 Lobar
- 13 Segmental
- 14 Subsegmental

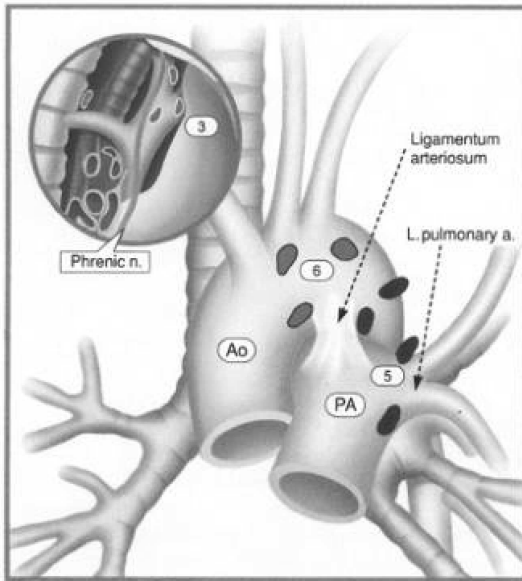
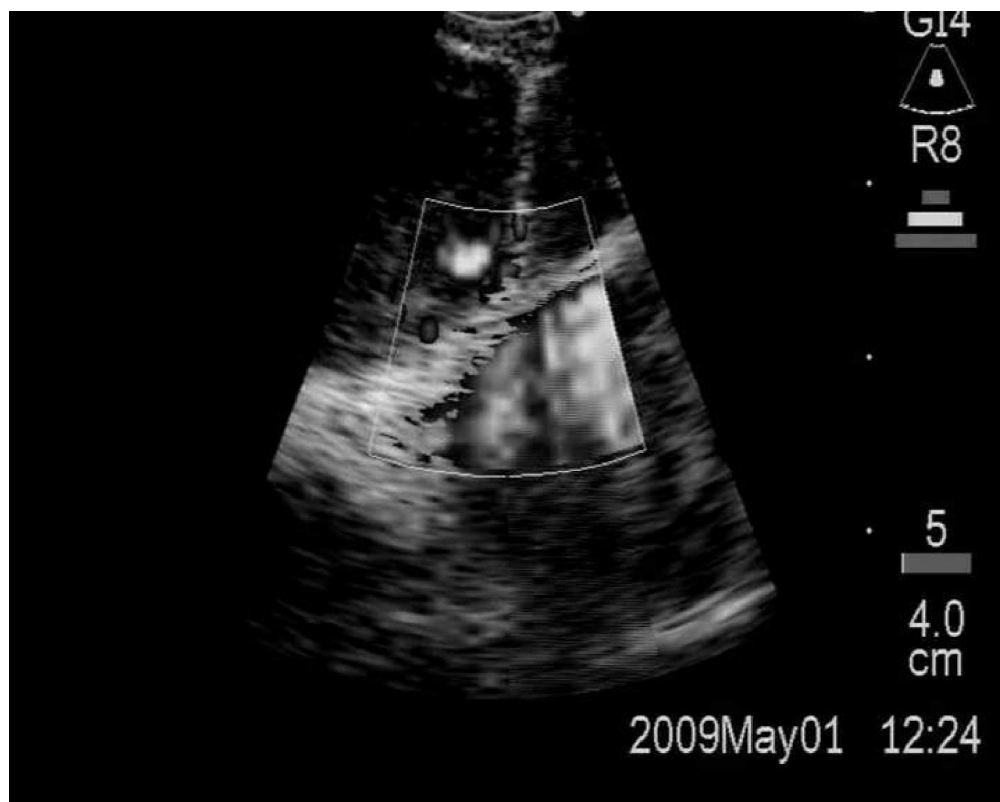

Figure 1: Regional lymph node map. Reproduced with permission from: Mountain CF, Dresler CM. Regional lymph node classification for lung cancer staging. Chest 1997; 111: 1718-23. 104x126mm (600 x 600 DPI)



34
35
36
37
38
39
40
41
42
43
44
45
46
47
48
49
50
51
52
53
54
55
56
57
58
59
60

Figure 2: Typical linear probe EBUS-TBNA image (prior to sampling) of lymph node with adjacent aorta (illustrated in power Doppler mode below).
190x151mm (600 x 600 DPI)

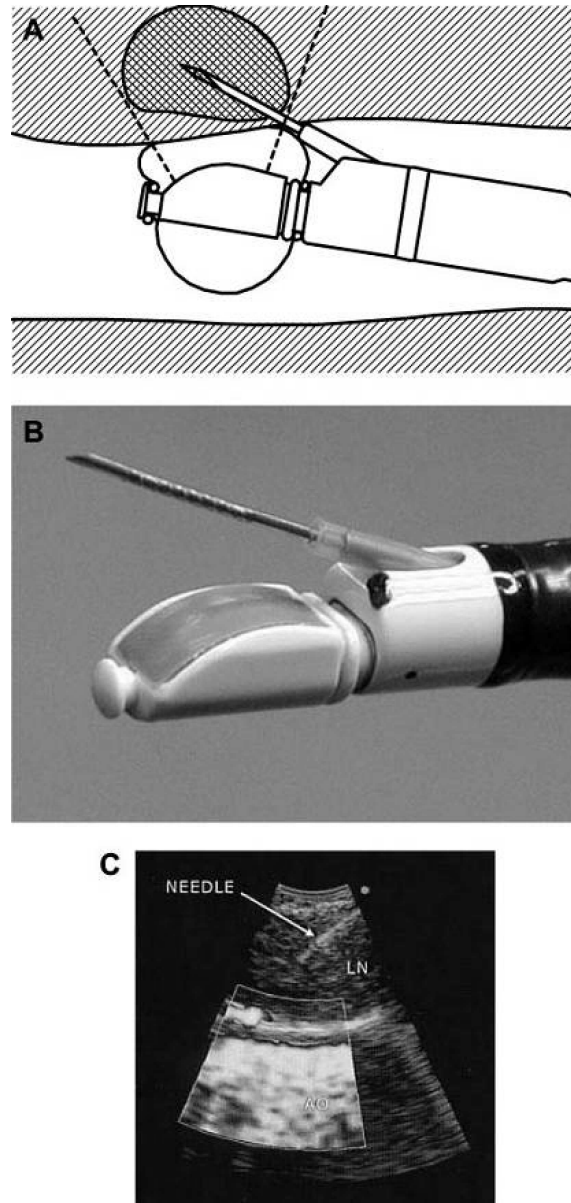


Figure 3: Figure A and B: (Linear probe) EBUS-TBNA has the ultrasound probe at the distal end of the EBUS bronchoscope. The direct view is 30° to the horizontal. The biopsy needle is placed through the working channel, extending from the bronchoscope end at 20° to the direct view. Figure C: The ultrasound image (needle in a node) is a 50° slice, in parallel to the long axis of the EBUS bronchoscope (power Doppler flow image shown in bottom half). Reproduced with permission from: Sheski FD, Mathur PN. Endobronchial ultrasound. *Chest* 2008; 133(1): 264-70. AO: aorta, LN: lymph node. 70x148mm (600 x 600 DPI)

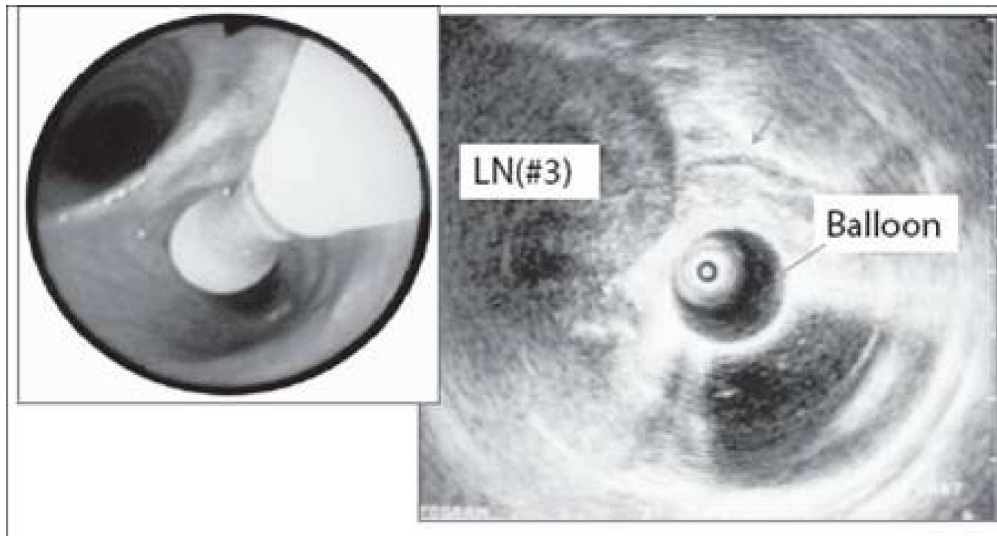


Figure 4: Left: Radial probe EBUS-TBNA. Radial probe is placed in the EBUS bronchoscope working channel but must be removed prior to sampling. Right: the radial probe ultrasound image is 360 degrees to the long axis of the EBUS bronchoscope. Reproduced with permission from: Sheski FD, Mathur PN. Endobronchial ultrasound. Chest 2008; 133(1): 264-70. LN#3: lymph node. 119x63mm (600 x 600 DPI)