



HAL
open science

An innovative local treatment for staphylococcal scalded skin syndrome

E. Mueller, M. Haim, T. Petnehazy, B. Acham-Roschitz, M. Trop

► **To cite this version:**

E. Mueller, M. Haim, T. Petnehazy, B. Acham-Roschitz, M. Trop. An innovative local treatment for staphylococcal scalded skin syndrome. *European Journal of Clinical Microbiology and Infectious Diseases*, 2010, 29 (7), pp.893-897. 10.1007/s10096-010-0927-x . hal-00589724

HAL Id: hal-00589724

<https://hal.science/hal-00589724>

Submitted on 1 May 2011

HAL is a multi-disciplinary open access archive for the deposit and dissemination of scientific research documents, whether they are published or not. The documents may come from teaching and research institutions in France or abroad, or from public or private research centers.

L'archive ouverte pluridisciplinaire **HAL**, est destinée au dépôt et à la diffusion de documents scientifiques de niveau recherche, publiés ou non, émanant des établissements d'enseignement et de recherche français ou étrangers, des laboratoires publics ou privés.

An innovative local treatment for staphylococcal scalded skin syndrome

E. Mueller · M. Haim · T. Petnehazy ·
B. Acham-Roschitz · M. Trop

Received: 16 October 2009 / Accepted: 3 April 2010 / Published online: 1 May 2010
© Springer-Verlag 2010

Abstract Staphylococcal scalded skin syndrome (SSSS) is the clinical term used to describe a range of blistering skin disorders induced by the exfoliative toxins of *Staphylococcus aureus* and prevalently affects neonates, infants and toddlers who lack antibodies to *S. aureus* toxins. SSSS is a highly contagious disease and is characterised by erythema and fever, followed by the formation of large fragile superficial blisters, which rupture only to leave extensive areas of denuded skin. A diagnosis of SSSS relies on the clinical picture, as well as on histological and microbiological findings. Neonates and young infants are particularly susceptible to a lack of the protective skin barrier, which may cause excessive protein and fluid losses, hypothermia and secondary infection. Due to a complete denudation of skin, the patients also suffer from almost unbearable pain. In our communication, we present an innovative temporary coverage of the denuded skin with Suprathel® (PolyMedics Innovations GmbH, Denkendorf, Germany). Suprathel® relieves pain, prevents heat loss and secondary infection, accelerates wound healing, does not need to be changed and makes daily care easy for the nurses and is well tolerable for the patient.

In 1878, Baron Gottfried Ritter von Rittershain [1] described a remarkable type of disease in the newborn and named it “dermatitis exfoliativa”, which was, thereafter, referred to as “Ritter’s disease”. The aetiology of the disease was not known to him and von Rittershain believed devoutly that dermatitis exfoliativa was not contagious. In 1970, Melish and Glasgow [2] discovered the aetiological agent for Ritter’s disease to be phage Group 2 coagulase-positive staphylococci and reproduced the skin lesions using cultured supernatant strain TA (phage type 71, Group 2) in a neonatal mouse model. They called this disease entity staphylococcal scalded skin syndrome (SSSS). The clinical term SSSS is used to describe a range of blistering skin disorders induced by the exfoliative toxins (ETs) of *Staphylococcus aureus*. ETs are spread haematogenously from a localised source and, in the absence of specific antitoxin antibodies, cause widespread epidermal damage. In 2008, Nishifuji et al. [3] described the ETs’ action and coined the term “molecular scissors”. Virulent strains of the bacteria produce ETs that cause the loss of keratinocyte cell–cell adhesion in the superficial epidermis. The three isoforms of ETs, i.e. ETA, ETB and ETD, are glutamate-specific serine proteases that specifically and efficiently cleave a single peptide bond in the extracellular region of human and mouse desmoglein1 (Dsg1), a desmosomal intercellular adhesion molecule. Staphylococcal exfoliative toxins act as “molecular scissors” to facilitate percutaneous bacterial invasion by cleavage of keratinocyte cell–cell adhesion molecules. ETB-producing *S. aureus* is the predominant isolate in generalised SSSS and its ETs show species specificity for Dsg1 cleavage. SSSS prevalently affects neonates, infants and toddlers who lack antibodies to *S. aureus* toxins; only 41% of children aged 2 to 5 years but 91% of adults older than 40 years have antibodies against ETA. SSSS is a highly contagious disease and is characterised by erythema and fever, followed by the formation of large

E. Mueller · M. Trop (✉)
Paediatric Burns Centre, Medical University of Graz,
Graz, Austria
e-mail: marija.trop@medunigraz.at

M. Haim
Department of Neonatology, Medical University of Graz,
Graz, Austria

T. Petnehazy
Department of Paediatric Surgery, Medical University of Graz,
Graz, Austria

B. Acham-Roschitz
Department of Paediatrics, Medical University of Graz,
Graz, Austria

fragile superficial blisters, which rupture to leave extensive areas of denuded skin. In the generalised form, fluid from intact bullae is generally sterile and the infecting strain is usually recovered from distant sites, such as the throat and/or nose. Renal function plays a critical role in determining susceptibility to the generalised form of the disease in neonates and in adults [4]. The diagnosis of SSSS relies on the clinical picture as well as on histological and microbiological findings. Histopathologically, SSSS is marked by keratinocyte detachment in the superficial layers of the dermis and intra-epidermal blistering without induced keratinocyte necrosis [3].

We report the case of a male infant who had to stay in hospital since birth due to different congenital malformations resulting in major illnesses. The boy was delivered by caesarean section at 36 weeks of gestation because of oligohydramnios. Postpartum, a left lower limb deformity consisting of tibial and distal femoral aplasia, club foot and mirror foot was observed. He had multiple vertebral anomalies at different levels of the spine. Prenatally, he showed renal agenesis of the right kidney and hydronephrosis of the contralateral kidney. At 4 days of age, the patient developed a renal insufficiency with elevated serum creatinine concentration and was taken to surgery for decompression of the obstructed urinary system by percutaneous nephrostomy and insertion of a left nephrostomy tube. Due to the chronic renal insufficiency, he suffered from hypocalcaemia, hyperkalaemia, hyperphosphataemia, secondary hyperparathyroidism and renal anaemia. At 5 days of age, his abdomen had become distended and he began vomiting bile-stained fluid. An exploratory laparotomy was performed, which revealed a perforated ascending colon and an ileostomy was fashioned. Due to an interoperatively determined small bowel length of 60–85 cm and the fact that he demonstrated failure to thrive, he was diagnosed with congenital short bowel syndrome. At the age of 5 weeks, the patient again showed features of an acute abdomen and was taken to surgery for re-operation. A resection of part of the small intestine, a resection of part of the large intestine and a reduction of an intussusception were performed. A third laparotomy conducted at the age of 6 weeks showed a stenosis of the rectosigmoid junction. A double-barrel colostomy of the sigmoid colon was performed. At the age of 3 months, he underwent a colostomy reversal to rejoin the colon. Because the patient refused any food, a percutaneous endoscopic gastronomy (PEG) tube was inserted at the age of 11 months. The main problem regarding nursing care was severe diaper dermatitis with ulceration caused by intractable diarrhoea (at least ten stools a day) as a result of the combination of the short bowel syndrome and the renal insufficiency. The diaper dermatitis proved to be intractable to any local treatment. Microbiological analysis of the diaper area (specifically, the anus) repeatedly showed the presence of *Escherichia coli*, *Enterobacter cloacae*, *Klebsiella pneumoniae* and *Enterococcus faecalis*, as well as *S. aureus*.

At the age of 14 months, the boy suddenly developed fever, malaise and was more irritable than usual due to the discomfort of his persistent diaper dermatitis—although he was on permanent pain therapy. During routine night time care, a nurse spotted an erythematous rash on the skin of the trunk and facial area. Within only a few hours, the rash spread on the tender and painful skin and small flaccid bullae erupted. The patient was given an antibiotic (Cefuroxim) intravenously, increased parenteral fluid support and was transferred to the children's burns unit. The next morning the patient was taken to the operating room (OR). Under anaesthesia large sheets of epidermal detachment were removed and swabs taken (which remained sterile) (Fig. 1). The total body surface area affected was more than 50%. Mucous membranes and nails were not affected. Nikolsky's sign was positive. On the cleaned, oozing superficial red wounds, Suprathel® (PolyMedics Innovations GmbH, Denkendorf, Germany) was applied; above it, one layer of paraffin and absorbent gauze, secured with an elastic netting (Figs. 2 and 3). The next day, the wound check in the OR revealed new lesions all over the body, so that, in the end, 90% total body surface area was affected after 36 hours (Figs. 4 and 5). Suprathel® wound dressing was extended to the whole body with the exclusion of the genital region due to the frequent loose stools. Since SSSS is toxin-mediated, the lesions may continue to appear for 24–36 hours after the start of the antibiotic treatment. Any Suprathel® that became dislodged or any new areas of SSSS that developed after the first application were covered with new Suprathel®. With Suprathel® in place, the patient's pain dramatically decreased and the wounds needed no further treatment. Skin biopsy was obtained from the right flank and the histological examination—showing mid-epidermal cleavage with minimal inflamma-

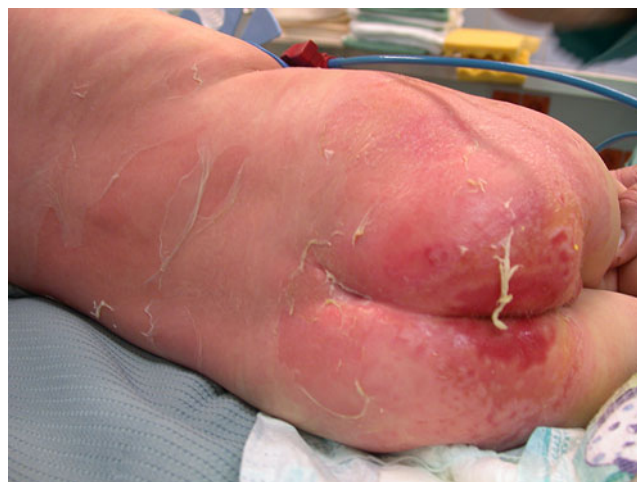

Fig. 1 Sheets of epidermal detachment on the patient's back and diaper dermatitis as presented at the first admission to the operating room

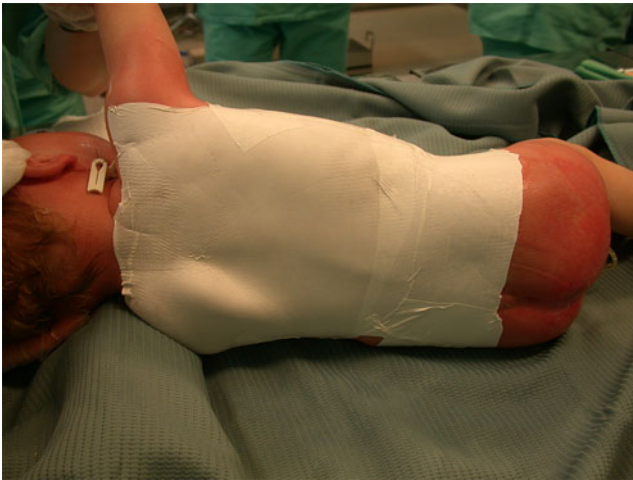


Fig. 2 Suprathel® was applied on the cleaned red wounds

tion—confirmed the clinical diagnosis of SSSS. *S. aureus* strains isolated from the colonised site of the diaper dermatitis skin lesions grew methicillin-sensitive *S. aureus* (MSSA) producing ETB. Complicated electrolyte and fluid management in this particular case was accomplished in cooperation with paediatric nephrologists. The intravenous dosage of the antibiotic was adapted based on the impaired renal function (serum creatinine between 266 and 354 $\mu\text{mol/L}$, normal range 26–44 $\mu\text{mol/L}$). With Suprathel® treatment as a whole-body dressing, the blister formation subsided and complete resolution occurred within five days, without scarring (Figs. 6 and 7). The patient was transferred back to the Department of Neonatology after seven days at the paediatric burns unit. The intravenous antibiotic therapy was continued for a total course of 14 days.

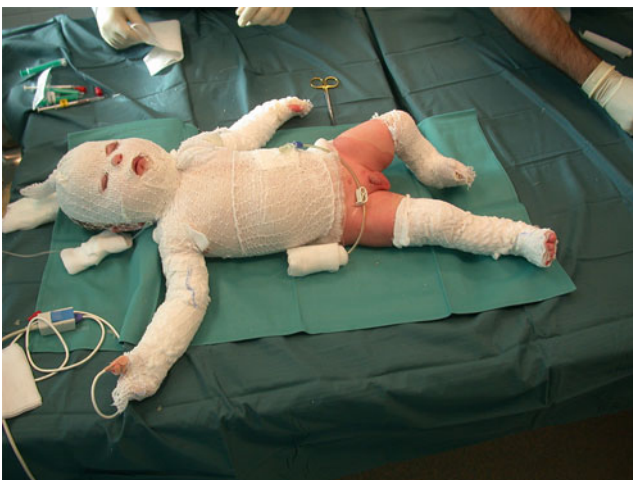

Fig. 3 Complete temporary coverage of the denuded skin with Suprathel®, a layer of paraffin and absorbent gauze secured with elastic netting

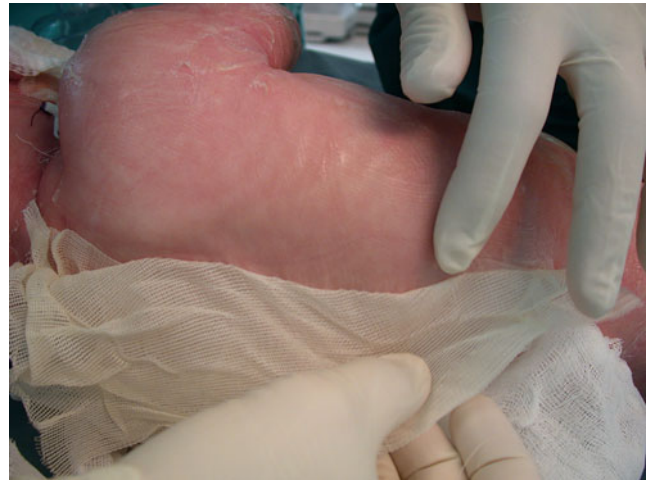

Fig. 4 Wound check on the second day: Suprathel® became transparent and adheres well to the wounds

Since the aetiology of SSSS has been known and antibiotics have been available, systemic antibiotic therapy has become a standard treatment. In severe cases, intravenous therapy with anti-staphylococcal antibiotics is required. In patients with initial therapeutic failure using conventional antibiotics, one should not forget the possibility of methicillin-resistant *S. aureus* (MRSA) involvement. Topical antibiotics in generalised SSSS are often not effective, since the focus of infection is usually not known and often distant from the site of blistering. They should also be avoided due to unpredictable absorption through denuded skin. Silver sulfadiazine, which is still used in some burns units, is not recommended for SSSS because of enhanced systemic absorption through denuded skin [5]. Steroids are contraindicated on the basis of both experimental and clinical evidence [6]. In addition to the antibiotic management strategy, about which there is no controversy, there is a vast consensus that patients with

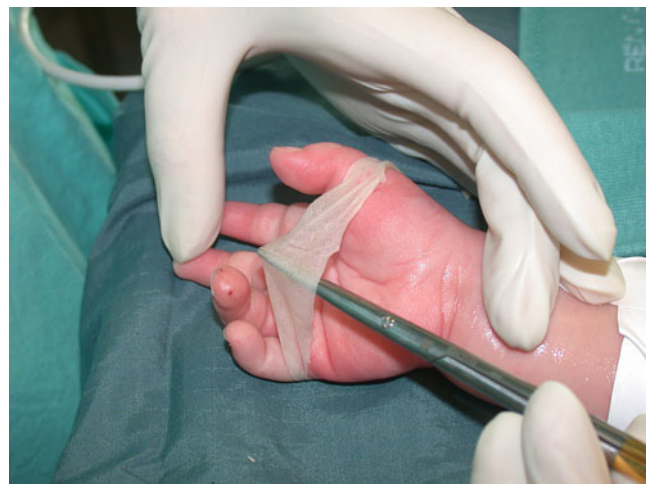

Fig. 5 New lesions appeared on day two

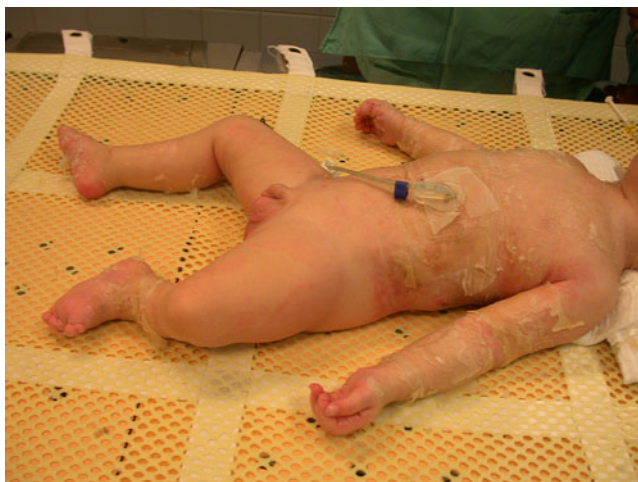

Fig. 6 Day five: Suprathel® peels away and can be easily removed with any emollient

severe blistering skin diseases are better managed in burns units. Burns units have a number of specialised facilities and a team trained in dealing with all aspects of major burns [7]. Core temperature and room temperature need to be monitored carefully, as thermal dysregulation is common; even though the patient is febrile, peripheral vasodilatation adds to loss of heat and may cause a drop in the core temperature. Despite the burn-like appearance of SSSS, massive fluid resuscitation is not required since the massive burn oedema, which develops after thermal injury, does not appear in SSSS. Pain management and local skin care represent the major challenges in SSSS. The choice of analgesia must be based on the needs of the patient and opiates are preferred. Selecting the proper wound dressing helps to alleviate pain remarkably—but skin care in generalised SSSS is the most divergently discussed topic. Lowney et al. [8] recommend general measures: “the skin must be treated gently and kept clean.” Margileth [9] states:

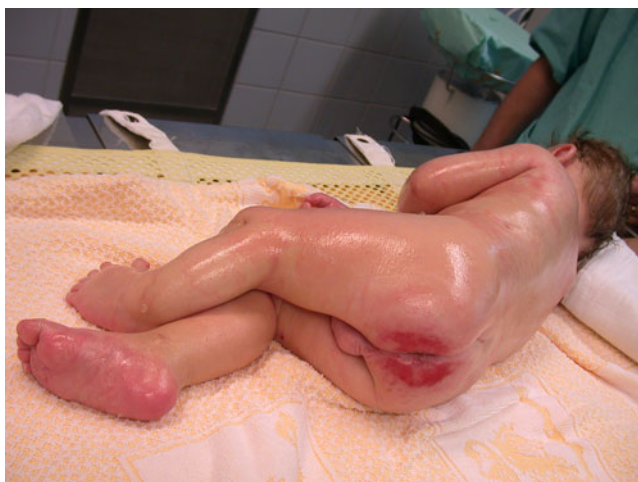

Fig. 7 Skin lesions are healed completely on day five

“Topical therapy includes manual removal of denuded skin, using aseptic technique two or three times daily. Patients with extensive (over 50%) denuded skin might be treated as burn patients using continuous 0.5% silver nitrate compresses for several days.” Elias et al. [10] used cool, continuous wet dressings with 0.5% silver nitrate alternating with the application of mafenide acetate or sulfadiazine silver cream. Simpson [11] advocates: “The child should be nursed in a warm environment with minimal clothing. An emollient, such as a 50:50 mix of white soft paraffin and liquid paraffin, may be applied to lesions to reduce fluid loss and soothe the area.” Patel [12] suggests: “Blisters should be left intact and eroded skin treated with emollients or covered with Vaseline impregnated gauze to maintain skin barrier function, as well as reduce further skin trauma.” Blyth et al. [13] advises: “Sterile dressings are required and these should be applied in theatre initially to minimise the pain involved and to reduce the infection risk. Daily theatre changes of dressings are required until recovery starts.”

In our case, the main focus of attention at the burns unit was given to the denuded skin and the subsequent implications of such a large wound area. We used Suprathel® in this patient as a wound cover. Suprathel®, a newly developed wound dressing, is produced from a synthetic copolymer consisting mainly of DL-lactide (>70%), trimethylene carbonate and ϵ -caprolactone. It represents a synthetic dressing that imitates the properties of natural epithelium and consists of a membrane with 80% porosity. Pore sizes vary between 2 and 50 μm . Its moisture permeability prevents the accumulation of wound fluid, supporting wound healing and re-epithelisation. It is also permeable to oxygen. During the course of re-epithelisation, the membrane becomes transparent, allowing the evaluation of the wound bed without manipulation of the wound dressing itself. Suprathel® can be quite simply adapted to any body part and does not hinder the patient’s mobilisation and comfort. Mechanical alteration is avoided by the spontaneous attachment due to the adsorption of wound secretion. Suprathel® as a material itself may be costly *prima facie* (1 cm^2 costs 50 to 60 cents); however, comparing the overall treatment cost to a material which needs daily dressing changes and causes painful discomfort for the patient reveals a reduction of costs overall. We use Suprathel® in children with superficial and deep dermal burns with good results. The clinical studies in burn patients confirmed the promotion of re-epithelisation, minimisation of pain, reduction of patient discomfort and cost-effectiveness [14, 15]. Taking these qualities into account, the wound dressing Suprathel® should be introduced into the field of acute non-burn conditions in children as well, because the local treatment with Suprathel® in SSSS relieves pain, prevents heat loss and secondary infection, accelerates wound healing, does not

need to be changed and, hence, makes daily care easy for the nurses and is well tolerated by the patient. This is also the first case report where Suprathel® has been used as a whole-body dressing for local treatment in SSSS.

We browsed the literature for relevant references about where and how to treat skin lesions in patients with generalised SSSS, and frequent recommendations to treat severe cases in burns units were found. Recommendations on how to treat skin lesions differ enormously from very general to very specific. From the published references, the impression emerges that wound handling is usually painful, the dressing procedures may have to be repeated several times a day, recommended cool and wet dressings enhance the danger of hypothermia and when silver dressings have been used, silver absorption is uncontrollable. The handling of the patient is far from easy for the nursing staff and unpleasant and dolorous for the patient. With complete temporary coverage of the denuded skin with Suprathel®, a layer of paraffin and absorbent gauze secured with elastic netting, a whole-body dressing is created. The handling of the patient in question was easier, hypothermia did not occur and the nurses' acceptance of the whole-body dressing was outstanding.

Conflict of interest The authors indicate that they have no financial relationships to this article to disclose and they do not have any relationship to the manufacturer of the described dressing.

References

- Ritter von Rittershain G (1878) Die exfoliative dermatitis jüngerer Säuglinge. Zent-Ztg Kinderheilkunde 2:3–23
- Melish ME, Glasgow LA (1970) The staphylococcal scalded-skin syndrome: development of an experimental model. N Engl J Med 282:1114–1119
- Nishifuji K, Sugai M, Amagai M (2008) Staphylococcal exfoliative toxins: “molecular scissors” of bacteria that attack the cutaneous defense barrier in mammals. J Dermatol Sci 49:21–31
- Cribier B, Piemont Y, Grosshans E (1994) Staphylococcal scalded skin syndrome in adults. A clinical review illustrated with a new case. J Am Acad Dermatol 30:319–324
- Murray RJ (2005) Recognition and management of *Staphylococcus aureus* toxin-mediated disease. Intern Med J 35(Suppl 2): S106–S119
- Ladhani S, Joannou CL, Lochrie DP, Evans RW, Poston SM (1999) Clinical, microbial, and biochemical aspects of the exfoliative toxins causing staphylococcal scalded-skin syndrome. Clin Microbiol Rev 12(2):224–242
- Sheridan RL, Briggs SE, Remensnyder JP, Gagnon SW, Doody DP, Ryan DP, Tompkins RG (1995) The burn unit as a resource for the management of acute nonburn conditions in children. J Burn Care Rehabil 16(1):62–64
- Lowney ED, Baublis JV, Kreye GM, Harrell ER, McKenzie AR (1967) The scalded skin syndrome in small children. Arch Dermatol 95(4):359–369
- Margileth AM (1975) Scalded skin syndrome: diagnosis, differential diagnosis, and management of 42 children. South Med J 68(4):447–454
- Elias PM, Fritsch P, Epstein EH (1977) Staphylococcal scalded skin syndrome. Clinical features, pathogenesis, and recent microbiological and biochemical developments. Arch Dermatol 113(2):207–219
- Simpson C (2003) The management of staphylococcal scalded skin syndrome in infants. Nurs Times 99(42):59–61
- Patel GK (2004) Treatment of staphylococcal scalded skin syndrome. Expert Rev Anti Infect Ther 2(4):575–587
- Blyth M, Estela C, Young AE (2008) Severe staphylococcal scalded skin syndrome in children. Burns 34(1):98–103
- Uhlig C, Rapp M, Hartmann B, Hierlemann H, Planck H, Dittel KK (2007) Suprathel—an innovative, resorbable skin substitute for the treatment of burn victims. Burns 33(2):221–229
- Schwarze H, Küntscher M, Uhlig C, Hierlemann H, Prantl L, Ottomann C, Hartmann B (2008) Suprathel, a new skin substitute, in the management of partial-thickness burn wounds: results of a clinical study. Ann Plast Surg 60(2):181–185