



HAL
open science

LONG TERM FOLLOW UP WITH I-CARE PHACIC IOLs

Sophie Plainer, Elfriede Wenzl, Ali A Saalabian, Christina Wohlfart, Bertram Vidic, Yosuf El-Shabrawi, Navid Ardjomand

► **To cite this version:**

Sophie Plainer, Elfriede Wenzl, Ali A Saalabian, Christina Wohlfart, Bertram Vidic, et al.. LONG TERM FOLLOW UP WITH I-CARE PHACIC IOLs. *British Journal of Ophthalmology*, 2010, 95 (5), pp.710. 10.1136/bjo.2009.172650 . hal-00588345

HAL Id: hal-00588345

<https://hal.science/hal-00588345>

Submitted on 23 Apr 2011

HAL is a multi-disciplinary open access archive for the deposit and dissemination of scientific research documents, whether they are published or not. The documents may come from teaching and research institutions in France or abroad, or from public or private research centers.

L'archive ouverte pluridisciplinaire **HAL**, est destinée au dépôt et à la diffusion de documents scientifiques de niveau recherche, publiés ou non, émanant des établissements d'enseignement et de recherche français ou étrangers, des laboratoires publics ou privés.

LONG TERM FOLLOW UP WITH I-CARE PHACIC IOLs

Sophie Plainer, Elfriede Wenzl, Ali A. Saalabian, Christina Wohlfart, Bertram Vidic,
Yosuf El-Shabrawi and Navid Ardjomand

Department of Ophthalmology

Medical University Graz

Graz, Austria

Key words: corneal endothelium, myopia, phakic IOL

Word count: 2176

Correspondence: Navid Ardjomand, MD; Department of Ophthalmology, Medical
University Graz, Auenbruggerplatz 4, A-8036 Graz, Austria; Tel.: ++43 316 385 80704; Fax:
++43 316 304909; email: navid.ardjomand@meduni-graz.at

Licence for Publication

"The Corresponding Author has the right to grant on behalf of all authors and does grant on behalf of all authors, an exclusive licence (or non exclusive for government employees) on a worldwide basis to the BMJ Publishing Group Ltd and its Licensees to permit this article (if accepted) to be published in BJO editions and any other BMJPGGL products to exploit all subsidiary rights, as set out in our licence(<http://group.bmj.com/products/journals/instructions-for-authors/licence-forms/>)."

Competing Interest

Please list Competing Interests if they exist, if not please include the following statement:

"Competing Interest: None to declare."

Abstract

Purpose: To evaluate visual quality and postoperative results as well as adverse events in myopic patients undergoing I-CARE anterior chamber angle supported phakic intraocular lens (IOL) implantation.

Design: A retrospective, nonrandomized, case series.

Participants: Data of 29 eyes (16 patients) receiving I-CARE phakic IOL for high myopia (-11.66 ± 3.3) was analyzed.

Methods: The IOLs were implanted between 2003 and 2006 at the Department of Ophthalmology, Medical University, Graz, Austria. The mean follow up was 51.7 ± 16 months (17 – 78 months).

Main Outcome Measures: We measured uncorrected visual acuity (UCVA) and best-corrected visual acuity (BCVA); patients underwent, slit-lamp examination, corneal topography, Scheimpflug imaging and measurement of endothelial cells (EC).

Results: Mean UCVA and BCVA were 0.63 and 0.94 decimal after one year. Endothelial cell loss was the most serious adverse event observed. Mean EC loss was 2%, 9%, 17%, 21%, 33% and 47% after one (n=17), two (n=20), three (n=17), four (n=17), five (n=12) and six (n=3) years, respectively. Eight IOL explantations were made due to severe EC loss three to six years after implantation.

Other serious complications included one patient with an Urrets-Zavalía Syndrome (1 eye).

Conclusion: Implantation of the I-CARE phakic-IOL is not a safe method for the correction of high myopia due to a serious endothelial cell loss, that might occur in a high number of patients. Patients with these IOLs should be followed up at least every 6 months and the IOL should be explanted, once the EC count drops to less than 2000 cells/mm².

Financial Disclosure(s): The authors have no proprietary or commercial interest in any of the materials discussed in this article.

Introduction

Implantation of phakic intraocular lenses (IOL) for correction of ametropia has gained popularity over the last years, especially in eyes with higher refractive errors, where corneal procedures pose a risk for iatrogenic keratektasia^{1,2}.

The first phakic IOLs for the correction of myopia were introduced by Fechner & Worst and George Baikoff almost 20 years ago³⁻⁶. A high number of different phakic IOLs made of rigid or foldable material have been designed and implanted since then⁷⁻¹⁰. The advantage of foldable compared to rigid phakic IOLs lies in the possibility to implant the IOL through a smaller incision, which reduces surgical time, has less influence on corneal astigmatism and may be stitchless.

A high number of studies on patients receiving rigid phakic IOLs have been published^{8, 9, 11-14}, but data on the outcome of foldable hydrophilic acrylic phakic IOLs are still rare¹⁵⁻¹⁸.

The French Society of Ophthalmology (SFO) withdrew all angle-supported phakic IOLs in 2007 due to severe endothelial cell loss two to three years after implantation⁹.

Two short term studies on the I-CARE lens, a hydrophilic monobloc foldable phakic IOL, have been published, showing good and predictable results¹⁵.

This retrospective study presents for the first time long-term results with foldable I-CARE phakic IOL in patients with high myopia.

Materials and Methods

The I-CARE lens (Corneal, France) is a phakic intraocular lens designed to treat highly short-sighted or hyperopic patients. It is a hydrophilic acrylic monobloc lens with four independent feet. The diameter of the lens' optic is 5.75 mm and it is available with an overall diameter from 12 mm to 13.5 mm.

Data of 16 patients (29 eyes; 6 female, 10 male), who had I-CARE phakic intraocular lens implantation at the Department of Ophthalmology, Medical University Graz between 2003

and 2006 were analyzed retrospectively. This retrospective case series was approved by the local Ethic committee.

Pre- and postoperative clinical examination included slitlamp examination, Goldmann tonometry and corneal topography (Orbscan II, Bausch&Lomb, USA). Additionally endothelial cell (EC) count of the central cornea (Noncon Robo clinical specular microscope, Konan, USA), subjective and cycloplegic refraction and retinoscopy was performed in all patients at all visits.

Pentacam imaging (Oculus, Germany) was performed in all patients postoperatively starting from January 2007.

Candidates for implantation were patients without any major systemic diseases, who presented a stable myopia for at least two years, were older 24 years of age and did not show any other ocular co-morbidity but myopia. Ten patients had soft and six patients had rigid gas permeable contact lenses before phakic IOL implantation.

Visual acuity was tested and documented in decimal, but converted in logMar for statistical analysis. Clinical data of the patients are presented in table 1.

Implantation Technique

IOL size and dioptric power of the lens was calculated with a software available on the homepage of the Corneal company (France), which was based on the subjective and cycloplegic refraction and corneal white-to-white measurement (Orbscan II, Bausch&Lomb, USA).

Anterior chamber depth, measured by Orbscan II topography, was at least 3,4 mm as recommended by the company. EC count was at least 2400 cells/mm² in all cases and corneal astigmatism was less than 3.0 D in all patients (table 2).

All operations were done in local (n=11) or general anaesthesia (18) by one surgeon (BV). The selection of anesthesia technique was based on the patients preference and the anesthesiologists recommendation. YAG iridotomy was performed the day before surgery in all cases.

The pupil was constricted with Miochol[®] (Novartis, Germany), which was applied through a paracentesis. Healon GV (Pfizer, USA) was then injected into the anterior chamber and a 3.0 mm corneoscleral tunnel was performed at the 12 o'clock position in all cases. The I-CARE phakic IOL was implanted with the injector and Healon GV was washed out at the end of the operation with a simcoe cannule. Sutures were not used in any patient.

IOL position

IOL rotation was measured using postoperative photography of the patients.

Decentration of the phakic IOL was determined by deviation of the center of the IOL from the center of the pupil¹⁹

Statistical analysis

One-way ANOVA test was used for evaluating significance of difference during the follow up period for visual acuity (converted in log MAR for statistical analysis), refraction, intraocular pressure and endothelial cell count.

Results

Endothelial Cell Loss

There was no statistical significant decrease of the endothelial cell count within the first year, but a significant decrease could be seen after the second post-operative year. The average EC count was 1850 ± 693 cells/mm² after five and 1544 ± 136 cells/mm² after six years.

Endothelial cell count of less than 2000 cells/mm² was seen in five out of 17 eyes, in five out of 12 eyes and in three out of three eyes after four, five and six years, respectively. Exact data is shown in table 3.

IOL explantation

All IOL explantations were done due to a serious endothelial cell loss.

Eight IOLs were explanted within the third and sixth year after implantation and another two patients (two eyes) were scheduled for IOL explantation at the time of manuscript submission.

Exact data of eyes with IOL explantation are shown in table 4.

Visual acuity and refraction

Uncorrected (UCVA) and best corrected spectacle visual acuity (BCSVA) increased significantly after phakic IOL implantation. Best visual acuity was seen two years after implantation and decreased thereafter again, but the decrease between the second and fifth postoperative year was statistically not significant ($p=0.50$; 2 years vs 5 years) (exact data are shown in table 5).

Spherical equivalent was $-0,26 \pm 0,6$ dpt one month after implantation and remained stable over the entire follow-up period.

Intraocular pressure

Two patients had increase of intraocular pressure (IOP) the day after surgery. IOP could be controlled in one case with a single i.v. application of acetazolamide 500 mg. The second patient developed an Urrets-Zavalía syndrome (Figure 1), but had normal IOP 48 hours after IOL implantation. IOP remained normal in all other patients during the entire follow-up period.

Halos

Halos were reported in six out of 16 patients (37,5%) within the first three postoperative months. Two of these patients received brimonidine tartrate 0,2% ophthalmic solution for a period of three months. None of the patients reported problems with halos one year after phakic IOL implantation.

Pupil Ovalisation 12 eyes (41.4%) out of 29 showed a mild pupil ovalisation. Severe cases of pupil ovalisation were not seen and no explanations had to be made due to this complication (Figure 2).

Rotation and Decentration In 17 cases (58.6%) the phakic IOL rotated at least 10°, the average rotation was 33°.

Decentration of the pIOL appeared in 8 eyes (Figure 3).

Discussion

Phakic IOLs have been introduced in the 1980s for the correction of myopia. George Baikoff introduced an angle-supported and Fechner & Worst an iris-claw phakic IOL³⁻⁶.

Corneal refractive surgery is a limited option, since the treatment of high myopia can result in keratectasia^{1,2}.

The first anterior chamber phakic IOLs were made of rigid material. Several foldable anterior chamber phakic IOLs made of acrylic or silicone material were introduced within the last years^{9, 15, 18, 20}.

Rigid angle supported phakic IOLs have shown good refractive predictability and stable endothelial cell count. However, various serious adverse events including iris ischemia²¹ have also been published. One of the main problems is sizing of the angle-supported phakic IOL²². In cases of over-sizing, the eye will develop pupil ovalization and iris ischemia due to the pressure on the iris roots and in cases of under-sizing the IOL will rotate or dislocate^{11, 21-23}.

Only few studies report on results of hydrophilic acrylic foldable anterior chamber phakic IOLs^{15, 24, 25}.

Our retrospective study investigated clinical outcome and complications after implantation of the I-CARE phakic IOL during a follow-up period of up to 6 years.

Corneal EC count was stable over the first 12 months, but a gradual decrease of the cells was observed between the second and 6th post-operative year. The 6th follow-up year is limited to three eyes of three patients, but all three eyes had an endothelial cell decrease to less than 2000 cells/mm² and the I-CARE IOLs were therefore explanted or scheduled for explantation. 2000 cells/mm² seems to be the critical limit to us and eyes with an I-CARE phakic IOL and an endothelial cell decrease to less than 2000 cells/mm² should be considered for IOL explantation, since all eyes with a central corneal endothelial cell count of less than 2000 cells/mm² seem to be progressive in terms of serious endothelial cell loss.

All anterior chamber phakic IOLs have a potential risk to damage the corneal endothelium. Alio et al. have shown in a retrospective study, that endothelial cell loss was the second most common reason for explantation of rigid anterior chamber phakic IOLs¹¹. The mean explantation time after implantation was almost 9 years and counted for 24% of explantation reasons. In average, the endothelial cell loss with the latest generation of angle-supported rigid anterior chamber phakic IOLs is about 3 to 4% within the first year and then 1 -2% every year^{8, 9, 23}. Two recent studies on foldable material showed similar results. A phase 3 non-randomized multicenter clinical trial showed an endothelial cell loss of 5% with the hydrophobic acrylic Acrysof angle-supported phakic IOL and only 1% cell loss with the foldable silicone iris-claw phakic IOL (Artiflex). However, the follow-up period was only 1 year with the Acrysof and two years with the Artiflex phakic IOL^{17, 20}. Both lenses are not comparable with the I-CARE phakic IOL since they vary in design and material.

Refractive predictability and stability of the I-CARE phakic IOL was similar to other anterior chamber angle supported phakic IOLs^{8, 9, 20, 23}. One patient ended up with a spherical equivalent of -2,0 dpt and a second one with -1,5 dpt. All other patients were within $\pm 1,0$ dpt and the refraction stayed stable over the entire follow up period.

Intraocular pressure did not significantly change after phakic IOL implantation with the exception of two patients developing an intraocular pressure peak of 60 mmHg on the first postoperative day. Whereas the pressure could be managed with acetazolamide in one patient without any long-term complications, the second patient developed an Urrets-Zavalía syndrome with iris ischemia and fixed dilated pupil. This complication is rare after anterior chamber phakic IOL implantation, but has also been described before with other types of phakic IOLs^{26, 27}.

Halos are a known complication after corneal refractive surgery or phakic IOL implantation, if the patient has a large pupil under mesopic or scotopic conditions. Especially patients with the first generation of phakic IOLs complained about halos at night. The newer models in the

late 1990s and beginning of 2000 had better optic edge for reduction of this phenomenon, but patients still described halos in up to 30%⁸. Six of our patients complained about halos immediately after IOL implantation and two patients were successfully started on brimodine eye drops. Lee JH et al have shown that brimonidine application once a day was sufficient to reduce halos after LASIK²⁸. There are no studies showing the effect of brimonidine in patients with phakic IOLs, but our two patients reported reduction of halos and the drops were stopped three months after onset. No patient complained about halos 12 months after IOL implantation.

Pupil ovalization is also a known complication of angle-supported phakic IOLs and counts for 10% of phakic IOL explantations¹¹. It is a result of iris ischemia via pressure on the iris roots²¹. This complication probably happens, when the IOL is over-sized. In contrast to rigid IOLs, which increase the pressure on the iris roots in cases of over-sizing, IOLs made of hydrophilic acrylic material develop a vaulting and decrease the distance to the corneal endothelium. One patient, who had an IOL explantation showed a distance of only 1030 μm from the central anterior surface of the IOL to the central corneal endothelium (Figure 4). Couillet et al. recently presented three cases of I-CARE oversizing resulting in severe corneal endothelial cell decrease with one eye undergoing corneal transplantation for corneal decompensation²⁴.

In cases of under-sizing, the IOL will dislocate or rotate. This happened in 17 out of 29 eyes in our study. IOL rotation has been described in up to 50% within the first 24 postoperative months⁸.

The main problem of anterior chamber phakic IOLs, and especially foldable phakic IOLs, is the importance of exact measurement of the anterior chamber²³. An estimation from the white-to-white distance of the cornea is not adequate, since it does not represent the real anatomical structures of the internal eye.

Our study shows for the first time the long-term problems with the hydrophilic acrylic phakic IOL I-CARE. The lens is withdrawn from the market, but patients with an I-CARE phakic IOL should be seen at least every 6 months and in cases of endothelial cell decrease to less than 2000 cells/mm² IOL explantation should be considered.

References:

1. Condon PI. 2005 ESCRS Ridley Medal Lecture: will keratectasia be a major complication for LASIK in the long term? *J Cataract Refract Surg* 2006;32(12):2124-32.
2. Dupps WJ, Jr., Wilson SE. Biomechanics and wound healing in the cornea. *Exp Eye Res* 2006;83(4):709-20.
3. Fechner PU, van der Heijde GL, Worst JG. The correction of myopia by lens implantation into phakic eyes. *Am J Ophthalmol* 1989;107(6):659-63.
4. Fechner PU, van der Heijde GL, Worst JG. [Intraocular lens for the correction of myopia of the phakic eye]. *Klin Monatsbl Augenheilkd* 1988;193(1):29-34.
5. Baikoff G, Joly P. [Surgical correction of severe myopia using an anterior chamber implant in the phakic eye. Concept--results]. *Bull Soc Belge Ophtalmol* 1989;233:109-25.
6. Baikoff G. Phakic anterior chamber intraocular lenses. *Int Ophthalmol Clin* 1991;31(1):75-86.
7. Saxena R, Boekhoorn SS, Mulder PG, et al. Long-term follow-up of endothelial cell change after Artisan phakic intraocular lens implantation. *Ophthalmology* 2008;115(4):608-13 e1.
8. Perez-Santonja JJ, Alio JL, Jimenez-Alfaro I, Zato MA. Surgical correction of severe myopia with an angle-supported phakic intraocular lens. *J Cataract Refract Surg* 2000;26(9):1288-302.
9. Espandar L, Meyer JJ, Moshirfar M. Phakic intraocular lenses. *Curr Opin Ophthalmol* 2008;19(4):349-56.
10. Kohnen T. Evaluation of new phakic intraocular lenses and materials. *J Cataract Refract Surg* 2007;33(8):1347.

11. Alio JL, Abdelrahman AM, Javaloy J, et al. Angle-supported anterior chamber phakic intraocular lens explantation causes and outcome. *Ophthalmology* 2006;113(12):2213-20.
12. Alio JL, de la Hoz F, Perez-Santonja JJ, et al. Phakic anterior chamber lenses for the correction of myopia: a 7-year cumulative analysis of complications in 263 cases. *Ophthalmology* 1999;106(3):458-66.
13. Baikoff G. Intraocular phakic implants in the anterior chamber. *Int Ophthalmol Clin* 2000;40(3):223-35.
14. Baikoff G, Arne JL, Bokobza Y, et al. Angle-fixated anterior chamber phakic intraocular lens for myopia of -7 to -19 diopters. *J Refract Surg* 1998;14(3):282-93.
15. Gierek-Ciaciura S, Gierek-Lapinska A, Ochalik K, Mrukwa-Kominek E. Correction of high myopia with different phakic anterior chamber intraocular lenses: ICARE angle-supported lens and Verisyse iris-claw lens. *Graefes Arch Clin Exp Ophthalmol* 2007;245(1):1-7.
16. Gierek-Ciaciura S, Ochalik K, Gierek-Lapinska A, Myga B. [Correction of high myopia with anterior chamber angle-supported phakic intraocular lenses--own results]. *Klin Oczna* 2003;105(6):373-7.
17. Dick HB, Budo C, Malecaze F, et al. Foldable Artiflex phakic intraocular lens for the correction of myopia: two-year follow-up results of a prospective European multicenter study. *Ophthalmology* 2009;116(4):671-7.
18. Guell JL, Morral M, Gris O, et al. Evaluation of Verisyse and Artiflex phakic intraocular lenses during accommodation using Visante optical coherence tomography. *J Cataract Refract Surg* 2007;33(8):1398-404.
19. Tahzib NG, MacRae SM, Yoon G, et al. Higher-order aberrations after implantation of iris-fixated rigid or foldable phakic intraocular lenses. *J Cataract Refract Surg* 2008;34(11):1913-20.

20. Kohnen T, Knorz MC, Cochener B, et al. AcrySof Phakic Angle-supported Intraocular Lens for the Correction of Moderate-to-High Myopia: One-Year Results of a Multicenter European Study. *Ophthalmology* 2009.
21. Fellner P, Vidic B, Ramkissoon Y, et al. Pupil ovalization after phakic intraocular lens implantation is associated with sectorial iris hypoperfusion. *Arch Ophthalmol* 2005;123(8):1061-5.
22. Reinstein DZ, Archer TJ, Silverman RH, et al. Correlation of anterior chamber angle and ciliary sulcus diameters with white-to-white corneal diameter in high myopes using artemis VHF digital ultrasound. *J Refract Surg* 2009;25(2):185-94.
23. Lovisolo CF, Reinstein DZ. Phakic intraocular lenses. *Surv Ophthalmol* 2005;50(6):549-87.
24. Couillet J, Mahieu L, Malecaze F, et al. Severe endothelial cell loss following uneventful angle-supported phakic intraocular lens implantation for high myopia. *J Cataract Refract Surg* 2007;33(8):1477-81.
25. Piovella M, Camesasca F, Kusa B. Long-term anterior chamber phakic IOL complications make strict, regular follow-up controls mandatory. Abstract book of the XXIV Congress of the ESCRS 2006.
26. Park SH, Kim SY, Kim HI, Yang SW. Urrets-Zavalía syndrome following iris-claw phakic intraocular lens implantation. *J Refract Surg* 2008;24(9):959-61.
27. Yuzbasioglu E, Helvacioğlu F, Sencan S. Fixed, dilated pupil after phakic intraocular lens implantation. *J Cataract Refract Surg* 2006;32(1):174-6.
28. Lee JH, You YS, Choe CM, Lee ES. Efficacy of brimonidine tartrate 0.2% ophthalmic solution in reducing halos after laser in situ keratomileusis. *J Cataract Refract Surg* 2008;34(6):963-7.

Table 1: Demographic data of the patients

	Mean \pm SD
Age (y)	37,5 \pm 5,9 (28 to 53,21)
Follow up (m)	51,7 \pm 16 (17 - 78)
IOL power in (D)	-11,3 \pm 2,43 (-16,0 to -7,0)
IOL length (mm)	12,9 \pm 0,40 (12 to 13,5)
ACD to Epithelium	3,9 \pm 0,28 (3,44 to 4,4)
W – W (mm)	11,85 \pm 0,38 (11,10 to 12,70)

Table 2: Corneal Astigmatism and phakic IOL distance data.

	Pre-operatively	Post-operatively
Corneal astigmatism (dpt)	1,26 ± 0,7 (0,2 – 2,9); n = 29	1,40 ± 0,58 (0,2 – 2,6); n = 24
Endothelium - IOL (mm)		1,4 ± 0,23 (1,0 – 2,0) n= 23
Crystalline lens - IOL (mm)		1,4 ± 0,29 (1,0 – 2,0) n= 23

Table 3: Endothelial cell count (ECC) (cells/mm²)

	ECC	p
Preoperative (n=29)	2755 ± 161 (2481 – 3300)	
1 year (n=17)	2696 ± 260 (2444 – 3194)	0,941
2 years (n=20)	2503 ± 430 (1111 – 3134)	0,016
3 years (n=19)	2306 ± 582 (751 – 3164)	0,004
4 years (n=17)	2157 ± 574 (1200 – 2785)	0,001
5 years (n=12)	1850 ± 693 (530 – 3030)	0,001
6 years (n=3)	1544 ± 136 (1443 – 1700)	0,006

Table 4: Endothelial cell count (ECC) (cells/mm²) of eyes with IOL explantation at the time of phakic IOL removal

Patient	ECC	Years after implantation
1	1324	3 years
2	751	3 years
3	1302	4 years
4	1550	5 years
5	1098	5 years
6	1697	5 years
7	530	5 years
8	1443	6 years
9	1490	6 years (scheduled)
10	1700	6 years (scheduled)

Table 5: Visual acuity and refraction

	UCVA	BCSVA	SE
Preoperative		0,74±0,22 (0,4 – 1,25)	-11,66 ± 3,3 (-18,0 to -7,0)
1 month (n=21)	0,67±0,2 (0,4 – 1,0)	0,88±0,2 (0,5 – 1,25)	-0,26 ± 0,6 (-1,0 to +1,0)
1 year (n=17)	0,63±0,2 (0,2 – 1,25)	0,94±0,16 (0,5 – 1,25)	-0,50 ± 0,8 (-2,25 to +0,5)
2 years (n=20)	0,70±0,2 (0,5 – 1,0)	0,98±0,17 (0,8 – 1,25)	-0,27 ± 0,7 (-2,0 to +1,0)
3 years (n=17)	0,69±0,2 (0,5 – 1,25)	0,95±0,18 (0,8 – 1,25)	-0,29 ± 0,24 (-0,50 to 0,0)
4 years (n=17)	0,67±0,2 (0,32 – 1,0)	0,90±0,20 (0,63 – 1,25)	-0,40 ± 0,52 (-1,25 to 0,0)
5 years (n=12)	0,59±0,2 (0,32 – 1,0)	0,85±0,10 (0,8 – 1,0)	-0,75 ± 0,9 (-1,5 to 0,0)
6 years (n=3)	0,5±0,2 (0,4 – 0,8)	0,80±0,09 (0,8 – 1,0)	-0,75 ± 0,9 (-1,5 to 0,0)

Legend:*Table 1:*

(y): years; (m): months; (D): diopters; (mm): millimeters; ACD: anterior chamber depth in mm (Orbscan); W – W: Horizontal white to white distance of the cornea (Orbscan).

Table 3:

The pre- and postoperative corneal endothelial cell count. p-values are given for comparison with preoperative data.

Table 5:

UCVA: Uncorrected visual acuity; BCSVA: Bestcorrected spectacle visual acuity; SE: Spherical equivalent of spectacle refraction in dpt; BCSVA preoperative vs BCSVA 1 month: $p=0.011$; No statistical significant change in terms of BCSVA after 1 month. No statistical significant change in terms of UCVA and SE were seen between the first postoperative month and the 6th postoperative year.

Figure 1: Urrets-Zavalía Syndrome

Iris ischemia can be seen at the pupil margin with dilated non-reactive pupil. IOL is well centered.

Figure 2: Rotation of the phakic IOL

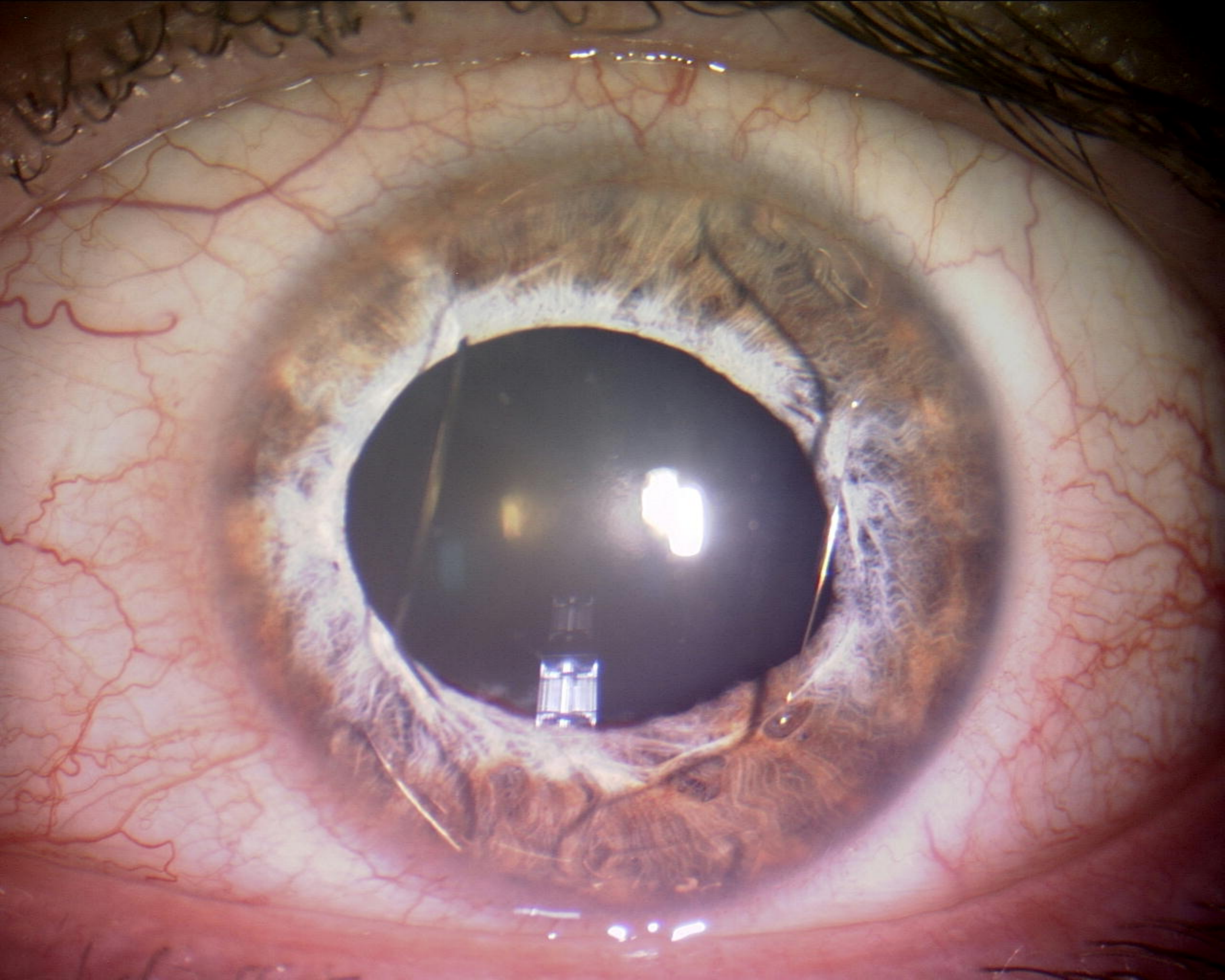
The IOL was implanted at 90° in the 12-6 o'clock position. Twelve months after implantation, the IOL had rotated over 90° and was seen in the 3-9 o'clock position.

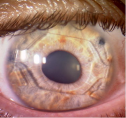Figure 3: Decentration of the phakic IOL

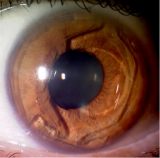
IOL is decentred towards left, probably due to undersizing of the IOL.

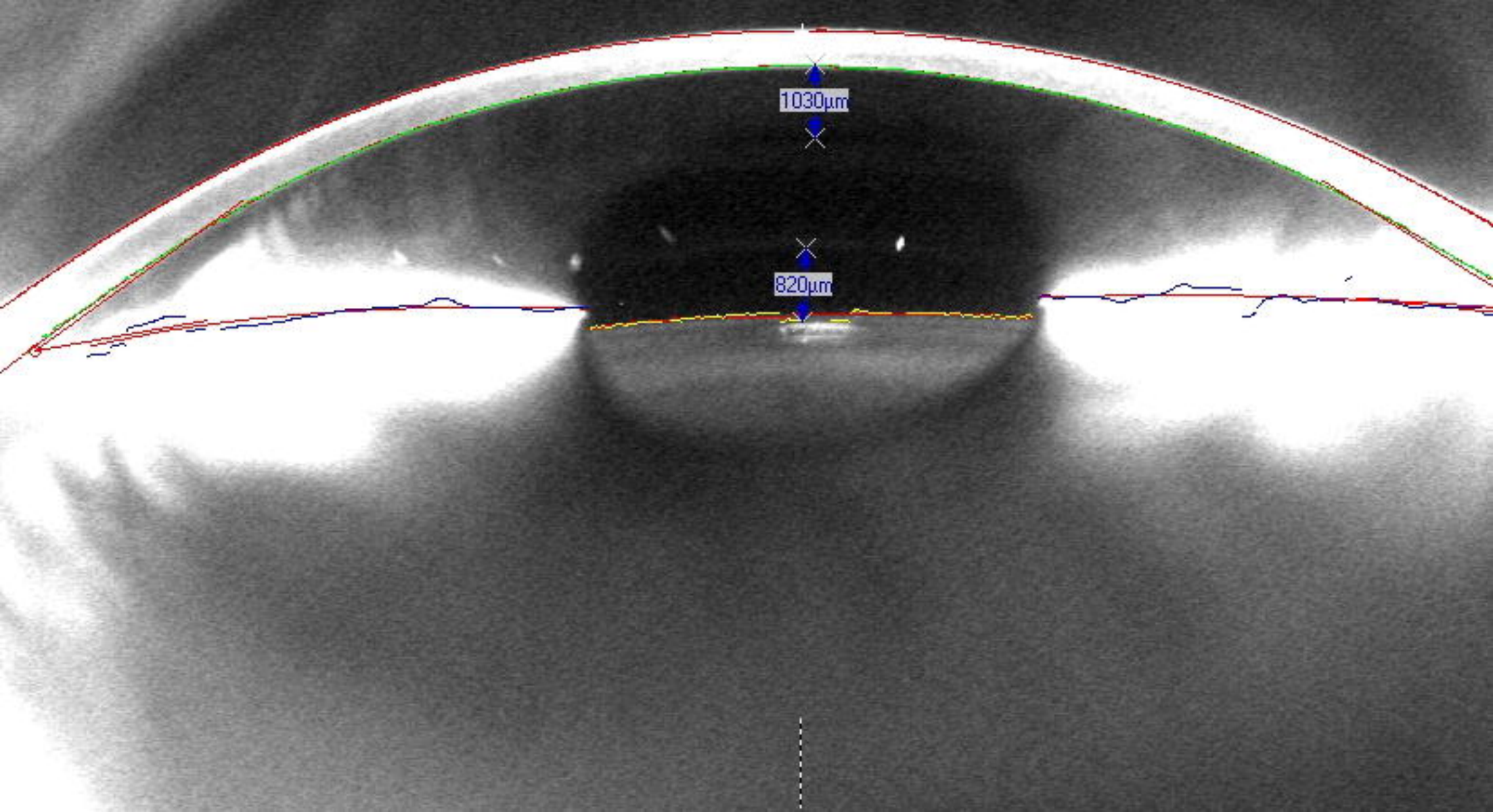
Figure 4: IOL distance to cornea and crystalline lens

Scheimpflug picture of a patient with a low distance of 1030 μm between the IOL and the corneal endothelium.









1030µm

820µm