



HAL
open science

Clinical Relevance of Brain Volume Changes in Patients with Cerebrotendinous Xanthomatosis

Silvia Guerrera, Maria Laura Stromillo, Andrea Mignarri, Marco Battaglini, Silvia Marino, Carol Di Perri, Antonio Federico, Maria Teresa Dotti, Nicola de Stefano

► **To cite this version:**

Silvia Guerrera, Maria Laura Stromillo, Andrea Mignarri, Marco Battaglini, Silvia Marino, et al.. Clinical Relevance of Brain Volume Changes in Patients with Cerebrotendinous Xanthomatosis. Journal of Neurology, Neurosurgery and Psychiatry, 2010, 81 (11), pp.1189. 10.1136/jnnp.2009.203364 . hal-00587981

HAL Id: hal-00587981

<https://hal.science/hal-00587981>

Submitted on 22 Apr 2011

HAL is a multi-disciplinary open access archive for the deposit and dissemination of scientific research documents, whether they are published or not. The documents may come from teaching and research institutions in France or abroad, or from public or private research centers.

L'archive ouverte pluridisciplinaire **HAL**, est destinée au dépôt et à la diffusion de documents scientifiques de niveau recherche, publiés ou non, émanant des établissements d'enseignement et de recherche français ou étrangers, des laboratoires publics ou privés.

Clinical Relevance of Brain Volume Changes in Patients with Cerebrotendinous Xanthomatosis

S. Guerrera*#, MD, M.L. Stromillo*, MD, A. Mignarri*, MD, M. Battaglini*, PhD, S. Marino#, MD, C. Di Perri*, MD, A. Federico*, MD, M.T. Dotti*, MD and N. De Stefano*, MD/

*Dept. of Neurological and Behavioural Sciences, Italy
#IRCCS Centro Neurolesi “Bonino Pulejo”, Messina, Italy

Reprint requests and correspondence to:

Nicola De Stefano, MD
Neurology & Neurometabolic Unit
Dept. Neurological and Behavioural Sciences
University of Siena
Viale Bracci 2
53100 Siena, Italy
Tel: +39-0577-233432
Fax: +39-0577-233411

Running title: Quantitative brain volume changes in CTX

Keywords: cerebrotendinous xanthomatosis, brain, magnetic resonance, therapy, atrophy.

Word Count: Abstract 247; Body: 2531

The Corresponding Author has the right to grant on behalf of all authors and does grant on behalf of all authors, an exclusive licence (or non exclusive for government employees) on a worldwide basis to the BMJ Publishing Group Ltd to permit this article (if accepted) to be published in JNNP and any other BMJPGJL products and sublicences such use and exploit all subsidiary rights, as set out in our licence.

Competing Interest: None.

Abstract

Objective: To quantify total and regional brain damage in subjects with cerebrotendinous xanthomatosis (CTX) by using MR-based quantitative measures. **Background:** CTX is a rare, inherited disorder characterized by progressive neurological impairment. Appropriate therapy can slow disease progression. Measures of brain volume changes have been used in several neurological disorders due to their value in assessing disease outcome and monitoring patients' evolution.

Methods: Twenty-four CTX patients underwent conventional MRI to measure total and regional brain volumes. In five CTX patients who started therapy at baseline, clinical and MRI examinations were repeated after 2 years. Clinical disability, overall cognitive performance and cerebellar function were evaluated using modified Rankin Scale (RS), Mini-Mental-Status Examination (MMSE) and cerebellar functional system score (CB-FSS).

Results: Measures of normalized brain, cortical and cerebellar volumes were lower in CTX patients than in healthy controls ($p < 0.01$). Instead, there were no differences in normalized white matter volumes between the two groups ($p = 0.1$). At regional analysis, significant volume decrease was found in each cortical region ($p < 0.01$ for all regions). Normalized cortical volumes correlated closely with age ($r = -0.9$, $p < 0.0001$), RS ($r = -0.65$, $p < 0.001$) and MMSE ($r = -0.60$, $p < 0.01$). Normalized cerebellar volumes correlated closely with CB-FSS scores ($r = -0.58$, $p < 0.01$). In the five CTX patients followed over time, the annual brain volume decrease was $-1.1 \pm 0.2\%$. **Conclusions:** Cortical volume, rather than white matter volume, is diffusely decreased in CTX patients and correlates closely with the patients' clinical status. These data provide evidence for the presence of clinically relevant neuronal-axonal damage in the brains of CTX patients.

Introduction

Cerebrotendinous xanthomatosis (CTX) is a rare autosomal recessive disease characterised by the abnormal deposition of cholestanol and cholesterol in multiple tissues, including the central nervous system (CNS)^{1;2}. In CTX patients, the systemic defective activity of the mitochondrial enzyme sterol 27-hydroxylase results in a defective bile acid synthesis (with increases in cholic acid and decreases in chenodeoxycholic acid) and abnormally high levels of cholestanol in plasma, urine, feces and other tissues³⁻⁵. This abnormal metabolism is considered responsible for the clinical manifestations, which may involve different organ systems but is usually dominated by the classical triad of the disease: juvenile cataracts, tendon xanthomas and progressive neurological impairment^{6;7}. These clinical manifestations are crucial to address the diagnosis, which needs to be confirmed biochemically (by the increased serum level of cholestanol)⁸ and genetically (by molecular genetic defects in the sterol 27-hydroxylase gene)^{6;7}. An early diagnosis is imperative in these patients, as the pharmacological treatment with chenodeoxycholic acid (or with a combination of chenodeoxycholic acid and HMG-CoA reductase inhibitors) has been shown to slow or even reverse the progression of the disease⁹.

Conventional magnetic resonance imaging (MRI) can be helpful in CTX patients with incomplete or peculiar clinical manifestations as the presence of the bilateral abnormal signal of the dentate nuclei and their surrounding white matter is considered a characteristic feature of the disease^{5;10;11}. Additional MRI findings are white matter abnormalities as well as cerebral and cerebellar atrophy¹². Each of these MR features could be accurately assessed and quantified by using modern neuro-imaging quantitative tools¹³, which allow computed volume estimation of the entire brain as well as specific brain tissues and regions¹⁴. These measures have been used recently to demonstrate that focal and diffuse abnormalities can be found in the brain of patients with several neurological disorders since the very early clinical stages have clinical relevance and can be useful for monitoring patients' clinical evolution¹⁵⁻¹⁹.

All the points mentioned above are potentially important in a chronic and severe, albeit treatable, disease such as CTX. Thus, we performed a volumetric MRI analysis in a relatively large CTX

population with the aim to quantify the extent of brain damage in different brain regions and tissues, to estimate, in a small subgroup of these patients, their longitudinal changes and to assess whether these quantitative MR measures might be related to patients' clinical status.

Methods

Study Population

Twenty-four CTX patients (13 women and 11 men, mean age 39.7 years, range 15-62 years) from eighteen Italian families and 22 demographically matched healthy controls (HC) (13 women and 9 men, mean age 39.2 years, range 22-56 years) were studied. All patients met the clinical criteria for CTX, had a blood level of cholestanol greater than 1 mg/dL and showed DNA point mutations or deletions in the sterol 27-hydroxylase gene. At study entry, 18 CTX patients had been treated with chenodeoxycholic acid (750 mg/day) for several years, while 5 CTX patients were not taking any medication at the time of the MRI examination. These 5 CTX patients started therapy with chenodeoxycholic acid (750 mg/day) at the time of the MRI exam and underwent a second MRI exam after a median follow-up time of 2 years (range 1.9-3.2 years). For each patient, neurological evaluation was performed within 24 hours of the MR examination by an experienced observer (MTD) who was kept blinded to the MRI results. This clinical evaluation included the full neurological examination, the assessment of clinical disability by using the modified Rankin Scale (RS)²⁰, the assessment of the cerebellar function by using the functional system score (CB-FSS)²¹, and the evaluation of the overall cognitive performance by the Mini-Mental-Status Examination (MMSE)²². **The latter could not be assessed in 1 patient.** The study was approved by the Ethics Committee of the Faculty of Medicine of the University of Siena and informed written consent was obtained from all participating subjects.

MRI examination

All subjects were examined using an identical MR protocol. Acquisitions of brain were obtained in a single session using a Philips Gyroscan operating at 1.5 T (Philips Medical Systems, Best, The

Netherlands). A sagittal survey image was used to identify the anterior commissure (AC) and posterior commissure (PC). A dual-echo, turbo spin-echo sequence (TR/TE1/TE2= 2075/30/90 ms, 256x256 matrix, 1 signal average, 250mm field of view, 50 contiguous 3mm slices) yielding proton density (PD) weighted and T₂-weighted (T₂W) images was acquired in the transverse plane parallel to the line connecting the AC and PC. Fluid-attenuated inversion recovery (FLAIR) images (TR= 9000 ms; TE= 150 ms; IT= 2725, 50 contiguous 3mm slices) were acquired in the same direction. Subsequently, T₁-weighted (T₁W) 3D gradient echo images (TR/TE=35 ms/10, 256x256 matrix, 1 signal average, 250mm field of view, 50 contiguous 3mm slices) were acquired. These were oriented to exactly match the PD/T₂ and FLAIR acquisitions. No major hardware upgrades were carried out on the scanner during the time of the study, and monthly quality assurance sessions confirmed the stability of measurements throughout the duration of the study.

MRI data analysis

Global and Regional Brain Volume measurements. Brain parenchyma volumes were measured on T₁-W images of CTX patients and HC by using the cross-sectional version of the SIENA software, SIENAX (part of FSL 4.0 - <http://www.fmrib.ox.ac.uk/fsl/>). SIENAX allows global measures of normalized brain volume (NBV) as well as selective measurement of normalized cortical volumes (NCV)¹⁴. In the five CTX patients who underwent the second MR examination, longitudinal (two time-points) percentage brain volume change (PBVC) was estimated on T₁-weighted images by using SIENA¹³. Changes in PBVC were annualised (PBVC/y) to account for differences in the length of follow-up between the two scans across the 5 patients.

For volume measurement of specific cortical regions, predefined standard space masks can be used to select the cortical gray matter of these regions (see structural atlas in <http://www.fmrib.ox.ac.uk/fsl/>) and estimate volumes normalized for subject's head size. We considered here normalized volumes of frontal (NFV), temporal (NTV), parietal (NPV, which included the insula) and occipital (NOV) lobes of both hemispheres. Furthermore, with an identical

approach, we estimated the normalized volume of the cerebellum (NCbV). In this case, when necessary, the cerebellum mask of the subject was manually edited by an expert user (SG).

Dentate nuclei and surrounding white matter measurement. Volume quantification of the abnormal signal detected in the dentate nuclei and surrounding white matter (DV) was performed in each subject by a single observer (SG) employing a segmentation technique based on user-supervised local thresholding. For the DLV classification, lesion borders were determined primarily on PD images, but information from T1-W, T2-W and FLAIR images was also considered as the software used (Jim 4.0, Xinapse System, Leicester, UK) offered the ability to toggle between the PD, T2-W, FLAIR and T1-W images, providing the operator with convenient access to the information in all data sets while defining lesions. The value of total DV was calculated by multiplying lesion area by slice thickness.

Statistical analysis

The MR measures of the CTX population were compared to those of the HC group by using the non-parametric Mann-Whitney rank sum test. Although there were no differences in age between the groups, age was included as covariate in the measurement of group differences.

Relationships of MR metrics with clinical and demographic indices were assessed using the non-parametric Spearman rank order correlation. Values were considered significant at the 0.05 level. The SYSTAT software version 9 running on Windows (copyright SPSS Inc.1988) was used to performed statistical calculations.

Results

Clinical features

The group of CTX patients had wide ranges of overall disability (RS: median 2, range 0-5), cerebellar functional status (CB-FSS: median 1.0, range 0-3) and overall cognitive performance (MMSE: median 22, range 15-28). As expected in a slowly progressive, chronic disorder such as

CTX, measures of RS and MMSE were closely correlated with age ($r= 0.73$ for RS and -0.68 for MMSE, $p<0.01$ for both).

Global and Regional Brain Volume measurements

As expected, all CTX patients showed bilateral abnormalities in the dentate nuclei and surrounding white matter. The DV values ranged $0.16-9.85 \text{ cm}^3$.

Measurements of NBV were significantly lower in CTX patients than HC ($1510\pm137 \text{ cm}^3$ in CTX, $1626\pm56 \text{ cm}^3$ in HC, $p<0.001$, see Figure 1). Also, NCbV values were significantly lower in CTX patients than in HC ($142\pm25 \text{ cm}^3$ in CTX, $161\pm15 \text{ cm}^3$ in HC, $p <0.005$, see Figure 1).

Brain tissue specific measures showed that NCV were significantly lower in CTX patients than HC ($577\pm101 \text{ cm}^3$ in CTX, $668\pm33 \text{ cm}^3$ in HC, $p<0.0001$, see Figure 2). In contrast, differences in NWMV between the two groups were not significant ($820\pm68 \text{ cm}^3$ in CTX, $850\pm44 \text{ cm}^3$ in HC, $p=0.1$).

Finally, the regional analysis revealed that the decrease in neocortical volume was widespread in CTX patients, being significantly lower in the CTX group than in the HC group in each of the measured cortical regions (NFV: $203\pm38 \text{ cm}^3$ in CTX, $235\pm13 \text{ cm}^3$ in HC; NPV: $155\pm29 \text{ cm}^3$ in CTX, $183\pm12 \text{ cm}^3$ in HC; NTV: $142\pm25 \text{ cm}^3$ in CTX, $159\pm7 \text{ cm}^3$ in HC; NOV: $78\pm13 \text{ cm}^3$ in CTX, $89\pm6 \text{ cm}^3$ in HC; <0.01 for all regions, see Figure 2).

Interestingly, a single-subject analysis of the different brain regions showed that, in CTX patients, values were at least two standard deviations below the mean of the HC in 20/24 of the NPV, 15/24 of the NFV and 14/24 of both NTV and NOV. In contrast, values were at least two standard deviations below the HC mean only in 8/24 of the NCbV.

Correlations between age, clinical scores and MR measures.

In CTX patients, increasing age was closely correlated with decreases in NBV ($r= -0.69$, $p <0.0001$) and even more closely with decrease in NCV ($r= -0.90$, $p <0.0001$ (Figure 3)). A similarly

close correlation with age was found in each cortical region measurement. Age was also correlated, but to a lesser extent, with measures of NCbV ($r = -0.52$, $p < 0.01$, see Figure 3).

A close negative correlation was also found between RS scores and NBV ($r = -0.62$, $p < 0.01$), NCV ($r = -0.65$, $p < 0.001$) and between CB-FSS scores and NCbV values ($r = -0.58$, $p < 0.01$). There was also a close relationship between decreasing values of MMSE and decreases in both NBV ($r = 0.50$, $p < 0.01$), NCV ($r = 0.60$, $p < 0.01$). As expected, there was no correlation between NCbV and MMSE ($r = 0.25$, $p > 0.1$).

Finally, no significant correlations were found between measures of DV and age, clinical scores and MRI measures, with the exception of a moderate negative correlation with NCbV values, ($r = -0.44$, $p < 0.03$).

Longitudinal analysis

As mentioned before, in the 5 CTX patients who began treatment with chenodeoxycholic acid at the time of the first MRI scan, conventional MRI and clinical evaluation were performed after about 2 years. All 5 patients were clinically stable during the follow-up period, maintaining the same baseline RS values. In contrast, there was an overall decrease of brain volume during the follow-up (mean \pm sd PVBC/y = $-1.1 \pm 0.2\%$). This value was almost twice lower in the youngest patient than in the oldest patient (-0.68% versus -1.25%).

Discussion

This is the first study attempting a quantification of global and regional brain tissues in CTX patients by means of a computed quantitative analysis of MR images. In this relatively large patient population, we found a diffuse decrease in total brain volumes and, at a tissue type analysis, this decrease was very pronounced in the cortical grey matter and not significant in the white matter. These results add further evidence to the hypothesis that CTX is a primary neuronal disorder where the enzymatic defect causes an abnormal accumulation of metabolites in the brain leading to a

progressive impairment of the neuron metabolic apparatus and the consequent irreversible neuro-axonopathy.^{23;24}

In most of the CTX patients studied here, the grey matter atrophy could be documented in all neocortical regions, with particular preference for the fronto-parietal cortex. In addition, these cortical volume decreases correlated very closely with both increasing age and measures of overall disability and cognition. This is in line with the nearly constant presence of the slowly progressive sensory-motor impairment and behavioural disturbances in the clinical feature of the CTX patients and provides clear evidence for the clinical relevance of the cortical pathology as detected by quantitative MR metrics. Also, these results add to previous findings similarly reporting close correlations between clinical disability and MR measures of brain tissue damage in smaller populations of CTX patients^{5;25}, stressing the importance of tissue specific quantitative MR metrics as measures of disease outcome.

In the population studied here, the quantitative analysis of cerebellar volumes also did correlate closely with specific measures of cerebellar impairment. However, it is interesting to note that, at a single-subject evaluation, a significant decrease in cerebellar volume was found only in 8/24 CTX patients and correlated only moderately with the patients' clinical status. This is particularly intriguing as common neurological symptoms and signs do include cerebellar dysfunction and cerebellar atrophy are generally considered as one of the most common findings in previous qualitative MR studies of patients with CTX.^{5;11;12;26} It seems, instead, that in CTX patients significant cerebellar pathology occurs at later disease stages than generally thought and, most likely, later than in fronto-parietal cortical regions. Further studies should be carried out to confirm this important result. These might take advantage of high resolution, isotropic MR images, which were not used in the present study.

In a small subgroup of 5 CTX patients who started the classical CTX treatment at baseline, conventional MRI and clinical evaluation were repeated after about 2 years. These patients were all clinically stable during the follow-up period, but showed a sustained decrease in the overall brain volume (PVBC/y of about -1%). When compared to recent literature data using the same method

for the longitudinal assessment of brain volume changes, this value is about 4 times higher than the PBVC/y of normal controls²⁷ and about twice that of patients with CADASIL or multiple sclerosis^{27;28}. The small number of patients studied and the lack of data on an untreated patient group do not allow for general conclusions on this important issue. However, data reported here suggest that despite therapy initiation the complex pathological process leading to atrophy seems to continue. This is in agreement with the notion that the pathological process underlying this rare neurological disease is severe and its reversibility is questionable²⁴. This reinforces the idea that the classical therapy of this disorder is effective only if it is started very early, before the abnormal accumulation of cholesterol and cholestanol leads to irreversible tissue damage. The presence, in our small patient group, of very different PBVC/y values in the youngest (patient 9: -0.68%) and in the oldest (Patient 11: -1.25%) seems to be in line with this.

To conclude, MR-based measurements of brain volume changes provided in vivo estimates of CTX brain damage that closely correlated with the patients' clinical status. It also provided further in vivo evidence that the involvement of the cortical grey matter, rather than that of the white matter, is a clinical relevant aspect of the pathology of this rare metabolic disorder. MR-based, quantitative metrics allow accurate and objective estimation in lesioned and normal appearing brain. They should be used together, in multiparametric, MR-based long-term studies to monitor disease evolution and improve our understanding of the pathophysiology of rare and complex neurological disorders such as CTX.

Figure Legend

Figure 1: Box plots comparing MR measurements of normalized brain volume (NBV), normalized cortical volume (NCV) and normalized cerebellar volume (NCbV) in 22 healthy controls (HC) and 24 patients with cerebrotendinous xanthomatosis (CTX). All measurements of CTX patients are significantly (NBV: $p < 0.001$, NCV: $p < 0.0001$ and NCbV: $p < 0.005$) lower than those of HC.

Figure 2: Box plots comparing MR measurements of normalized volumes of the frontal (NFV) parietal (NPV) temporal (NTV) and occipital (NOV) lobes in 22 healthy controls (HC) and 24 patients with cerebrotendinous xanthomatosis (CTX). All measurements of CTX patients are significantly lower than those of HC ($p < 0.01$ for all regions).

Figure 3. Scatterplots of the correlation of normalized cortical volume (NCV) with age ($r = -0.90$, $p < 0.0001$), Mini-Mental-Status Examination (MMSE: $r = -0.60$, $p < 0.1$) and modified Rankin Scale (RS: $r = -0.65$, $p < 0.001$). Values are relative to the whole group of CTX patients (MMSE value was not available for 1 patient).

References

1. Bjorkhem I, Skrede S (1989) Familial diseases with storage of sterols other than cholesterol: cerebrotendinous xanthomatosis and phytosterolemia. In: Scriver CR, Beaudet AL, Sly WS, Valle D (eds) *The metabolic basis of inherited disease*, 6th edn. Mc Graw Hill, New York, pp 1283-1302.
2. Bjorkhem I, Boberg KM. Inborn errors in bile acid biosynthesis and storage of sterols other than cholesterol. In: Scriver CR, Beaudet AL, Sly WS Valle D, editors. *The metabolic and molecular bases of inherited disease*. 7th ed. New York: Mc Grow Hill; 1995. p. 2073-99
3. Dotti MT, Manneschi L, Federico A. Mitochondrial enzyme deficiency in cerebrotendinous xanthomatosis. *J Neurol Sci* 1995; **129**:106-8.
4. Salen G, Shefer S, Berginer V. Biochemical Abnormalities in Cerebrotendinous Xanthomatosis. *Dev Neurosci* 1991; **13**:363-370.
5. De Stefano N, Dotti M.T, Mortilla M, and Federico A. Magnetic resonance imaging and spectroscopic changes in brains of patients with cerebrotendinous xanthomatosis. *Brain* 2001; **124**,121-131.
6. Federico A, Dotti MT. Cerebrotendinous xanthomatosis. In:Vinken PJ, Bruyn GW, Moser HW, editor. *Handbook of clinical neurology*, Vol 66. Amsterdam: Elsevier Science; 1996. p.599-613.
7. Verrips A, Hoefsloot LH, Steenbergen GC, Theelen JP, Wevers RA, Gabreels FJ, et al. Clinical and molecular genetic characteristics of patients with cerebrotendinous xanthomatosis. *Brain* 2000; **123**:908-19.
8. Wolthers BG, Volmer M, van der Molen J, Koopman BJ, de Jager AEJ, Waterreus RJ. Diagnosis of cerebrotendinous xanthomatosis (CTX) and effect of chenodeoxycholic acid therapy by analysis of urine using capillary gas chromatography. *Clin Chim Acta* 1983; **131**:52-65.
9. Berginer VM, Salen G, Shefer S. Long-term treatment of cerebrotendinous xanthomatosis with chenodeoxycholic acid. *N Engl J Med* 1984; **311**:1649-52.
10. Valk J, van der Knaap MS. Selective vulnerability in toxic encephalopathies and metabolic disorders. *Riv. Neuroradiol* 1996; **9**:749-760.
11. Barkhof F, Verrips MD, et al. Cerebrotendinous Xanthomatosis: The spectrum of Imaging Findings and the Correlation with Neuropathologic Findings. *Radiology* 2000; **217**:869-876.
12. Berginer VM, Berginer J, Korczyn AD Tadmor R. Magnetic resonance imaging in cerebrotendinous xanthomatosis: a prospective clinical and neuroradiological study. *J Neurol Sci* 1994; **122**:102-8.
13. Smith SM, Jenkinson M, Woolrich MW, Beckmann CF, Behrens TE, Johansen-Berg H et al. Advances in functional and structural MR image analysis and implementation as FSL. *Neuroimage* 2004;**23**:208-19
14. Smith SM, Zhang Y, Jenkinson M, et al. Accurate, robust and automated longitudinal and cross-sectional brain change analysis. *NeuroImage* 2002;**17**:479-89

15. Fox NC, Warrington EK, Rossor MN. Serial magnetic resonance imaging of cerebral atrophy in preclinical Alzheimer's disease [letter]. *Lancet* 1999;**353**:2125
16. Giorgio A, Dotti MT, Battaglini M, et al. Cortical damage in brains of patients with adult-form of myotonic dystrophy type1 and no or minimal MRI abnormalities. *J Neurol.* 2006;**253**:1471-1477
17. Stromillo ML, Dotti MT, Battaglini M et al. Structural and metabolic brain abnormalities in preclinical cerebral autosomal dominant arteriopathy with subcortical infarcts and leucoencephalopathy. *JNNP* 2009;**80**:41-47
18. Mitsumoto H, Ulug AM, Pullman SL, et al. Quantitative objective markers for upper and lower motor neuron dysfunction in ALS. *Neurology.* 2007;**68**:1402-1410
19. Filippi M. In vivo tissue characterization of multiple sclerosis and other white matter diseases using magnetic resonance based techniques. *J. Neurol.* 2001;**248**:1019-1029
20. Bonita R, Beaglehole R. Modification of Rankin Scale: Recovery of motor function after stroke. *Stroke* 1988;**19**(12):1497-1500
21. Kurtzke JF. Rating neurologic impairment in multiple sclerosis: an expanded disability status scale (EDSS). *Neurology* 1983;**33**:1444-52
22. Cockrell JR, Folstein MF, Mini-Mental State Examination (MMSE) *Psychopharmacol. Bull.* 1988;**24**:689-692.
23. Soffer D, Benharroch D, Berginer V. The neuropathology of cerebrotendinous xanthomatosis revisited: a case report and review of the literature. *Acta Neuropathol* 1995;**90**: 213-220
24. Pilo de la Fuente B, Ruiz I, Lopez de Munain A, Jimenez-Escrig A. Cerebrotendinous xanthomatosis: neuropathological findings. *J Neurol.* 2008;**255**(6):839-42.
25. Inglese M, De Stefano N et al. Quantification of Brain Damage in Cerebrotendinous Xanthomatosis with Magnetization Transfer MR Imaging. *AJNR Am J Neuroradiology* 2003;**24**:495-500.
26. Dotti MT, Federico A, Signorini E, Caputa N, Venturi C, Filosofi G et al. Cerebrotendinous xanthomatosis (van Bogaert-Scherer-Epstein disease): CT and MR findings. *AJNR Am J Neuroradiol* 1994; **15**:1721-6.
27. Giorgio A, Battaglini M, Smith SM, De Stefano N. Brain atrophy assessment in multiple sclerosis: importance and limitations. *Neuroimaging Clin N Am.* 2008;**18**(4):675-86, xi. Review.
28. Peters N, Holtmannspötter M, Opherck C, Gschwendtner A, Herzog J, Sämann P, Dichgans M. Brain volume changes in CADASIL: a serial MRI study in pure subcortical ischemic vascular disease. *Neurology.* 2006;**66**(10):1517-22.

Figure 1

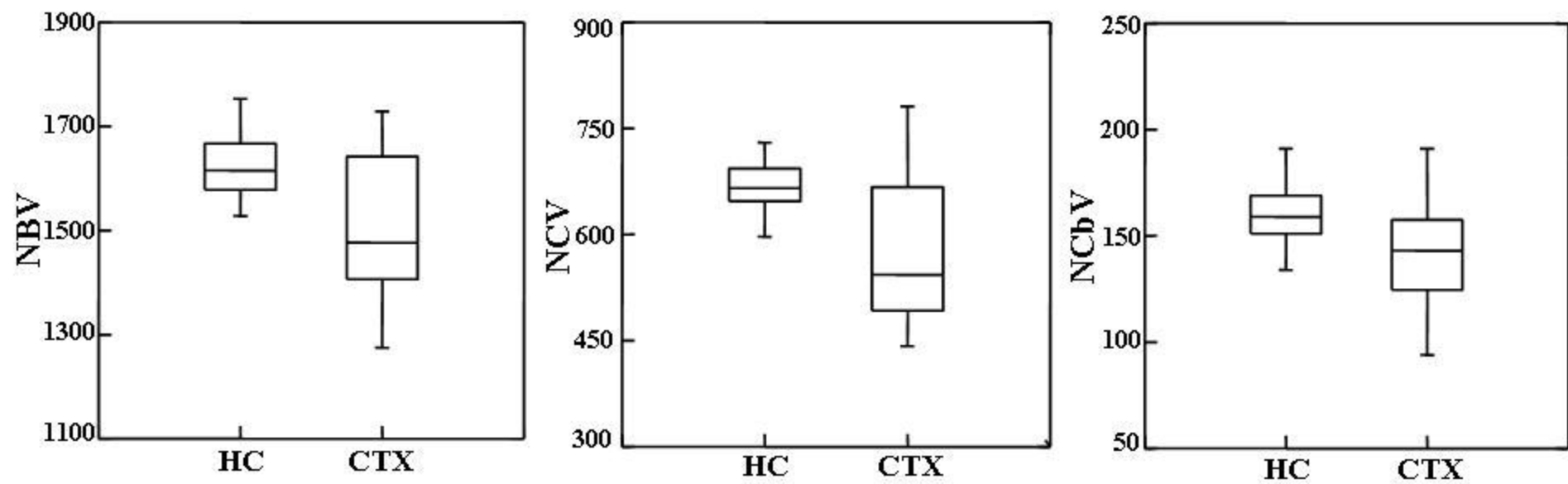


Figure 2

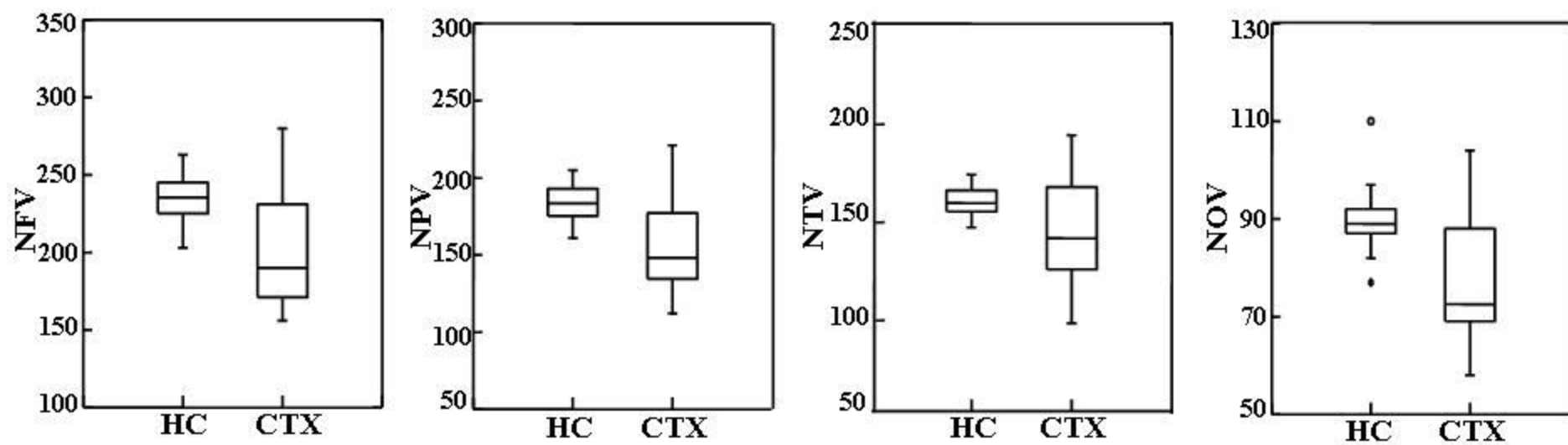


Figure 3

