



**HAL**  
open science

## Comparative evaluation of nm23 and p16 expression as biomarkers of HR-HPV infection and CIN2+ lesions of the uterine cervix

Maria Benevolo, Irene Terrenato, Marcella Mottolese, Ferdinando Marandino, Mariantonia Carosi, Paola Muti, Francesca Rollo, Livia Ronchetti, Luciano Mariani, Giuseppe Vocaturo, et al.

### ► To cite this version:

Maria Benevolo, Irene Terrenato, Marcella Mottolese, Ferdinando Marandino, Mariantonia Carosi, et al.. Comparative evaluation of nm23 and p16 expression as biomarkers of HR-HPV infection and CIN2+ lesions of the uterine cervix. *Histopathology*, 2010, 57 (4), pp.580. 10.1111/j.1365-2559.2010.03674.x. hal-00586994

**HAL Id: hal-00586994**

**<https://hal.science/hal-00586994>**

Submitted on 19 Apr 2011

**HAL** is a multi-disciplinary open access archive for the deposit and dissemination of scientific research documents, whether they are published or not. The documents may come from teaching and research institutions in France or abroad, or from public or private research centers.

L'archive ouverte pluridisciplinaire **HAL**, est destinée au dépôt et à la diffusion de documents scientifiques de niveau recherche, publiés ou non, émanant des établissements d'enseignement et de recherche français ou étrangers, des laboratoires publics ou privés.



## Comparative evaluation of nm23 and p16 expression as biomarkers of HR-HPV infection and CIN2+ lesions of the uterine cervix



Journal:	<i>Histopathology</i>
Manuscript ID:	HISTOP-09-09-0538.R1
Manuscript Type:	Original Article
Date Submitted by the Author:	22-Jan-2010
Complete List of Authors:	BENEVOLO, MARIA; Regina Elena Cancer Institute, Pathology Terrenato, Irene; Regina Elena Cancer Institute, Epidemiology Mottolese, Marcella; Regina Elena Cancer Institute, Pathology Marandino, Ferdinando; Regina Elena Cancer Institute, Pathology Carosi, Mariantonia; Regina Elena Cancer Institute, Pathology Muti, Paola; Regina Elena Cancer Institute, Scientific Direction Rollo, Francesca; Regina Elena Cancer Institute, Pathology Ronchetti, Livia; Regina Elena Cancer Institute, Pathology Mariani, Luciano; Regina Elena Cancer Institute, Oncologic Gynecology Vocaturo, Giuseppe; Regina Elena Cancer Institute, Oncologic Gynecology Vocaturo, Amina; Regina Elena Cancer Institute, Pathology
Keywords:	nm23, p16INK4a, Uterine cervix, Human Papillomavirus, diagnostic biomarkers



## Comparative evaluation of nm23 and p16 expression as biomarkers of HR-HPV infection and CIN2+ lesions of the uterine cervix

Maria Benevolo<sup>1</sup>, Irene Terrenato<sup>2</sup>, Marcella Mottolise<sup>1</sup>, Ferdinando Marandino<sup>1</sup>, Paola Muti<sup>4</sup>, Mariantonia Carosi<sup>1</sup>, Francesca Rollo<sup>1</sup>, Livia Ronchetti<sup>1</sup>, Luciano Mariani<sup>3</sup>, Giuseppe Vocaturo<sup>3</sup>, Amina Vocaturo<sup>1</sup>

<sup>1</sup>Pathology, <sup>2</sup>Epidemiology and <sup>3</sup>Oncologic Gynecology Department, <sup>4</sup>Scientific Direction, Regina Elena Cancer Institute, Rome, Italy

Corresponding author:

Maria Benevolo

Pathology Department - Regina Elena "Cancer Institute"

Via Elio Chianesi 53 - 00144 Rome, Italy

Phone number: +390652666905

Fax number: +390652666102

E-mail: [benevolo@ifp.it](mailto:benevolo@ifp.it)

**Keywords:** nm23, p16<sup>INK4a</sup>, Uterine cervix, Human Papillomavirus, Cervical Intraepithelial Neoplasia, HPV testing, diagnostic biomarkers

**Running title:** nm23 and p16 in cervical lesions

## Summary

**Aims:** to investigate the clinical role of nm23 expression in identifying both HR-HPV and high-grade cervical lesions or carcinomas (CIN2+), and compare it with p16 overexpression, as this latter biomarker has already been widely reported in HR-HPV infected cervical lesions.

**Methods:** Immunohistochemical evaluation of nm23 and p16 in 143 cervical biopsies including negative, low- and high-grade lesions and squamous carcinomas (SC). HR-HPV testing by Digene HC2 and PCR, on the cervico-vaginal samples of the same patients.

**Results:** In detecting CIN2+, p16 was significantly more sensitive and specific than nm23 (96.3% vs 81.8% and 66% vs 36.4% respectively, both  $p < 0.0001$ ). Concerning HR-HPV detection by HC2, p16 showed a significantly higher specificity than nm23 (82% vs 47%,  $p < 0.0001$ ), although the sensitivities were comparable (71% vs 76%). We found a significantly direct correlation between nm23 and HC2 findings. However, nm23 expression did not correlate with HPV16/18 infection. On the contrary, we observed a significant association between p16 overexpression and HPV 16/18 genotypes.

**Conclusions:** We confirm the promising clinical role of p16 overexpression. Moreover, despite *in vitro* data regarding the interaction with the HPV-E7 protein, nm23 does not appear to be a more useful biomarker than p16 in identifying CIN2+ or HR-HPV infection.

## Introduction

Persistent infection with human papillomavirus (HPV) is generally accepted as a primary cause of cervical cancer. However, neoplastic transformation is a rare complication of a HPV infection which, in the majority of cases, is a transient event (1). In recent years, considerable time and effort has been spent in order to identify biomarkers which could increase the specificity of DNA-based HPV assays, and which are able to detect those HPV infections significantly involved in cervical tumor progression. Among the emerging risk-progression biomarkers, the p16 protein, a cyclin-dependent kinase inhibitor involved in cell cycle control, is one of the most promising. As widely reported, p16 expression is affected by the HR-HPV E7 protein and its up-regulation in the uterine cervix significantly correlates with the increasing severity of the lesions (2-4). Nevertheless, the immunohistochemical (IHC) evaluation of p16 on histological specimens usually presents a limited reproducibility due to the lack of standardized criteria for the interpretation of immunostaining (5). This limitation may be overcome by the use of a panel of well-validated biomarkers, which can both increase clinical sensitivity and specificity and provide an internal validation control for each single marker. In the continuing search for more robust biomarkers of risk progression in human cervical lesions, the nm23 protein could represent an emerging and interesting candidate. This protein, which works as a nucleoside diphosphate kinase, displaying antimetastatic potential in human malignancies, is also involved in the control of normal development and differentiation (6-8). Preliminary *in vitro* studies suggest that the physical interaction between the E7 protein from HR-HPV types and the nm23 affected protein stability and function thus favouring the HPV tumorigenic potential (9). Nevertheless, a limited and conflicting number of clinical studies have been performed to investigate and validate the role of nm23 as a marker of cervical

HPV infection, disease onset and progression (10-14). In particular, only one study has analysed nm23 expression together with HPV testing (15).

By means of IHC, the aims of the present study were: 1) to confirm the *in vitro* data evaluating whether nm23 may be a useful biomarker in the identification of high grade lesions in a series of human preneoplastic and neoplastic cervical lesions; 2) to verify the potential association between nm23 expression and HR-HPV infection, focusing on HPV 16 and 18; 3) to investigate the relationships between p16 and nm23 proteins evaluating their relative impact in clinical practice.

## Materials and Methods

### Patients

We analysed 143 formalin fixed cervical specimens from the Regina Elena Cancer Institute archives, collected between July 2004 and October 2007. All cases had a cervico-vaginal sample for HPV testing **taken at the same time of** colposcopic examination and biopsy. Patient median age was 34 years (range 18 to 78 years).

The study was reviewed by the Ethics Committee of the Regina Elena Cancer Institute.

### Histological diagnoses

Cervical tissue samples were fixed in 10% buffered formalin, paraffin embedded, and haematoxylin-eosin stained according to routine histological practice. All slides were examined independently by two investigators (FM, MC) without any pathological or clinical information concerning the cases under study. Histological diagnosis revealed 32 tissues without any relevant morphologic lesions (hereinafter referred as negative), 56 CIN (Cervical Intraepithelial Neoplasia) 1, 19 CIN2, 20 CIN3 and 16 invasive squamous carcinomas (SC).

### nm23 and p16 immunostaining

The nm23 and p16 immunostaining was carried out on 5 µm thick sections from formalin fixed paraffin embedded blocks. nm23 IHC was performed using the monoclonal antibody 37.6 directed against the nucleoside diphosphate kinase A, codified by the nm23-H1 gene. Immunoreactivity was revealed by means of a super sensitive streptavidin-biotin immunoperoxidase system (Biogenex, Menarini, Florence, Italy), using 3-amino-9-ethyl-carbazole as a chromogenic substrate. All cytoplasmic stainings, independent of occasional nuclear staining, were considered positive. On the basis of staining intensity and localization throughout the epithelium, we distinguished 3 categories of reactivity: negative when any form of staining was observed; positive heterogeneous when only the basal and parabasal epithelial layers presented a weak to moderate immunostaining;

positive homogeneous when a strong immunoreactivity was evidenced throughout all the squamous epithelium. Nevertheless, because the heterogeneous and homogeneous positive samples were randomly distributed in the different histological categories and were not related to HPV infection, the staining findings were treated in results and data analysis as dichotomous categorical variables, so that all the positive cases were grouped together and compared with the negatives.

p16 expression was revealed by means of a commercially available kit (CINTec Histology Kit, Mtm, Italy), which includes the monoclonal antibody E6H4 (16), following the manufacturer's instructions. Nuclear, with or without cytoplasmic reactivity, was considered positive and, according to the interpretation score proposed by Klaes (2), we considered the diffuse staining of the basal and parabasal cell layers as a positive cut-off. Staining intensity was not graded to avoid subjective interpretation.

#### HPV testing

The HC2 test was performed on cervicovaginal specimens taken at the same time of colposcopic examination and collected in 20 mL of PreservCyt solution (Cytoc, Italy). For each specimen, a Papanicolaou stained slide was prepared by means of ThinPrep 2000 System (Cytic), to ensure the quality and cellularity of the sample. The HR-HPV DNA detection was performed by means of the Digene HC2 system (Qiagen, Italy), following the manufacturer's recommendations, using 4 mL of each cervico-vaginal samples. The HR-HPV HC2 assay recognizes the 13 most common HR-HPV types: 16, 18, 31, 33, 35, 39, 45, 51, 52, 56, 58, 59 and 68. Before the HC2 testing, the samples were processed using the Digene HC2 Sample Conversion Kit (Qiagen).

The HPV genotyping test was performed by means of the Linear Array kit (Roche, Italy), utilizing 250 µL of the residual liquid sample. This PCR assay is able to recognize 37 high, intermediate and low risk HPV types (6, 11, 16, 18, 26, 31, 33, 35, 39, 40, 42, 45, 51, 52,



53, 54, 55, 56, 58, 59, 61, 62, 64, 66, 67, 68, 69, 70, 71, 72, 73, 81, 82, 83, 84, IS39 and CP6180). Because of the higher oncogenic potential displayed by HPV 16 and 18 types, in the PCR interpretation we divided the positive results into two categories: 1) presence of HPV 16 and/or 18 sequences with or without other genotypes (16/18+), 2) revelation of HR-HPV genotypes other than 16 and 18, as single or multiple infections, comprising at least one of the genotypes recognized by the HC2 system (HR-HPV+).

### Statistical analyses

The Pearson's Chi-Square test was applied for all comparisons between variables of interest and when the p-value was  $< 0.05$  it was considered to be statistically significant.

The nm23 and p16 immunoreactivities were evaluated in terms of sensitivity, specificity and predictive values of the test, considering both histological CIN2 or worse diagnosis (CIN2+), and HR-HPV infection by HC2 test, as the endpoint.

## Results

### nm23 and p16 distribution according to histological diagnoses

We evaluated IHC nm23 expression, in parallel with p16, in our series of 143 cervical biopsies. Figure 1A shows nm23 distribution according to histological diagnoses. Among the 32 negative cervical tissues, 17 cases demonstrated nm23 immunoreactivity (53%). The CIN1, as well as the CIN2 and the CIN3 lesions, demonstrated nm23 positivity in 39 out of 56 (70%), 13 out of 19 (68.5%), and 15 out of 20 (75%) samples respectively, while all the analysed squamous carcinomas displayed a homogeneous cytoplasmic staining (Figure 2). Starting from the negative tissues through to carcinomas, a trend of constant and significant increase of protein overexpression was observed ( $p\chi^2_{\text{trend}}=0.002$ ).

As shown in figure 1B, p16 immunoreactivity was detected in 19% of the normal tissues, in 43% of the CIN1, in 100% of the CIN2, in 95% of the CIN3 and in 94% of the SC cases. Also in the case of p16 immunoreactivity, we observed a significant increase of p16 overexpression starting from the negative specimens through to the carcinomas ( $p\chi^2_{\text{trend}} < 0.0001$ ), confirming data which was previously obtained by our group (4).

### Analysis of HR- HPV distribution

The cervico-vaginal samples from all the 143 patients included in our study were analysed for HR-HPV infection by the HC2 system. HR-HPV infection was found in 109 samples (76%). In particular, as shown in Table 1, HR-HPV infection was found in 14 out of the 32 histologically negative tissues (44%), in 41 out of the 56 CIN1 cases (73%), in 18 out of the 19 CIN2 (95%), and in all the CIN3 lesions as well as in the squamous carcinomas. The proportion of HR-HPV infected samples significantly increased during progression from negative, CIN1, CIN2 and CIN3 to invasive cancer, with statistical significance ( $p\chi^2_{\text{trend}} < 0.0001$ ).

### Relationship between nm23 and p16 immunostaining and HR-HPV testing

In order to verify whether a relationship between nm23 and p16 immunostaining and HR-HPV infection occurred in our series of samples, we compared the IHC findings with HC2 results (Table 2). Concerning HC2 negative patients, 47% were also nm23 negative (16 out of 34), against the 82% (28 out of 34) evidenced in the p16 negative group. Of the 109 HR-HPV positive patients, 83 were nm23 (76%) and 77 p16 positive (71%). We observed a statistically significant correlation between nm23 expression and HR-HPV infection ( $p(\chi^2)=0.009$ ), as well as between p16 upregulation and HR-HPV infection ( $p(\chi^2)<0.0001$ ). This latter finding further confirmed the usefulness of p16 overexpression in HR-HPV detection, as we have already demonstrated in a different series (4).

### Relationship between nm23 and p16 immunostaining and HPV genotyping by PCR

A genotyping test was performed in 84 out of the 109 HC2 positive cases. Overall, 45 cases presented the 16 and/or 18 genotypes (HPV 16/18+, 54%) whereas 39 displayed other high risk genotypes (46%), as described in the Materials and Methods Section. Analysing the distribution of nm23 and p16 immunostaining compared to PCR genotyping (Table 3), we evidenced that nm23 immunoreactivity did not correlate with HPV16/18+ infection ( $p=0.251$ ), whereas p16 overexpression showed a significant association with the presence of HPV16/18 types ( $p=0.008$ ). In fact, even if 38 out of the 45 16/18+ cases showed nm23 immunostaining (84%), 29 out of the 39 HR-HPV+ infected samples were also nm23 immunoreactive (74%). In contrast, among the 45 16/18+ cases, 39 displayed p16 overexpression (87%), while among the 39 HR-HPV+ specimens, only 24 were p16 positive (62%).

### Sensitivity, Specificity, PPV and NPV of nm23 and p16 expression in detecting CIN2+ and HR-HPV infection

To better understand the diagnostic value of the two biomarkers being studied, i.e. nm23 and p16 expression, we evaluated their performance in terms of sensitivity, specificity and predictive values for detection of CIN2+ and/or identification of HR-HPV infection.

In detecting CIN2+ (Figure 3), we found that p16 was significantly more sensitive and specific than nm23 (sensitivity: 96.3% vs 81.8%; specificity: 66% vs 36.4%, both  $p < 0.0001$ ). Positive predictive value (PPV) of p16 was higher than that found for nm23, the difference being statistically significant (63.8% vs 44.5%,  $p = 0.0013$ ). Regarding negative predictive value (NPV), both the markers showed a high value, p16 displaying the highest (96.6% vs 76.2%,  $p < 0.0001$ ).

Concerning HR-HPV infection (Figure 4), we found that the two biomarkers had comparable sensitivity and NPV (sensitivity: 71% vs 76%,  $p = 0.41$ ; NPV: 47% vs 38%,  $p = 0.156$ ). However, p16 showed a significantly higher specificity compared to nm23 (82% vs 47%,  $p < 0.0001$ ) and PPV (93% vs 82%,  $p = 0.008$ ).

## Discussion

Once a HPV infection is established in the cervical epithelium, altered transcriptional regulation of the viral E6/E7 oncogenes, which affects almost all the cellular pathways (17-18), probably provides the subsequent important step towards malignancy. In this context, it appears of paramount clinical importance to search for novel additional assays capable of identifying molecular alterations strictly associated with cervical malignant transformation rather than simply detecting HR-HPV infections (19). Starting from the knowledge that p16 overexpression is indirectly caused by the E7 viral protein (3), a number of studies recently supported the possible clinical role of this cyclin-dependent kinase inhibitor. It has been widely reported, in fact, that p16 is a specific biomarker able to identify HR-HPV associated high-grade precancerous lesions and cervical carcinomas (2-4). Nevertheless, p16 immunostaining lacks standardized interpretation criteria and internal validation controls (5). Recently, experimental data have indicated that nm23-H1 could represent a novel, intriguing biomarker of cervical carcinogenesis. In fact, it has been shown that nm23 stability and function is affected by the HR-HPV E7 protein (9). Nevertheless, the possible molecular links of nm23 to oncogenic HPV have yet to be fully elucidated.

In this context, the aim of our study was to verify whether IHC detection of nm23 could be a useful tool in the identification of CIN2+ lesions and/or HR-HPV infection either as a single marker or used in combination with p16. Concerning p16, we confirmed our previous findings (4) further demonstrating the elevated specificity and sensitivity of this marker in identifying CIN2+ or HR-HPV infected samples, particularly HPV 16/18 infections. In contrast, nm23 did not appear to be a more useful biomarker than p16, showing a lower sensitivity and specificity in CIN2+ detection. Moreover, in identifying HR-HPV infection, p16 specificity was significantly higher than nm23, although the two markers displayed comparable sensitivities. Nevertheless, in our series, we observed a

direct relationship between increasing IHC expression of nm23, high grade cervical lesions and HR-HPV presence. This is a particularly important point. In fact, experimental data showed that *in vitro* physical interaction between HPV-16 E7 and nm23-H1 and -H2 proteins promotes transcriptional down-regulation and degradation of intracellular content of nm23, favouring the acquisition of invasiveness and resistance to apoptosis (9). Consistent with this data, loss of Nm23-H1 might allow HPV-16 E7 to promote cell transformation and tumor progression. In contrast, to the best of our knowledge, studies on the expression of nm23 in normal and pathologic human cervical tissues, are limited and conflicting (10-15). Only two *in vivo* studies have observed a statistically significant decrease of nm23 expression starting from CIN1 to cancer (12, 15). The majority of the *in vivo* studies, including the present research, have reported an increase in nm23 expression with increased CIN grade (10-11, 13-14). We could hypothesize that *in vivo* nm23 expression could also be affected by different control mechanisms which are HPV-independent, or that the amount of the E7 protein present in the HR-HPV infected cells might not be sufficient to inactivate the nm23 protein.

Concerning the relationship between HR-HPV and nm23, only one published study has compared nm23 expression with HPV DNA testing in a series of CIN and cervical cancers (15). The Branca study showed no relationship between nm23 and HR-HPV distinguishing HR-HPV positive cases from negatives, without typing. To our knowledge, our study represents the first in which nm23 IHC findings are also compared with HPV genotyping. In our series of patients, we found a significant direct correlation between nm23 immunoreactivity and HC2 findings. However, when we compared nm23 IHC findings with HPV genotyping, we observed no association between protein expression and HPV16 and 18 genotypes, which are known to have the highest oncogenic potential. This is an important point to be considered. In fact, nm23 expression may also depend on the HR-

HPV genotype present and it has been shown that the E6 and E7 oncoproteins from different HPV types have a different efficiency in their binding with the host proteins.

On the contrary, we found a significant association between p16 overexpression and HPV 16/18 infection. These data, further confirm the promising clinical role of p16 as a marker of progression risk, particularly evidencing the correlation between p16 overexpression and presence of HPV 16/18 genotypes.

In conclusion, in our series of patients, the comparative evaluation of the clinical impact of nm23 and p16 proteins, as biomarkers of high grade lesions and HR-HPV detection, showed that nm23 IHC does not display a better performance compared to p16. Therefore, the introduction of nm23 in clinical practice does not seem recommendable at present, as it provides no further useful information. Probably additional research must be carried out to study the relationship between this protein and oncogenic HPV proteins before it can be taken into consideration.

## Acknowledgements

This study was supported by the Italian Ministry of Health, Italian Cancer Research Association (AIRC), Lega Italiana per la Lotta contro I Tumori (LILT). We also would like to thank Michael Kenyon for his formal revision of the manuscript and Maria Assunta Fonsi for her secretarial assistance.

For Peer Review



## REFERENCES

1. Dalstein V, Riethmuller D, Pretet JL, et al. Persistence and viral load of high-risk HPV are predictors for development of incident disease. *Int J Cancer*, 2003; 106: 396-403.
2. Klaes R, Friedrich T, Spitkovsky D, et al. Overexpression of p16<sup>INK4a</sup> as a specific marker for dysplastic and neoplastic epithelial cells of the cervix uteri. *Int J Cancer*, 2001; 92: 276-284.
3. von Knebel Doeberitz M. New markers for cervical dysplasia to visualise the genomic chaos created by aberrant oncogenic papillomavirus infections. *Eur J Cancer*, 2002; 38: 2229-2242.
4. Benevolo M, Mottolese M, Marandino F, et al. Immunohistochemical expression of p16<sup>INK4a</sup> is predictive of HR-HPV infection in cervical low-grade lesions. *Mod Pathol*, 2006; 19: 384-391.
5. Tsoumpou I, Arbyn M, Kyrgiou M, et al. p16<sup>INK4a</sup> immunostaining in cytological and histological specimens from the uterine cervix: a systematic review and meta-analysis. *Cancer Treat Rev*, 2009; 35: 210-220.
6. Lombardi D, Lacombe M-L, Paggi MG. m23: Unraveling its biological function in cell differentiation. *J Cell Physiol*, 2000; 182: 144-149.
7. Steeg PS. Metastasis Suppressor genes. *JNCJ*, 2004; 96 (6): E4.

8. Hsu C-G, Lin L-Y, Ko J-L, et al. High expression of human nonmetastatic clone 23 type 1 in cancer of uterine cervix and its association with poor cell differentiation and worse overall survival. *J Surg Oncol*, 2008; 98(6): 448-456.
9. Mileo AM, Piombino E, Severino A, Tritarelli A, Paggi MG, Lombardi D. Multiple interference of the human papillomavirus-16 E7 oncoprotein with the functional role of the metastasis suppressor Nm23-H1 protein. *J Bioenerg Biomembr*, 2006; 38: 215-225.
10. Wang P-H, Chang H, Ko J-L, Lin L-Y. Nm23-H1 immunohistochemical expression in multisteps of cervical carcinogenesis. *Int J Gynecol Cancer*, 2003;13: 325-330.
11. Wang P-H, , Ko J-L, Chang H, Lin L-Y. Clinical significance of high nm23-H1 expression in intraepithelial neoplasia and early-stage squamous cell carcinoma of the uterine cervix. *Gynecol Obstet Invest*, 2003; 55: 14-19.
12. Lee CS, Gad, J. Nm23-H1 protein immunoreactivity in intraepithelial neoplasia and invasive squamous cell carcinoma of the uterine cervix. *Pathology International*, 1998; 48: 806-811.
13. Ravazoula P, Aletra Ch, Kourounis G, Ladopoulos I, Tzigounis V. Immunohistochemical analysis of nm23-H1 expression in human cervical lesions. *Eur J Gynecol*, 2000; 21: 510-512.
14. Hsu C-G, Wang P-H, Kos J-L, et al. Concurrent high expression of human telomerase reverse transcriptase and human nonmetastatic clone 23 in high grade

squamous intraepithelial neoplasia and squamous cell carcinoma of uterine cervix. *Int J Gynecol Cancer*, 2007; 17: 851-857.

15. Branca M, Giorgi C, Ciotti M. et al. Down-regulated nucleoside diphosphate kinase nm23-H1 expression is unrelated to high-risk human papillomavirus but associated with progression of cervical intraepithelial neoplasia and unfavourable prognosis in cervical cancer. *J Clin Pathol*, 2006; 59: 40-47.
16. Agoff N, Lin P, Morihara J, Mao C, Kiviat NB, Koutsky LA. p16<sup>INK4a</sup> expression correlates with degree of cervical neoplasia: a comparison with Ki-67 expression and detection of high risk HPV types. *Mod Pathol*, 2003; 16: 665-673.
17. zur Hausen H. Immortalization of human cells and their malignant conversion by high risk human papillomavirus genotypes. *Semin Cancer Biol*, 1999; 9: 405-411.
18. Fehrmann F, Laimins LA. Human Papillomavirus: targeting differentiating epithelial cells for malignant transformation. *Oncogene*, 2003; 22: 5201-5207.
19. Mosciki B, Schiffman M, Kjaer S, Villa LL. Updating the natural history of HPV and anogenital cancer. *Vaccine*, 2006; 24S3: S3/42-S3/51.

## Legends to figures

**Figure 1:** distribution of **A:** nm23 and **B:** p16 immunostaining, according to histological diagnosis in 143 cervical biopsies

**Figure 2:** nm23 immunohistochemical staining of squamous cell carcinoma of the uterine cervix. Counterstaining with haematoxylin. Magnification 20X

**Figure 3:** Representative images of the relationship between sensitivity, specificity, positive predictive value and negative predictive value of nm23 and p16 immunostaining, considering the detection of histological CIN2 or worse diagnosis (CIN2+) as the endpoint.

**Figure 4:** Representative images of the relationship between sensitivity, specificity, positive predictive value and negative predictive value of nm23 and p16 immunostaining, considering the detection of HR-HPV infection by HC2 test (HC2+) as the endpoint.

**Table 1.** HR-HPV distribution according to histological diagnoses in 143 cervical biopsies

HR-HPV	NEG	CIN1	CIN2	CIN3	SC	Total
Positive	14 (44%)	41 (73%)	18 (95%)	20 (100%)	16 (100%)	109 (76%)
Negative	18 (56%)	15 (27%)	1 (5%)	0	0	34 (24%)
Total	32 (100%)	56 (100%)	19 (100%)	20 (100%)	16 (100%)	143 (100%)

$p(X^2_{\text{TREND}}) < 0.0001$

**Table 2.** nm23 and p16 distribution according to the presence of HR-HPV in 143 cervical biopsies

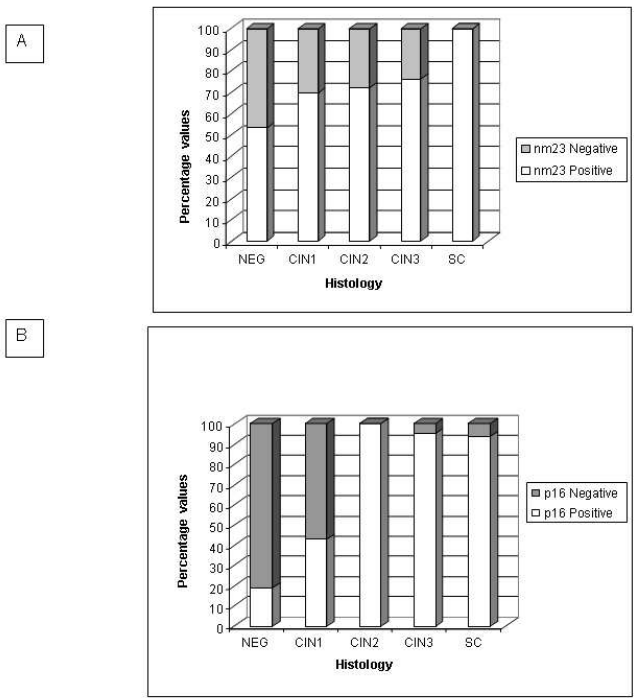
		HC2		
		Negative	Positive	Total
nm23*	Negative	16 (47%)	26 (24%)	42
	Positive	18 (53%)	83 (76%)	101
	Total	34 (100%)	109 (100%)	143
p16°	Negative	28 (82%)	32 (29%)	60
	Positive	6 (18%)	77 (71%)	83
	Total	34 (100%)	109 (100%)	143

\* $p(X^2) = 0.009$ ° $p(X^2) < 0.0001$

**Table 3.** nm23 and p16 distribution according to HPV genotyping in 84 HC2 positive samples

		PCR		
		HPV 16/18 +	HR-HPV +	Total
nm23*	Positive	38 (84%)	29 (74%)	67
	Negative	7 (16%)	10 (26%)	17
	Total	45 (100%)	39 (100%)	84
p16°	Positive	39 (87%)	24 (62%)	63
	Negative	6 (13%)	15 (38%)	21
	Total	45 (100%)	39 (100%)	84

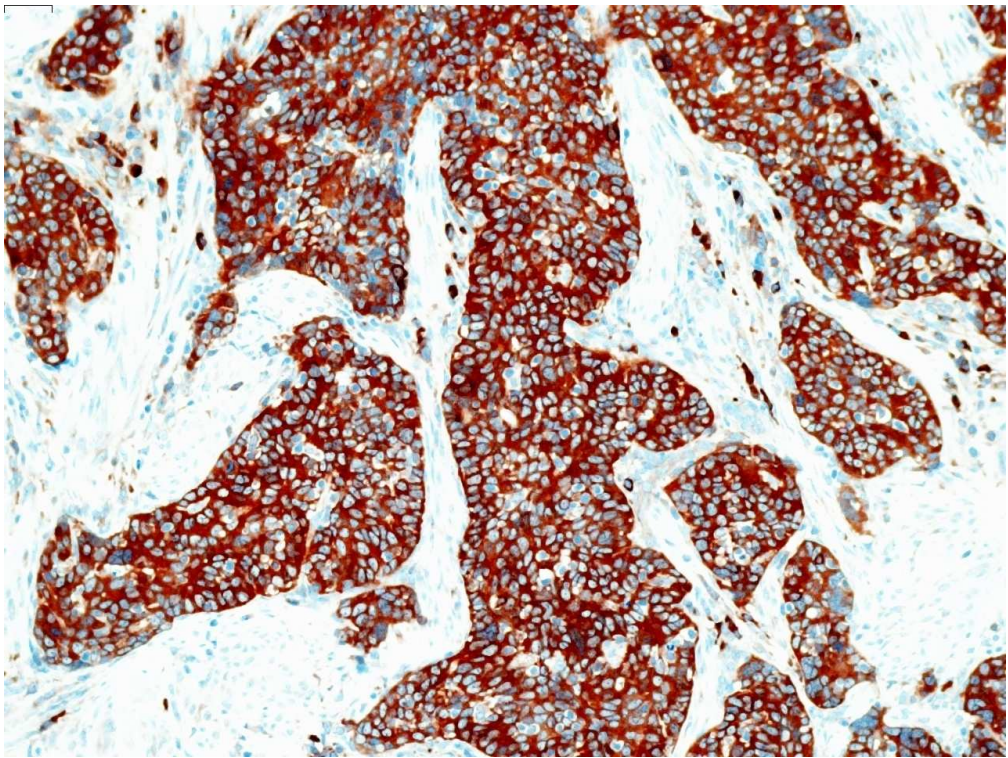
\*  $p(X^2) = 0.251$ °  $p(X^2) = 0.008$



254x190mm (96 x 96 DPI)

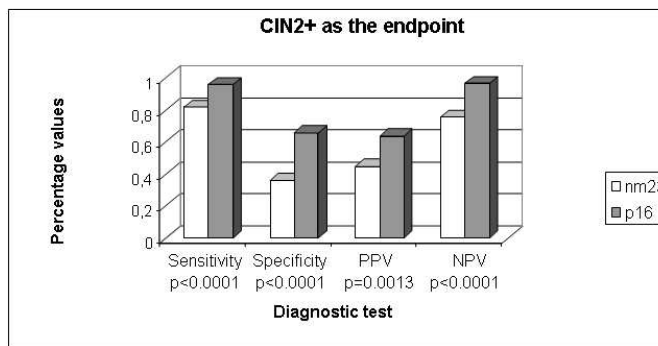
Review





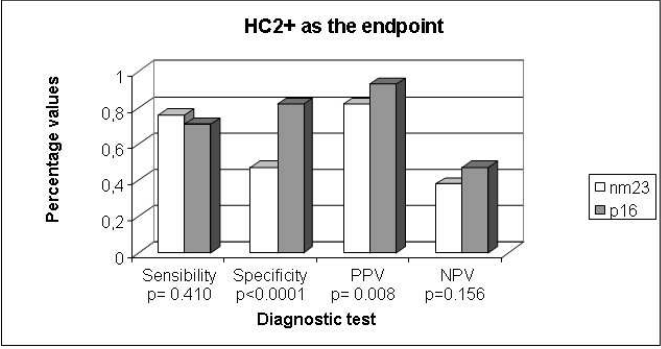
338x254mm (96 x 96 DPI)

Review



254x190mm (96 x 96 DPI)

Review



254x190mm (96 x 96 DPI)

Review