



HAL
open science

Subthreshold Laser Treatment for Retinal Arterial Macroaneurysm

Maurizio Battaglia Parodi, Pierluigi Iacono, Giuseppe Ravalico, Francesco
Bandello

► **To cite this version:**

Maurizio Battaglia Parodi, Pierluigi Iacono, Giuseppe Ravalico, Francesco Bandello. Subthreshold Laser Treatment for Retinal Arterial Macroaneurysm. *British Journal of Ophthalmology*, 2010, 95 (4), pp.534. 10.1136/bjo.2009.175547 . hal-00586525

HAL Id: hal-00586525

<https://hal.science/hal-00586525>

Submitted on 17 Apr 2011

HAL is a multi-disciplinary open access archive for the deposit and dissemination of scientific research documents, whether they are published or not. The documents may come from teaching and research institutions in France or abroad, or from public or private research centers.

L'archive ouverte pluridisciplinaire **HAL**, est destinée au dépôt et à la diffusion de documents scientifiques de niveau recherche, publiés ou non, émanant des établissements d'enseignement et de recherche français ou étrangers, des laboratoires publics ou privés.

Subthreshold Laser Treatment for Retinal Arterial Macroaneurysm

M. Battaglia Parodi¹, P. Iacono², G. Ravalico³, F. Bandello¹

¹ Department of Ophthalmology, University Vita-Salute, Scientific Institute San Raffaele, Milano, Italy

² Fondazione G. B. Bietti per l'Oftalmologia, IRCCS (Istituto di Ricovero e Cura a Carattere Scientifico), Roma, Italy

³ Clinica Oculistica, University of Trieste, Trieste, Italy

Corresponding author:

Francesco Bandello MD, FEBO

Department of Ophthalmology,

University Vita-Salute

Scientific Institute San Raffaele

Via Olgettina 60, 20132, Milano, Italy

Phone: +39 02 26432648

Fax : +39 02 26483643

E-mail: francesco.bandello@hsr.it

"The Corresponding Author has the right to grant on behalf of all authors and does grant on behalf of all authors, an exclusive licence (or non exclusive for government employees) on a worldwide basis to the BMJ Publishing Group Ltd and its Licensees to permit this article (if accepted) to be published in BJO editions and any other BMJPGl products to exploit all subsidiary rights, as set out in our licence (<http://group.bmj.com/products/journals/instructions-for-authors/licence-forms/>)."

Competing Interest: None to declare

Abstract

Purpose: To assess the effects of subthreshold laser treatment (STLT) for retinal arterial macroaneurysms (RAM) associated with foveal exudative manifestations and visual acuity deterioration.

Methods: Patients with RAM associated with foveal exudative manifestations and best corrected visual acuity (BCVA) worse than 20/80 Snellen equivalent underwent a ophthalmologic examination, including ETDRS visual acuity, optical coherence tomography (OCT), and fluorescein angiography. The patients were prospectively observed for 4 months period, and in absence of spontaneous improvement, they underwent STLT using an infrared diode laser.

Primary outcome measures were reduction of mean central point thickness (CPT) and BCVA changes at the 12-month examination. Secondary outcomes included changes in mean total macular volume (TMV) and central subfield thickness (CST).

Results: Nine patients were enrolled and prospectively followed up. Mean baseline values of BCVA, CPT, TMV, and CST were 0.8 ± 0.1 (logMAR \pm SD), $340 \pm 49 \mu\text{m}$, $7.14 \pm 0.05 \text{mm}^3$, and $366 \pm 37 \mu\text{m}$, respectively. At the 4-month examination following STLT, mean BCVA improved to 0.6 ± 0.2 , whereas mean CPT, TMV, and CST decreased to $274 \pm 29 \mu\text{m}$, $6.87 \pm 0.11 \text{mm}^3$, and $296 \pm 33 \mu\text{m}$. At the 12-month examination, mean BCVA was 0.36 ± 0.2 , mean CPT was $195 \pm 11 \mu\text{m}$, mean TMV was $6.55 \pm 0.19 \text{mm}^3$, and mean CST was $239 \pm 14 \mu\text{m}$, respectively. No side-effects were noted. In particular, no sign of retinal thinning and underlying backscattering typical of conventional laser treatment could be detected at the site of the laser application on OCT.

Conclusion: The current pilot investigation of STLT for the treatment of symptomatic RAM shows encouraging data. A randomized clinical trial is required to ascertain the real efficacy this technique and the most appropriate settings to be employed.

Introduction

Retinal Arterial Macroaneurysms (MAR) are acquired saccular or fusiform dilations of the large arterioles of the retina. MAR are strongly associated with systemic hypertension and atherosclerosis.¹⁻⁸ Natural history may lead to a spontaneous obliteration of the lesion, but also to a number of vision threatening complications, including subretinal, preretinal, or vitreous hemorrhages, macular edema, serous macular detachment, macular deposition of hard exudates, macular hole, and branch retinal vein occlusion.¹⁻¹⁵ Treatment of MAR is still controversial.¹⁻⁹ In general, treatment is reserved to MAR causing exudative manifestations involving the fovea, and it is carried out using threshold laser photocoagulation in an attempt to achieve the obliteration of the vascular lesion, which leads to visible scar. Nevertheless, several complications have been related to laser photocoagulation, including arteriolar obliteration and consequent retinal ischemia.¹⁰

Subthreshold laser treatment (STLT) has been proposed in an attempt to minimize the adverse aspects of conventional laser photocoagulation by reducing the duration of laser exposure and by using a subvisible clinical end point.¹⁶⁻²⁰ Repeated laser pulses potentially localises the thermal effects to the retinal pigment epithelium (RPE) with limited protein denaturation.²¹

The aim of the present pilot study is to evaluate the effect of subthreshold laser treatment (STLT) in reducing the exudative manifestations secondary to RAM.

Methods

Patients referred to Department of Ophthalmology of the University of Udine and Trieste between January 2007 and January 2008 with the diagnosis of RAM were prospectively enrolled in the study. The research adhered to the tenets of the Declaration of Helsinki, and investigational review board approval was obtained. Each patient was carefully informed about the purpose of the research, providing signed consent to all procedures.

Inclusion criteria included the diagnosis of RAM, regarded as symptomatic whenever associated with visual acuity deterioration and distortion. More specifically, we selected eyes presenting RAM,

defined as an acquired dilation of the retinal arteries on biomicroscopy and fluorescein angiography (FA), which was associated with exudative manifestations involving the fovea (including: subretinal/intraretinal fluid, and/or hard exudates, and/or hemorrhages), and presented best corrected visual acuity (BCVA) worse than 20/80 Snellen equivalent, corresponding to 0.6 LogMAR. Patients who had undergone any other treatment for RAM in the past, or were affected by any other ocular disease were excluded from the study.

Each patient underwent a complete ophthalmological examination, including BCVA, on standard ETDRS charts, FA and optical coherence tomography (OCT). The patients were regularly scheduled at each 4-month follow-up for up to 12 months after laser treatment. BCVA measurement and OCT were performed by masked staff members, who were unaware of the purpose of the study. OCT (Stratus, Carl Zeiss, Meditec Inc, Germany) was performed using the fast macular thickness map protocol, consisting of six 6-mm radial lines, oriented 30° apart, centred on the fovea. When the automatic segmentation algorithm of fast macular thickness map failed to identify inner and outer retinal boundaries correctly, the central point thickness (CPT) was manually measured for each radial scan and the average of the 6 values obtained was used for statistical analysis. The mean CPT was defined as the distance from the inner retinal surface to the inner border of the RPE. Total macular volume (TMV) was determined by the sum of the volumes of the 9 quadrants obtained by a central macular thickness map. Central subfield thickness (CST) was defined as the mean value of the thickness values obtained in the central subfield.

In accordance with the protocol, each patient was first observed for a 4 months period to allow any spontaneous improvement of the symptoms to occur. If no improvement in BCVA and CPF was detected after 4 months, the patient was considered not able to achieve a spontaneous recovery and thus, eligible for the treatment with STLT, in an attempt to limit the exudation from the RAM, and to improve the visual function. Our protocol also made provision for each patient to undergo conventional visible laser treatment if BCVA had not improved by at least 1 ETDRS line and/or CPT had not reduced at least by 10% after 4 months following STLT.

STLT was performed using an infrared diode laser (Iris Medical Oculight, SLx Photocoagulator, Iridex Corp, Mountain View, Ca). The laser used parameters were: 125 μ m laser spot diameter, 0.3 second exposure, and 15% duty cycle. The laser power was arbitrarily set at 1400mW. This setting was chosen on the basis of our previous experience with STLT in the treatment of other diseases^{19,20} and the specific treatment of RAM (Parodi MB unpublished data). In particular, from our previous data regarding the treatment of RAM, we found out that a lower laser power had no beneficial effect on the leakage from RAM. In each case, laser spots were delivered in a contiguous mode with no free space between each spot application, and covered both the entire RAM lesion and the surrounding area, in order to promote a response in the neighbouring RPE too.

Primary outcome measures were the reduction of CPT and the improvement of BCVA at the 12-month examination. Secondary outcomes included also the changes in TMV and CST.

Results

Twelve consecutive patients affected by RAM with exudative manifestations involving the fovea were considered for the study. Nine patients who fulfilled the eligibility and exclusion criteria were enrolled (6 females and 3 males), with a mean age of 74.2 years (range: 56-81, SD: 11.3). Three patients were excluded because they had previously undergone to laser treatment.

Of the 9 patients enrolled, 7 were affected by hypertension and 2 by diabetes mellitus. At the initial examination, 6 eyes showed a macular hemorrhage centered on the fovea, comprising a subinternal limiting membrane hemorrhage associated with a retinal hemorrhage. The remaining 3 eyes revealed on OCT a retinal edema especially at the outer retinal layer, associated with serous retinal detachment involving the fovea. FA showed profuse leakage from RAM in all cases.

All patients performed all the planned controls and completed the 12-month follow-up.

The complete data of patients is listed in Table 1. At the enrolment, all the 9 patients had a BCVA \leq 0.6 LogMAR (approximately 20/80 Snellen equivalent), with a mean BCVA was 0.8 ± 0.1 SD

LogMAR (approximately 20/125 Snellen equivalent) (range: 1-0.6 LogMAR), a mean CPT of 314±22μ SD, a mean TMV of 7.05 mm³ ±0.06 SD, and a mean CST of 344±27μ SD.

In accordance with the protocol, the 9 patients enrolled were simply observed for 4 months to permit a possible improvement in BCVA to take place and to monitor the spontaneous development of the clinical picture. After the 4-month observation period no patient showed any BCVA improvement. On the contrary CPT was increased in all the 9 patients with a mean value of 340±49μ SD, TMV had showed a mean value of 7.14 mm³ ±0.05 SD, and mean CST was 366±37μ SD. Thus, all the patient were considered eligible to undergo STLT.

At the 4-month examination following STLT, BCVA and CPT improved in all 9 patients. More specifically, mean BCVA was 0.6±0.2 SD LogMAR (approximately 20/80 Snellen equivalent) (range: 0.9-0.4 LogMAR), CPT reduced to 274±29μ SD, TMV to 6.87 mm³ ±0.11 SD, and CST to 296±33μ SD.

Mean BCVA readings at the 8- and 12-month examinations were to 0.5±0.1 SD LogMAR (approximately 20/63 Snellen equivalent) (range: 0.3-0.7 LogMAR), and 0.36±0.2 SD LogMAR (approximately 20/50 Snellen equivalent) (range: 0.2-0.6 LogMAR), respectively (Fig. 1). Mean CPT reduced to 221±14μ SD and 195±11μ SD at the 8- and the 12-month control examinations, mean TMV passed to 6.68 mm³ ±0.2 SD and 6.55 mm³ ±0.19 SD, and mean CST was 257±20μ SD and 239±14μ SD, respectively (Figure 1 and 2).

The frequency distribution of BCVA changes revealed that all the patients gained a mean of 4.4 lines at the end of the follow-up, with 8 out of 9 eyes gaining 3 or more lines. No patient required additional treatment over the follow-up.

Baseline OCT performed at the level of the RAM revealed a vascular structure with a reflective wall associated with retinal thickening in the surrounding area. OCT scans after STLT revealed a reduction of RAM size associated with disappearance of the intraretinal oedema, with no sign of the retinal thinning and underlying backscattering, typical of conventional laser treatment.

CPT was manually measured in six cases, because the automatic segmentation algorithm failed to precisely identify inner and outer retinal boundaries.

All cases showed a complete resolution of exudative manifestation at the end of the follow-up and a cessation of the dye leakage on FA. Interestingly, no biomicroscopic, or angiographic evidence of the treatment turned out to be detectable at the laser application site (Fig. 3). No side-effect was noted over the follow-up.

Discussion

The treatment of RAM is controversial and at present there is no general consensus about the optimum approach. Spontaneous obliteration of RAM may occur over the follow-up, but the long persistence of blood or subretinal fluid may lead to progressive photoreceptor damage, with consequent irreversible visual impairment.⁹ More specifically, the presence of subretinal hemorrhage beneath the fovea leads to a diminished visual function.⁹ Treatment is generally indicated for RAM associated with exudative manifestations involving the fovea which do not tend to resolve spontaneously. The most commonly employed approach is direct or indirect laser photocoagulation with visible end-point. Nevertheless, several complications may be associated with conventional threshold laser for macular lesions, including enlargement of laser scar, choroidal neovascularization, and subretinal fibrosis.²²⁻³⁰ In addition to these complications, arteriolar obliteration, increased retinal exudation and scarring, with possible retinal traction, have also been reported as possible sequelae of the laser photocoagulation of RAM.²⁻¹⁰

The use of STLT represents a different approach to the treatment of RAM. STLT has been proposed in an attempt to minimize the negative aspects of conventional grid laser photocoagulation and has achieved encouraging results, especially in macular oedema secondary to diabetic retinopathy, proliferative diabetic retinopathy, and branch retinal vein occlusion.^{19,20,31-35} The purpose of employing STLT is to attempt to decrease laser damage by reducing the duration of laser exposure and by using a subvisible clinical end point. A micropulse diode laser releases low energy

micropulses in order to confine the energy to the RPE cells, with limited protein denaturation,²¹ avoiding lateral thermal spreading.

The current study presents the result of a pilot investigation of STLT for the treatment of symptomatic RAM show encouraging data. All the patients achieved a cessation of leakage on FA, with improvements in BCVA, CPT, CST, and TMV. No biomicroscopic, angiographic, or OCT sign of laser treatment was detected over the follow-up. Moreover, no evidence of arterial obliteration, increased retinal exudation, or retinal traction was noted.

The underlying mechanisms by which STLT acts remains a matter of speculation, because no specific histopathologic study in humans has been carried out. However, bearing in mind the selective damage to the RPE cells induced by a subthreshold laser application,³⁶⁻³⁸ it can be hypothesized that the effects of STLT may lead to an improved balance in cytokines release, perhaps including an upregulation of basic fibroblast growth factor.³⁹ Thus, STLT may act on the complex interaction among the different molecules implicated in the vascular permeability, promoting a vascular repair together with an improved fluid reabsorption.

We are perfectly aware that ours is a pilot study designed only to find out if a positive effect can be obtained using STLT in the treatment of long-standing symptomatic RAM. The major limitations of the present study are represented by the small number of patients involved and the absence of a control group. In an attempt to be more confident that the effect noted are indeed due to STLT and not to the spontaneous evolution of RAM as part of its natural history, we designed the protocol so as to turn to STLT only after a 4-month period of simple observation in order to allow for the possible spontaneous resolution of the exudative manifestations of RAM. Patients were then there treated, as it was consider improper to prolong the observation beyond this period in patients having low visual acuity. Moreover, we chose the laser setting on the basis of our personal experience and cannot rule out that a different setting might lead to a even better functional and anatomical outcome.

Thus, this research is to be considered an initial investigation acting as the basis for a multicentre randomised clinical trial. In essence, STLT offers promising results in the treatment of symptomatic RAM without bringing about negative side-effects. A multicentre randomized clinical trial is required to ascertain the real efficacy of this technique, and the most appropriate settings to be employed.

References

1. Nadel AJ, Gupta KK. Macroaneurysms of the retinal arteries. *Arch Ophthalmol.* 1976;94:1092-1096.
2. Lewis RA, Norton EW, Gass JD. Acquired arterial macroaneurysms of the retina. *Br J Ophthalmol.* 1976;60:21-30.
3. Abdel-Khalek MN, Richardson J. Retinal macroaneurysm: natural history and guidelines for treatment. *Br J Ophthalmol.* 1986;70:2-11.
4. Lavin MJ, Marsh RJ, Peart S, Rehman A. Retinal arterial macroaneurysms: a retrospective study of 40 patients. *Br J Ophthalmol.* 1987;71:817-25.
5. Rabb MF, Gagliano DA, Teske MP. Retinal arterial macroaneurysms. *Surv Ophthalmol.* 1988;33:73-96.
6. Panton RW, Goldberg MF, Farber MD. Retinal arterial macroaneurysms: Risk factors and natural history. *Br J Ophthalmol.* 1990;74:595-600.
7. Brown DM, Sobol WM, Folk JC, Weingeist TA. Retinal arterial macroaneurysm: long term visual outcome. *Br J Ophthalmol.* 1994;78:534-538.
8. Moosavi RA, Fong KC, Chopdar A. Retinal artery macroaneurysms: clinical and fluorescein angiographic features in 34 patients. *Eye.* 2006;209:1011-1020.

9. Tsujikawa A, Sakamoto A, Ota M, et al. Retinal structural changes associated with retinal arterial macroaneurysm examined with optical coherence tomography. *Retina*. 2009;29:782-792.
10. Russell SR, Folk JC. Branch retinal artery occlusion after dye yellow photocoagulation of an arterial macroaneurysm. *Am J Ophthalmol*. 1987;104:186-7.
11. Ciardella AP, Barile G, Schiff W, et al. Ruptured retinal arterial macroaneurysm associated with a stage IV macular hole. *Am J Ophthalmol*. 2003;135:907-9.
12. Colucciello M, Nachbar JG. Macular hole following ruptured retinal arterial macroaneurysm. *Retina* 2000;20:94–96.
13. Sagara N, Kawaji T, Koshiyama Y, et al. Macular hole formation after macular hemorrhage associated with rupture of retinal arterial macroaneurysm. *Br J Ophthalmol*. 2009 Jun 10. [Epub ahead of print].
14. Parodi MB, Bondel E, Saviano S, Ravalico G. Branch retinal vein occlusion after spontaneous obliteration of retinal arterial macroaneurysm. *Retina*. 1998;18:378-379.
15. Takahashi K, Kishi. Serous macular detachment associated with retinal arterial macroaneurysm. *Jpn J Ophthalmol*. 2006;50:460-464.
16. Friberg TR, Karatza EC. The treatment of macular disease using a micropulsed and continuous wave 810-nm diode laser. *Ophthalmology*. 1997;104:2030–2038.
17. Roider J, Brinkmann R, Wirbelauer C, et al. Retinal sparing by selective retinal pigment epithelial photocoagulation. *Arch Ophthalmol* 1999;117:1028–1034.
18. Moorman CM, Hamilton AM. Clinical applications of the MicroPulse diode laser. *Eye*. 1999;13:145–150.
19. Parodi MB, Spasse S, Iacono P, et al. Subthreshold grid laser treatment of macular edema secondary to branch retinal vein occlusion with micropulse infrared (810 nanometer) diode laser. *Ophthalmology*. 2006;113:2237-2242.

20. Parodi MB, Iacono P, Ravalico G. Intravitreal triamcinolone acetonide combined with subthreshold grid laser treatment for macular oedema in branch retinal vein occlusion: a pilot study. *Br J Ophthalmol.* 2008;92:1046-50.
21. Desmetre TJ, Mordon SR, Buzawa DM, Mainster MA: Micropulse and continuous wave diode retinal photocoagulation: Visible and subvisible lesion parameters. *Br J Ophthalmol.* 2006;90:709-712.
22. Schatz H, Madeira D, McDonald HR, et al. Progressive enlargement of laser scars following grid laser photocoagulation for diffuse diabetic macular edema. *Arch Ophthalmol.* 1991;109:1549–1551.
23. Morgan CM, Schatz H. Atrophic creep of the retinal pigment epithelium after focal macular photocoagulation. *Ophthalmology.* 1989;96:96–103.
24. Early Treatment Diabetic Retinopathy Study Research Group. Focal photocoagulation treatment of diabetic macular edema. Relationship of treatment effect to fluorescein angiographic and other retinal characteristics at baseline: ETDRS report no 19. *Arch Ophthalmol.* 1995;113:1144–1155.
25. Lewen RM. Subretinal neovascularization complicating laser photocoagulation of diabetic maculopathy. *Ophthalmic Surg.* 1988;19:734–737.
26. Lewis H, Schachat AP, Haimann MH, et al. Choroidal neovascularization after laser photocoagulation for diabetic macular edema. *Ophthalmology.* 1990;97:503–510.
27. Guyer DR, D’Amico DJ, Smith CW. Subretinal fibrosis after laser photocoagulation for diabetic macular edema. *Am J Ophthalmol.* 1992;113:652–656.
28. Rutledge BK, Wallow IH, Poulsen GL. Sub-pigment epithelial membranes after photocoagulation for diabetic macular edema. *Arch Ophthalmol.* 1993;111:608–613.
29. Fong DS, Segal PP, Myers F, et al. Subretinal fibrosis in diabetic macular edema. ETDRS report 23. Early Treatment Diabetic Retinopathy Study Research Group. *Arch Ophthalmol.* 1997;115:873-877.

30. Han DP, Mieler WF, Burton TC. Submacular fibrosis after photocoagulation for diabetic macular edema. *Am J Ophthalmol.* 1992;113:513-521.
31. Friberg TM. Infrared micropulsed laser treatment for diabetic macular edema--subthreshold versus threshold lesions. *Semin Ophthalmol.* 2001;16:19-24.
32. Luttrull JK, Musch DC, Maister MA. Subthreshold diode laser micropulse photocoagulation for the treatment of clinically significant diabetic macular oedema. *Br J Ophthalmol.* 2004;89:74-80.
33. Luttrull JK, Spink CA. Serial optical coherence tomography of subthreshold diode laser micropulse photocoagulation for diabetic macular edema. *Ophthalmic Surg Lasers Imaging.* 2006;37:370-7.
34. Figueira J, Khan J, Nunes S, et al. Prospective randomized controller trial comparing sub-threshold micropulse diode laser photocoagulation and conventional green laser for clinically significant diabetic macular oedema. *Br J Ophthalmol.* 2009;93:1341-1344.
35. Luttrull JK, Spink CA, Musch DC. Subthreshold diode micropulse panretinal photocoagulation for proliferative diabetic retinopathy. *Eye.* 2008;22:607-612.
36. Chong LP, Kohen L, Kelsoe W, et al. Selective RPE damage by micro-pulse diode laser photocoagulation. *Invest Ophthalmol Vis Sci.* 1992;33 (suppl):722. Abstract 150.
37. Chong LP, Kohen L. A retinal laser which damages only the RPE: Ultrastructural study. *Invest Ophthalmol Vis Sci.* 1993;34 (suppl):960. Abstract 1270.
38. Morimura Y, Okada AA, Hayashi A et al. Histological effect and protein expression in subthreshold transpupillary thermotherapy in rabbit eyes. *Arch Ophthalmol.* 2004;122:1510-1515.
39. Xiao M, Sastry SM, Li Z-Y, et al. Effects of retinal laser photocoagulation on photoreceptor basic fibroblast growth factor and survival. *Invest Ophthalmol Vis Sci.* 1998;39:618-630.

Figure and Table Legends

Figure 1

Mean best corrected visual acuity values (LogMAR) over the follow-up. A statistically significant difference was found ($p < 0.01$, Wilcoxon test) from the 4-month examination after subthreshold laser treatment on.

Figure 2

Mean central point thickness (μm) over the follow-up. A statistically significant difference was found ($p < 0.01$, Wilcoxon test) from the 4-month examination after subthreshold laser treatment on.

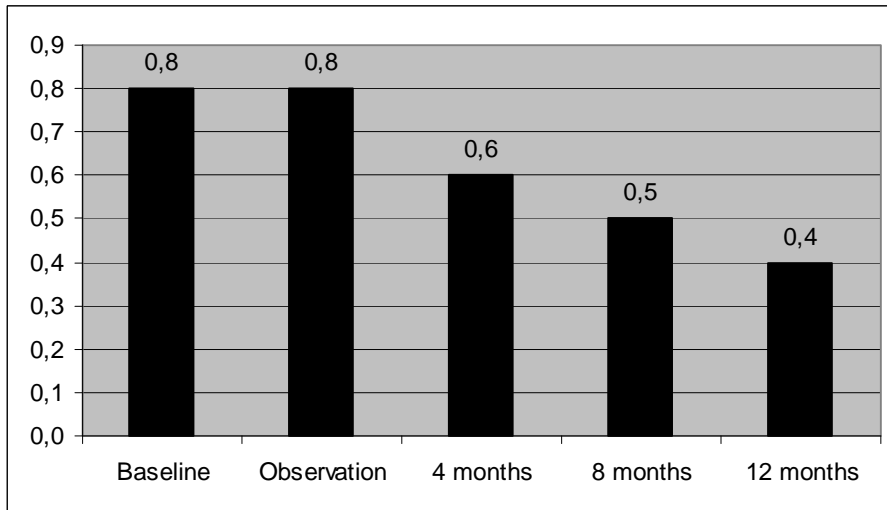
Figure 3

Case 8. Top left: Colour photograph showing a retinal arterial macroaneurysm surrounded by retinal haemorrhage along the superotemporal arcade. Top right: Same case at the end of the follow-up revealing the complete resolution of the haemorrhage with absence of the retinal pigment epithelium alterations at the site of the laser spot application. Centre left: Fluorescein angiography at baseline. Centre right: Fluorescein angiography at the end of the follow-up disclosing the obliteration of the retinal arterial macroaneurysm, without visible scar. Bottom Left. OCT at baseline, showing neurosensory detachments and intraretinal cysts. Bottom right: OCT at the end of the follow-up with fluid disappearance.

Table legend

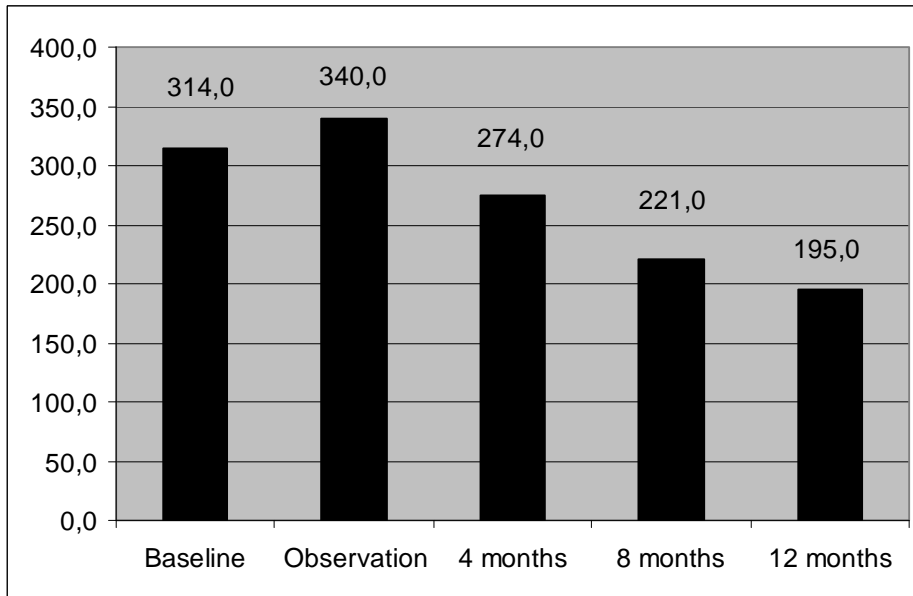
BCVA indicates best corrected visual acuity; CPT indicates central point thickness; CST indicates central subfield thickness; TMV indicates total macula volume. Statistical analyses were performed using Wilcoxon test.

Fig. 1. Mean Best corrected visual acuity values (LogMAR) over the follow-up.



Legend: Mean best corrected visual acuity values (LogMAR) over the follow-up. A statistically significant difference was found ($p < 0.01$, Student's t-test) from the 4-month examination after subthreshold laser treatment on.

Figure 2. Mean central point thickness (μm) over the follow-up.



Legend: Mean central point thickness (μm) over the follow-up. A statistically significant difference was found ($p < 0.01$, Student's t-test) from the 4-month examination after subthreshold laser treatment on.

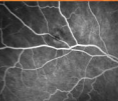
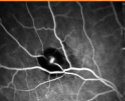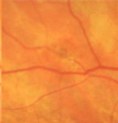

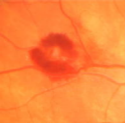
Table 1. Best corrected visual acuity and OCT data of the nine patients treated with subthreshold laser treatment over the follow-up

CASE	BCVA					CPT					CST					TMV				
	baseline	observation	4 mos	8 mos	12 mos	baseline	observation	4 mos	8 mos	12 mos	baseline	observation	4 mos	8 mos	12 mos	baseline	observation	4 mos	8 mos	12 mos
1	1,0	1,0	0,9	0,7	0,6	345	450	257	230	213	361	436	263	241	229	7,01	7,20	6,78	6,80	6,70
2	0,8	0,7	0,7	0,6	0,5	289	299	222	220	189	297	308	253	251	210	6,99	7,08	6,80	6,80	6,59
3	0,7	0,7	0,7	0,6	0,5	278	270	240	231	187	299	319	267	245	230	7,03	7,12	6,85	6,90	6,78
4	0,9	0,9	0,5	0,4	0,3	310	327	289	201	198	346	367	301	236	249	7,07	7,20	7,01	6,90	6,80
5	0,6	0,6	0,4	0,4	0,3	340	329	296	212	201	367	359	341	278	256	7,18	7,10	7,00	6,50	6,50
6	0,8	0,9	0,4	0,4	0,2	324	350	302	231	212	356	373	349	289	248	7,01	7,13	6,80	6,40	6,30
7	0,7	0,8	0,5	0,3	0,2	301	328	289	201	178	356	367	301	234	243	6,99	7,08	6,90	6,40	6,30
8	0,9	0,9	0,7	0,5	0,4	325	355	301	243	189	367	378	302	267	237	7,12	7,20	7,00	6,70	6,42
9	0,8	0,8	0,6	0,5	0,2	314	360	269	222	190	354	387	289	278	249	7,06	7,14	6,73	6,70	6,53
media	0,8	0,8	0,6	0,5	0,4	314	341	274	221	195	345	366	296	258	239	7,05	7,14	6,87	6,68	6,55
sd	0,1	0,1	0,2	0,1	0,2	22,3	49,8	28,8	14,4	11,8	27,3	37,3	33,1	20,6	14,2	0,06	0,05	0,11	0,20	0,19
P value			0,016	0,003	0,003			0,003	0,003	0,003			0,003	0,003	0,003			0,003	0,003	0,003

Legend: BCVA indicates best corrected visual acuity; CPT indicates central point thickness; CST indicates central subfield thickness; TMV indicates total macula volume. Statistical analyses were performed using Wilcoxon test.