

Automatic Retina Exudates Segmentation without a Manually Labelled Training Set

Luca Giancardo^{a,b}, Fabrice Meriaudeau^b, Thomas P. Karnowski^a, Yaqin Li^c, Kenneth W. Tobin^a and Edward Chaum^c

Aims

Diabetic Macular Edema (DME) is a complication of Diabetic Retinopathy and one of the leading causes of blindness in the industrialized world. Early detection is the necessary step to provide effective treatment; however, the current number of trained eye care professionals is inadequate to screen the increasing number of diabetic patients.

We present two new methods for the detection of exudates are presented which do not use a supervised learning step; therefore, they do not require labelled training sets which are time consuming to create, difficult to obtain and prone to human error. We introduce a new dataset of fundus images from various ethnic groups and levels of DME which we have made publicly available. We evaluate our algorithm with this dataset and compare our results with two recent exudate segmentation algorithms [1,2] which do not explicitly require a training dataset at lesion level.

Materials

Ethnicity	
African American	104 (62%)
Caucasian	42 (25%)
Hispanic	19 (11%)
Unknown	4 (2%)
DME Diagnosis	
Negative	115 (68%)
Positive	54 (32%)
Patients' Age	
age < 26	5 (3%)
26 ≤ age < 43	20 (12%)
43 ≤ age < 61	105 (62%)
age ≥ 61	39 (23%)

The 169 images collected from the telemedicine network are publicly available at <http://vibot.u-bourgogne.fr/luca/>.

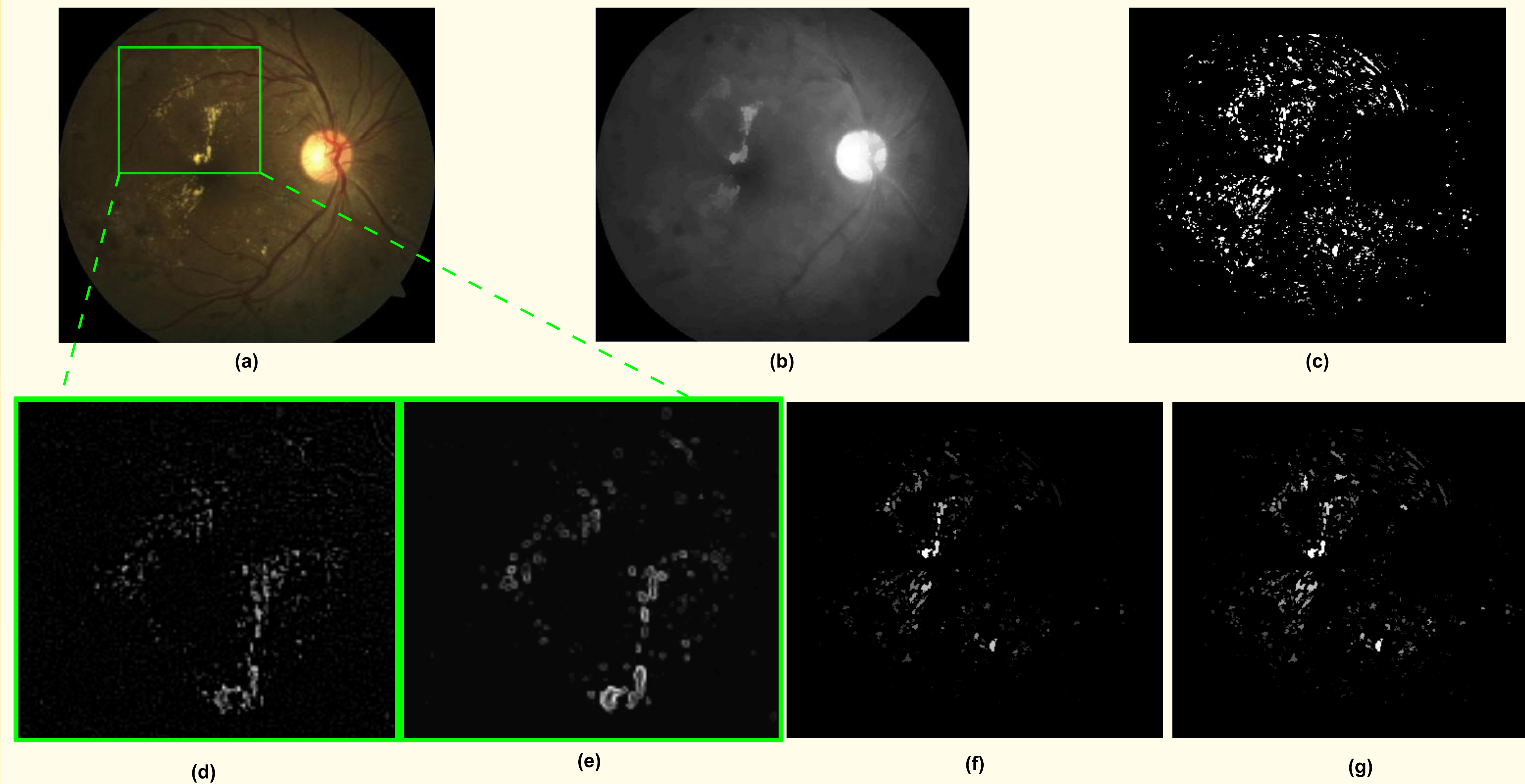
References

- [1] C I Sanchez, M Garcia, A Mayo, M I Lopez, and R Hornero, "Retinal image analysis based on mixture models to detect hard exudates.", *Medical Image Analysis*, vol. 13, no. 4, pp. 650–658, Aug 2009.
- [2] A Sopharak, B Uyyanonvara, S Barman, and T H Williamson, "Automatic detection of diabetic retinopathy exudates from non-dilated retinal images using mathematical morphology methods.", *Computerized Medical Imaging and Graphics*, vol. 32, no. 8, pp. 720–727, Dec 2008.

Affiliations and Acknowledgements

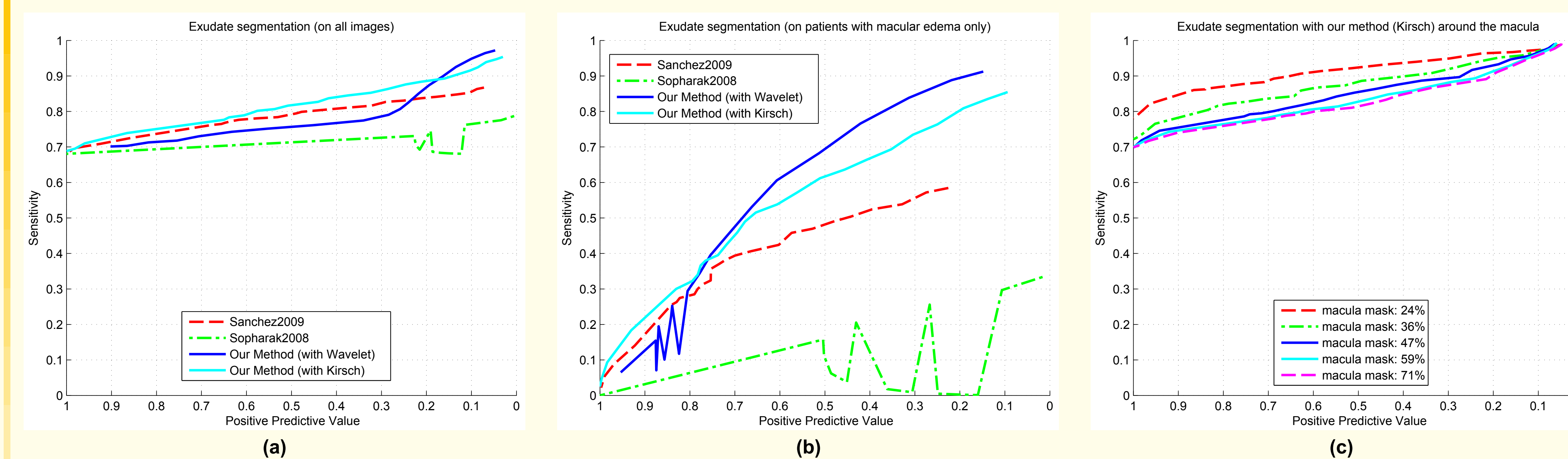
(a) Oak Ridge National Laboratory, Oak Ridge TN, USA; (b) University of Burgundy, France; (c) Hamilton Eye Inst., UT Health Sciences Center, Memphis TN, USA. These studies were supported in part by grants from Oak Ridge National Laboratory, the National Eye Institute, (EY017065), by an unrestricted UTHSC Departmental grant from Research to Prevent Blindness (RPB), New York, NY, Fight for Sight, New York, NY, by The Plough Foundation, Memphis, TN and by the Regional Burgundy Council, France. Dr. Chaum is an RPB Senior Scientist.

Method: Exudate Detection



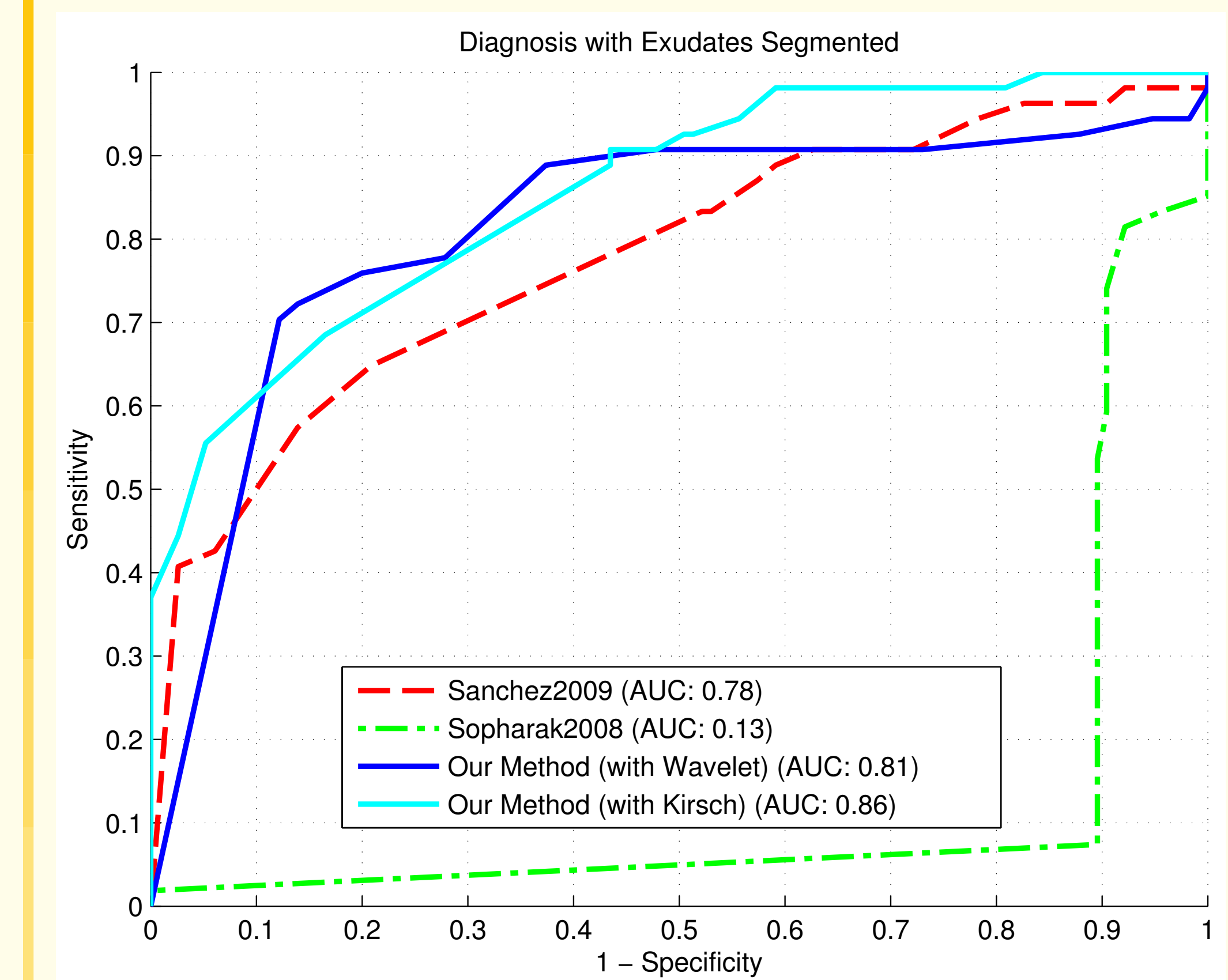
- (a) Example of a fundus image of the dataset used. The square represents the details shown in (d) and (e).
 (b) Background. A large median filter on the I channel (HSI colour space) is the initial estimate. Then, we enhance the normalisation with morphological reconstruction step.
 (c) Initial exudates candidates. The image is normalised and the candidates are selected with a hard thresholding operation, based on the histogram distribution.
 (d) Stationary Haar Wavelet Analysis. A stationary Haar wavelet analysis is performed up to the second level on I_g . The process is inverted maintaining the last vertical, diagonal and horizontal details only, as these are the wavelet coefficients that seem to contain most of the foreground structures. By transforming back to the image space we obtain a background-less image with a strong response at the centre of exudates.
 (e) Kirsch's Edges Image Analysis. It tries to capture the external edges of the lesion candidate. This edge detector is based on a kernel evaluated at 8 different directions.
 (f) Exudates Probability with Wavelet. Mean outputs of (d) are calculated on a cluster basis and assigned to the lesion in its entirety.
 (g) Exudates Probability with Kirsch's Edges. Same as above, but the mean outputs of (e) are employed.

Results: FROC curves



- (a) The exudate segmentation performances on all images; (b) The performance on the images diagnosed with DME only; (c) The exudate segmentation performances of our method using Kirsch's edges in the macula area; each line corresponds to a growing circular area centred on the fovea. Note that: $Sensitivity = \frac{TP}{TP+FN}$ Positive Predictive Value = $\frac{TP}{TP+FP}$.

Other Results



ROC curves of the diagnosis of DME by employing only the lesions segmented, i.e. an image is considered positive if it shows at least a lesion.

Method	Seconds per image
Sanchez et al.	~39
Sopharak et al.	~36
Our method (with Wavelet)	~2.4
Our method (with Kirsch)	~1.9

On a 2.6 GHz platform with an unoptimised Matlab implementation.

Conclusions

In all instances, we evaluate the performance of the lesion segmentation algorithms on a lesion by lesion basis for each image. A lesion is considered a true positive (TP) if it overlaps at least in part with the ground-truth; a false negative (FN) if no corresponding lesion is found in the automatic segmentation; a false positive (FP) if an exudate is found in the automatic segmentation but no corresponding lesion has been manually segmented. In all of our tests, our algorithms perform better or comparable to the methods in [1,2] with an order of magnitude reduction in computational time. The method by Sanchez et al. is somewhat close to ours tests, however, the image normalisation procedure gives a substantial computational advantage to our method. In addition we have evaluated our algorithms ability in identifying patients with DME based on the segmentation of one or more lesion in a fundus image. This is a simplistic method for DME diagnosis, but does provide a baseline of the possible screening performances that can be achieved employing the output of the segmentation as a classification feature.