



HAL
open science

Replacement of the Proximal Humerus with MUTARS Tumor Endoprostheses

P. Raiss, S. Kinkel, U. Sauter, T. Bruckner, B. Lehner

► **To cite this version:**

P. Raiss, S. Kinkel, U. Sauter, T. Bruckner, B. Lehner. Replacement of the Proximal Humerus with MUTARS Tumor Endoprostheses. *EJSO - European Journal of Surgical Oncology*, 2010, 36 (4), pp.371. 10.1016/j.ejso.2009.11.001 . hal-00576169

HAL Id: hal-00576169

<https://hal.science/hal-00576169>

Submitted on 13 Mar 2011

HAL is a multi-disciplinary open access archive for the deposit and dissemination of scientific research documents, whether they are published or not. The documents may come from teaching and research institutions in France or abroad, or from public or private research centers.

L'archive ouverte pluridisciplinaire **HAL**, est destinée au dépôt et à la diffusion de documents scientifiques de niveau recherche, publiés ou non, émanant des établissements d'enseignement et de recherche français ou étrangers, des laboratoires publics ou privés.

Accepted Manuscript

Title: Replacement of the Proximal Humerus with MUTARS Tumor Endoprosthesis

Authors: P. Raiss, S. Kinkel, U. Sauter, T. Bruckner, B. Lehner

PII: S0748-7983(09)00503-4

DOI: [10.1016/j.ejso.2009.11.001](https://doi.org/10.1016/j.ejso.2009.11.001)

Reference: YEJSO 2912

To appear in: *European Journal of Surgical Oncology*


Received Date: 24 August 2009

Revised Date: 20 October 2009

Accepted Date: 2 November 2009

Please cite this article as: Raiss P, Kinkel S, Sauter U, Bruckner T, Lehner B. Replacement of the Proximal Humerus with MUTARS Tumor Endoprosthesis, *European Journal of Surgical Oncology* (2009), doi: [10.1016/j.ejso.2009.11.001](https://doi.org/10.1016/j.ejso.2009.11.001)

This is a PDF file of an unedited manuscript that has been accepted for publication. As a service to our customers we are providing this early version of the manuscript. The manuscript will undergo copyediting, typesetting, and review of the resulting proof before it is published in its final form. Please note that during the production process errors may be discovered which could affect the content, and all legal disclaimers that apply to the journal pertain.



Replacement of the Proximal Humerus with MUTARS Tumor Endoprostheses

Raiss P.¹, Kinkel S.¹, Sauter U.¹, Bruckner T.² and Lehner B.¹

*From the Orthopaedic Department¹ and Institute for Medical Biometrics and Informatics²,
University of Heidelberg, Germany*

Patric Raiss, MD
Stefan Kinkel, MD
Ulrich Sauter
Thomas Bruckner, PhD
Burkhard Lehner, MD

Division of Orthopaedic Oncology
Department of Orthopaedics,
University of Heidelberg,
Schlierbacher Landstrasse 200 A,
69118 Heidelberg,
Germany

Department of Medical Biometrics and Informatics
University of Heidelberg
Im Neuenheimer Feld 305
69120 Heidelberg
Germany

Corresponding author: Burkhard Lehner, MD
Orthopädische Universitätsklinik Heidelberg,
Schlierbacher Landstrasse 200 A,
69118 Heidelberg,
Germany
Email: Burkhard.Lehner@ok.uni-heidelberg.de
Telephone: +49-6221-966360, Fax: +49-6221-966311

Abstract

Background and Objectives: The aim of this study was to analyze our results using a modular endoprosthetic replacement system (MUTARS) for bone tumors of the proximal humerus.

Methods: Thirty-nine patients were treated with a MUTARS endoprosthesis of the proximal humerus. Mean follow-up duration was 38 months (3--138 months). Most operations were necessitated by metastasis (n=30); surgery for a primary tumor (n=9) was less frequent. The Enneking score was recorded and the active ranges of motion for shoulder flexion, abduction, and external rotation. Complete refixation of the rotator cuff was possible in 23 cases. Radiographs of the affected shoulders were obtained in two planes.

Results: Patient survival was 77% at 2 years and 45% at 11.5 years after surgery. The survival rate of the limb was 90% at 11.5 years. The mean Enneking score was 19 points (range 7--27 points). The mean shoulder flexion was 34° (range 0--90°), abduction 33° (range 0--90°), and external rotation 12° (range --10--50°). Patients with a complete rotator cuff repair showed a significant better range of motion compared to patients with a partial or no repair (p<0.015). No signs of implant loosening were observed on postoperative radiographs. Seven complications occurred, five of them leading to implant revision. At 11.5 years after surgery, the survival rate for the whole cohort without complications was 72%, without revision of the implant 70%.

Conclusions: Replacement of the proximal humerus with MUTARS endoprosthesis is a viable treatment option for bone tumors with satisfying results.

Key words: arthroplasty; humerus; defect reconstruction; limb salvage;
megaprosthesis; MUTARS

ACCEPTED MANUSCRIPT

Introduction

Malignant bone tumors of the proximal humerus are common, and multiple treatment options have been reported in recent years [1-8]. In most cases, surgery comprises an essential element of therapy. The clinical outcome, local recurrence, and survival rates after limb-preserving and other procedures seem to be comparable [9-11]. To provide a platform for elbow and hand function, reconstructive limb-preserving procedures have been proposed for the proximal humerus [12]. Moreover, patient acceptance has been described as higher for limb-preserving treatments. Therefore, amputation of the shoulder girdle is avoided if possible.

In limb salvage procedures, large bone defects may result after resection of the proximal humerus. These defects can be reconstructed with osteoarticular allografts, allograft prosthesis composites, or endoprostheses [12-15].

Many different endoprosthetic systems for defect reconstruction of the proximal humerus are currently in clinical use. Different implants from different manufactures with a cemented or uncemented fixation concept have been described for replacement [2;8;8;12;16-18]. Little information is available about the modular endoprosthetic system "MUTARS" for replacement of the proximal humerus [19;20]. This implant is available in combination with a Trevira tube for refixation of detached tendons. There is no information available on whether refixation of the detached tendons to a tube leads to a better functional outcome.

Therefore, the aim of the present study was to examine the clinical and oncological outcome using this endoprosthetic system while evaluating the implant survival rate.

Materials and Methods

Patients

Between 1995 and 2008, 61 patients at our institution were treated by endoprosthetic replacement of the proximal humerus after tumor resection and included in a prospective database. In 43 cases a modular tumor endoprosthesis (MUTARS) was used. Four of these 43 patients were lost to follow-up, so 39 patients were included in this study. Inclusion criteria were: (1) tumor or metastasis of the proximal humerus and (2) treatment with a modular tumor endoprosthesis (MUTARS).

There were 20 women and 19 men, with an average age of 60 years (24--84 years) at the time of implantation. The mean duration of follow-up was 38 months (range 3--138 months). Eighteen patients died during the follow-up period, 7 of them within 3 months of surgery.

Most operations were performed because of metastasis (n=30); surgery for a primary tumor (n=9) was less frequent. The tumor entities were: renal cell cancer (n=9), breast cancer (n=7), lung cancer (n=5), plasmacytoma (n=4), chondrosarcoma (n=4), Ewing sarcoma (n=2), hepatocellular carcinoma (n=2), angiosarcoma (n=2), colon cancer (n=1), Non-Hodgkin lymphoma (n=1), prostate cancer (n=1) and leiomyosarcoma (n=1). The indication for surgery was a pathological fracture in 25 patients and an initial manifestation of a tumor at the proximal humerus in 14 patients. In one case a previous osteosynthesis had failed.

Clinical and radiographical examination

Radiographs in two planes (antero-posterior and lateral) and MRI's of the affected shoulder were obtained preoperatively. Postoperatively, all patients were evaluated using the Enneking score. This score was used to assess the function of the upper

extremity. The Enneking score is divided in 6 subgroups: pain, function, emotional acceptance, hand position, manual dexterity and lifting ability [21]. For each subgroup a minimum of 0 points and a maximum of 5 points can be reached. An overall result of 30 points represents a normal function without pain of the upper extremity, whereas 0 points represents no function and disabling pain. Additionally, the active range of motion in degrees was recorded for shoulder flexion, abduction and external rotation with the hanging arm in neutral position and elbow flexion of 90°. All patients were routinely evaluated according to the treatment plan for each tumor entity at defined intervals. Neoadjuvant or adjuvant therapy was performed according to the diagnosis and the corresponding protocol. Radiographs in two planes were made for all follow-up examinations (Fig. 1).

Operative technique and implants

An anterior deltopectoral approach was used in all cases. In all but one case, intraarticular resection of the tumor was possible. For the one extraarticular resection, the neck of the glenoid was transected. In all cases the tendons of the rotator cuffs were detached from the proximal humerus. Complete refixation of the cuff was possible in 23 cases. A partial reattachment of the cuff (supra- and infraspinatus tendons) was possible in 6 patients. In 10 patients reattachment of any tendon failed. Incomplete or failed reattachment of the rotator cuff was based due to the desired resection margins and therefore determined by the oncological approach. In three patients part of the triceps brachii muscle and in three patients part of the deltoid muscle including the axillary nerve had to be resected. After preparation or resection of the soft tissues, the humerus was explored. The osteotomy was performed according to the intramedullary extension of the tumor planned on MRI's and radiographs in two projections. The mean length of the bone segment resected

was 13 cm (range 7–19 cm) measured from the apex of the humerus. Depending on the site and length of resection, the required MUTARS modules were selected. The fixation was achieved with an intramedullary stem, which was cemented in 33 cases and inserted cementless in 6 cases. In the cementless version the stem is inserted using a press-fit technique in order to achieve sufficient primary stability. The stem has a rough surface to allow ongrowth of bone. The stem is made of titanium alloy (TiAl6V4) in the cementless and of CoCrMo alloy in the cemented version. After implantation, a Trevira tube for refixation of the tendons was used in all patients. The rotator cuff was repaired if possible.

Rehabilitation protocol

Drains were removed on the second day after operation. To protect the reconstructed tendons the arms were placed in internal rotation in Gilchrist bandages for 6 weeks. Postoperatively, the shoulders were mobilized passively by a physiotherapist for 6 weeks with 60° shoulder flexion and abduction and 0° external rotation. After 6 weeks patients were asked to support these movements actively with an unlimited range of motion.

Statistics and ethics

Statistical analysis was performed using SAS 9.1. Estimates of survival were calculated by means of the Kaplan--Meier method for the whole cohort of patients, for amputations, for implants, for complications, and for revisions. The Wilcoxon U-test was used to assess differences in the postoperative shoulder motion between patients with or without refixation of the rotator cuff. $P < 0.05$ was considered significant.

The study was reviewed and approved by the ethics committee of the local university (IRB number 278/99).

ACCEPTED MANUSCRIPT

Results

Clinical results

The functional score according to Enneking was 19 points (range 7 -- 27 points) at the last follow-up examination. Figure 2 shows the overall Enneking score and its subgroups for the whole study cohort.

The mean postoperative shoulder flexion of the whole cohort was 34° (range 0–90°), abduction 33° (range 0–90°), and external rotation 10° (range --10–50°).

Patients with a complete refixation of the rotator cuff had better shoulder motion than patients with partial repair of the cuff (Figure 3). These differences were significant ($p<0.015$).

All patients were able to reach their mouth with the ipsilateral hand.

Survival and complications

For the whole cohort the overall survival was 77% at 2 years and 45% at 11.5 years (Fig. 4). The survival rate of the limb without amputation was 90% at 11.5 years.

Twenty-seven of the monitored patients had metastases at the last follow-up examination. Local recurrences had been detected in 2 patients, one of these leading to an interscapulothoracic amputation. The overall 5-year survival of patients with and without metastases was 48% and 64%, respectively. There was no significant difference between the survival curves (log-rank-test: $p=0.192$).

The local recurrences developed after resection of metastases of the proximal humerus without pathological fractures. The overall 5-year survival of patients with and without pathological fractures of the proximal humerus was 42% and 66%, respectively. There was no significant difference between the survival curves (log-

rank-test $p=0.379$). There was no further evidence of neoplastic disease in nine patients.

In total, 7 complications in 39 proximal humeral replacements were recorded. Out of these seven patients, five underwent revision surgery. The most common complication was dislocation of the humeral head ($n=4$). In three of these cases the rotator cuff was completely resected, and in one case the supra- and infraspinatus muscles were resected. Implant revision was necessary for two of the patients with dislocation. Retroversion of the humeral head was changed from 40° to 60° in both cases, without any re-dislocation. In two patients deep wound infection occurred, 4 and 5 years after surgery. In both cases the prosthesis was explanted. In one of these cases re-implantation was possible 7 months after explantation following two further revisions. Implant loosening was observed in one patient with a cementless implant. After explantation of the prosthesis the defect was treated with an autologous fibula graft. In one case an intraoperative fracture of the humeral shaft was observed and treated with osteosynthesis during the same session. All complications with radiographic results and treatments are shown in table 1.

The survival rate for the whole cohort without any complication was 82% at 2 years and 72% at 11.5 years.

The survival rate without revision of the implant was 90% at 2 years and 70% at 11.5 years (Fig. 5).

Imaging results

Implant loosening was seen in only one patient, who underwent revision surgery (see above). No further obvious radiological signs of implant loosening were observed.

Cranial migration of the humeral head was observed in 14 cases. In 6 of these patients a partial ($n=3$) or complete ($n=3$) resection of the rotator cuff was performed.

Caudal migration of the humeral head was detected in 3 cases after resection of the deltoid muscle and axillary nerve.

In no case was secondary wear of the glenoid cartilage and bone found on the most recent follow-up radiographs in two planes.

ACCEPTED MANUSCRIPT

Discussion

Treatment options for defect reconstruction

Bone tumors of the proximal part of the humerus often necessitate combined procedures such as chemotherapy, radiotherapy, and surgery. If surgery is required, large bone defects of the proximal humerus can result. Different interventions have been proposed for bridging the resulting defects. In children and in patients with small bone defects, the clavícula pro humero procedure has been employed with an acceptable outcome but also with a high complication rate [7]. Biologic reconstruction procedures such as osteoarticular allografts, prosthesis allograft composites, and fibula autografts, which can be implanted vascularized or non-vascularized, have been described as viable treatment options [14;22-24]. As a non-biologic reconstruction, endoprosthetic replacement of the proximal humerus with mega-implants has been described in several studies [2;8;9;12;16-20].

Endoprosthetic replacement of the proximal humerus

Cannon et al. recently published a series of 83 patients treated with endoprosthetic replacement for defects of the proximal humerus [12]. In all of these cases an intraarticular resection of the tumor was performed, with sparing of the deltoid muscle and axillary nerve. Mean shoulder flexion was 42° and abduction 41°, with a mean Musculoskeletal Tumor Society Score (MSTS) of 63%. Loosening of the implant was not observed, and the overall complication rate was low.

One hundred patients with endoprosthetic replacement of the proximal humerus were followed up by Kumar et al. [2]. The authors reported mean shoulder flexion of 55° and abduction of 45° in combination with a mean MSTS of 79%. The overall survival at 10 years was 42%, and the survival of the implant without further surgery for

mechanical failure was 86.5% at 20 years. In 9 patients an implant-related revision was necessary, and in 8 patients a forequarter amputation was performed.

Complications of endoprosthetic replacement of the proximal humerus

Divergent rates of complications and revision have been reported in further studies [2;8;12;16;17;19]. Revision rates of up to 67% [17] and complication rates of up to 72% [8] have been described. The complication rate in our study seems to be acceptable compared with the above-mentioned trials. In only one case aseptic loosening of an uncemented implant was observed. Therefore, we do not further use uncemented humeral stems. We did not observe any signs of loosening in cases with cemented stems. Hence, we routinely use this fixation technique for MUTARS shoulders in our institution.

Results with the MUTARS system

The use of MUTARS tumor endoprostheses in the lower limb is well documented [19;25-27]. To our knowledge, however, only a few studies have been published on the use of this modular system for the treatment of large bone defects of the proximal humerus [19;20]. Gosheger et al. reported endoprosthetic replacement in 250 patients with sarcoma [19]. Out of this cohort, 39 patients were treated with replacement of the proximal humerus. The 5-year survival of the endoprosthesis was 93.6%. The mean Enneking score was 21 points, and the authors stated that the MUTARS systems have some advantages over other endoprosthetic systems. They concluded that the use of a Trevira tube makes muscle and tendon refixation easier, resulting in a reduced dislocation rate and better functional results in the lower extremity. They did not describe if refixation of the rotator cuff using the Trevira tube leads to a better functional outcome in cases of replacement of the proximal

humerus. Overall, a high success rate and good functional results were stated. This system was also introduced by Gosheger et al. for a combined procedure with replacement of the proximal humerus and a trapezius--latissimus dorsi transfer [20].

The role of the rotator cuff and discussion of results

The clinical results of the current investigation seem to be comparable with those of the above-mentioned studies. The mean Enneking score of 19 points represents an overall good result for this procedure. The mean degree of pain after surgery was between no pain and non-disabling pain (Figure 2). Emotional acceptance after surgery was satisfying. The function of the affected limb was acceptable, although mean shoulder elevation was restricted to 33°. The shoulder motion results reported by Cannon et al. [12] and Kumar et al. [2] are superior to our findings. A possible reason for these divergent results is the degree of refixation of the rotator cuff and the degree of resection of the deltoid muscle and axillary nerve. We demonstrated that the degree of refixation of the rotator cuff to a Trevira tube has an influence on postoperative shoulder function (Figure 3). In other endoprosthesis systems, the sutures of the arched rotator cuffs can be fixated by special eyelets. We believe that a Trevira or Dacron tube [16] offers more advantages for refixation of tendons compared to eyelets because fibrous ingrowths of the tissue into the tube is possible. Moreover, the area for refixation of the tissue is much greater by using a tube. Using an eyelet, only a punctual refixation without ingrowths is possible.

The shoulder motion in patients with preserved rotator cuffs in the current study was comparable with the shoulder motion reported in the above-mentioned trials. Possibly, the use of a reversed tumor-implant for the proximal humerus could lead to better functional results in cases when the deltoid muscle and axillary nerve can be preserved.

Failed refixation of the rotator cuff and/or the deltoid muscle often leads to cranial migration of the humeral head. Cannon et al. found cranial migration of the prosthesis in 22 out of 76 patients with adequate postoperative radiographs. In our study this was encountered in 14 cases. However, refixation of the rotator cuff had been performed in only 8 of the 14 patients, and it seems that there is no strict coherence between cranial migration and refixation of the rotator cuff. Moreover, caudal migration of the prosthesis was found in three cases after resection of parts of the deltoid muscle and axillary nerve.

Hand function after endoprosthesis replacement of the proximal humerus

It has been reported that replacement of the proximal humerus provides an excellent platform for function of the elbow and the hand [12]. In this study all the patients had good elbow and hand function with very satisfying manual dexterity, and they were able to reach their mouth with the ipsilateral hand. In the current study, most operations were performed due to metastases. In this light the patient survival rate of 45% at 11.5 years appears acceptable, as does the local recurrence rate of 5%.

Implant survival

Survival of the implant was lower in our study than in other trials. Mayilvahanan et al. [18] and Kumar et al. [2] described survival rates of 83% and 87% after 10 years, respectively. Our finding of implant survival of 70% after 11.5 years may be explained by the different indications for surgery: a relatively high proportion of patients in the present study were treated because of a metastasis or pathological fracture of the proximal humerus.

Conclusion

In conclusion, reconstruction of the proximal humerus with the MUTARS system seems to be a viable treatment option after resection of bone tumors. Acceptable complication and survival rates of patients and implants were found, and most of the patients were satisfied with the procedure. Although the implant provides a good platform for elbow and hand function, shoulder function is severely restricted in most cases. Refixation of the rotator cuff to a Trevira tube is associated with better functional results. Most of the patients were nearly pain free.

ACCEPTED MANUSCRIPT

Conflict of interest statement

None of the authors has financial relationships with commercial companies with involved products in this study.

Role of the funding source

None of the authors received any kind of sponsorship or funds.

ACCEPTED MANUSCRIPT

Reference List

1. Hage WD, Aboulafia AJ, Aboulafia DM. Incidence, location, and diagnostic evaluation of metastatic bone disease. *Orthop Clin North Am* 2000;31:515-28, vii
2. Kumar D, Grimer RJ, Abudu A, Carter SR, Tillman RM. Endoprosthetic replacement of the proximal humerus. Long-term results. *J Bone Joint Surg Br* 2003;85:717-722
3. Gebhardt MC, Roth YF, Mankin HJ. Osteoarticular allografts for reconstruction in the proximal part of the humerus after excision of a musculoskeletal tumor. *J Bone Joint Surg Am* 1990;72:334-345
4. Jensen KL, Johnston JO. Proximal humeral reconstruction after excision of a primary sarcoma. *Clin Orthop Relat Res* 1995;164-175
5. Kocialkowski A, Wallace WA, Harvey L. Fate of frozen intercalary allograft at one year after implantation with adjuvant chemotherapy treatment. A case report. *Clin Orthop Relat Res* 1991;146-151
6. Mankin HJ, Gebhardt MC, Jennings LC, Springfield DS, Tomford WW. Long-term results of allograft replacement in the management of bone tumors. *Clin Orthop Relat Res* 1996;86-97
7. Rodl RW, Gosheger G, Gebert C, Lindner N, Ozaki T, Winkelmann W. Reconstruction of the proximal humerus after wide resection of tumours. *J Bone Joint Surg Br* 2002;84:1004-1008

8. Ross AC, Wilson JN, Scales JT. Endoprosthetic replacement of the proximal humerus. *J Bone Joint Surg Br* 1987;69:656-661
9. Malawer MM, Chou LB. Prosthetic survival and clinical results with use of large-segment replacements in the treatment of high-grade bone sarcomas. *J Bone Joint Surg Am* 1995;77:1154-1165
10. Simon MA, Aschliman MA, Thomas N, Mankin HJ. Limb-salvage treatment versus amputation for osteosarcoma of the distal end of the femur. *J Bone Joint Surg Am* 1986;68:1331-1337
11. Springfield DS, Schmidt R, Graham-Pole J, Marcus RB, Jr., Spanier SS, Enneking WF. Surgical treatment for osteosarcoma. *J Bone Joint Surg Am* 1988;70:1124-1130
12. Cannon CP, Paralicci GU, Lin PP, Lewis VO, Yasko AW. Functional outcome following endoprosthetic reconstruction of the proximal humerus. *J Shoulder Elbow Surg* 2009;
13. Black AW, Szabo RM, Titelman RM. Treatment of malignant tumors of the proximal humerus with allograft-prosthesis composite reconstruction. *J Shoulder Elbow Surg* 2007;16:525-533
14. Wada T, Usui M, Isu K, Yamawakii S, Ishii S. Reconstruction and limb salvage after resection for malignant bone tumour of the proximal humerus. A sling procedure using a free vascularised fibular graft. *J Bone Joint Surg Br* 1999;81:808-813

15. Wittig JC, Bickels J, Kellar-Graney KL, Kim FH, Malawer MM. Osteosarcoma of the proximal humerus: long-term results with limb-sparing surgery. *Clin Orthop Relat Res* 2002;156-176
16. Asavamongkolkul A, Eckardt JJ, Eilber FR, et al. Endoprosthetic reconstruction for malignant upper extremity tumors. *Clin Orthop Relat Res* 1999;207-220
17. Bos G, Sim F, Pritchard D, et al. Prosthetic replacement of the proximal humerus. *Clin Orthop Relat Res* 1987;178-191
18. Mayilvahanan N, Paraskumar M, Sivaseelam A, Natarajan S. Custom mega-prosthetic replacement for proximal humeral tumours. *Int Orthop* 2006;30:158-162
19. Gosheger G, Gebert C, Ahrens H, Streitbueger A, Winkelmann W, Harges J. Endoprosthetic reconstruction in 250 patients with sarcoma. *Clin Orthop Relat Res* 2006;450:164-171
20. Gosheger G, Harges J, Ahrens H, Gebert C, Winkelmann W. Endoprosthetic replacement of the humerus combined with trapezius and latissimus dorsi transfer: a report of three patients. *Arch Orthop Trauma Surg* 2005;125:62-65
21. Enneking WF, Dunham W, Gebhardt MC, Malawar M, Pritchard DJ. A system for the functional evaluation of reconstructive procedures after surgical treatment of tumors of the musculoskeletal system. *Clin Orthop Relat Res* 1993;241-246

22. Enneking WF, Eady JL, Burchardt H. Autogenous cortical bone grafts in the reconstruction of segmental skeletal defects. *J Bone Joint Surg Am* 1980;62:1039-1058
23. Getty PJ, Peabody TD. Complications and functional outcomes of reconstruction with an osteoarticular allograft after intra-articular resection of the proximal aspect of the humerus. *J Bone Joint Surg Am* 1999;81:1138-1146
24. Rodl RW, Ozaki T, Hoffmann C, Bottner F, Lindner N, Winkelmann W. Osteoarticular allograft in surgery for high-grade malignant tumours of bone. *J Bone Joint Surg Br* 2000;82:1006-1010
25. Bruns J, Delling G, Gruber H, Lohmann CH, Habermann CR. Cementless fixation of megaprotheses using a conical fluted stem in the treatment of bone tumours. *J Bone Joint Surg Br* 2007;89:1084-1087
26. Heisel C, Kinkel S, Bernd L, Ewerbeck V. Megaprotheses for the treatment of malignant bone tumours of the lower limbs. *Int Orthop* 2006;30:452-457
27. Witte D, Bernd L, Bruns J, et al. Limb-salvage reconstruction with MUTARS((R)) hemipelvic endoprosthesis: A prospective multicenter study. *Eur J Surg Oncol* 2009;

Legends:

Fig. 1: Radiograph of a 35-year-old man 2 years after resection of a chondrosarcoma and treatment with a cementless replacement of the proximal humerus using a MUTARS endoprosthesis.

Fig. 2: The graph is showing the results (points) of the Enneking score and its subgroups of the examined patients compared to the maximal reachable points (means with standard deviations).

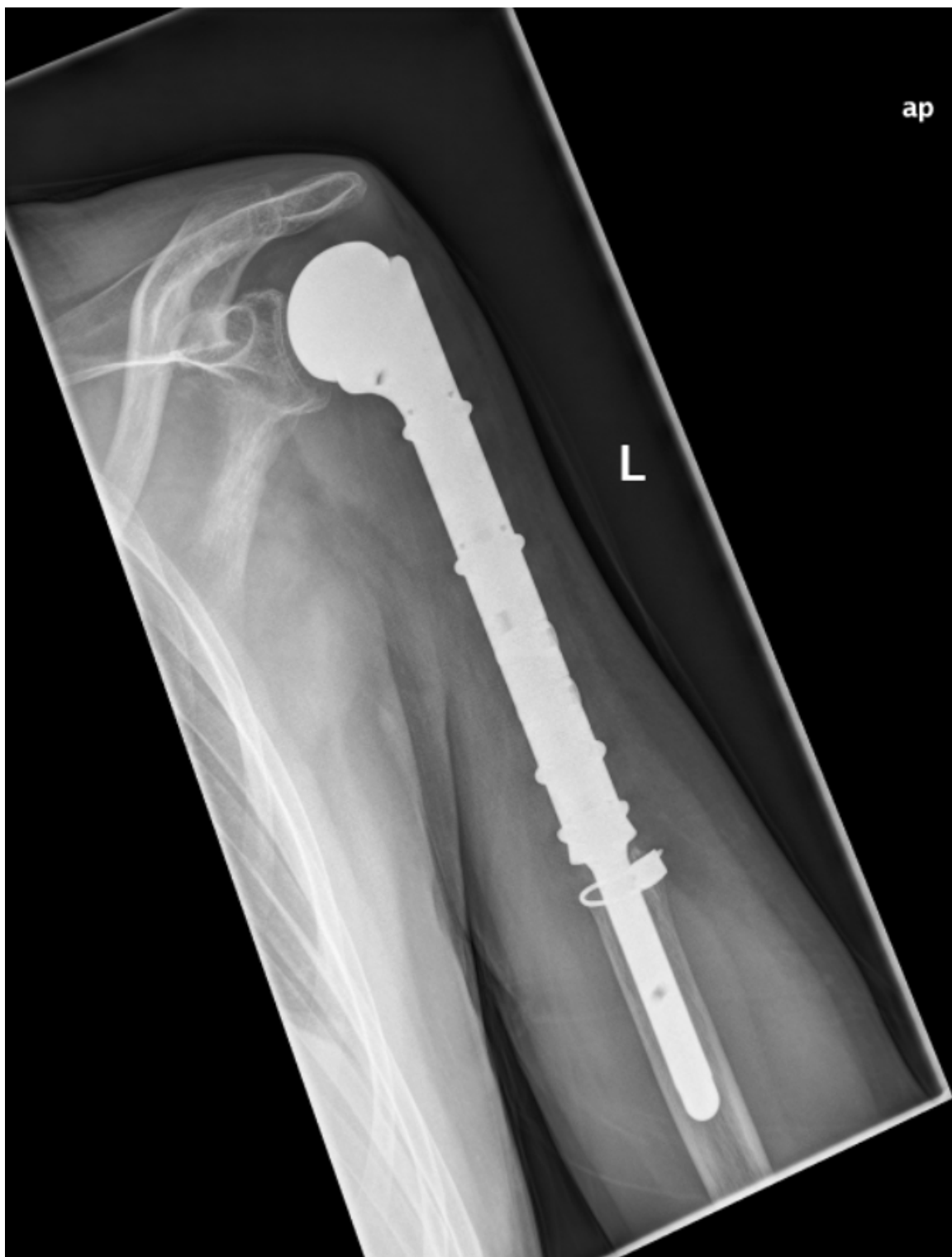Fig. 3: The graph is showing the normal Range of Motion (ROM) of the shoulder for flexion, abduction and external rotation compared to patients with complete, partial and failed refixation of the rotator cuff (means with standard deviations).

Fig. 4: Kaplan--Meier curve showing overall patient survival.

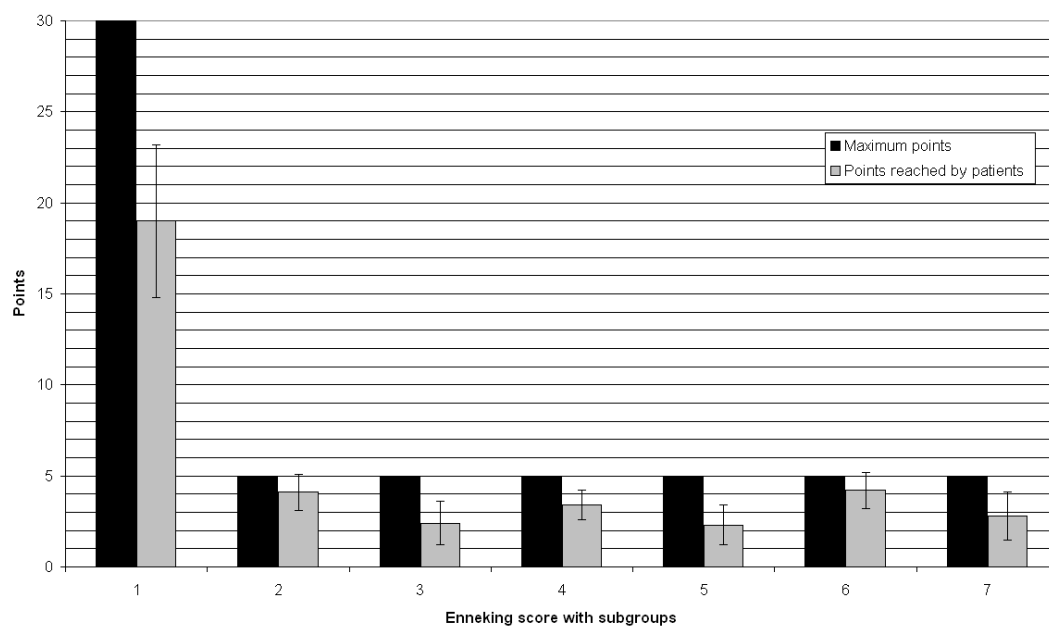
Fig. 5: Kaplan--Meier curve showing implant survival without further surgery.

Table 1: Early and late complications with imaging results and treatments

| Time | Complications | Imaging results | Treatment |
|----------------------------------|-------------------------------------|---|---|
| Early (< 3 months after surgery) | Dislocation (n=4) | Anterior dislocation (n=3) Posterior dislocation (n=1) | Conservative (n=2) Re-operation with changing the retroversion |
| | Intraoperative shaft fracture (n=1) | Fracture of the humeral shaft | Osteosynthesis |
| Late (>3 months after surgery) | Infection (n=2) | Correct positioning of the implants, no signs for loosening | Removal of the implant (n=2), re-implantation (n=1) |
| | Aseptic loosening (n=1) | Loosened cementless stem | Removal of the implant, autologous fibula graft |

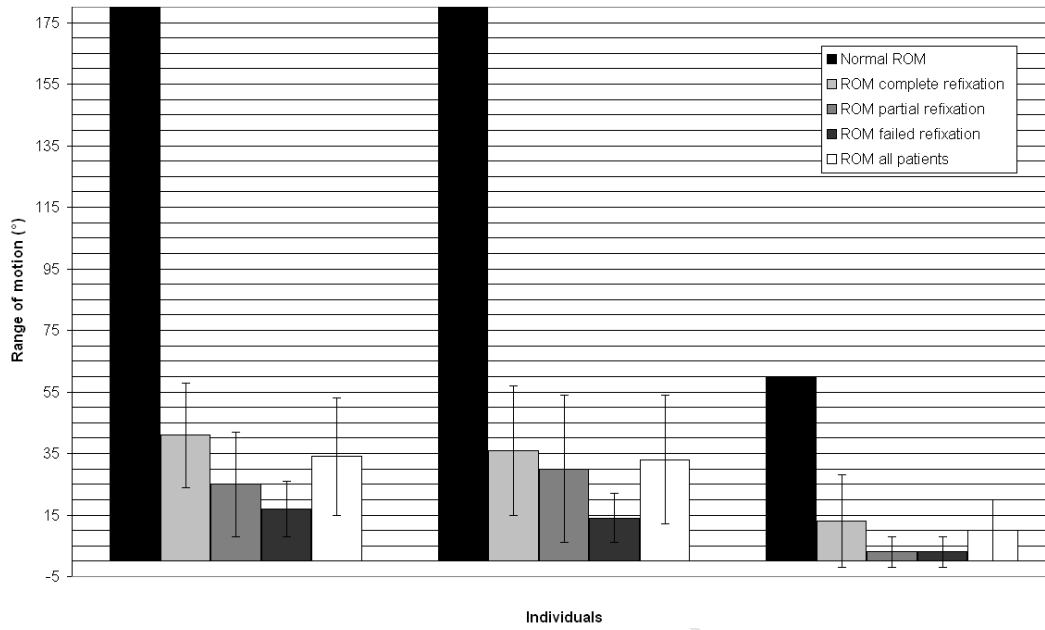


Results of the Enneking score



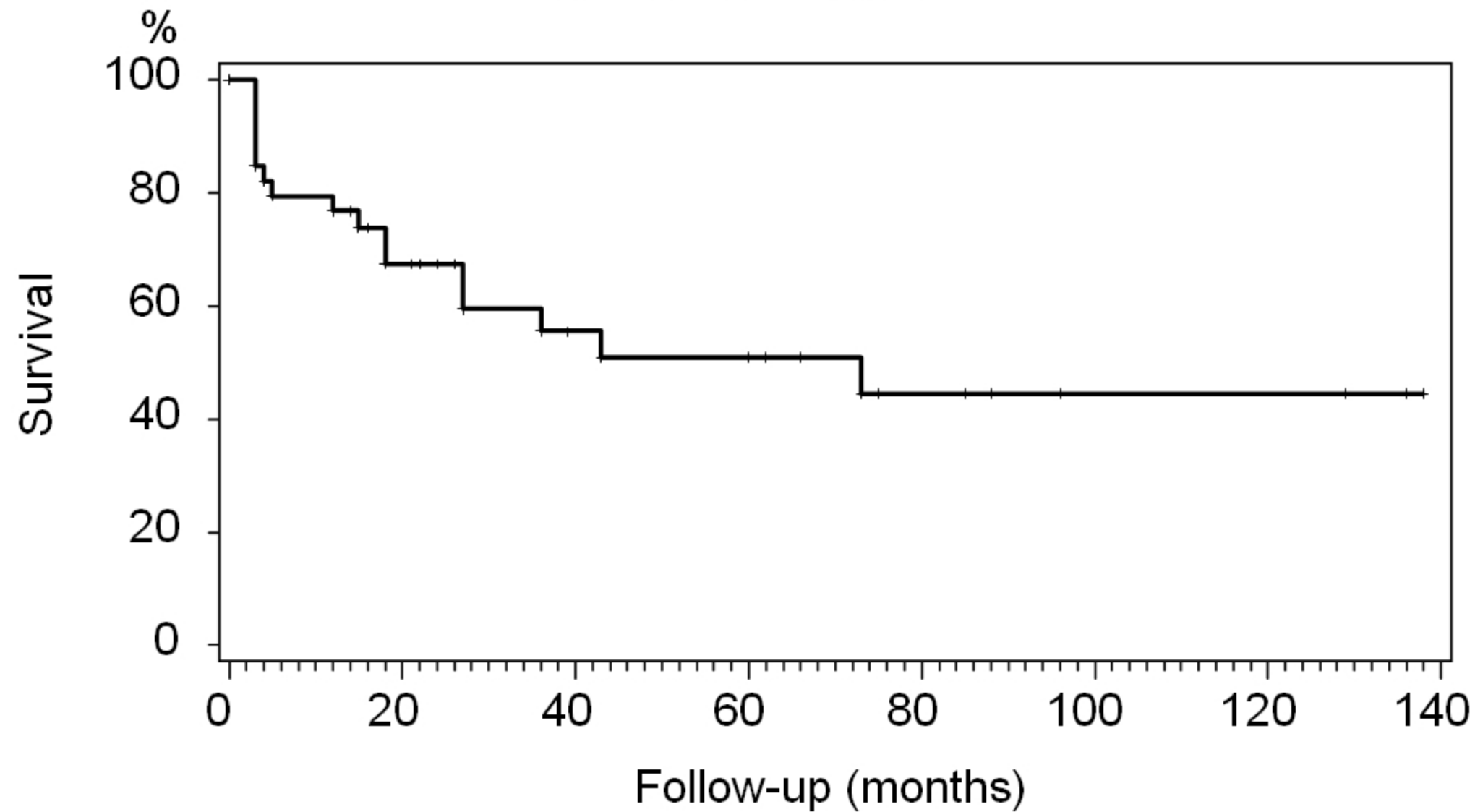
ACCEPTED MANUSCRIPT

Range of motion of the shoulder



ACCEPTED MANUSCRIPT

Survival of patients



Implant survival without further surgery

