



**HAL**  
open science

## An electrophysiological study on the safety of the endoscope-assisted microsurgical removal of vestibular schwannomas

V.M. Gerganov, M. Giordano, C. Herold, A. Samii, M. Samii

► **To cite this version:**

V.M. Gerganov, M. Giordano, C. Herold, A. Samii, M. Samii. An electrophysiological study on the safety of the endoscope-assisted microsurgical removal of vestibular schwannomas. *EJSO - European Journal of Surgical Oncology*, 2010, 36 (4), pp.422. 10.1016/j.ejso.2009.11.003 . hal-00576168

**HAL Id: hal-00576168**

**<https://hal.science/hal-00576168>**

Submitted on 13 Mar 2011


**HAL** is a multi-disciplinary open access archive for the deposit and dissemination of scientific research documents, whether they are published or not. The documents may come from teaching and research institutions in France or abroad, or from public or private research centers.

L'archive ouverte pluridisciplinaire **HAL**, est destinée au dépôt et à la diffusion de documents scientifiques de niveau recherche, publiés ou non, émanant des établissements d'enseignement et de recherche français ou étrangers, des laboratoires publics ou privés.

# Accepted Manuscript

Title: An electrophysiological study on the safety of the endoscope-assisted microsurgical removal of vestibular schwannomas

Authors: V.M. Gerganov, M. Giordano, C. Herold, A. Samii, M. Samii



PII: S0748-7983(09)00511-3

DOI: [10.1016/j.ejso.2009.11.003](https://doi.org/10.1016/j.ejso.2009.11.003)

Reference: YEJSO 2914

To appear in: *European Journal of Surgical Oncology*

Received Date: 6 October 2009

Revised Date: 4 November 2009

Accepted Date: 9 November 2009

Please cite this article as: Gerganov VM, Giordano M, Herold C, Samii A, Samii M. An electrophysiological study on the safety of the endoscope-assisted microsurgical removal of vestibular schwannomas, *European Journal of Surgical Oncology* (2009), doi: 10.1016/j.ejso.2009.11.003

This is a PDF file of an unedited manuscript that has been accepted for publication. As a service to our customers we are providing this early version of the manuscript. The manuscript will undergo copyediting, typesetting, and review of the resulting proof before it is published in its final form. Please note that during the production process errors may be discovered which could affect the content, and all legal disclaimers that apply to the journal pertain.

**An electrophysiological study on the safety of the endoscope-assisted  
microsurgical removal of vestibular schwannomas**

**Authors:**

- *Gerganov, VM*, MD, PhD; International Neuroscience Institute, Rudolf Pichlmayr Str. 4, Hannover 30625, Germany; [vgerganov@gmail.com](mailto:vgerganov@gmail.com)
- *Giordano, M*, MD; International Neuroscience Institute, Rudolf Pichlmayr Str. 4, Hannover 30625, Germany; [giordano@ini-hannover.de](mailto:giordano@ini-hannover.de)
- *Herold, C*, MD; International Neuroscience Institute, Rudolf Pichlmayr Str. 4, Hannover 30625, Germany; [herold@ini-hannover.de](mailto:herold@ini-hannover.de)
- *Samii, A*, MD, PhD; Prof; International Neuroscience Institute, Rudolf Pichlmayr Str. 4, Hannover 30625, Germany; [asamii@ini-hannover.de](mailto:asamii@ini-hannover.de)
- *Samii, M*, MD, PhD; Prof; International Neuroscience Institute, Rudolf Pichlmayr Str. 4, Hannover 30625, Germany; [samii@ini-hannover.de](mailto:samii@ini-hannover.de)

**Corresponding Author:**

Venelin M. Gerganov, MD, PhD

Address: International Neuroscience Institute- Hannover, Rudolf Pichlmayr Str. 4, Hannover 30625, Germany

Phone: ++49 (511) 27092835

Fax: ++49 (511) 27092706

Email: [vgerganov@gmail.com](mailto:vgerganov@gmail.com)

**Abstract**

*Background*

Endoscopy is being increasingly used in skull base surgery. The issue of its safety, however, has not been definitely solved.

### *Methods*

We evaluated the risk of thermal or mechanical iatrogenic nerve injury related to endoscope application during microsurgical removal of vestibular schwannomas (VS) in a prospective group of 30 patients (Group A). Main analysed parameters were electrophysiological monitoring data (auditory evoked potentials and EMG) during and after endoscopic observation. The structural and functional preservation of facial and cochlear nerves, radicality of tumour removal, and CSF leak rate were evaluated and compared to historical group of 50 patients (Group B), operated consecutively with classical microsurgical technique.

### *Results*

No electrophysiological changes directly related to endoscope were registered. The rate of loss of waves I, II, and V did not depend on application of endoscope and was similar in both groups. The functional and general outcome was also similar. Endoscopic inspection provided early and detailed view of anatomical relations within cerebellopontine angle and internal auditory canal and confirmed completeness of tumour removal. Total tumour removal was achieved in all patients from Group A and in 49/50 from Group B. Useful hearing after the surgery had 17/30 patients in Group A and 26/50 in Group B.

### *Conclusions*

The application of endoscope during microsurgical removal of VS is a safe procedure that does not lead to heat-related or mechanical neural or vascular injuries. The actual significance of this additional endoscopic information, however, is related to the particular operative technique and experience of the surgeon.

**Keywords:** Vestibular schwannoma, endoscope - assisted microsurgery, retrosigmoid approach, intraoperative electrophysiological monitoring

The endoscope is an established component of contemporary brain tumour surgery armamentarium. Its application in various skull base procedures, either as a sole visualizing tool or as an adjunct to the microscope, is constantly expanding [1]. The endoscope provides superior illumination and magnification, as well as possibility “to look around the corner”, thus allowing for more radical but safe surgeries [2]. The endoscope-assisted microsurgery (EAM) combines the advantages of both the classical microneurosurgery and endoscopy. Its application in case of lesions located in cerebellopontine angle (CPA), offers the possibility to identify at an early stage various structures and their relations, as well as to look for hidden tumour parts [3]. In case of vestibular schwannomas (VS) the whole internal auditory canal (IAC) up to its fundus can be inspected without increasing the risk of violation to the bony labyrinth; thus tumour remnants or opened air cells are readily visualized [4-8].

The issue of the safety of the endoscopic technique, however, has not been definitely solved. When inserting the endoscope through the complex lattice of nerves and vessels in the CPA, a risk of mechanical injury exists [9]. The close observation of vulnerable structures, such as cranial nerves or tiny vessels, exposes them to a potential risk of thermal injury from the heat generated by the light of the endoscope. Although a general awareness of these risks exists [4,8,10,11], their clinical significance has not been addressed systematically. The goal of the current study was to evaluate the safety of the EAM technique and the outcome after its application in a prospective series of patients with VS.

### **Methods and patients**

A prospective study was performed that included 30 patients with VS operated via the retrosigmoid approach with the EAM technique. The inclusion criteria were: presence of unilateral sporadic vestibular schwannomas, age above 20 years, primary surgery, normal facial nerve function, and presence of functional hearing on the involved side preoperatively. Patients with neurofibromatosis type 2, previous surgical or radiosurgical treatment, previous infectious diseases of the brain, facial palsy and/or severe hearing loss, have been excluded. The Hannover VS extension classification system was applied [12]. Facial nerve function was assessed using the House–Brackmann grading system [13]. Hearing was graded according to the New Hannover Classification. Hearing Classes H1 to H2 with pure tone average of up to 40 dB and speech discrimination score more than 70%, were accepted as functional hearing levels [14].

The evaluated parameters were: structural and functional preservation of the facial and cochlear nerves, the data from the electrophysiological monitoring, radicality of tumour removal, and CSF leak rate. The results in this group (Group A) have been compared to a historical group of 50 patients, operated consecutively with the classical microsurgical technique, that corresponded to the inclusion criteria of the current study (Group B).

*Operative technique:* in all cases the retrosigmoid approach was used with the patient in semi-sitting position. The details of the technique have been discussed in detail previously and only the main steps are highlighted here [12,15]. The goal of surgery has always been to achieve complete tumour removal but preservation of all neurological functions had a priority. A retrosigmoid craniotomy has been performed exposing the edges of the transverse and sigmoid sinuses. A slightly curved dural incision along the sinuses has been done and the lateral cerebellomedullary cistern was opened to allow sufficient egress of CSF. Thus, a minimal brain retraction was necessary. The intrameatal tumour portion was approached initially by removing the posterior wall of the IAC. The dissection of the tumour from cranial nerves and other neural structures was performed only after sufficient tumour debulking. The tumour was dissected from surrounding neural and vascular structures by gripping the tumour capsule only and dissecting it in the level of the arachnoid plane. After the removal of the tumour, multiple fat pieces have been used to plug the drilled IAC and were sealed with fibrin glue.

*Neurophysiological monitoring:* continuous electrophysiological monitoring using a commercially available hardware and software (Endeavor CR intraoperative monitor; VIASYS Healthcare, Nicolet Biomedical, Madison, WI) provided feedback regarding the functional integrity of the facial and cochlear nerves [14,15]. The cochlear nerve function was assessed with brainstem auditory evoked potentials (BAEP): the needle electrodes were placed anteriorly to the tragus on both sides for registering of the potentials. The acoustic stimulation was done by generating alternate click noises, transferred with tubal insert phones (300-V stimulators) for intraaural stimulation. On the tumour side 100-dB normal hearing level stimulus and a 70-dB normal hearing level noise on the other side were applied (100-msec stimulus duration and 0.01-Hz stimulus frequency). Input characteristics for acquiring evoked potentials were: 10,000 amplification rate, 1000 averaged sweeps, 150-Hz to 1.5-kHz filter, 0.2-mV sensitivity, and 10-msec duration of signal acquisition. The BAEP findings were classified according to Nordstadt's ABR typing system, consisting of Types B1 through

B5, which are determined by the presence of waves I to V, their amplitude and latency [16]. The facial nerve function was monitored with EMG recordings of the orbicularis oris and oculi muscles and the input characteristics for acquiring the EMG signals were: 5000 amplification rate, 10-Hz to 1.5-kHz filter, 50-mV sensitivity, and 2-second duration of signal acquisition.

*Endoscopic observation:* A rigid rod-lens endoscope with an outer diameter of 2 mm and length of 26 cm with lens degree of 0 and 30° have been used (Karl Storz GmbH, Tuttlingen, Germany). They have been introduced in the CPA at different stages of VS dissection and removal for inspection of the relations of the tumour to surrounding neurovascular structures and for identification of cranial nerves and vessels. The endoscope was introduced freehand under microscopic visual control (Fig.1). After tumour removal, the lateral end of IAC has been inspected in order to look for residual tumour parts and/or opened mastoid air cells. The effect of this procedure on the facial and cochlear nerves was assessed by observing the EMG and BAEP data during the entire procedure with a special attention during the introduction of the endoscope and the endoscopic observation.

#### *Statistical analysis*

The  $\chi^2$  test and Fisher's exact test were used to compare the outcome in both groups and a difference of  $P < 0.05$  was accepted as significant.

## **Results**

The mean age of the patients was 47.4 years (range 21-68 years) in Group A and 45.6 years (range 18-72) in Group B. Both groups had similar clinical presentation that included most frequently hearing loss, tinnitus, vertigo, dizziness, or unstable gait. The mean tumour size in Group A was 2.0 cm and in Group B – 2.2 cm. Tumour extension data are presented on Table 1. The mean follow up period for Group A was 28 months (range 12-42 months) and for Group B – 32 months (range 8-56 months).

Total tumour removal was achieved in all patients from Group A and in 49/50 patients from Group B. In 1 patient from Group B the lesion was tightly adherent to the nerve, and the

attempt to dissect the nerve from the tumour capsule led to intense changes of the EMG. In this case a deliberate subtotal tumour removal was performed.

Anatomical preservation of the facial nerve was possible in all patients from Group A and in 49/50 patients from Group B (Table 2). In 1 patient with large VS (Grade 4B) the facial nerve was extremely atrophic and its integrity could not be preserved. Three weeks later a hypoglosso-facial anastomosis was performed in order to reconstruct the function of the facial nerve. Seventeen patients from Group A had useful hearing after the surgery (56.7%); in Group B 26 patients (52%) had preserved hearing. One patient from Group A and 2 patients from the second group had transient caudal nerve dysfunction (swallowing difficulty) that resolved completely in the early postoperative period and did not cause additional morbidity. A CSF leak was diagnosed in 1 patient from Group A and 2 patients from Group B. In all these cases it was managed successfully by a lumbar drainage insertion.

The evaluation of the electrophysiological data did not demonstrate any changes directly related to the application of the endoscope. The wave I was lost permanently in one case and temporary in 6 cases in Group A and in 2 and 12 cases, respectively, in Group B. Wave III was lost permanently in 2 and transiently in 7 cases in Group A and in 3 and 13 cases, respectively, in Group B. Wave V was lost in 6 cases of microsurgical actions in Group A and in 11 cases in Group B. The reason for loss of waves was most frequently pulling of the nerves during tumour dissection and drilling of the IAC.

The inspection with the E provided clear and detailed view of the anatomical relations within the CPA and in the IAC, up to its fundus (Fig.2,3). The inspection after microscopically confirmed complete tumour removal did not detect tumour remnants. Opened air cells in the IAC, not directly visible with the microscope, have been found in 5 patients. There were no mechanical injuries during the introduction of the E, its manipulation close to the neural structures or its removal. The application of the endoscope added 15 to 20 minute to the standard operative time.

## **Discussion**

### *Application of endoscopy during VS surgery*

The first reported use of an endoscope for the inspection of the CPA was done by Doyen in 1917 [17]. Later on, Prott and Opel described in detail the endoscopy of the CPA [18,19]. In the last two decades the endoscope became an integral part of the skull base surgery



armamentarium. It increases the light intensity while approaching an object, permits a clear depiction of details in close-up positions and extends the viewing angle [20]. In CPA surgery, it is used to identify important anatomic structures and their relations to the tumour. The early identification of the brainstem and neurovascular structures in case of large tumours may be important in order to plan the subsequent surgical steps [21]. In case of smaller VS, the relationship between the tumour and facial and cochlear nerves within the IAC can be assessed [4,6,9]. The safe opening of the posterior wall of the IAC may be limited by the posterior semicircular canal and the inner ear. In such cases the endoscopic inspection allows for assessment of the completeness of tumour removal, especially the existence of tumour remnants in the most lateral part of the IAC [22]. The remnant could be removed under endoscopic or microscopic control [3,5,9]. Although in our series we did not find such remnants, some authors report a rate of up to 17.6% [3,8]. The endoscopic inspection after tumour removal allows for identification of opened air cells that have to be occluded in order to prevent CSF leaks. Some authors report that thus the risk of CSF leakage has been lowered or even completely avoided [3,8,10] Our technique for occlusion of the opened IAC is to plug the IAC with multiple small fat pieces, sealed with fibrin glue. It is preformed in all cases and does not rely on the visualization of opened air cells.

The published data showed that the endoscopic inspection during the removal of VS may help reduce the complication rates and avoid remnants. The actual significance of this additional information, however, is related to the particular operative technique and experience of the surgeon. In our series, applying the technical nuances described above, it is of relative value and is used as a method to confirm the completeness of tumor removal.

The application of endoscope, however, is related to some risk of iatrogenic neural or vascular injuries. The introduction and manipulation of the endoscope in the anatomically highly complex CPA is difficult and may lead to mechanical injury [9]. The lack of three-dimensional vision does not allow estimating accurately the real distance between the tip of the endoscope and the visualized structures. Further, the surgeon does not have an overview of the entire CPA – only the area at the tip of the endoscope is seen. In one case, reported by Hori et al [11], the facial nerve was mechanically damaged by the endoscope itself, which necessitated its direct suturing. In order to avoid such complications, we always introduce the endoscope under microscopic control. Only when the endoscope is placed in the planned position, is the microscope withdrawn. With this technique we did not register any mechanical endoscope-related complications.

The issue of potential thermal injury caused by the heat generated by the light source of endoscopes has been mentioned by several authors [3,5,10]. This effect in laboratory settings has been studied by Hori et al, who performed a thermographic study [11]. The authors found that the endoscopic observation in the CPA did not lead to significant changes of the local temperature. Contrary to that, during drilling of the IAC a prominent increase of the local temperature was registered.

#### *Intraoperative electrophysiological monitoring*

The intraoperative monitoring of facial and cochlear nerves function is an essential part of each VS removal and has contributed significantly to the improved functional outcome of such surgeries. The intraoperative monitoring of BAEP, first description by Sohmer in 1967 [23], is a highly sensitive method for evaluation of the cochlear nerve and provides a continuous, almost real-time, feedback information on its functional status [16,18]. Further, a loss of a component may predict the risk of hearing loss, e.g. the loss of wave V is the sign most often associated with a following deafness. It has been shown that the presence of waves I, III and V, their amplitude and latency, correlate to certain microsurgical actions, which directly (such as pulling of the nerves during the tumour dissection) or indirectly (such as drilling of the IAC) affect the nerve. Therefore, in the current study we used this technique for assessment of the effect of the heat generated by the light source of the endoscope. Our hypothesis was that if such deleterious influence existed, it should lead to changes of the BAEP trace. Importantly, the groups of patients operated with or without E control, were highly homogeneous in regard to the characteristics of the VS. They have been all operated by a single neurosurgeon (MS) and the operative technique, applied in all cases, was identical. Further, patients with neurofibromatosis type 2, previous surgical or radiosurgical treatment, previous infectious diseases of the brain, facial palsy and/or severe hearing loss, have been excluded. These inclusion criteria allowed us to exclude other variables that could affect the electrophysiological data or influence the outcome.

#### *Electrophysiological monitoring during endoscope application*

The evaluation of our data demonstrated that the risk for loss of waves I, II, and V, both transiently or permanently, did not depend on the application of E and was similar in both patient groups. These rates were not higher than the reported in a previous series of 201

patients, operated by the same surgeon [16]. Contrary to our findings, King et al [10] observed reversible intraoperative changes of the BAEP during endoscopic observation. However, in those cases it is difficult to exclude the influence of other coexisting factors. The application of endoscopic did not influence the rate of useful hearing preservation: it was preserved in 17/30 patients from Group A and in 26/50 of those from Group B. Further, it did not lead to any EMG abnormalities and influence the facial nerve function after the surgery.

### **Conclusion**

The application of endoscope during microsurgical removal of VS is a safe procedure that does not lead to heat-related or mechanical neural or vascular injuries. It allows for early identification of neural structures and confirms the completeness of tumour resection. The actual significance of this additional information in regards to functional outcome, radicality of surgery and complication avoidance, however, is related to the particular operative technique and experience of the surgeon.

### References:

1. Monfared A, Agrawal S, Jackler RK. Cranial base approaches to inaccessible intracranial tumours. *Curr Opin Neurol* 2007;20:726-31
2. Perneczky A, Fries G. Endoscope-assisted brain surgery: part 1--evolution, basic concept, and current technique. *Neurosurgery* 1998;42:219-24
3. Wackym PA, King WA, Meyer GA, Poe DS. Endoscopy in neuro-otologic surgery. *Otolaryngol Clin North Am* 2002;35:297-323
4. Goksu N, Bayazit Y, Kemaloglu Y. Endoscopy of the posterior fossa and dissection of acoustic neuroma. *J Neurosurg* 1999;91: 776-80
5. Göksu N, Yilmaz M, Bayramoglu I, Aydil U, Bayazit YA. Evaluation of the results of endoscope-assisted acoustic neuroma surgery through posterior fossa approach. *ORL J Otorhinolaryngol Relat Spec* 2005;67:87-91
6. McKennan KX. Endoscopy at the internal auditory canal during hearing conservation acoustic tumour surgery. *Am J Otol* 1993;14:259-62

7. Valtonen HJ, Poe DS, Heilman CB, Tarlov EC. Endoscopically assisted prevention of cerebrospinal fluid leak in suboccipital acoustic neuroma surgery. *Am J Otol* 1997;18:381-5
8. Wackym PA, King WA, Poe DS, Meyer GA, Ojemann RG, Barker FG, Walsh PR, Staecker H. Adjunctive use of endoscopy during acoustic neuroma surgery. *Laryngoscope* 1999;109:1193-201
9. Miyazaki H, Deveze A, Magnan J. Neuro-otologic surgery through minimally invasive retrosigmoid approach: endoscope assisted microvascular decompression, vestibular neurectomy, and tumour removal. *Laryngoscope* 2005;115:1612-7
10. King WA, Wackym PA. Endoscope assisted Surgery for acoustic neuromas (Vestibular Schwannomas): early experience using the rigid hopkins telescope. *Neurosurgery* 1999;44:1095-102
11. Hori T, Okada Y, Maruyama T, Chernov M, Attia W. Endoscope-controlled removal of intrameatal vestibular schwannomas. *Minim Invasive Neurosurg* 2006;49:25-9
12. Samii M, Matthies C. Management of 1000 vestibular schwannomas (acoustic neuromas): surgical management and results with an emphasis on complications and how to avoid them. *Neurosurgery*. 1997;40:11-21
13. House JW, Brackmann DE: Facial nerve grading system. *Otolaryngol Head Neck Surg* 93:146–147, 1985
14. Samii M, Matthies C. Management of 1000 vestibular schwannomas (acoustic neuromas): hearing function in 1000 tumour resections. *Neurosurgery* 1997;40:248-60
15. Samii M, Gerganov V, Samii A. Improved preservation of hearing and facial nerve function in vestibular schwannoma surgery via the retrosigmoid approach in a series of 200 patients. *J Neurosurg* 2006;105:527–35
16. Matthies C, Samii M. Management of vestibular schwannomas (acoustic neuromas): The value of neurophysiology for diagnosis and prediction of auditory function in 400 cases. *Neurosurgery* 1997;40:459-66
17. Doyen E. *Surgical Therapeutics and Operative Techniques*. London: Balliere, Tindall and Cox, 1917;1:599-602
18. Nakamura M, Roser F, Dormiani M, Samii M, Matthies C. Intraoperative auditory brainstem responses in patients with cerebellopontine angle meningiomas involving the inner auditory canal: analysis of the predictive value of the responses. *J Neurosurg* 2005;102:637-42.
19. Oppel F. Endoscopy of the cerebello-pontine angle: its diagnostic and therapeutic possibilities. In: *Advances in Neurosurgery*, vol.5. Berlin: Springer, 1978:269-75.
20. Fries G., Perneczky A. Endoscope- assisted brain surgery: Part 2- Analysis of 380 procedures. *Neurosurgery* 1998; 42:226-232
21. Gerganov VM, Romansky KV, Bussarsky VA, Noutchev LT, Iliev IN. Endoscope–assisted microsurgery of large vestibular schwannomas. *Minim Invas Neurosurg* 2005; 48: 39-43

22. Tatagiba M., Matthies C., Samii M. Microendoscopy of the internal auditory canal in vestibular schwannoma surgery. *Neurosurgery* 1996;38:737- 740
23. Sohmer H, Feinmesser M. Cochlear action potentials recorded from the external ear in man. *Ann Otol Rhinol Laryngol* 1967;76: 427–35

### **Conflict of interest statement**

VM Gerganov received the International Fellowship for Neuroendoscopy from the company Karl Storz (2006-2007).

The senior authors of the manuscript (AS and MS) have personal relationships with the company Karl Storz.

### **Text to the figures:**

Fig.1. Microscopic view of the position of the endoscope shaft (E) in the CPA. The facial (\*) and the cochlear (\*\*) cranial nerves are seen in both their cisternal and intracanalicular segments. IAC – internal auditory canal; F- fundus of the IAC; R – retractor, holding the cerebellar hemisphere.

Fig.2. Endoscopic view of the cerebellopontine angle (CPA) with the facial nerve (\*) and the cochlear nerves (\*\*). P- porus of the IAC.

Fig.3. Endoscopic view of the whole internal auditory canal (IAC), from the porus (P) up to its fundus (F). (\*- facial nerve; \*\*- cochlear nerve).

**Conflict of interest statement**

VM Gerganov received the International Fellowship for Neuroendoscopy from the company Karl Storz (2006-2007).

The senior authors of the manuscript (AS and MS) have personal relationships with the company Karl Storz.

ACCEPTED MANUSCRIPT

|                  | Group A,<br>n=30 | Group B,<br>n=50 |
|------------------|------------------|------------------|
| <i>Grade T1</i>  | 5                | 7                |
| <i>Grade T2</i>  | 4                | 10               |
| <i>Grade T3a</i> | 6                | 9                |
| <i>Grade T3b</i> | 8                | 11               |
| <i>Grade T4a</i> | 4                | 7                |
| <i>Grade T4b</i> | 3                | 6                |

Table 1. Distribution of the VS according to the Hannover VS extension classification.

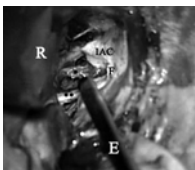ACCEPTED MANUSCRIPT

|  | Group A,<br>n=30 | Group B,<br>n=50 |
|--|------------------|------------------|
| Complete tumor removal                       | 30               | 49               |
| CSF leak                                     | 1                | 3                |
| Anatomical preservation of facial nerve      | 30               | 49               |
| Facial nerve function (early postoperative): |                  |                  |
| • HB I                                       | • 16             | • 26             |
| • HB II                                      | • 5              | • 7              |
| • HB III                                     | • 3              | • 7              |
| • HB IV                                      | • 3              | • 6              |
| • HB V                                       | • 2              | • 3              |
| • HB VI                                      | • 1              | • 1              |
| Hearing level:                               |                  |                  |
| • useful hearing                             | • 17             | • 26             |
| • not useful hearing                         | • 13             | • 24             |
| Caudal cranial nerves dysfunction            | 1*               | 1*               |

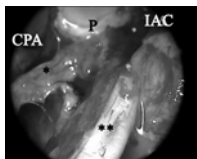
\* the caudal cranial nerve dysfunction was temporary in these cases and resolved completely in the early postoperative period.

Table 2. Functional outcome and complication rate in both patient groups. No statistically significant differences in the values were found.

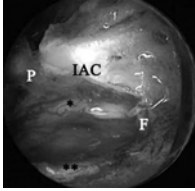




ACCEPTED MANUSCRIPT



ACCEPTED MANUSCRIPT



ACCEPTED MANUSCRIPT