



## Aggressive angiomyxoma: A case series and literature review

K. Haldar, I.E. Martinek, S. Kehoe

### ► To cite this version:

K. Haldar, I.E. Martinek, S. Kehoe. Aggressive angiomyxoma: A case series and literature review. *EJSO - European Journal of Surgical Oncology*, 2010, 36 (4), pp.335. 10.1016/j.ejso.2009.11.006 . hal-00576164

**HAL Id: hal-00576164**

**<https://hal.science/hal-00576164>**

Submitted on 13 Mar 2011

**HAL** is a multi-disciplinary open access archive for the deposit and dissemination of scientific research documents, whether they are published or not. The documents may come from teaching and research institutions in France or abroad, or from public or private research centers.

L'archive ouverte pluridisciplinaire **HAL**, est destinée au dépôt et à la diffusion de documents scientifiques de niveau recherche, publiés ou non, émanant des établissements d'enseignement et de recherche français ou étrangers, des laboratoires publics ou privés.

# Accepted Manuscript

Title: Aggressive angiomyxoma: A case series and literature review

Authors: K. Haldar, I.E. Martinek, S. Kehoe

PII: S0748-7983(09)00514-9

DOI: [10.1016/j.ejso.2009.11.006](https://doi.org/10.1016/j.ejso.2009.11.006)


Reference: YEJSO 2917

To appear in: *European Journal of Surgical Oncology*

Received Date: 3 August 2009

Revised Date: 7 November 2009

Accepted Date: 9 November 2009



Please cite this article as: Haldar K, Martinek IE, Kehoe S,. Aggressive angiomyxoma: A case series and literature review, *European Journal of Surgical Oncology* (2009), doi: 10.1016/j.ejso.2009.11.006

This is a PDF file of an unedited manuscript that has been accepted for publication. As a service to our customers we are providing this early version of the manuscript. The manuscript will undergo copyediting, typesetting, and review of the resulting proof before it is published in its final form. Please note that during the production process errors may be discovered which could affect the content, and all legal disclaimers that apply to the journal pertain.

**Aggressive angiomyxoma: A case series and literature review**

**Halder K** MRCOG (corresponding author)

Oxford Cancer Centre  
Department of Gynaecologic Oncology  
Churchill Hospital  
Old Road,  
Oxford OX3 7LJ  
United Kingdom

Phone +44 7533 508798

Fax +44 1865 35171

Email: [krishnayan\\_halder@yahoo.com](mailto:krishnayan_halder@yahoo.com)

**Martinek IE** MD

Oxford Cancer Centre  
Department of Gynaecologic Oncology  
Churchill Hospital  
Old Road, Oxford OX3 7LJ  
United Kingdom

Email: [igor.martinek@bluewin.ch](mailto:igor.martinek@bluewin.ch)

**Kehoe S** MD, FRCOG

Oxford Cancer Centre  
Department of Gynaecologic Oncology  
Churchill Hospital  
Old Road, Oxford OX3 7LJ  
United Kingdom

Email: [sean.kehoe@obs-gyn.ox.ac.uk](mailto:sean.kehoe@obs-gyn.ox.ac.uk)

**Acknowledgements**

We thank Dr. Sunanda Dhar, Consultant Gynaecological Pathologist, for her help.

## Abstract

**Background:** Aggressive angiomyxoma was identified as a distinct clinicopathologic entity in 1983 and since then fewer than 250 cases of these rare tumours have been reported in world literature. These tumours usually arise in the pelvis and perineal regions, most often in women of the reproductive age group; however a few cases of its occurrence outside the pelvis have also been reported.

**Patients and methods:** We report a series of 7 women treated in our institute in the last 8 years. Relevant literature on aggressive angiomyxoma was looked at and various management options reviewed.

**Conclusion:** Aggressive angiomyxomas are locally aggressive, notorious for local recurrence and extremely rare to metastasize. While surgery remains the mainstay of treatment, there has been a definite shift towards less radical forms of excision, over the years. Various adjuvant treatment modalities have also been tried to reduce tumour recurrence.

## Introduction

Aggressive angiomyxoma (AA) is a rare, locally aggressive myxoid mesenchymal neoplasm preferentially arising in the pelvic and perineal regions of young adult females, most commonly in the reproductive age group [1]. In men, the tumour involves analogous sites including the scrotum and inguinal area and usually appears at an older age [2]. AA was first described in 1983 [3] and since then less than 250 cases have been reported in literature, mostly in the form of small case series or isolated case reports. Though most of these tumours are locally aggressive occasional distant metastasis has also been reported [4, 5].

Diagnosis, more often than not, is at histological examination following surgical resection. Pre-operative diagnosis is difficult because of rarity of these tumours and lack of typical presenting signs and symptoms. The tumour is characterised by a soft, non-encapsulated mass with finger like projections into the adjacent soft tissue.

Surgery is usually the first line of treatment. Incomplete excision is common because of the infiltrating nature of the neoplasm and absence of a definite capsule. Local recurrence is common even after complete excision. Non-surgical interventions like hormonal manipulation, radiotherapy, arterial embolization etc. have been tried with variable success rates.

## **Patients and methods**

From 2002 – 2009, 11 women with aggressive angiomyxoma were managed in our institution. Seven of these cases were directly managed in our centre while the others were referred for expert opinion only. Among the seven, one interesting case of AA in a pregnant woman (case 1- table 1) has previously been reported separately [6]. We also performed a MEDLINE search from 1983 to July 2009 with the key words “aggressive” and “angiomyxoma” and reviewed relevant literature.

## Results

Table 1 summarizes the most relevant details for the 7 patients managed in our institution. In all but one case (case no 2), the diagnosis of AA was made only after initial surgery. The average age at diagnosis in our group of patients was just under 45 years (range 22 to 58 years), with an average disease free interval (DFI) of over 25 months. In 6 out of 7 cases histopathology confirmed involved resection margins. Five women had no recurrence following initial surgery. AA did not recur in the patient with clear margin. Case no 1 did respond well to GnRH-agonist therapy each time however recurred after discontinuation. Case no 2 was given GnRH-agonist as a neo-adjuvant treatment with the aim of tumour reduction but the treatment was unsatisfactory and the patient had to undergo surgery.

The MEDLINE search yielded 93 single case reports of this rare neoplasm in women if limited to the perineum and pelvis, and thirty-four of them in men. Ten cases of AA are reported in other parts of the body as well as two rare cases of lung metastases. A further 98 patients including both sexes are reported in series (n= 2 to 29 cases) bringing the whole number of cases reported in the literature to under 250 since the first description of AA in 1983.

## Discussion

Aggressive angiomyxomas are locally invasive connective tissue tumours presenting in about 90% of cases in women of reproductive age group with a peak incidence in the fourth decade of life [7]. The initial presentation varies from an asymptomatic perineal or vulval nodule/polyp or perineal hernia to a pelvic mass diagnosed on imaging studies. Occasionally, the tumour can be cystic and mistaken for a Bartholin's, labial or Gartner's duct cyst. They can exhibit a slow and insidious growth pattern and hence patients may be asymptomatic for long time until they become conscious of the significant size of the tumour. Tumour recurrences, like the primary ones, are often asymptomatic.

Pre-operative diagnosis is often a problem because of the rarity of these neoplasms and lack of typical features and most cases are diagnosed on histology after primary surgical excision. Accurate diagnosis before surgical excision is important in planning extent of excision and patient counseling.

### *Imaging characteristics of angiomyxomas*

Ultrasound is helpful in this regard and usually demonstrates a hypo echoic soft tissue mass that may even appear cystic. CT appearances are variable and include a well-defined homogenous mass hypo dense relative to muscle, a hypo attenuating solid mass with swirling internal pattern with contrast or a predominantly cystic appearing mass with solid components [8]. With MRI imaging an iso intense or less commonly hypo intense mass (compared to muscle) on T1 and hyper intense on T2 weighted images is characteristic. MRI imaging is accurate in detecting trans-levator spread and also is helpful in surgical planning by defining relation of the mass with anal sphincter, urethra, bladder and pelvic side-wall [8]. Recurrent tumor is also detected consistently in MRI scans and recurrent lesions have similar signal characteristics as that of primary tumor.

### *Histopathological findings*



Macroscopically these tumors often have a smooth surface, partially or completely encapsulated and cut surface gives a glistening, gelatinous appearance, bluish grey in color, with areas of hemorrhage and congestion. They are usually homogenous in consistency with no obvious nodularity [3].

Histologically they reveal a hypo cellular mesenchymal lesion consisting of a sparse population of bland spindled and stellate cells scattered in a background of loose myxoid stroma (Fig 1) composed of wavy collagen fibrils. The cells have abundant wispy pink cytoplasm with bland nuclei. There is no cytologic atypia, no atypical mitotic features or discernible mitotic activity and no evidence of coagulative tumor cell necrosis either. The lesion often also shows numerous blood vessels of varying caliber [3]. The stromal cells can show immunoreactivity to different combinations of vimentin, desmin, smooth muscle actin, muscle specific actin, CD 34, estrogen and progesterone receptors [9]. Recurrent tumors usually show similar histological characteristics.

#### *Angiomyxoma genetics*

Chromosomal abnormality involving chromosome 12, associated with rearrangement of HMGIC gene, has been reported in cases of AA [10]. On one hand the lack of consistent HMGIC expression in the vascular component and on the other hand very high frequency of HMGIC expression in the spindled stromal cells might suggest that this is the true neoplastic component and that the admixture of blood vessels may be a secondary phenomenon. Localization of HMGIC to neoplastic stromal cells of aggressive angiomyxoma by immunohistochemistry might be applied as a diagnostic tool in assessing margins status, which might be extremely difficult to assess on morphologic grounds alone [10].

#### *Tumour characteristics and surgical management*

Angiomyxomas are locally aggressive tumors and distant metastasis has only been reported in two occasions [4, 5]. In view of the high risk of local recurrence, wide local excision with tumor-free margins was initially thought to be the treatment of choice. Re-excisions, if the initial surgery was deemed incomplete, were also advocated. Involvement of bladder, gastrointestinal tract and bone has been described with angiomyxomas and in such situations extensive surgical resection, with significant operative morbidity, would be necessary to achieve clear margins. A review of over 100 cases however refuted this belief and showed that patients with clear resection margins were as prone to developing recurrences. The chances of remaining disease free were not statistically different from those who had incomplete resection, 50% vs. 40% in 10 years [7]. Also, excluding one case of metastasizing angiomyxoma, these tumors are not life threatening, even primary and recurrent tumors are often asymptomatic. Fertility is also an important factor as most of these tumors occur in women of the reproductive age group and radical resection in such situations may not be the best option. Thus though complete excision is still the aim, incomplete removals are acceptable when high operative morbidity is anticipated and fertility preservation is an issue [7].

#### *Adjuvant therapies*

Most of these tumors show estrogen and progesterone receptor positivity [11] and are likely to be hormone dependant. Hormonal manipulation is thus thought to be a viable treatment option. GnRH analogues have been used in a few instances in premenopausal women with AA [12] but re-growth of tumor can occur, as in one of our patients, once therapy is discontinued. Pre-operative shrinking of tumors using GnRH analogues might increase chances of complete excision and minimize the radicality of surgical procedure [13]. One patient treated with tamoxifen however continued to have tumor growth in spite of ongoing treatment [14].

Due to low mitotic activity radiotherapy or chemotherapy is unlikely to be a useful adjunct to primary surgery [15]. We could find no reports of use of chemotherapy in

treatment of AA. Pre-operative external beam irradiation and intra-operative electron beam radiotherapy was used in one case to reduce risk of recurrence but follow-up data on the same is not available [16]. Two cases of successful control of recurrent angiomyxoma with relatively high doses of external radiotherapy have also been reported [17, 18].

Angiographic embolization has also been attempted to shrink the tumor pre-operatively and thus increase the chances of complete removal [16]. The fact that the tumor might derive its blood supply from multiple sources rather than a singular feeding vessel would reduce the success of such procedure [7].

Equally, a trial of watchful waiting in case of asymptomatic patients with recurrent tumors or with large tumors where surgery carries significant morbidity might be a reasonable option [19].

Recurrence is one of unique characteristics of these otherwise non-malignant tumors. The usual sites of recurrence reflect the sites of the primary disease i.e. perineum, pelvis, ischio-rectal fossa and retro-peritoneum. No definite relation between patient's age and size of tumor and rate of recurrence has been established so far [7]. Recurrences generally occur in the first 5 years after primary surgery, about 70% in the first 3 years, but late recurrences up to 14 years have been reported. Follow-up should be clinical supplemented by radiological investigations; especially MRI scans [8].

#### *Angiomyxomas and pregnancy*

Though angiomyxomas are common in the reproductive age group women, very few reports are available to clearly define their behavior in pregnancy. There is one report of recurrence of previously treated angiomyxoma in a woman during her pregnancy [20]. One of our patients, while being followed up for recurrent disease became pregnant. The lesion was followed up throughout her pregnancy with MRI scans showing only marginal increase in size. This could be attributable to the hormone dependency of these tumors.

## Conclusion

Aggressive angiomyxomas are rare, locally aggressive tumors, arising mainly in the female pelvis with a high likelihood of recurrence even after complete surgical excision. Pre operative diagnosis is difficult due to its rarity and lack of characteristic features. Hence, AA should be considered a possibility in case of atypical mass lesion in the female pelvis or perineum. Few management options are available and multimodal therapy may be a good option. Patient counseling, multi disciplinary approach and individualization of each case and follow-up are essential for adequate management.

## References

- [1] Fetsch JF, Laskin WB, Lefkowitz M, Kindblom LG, Aggressive angiomyxoma: a clinicopathologic study of 29 female patients. *Cancer* 1996; 78:79–90
- [2] Idrees MT, Hoch BL. Aggressive angiomyxoma of male genital region. Report of 4 cases with immunohistochemical evaluation including hormone receptor status. *Ann Diagnostic Pathology* 2006 Aug;10(4):197-204
- [3] Steeper TA, Rosai J. Aggressive angiomyxoma of the female pelvis and perineum. Report of 9 cases of a distinctive type of gynecologic soft tissue neoplasm. *Am J Surg Pathol* 1983; 7; 463-475.
- [4] Siassi RM, Papadopoulos T. Metastasizing aggressive angiomyxoma. *The NEJM*. 1992 Dec; 341: 1772
- [5] Blandamura S, Cruz J aggressive angiomyxoma: a second case of metastasis with patient's death. *Human Pathol*. 2003 Oct; 34: 1072.
- [6] Aye C, Jefferis H A case of multi-modal managed vulval aggressive angiomyxoma diagnosed before conception and monitored during pregnancy. *Gynecol Oncol* 2009
- [7] Chan IM, Hon E. aggressive angiomyxoma in females: is radical resection the only option? *Acta Obstet Gynecol Scand* 2000; 79: 216–220
- [8] Jayadevan NN, Shoaib SAA. Imaging features of aggressive angiomyxoma. *Clinical radiology* 2002; 58: 157- 162.
- [9] Smith HO, Worrell RV, Smith AY, Dorin MH, Rosenberg RD Aggressive angiomyxoma of the female pelvis and perineum: review of the literature. *Gynecol Oncol* 1991; 42: 79–85.
- [10] Nucci MR, Weremowicz S. Chromosomal translocation t(8:12) induces aberrant HMGIC expression in angiomyxoma of vulva. *Genes, Chromosomes & Cancer* 2001; 32: 172-176.
- [11] Amezcua Ca, Begley SJ. Aggressive angiomyxoma of the female tract: A clinic-pathologic and immunohistochemical study of 12 cases. *Int J Gynecol Cancer* 2005; 15: 140-145.
- [12] McCluggage WG, Jamieson T. Aggressive angiomyxoma of vulva: dramatic response to gonadotropin-releasing hormone agonist therapy. *Gynecol Oncol*. 2006 Mar; 100(3): 623-5
- [13] Sereda D, Sauthier P. Aggressive angiomyxoma of the vulva: a case report and review of the literature. *J Low Genit Tract Dis*. 2009;13 (1): 46-50.
- [14] Magtibay PM, Salmon Z. Aggressive angiomyxoma of the female pelvis and perineum: A case series *Int J Gynecol Cancer* 2006; 16: 396-401.
- [15] Fetsch JF, Laskin WB. Aggressive angiomyxoma: A clinic-pathologic study of 29 female patients. *Cancer* 1996; 78: 79-90.

- [16] Nyam DCK, Pemberton J. Large aggressive angiomyxoma of the perineum and pelvis: An alternative approach. *Diseases of the colon and rectum* 1998; 41(4): 514-516.
- [17] Rhomberg W, Jasarevic Z. Aggressive angiomyxoma: Irradiation for recurrent disease. *Strahlentherapie und Onkologie* 2000; 176(7): 324-326.
- [18] Suleiman M, Duc C. Pelvic excision of large angiomyxoma in a woman: Irradiation for recurrent disease. *Int J Gynecol Cancer* 2006; 16(S1): 356-360.
- [19] Behranwala KA, Thomas JM. Aggressive angiomyxoma: A distinct clinical entity. *Eur J Surgical Oncol*; 29(7): 559-563.
- [20] Fishman A, Otey LP, Poindexter AN. Aggressive angiomyxoma of the pelvis and perineum. A case report. *J Reprod Med.* 1995; 40: 665–669.

**Table 1: Summary of patients with aggressive angiomyxoma (AA):**

| C<br>a<br>s<br>e | Original presentation & size   | Age at initial presentation | Location   | Surgical Treatment / Outcome   | Resection Margins | Adjuvant treatment                               | DFI/ number of recurrences  |
|------------------|--|-----------------------------|--|--|-------------------|--|---|
| 1                | Right sided 3 cm vulva swelling  | 22                          | Right vulva & vagina extending into Right ischiorectal - fossa & levator ani (Fig 2) | 3 * WLE / successful pregnancy after third surgery, currently stable size & awaiting | Positive          | GnRH analogue after the first and second surgery | 5 months after first WLE / 3 recurrences  |
| 2                | 8 cm Lt vulval lesion with unsuccessful initial GnRH analogue treatment        | 47                          | Left vulva and perineum  | WLE + 3 subsequent perianal abscesses drained  | Positive          | N  | 26 months / none  |
| 3                | Bowel habit changes, urinary urgency, bulky uterus, 8-9 cm pelvic mass on exam | 58                          | Left paravesical   | Laparotomy & excision of paravesical mass.   | Positive          | N  | 11 months / none  |
| 4                | 5 year intermittent swelling in perineum with 8 cm mass on palpation           | 46                          | Left paravaginal and perineal area   | Abdomino-perineal excision   | Positive          | N  | 16 months / none  |
| 5                | Anterior vaginal wall mass   | 49                          | Anterior vaginal wall  | WLE followed by VH and second WLE in 2 months  | Negative          | N  | 48 months / none  |
| 6                | Recurrent left Bartholin's cyst diagnosed as AA after a year                   | 44                          | Left vulva   | WLE  | Positive          | GnRH analogues to shrink recurrent tumour        | First recurrence at 24 months, currently 9 cm extending into left ischiorectal- fossa |
| 7                | Mistaken as cystocele,   | 48                          | Vulvo-vaginal mass   | WLE  | Positive          | N  | 48 months / none  |

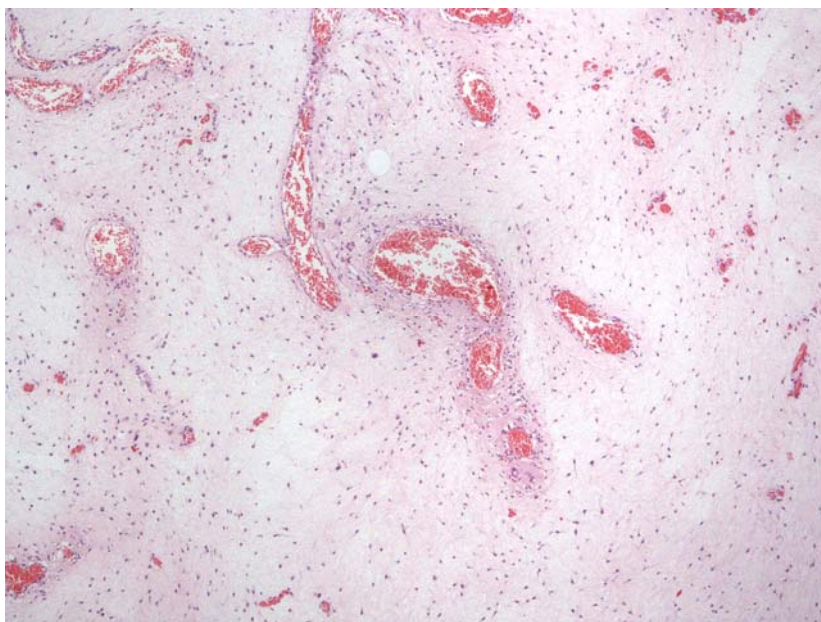
GnRH analogue : gonadotropin-releasing hormone agonist therapy; DFI: disease Free Interval ; WLE: Wide Local Excision

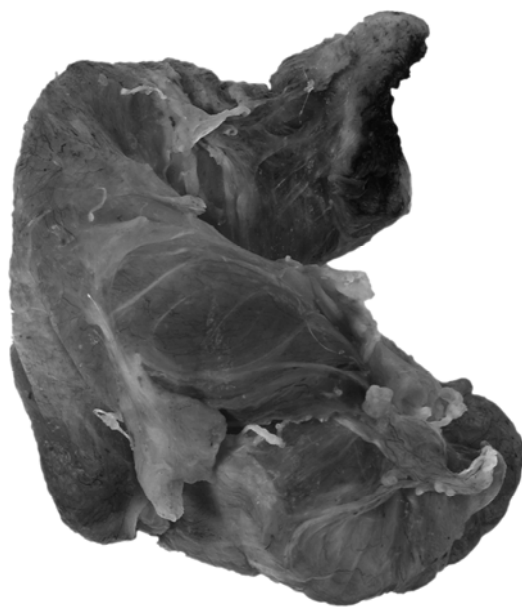
**Captions**

Fig 1- Microscopic appearance: The hypo cellular stroma and abundance of blood vessels of varying calibre are evident.

Fig 2- Macroscopic appearance: perineal angiomyxoma resected at initial surgery, Case 1 of our series.







ACCEPTED MANUSCRIPT