



HAL
open science

The role of FDG PET/CT in patients with locoregional breast cancer recurrence; a comparison to conventional imaging techniques

Tjeerd S. Aukema, Emiel J.Th. Rutgers, Wouter V. Vogel, Hendrik J. Teertstra, Hester S. Oldenburg, Marie-Jeanne T.F.D. Vrancken Peeters, Jelle Wesseling, Nicola S. Russell, Renato A. Valdés Olmos

► **To cite this version:**

Tjeerd S. Aukema, Emiel J.Th. Rutgers, Wouter V. Vogel, Hendrik J. Teertstra, Hester S. Oldenburg, et al.. The role of FDG PET/CT in patients with locoregional breast cancer recurrence; a comparison to conventional imaging techniques. *EJSO - European Journal of Surgical Oncology*, 2010, 36 (4), pp.387. <10.1016/j.ejso.2009.11.009>. <hal-00576161>

HAL Id: hal-00576161

<https://hal.science/hal-00576161v1>

Submitted on 13 Mar 2011

HAL is a multi-disciplinary open access archive for the deposit and dissemination of scientific research documents, whether they are published or not. The documents may come from teaching and research institutions in France or abroad, or from public or private research centers.

L'archive ouverte pluridisciplinaire HAL, est destinée au dépôt et à la diffusion de documents scientifiques de niveau recherche, publiés ou non, émanant des établissements d'enseignement et de recherche français ou étrangers, des laboratoires publics ou privés.



HAL Authorization

Accepted Manuscript

Title: The role of FDG PET/CT in patients with locoregional breast cancer recurrence; a comparison to conventional imaging techniques

Authors: Tjeerd S. Aukema, Emiel J.Th. Rutgers, Wouter V. Vogel, Hendrik J. Teertstra, Hester S. Oldenburg, Marie-Jeanne T.F.D. Vrancken Peeters, Jelle Wesseling, Nicola S. Russell, Renato A. Valdés Olmos

PII: S0748-7983(09)00517-4

DOI: [10.1016/j.ejso.2009.11.009](https://doi.org/10.1016/j.ejso.2009.11.009)

Reference: YEJSO 2920


To appear in: *European Journal of Surgical Oncology*

Received Date: 23 September 2009

Accepted Date: 16 November 2009

Please cite this article as: Aukema TS, Rutgers EJT, Vogel WV, Teertstra HJ, Oldenburg HS, Vrancken Peeters M-JTFD, Wesseling J, Russell NS, Valdés Olmos RA. The role of FDG PET/CT in patients with locoregional breast cancer recurrence; a comparison to conventional imaging techniques, *European Journal of Surgical Oncology* (2009), doi: 10.1016/j.ejso.2009.11.009

This is a PDF file of an unedited manuscript that has been accepted for publication. As a service to our customers we are providing this early version of the manuscript. The manuscript will undergo copyediting, typesetting, and review of the resulting proof before it is published in its final form. Please note that during the production process errors may be discovered which could affect the content, and all legal disclaimers that apply to the journal pertain.



Original article

The role of FDG PET/CT in patients with locoregional breast cancer recurrence; a comparison to conventional imaging techniques.

Tjeerd S Aukema ^a, Emiel J.Th. Rutgers ^b, Wouter V. Vogel ^a, Hendrik J Teertstra ^c, Hester S. Oldenburg ^b, Marie-Jeanne T.F.D. Vrancken Peeters ^b, Jelle Wesseling ^d, Nicola S Russell ^e, Renato A. Valdés Olmos ^a

^a Department of Nuclear Medicine, ^b Department of Surgery, ^c Department of Radiology, ^d Department of Pathology, ^e Department of Radiotherapy; The Netherlands Cancer Institute - Antoni van Leeuwenhoek Hospital, Amsterdam, The Netherlands

Corresponding author:

Tjeerd S. Aukema

Netherlands Cancer Institute - Antoni van Leeuwenhoek Hospital

Plesmanlaan 121

1066 CX Amsterdam

The Netherlands

Tel: + 31 20 5122282

Fax: +31 20 5122290

E-mail: t.aukema@nki.nl

Abstract

Purpose: The aim of this study was to evaluate the impact of ^{18}F -fluorodeoxyglucose positron emission tomography/ computed tomography (FDG PET/CT) on clinical management in patients with locoregional breast cancer recurrence amenable for locoregional treatment and to compare the PET/CT results with the conventional imaging data.

Patients and methods: From January 2006 to August 2008, all patients with locoregional breast cancer recurrence underwent whole-body PET/CT. PET/CT findings were compared with results of the conventional imaging techniques and final pathology. The impact of PET/CT results on clinical management was evaluated based on clinical decisions obtained from patient files.

Results: 56 patients were included. In 32 patients (57%) PET/CT revealed additional tumour localisations. Distant metastases were detected in 11 patients on conventional imaging and in 23 patients on PET/CT images ($p < 0.01$). In 25 patients (45%), PET/CT detected additional lesions not visible on conventional imaging. PET/CT had an impact on clinical management in 27 patients (48%) by detecting more extensive locoregional disease or distant metastases. In 20 patients (36%) extensive surgery was prevented and treatment was changed to palliative treatment. The sensitivity, specificity, accuracy, positive and negative predictive values of FDG PET/CT were respectively 97%, 92%, 95%, 94% and 96%.

Conclusions: PET/CT, in addition to conventional imaging techniques, plays an important role in staging patients with locoregional breast cancer recurrence since its result changed the clinical management in almost half of the patients. PET/CT could potentially replace conventional staging imaging in patients with a locoregional breast cancer recurrence.

Key words:

Breast Cancer; Neoplasm Staging; Patient Management; Positron-Emission Tomography; Recurrence; Surgery.

Introduction

Locoregional breast cancer recurrence occurs in about 10% of all breast cancer patients,¹ with a 5-year survival rate of approximately 60%.² Curative local treatment remains an option if the recurrence is truly locoregional. Even patients with locally advanced breast cancer recurrences can be treated with lasting local control, provided that there are no distant metastases.³ Therefore, adequate and accurate staging of the recurrence is imperative for optimal treatment of these patients.

At the Netherlands Cancer Institute / Antoni van Leeuwenhoek Hospital (NKI / AVL) conventional staging procedures in patients with locoregional breast cancer recurrence generally consists of physical examination to evaluate the local-regional situation, magnetic resonance imaging-scan (MRI) for local –regional evaluation and a chest radiograph, liver ultrasound or computed tomography (CT) scan and a bone scan, to diagnose potential distant metastases. With these conventional imaging techniques , approximately 10% of the patients will show overt distant metastases at the time of diagnosis of the locoregional breast cancer recurrence.^{4,5} However, the performance of this diagnostic strategy appears to be suboptimal since approximately 40% of patients will be diagnosed with distant metastases within 5 years.^{2,5-7}

¹⁸F-fluorodeoxyglucose positron emission tomography (FDG PET) was found to be a sensitive modality in the assessment of breast cancer recurrence with a sensitivity ranging from 89-100%.⁸⁻¹¹ Unfortunately the lack of anatomic information of FDG PET alone may affect its specificity.^{12,13} The recently introduced integrated PET/CT can provide both morphologic and metabolic information, by combining anatomic CT data and functional FDG PET data. Since FDG PET/CT is not organ specific and provides a whole body overview, it can potentially replace the array of conventional imaging.

This retrospective study evaluates the diagnostic performance of FDG PET/CT, compared to conventional imaging techniques, and evaluates the impact of these results on clinical management of patients with a confirmed locoregional breast cancer recurrence.

ACCEPTED MANUSCRIPT

Patients and Methods

Patients

From January 2006 until August 2008, 56 patients underwent total body FDG PET/CT imaging because of a confirmed locoregional breast cancer recurrence at the NKI-AVL. All recurrences were confirmed by fine needle aspiration or core needle biopsy. Because extensive locoregional surgery was deemed necessary, patients were referred to visualise the extent of the recurrence and to exclude metastatic disease. The patient's age and tumour stage at primary diagnosis of breast carcinoma, the initial treatment and subsequent interval before the first recurrence were retrieved from the patients' files.

FDG PET/CT

From January 2006 until August 2006 a PET/CT (Biograph2, Siemens, Erlangen, Germany) was used and FDG was administered in doses of 300-400MBq. From September 2006 a different PET/CT (Gemini TF, Philips, Eindhoven, The Netherlands) was used with 180-240 MBq FDG. Patients fasted for 6 hours prior to imaging. Diabetes mellitus was regulated in advance, with plasma glucose < 10 mmol/l. The interval between FDG administration and scanning was 60 minutes +/- 10 minutes. Low-dose CT images (40 mAs, 5 mm slices) were acquired without oral or intravenous contrast.

The images generated (PET/CT, low dose CT and PET) were displayed using an Osirix Dicom viewer in a Unix-based operating system (MAC OS X, Power G5, Apple, Cupertino, CA, USA) and were evaluated on the basis of two-dimensional orthogonal reslicing.

Increased FDG uptake not corresponding to physiological uptake patterns was recorded as positive for malignancy.

Clinical management

Patients underwent physical examination and conventional imaging was (partially) performed consisting of: MRI of the thoracic wall, chest radiograph or CT scan, liver ultrasound and bone scintigraphy. These different conventional imaging modalities were performed according to the preference of the referring surgeon. Imaging performed as a result of findings on FDG PET/CT was not considered to be part of conventional imaging work up and was subsequently not compared to the FDG PET/CT results. The diagnostic performance of conventional staging was compared with the results obtained from FDG PET/CT imaging. The impact of FDG PET/CT on clinical management was evaluated on the basis of clinical decisions obtained from patient files that were solely based on new findings from the PET/CT scan.

Reference standard

Histopathological verification served as the golden standard. The final diagnosis of additional lesions detected was established by fine needle aspiration and / or histological biopsy. If no histopathological result was obtained, additional imaging and/or clinical follow up accomplished the evaluation of new lesions detected on PET/CT scan.

Statistical analysis

Statistical analyses were performed by using SPSS 15 (Version 15, for Windows, SPSS Inc, Chicago, IL, USA). Sensitivity, specificity, positive predictive value, and negative predictive value were evaluated by standard methods. To calculate the difference between conventional imaging and FDG PET/CT regarding the ability to detect malignant distant metastases the chi-square test was used. $P < 0.05$ was considered statistically significant.

Results

Patient characteristics

The median age at the time of primary breast carcinoma was 48 years (range 27-74). The median time to recurrence was 4.0 years (range 0.4 – 17.8 years). The characteristics of the original primary tumours and the initial treatments are summarized in Table 1.

Conventional Imaging.

Besides FDG PET/CT imaging, 21 patients underwent MRI of the chest, 32 patients underwent chest radiography, 20 patients underwent a diagnostic CT of the chest, 35 patients underwent bone scintigraphy and 30 patients underwent ultrasound of the liver. Conventional imaging revealed distant metastases in 11 patients. The results of the conventional imaging are summarized in Table 2.

FDG PET/CT

The results of all FDG PET/CT scans (n=56) are demonstrated in a flowchart (Figure 1). In 53 patients FDG PET/CT was positive at the location of the proven locoregional breast cancer recurrence; in 3 patients the FDG PET/CT images were negative. Besides the locoregional recurrence, FDG PET/CT detected additional lesions in 32 patients (57%). The locations of these lesions were: the neck in 6 patients, the chest in 28 patients, in the abdomen in 10 patients and the pelvic area in 6 patients. This included a total of 30 new lymph node localisations, 20 skeletal sites, and 8 organ sites. The sites are further specified in Table 3. FDG PET/CT imaging revealed distant metastases in 23 patients.

Malignant involvement of the lesions identified was confirmed by histopathology (n = 14), further imaging or clinical follow-up with a mean period of 13.4 months. There were 2 false positive findings (4%), confirmed by further imaging and pathology, and 1 false negative case

(2%), with a metastasis in the bladder, resulting in a sensitivity of 97% and specificity of 92% for the presence of metastases. Detailed results on the diagnostic performance of FDG PET/CT are presented in Table 4.

FDG PET/CT versus conventional imaging

Diagnostic CT of the chest detected a small lung lesion in one patient which was not detected by FDG PET/CT. In all other patients, all confirmed lesions detected by conventional imaging were also visible on FDG PET/CT images. In 12 of the 32 patients (38%) with additional lesions on FDG PET/CT, none of conventional imaging modalities could detect all of the FDG PET/CT positive lesions. Furthermore, FDG PET/CT detected additional lesions in 13 patients who received partial conventional imaging. Distant metastases were detected in 11 patients on conventional imaging and in 23 patients on FDG PET/CT images ($p < 0.01$). Bone scintigraphy appeared to be false positive in 5 out of the 13 positive patients (38%) after evaluation by MRI.

Clinical impact of FDG PET/CT

In 56 patients who were clinically eligible for curative surgery of the local recurrence, FDG PET/CT findings changed the management of 27 patients (48%), 21 of whom received all conventional imaging modalities while 6 had partial conventional imaging. Palliative chemotherapy was started in 20 patients, these patients were not treated with surgery of the local recurrence. Radiotherapy only was given to 3 patients. Three patients underwent neoadjuvant chemotherapy prior to surgery, and in 1 patient a contralateral axillary lymph node dissection was performed. In 5 patients new lesions detected by PET/CT did not affect clinical management.

Discussion

Patients with locoregional breast cancer recurrence can be treated adequately with surgery.

The clinical management and prognosis of these patients are mainly based on the extent of the locoregional recurrence and the presence of distant metastases.^{2,3,14,15} Therefore, accurate staging is essential for surgical treatment of patients with a locoregional recurrence.

The sensitivity of conventional imaging techniques for the detection of distant metastases in breast cancer patients ranges from 32%-43%.¹⁶⁻¹⁸ Reasons why conventional imaging may not reliably detect the extent of the recurrence include the potentially small size of lesions and the inability to differentiate tumour from scar tissues after prior treatments. Moreover, conventional imaging is focused on detecting lesions in specific organs or sites of the body. FDG PET provides metabolic information and is able to screen the whole body. Several studies demonstrated that FDG PET is a sensitive tool in the detection of breast cancer recurrence in patients with a suspicion of breast cancer recurrence.^{10,19,20} FDG PET however, lacks accurate anatomical localization and morphological characterization of metastases which could be overcome by using integrated PET/CT.

Distant metastases from breast cancer patients most frequently occur in the skeleton.^{21,22} Until recently bone scintigraphy was the primary diagnostic tool to detect these metastases. An early study by Cook et al²³ showed that FDG PET is superior to bone scintigraphy in the detection of osteolytic breast cancer metastases while osteoblastic metastases are more frequently detected by bone scintigraphy. However, several more recent studies demonstrated that FDG PET (CT) is more accurate than bone scanning for the detection of both osteolytic and osteoblastic lesions.^{17,24-26} In the present study PET/CT detected all true positive lesions which were visible on bone scintigraphy and depicted other bone metastases not visible on bone scintigraphy. Moreover, the false positive rate of PET/CT (4%) was lower than that of bone scintigraphy (38%). These results suggest that bone scintigraphy could be replaced by

FDG PET/CT as initial modality for detection of distant metastases in the work-up of breast cancer patients. However, this study was not designed to compare these two modalities.

Prospective studies should be designed to definitively prove this hypothesis.

Several studies demonstrated that FDG PET is superior to chest radiography for the detection of pulmonary metastases.^{16,17} Integrated FDG PET/CT could potentially further increase the sensitivity of detecting distant metastases in the chest compared to chest radiography and consequently replace the chest radiography as a diagnostic tool to detect distant metastases in patients with breast cancer recurrence. In the present study chest radiography detected two lesions which were also visible on FDG PET/CT.

Recently Mahner et al¹⁷ suggested that FDG PET/CT could potentially replace conventional imaging techniques and detect distant metastases in primary breast cancer patients with sufficient accuracy. Our results with confirmed breast cancer recurrence are in line with this suggestion. All but one metastases detected by conventional imaging were also positive on FDG PET/CT. The only missed lesion by FDG PET/CT and detected by CT, a small lesion located in the lung in a patient with bone metastases, did not have clinical consequences for the patient. In addition, FDG PET/CT can perform a whole body evaluation in one single session which can contribute to appropriate and timely evaluation of possible distant metastases.

This study demonstrates that FDG PET/CT can detect distant metastases not visible on conventional imaging in patients with a confirmed locoregional breast cancer recurrence. The clinical management of 48% of the included patients was changed. In 36% of the patients extensive local surgery deemed not relevant and consequently these patients were treated with palliative systemic treatment. Furthermore, FDG PET/CT may be useful for the planning of axillary surgery. Albeit the sensitivity of FDG PET/CT to detect axillary lymph node metastases is moderate, its specificity ranges from 95%-100%.^{27,28} Therefore, direct axillary

lymph node dissection can be performed in case of positive axillary lymph nodes on FDG PET/CT.²⁹

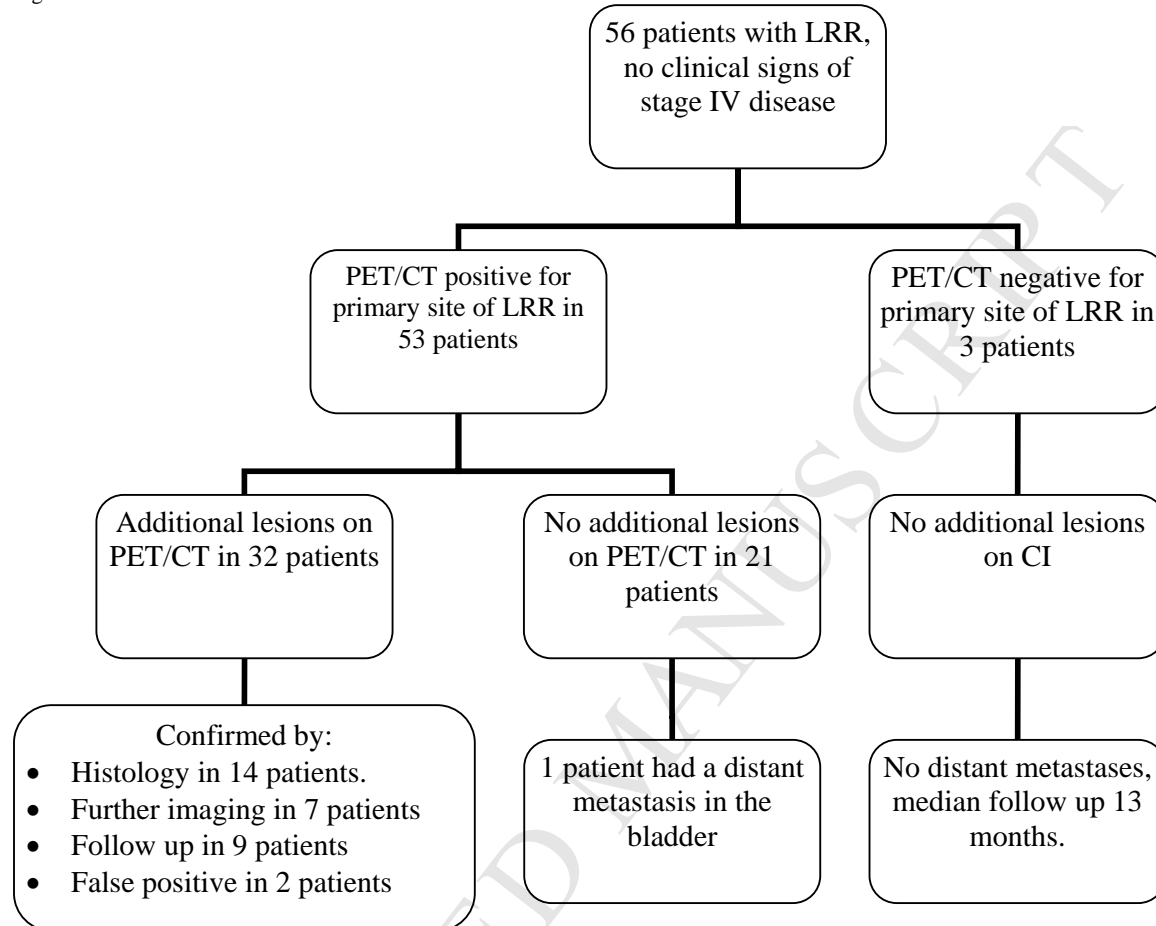
Some limitations of our study should be acknowledged. First, this study is a retrospective evaluation. Although our data were collected from original patients' files, the bias associated with a retrospective study remained. This type of study will inevitably be hampered by selection bias. However, the results are novel and justify further proper studying. Second, not all of the patients included underwent the full conventional work-up. This entangles the comparison between FDG PET/CT and conventional imaging. To avoid these two limitations prospective studies should be conducted, to confirm the hypothesis that FDG PET/CT can replace all other conventional imaging in patients where a search for distant disease is considered to be relevant: in patients with locoregional recurrence and stage III disease. In conclusion, FDG PET/CT, which adjusted clinical management in almost half of the patients in these series, plays an important role in the staging of patients with confirmed locoregional breast cancer recurrence. FDG PET/CT could potentially replace conventional staging imaging in patients with a locoregional breast cancer recurrence, and thus spare a significant proportion extensive but futile local treatment.

Conflict of interest statement

The authors declare no conflict of interest.

Figure

Figure 1. Flowchart of the results of FDG PET/CT.



Abbreviations: LRR, locoregional recurrence; CI, conventional imaging

Reference List

- (1) Voogd AC, Nielsen M, Peterse JL et al. Differences in risk factors for local and distant recurrence after breast-conserving therapy or mastectomy for stage I and II breast cancer: pooled results of two large European randomized trials. *J Clin Oncol* 2001;**19**(6):1688-97.
- (2) van Tienhoven G, Voogd AC, Peterse JL et al. Prognosis after treatment for loco-regional recurrence after mastectomy or breast conserving therapy in two randomised trials (EORTC 10801 and DBCG-82TM). EORTC Breast Cancer Cooperative Group and the Danish Breast Cancer Cooperative Group. *Eur J Cancer* 1999;**35**(1):32-8.
- (3) Aukema TS, Russell NS, Wesseling J, Rutgers EJ. Extensive soft tissue resection with autologous tissue closure for locally recurrent breast cancer: lasting local control and acceptable morbidity. *Eur J Surg Oncol* 2009;**35**(5):469-74.
- (4) van Oost FJ, van der Hoeven JJ, Hoekstra OS, Voogd AC, Coebergh JW, van de Poll-Franse LV. Staging in patients with locoregionally recurrent breast cancer: current practice and prospects for positron emission tomography. *Eur J Cancer* 2004;**40**(10):1545-53.
- (5) Voogd AC, van Tienhoven G, Peterse HL et al. Local recurrence after breast conservation therapy for early stage breast carcinoma: detection, treatment, and outcome in 266 patients. Dutch Study Group on Local Recurrence after Breast Conservation (BORST). *Cancer* 1999;**85**(2):437-46.
- (6) Haffty BG, Fischer D, Beinfield M, McKhann C. Prognosis following local recurrence in the conservatively treated breast cancer patient. *Int J Radiat Oncol Biol Phys* 1991;**21**(2):293-8.
- (7) Halverson KJ, Perez CA, Kuske RR, Garcia DM, Simpson JR, Fineberg B. Survival following locoregional recurrence of breast cancer: univariate and multivariate analysis. *Int J Radiat Oncol Biol Phys* 1992;**23**(2):285-91.
- (8) Gallowitsch HJ, Kresnik E, Gasser J et al. F-18 fluorodeoxyglucose positron-emission tomography in the diagnosis of tumor recurrence and metastases in the follow-up of patients with breast carcinoma: a comparison to conventional imaging. *Invest Radiol* 2003;**38**(5):250-6.
- (9) Grahek D, Montravers F, Kerrou K, Aide N, Lotz JP, Talbot JN. [18F]FDG in recurrent breast cancer: diagnostic performances, clinical impact and relevance of induced changes in management. *Eur J Nucl Med Mol Imaging* 2004;**31**(2):179-88.
- (10) Isasi CR, Moadel RM, Blaufox MD. A meta-analysis of FDG-PET for the evaluation of breast cancer recurrence and metastases. *Breast Cancer Res Treat* 2005;**90**(2):105-12.
- (11) Kamel EM, Wyss MT, Fehr MK, von Schulthess GK, Goerres GW. [18F]-Fluorodeoxyglucose positron emission tomography in patients with suspected recurrence of breast cancer. *J Cancer Res Clin Oncol* 2003;**129**(3):147-53.

- (12) Pelosi E, Messa C, Sironi S et al. Value of integrated PET/CT for lesion localisation in cancer patients: a comparative study. *Eur J Nucl Med Mol Imaging* 2004;**31**(7):932-9.
- (13) Antoch G, Saoudi N, Kuehl H et al. Accuracy of whole-body dual-modality fluorine-18-2-fluoro-2-deoxy-D-glucose positron emission tomography and computed tomography (FDG-PET/CT) for tumor staging in solid tumors: comparison with CT and PET. *J Clin Oncol* 2004;**22**(21):4357-68.
- (14) Abner AL, Recht A, Eberlein T et al. Prognosis following salvage mastectomy for recurrence in the breast after conservative surgery and radiation therapy for early-stage breast cancer. *J Clin Oncol* 1993;**11**(1):44-8.
- (15) Clark GM, Sledge GW, Jr., Osborne CK, McGuire WL. Survival from first recurrence: relative importance of prognostic factors in 1,015 breast cancer patients. *J Clin Oncol* 1987;**5**(1):55-61.
- (16) Dose J, Bleckmann C, Bachmann S et al. Comparison of fluorodeoxyglucose positron emission tomography and "conventional diagnostic procedures" for the detection of distant metastases in breast cancer patients. *Nucl Med Commun* 2002;**23**(9):857-64.
- (17) Mahner S, Schirrmacher S, Brenner W et al. Comparison between positron emission tomography using 2-[fluorine-18]fluoro-2-deoxy-D-glucose, conventional imaging and computed tomography for staging of breast cancer. *Ann Oncol* 2008;**19**(7):1249-54.
- (18) Schirrmeister H, Kuhn T, Guhlmann A, Santjohanser C, Horster T, Nussle K et al. Fluorine-18 2-deoxy-2-fluoro-D-glucose PET in the preoperative staging of breast cancer: comparison with the standard staging procedures. *Eur J Nucl Med* 2001;**28**(3):351-8.
- (19) Radan L, Ben Haim S, Bar-Shalom R, Guralnik L, Israel O. The role of FDG-PET/CT in suspected recurrence of breast cancer. *Cancer* 2006;**107**(11):2545-51.
- (20) Suarez M, Perez-Castejon MJ, Jimenez A et al. Early diagnosis of recurrent breast cancer with FDG-PET in patients with progressive elevation of serum tumor markers. *Q J Nucl Med* 2002;**46**(2):113-21.
- (21) Pivot X, Asmar L, Hortobagyi GN, Theriault R, Pastorini F, Buzdar A. A retrospective study of first indicators of breast cancer recurrence. *Oncology* 2000;**58**(3):185-90.
- (22) Viadana E, Cotter R, Pickren JW, Bross ID. An autopsy study of metastatic sites of breast cancer. *Cancer Res* 1973;**33**(1):179-81.
- (23) Cook GJ, Houston S, Rubens R, Maisey MN, Fogelman I. Detection of bone metastases in breast cancer by 18FDG PET: differing metabolic activity in osteoblastic and osteolytic lesions. *J Clin Oncol* 1998;**16**(10):3375-9.
- (24) Langsteger W, Heinisch M, Fogelman I. The role of fluorodeoxyglucose, 18F-dihydroxyphenylalanine, 18F-choline, and 18F-fluoride in bone imaging with emphasis on prostate and breast. *Semin Nucl Med* 2006;**36**(1):73-92.

- (25) Lonneux M, Borbath I, Berliere M, Kirkove C, Pauwels S. The Place of Whole-Body PET FDG for the Diagnosis of Distant Recurrence of Breast Cancer. *Clin Positron Imaging* 2000;**3**(2):45-9.
- (26) Yang SN, Liang JA, Lin FJ, Kao CH, Lin CC, Lee CC. Comparing whole body (18)F-2-deoxyglucose positron emission tomography and technetium-99m methylene diphosphonate bone scan to detect bone metastases in patients with breast cancer. *J Cancer Res Clin Oncol* 2002;**128**(6):325-8.
- (27) Fuster D, Duch J, Paredes P et al. Preoperative staging of large primary breast cancer with [18F]fluorodeoxyglucose positron emission tomography/computed tomography compared with conventional imaging procedures. *J Clin Oncol* 2008;**26**(29):4746-51.
- (28) Veronesi U, De Cicco C, Galimberti VE et al. A comparative study on the value of FDG-PET and sentinel node biopsy to identify occult axillary metastases. *Ann Oncol* 2007;**18**(3):473-8.
- (29) Aukema TS, Straver ME, Valdes Olmos RA, Vogel WV. A different role for FDG PET/CT in axillary lymph node staging in breast cancer. *Eur J Nucl Med Mol Imaging* 2009;**36**(11):1896-7.

Tables

Table 1. Clinical data of primary breast carcinoma

Number of patients	56
Mean age at primary diagnosis (yrs)	48
Mean age at time of FDG PET/CT scan (yrs)	54
Primary tumour size	
T1	20
T2	18
T3	5
T4	2
Unknown	10
Primary lymph node status	
N0	26
N1	17
N2	5
N3	6
Unknown	1
Primary metastases	
M0	56
M1	0

Table 2. The results of conventional imaging in patients with confirmed breast cancer recurrence.

Imaging modalities	Results
Diagnostic chest CT	20
Positive	4
Negative	16
MRI of the chest	21
Positive	3
Negative	18
Ultrasound of the liver	30
Positive	5
Negative	25
Bone scintigraphy	35
Positive	13
Negative	22
Chest radiography	32
Positive	2
Negative	30

Table 3. Distribution of new tumour localizations detected by FDG PET/CT

Region	Lymph nodes	Skeleton	Organ
Neck	5	1	0
Thorax	21	8	7
Abdomen	4	5	1
Pelvis	0	6	0
Total	30	20	8

Table 4. Diagnostic performance of PET/CT in patients with confirmed breast cancer recurrence.

Parameter	FDG PET/CT
Sensitivity	97%
Specificity	92%
Accuracy	95%
Positive predictive value	94%
Negative predictive value	96%

ACCEPTED MANUSCRIPT